

# **GİNGİVEKTOMİ VE GİNGİVOPLASTİDE YARA İYİLEŞMESİ**

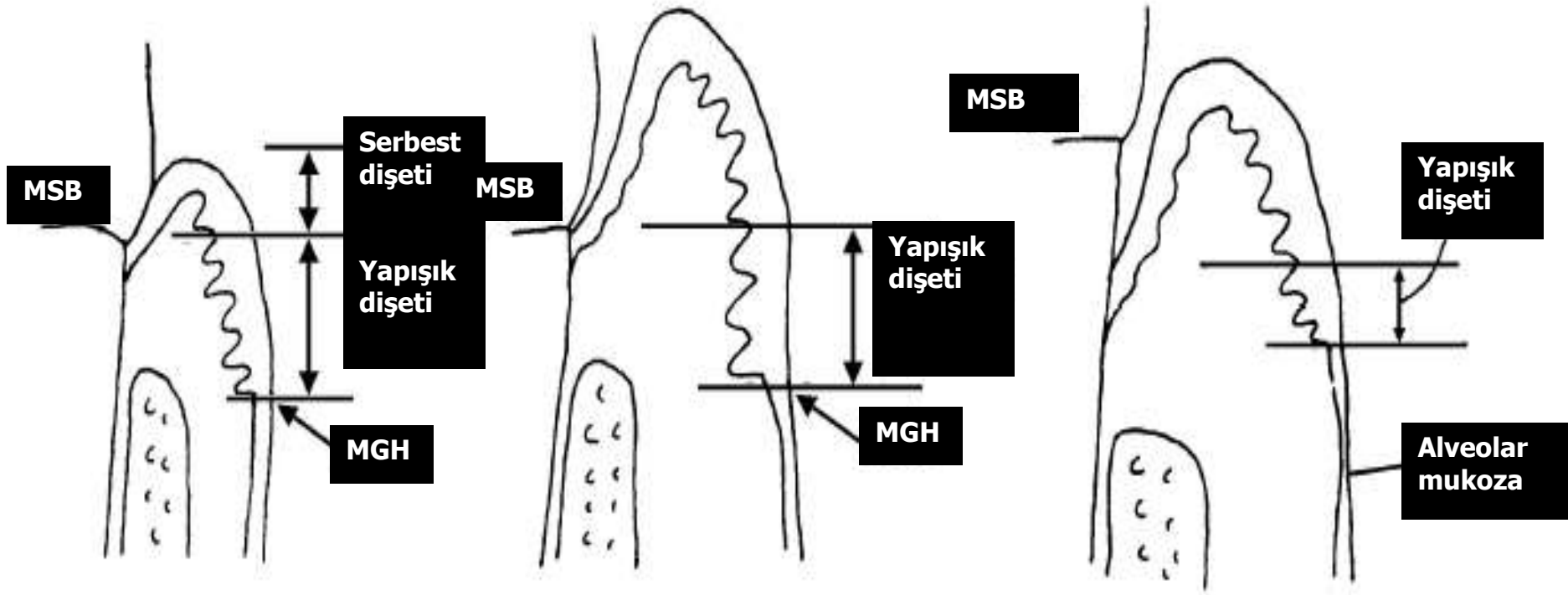
Prof.Dr.Yaşar Aykaç

## **Gingivektomi ve gingivoplasti'de amaç:**

**Fizyolojik dişeti konturunun restorasyonu ile periodontal hastalığın tekrarının engellenmesidir.**

**Gingivektomi: Periodontal cebin yumuşak doku duvarının kesilerek uzaklaştırılması işlemi.**

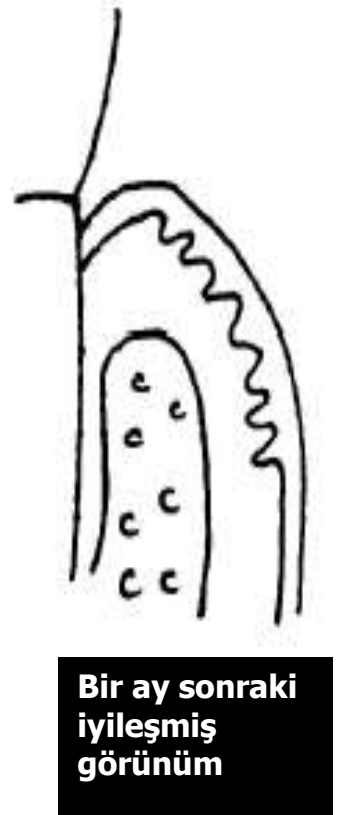
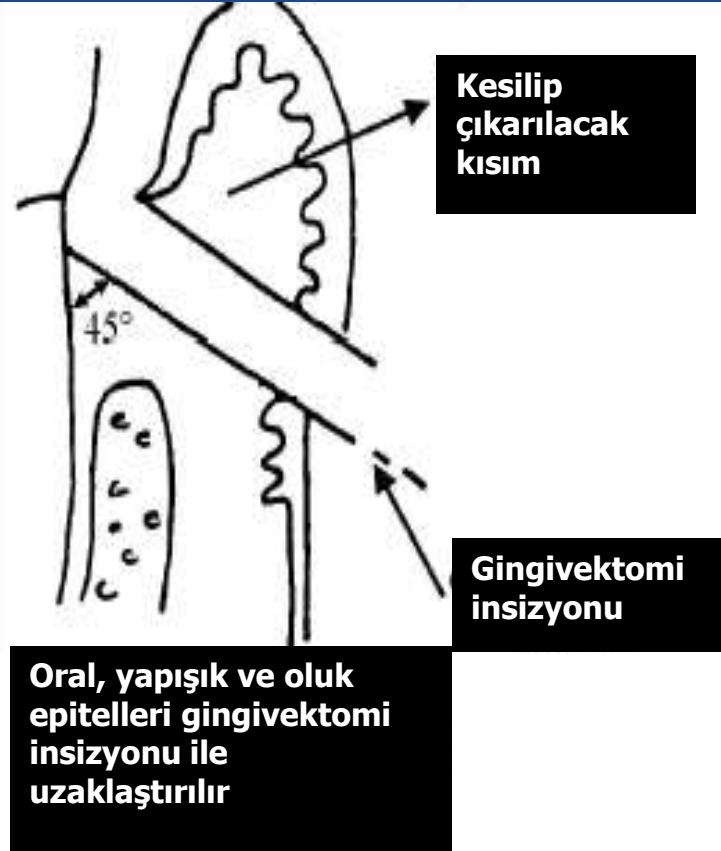
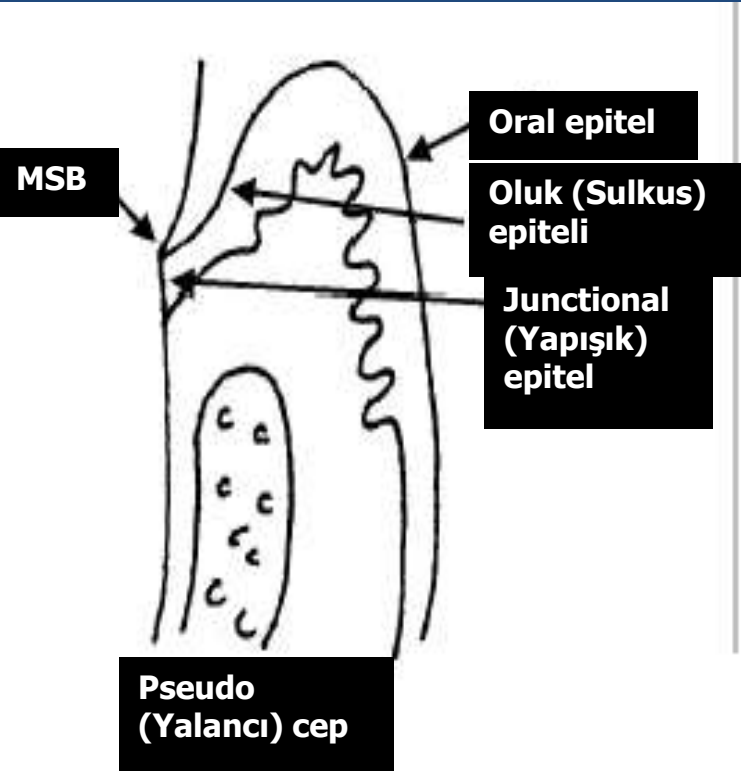
**Gingivoplasti: Dişeti konturunun düzeltilmesi işlemi.**



Normal oluk

Pseudo (Sahte) cep

Gerçek periodontal cep



**Endikasyonları:** \* **Suprabony (kemik üstü) ceplerin eliminasyonu.**

\* **Dişeti büyümelerinin eliminasyonu.**


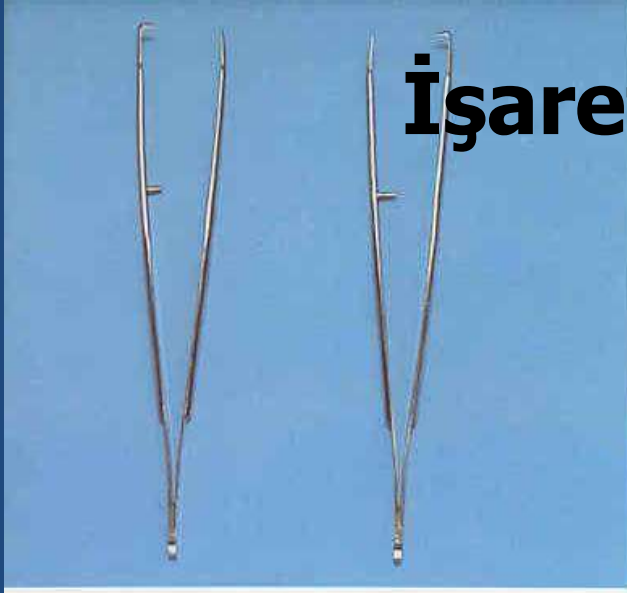
\* **Uyumsuz dişeti konturlarının düzeltilmesinde**

**Kontrendikasyonları:** \* **Kemik cerrahisi gerektiren durumlar.**

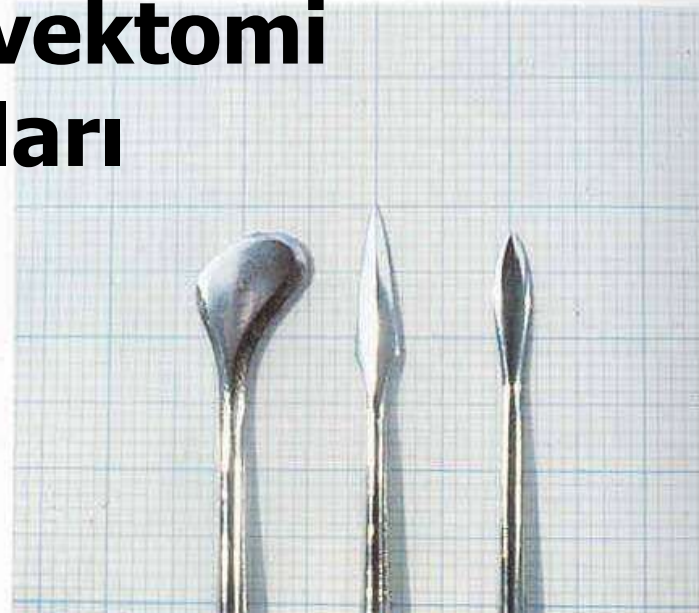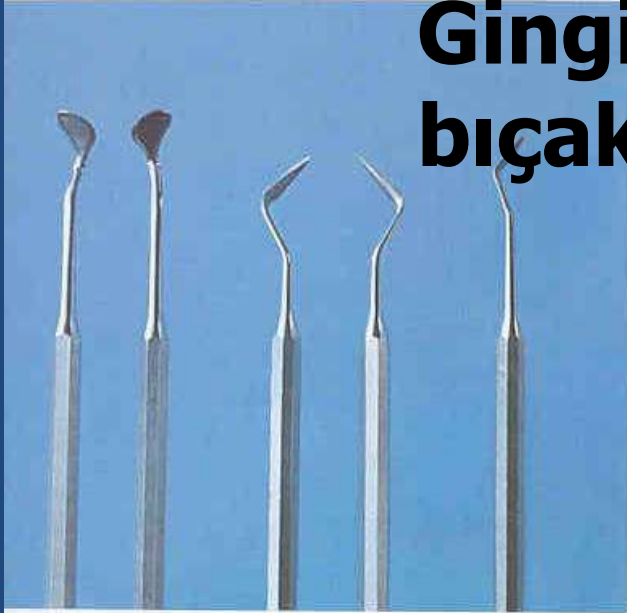\* **Cep tabanının mukogingival hattın apikalinde konumlandığı durumlar**

\* **Estetik problemler**

## İşaretleyiciler



## Gingivektomi bıçakları

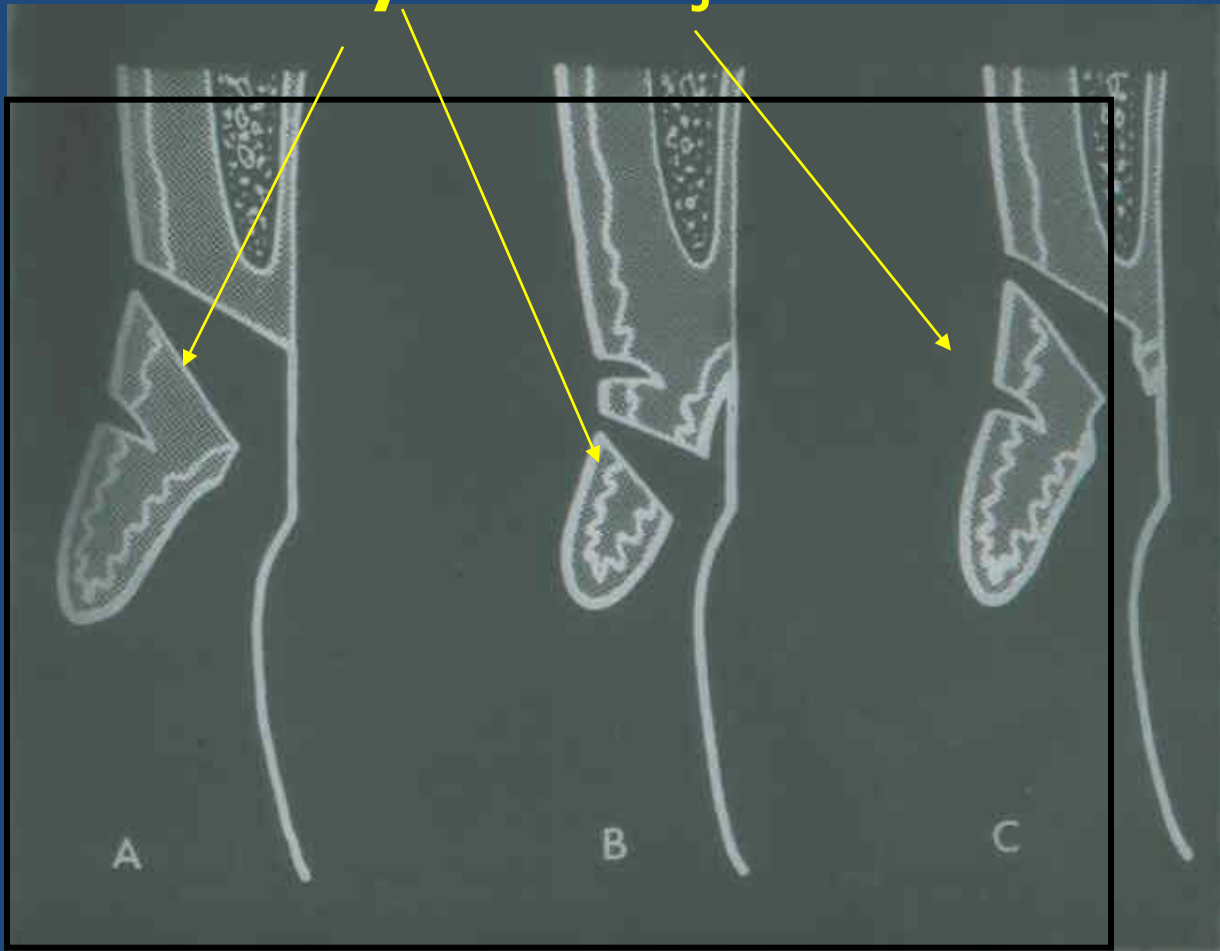


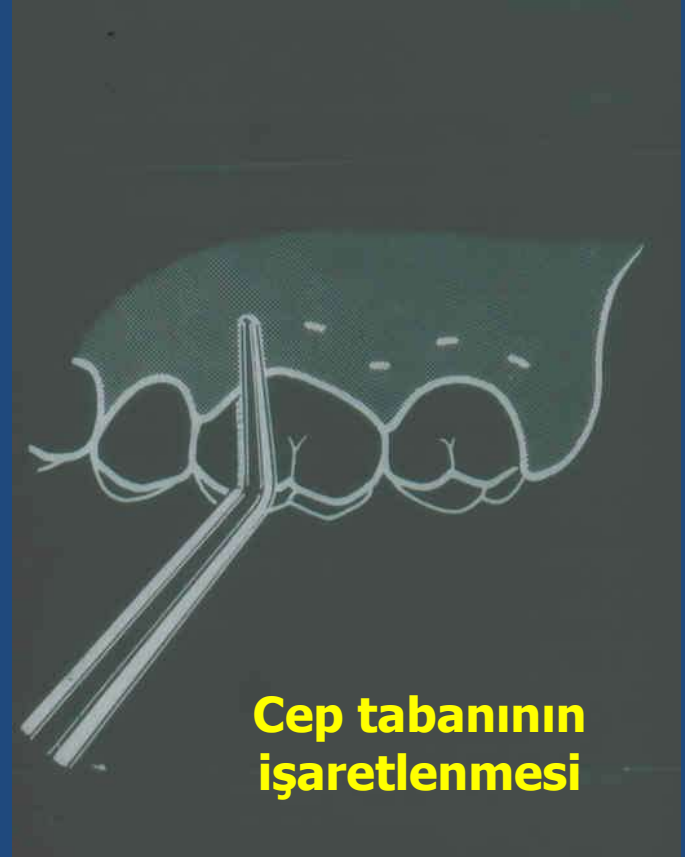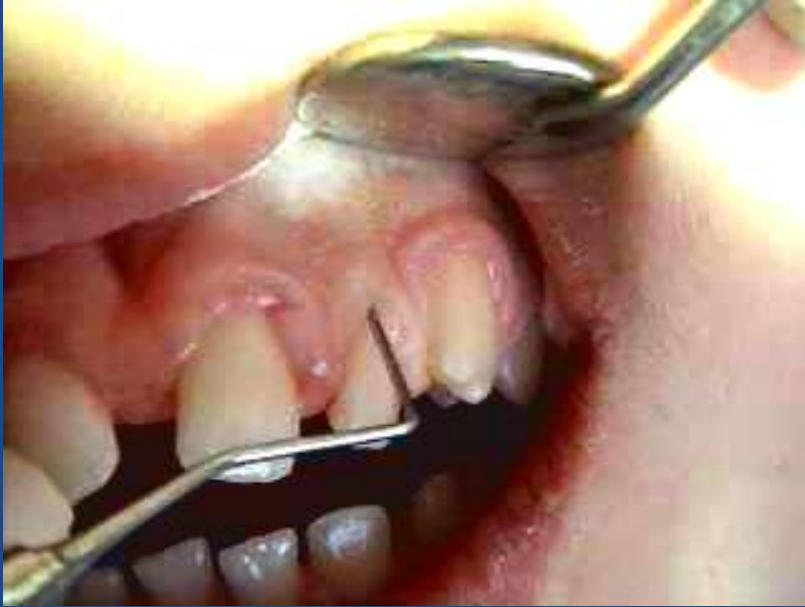**Gingivektomi'de kullanılan el aletleri**

# Gingivektomi insizyonları:

**Esas insizyon**

**İşaretleme**

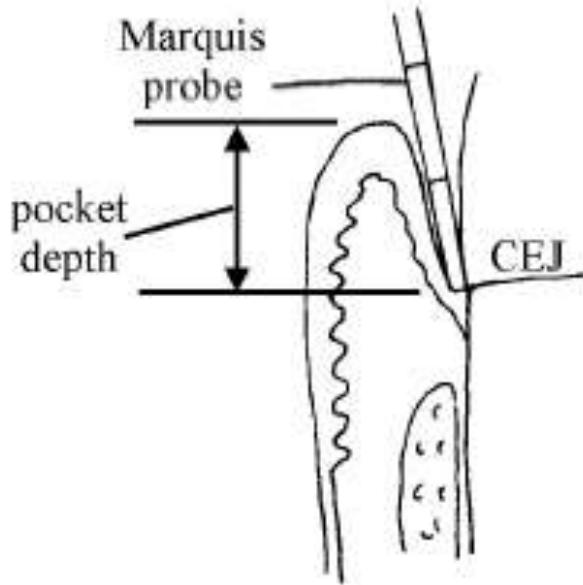




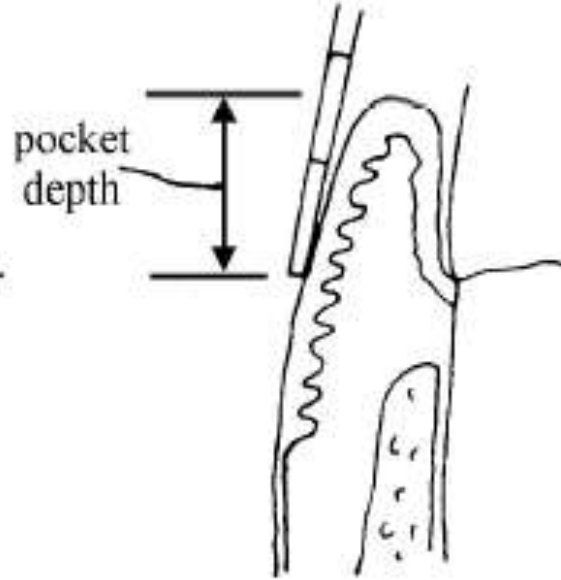
**Cep tabanının  
işaretlenmesi**



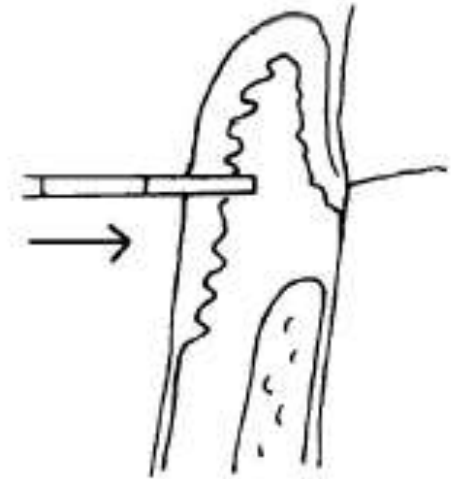




Measure pseudopocket depth



Find depth on gingiva

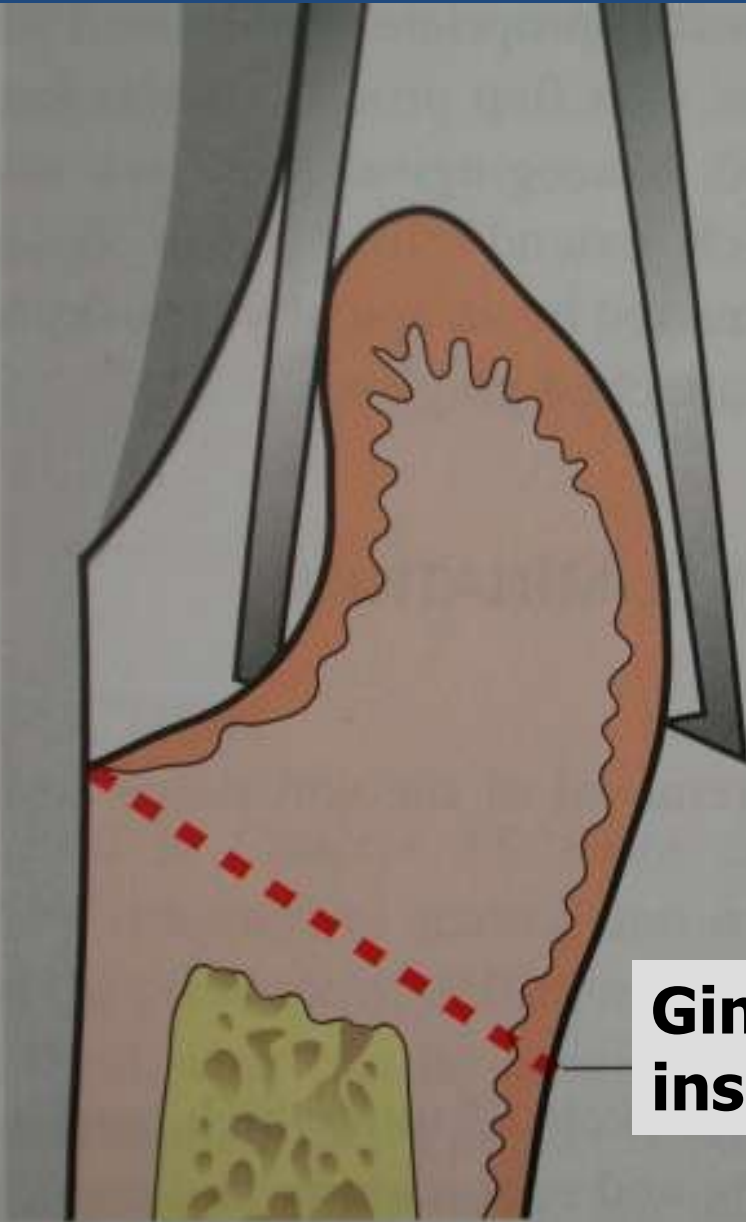


Puncture at depth of pseudopocket

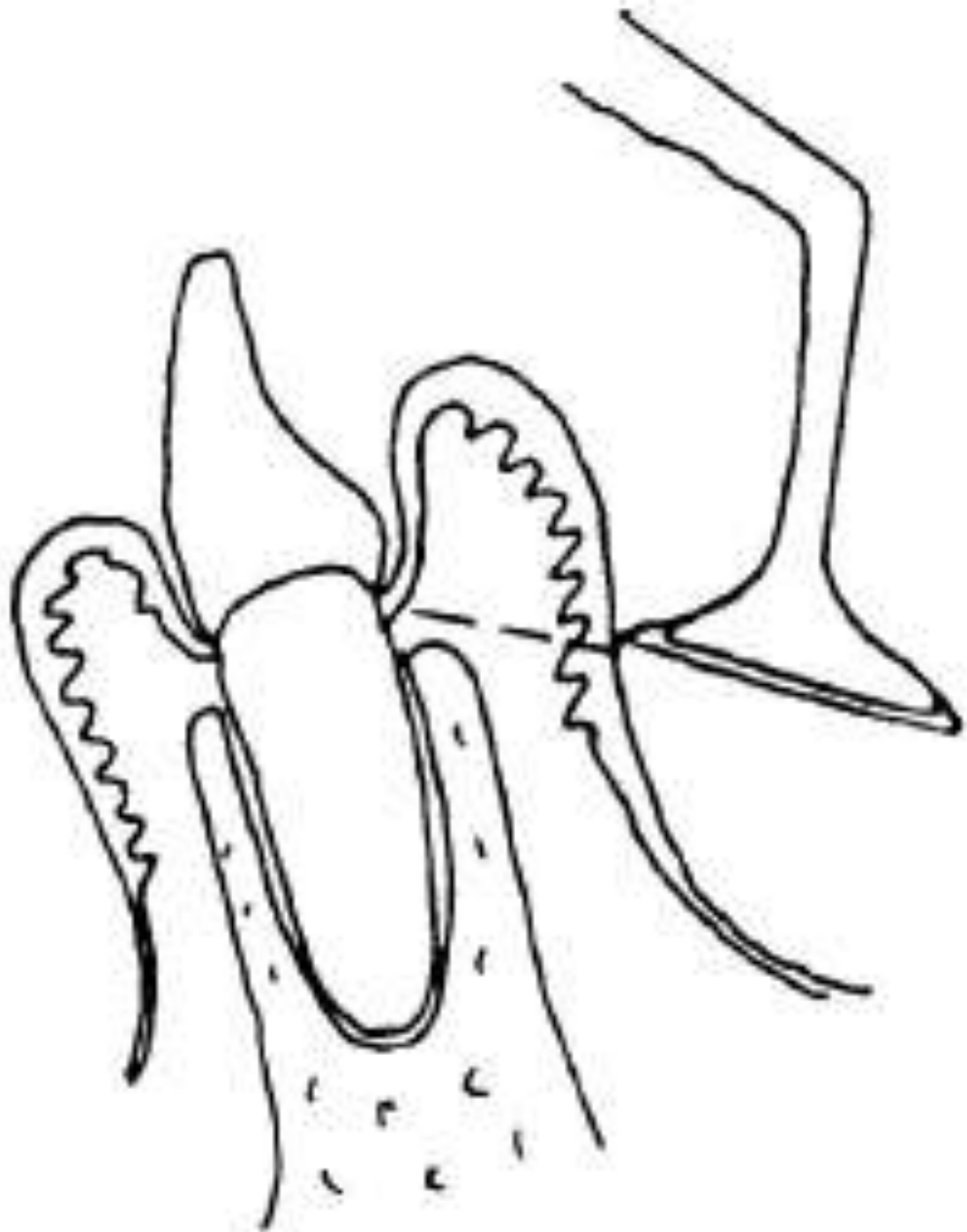
**Pseudo (Yalancı) cep derinliği**

**Vestibül yüzden cep derinliğinin hesaplanması**

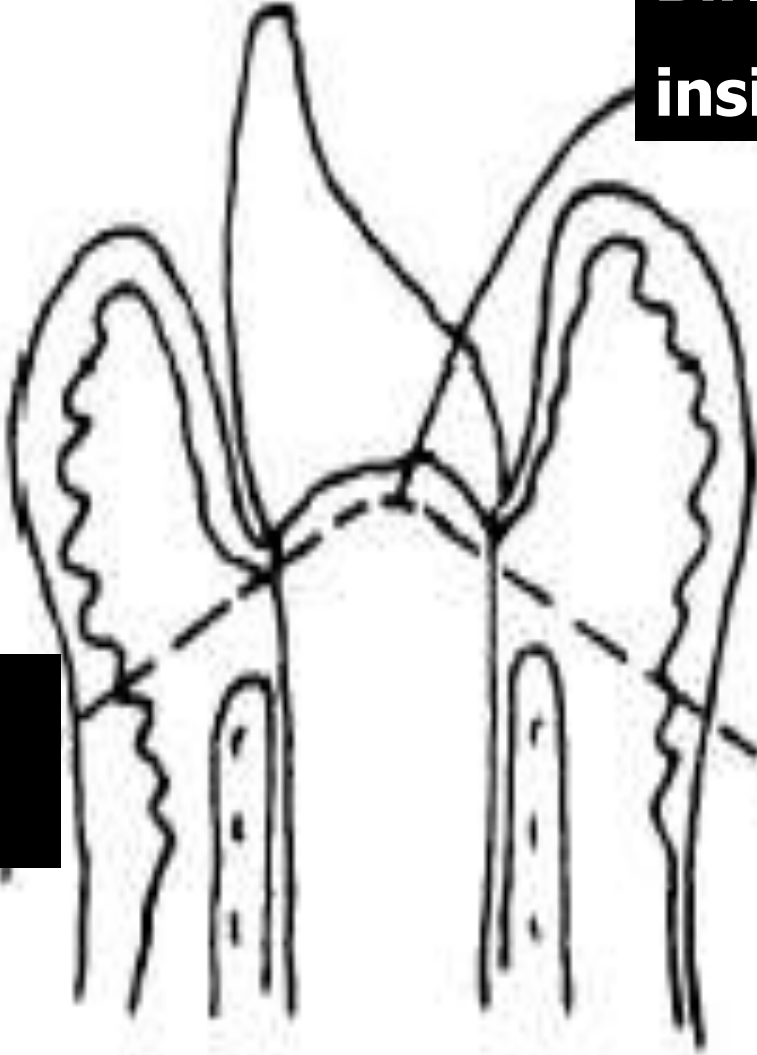
**Gerçek cep derinliği**



**Gingivektomi  
insizyonu**



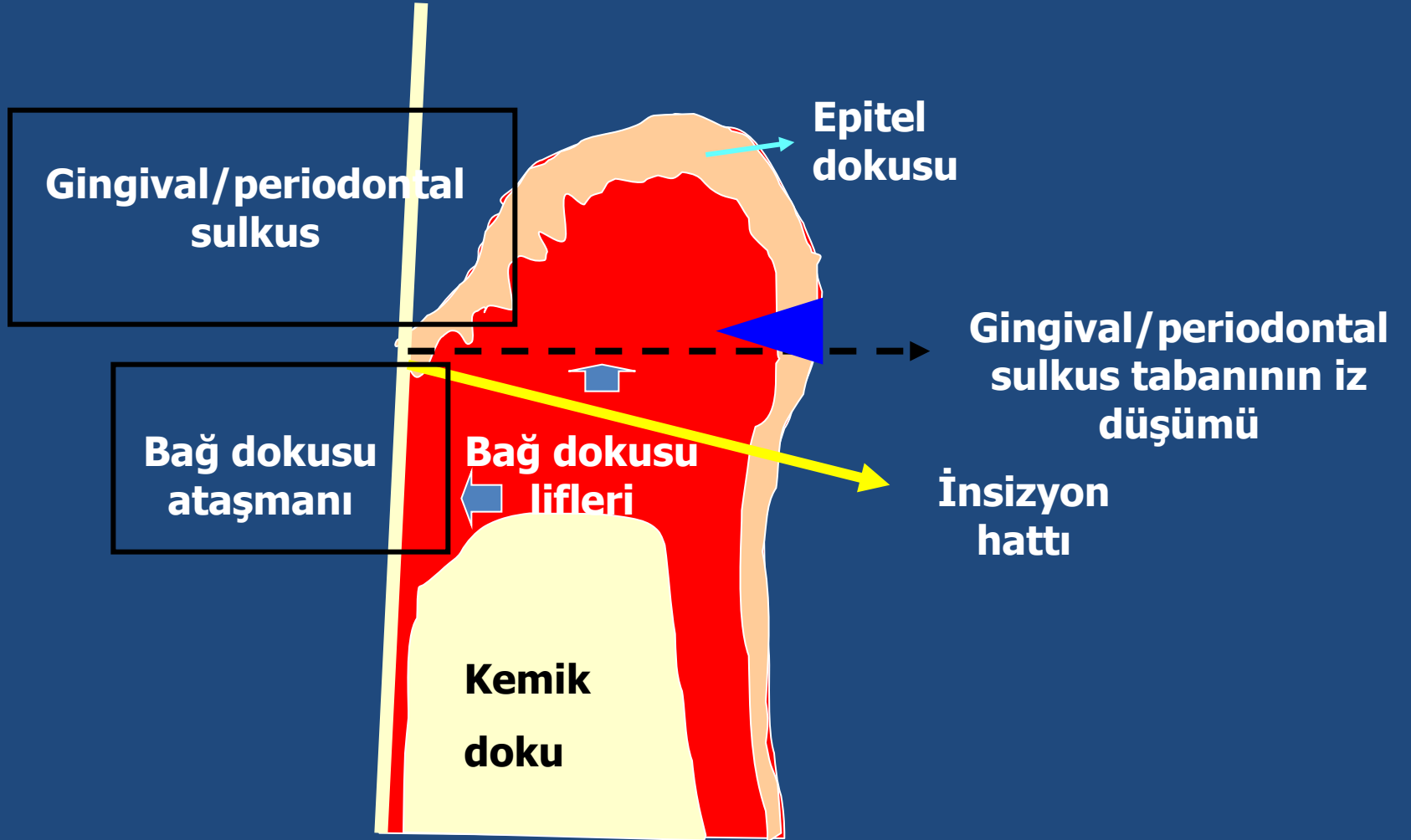
**Birleřtirici  
insizyon**



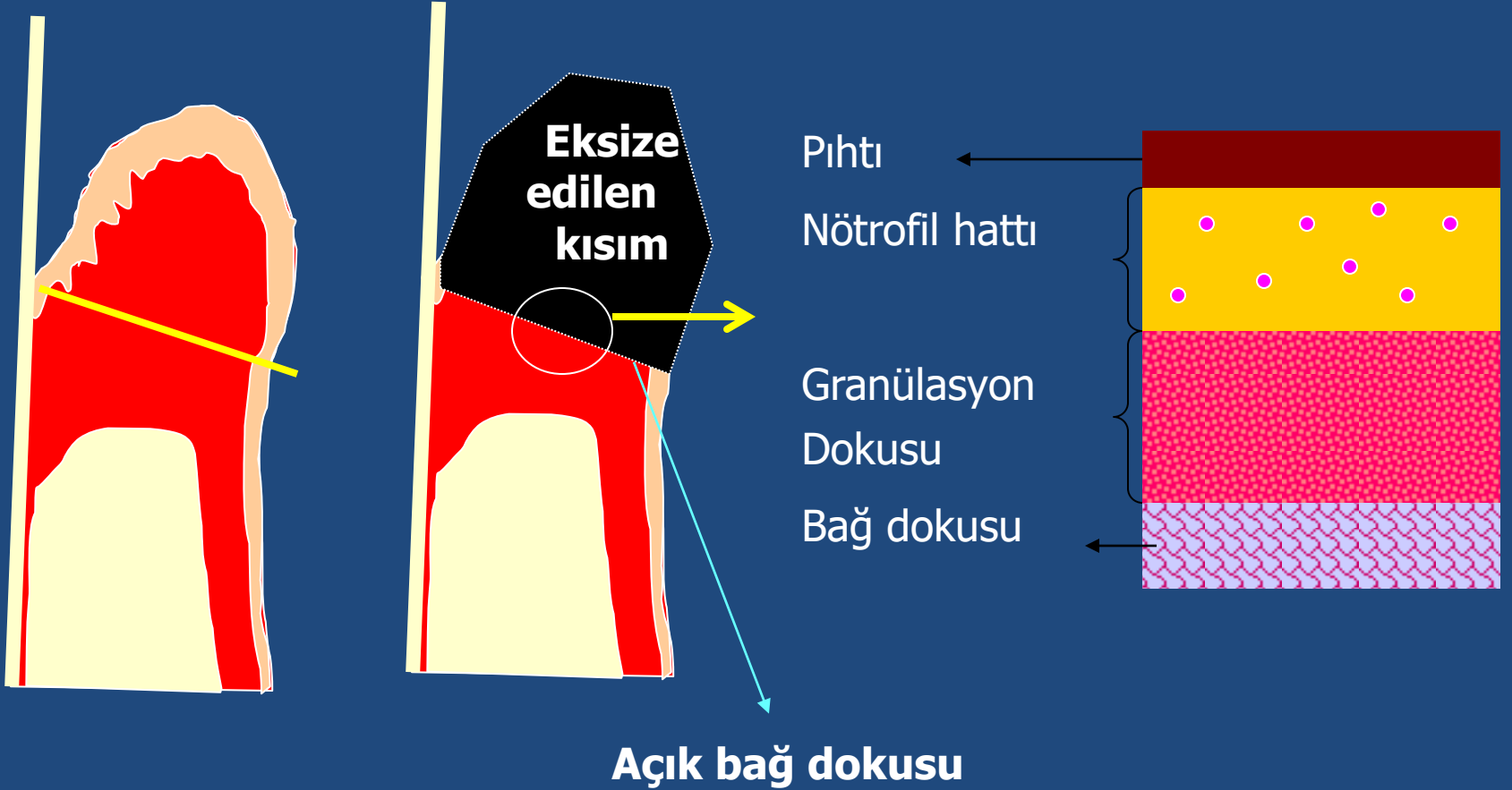
**Vestibül  
insizyonu**

**Lingual  
insizyon**

# Gingivektomi sonrası yara iyileşmesinin tamamlanması



# Gingivektomi insizyonu ve yara iyileşmesi



1- Açık bađ dokusu üzerini fibrin içeren pıhtı kaplar.

2- Bađ dokusundan gelen,

**Mitotik  
aktivite**

Fibroblastlar

Endotel hücreleri

Farklılaşmamış mezansimal  
kökenli hücrele

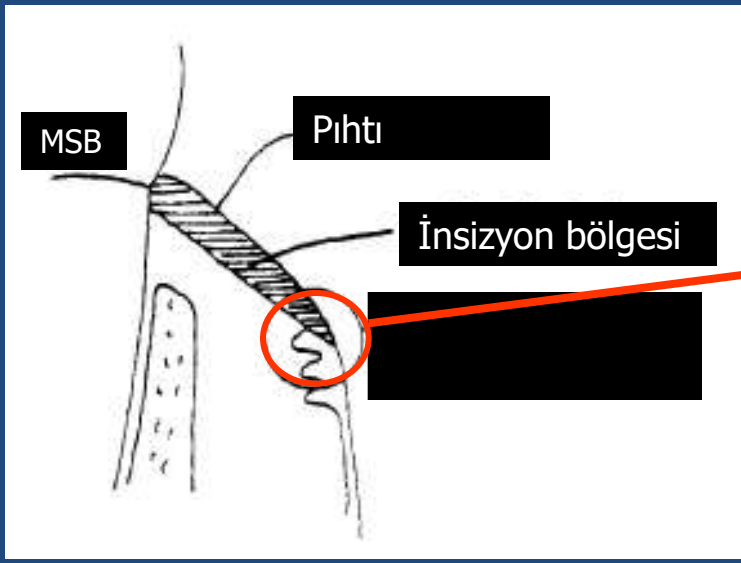
**GRANÜLASYON  
DOKUSU**

3- Granülasyon dokusu içi nütrofillerle dolar.

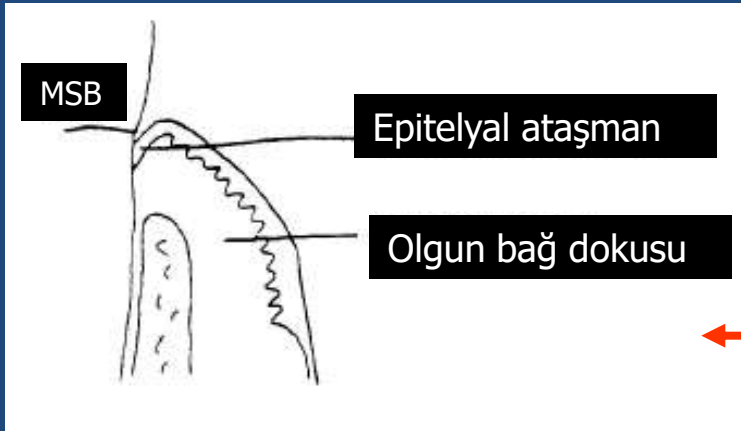
4- Vestibül yüzeyden, granülasyon tabakası üzerinden ve nütrofil hattı içinden epitel migrasyonu başlar.

5- Granülasyon tabakası içinde fibroblastlar kollagen üretmeye başlar.

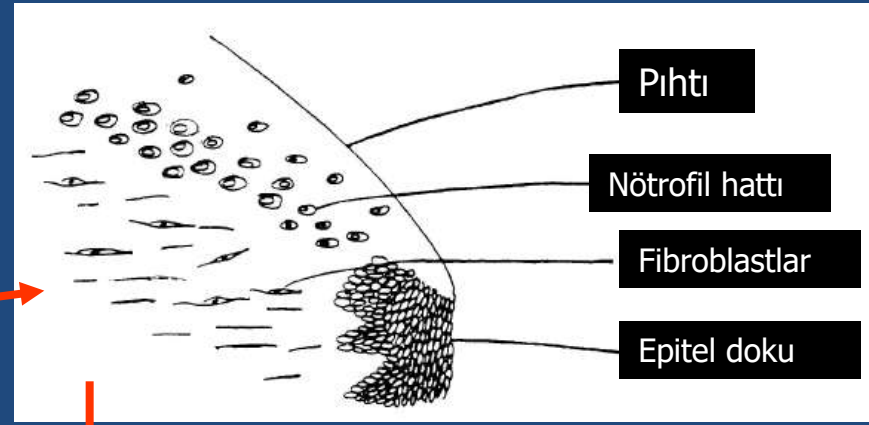




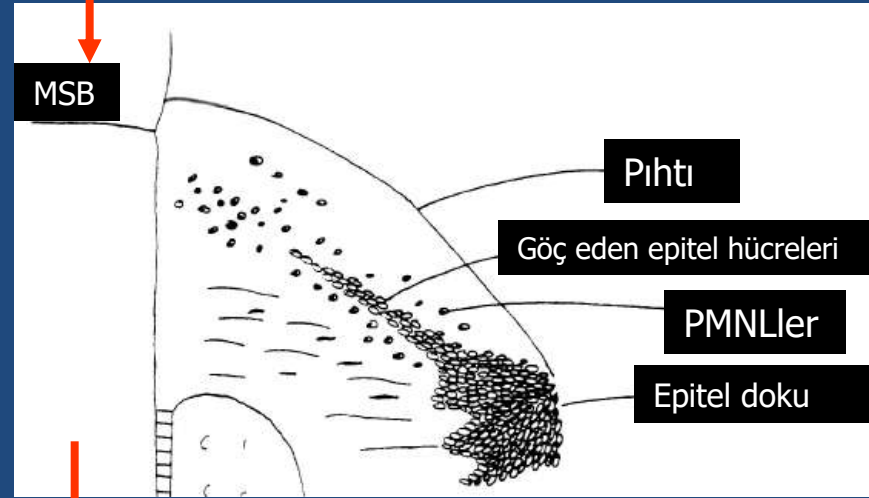
Gingivektomi sonrası



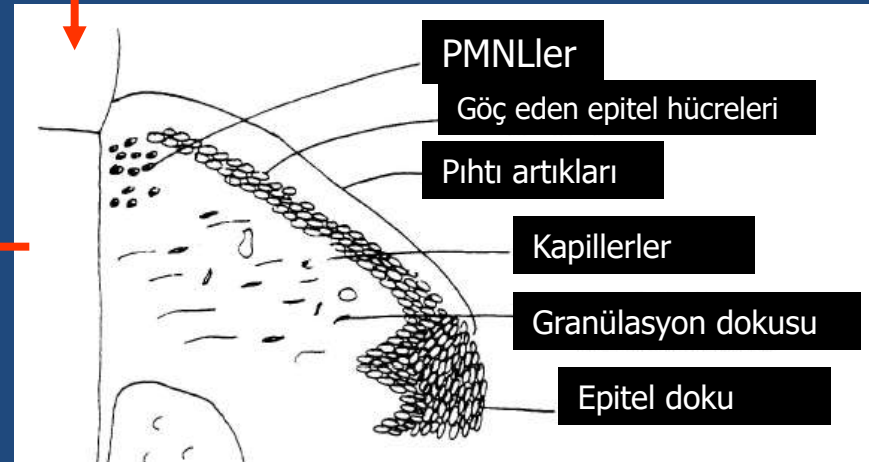
Post-op ~ 28 gün



0-5  
saat



2-3  
gün



4-10  
gün

**Bağ dokusu koronale doğru büyür**



**Gingival sulkus derinliği**



**Bağ dokusu içinde kollagen yapımı**



**Granülasyon dokusu miktarı**



# Histomorphometric Study of the Healing of Human Oral Mucosa After Gingivoplasty and Low-Level Laser Therapy

Carla A. Damante, MSc,<sup>1\*</sup> Sebastião L.A. Greggi, PhD,<sup>1</sup> Adriana C.P. Sant'Ana, PhD,<sup>1</sup>  
Euloir Passanezi, PhD,<sup>1</sup> and Rumio Tagn, PhD<sup>2</sup>

<sup>1</sup>Bauru School of Dentistry—University of São Paulo—Department of Periodontology, Bauru, São Paulo, Brazil

<sup>2</sup>Bauru School of Dentistry—University of São Paulo—Department of Biological Sciences, Bauru, São Paulo, Brazil

Lasers in Surgery and Medicine 35:377–384 (2004)

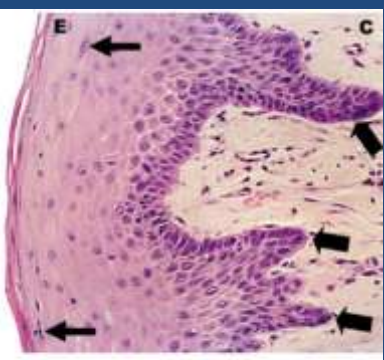


Fig. 1. Test side after 7 days of surgery. Epithelium (E).

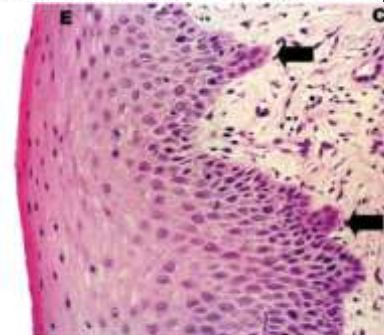


Fig. 3. Test side after 14 days of surgery. Epithelial projections

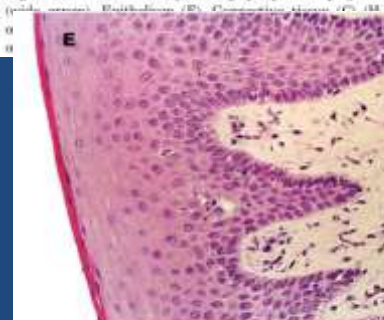


Fig. 6. Control side after 21 days of surgery. Epithelium—Connective tissue (C) (H.E. original augmentation—40×). [Figure can be viewed in color online via www.interscience.wiley.com.]

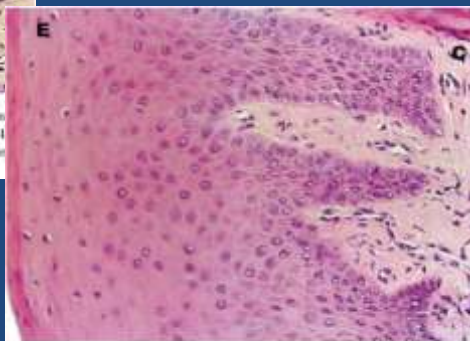


Fig. 7. Test side after 60 days of surgery. Epithelium (E), Connective tissue (C) (H.E. original augmentation—40×). [Figure can be viewed in color online via www.interscience.wiley.com.]

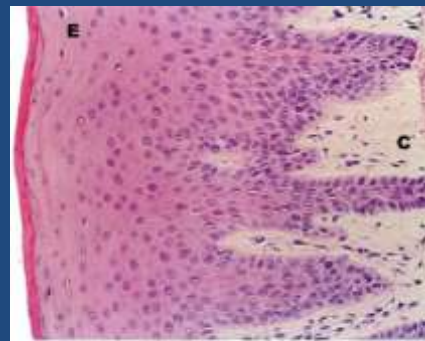


Fig. 8. Control side after 60 days of surgery. Epithelium (E), Connective tissue (C) (H.E. original augmentation—40×). [Figure can be viewed in color online via www.interscience.wiley.com.]

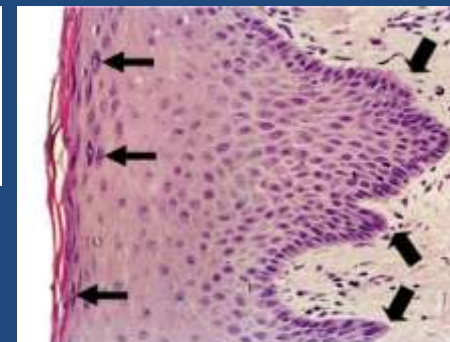


Fig. 2. Control side after 7 days of surgery. Epithelium (E).

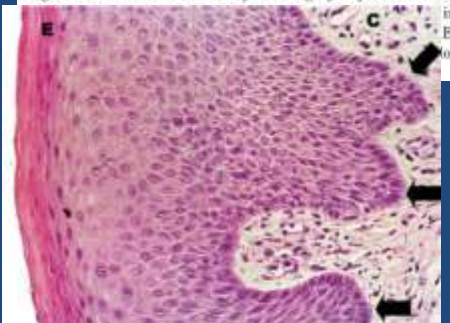


Fig. 4. Control side after 14 days of surgery. Epithelial

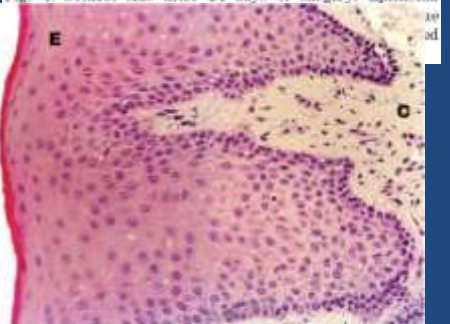


Fig. 5. Test side after 21 days of surgery. Epithelium (E), Connective tissue (C) (H.E. original augmentation—40×). [Figure can be viewed in color online via www.interscience.wiley.com.]