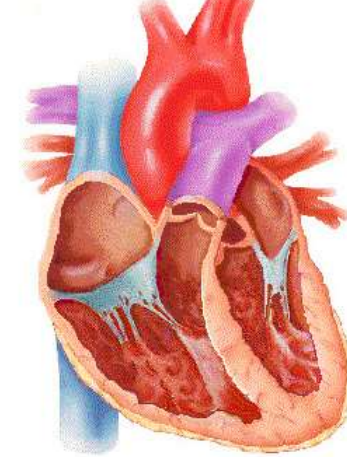
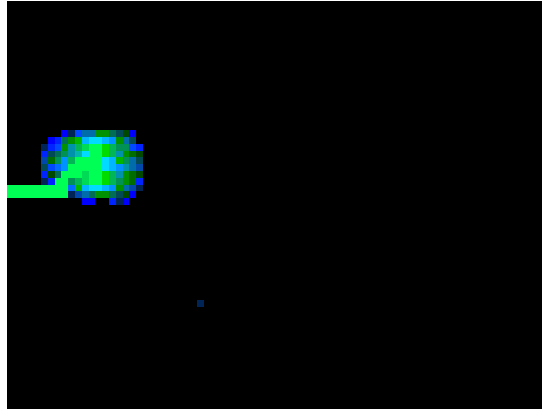
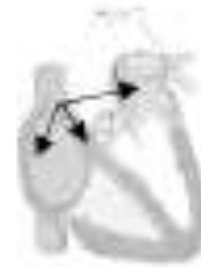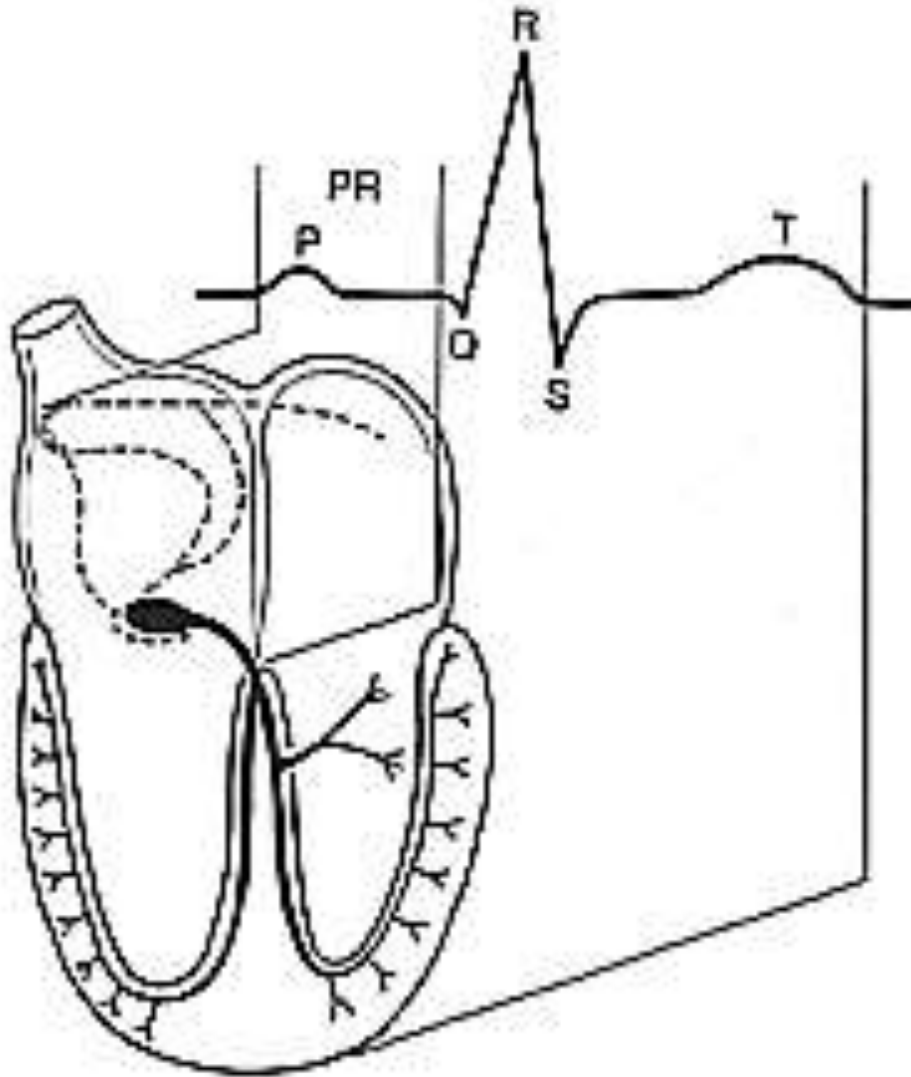


ELEKTROKARDİYOGRAFI



Ankara Üniversitesi Tıp Fakültesi
Kardiyoloji A.B.D

Kalbin Uyarı İletim Sistemi



P

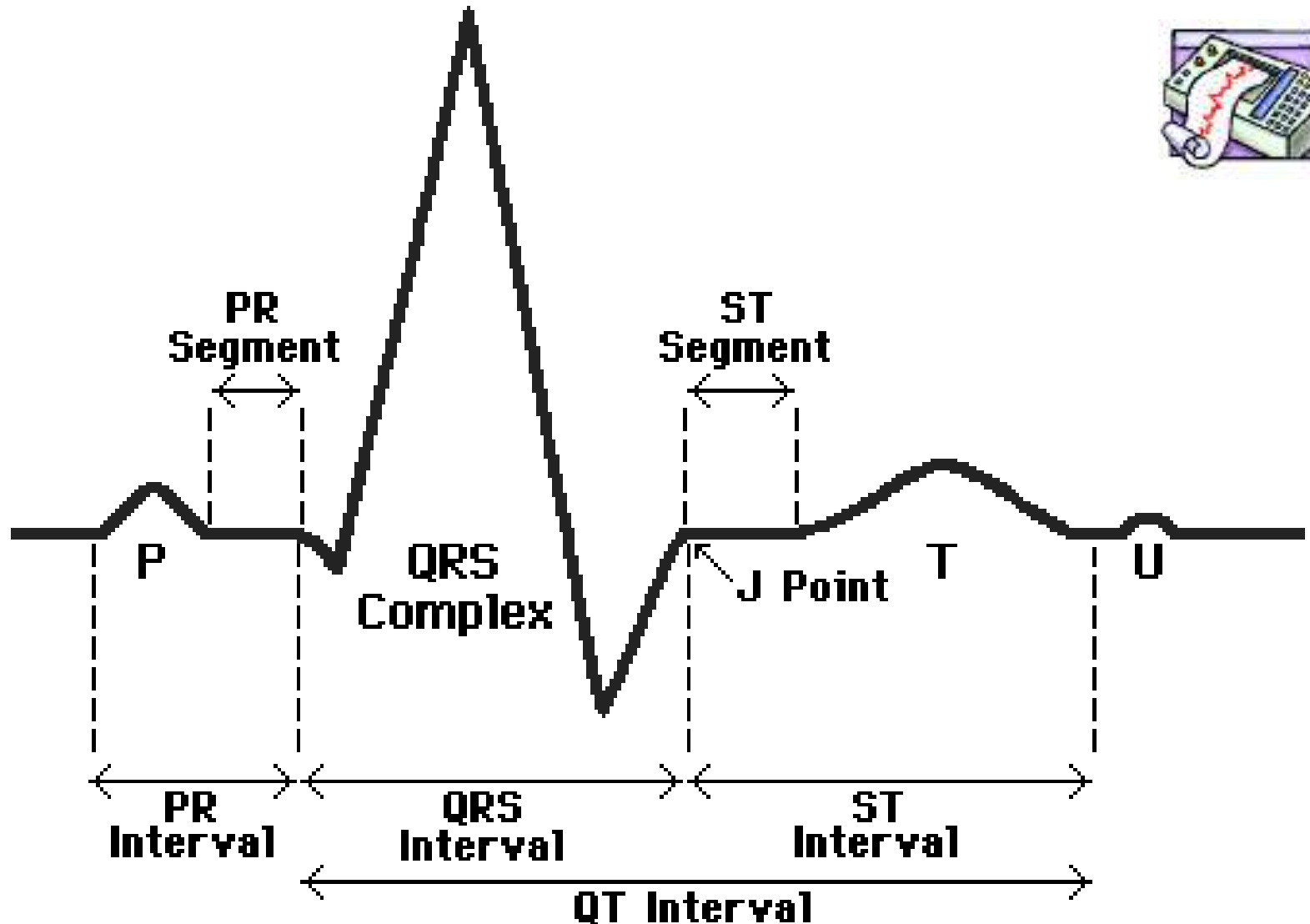


QRS



T

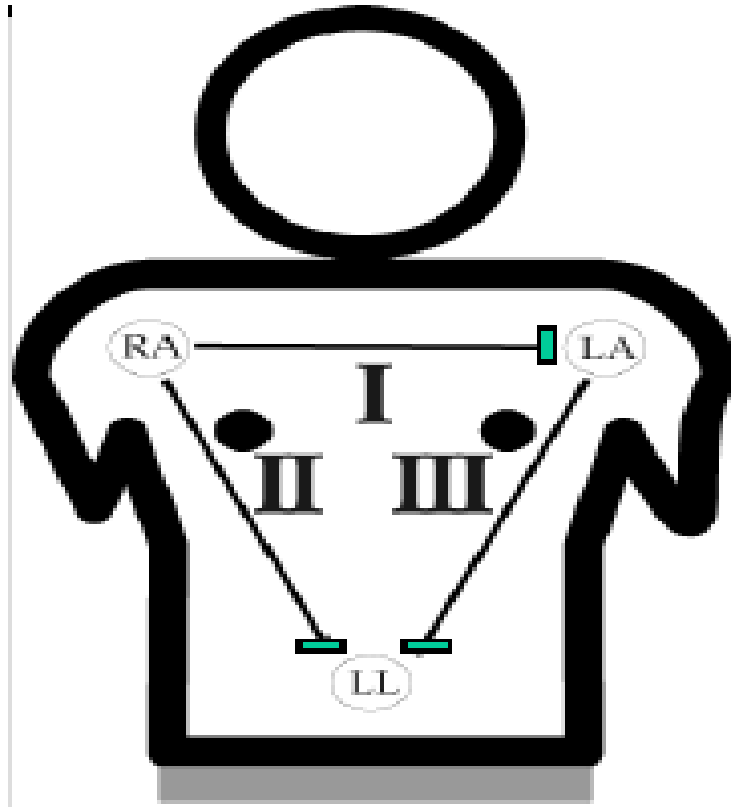
Normal Elektrokardiyogram Bileşigi



Elektrokardiyografi Derivasyonları

A) Ekstremitte Derivasyonları

1) Bipolar (standart) Derivasyonlar I, II, III

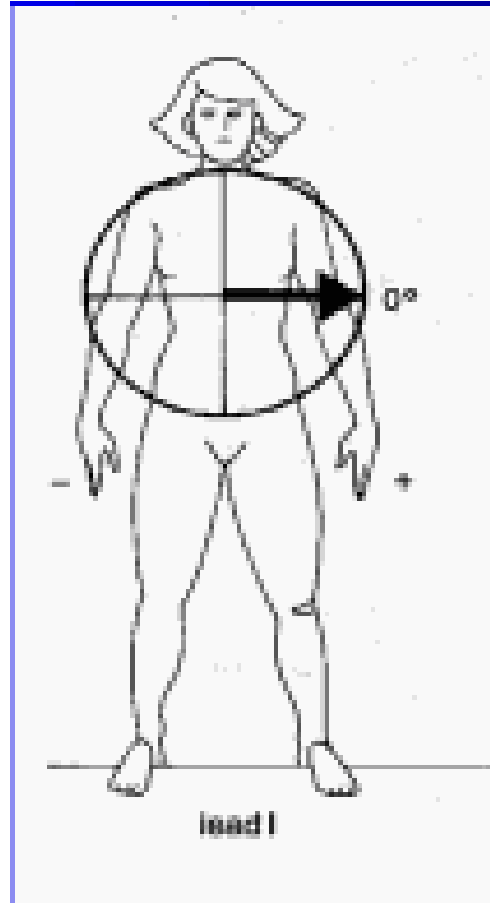


Elektrokardiyografi Derivasyonları

A) Ekstremiteler Derivasyonları

1) Bipolar (standart) Derivasyonlar I, II, III

Derivasyon
I

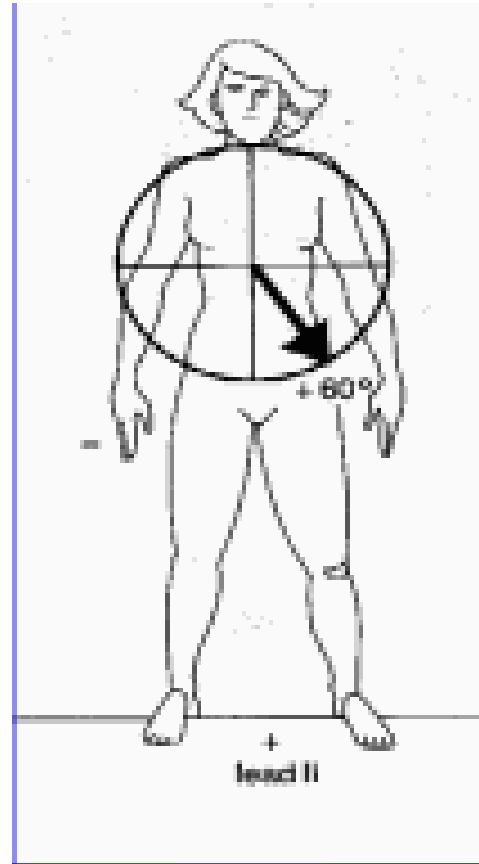


Elektrokardiyografi Derivasyonları

A) Ekstremitte Derivasyonları

1) Bipolar (standart) Derivasyonlar I, II, III

Derivasyon
II

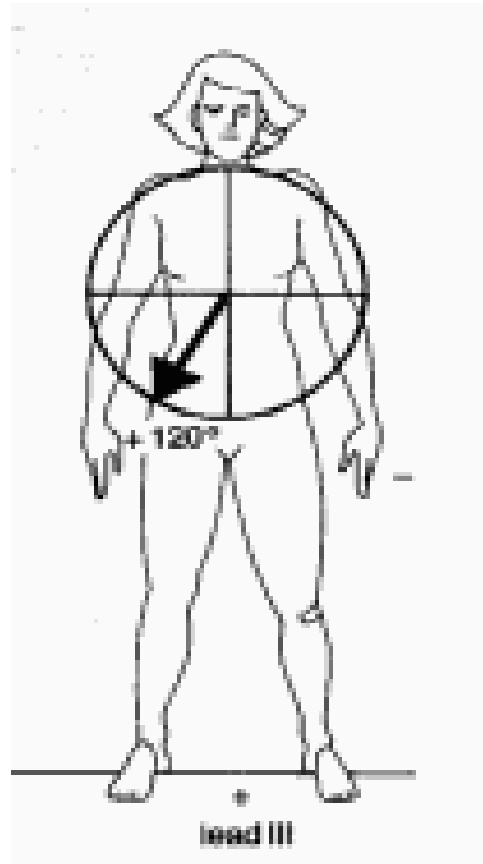


Elektrokardiyografi Derivasyonları

A) Ekstremitte Derivasyonları

1) Bipolar (standart) Derivasyonlar I, II, III

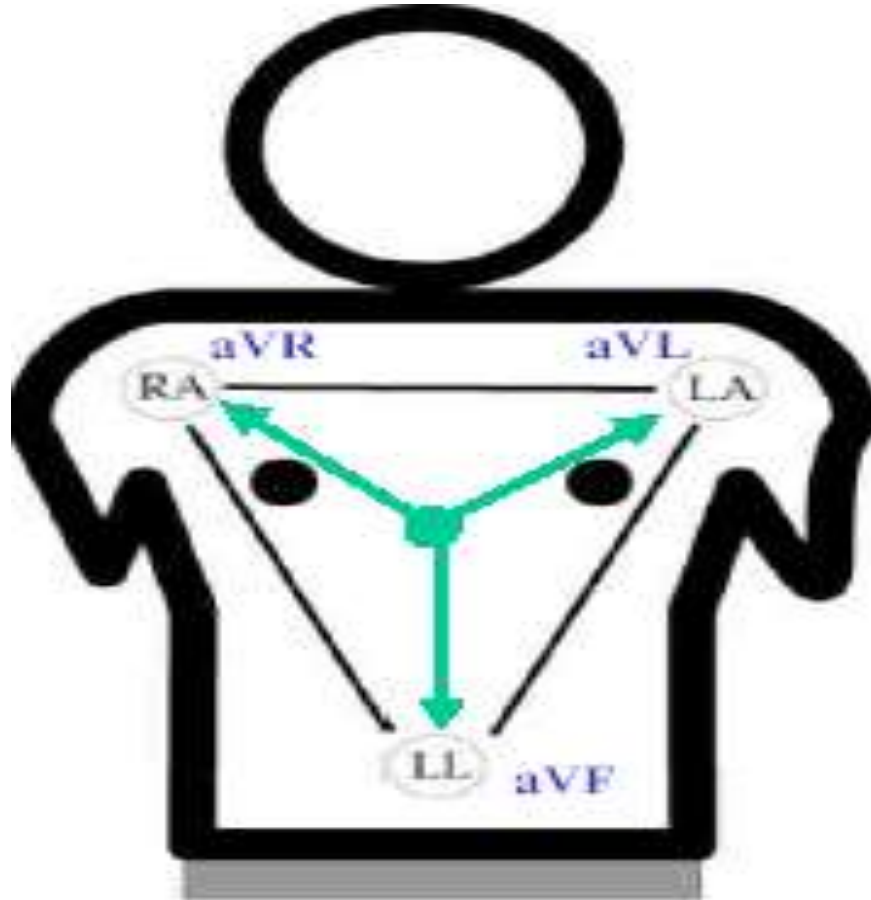
Derivasyon
III



Elektrokardiyografi Derivasyonları

A) Ekstremitte Derivasyonları

2) Unipolar (güçlendirilmiş) Derivasyonlar aVR, aVL, aVF

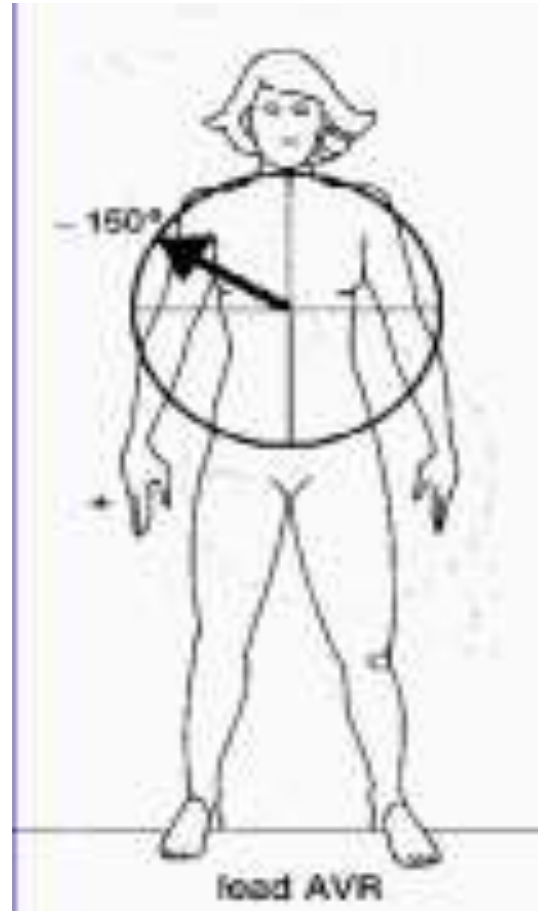


Elektrokardiyografi Derivasyonları

A) Ekstremitte Derivasyonları

2) Unipolar (güçlendirilmiş) Derivasyonlar aVR, aVL, aVF

Derivasyon
aVR

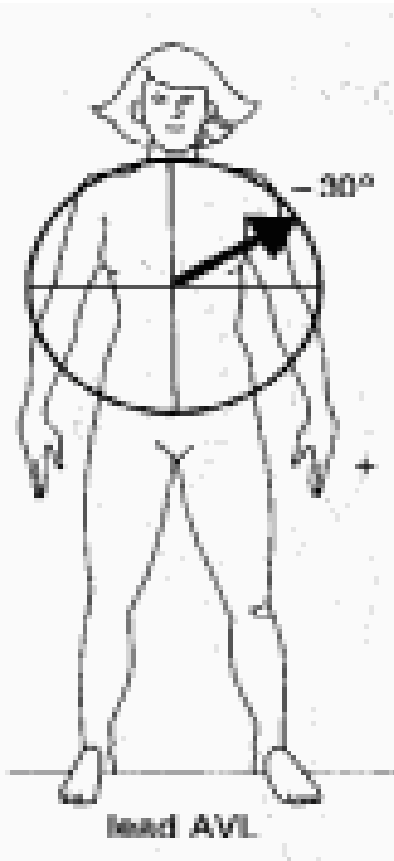


Elektrokardiyografi Derivasyonları

A) Ekstremitte Derivasyonları

2) Unipolar (güçlendirilmiş) Derivasyonlar aVR, aVL, aVF

Derivasyon
aVL

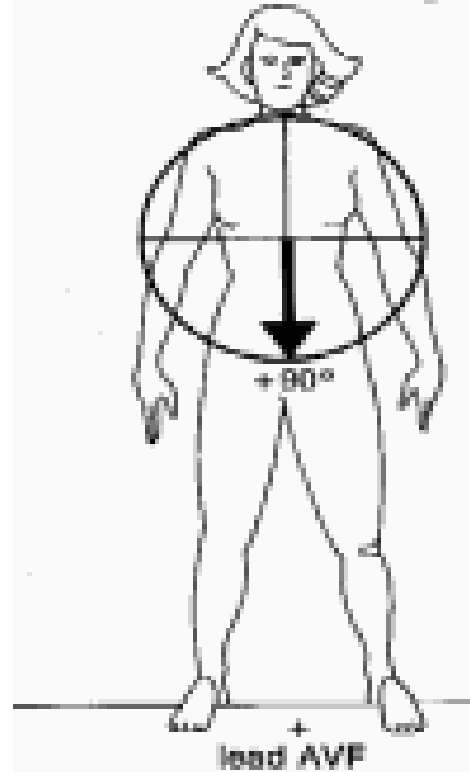


Elektrokardiyografi Derivasyonları

A) Ekstremitte Derivasyonları

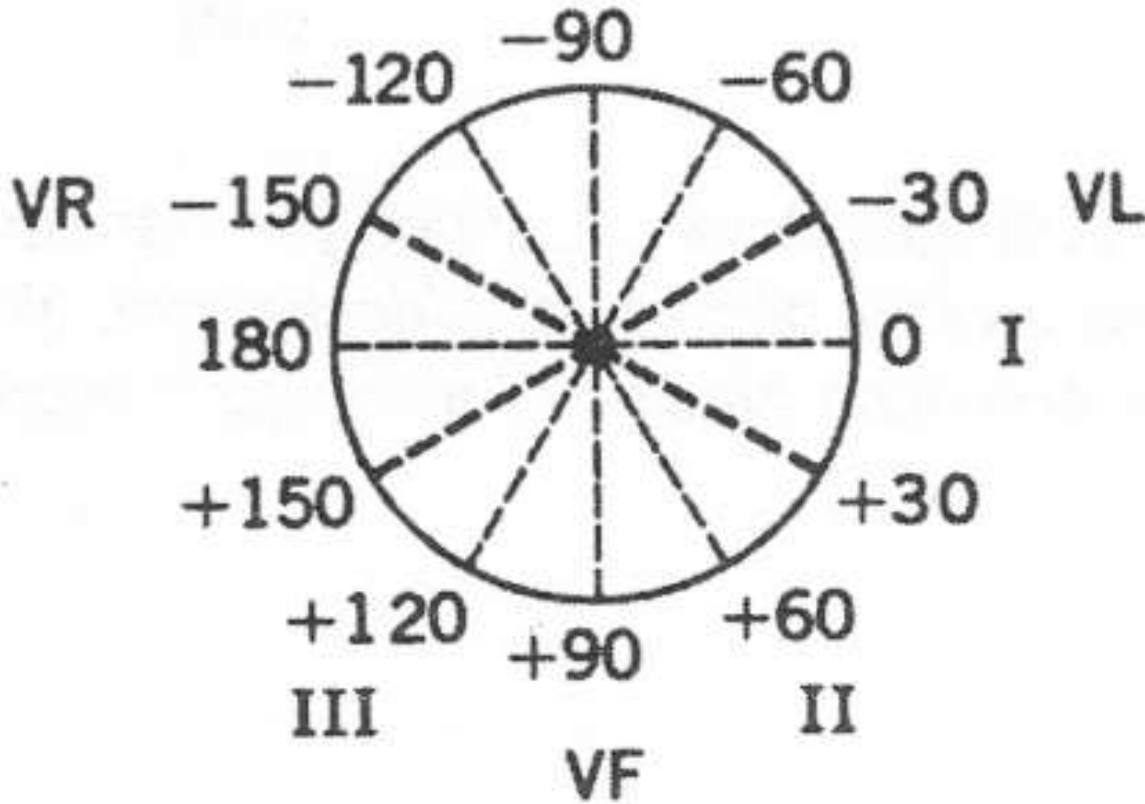
2) Unipolar (güçlendirilmiş) Derivasyonlar aVR, aVL, aVF

Derivasyon
aVF



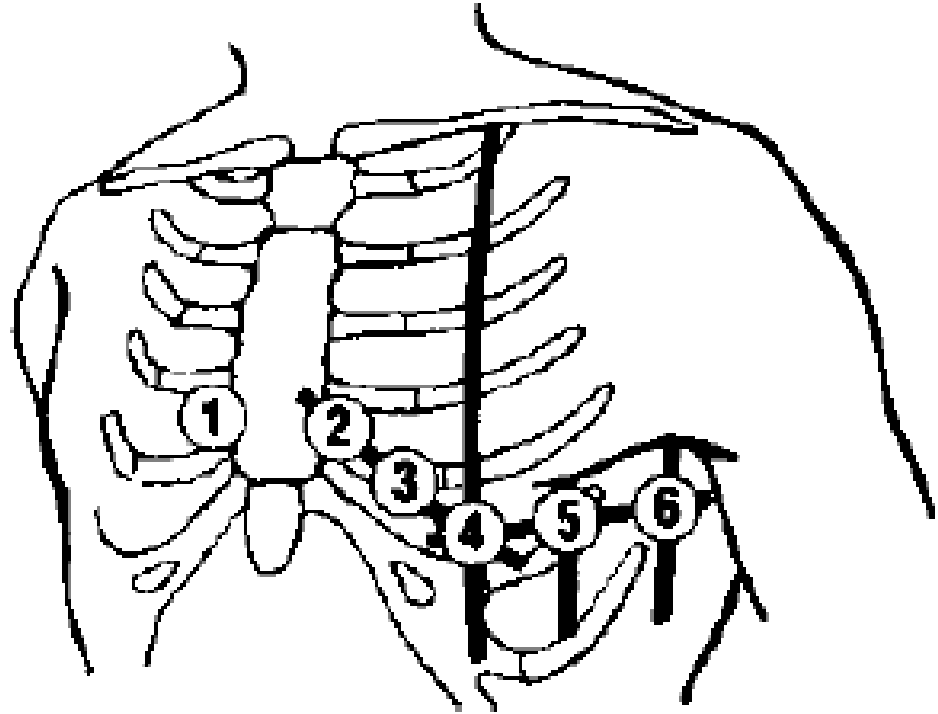
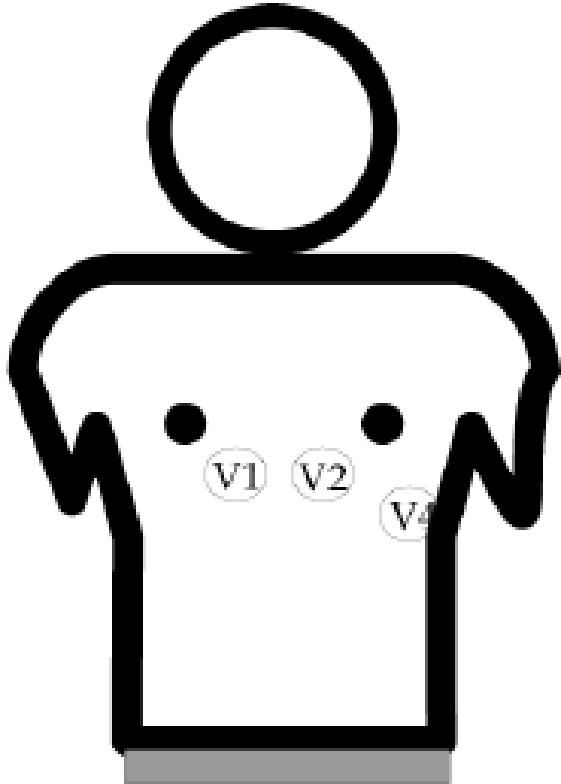
Elektrokardiyografi Derivasyonları

A) Ekstremité Derivasyonları



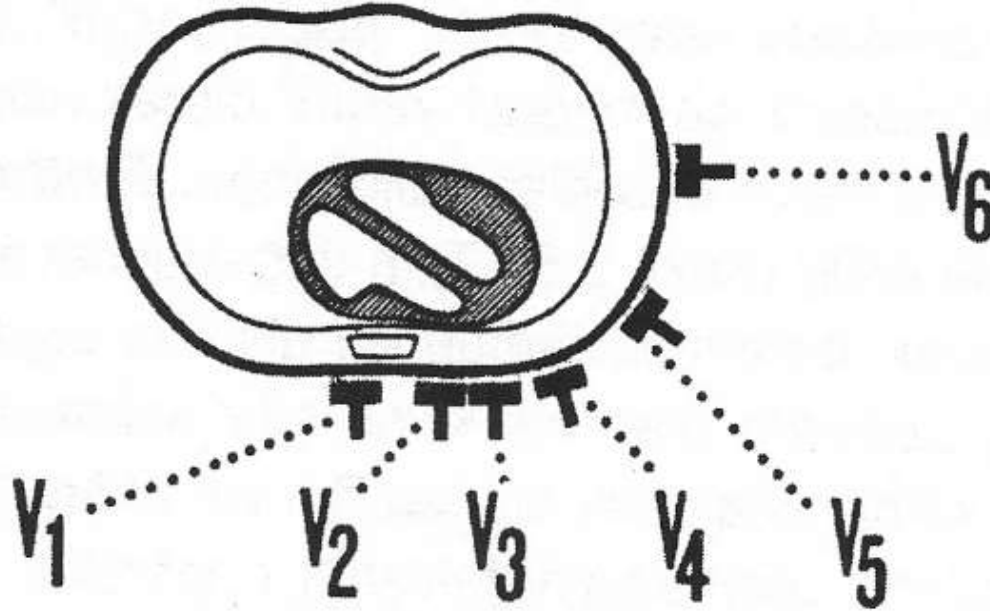
Elektrokardiyografi Derivasyonları

B) Göğüs Derivasyonları (Unipolar)

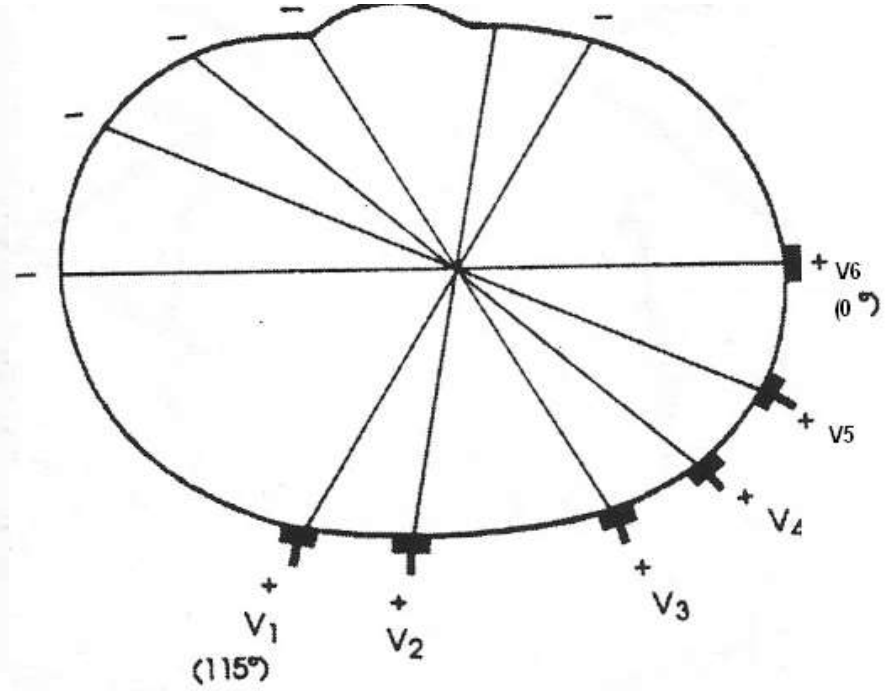
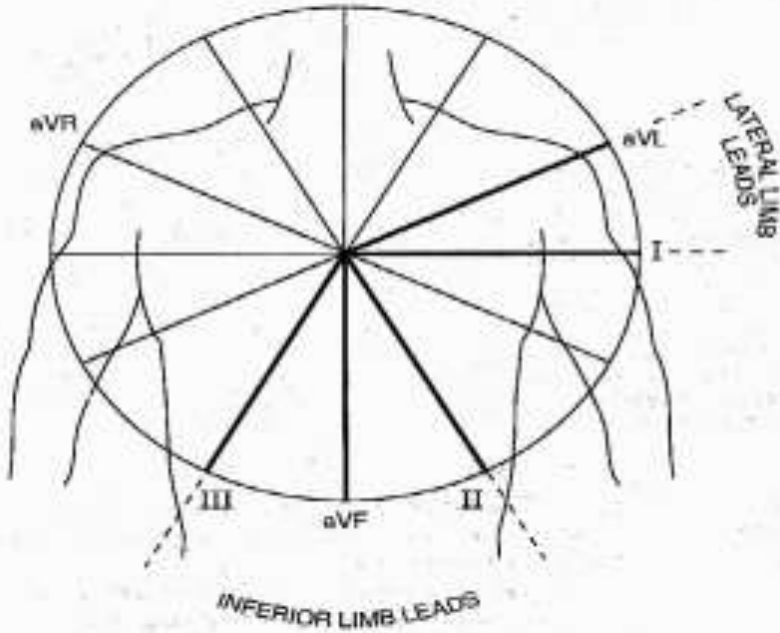


Elektrokardiyografi Derivasyonları

B) Göğüs Derivasyonları (Unipolar)



Elektrokardiyografi Derivasyonları



Inferior – II, III, aVF

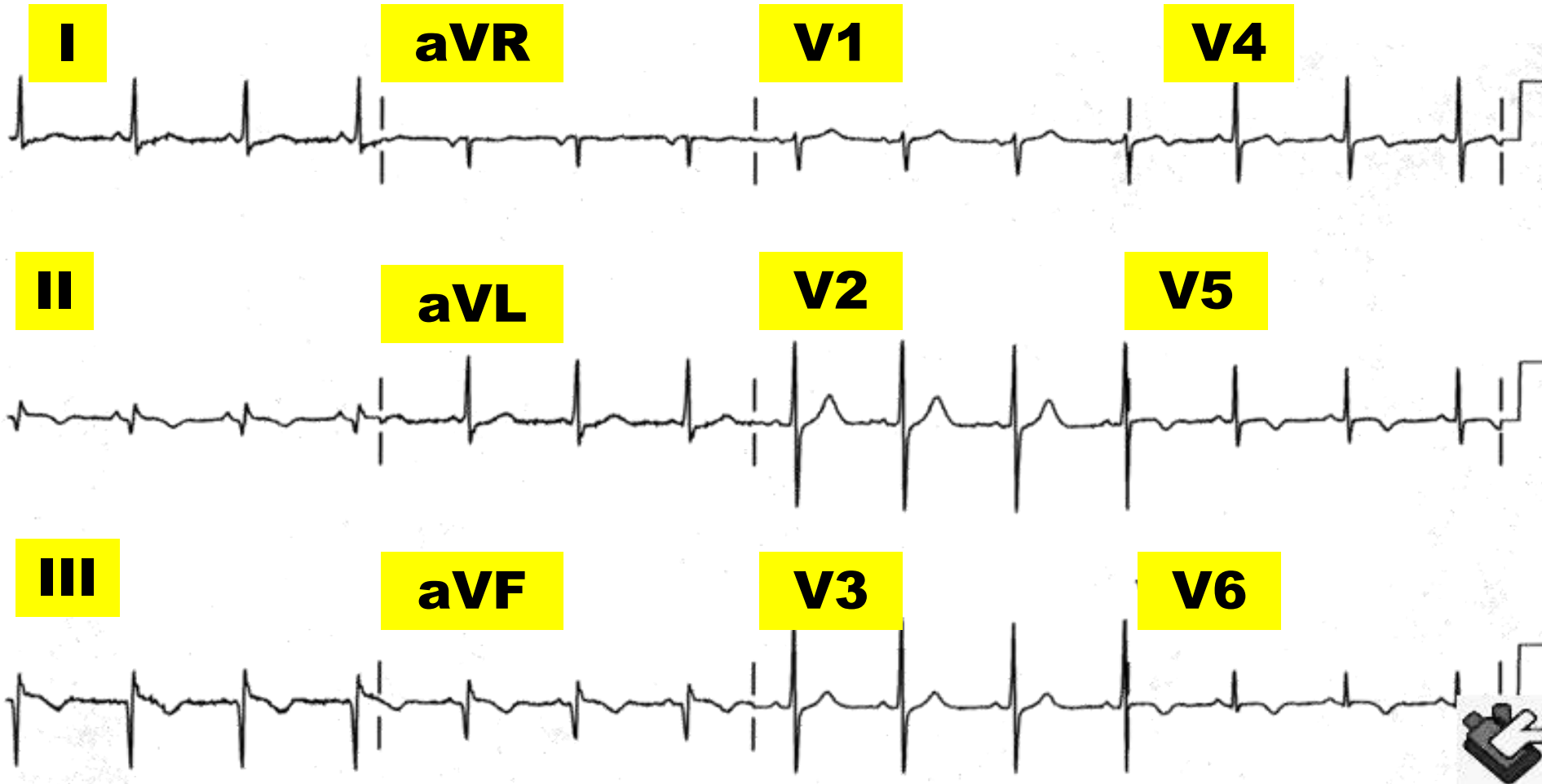
Septal – V1 – V2

Anterior – V3 – V4

Lateral – V5 – V6

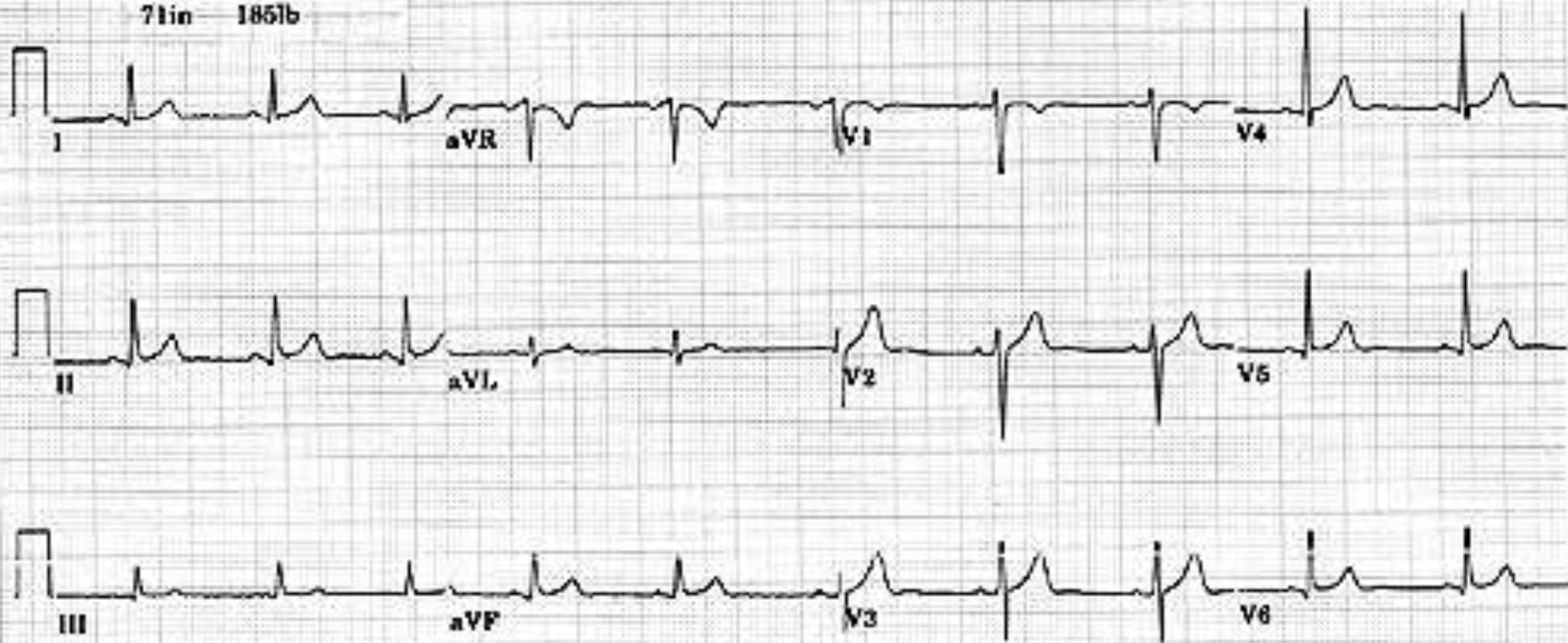
Yüksek Lateral – I, aVL

12 Derivasyonlu EKG

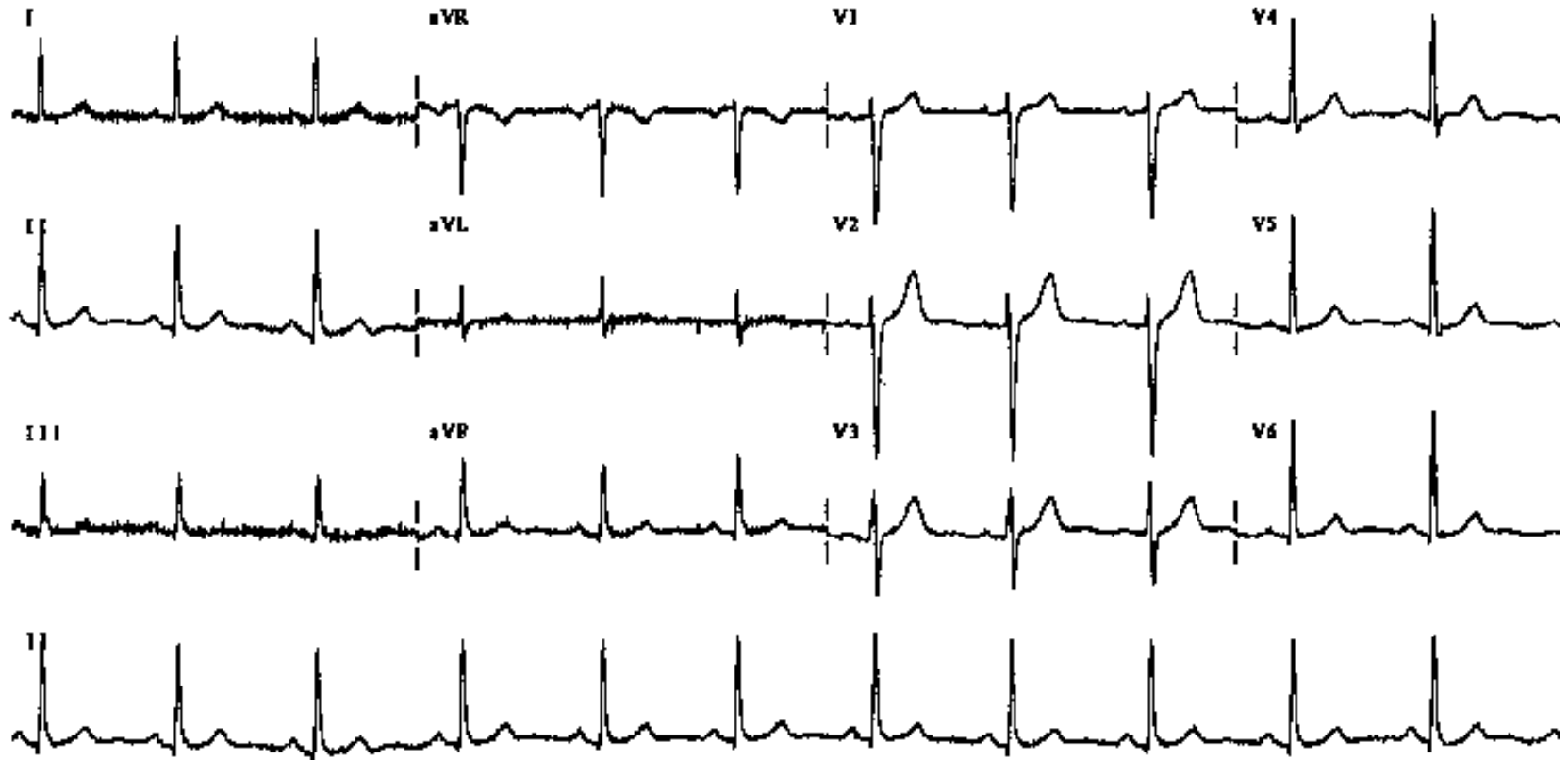


Normal EKG-1

08-NOV-1970 (25 yr)
Male Caucasian
71in 185lb



Normal EKG-2

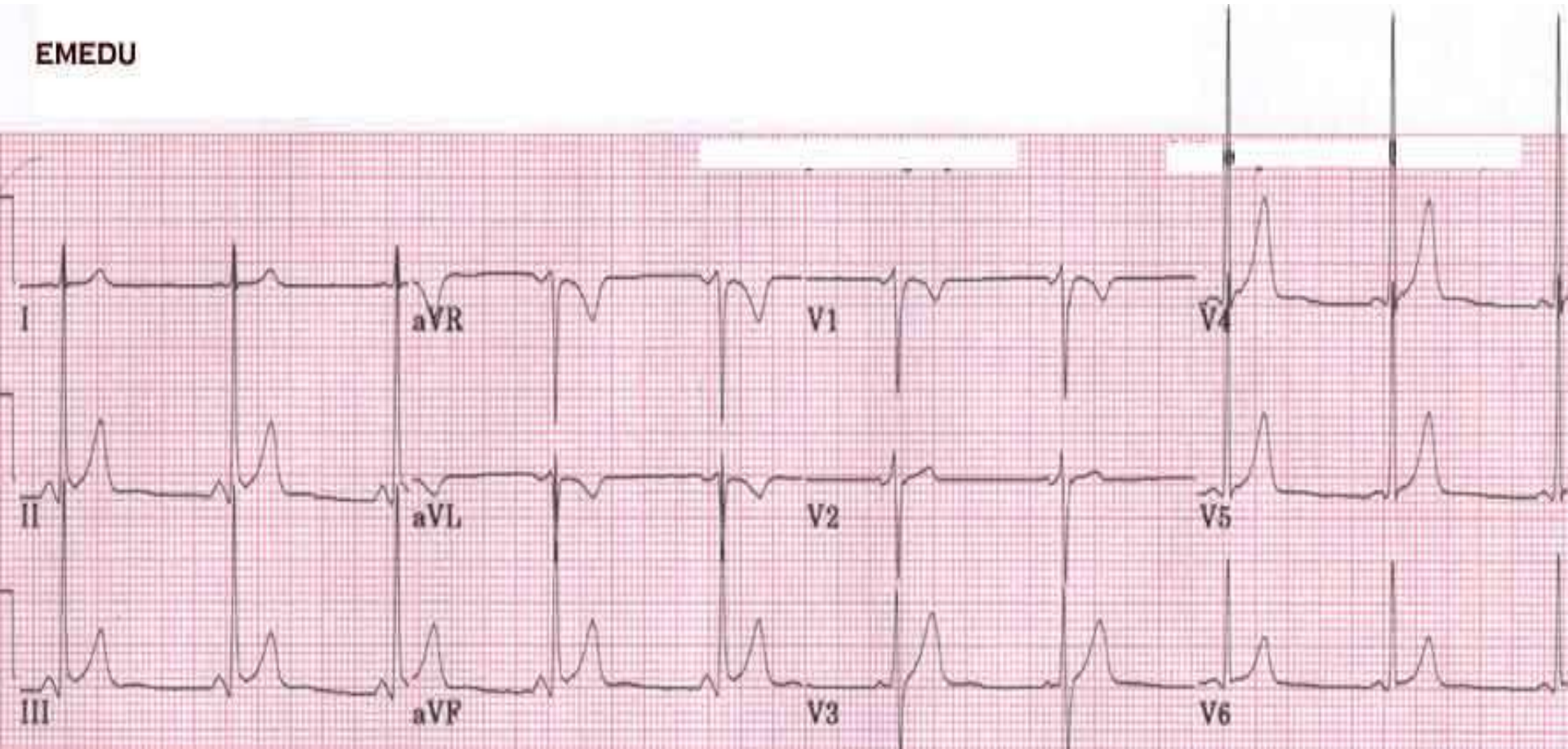


I.D.C 00000-0000 Speed: 25 mm/sec Limb: 10 mV Chest: 10 mm/mV

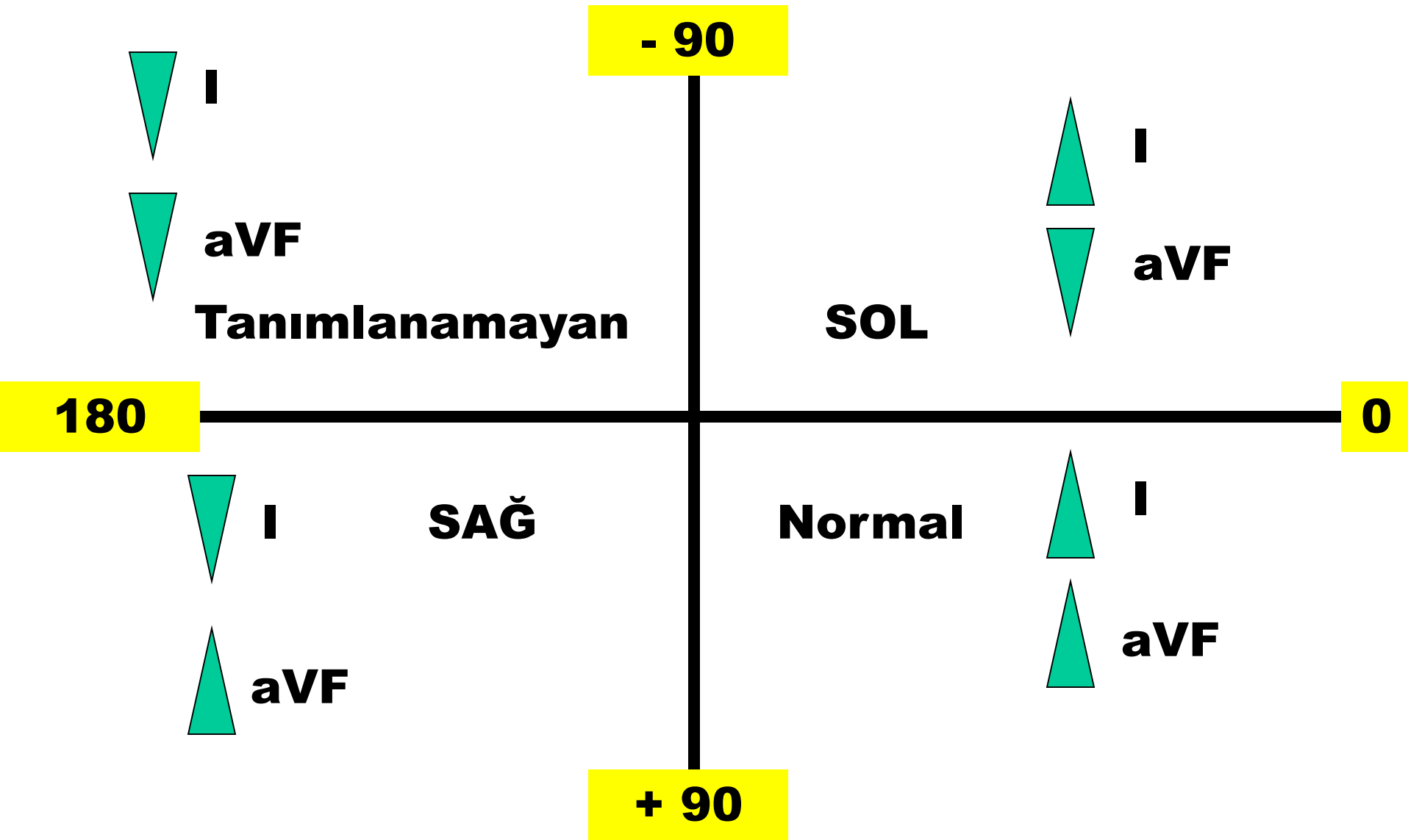
50% 0.15-150 Hz

Normal EKG-3 (Erken repolarizasyon)

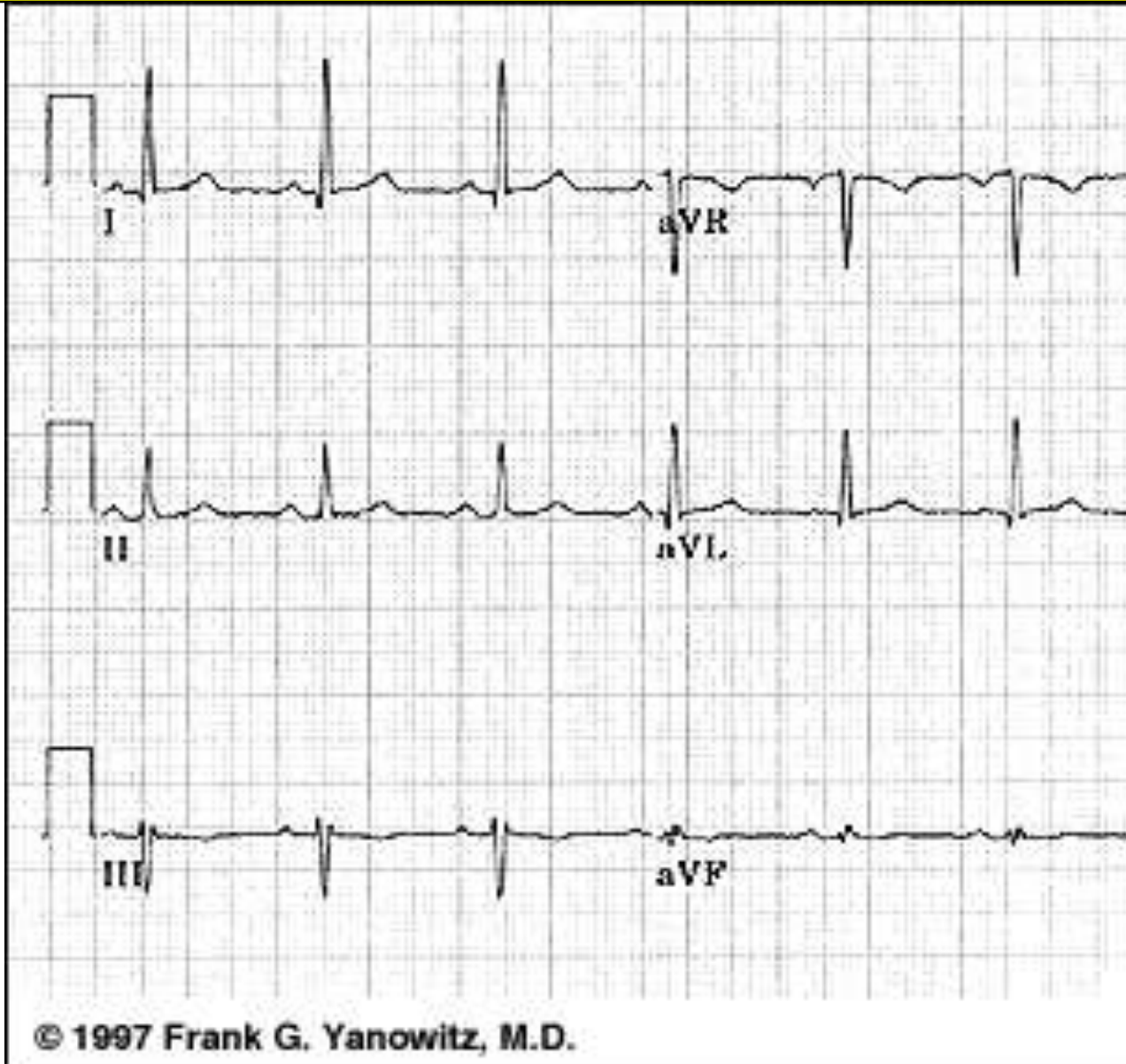
EMEDU



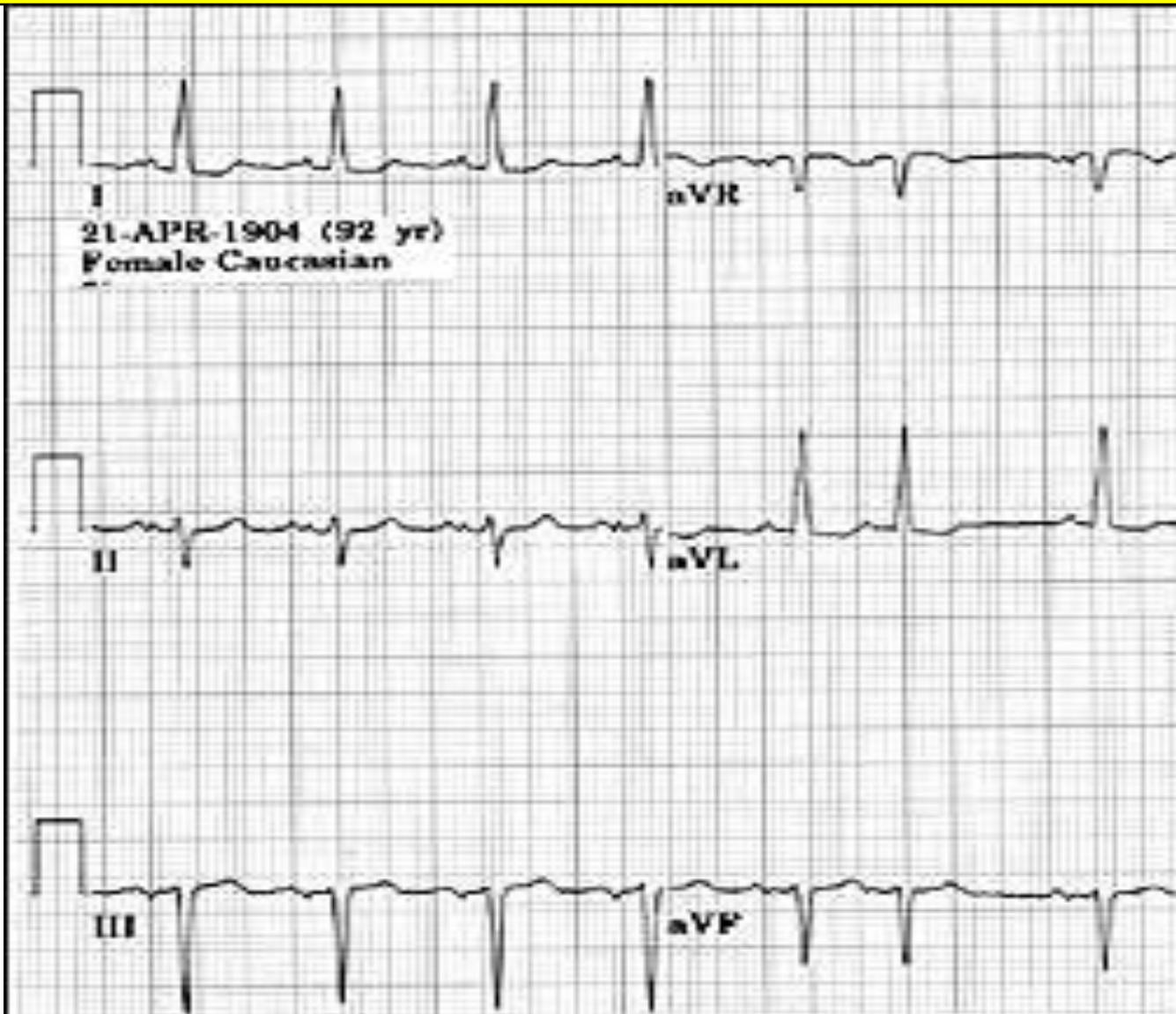
AKS SAPMALARI



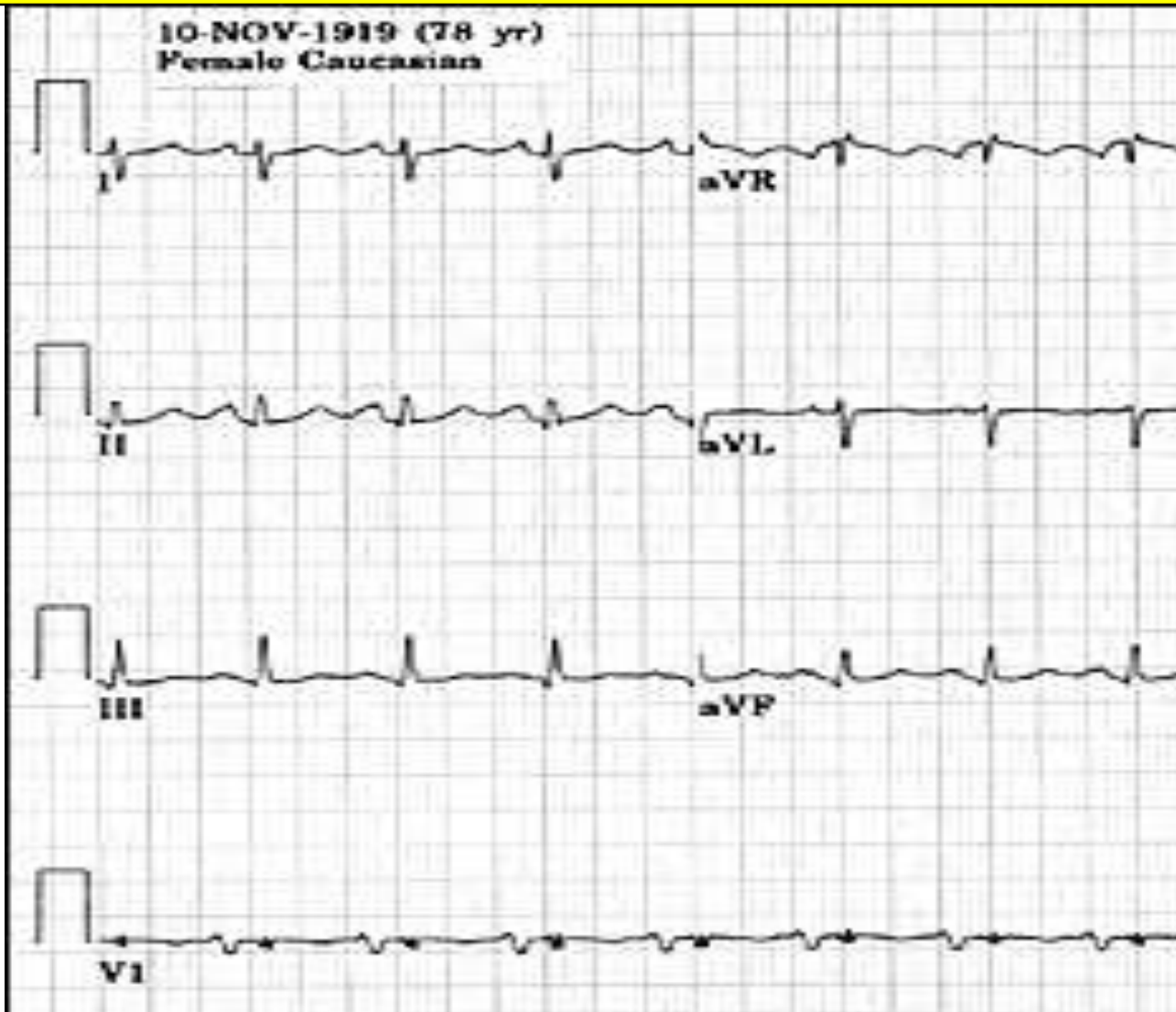NORMAL AKS



SOL AKS SAPMASI

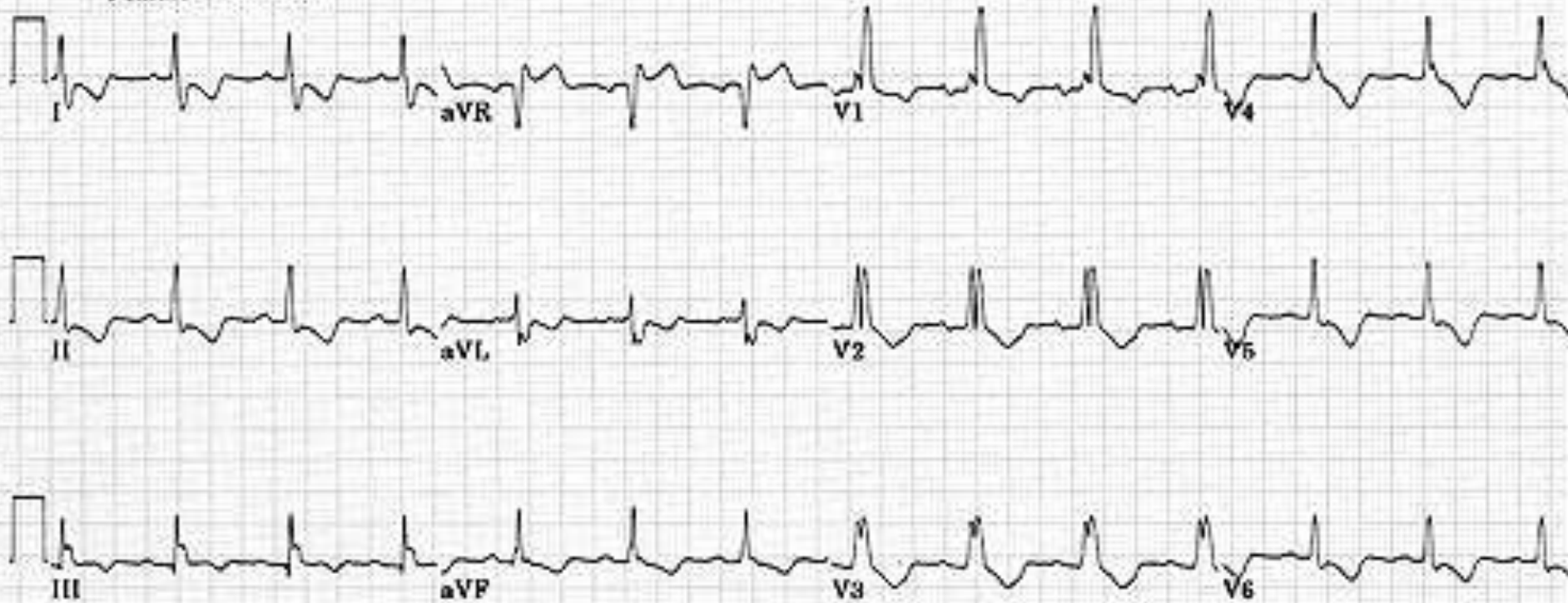

SAĞ AKS SAPMASI

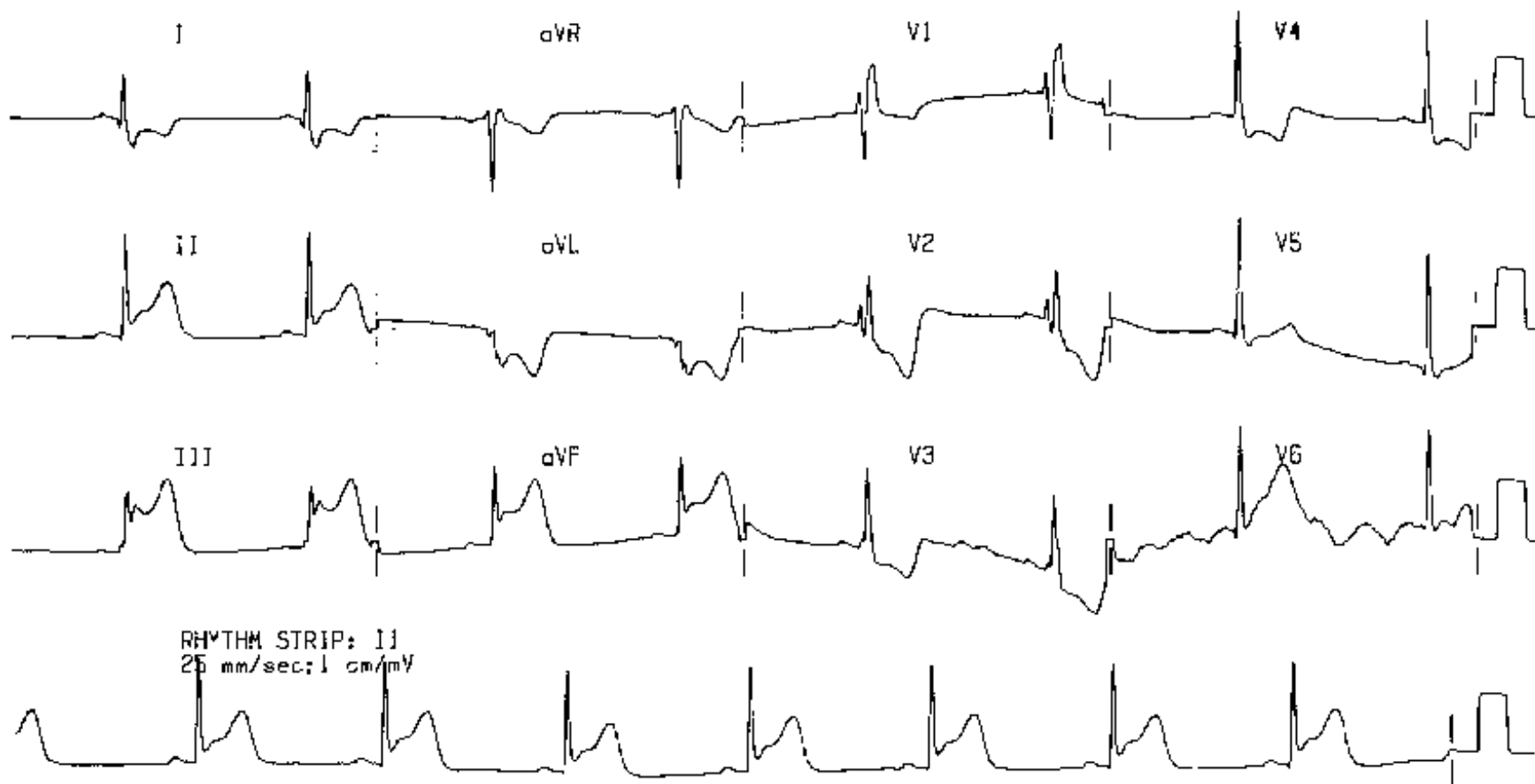


Sağ Dal Bloğu-1

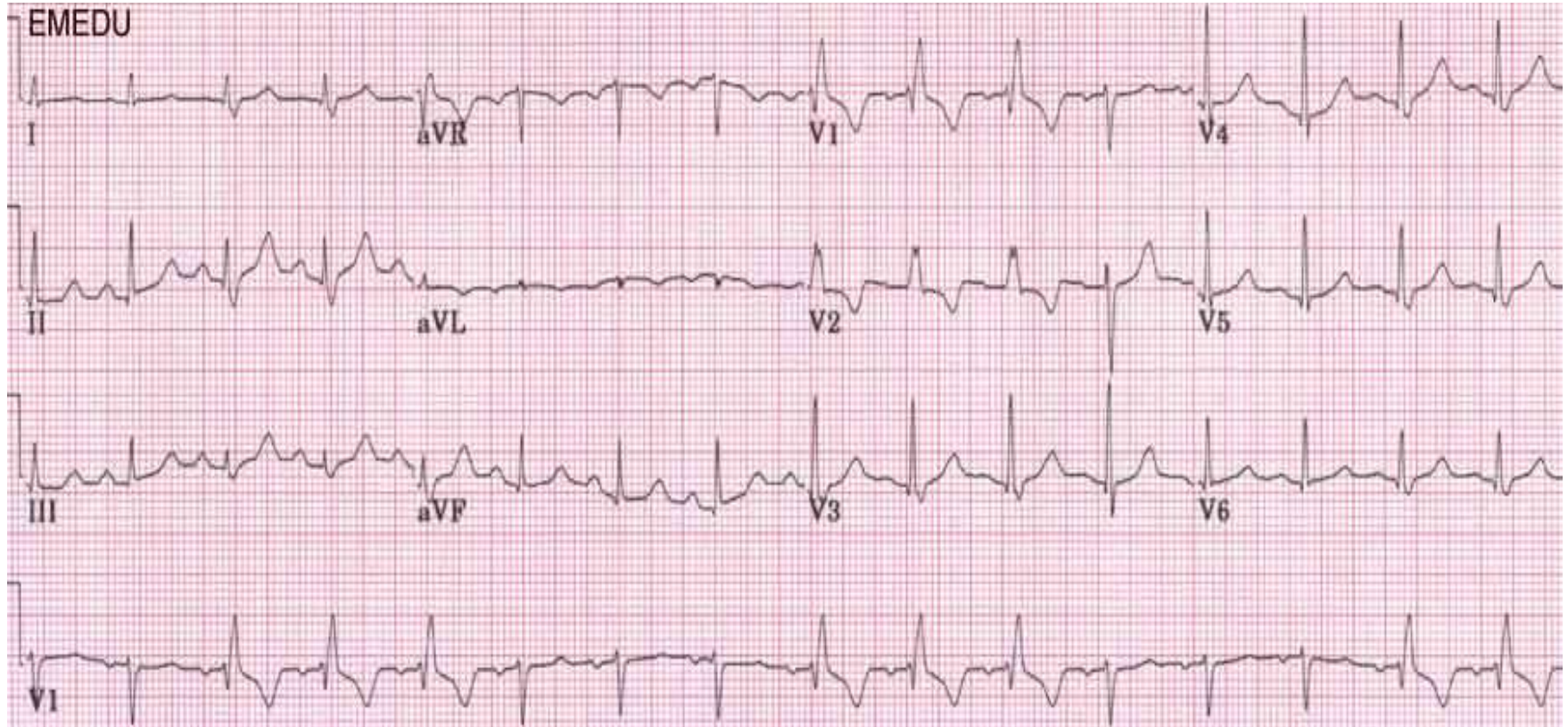
19-SEP-1932 (64 yr)
Female Caucasian



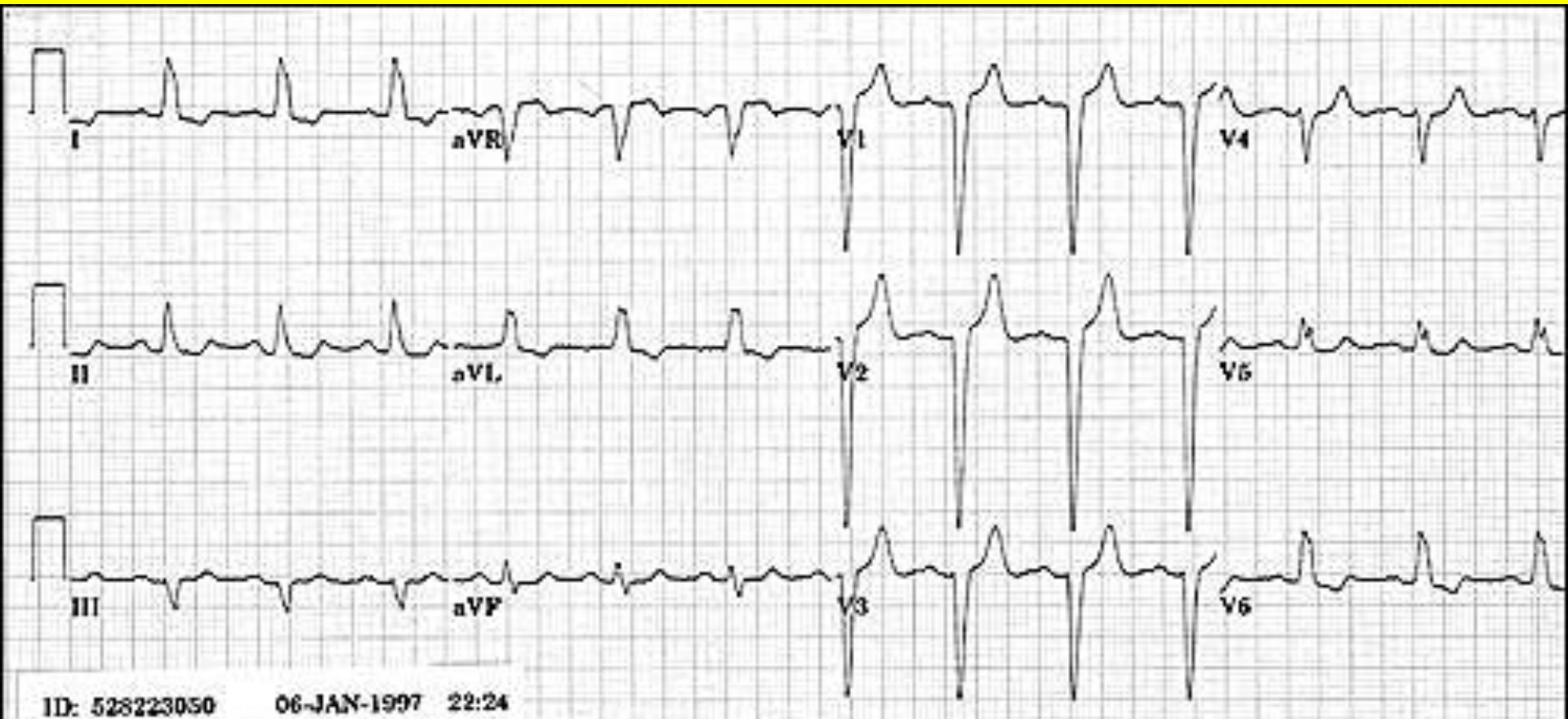
Sağ Dal Bloğu-2






Sağ Dal Bloğu-3



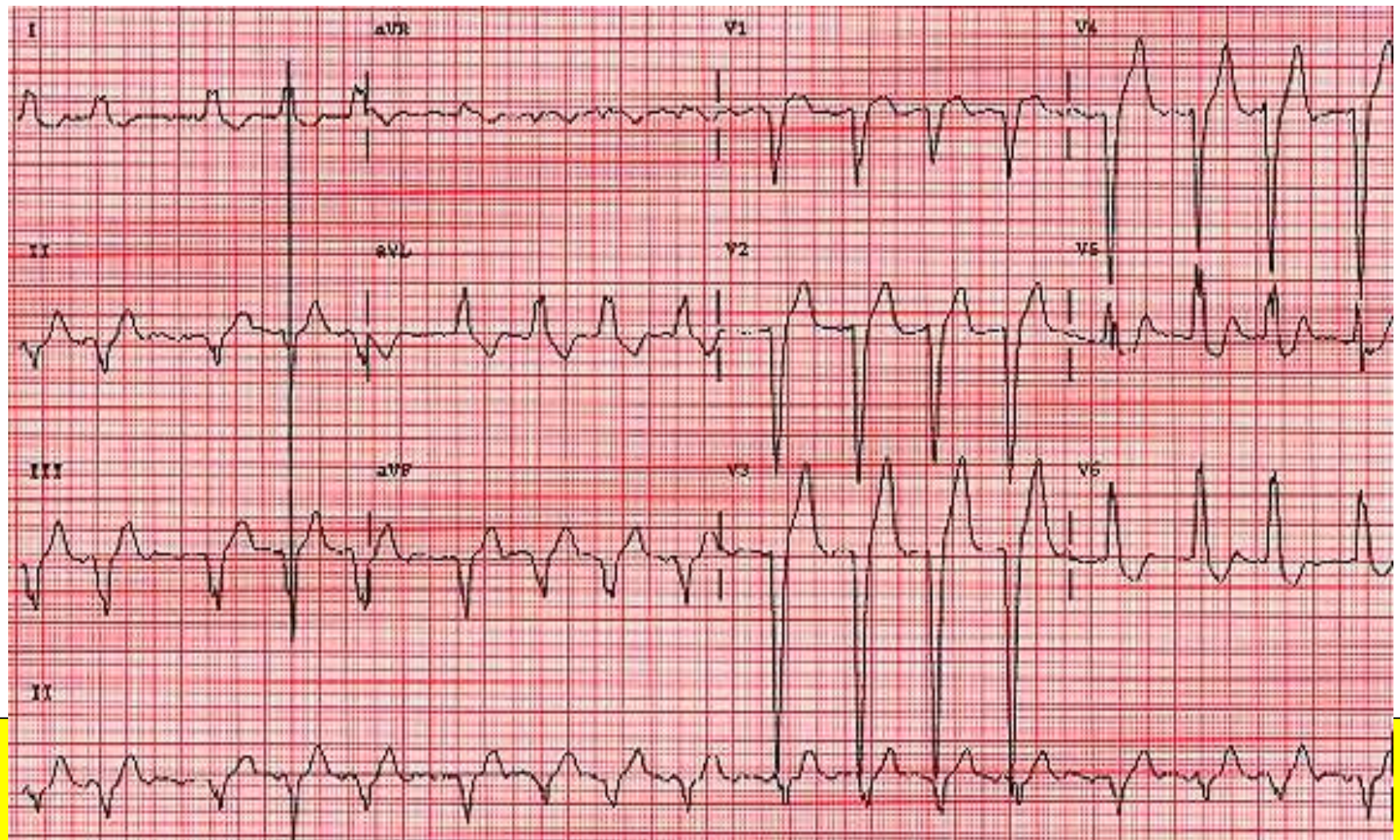
Sol Dal Bloğu-1



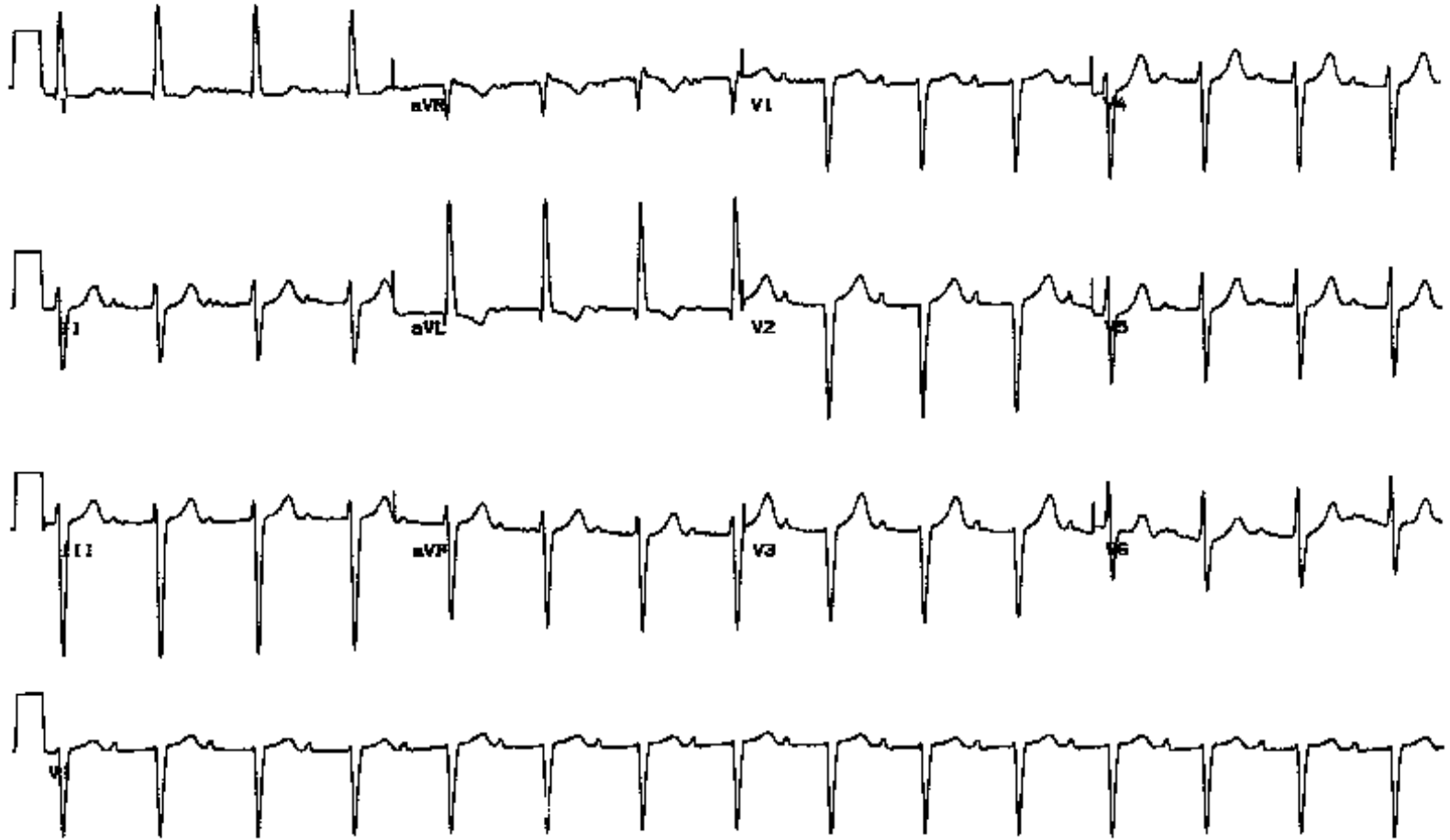
Sol Dal Bloğu-2



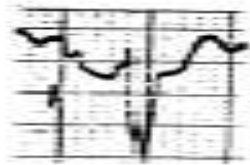
Sol Dal Bloğu-3




Sol Anterior Fasikül Bloğu



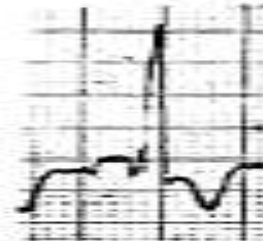
Sol Posterior Fasikül Bloğu




I



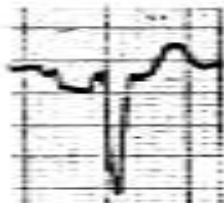II



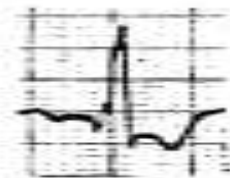
III



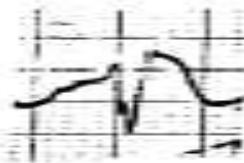aVR



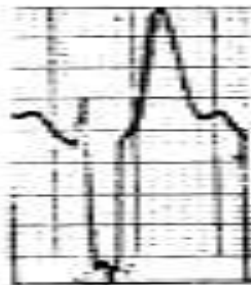
aVL



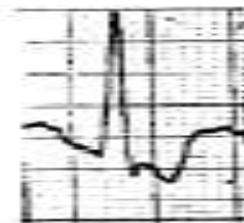aVF



V₁



V₄



V₆

Trifasiküler Blok

13-Jul-1999 09:44:16

Female

MHS TRUST

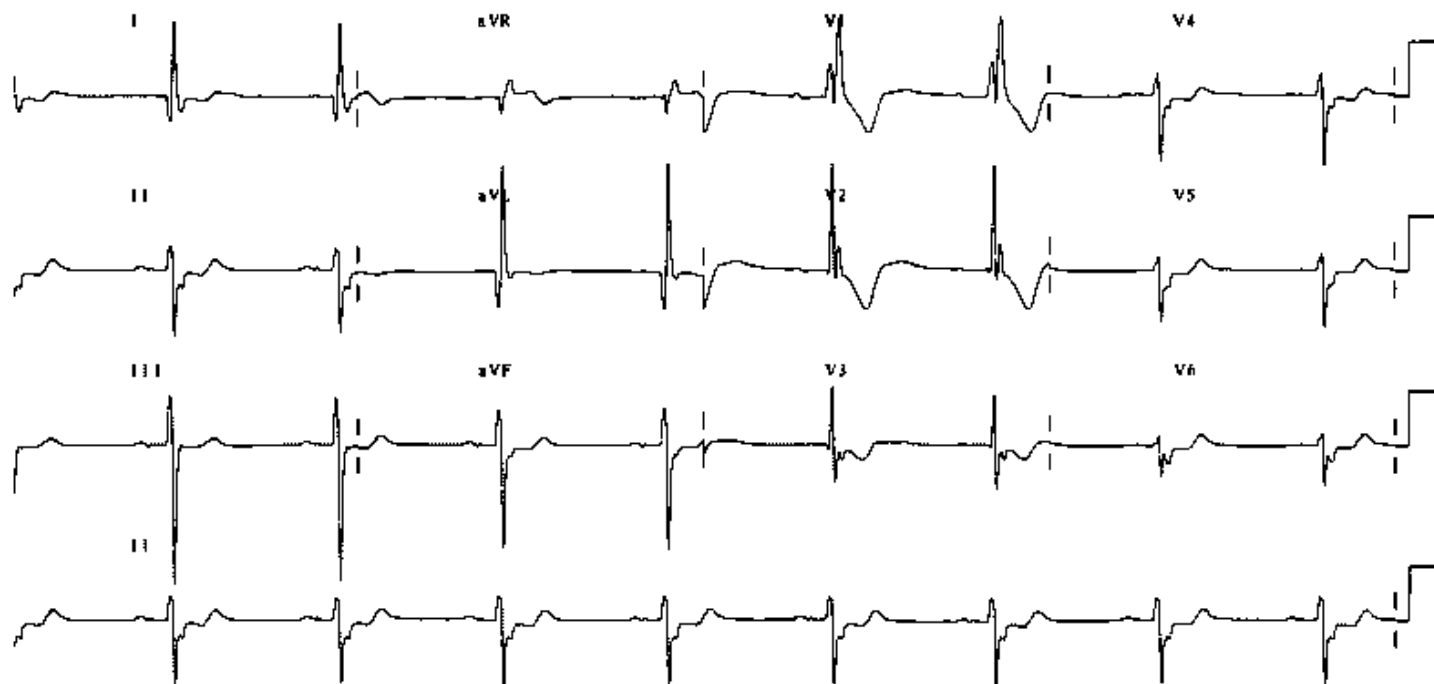
Department: BI

Operator: JLR

DOB

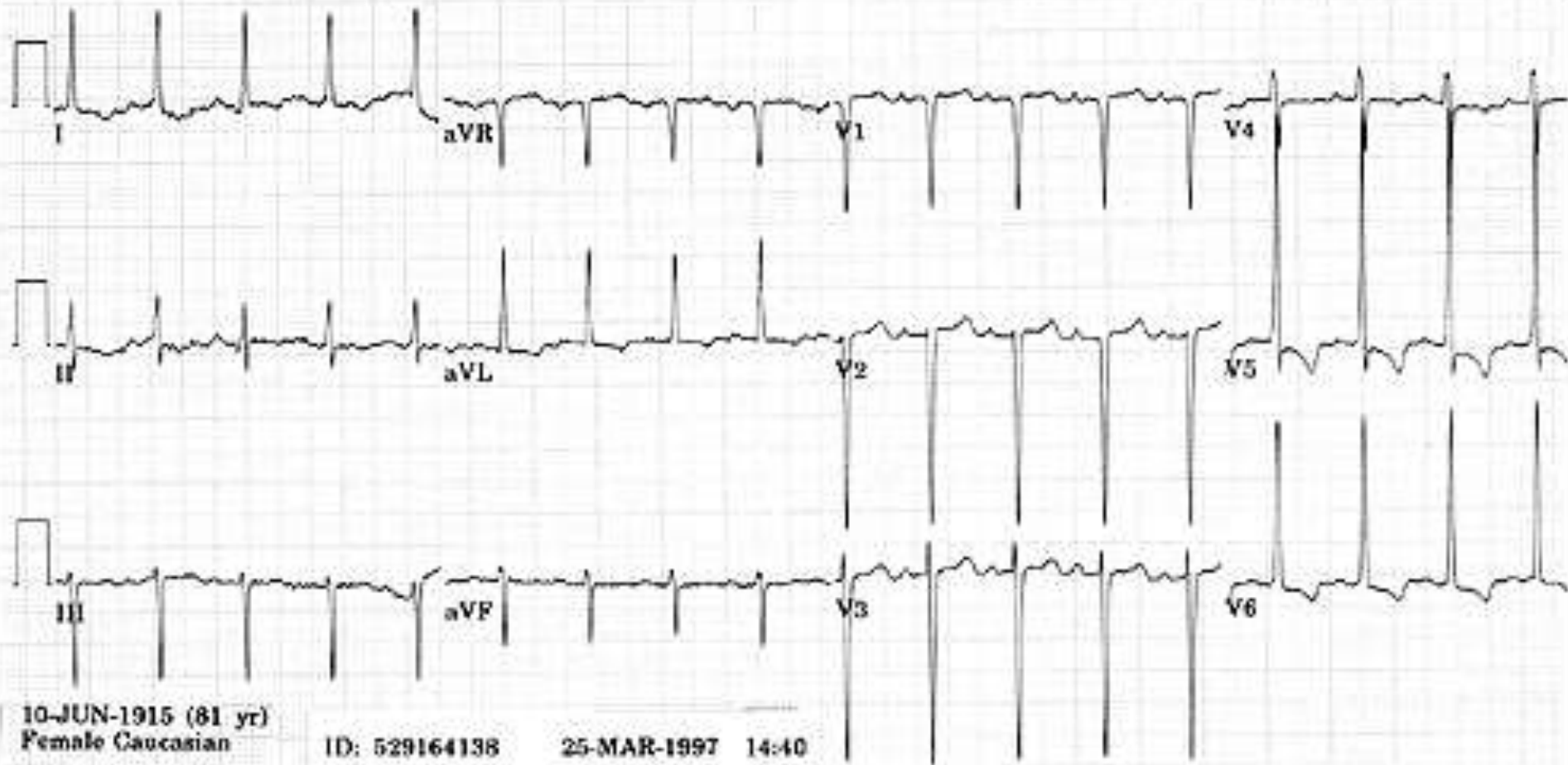
14-09-08

Requested by:



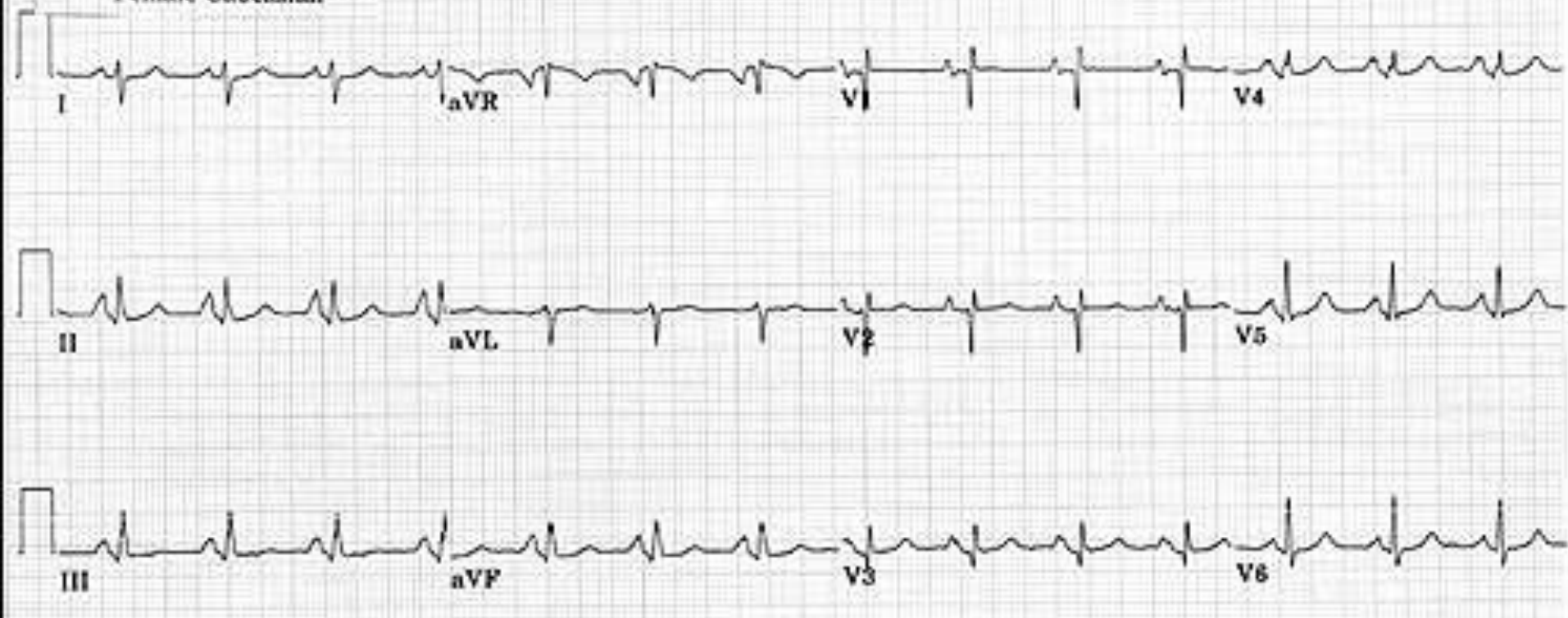
25 mm/s 10 mm/mV F ~ 0.5 Hz - 40 Hz W 14227

Sol Ventrikül Hipertrofisi



Sağ Hipertrofi

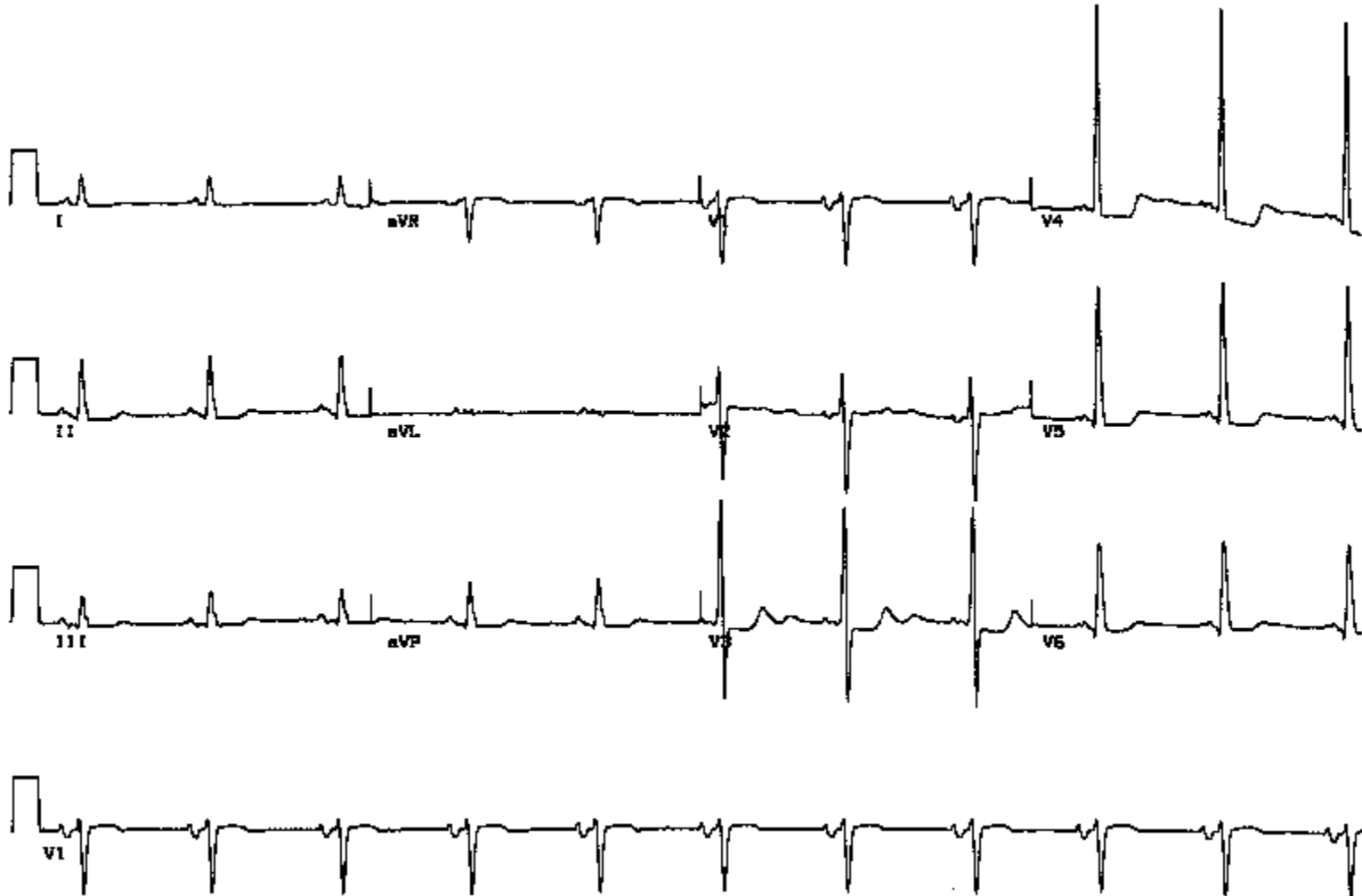
25-JUL-1942 (52 yr)
Female Caucasian



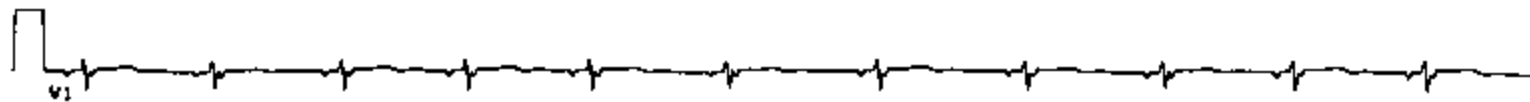

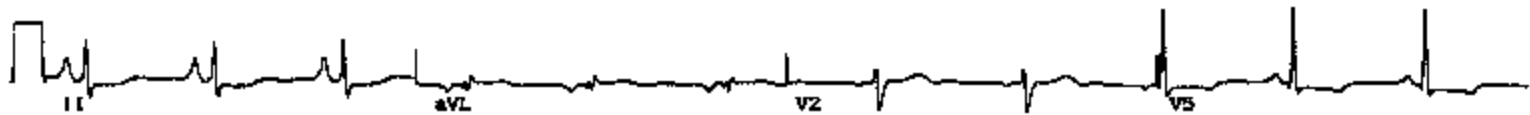

ID: 528549409 08-SEP-1994 12:55

© 1997 Frank G. Yanowitz, M.D.

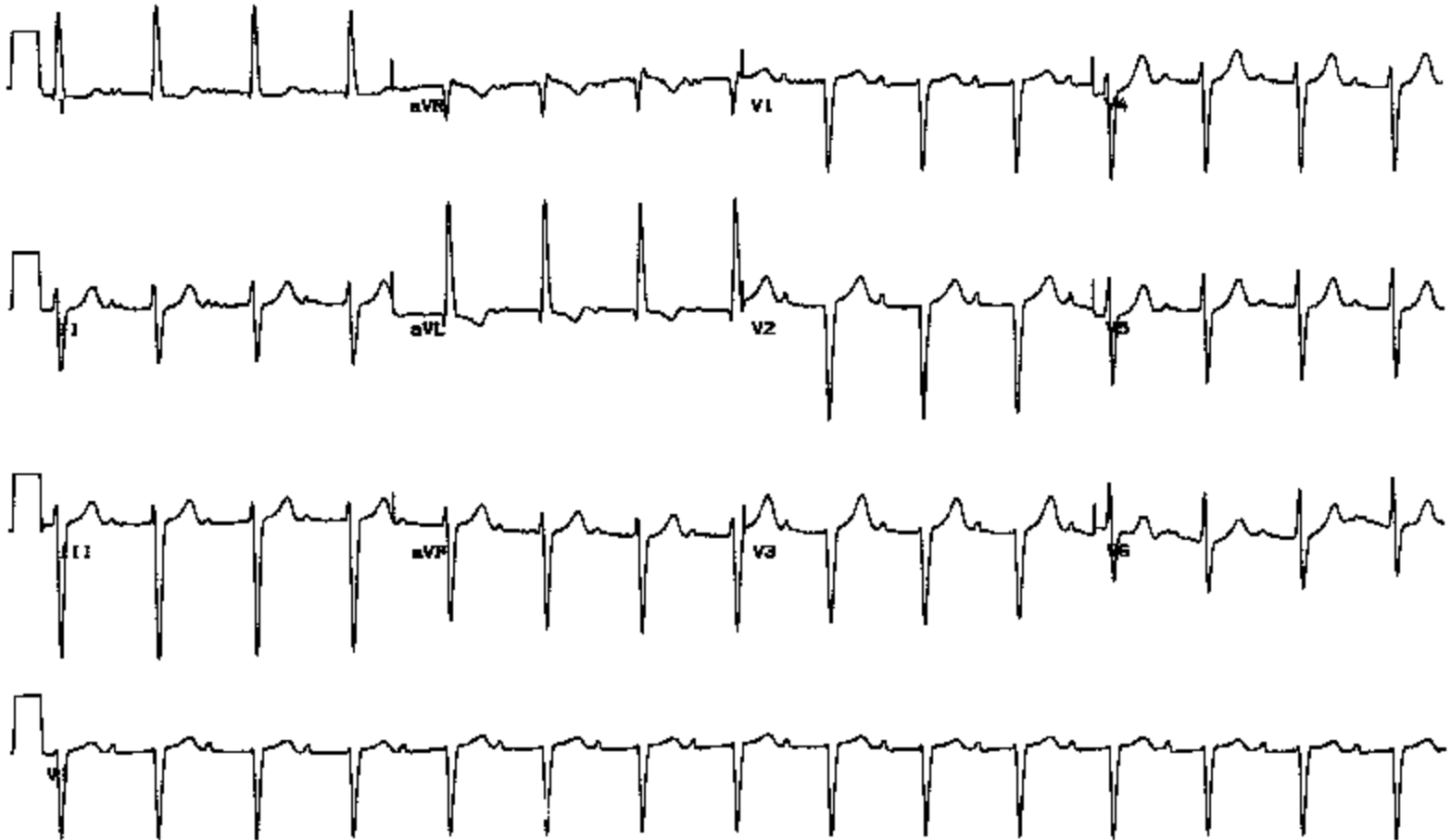Sol ventriküler ve sol atriyal hipertrofi



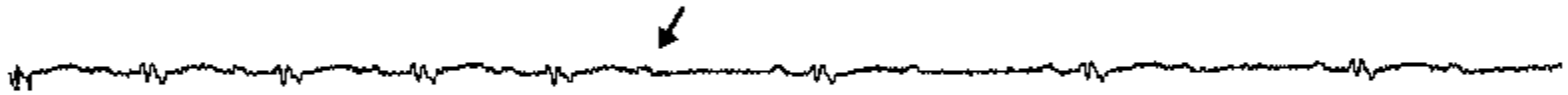
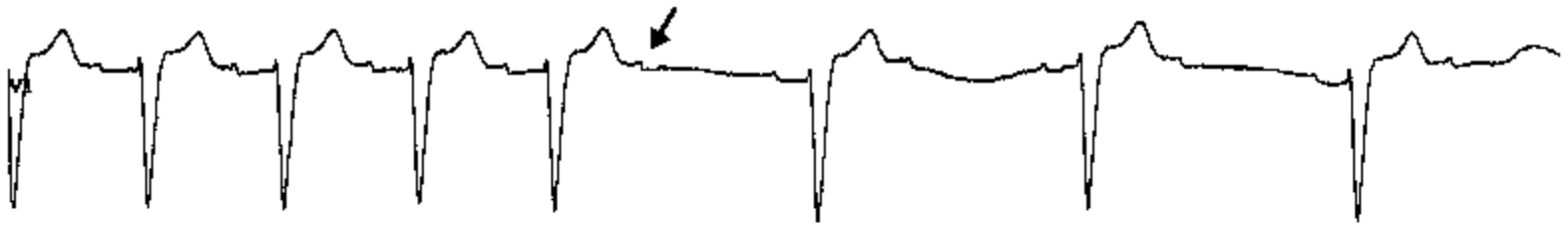
Sağ atriyal hipertrofi



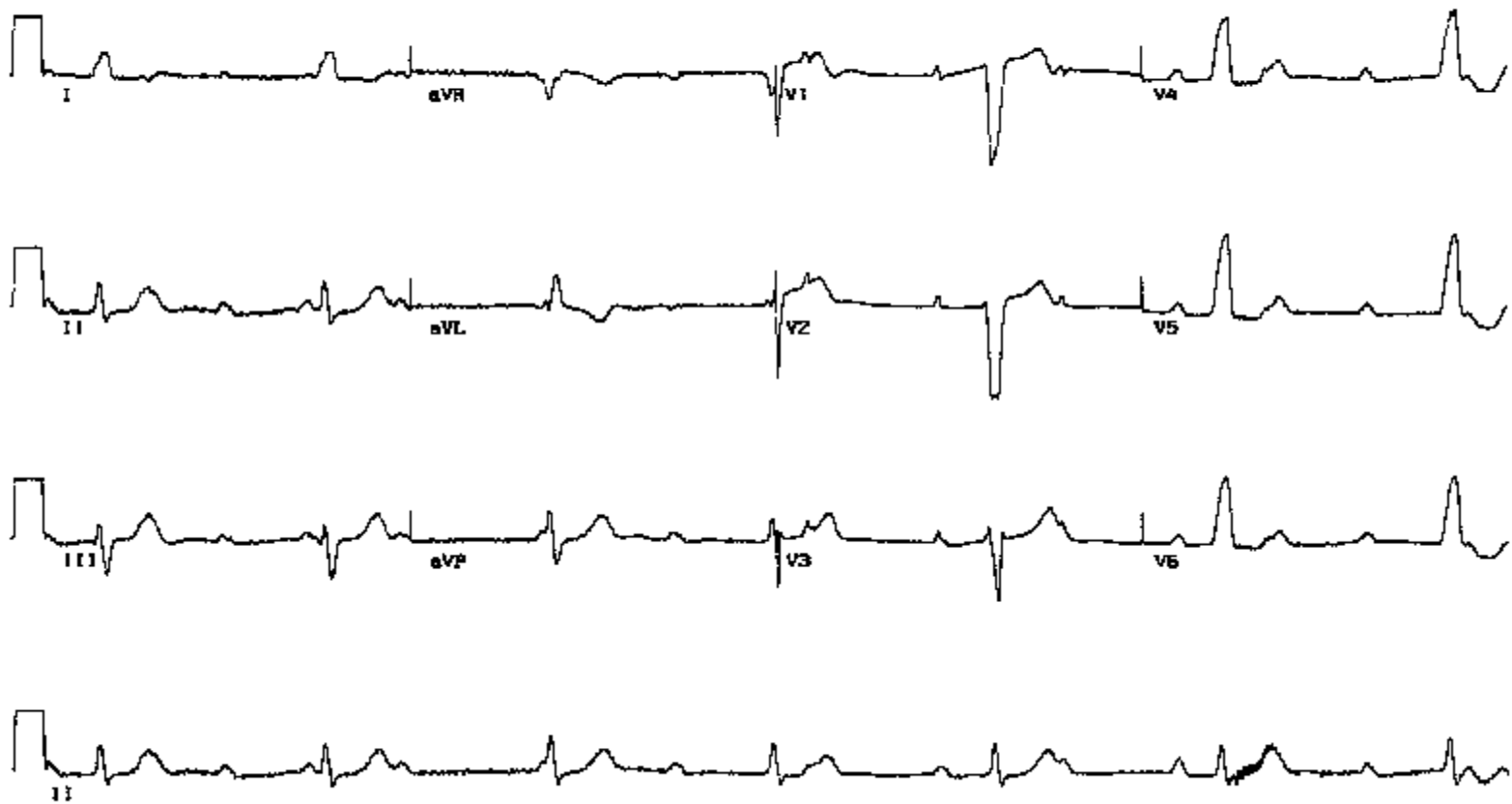
1. Derece AV Blok



2:1 AV Blok



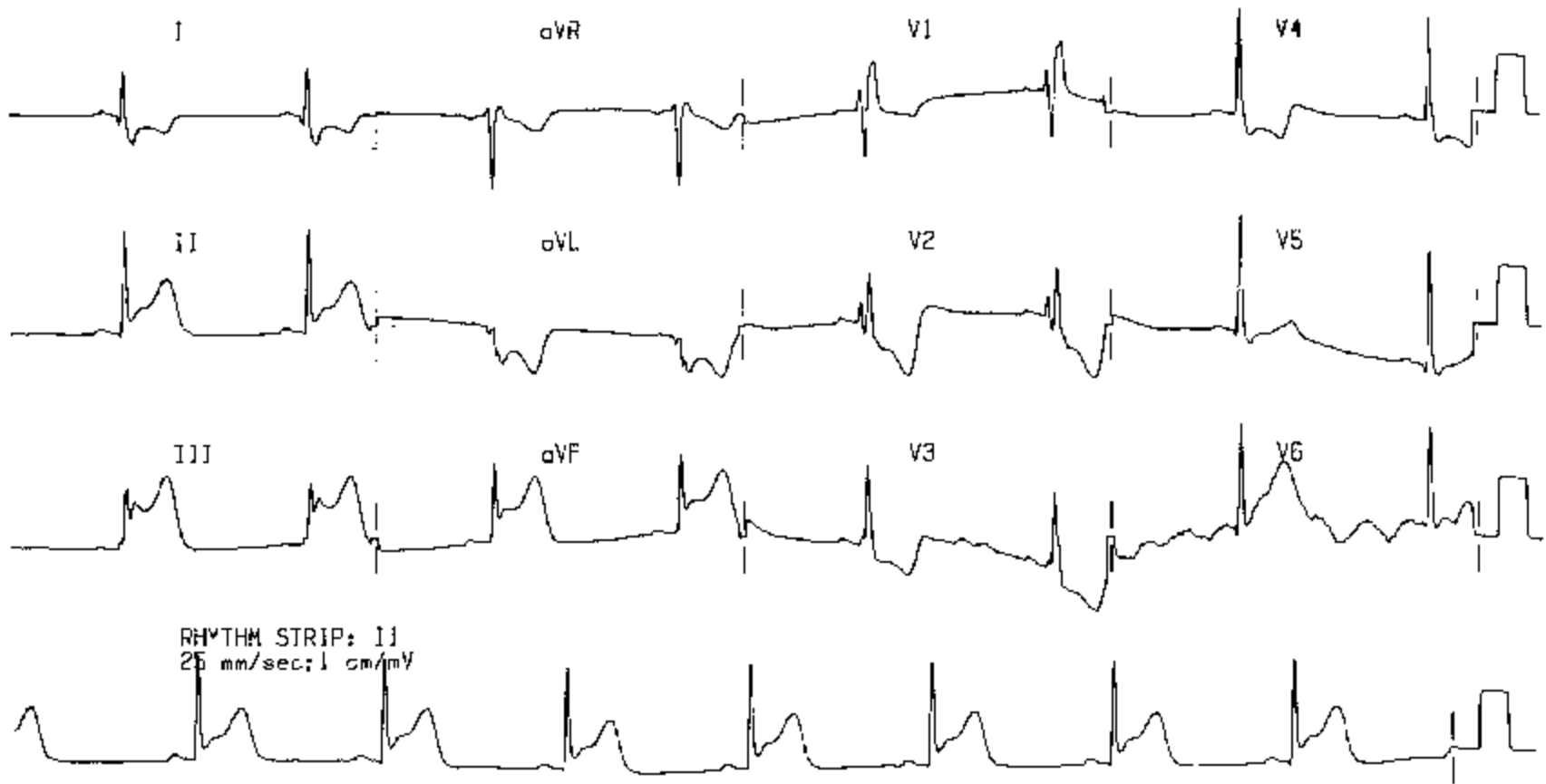
AV Tam Blok



Sinüs bradikardisi+

RBBB+

Akut inferiorposteriorlateral MI

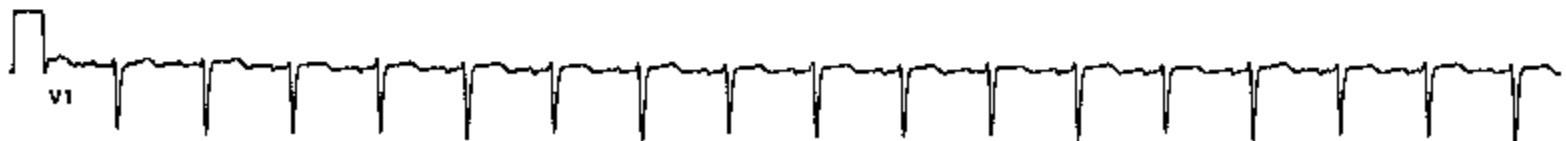
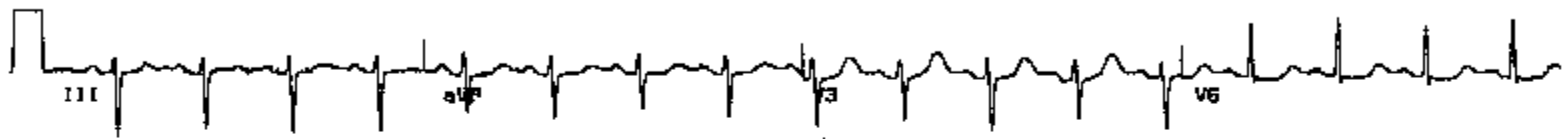

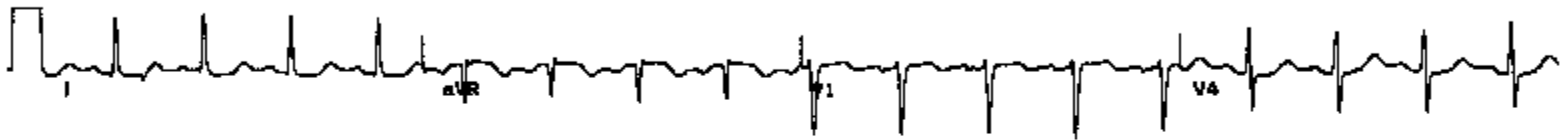


RHYTHM STRIP: II
25 mm/sec; 1 cm/mV

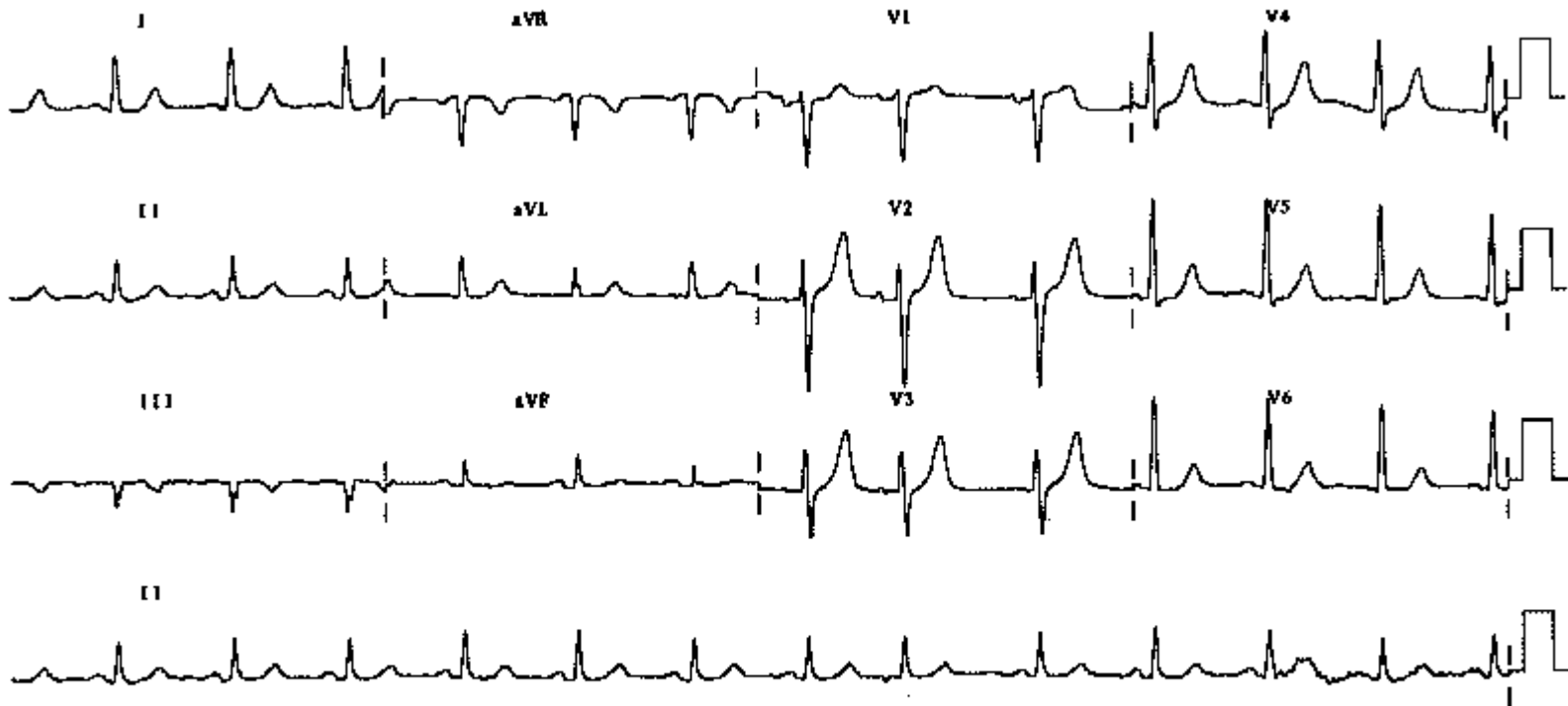
Sinüsal Takikardi

Referred by:

Uncont 1rus6



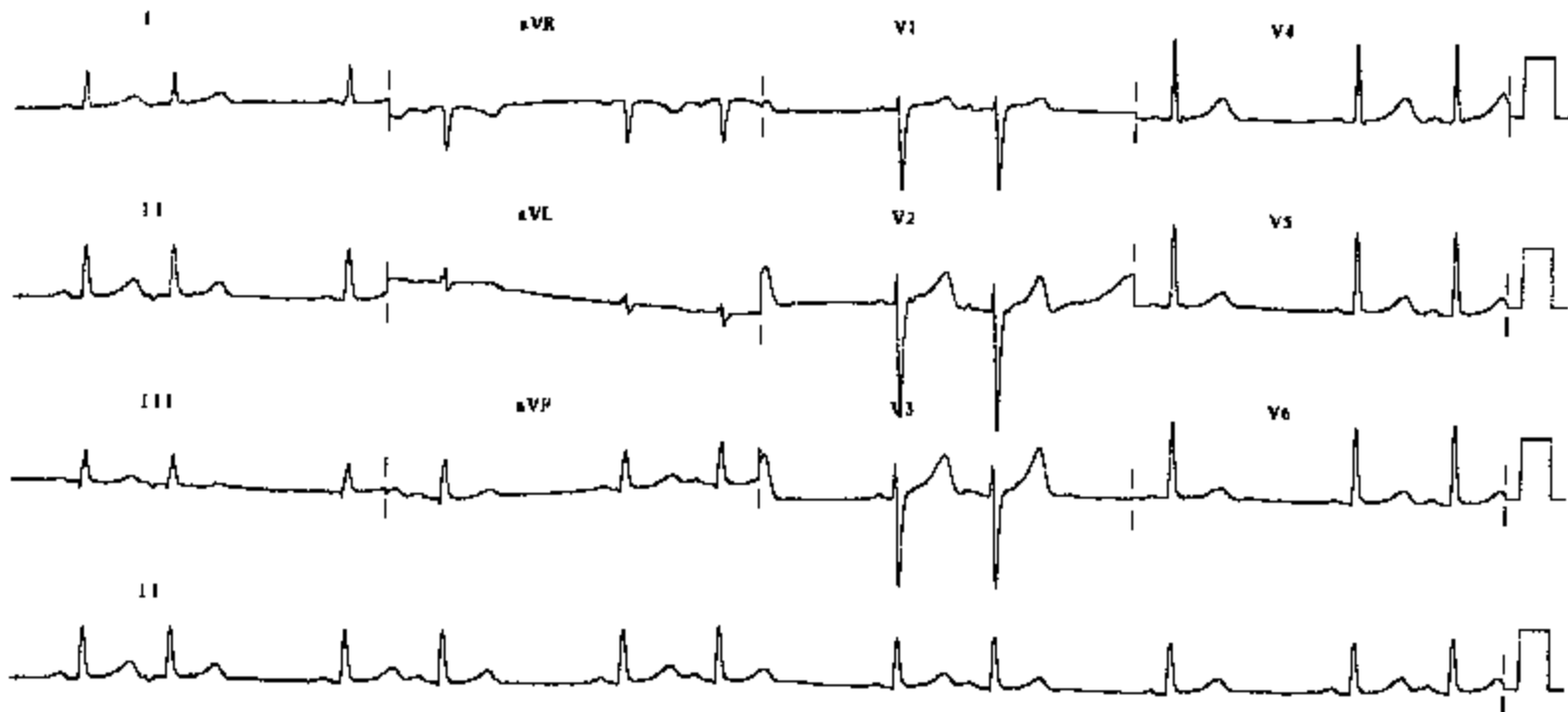
Atrial Premature Atım(APS)



25 mm/s 10 mm/mV P ~ 0.5 Hz - 40 Hz W 09663

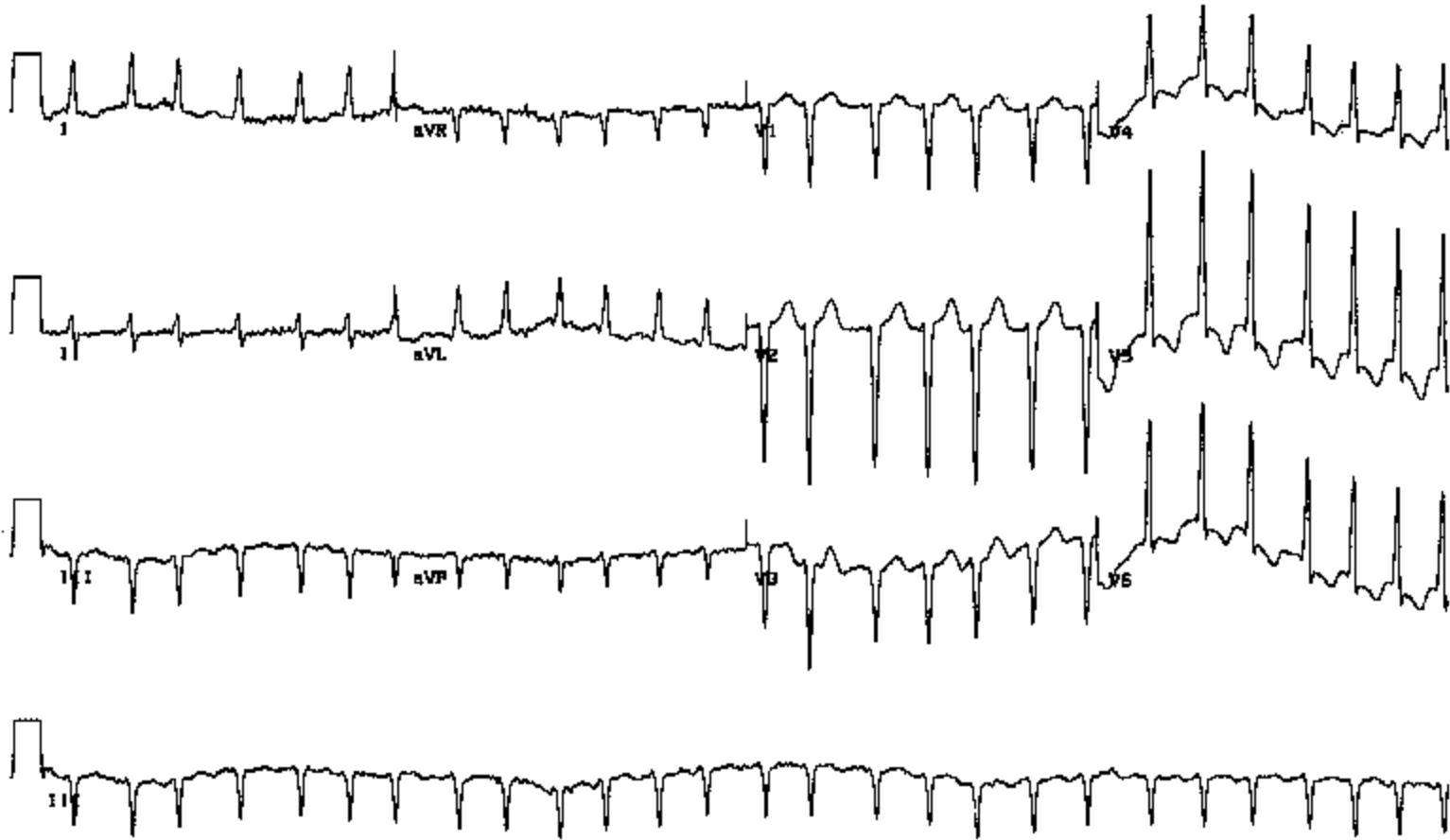
Atrial Premature Atım(APS) Atrial Bigemine atımlar

Requested by:
OPD

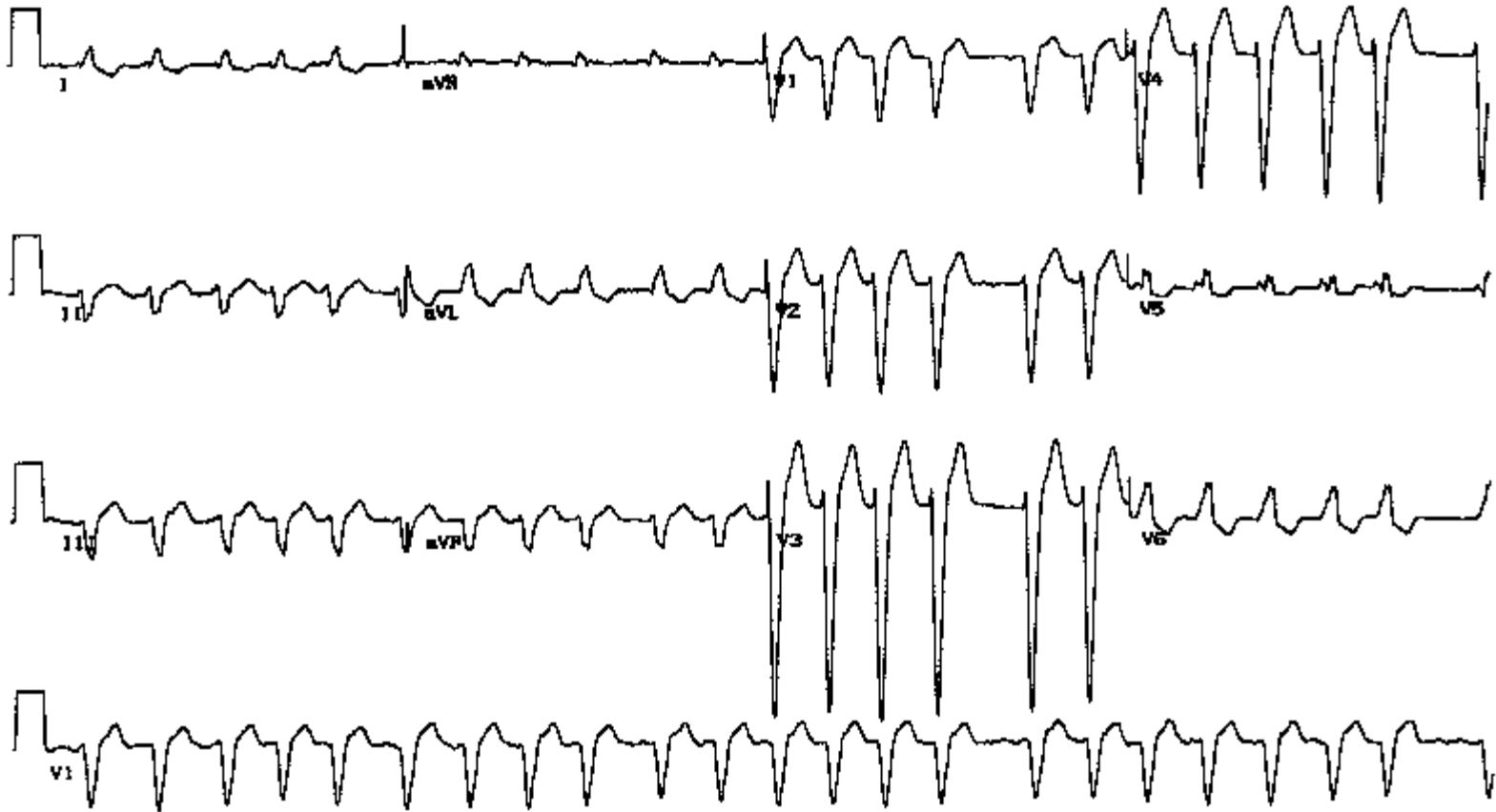

35 mm/s 10 mm/mV

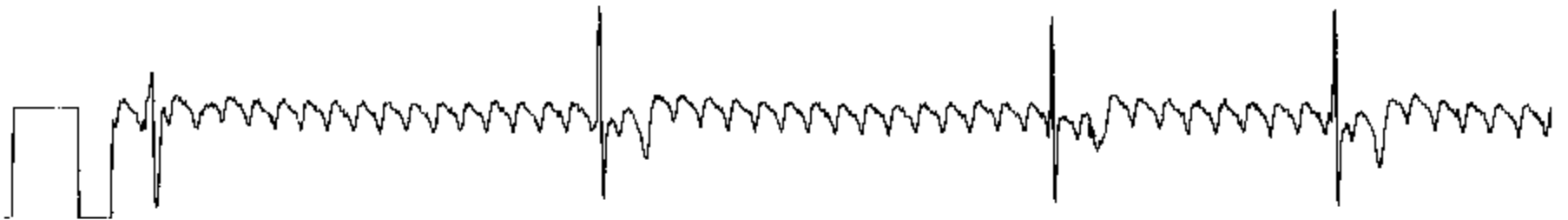
Hızlı Ventriküler geçişli AF



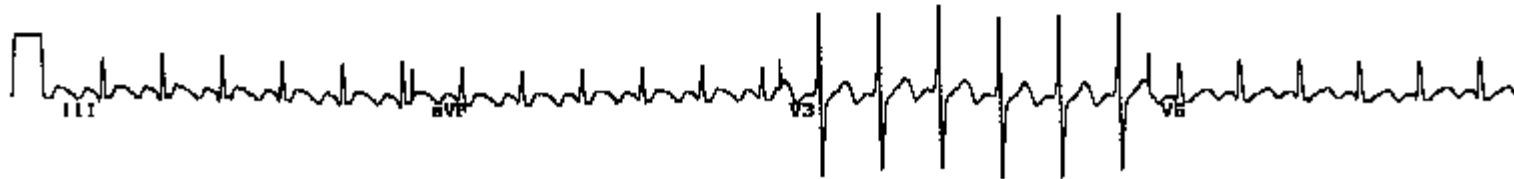


Hızlı Ventriküler geçişli AF +LBBB



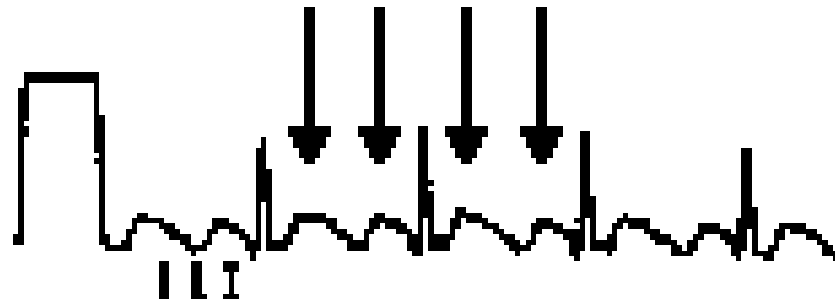Atrial Flutter



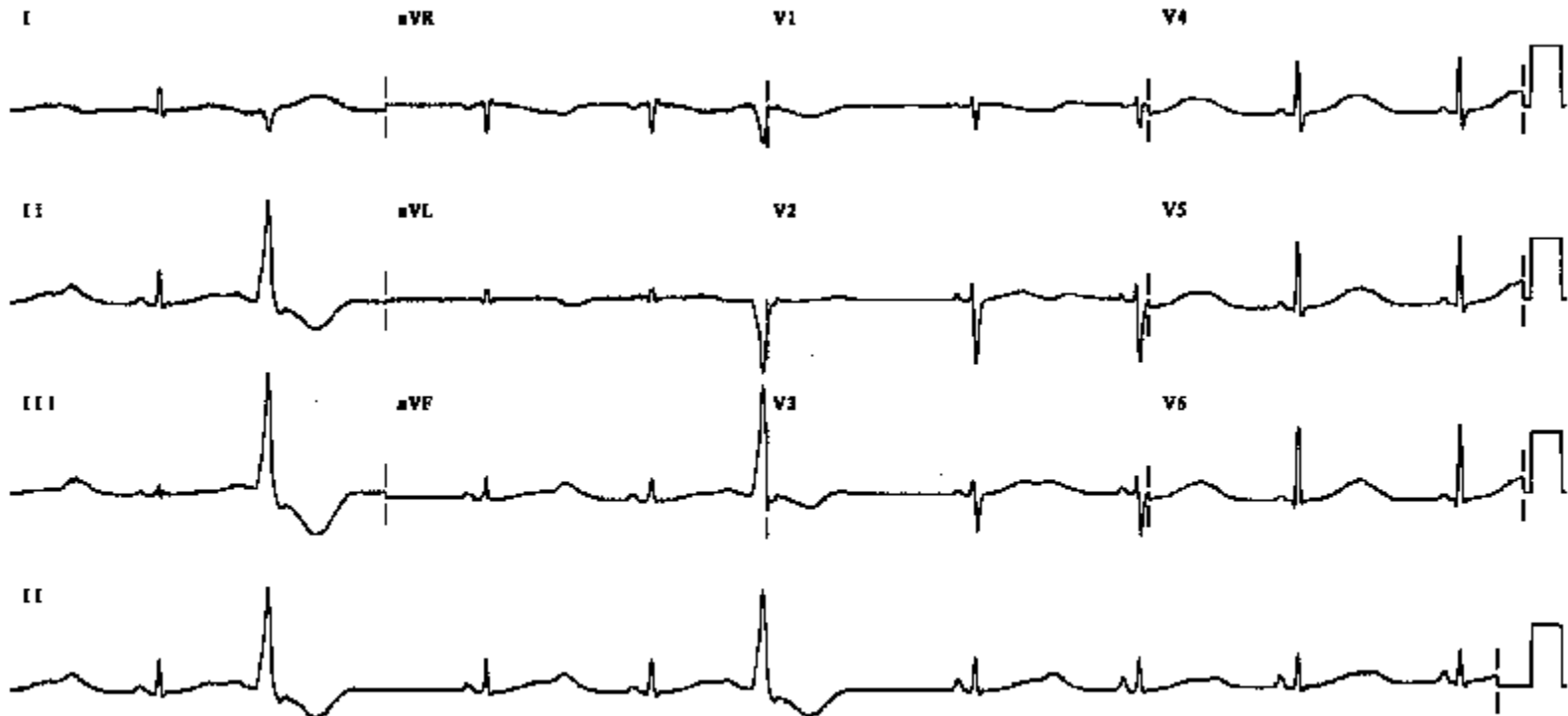
2:1 geişli Atriyal Flutter



2:1 geçişli Atriyal Flutter



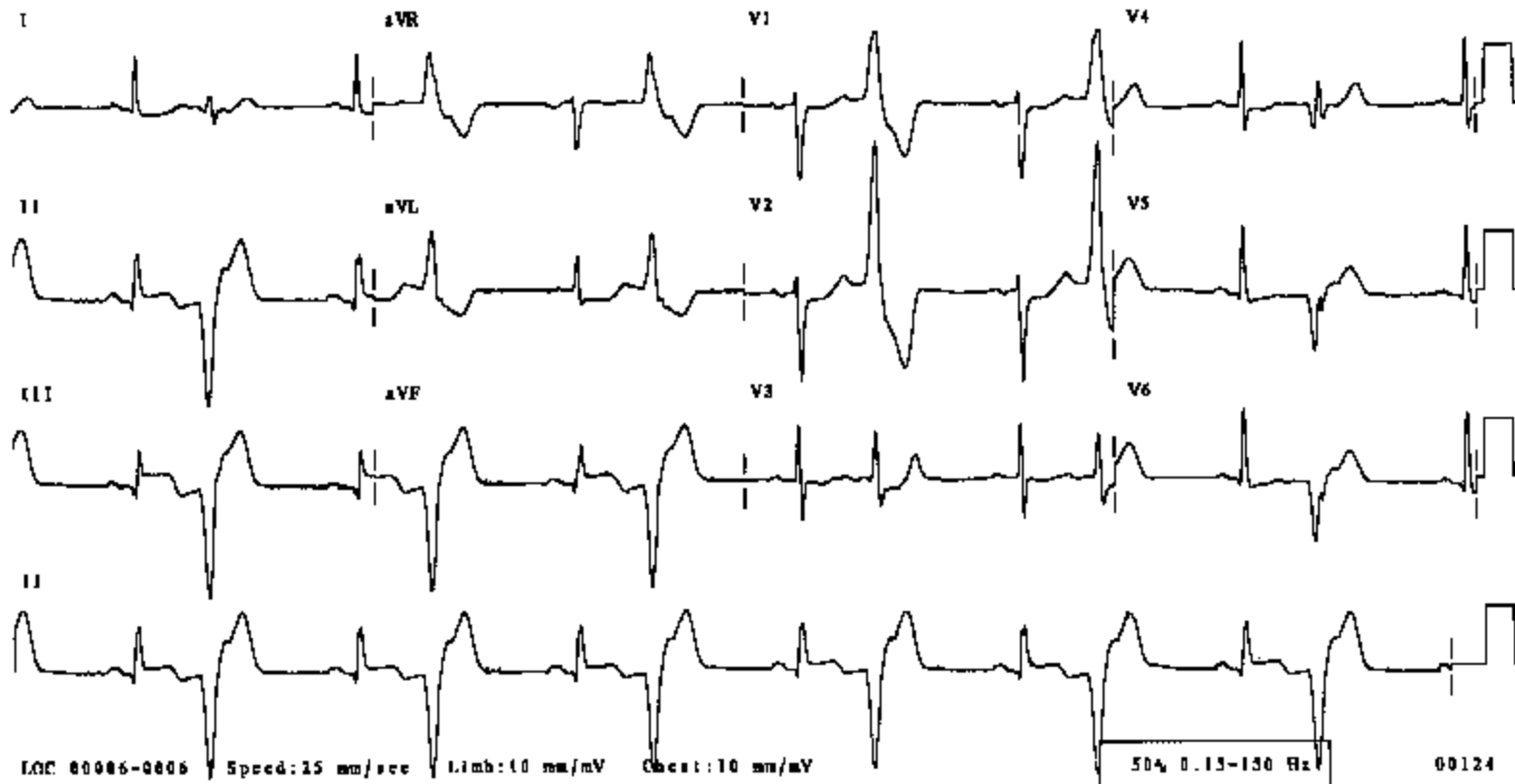
Ventriküler Prematüre Atım(VPS)



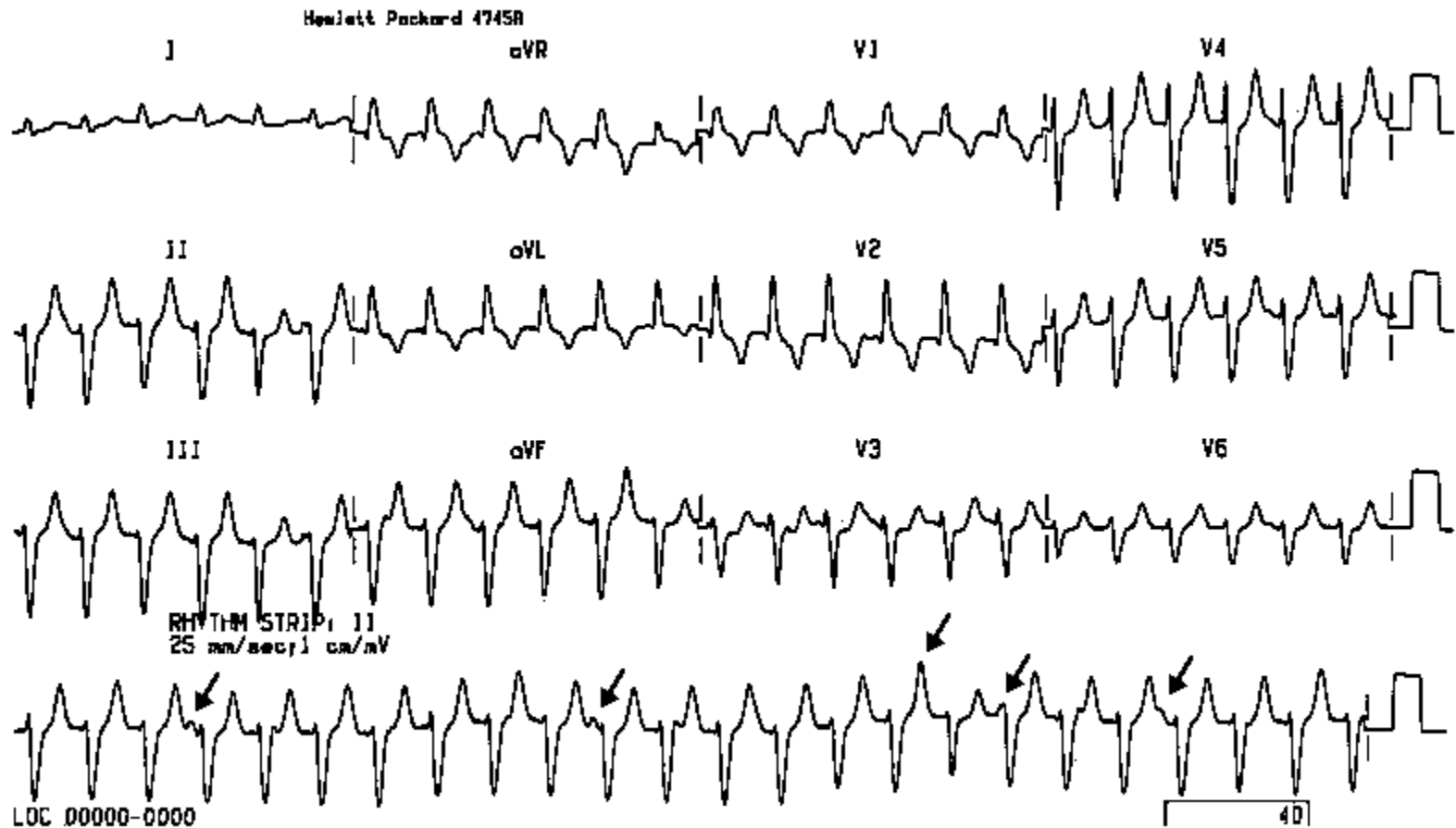
LOC 00000-0000 Speed: 25 mm/sec Limb: 10 mm/mV Chest: 10 mm/mV

SDr 0.15-150 Hz

Ventriküler Bigemine Atımlar



Ventriküler Takikardi



Ventriküler Takikardi

HORIZONTAL
 ORS
 P
 QRS
 T
 FRONTAL

RATE 85
 PR 140
 QRSD 111
 QT 251
 QTc 463

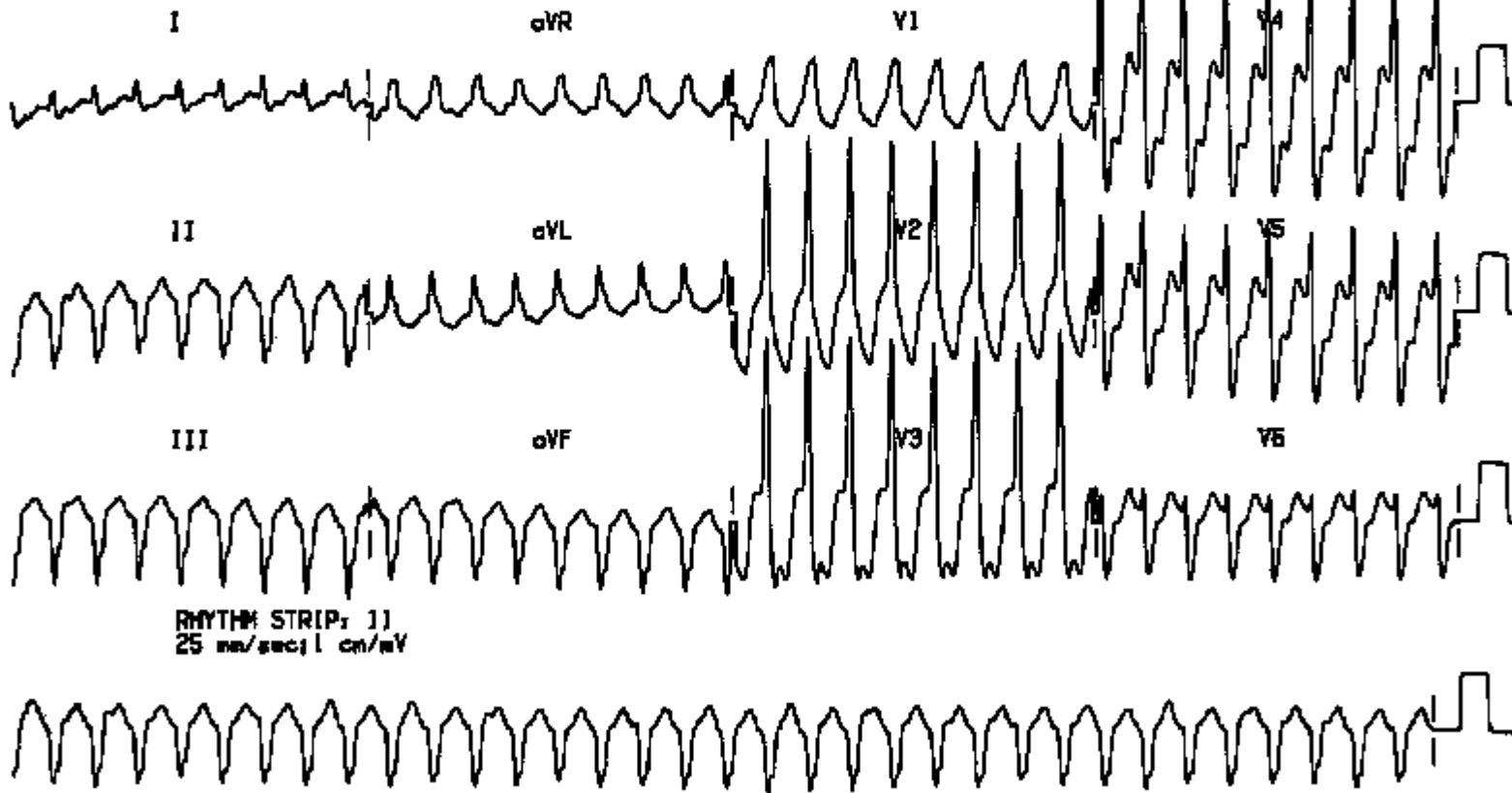
. INCOMPLETE RIGHT BUNDLE BRANCH BLOCK
 . RVH WITH ST-T ABNORMALITIES
 . INFERIOR INFARCT
 . NONSPECIFIC LATERAL ST DEPRESSION
 . V4, V5, V6 NOT USED FOR MORPHOLOGY ANALYSIS

-RHYTHM ECG-

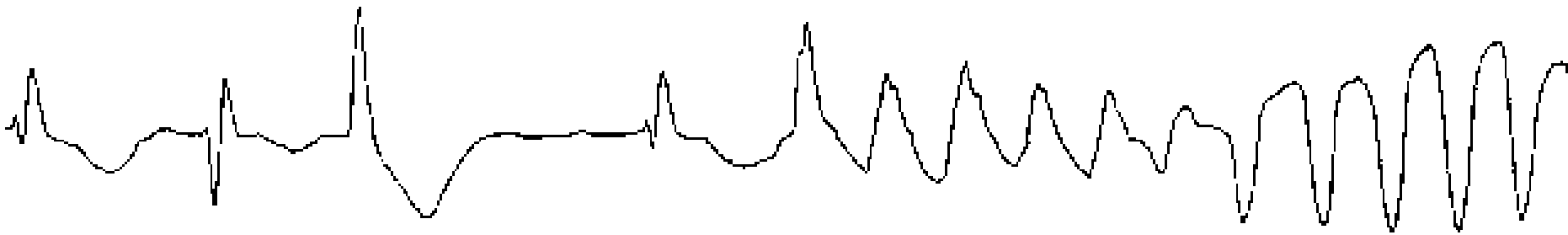
Emergency Department

PRELIMINARY. MD must review.

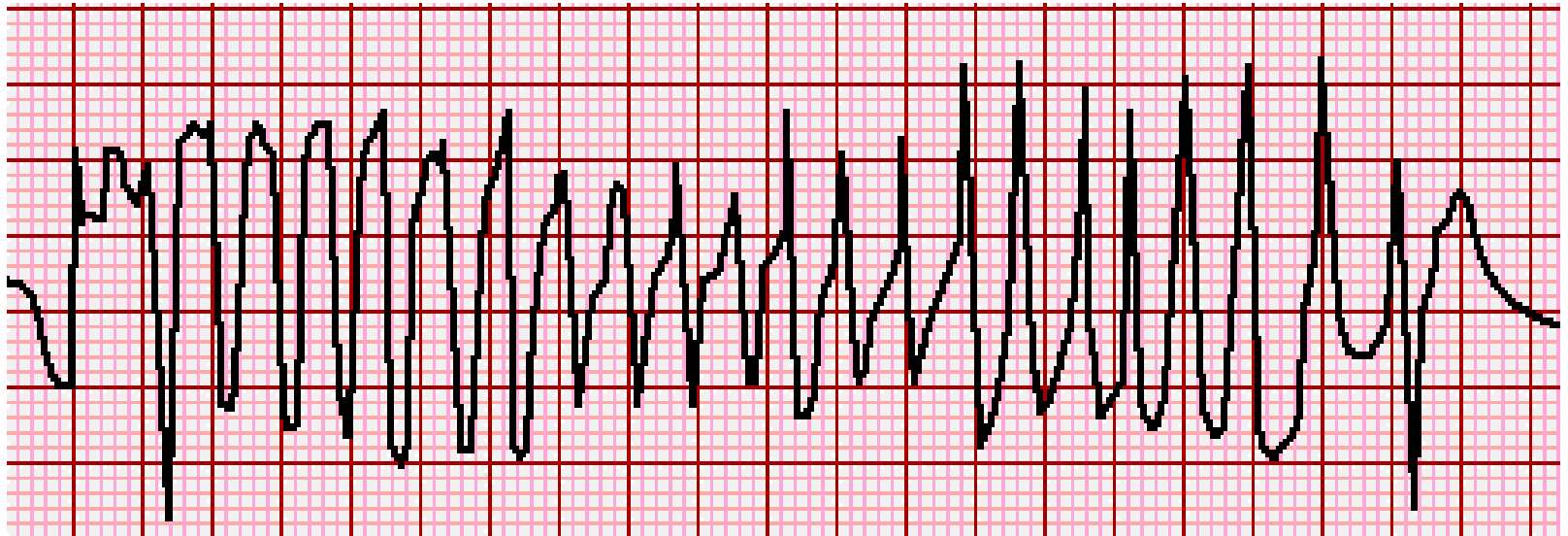
HP507



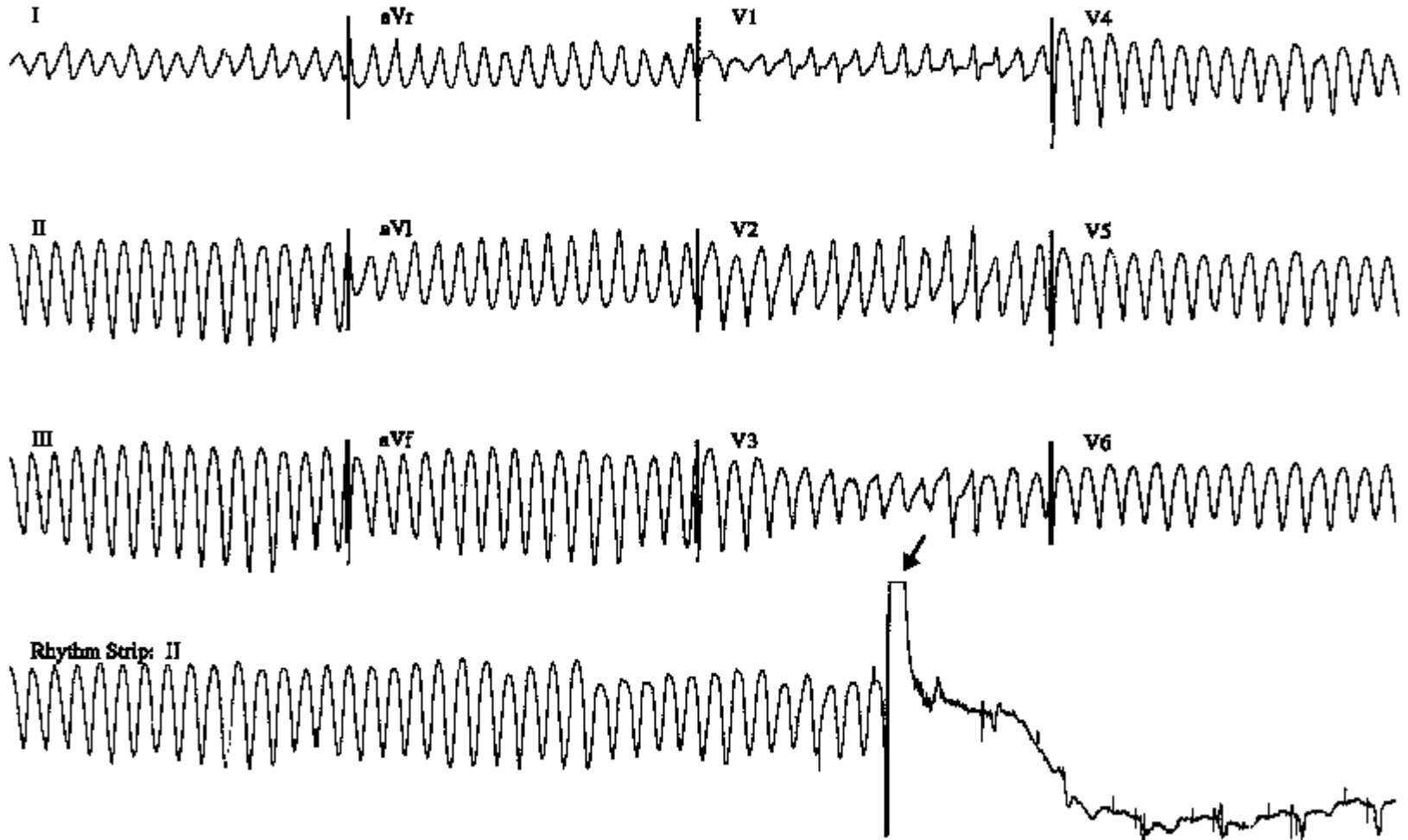
Torsades de Pointes



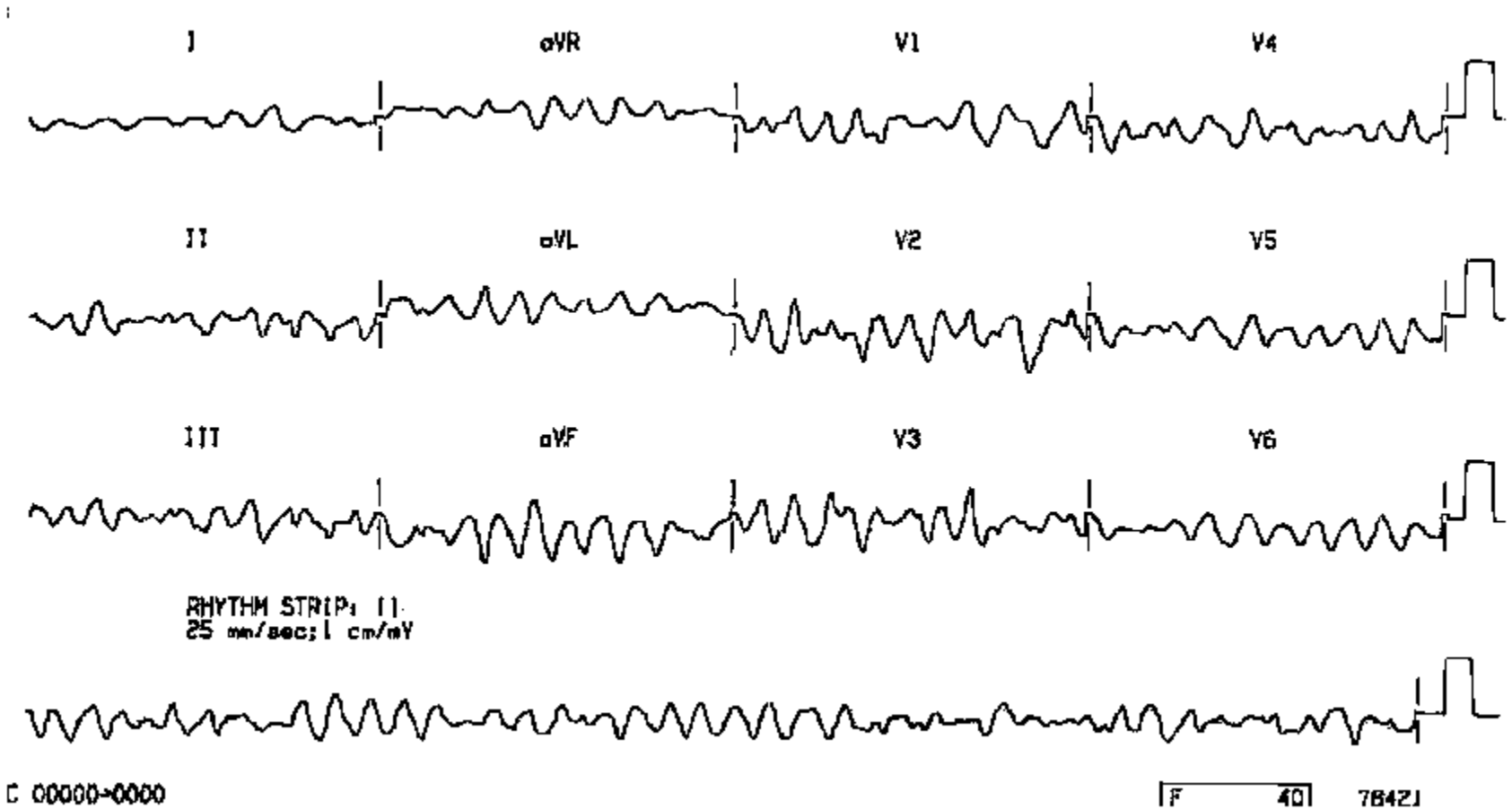
Torsades de Pointes



Polimorfik VT



Ventriküler Fibrilasyon



İNFARKTÜS - QRST

12 Lead ECG

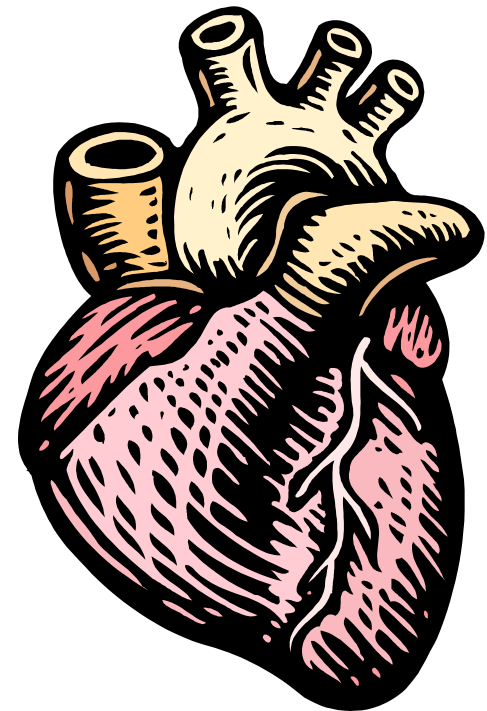
Inferior – II, III, aVF

Septal – V1 – V2

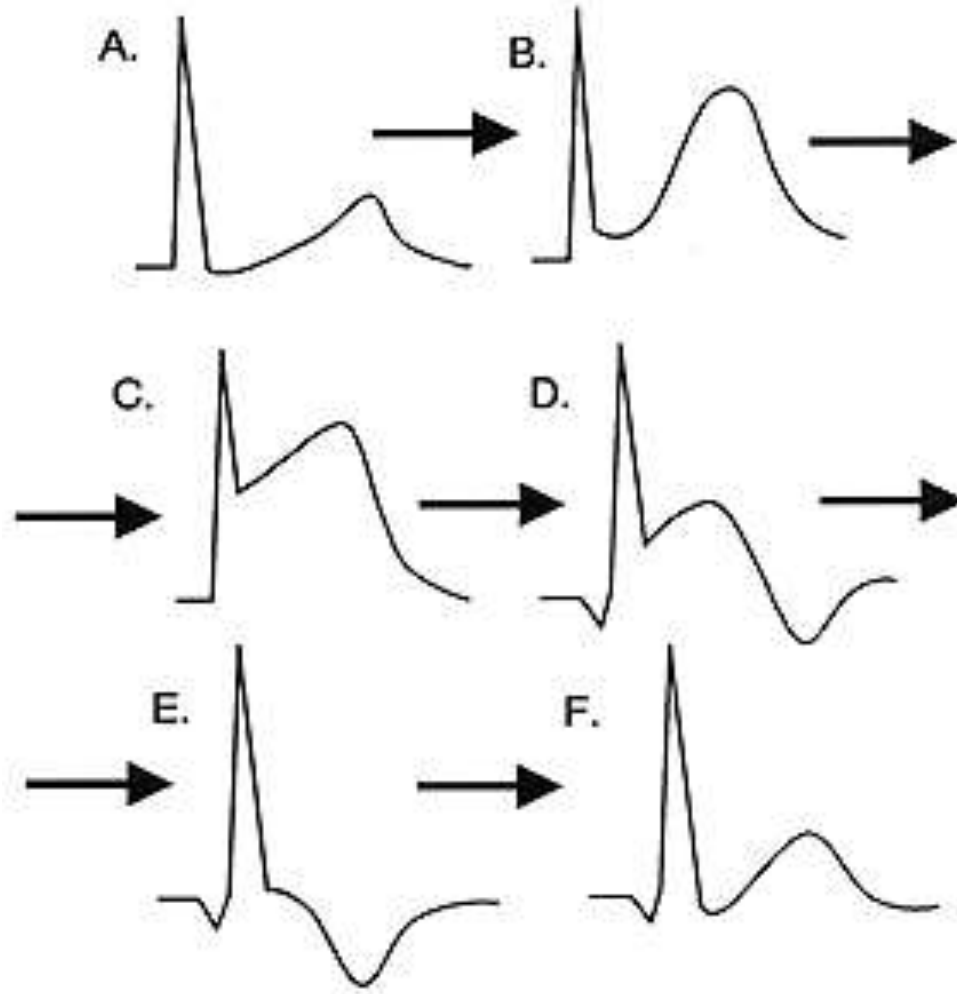
Anterior – V3 – V4

Lateral – V5 – V6

Yüksek Lateral – I, aVL

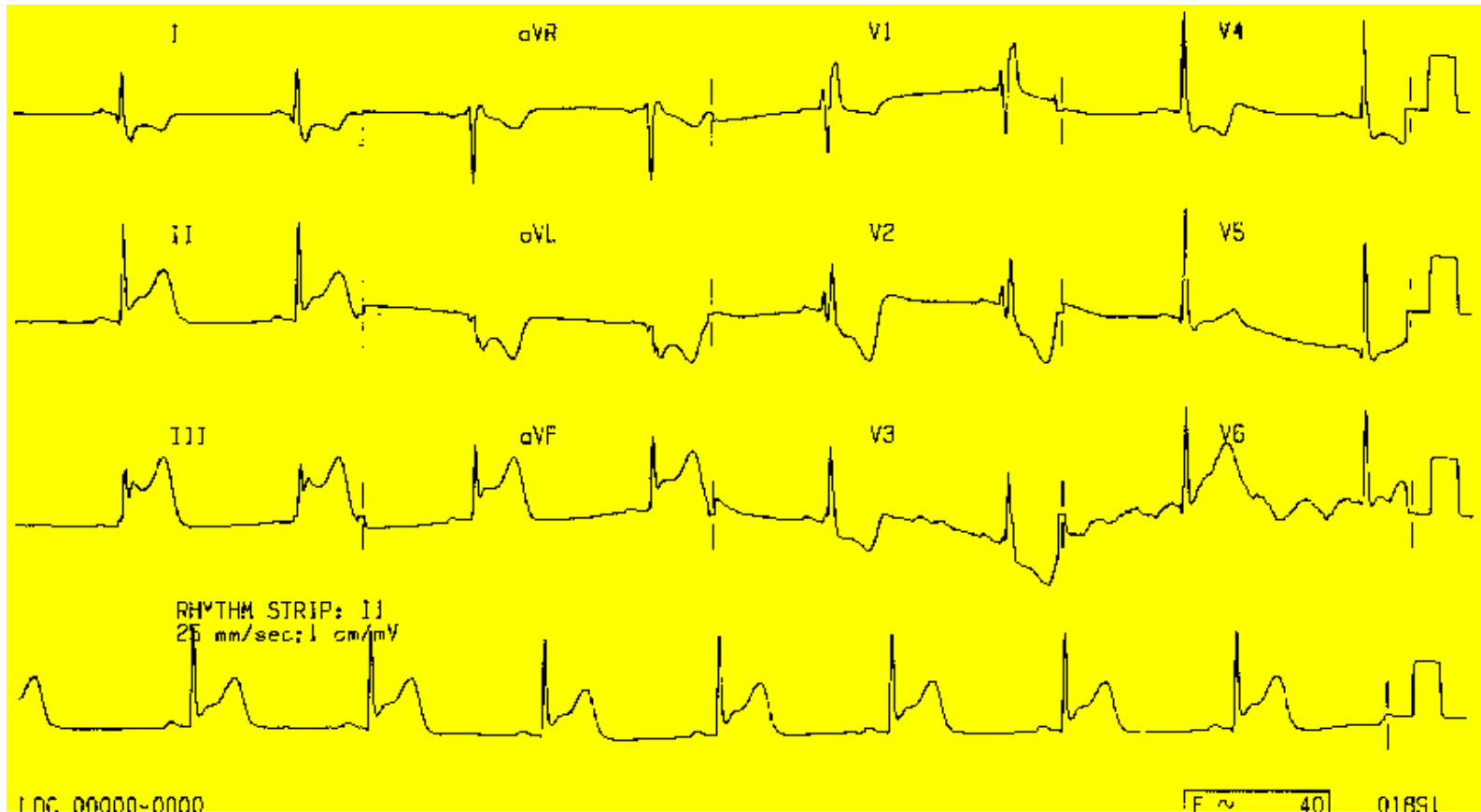


INFARKTÜS - QRST

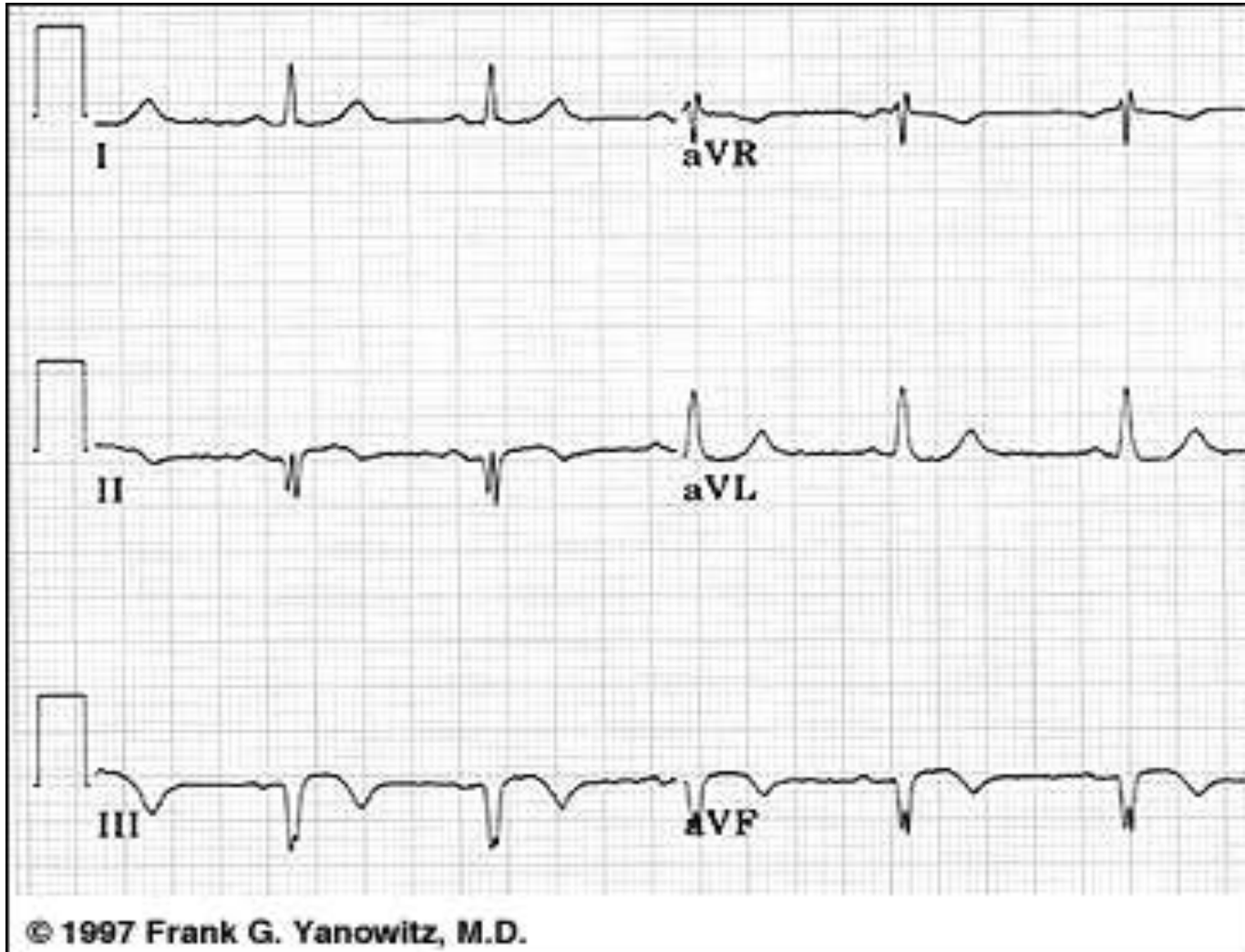


Evolution of Acute MI

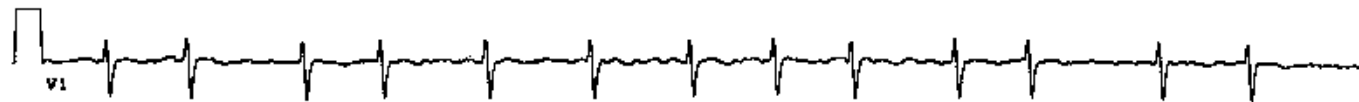



Akut inferior MI



Subakut(iyileşmekte olan) İnferior MI

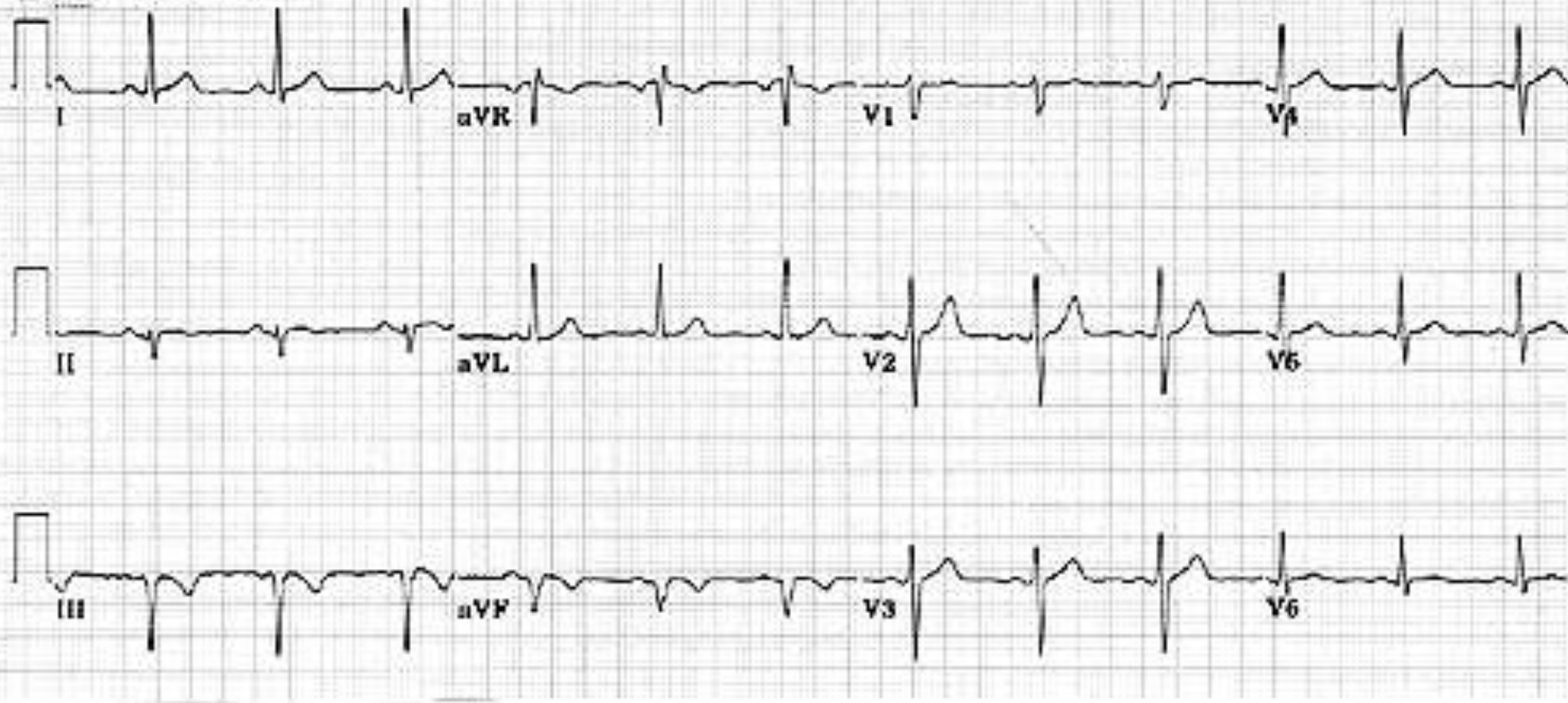


Eski İnferior MI



Eski Inferior MI

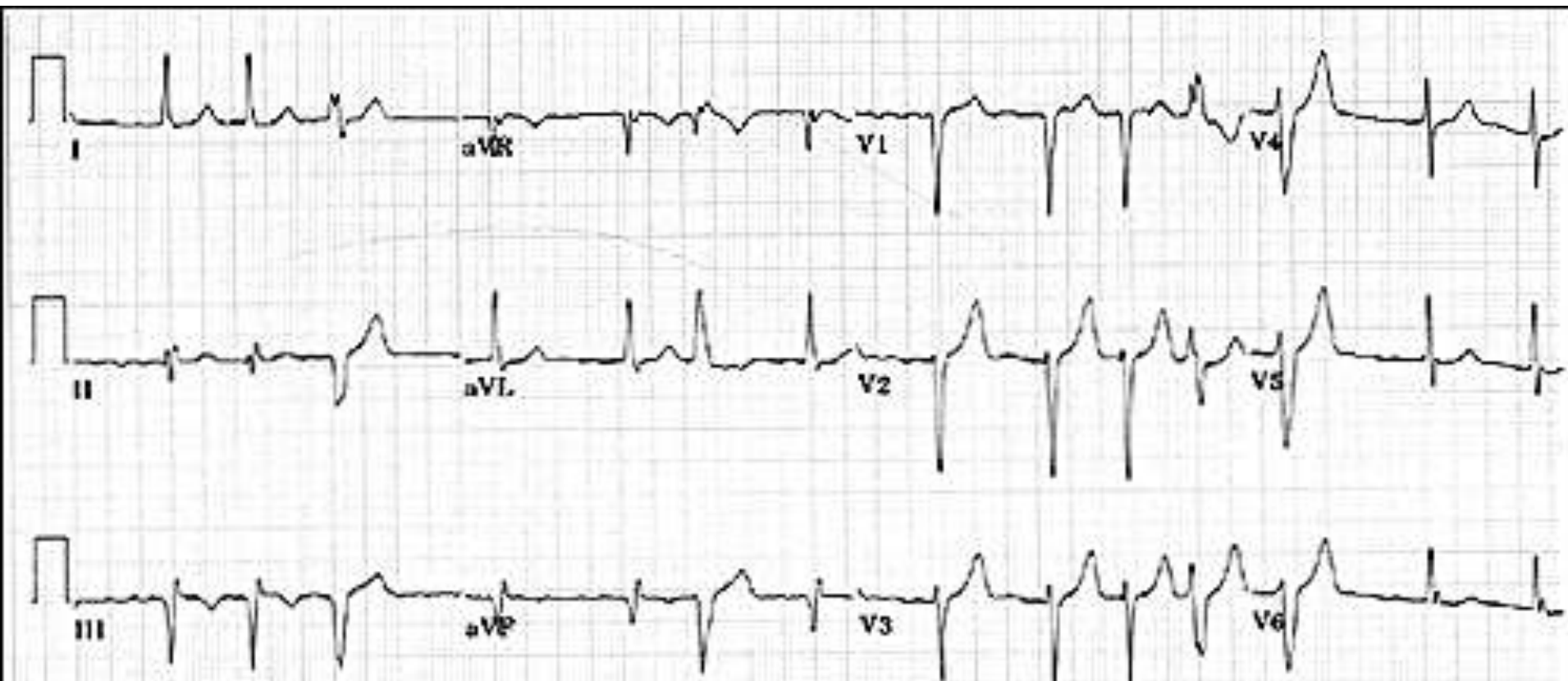
11-FEB-1942 (55 yr)
Male Caucasian



ID: 528527184 10-FEB-1997 07:55

© 1997 Frank G. Yanowitz, M.D.

Eski Inferior MI+AF



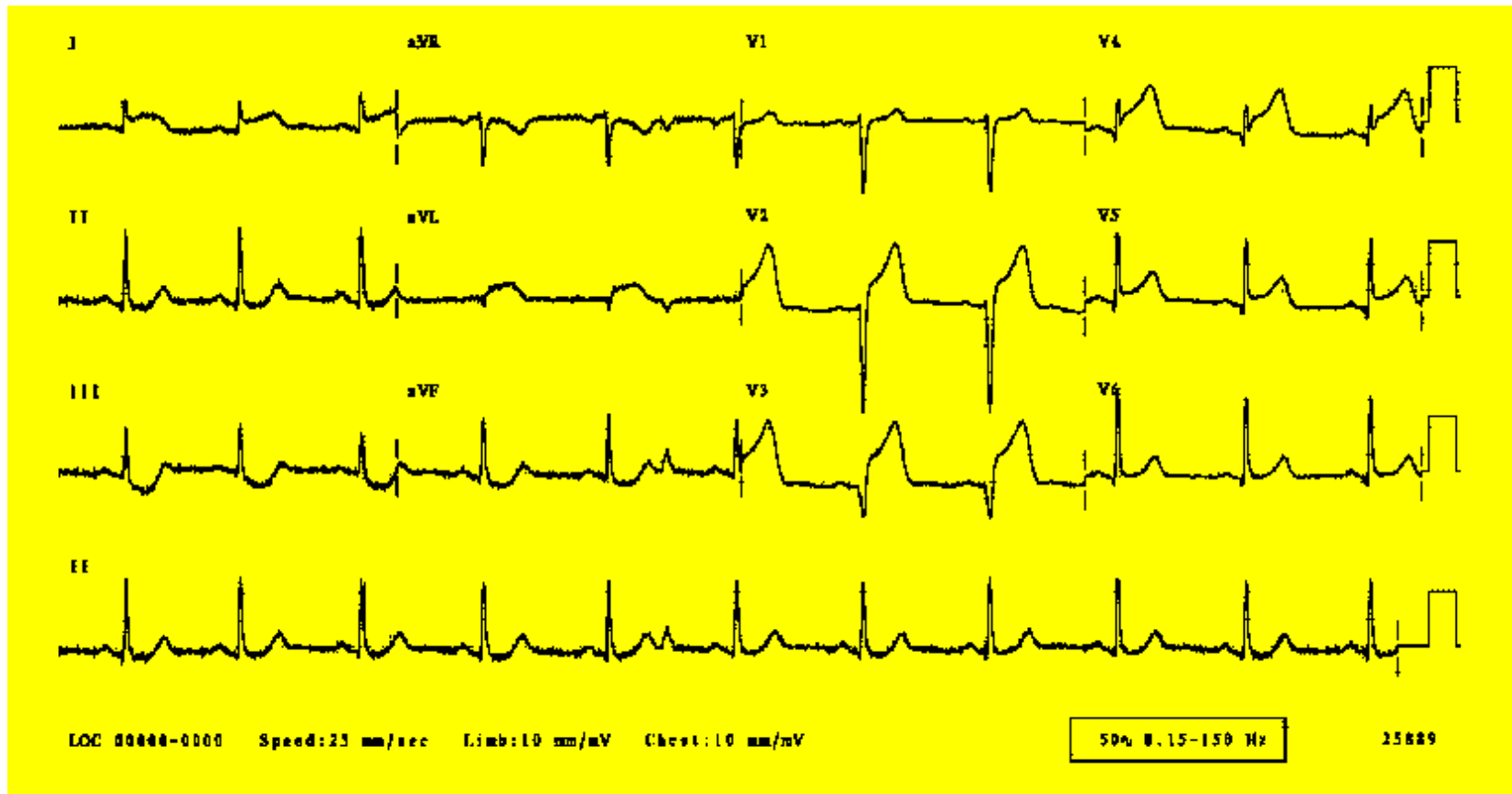
13-JUN-1927 (69 yr)
Male Caucasian

ID: 009147823

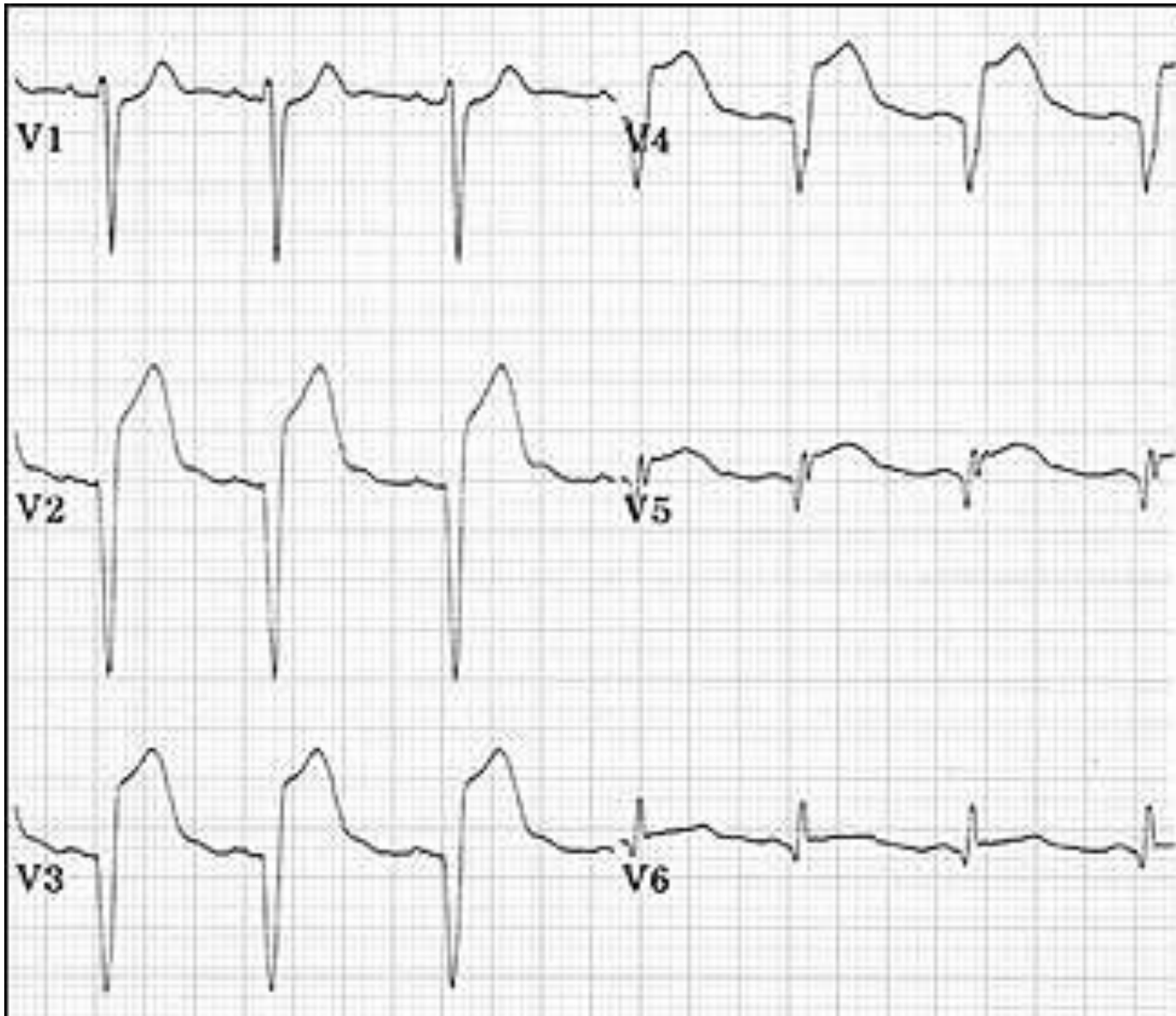
03-APR-1997 07:42

© 1997 Frank G. Yanowitz, M.D.

Akut Yaygın Anterior MI







Acute Anterior MI



Acute Anterior MI

11-OCT-1941 (53 yr)
Male Caucasian



25mm/s 10mm/mV 150Hz

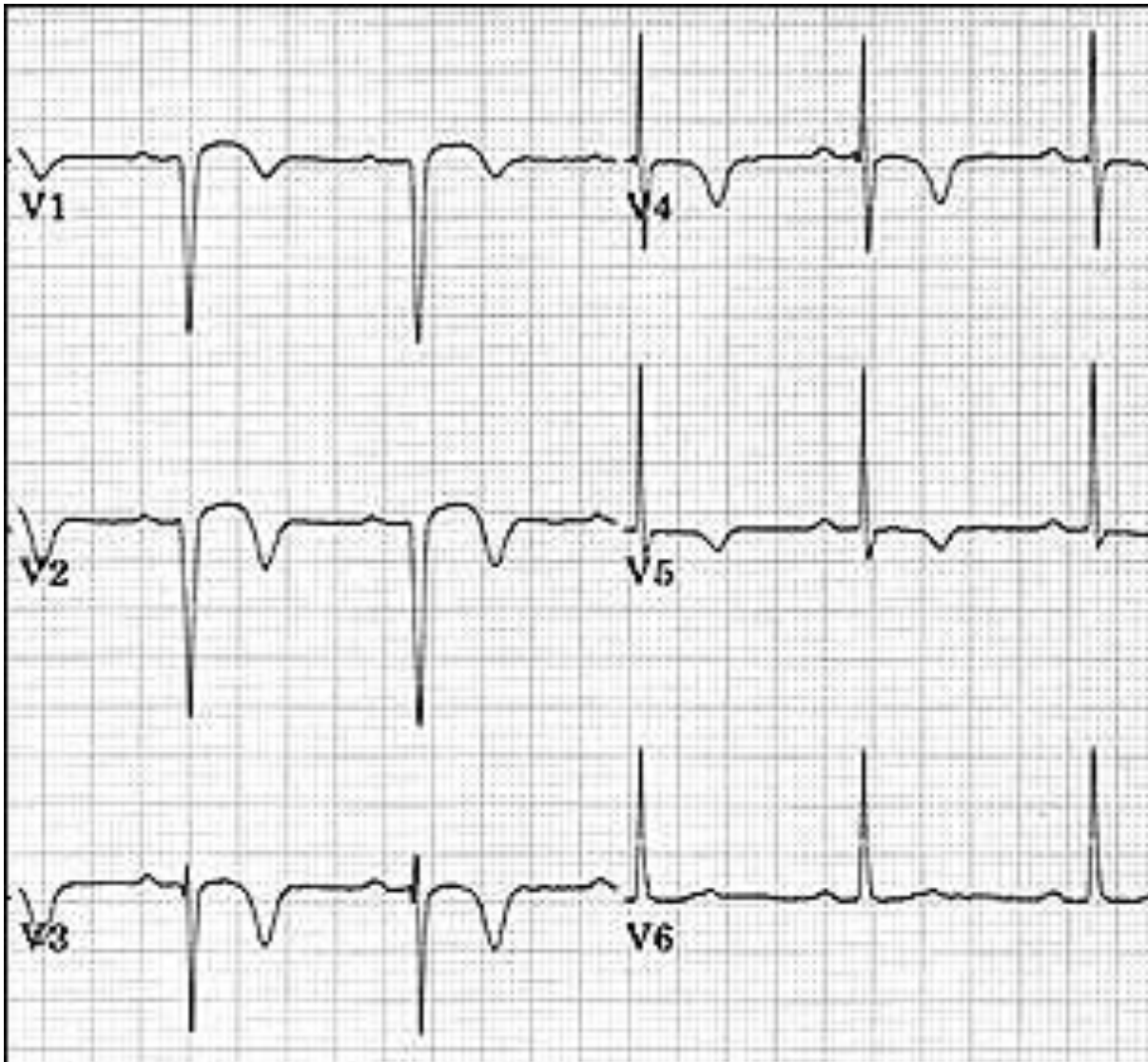
ID: 568407944

18-NOV-1994 16:01

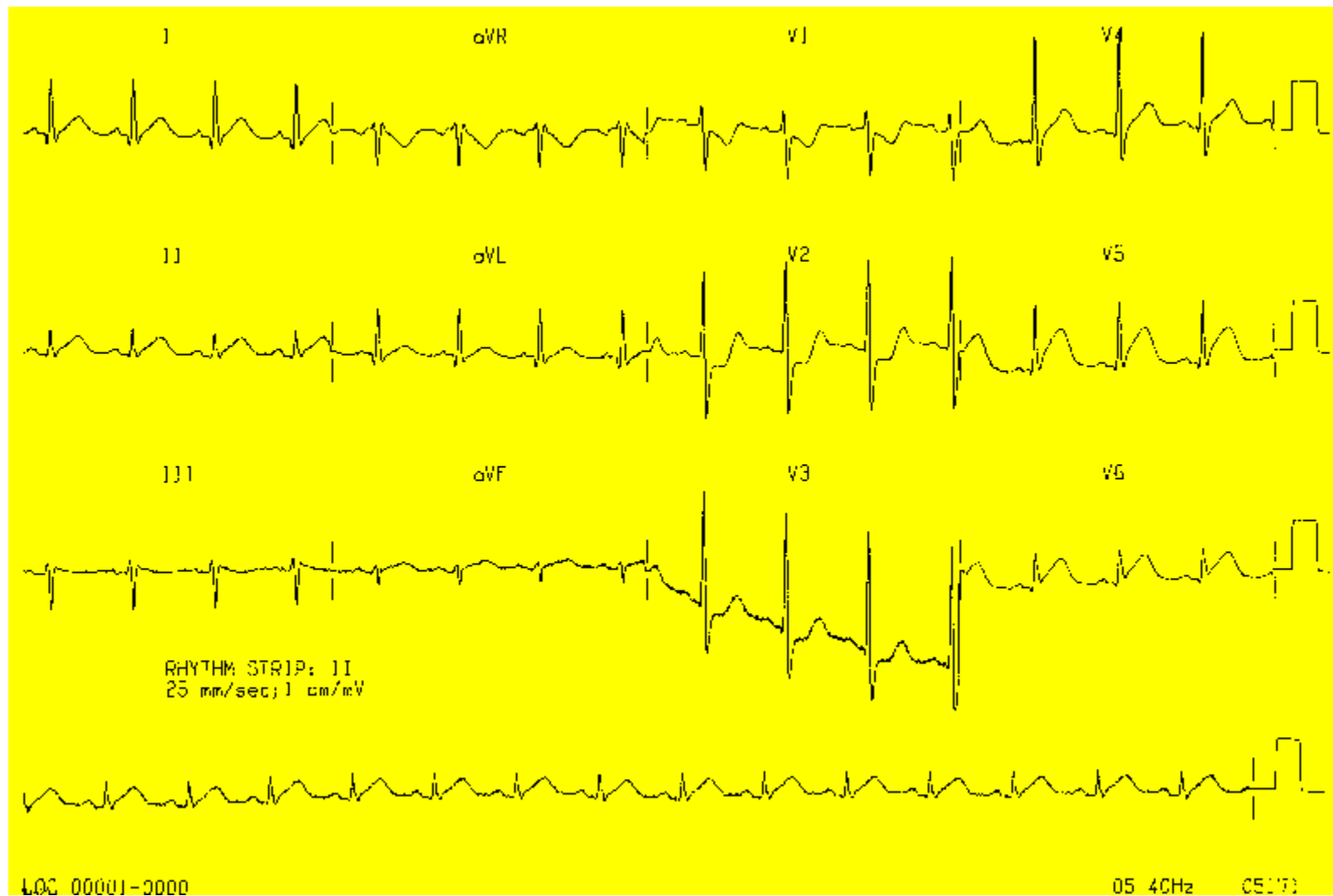
EID: Unconfirmed EDT: ORDER:

© 1997 Frank G. Yanowitz, M.D.

Subakut(iyileşmekte olan) Anterioseptal MI

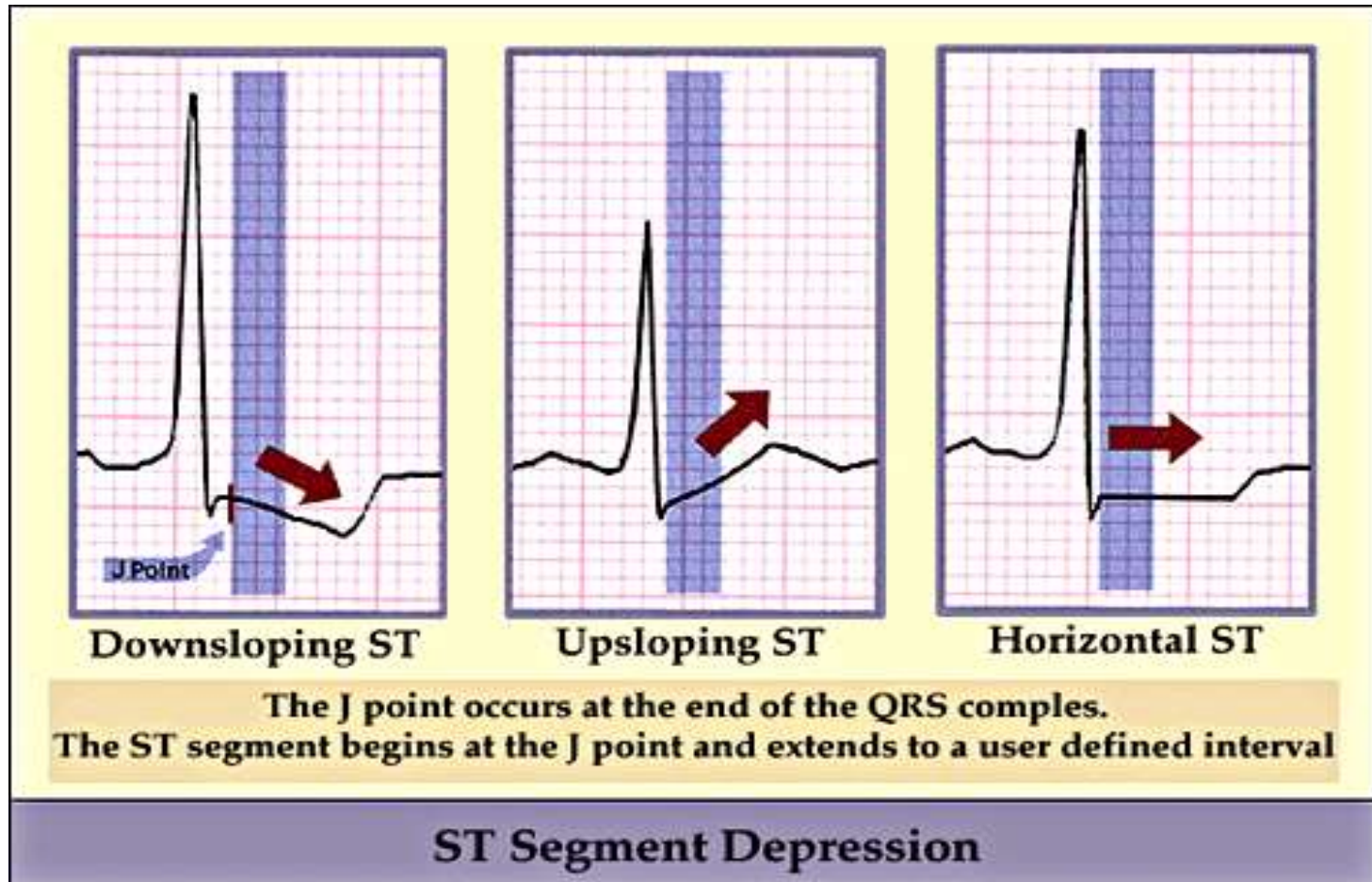


Akut Posterior MI



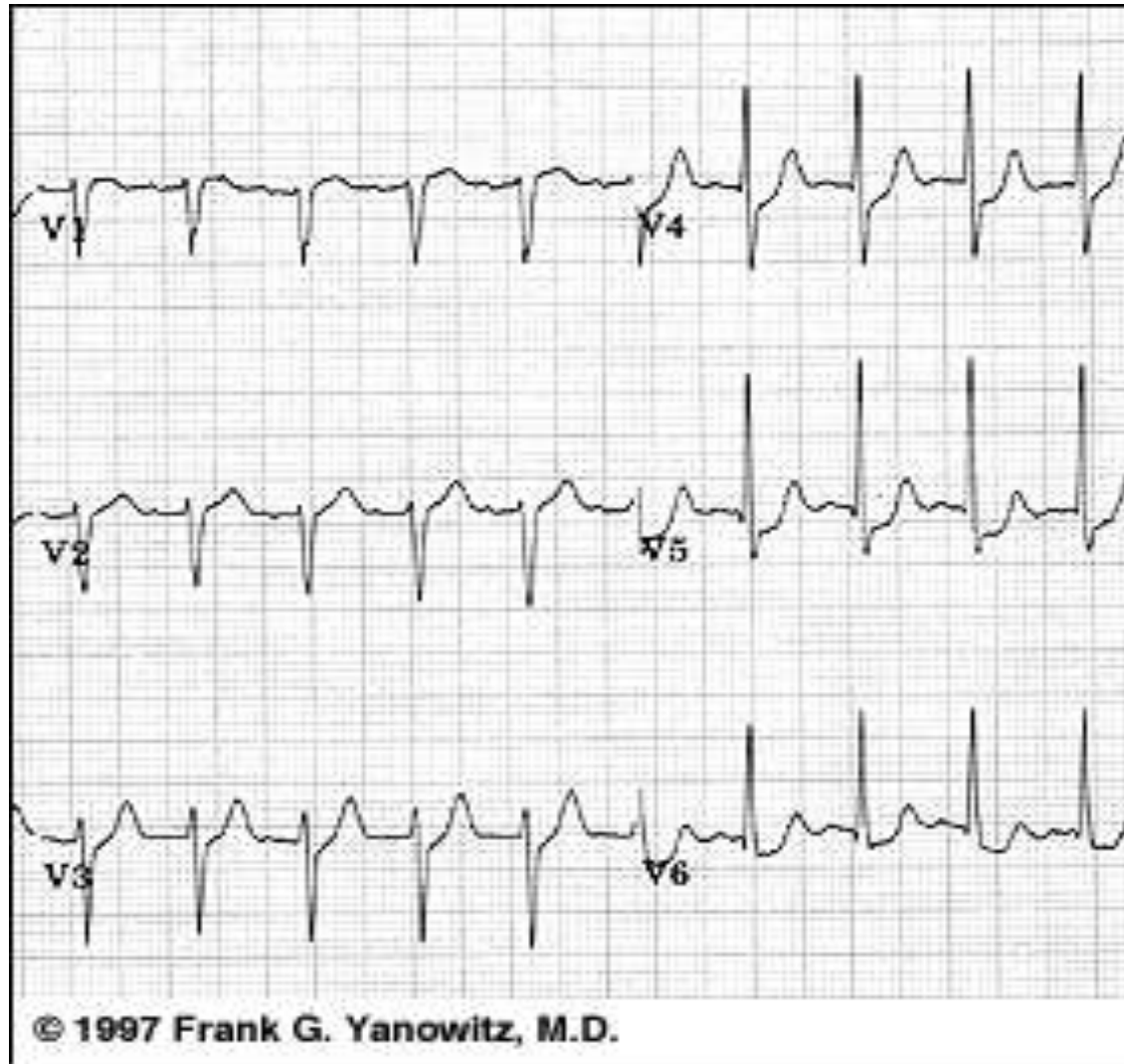
ST Segment Depresyonu

Ischemic heart disease

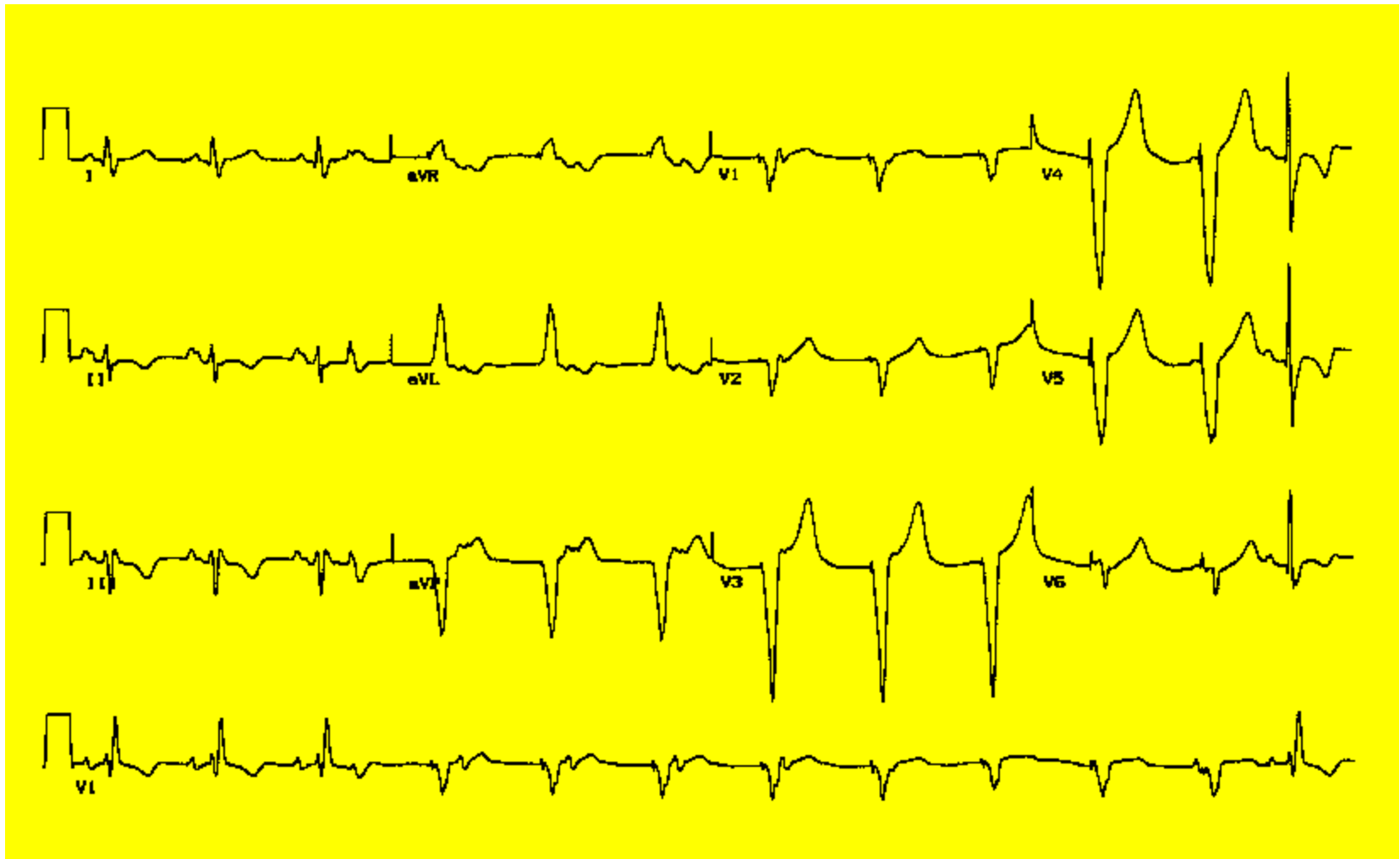

ST Segment Depresyonu

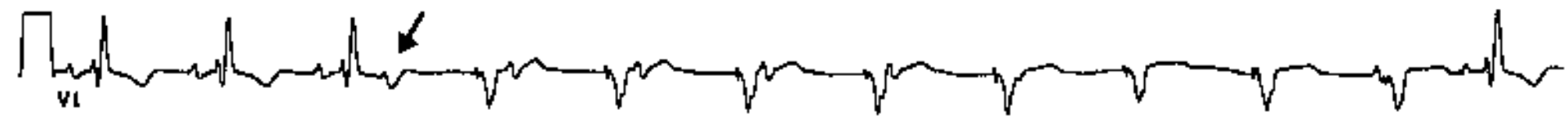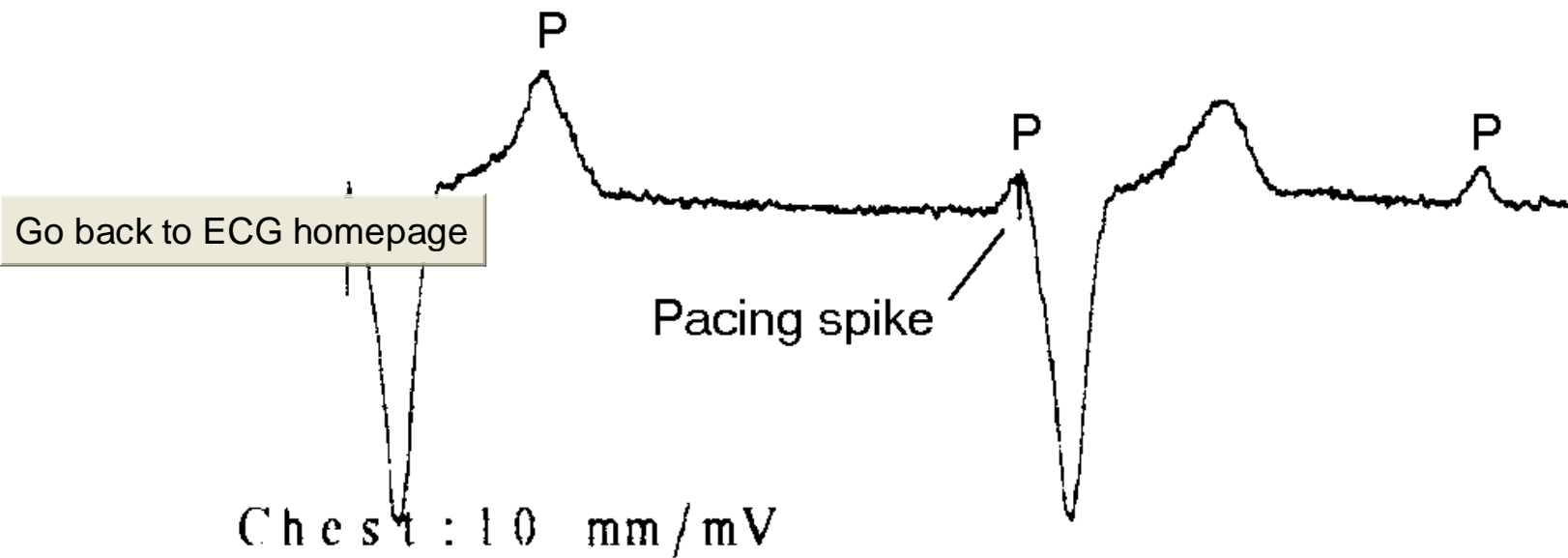
Akut koroner sendrom-NonSTEMI(Akut NonQMI)



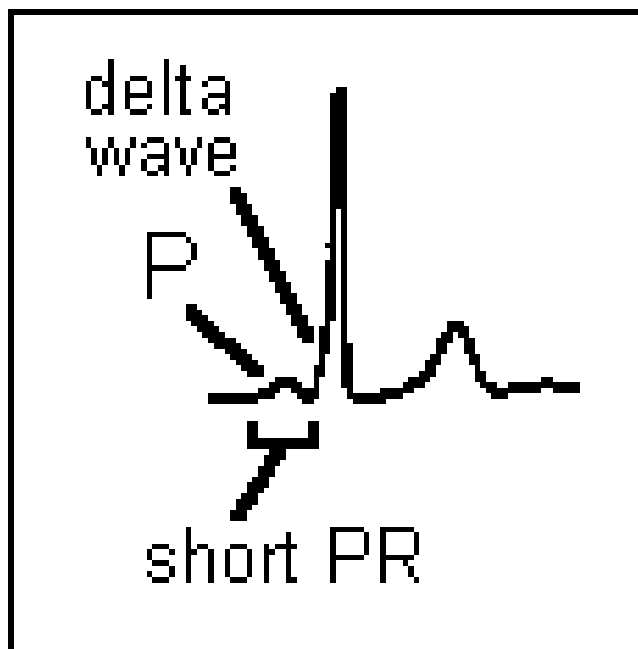
Ventriküler Pacemaker



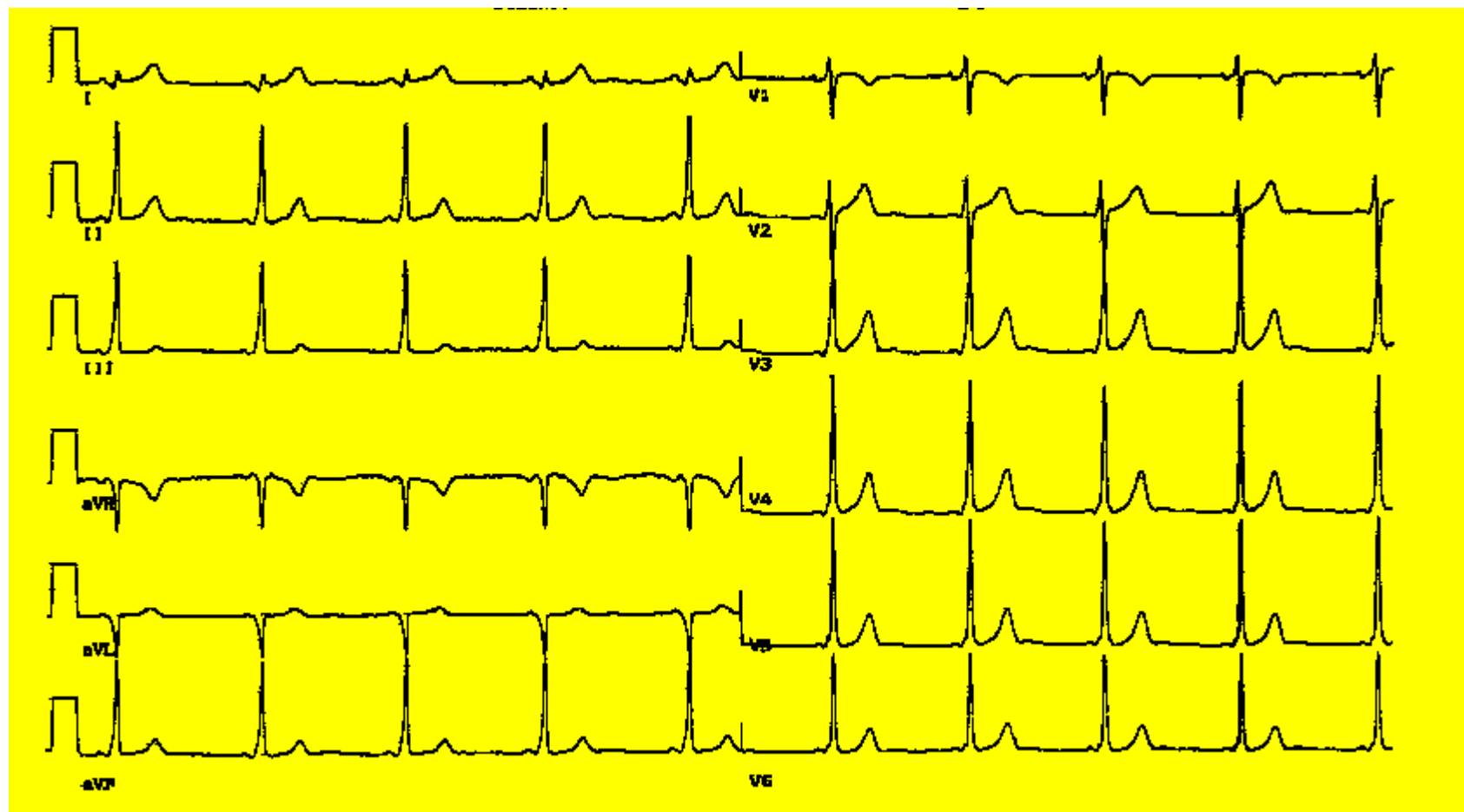
Pacemaker Spike



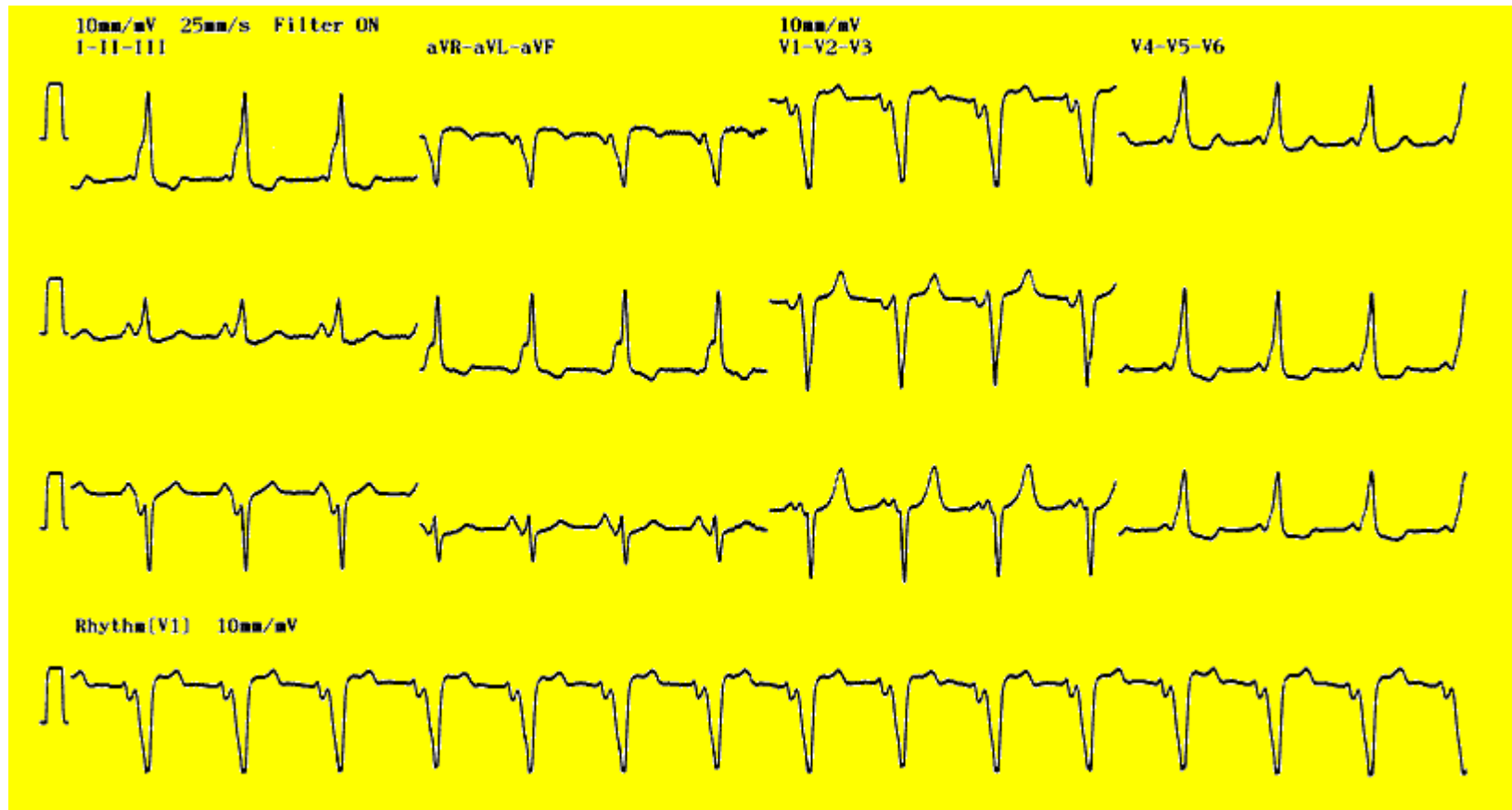
WPW



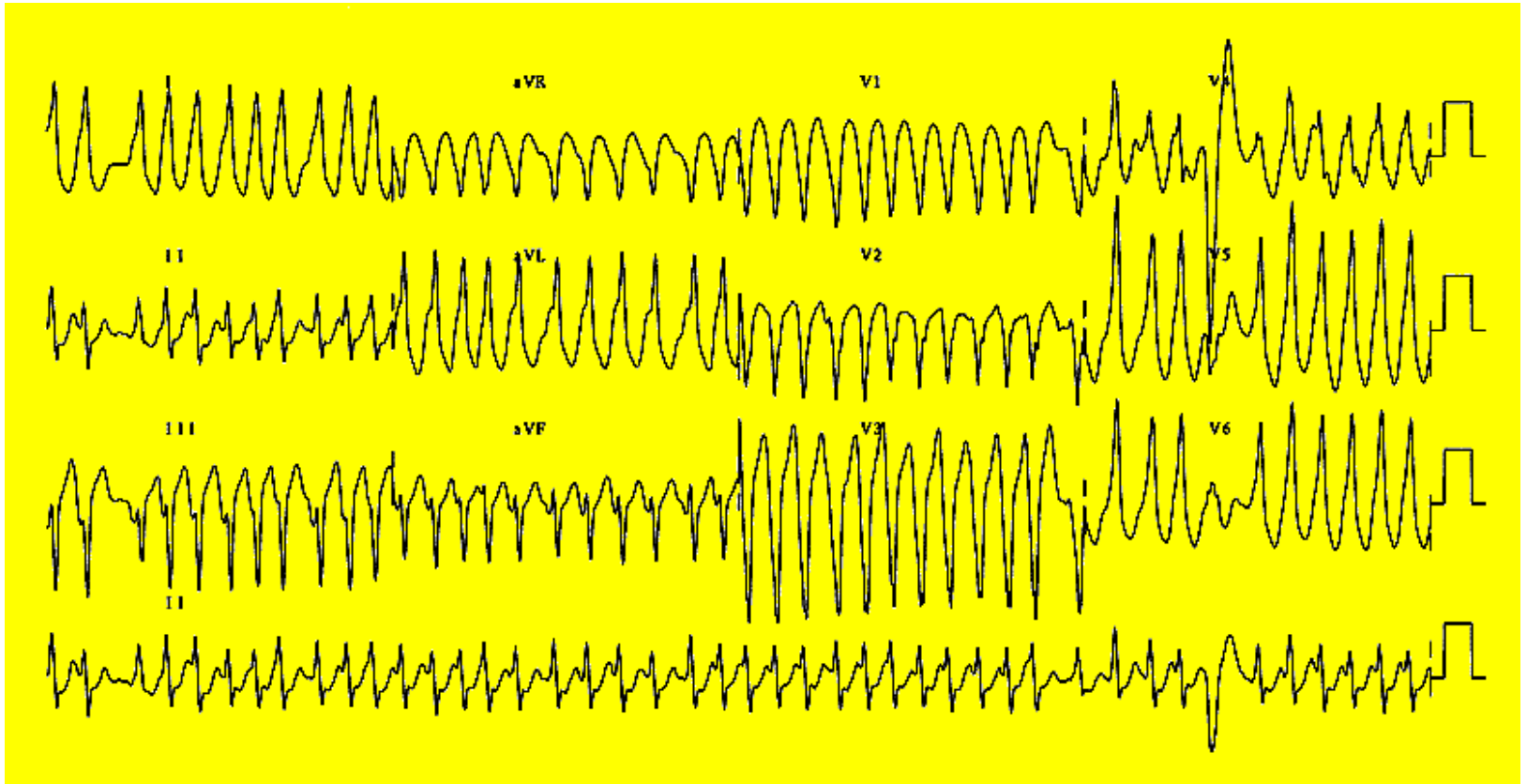
WPW



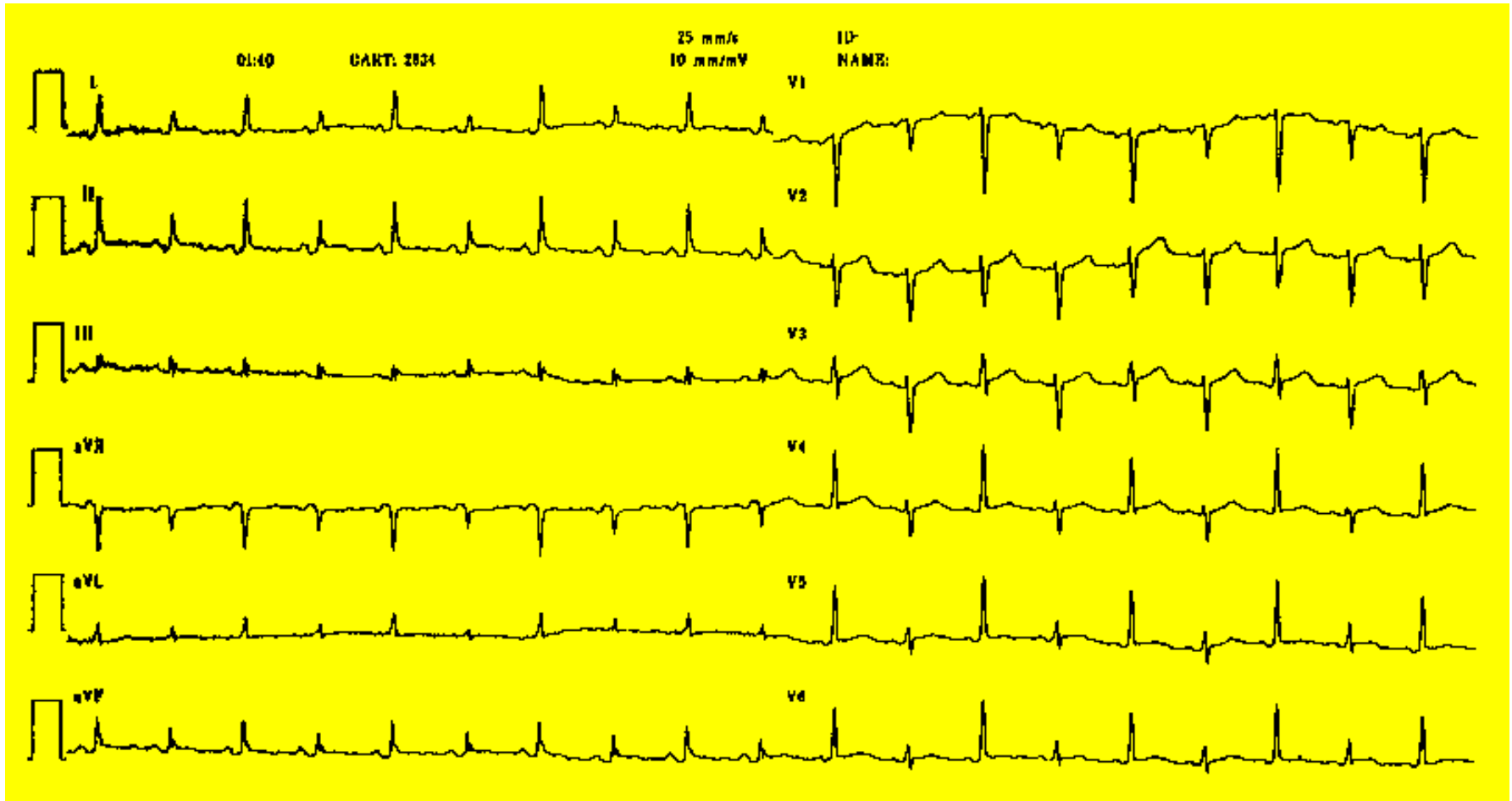
WPW



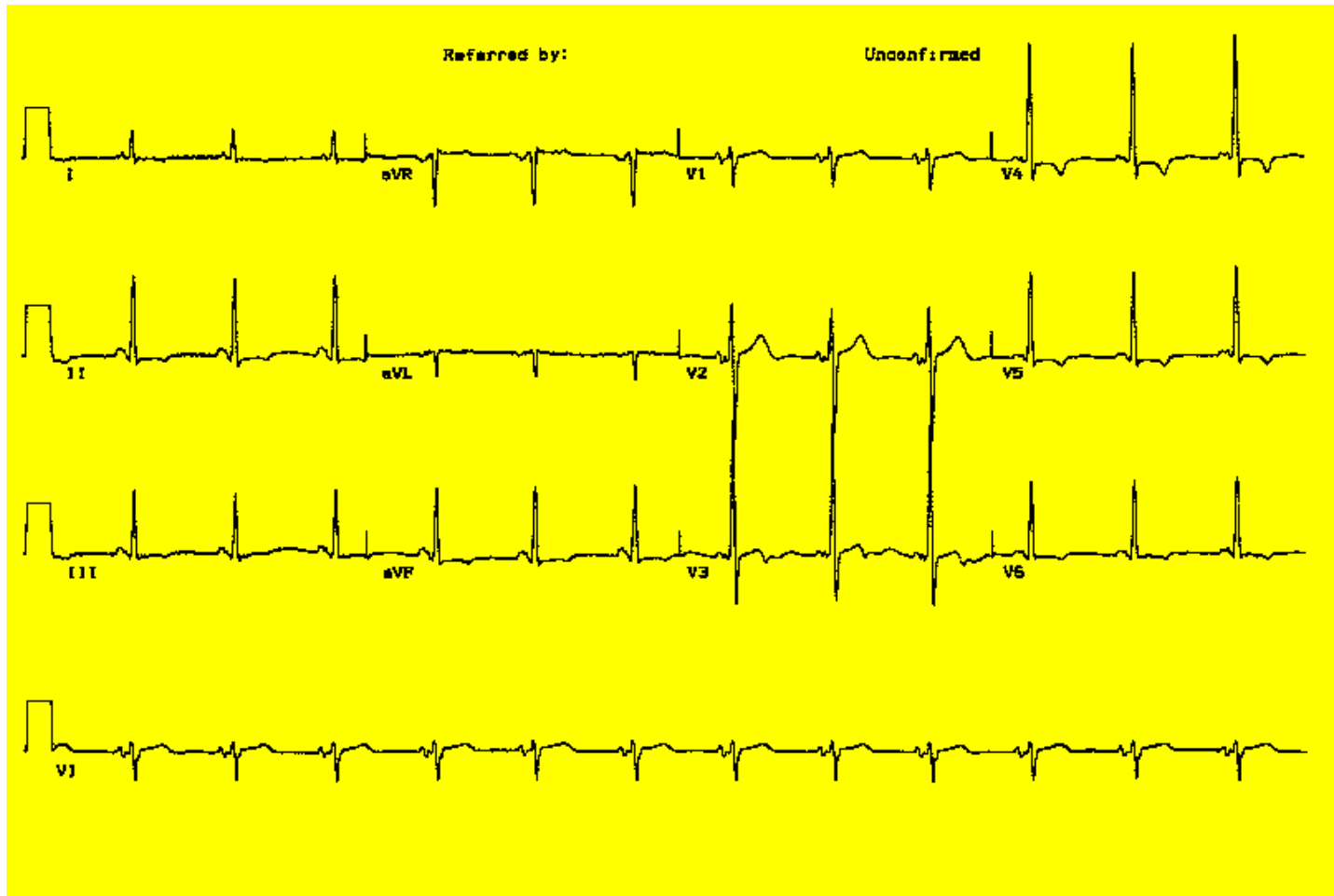
WPW+AF



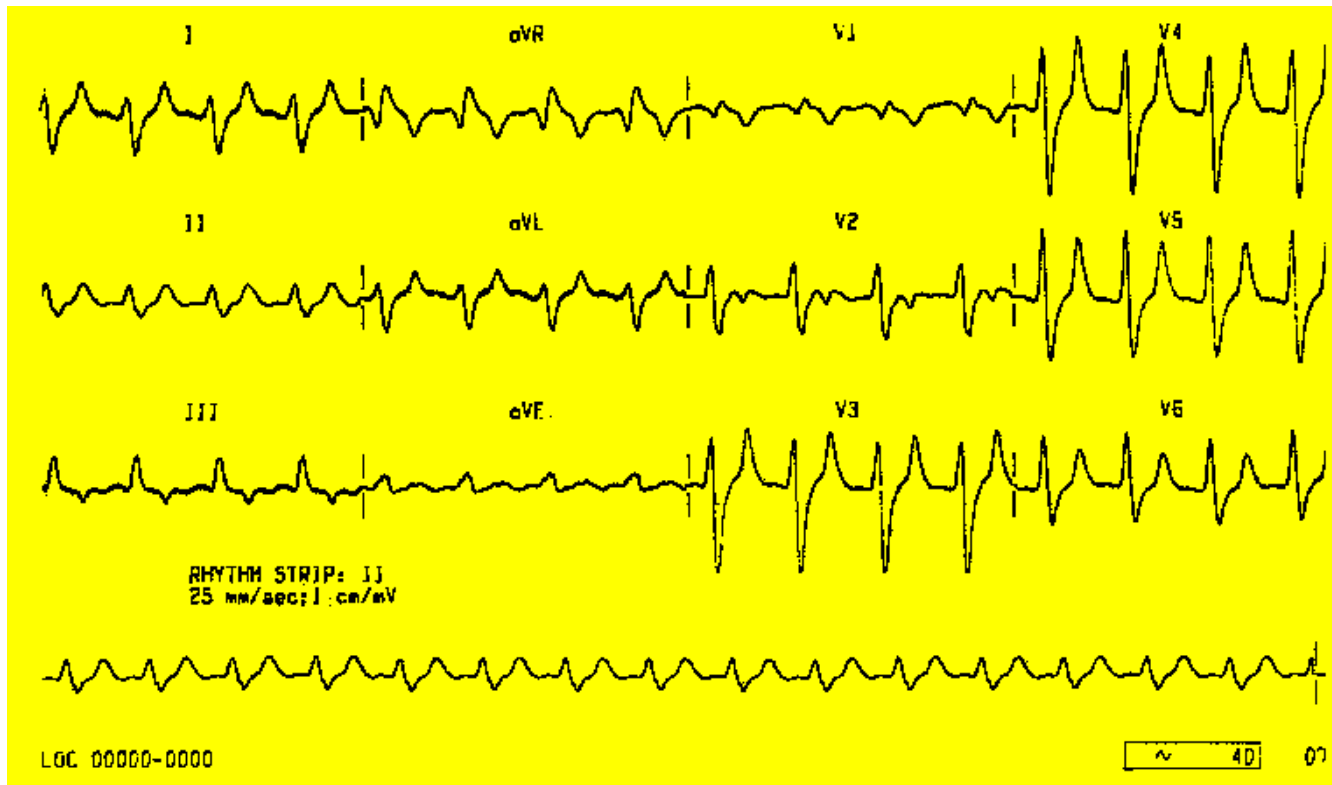
Perikardiyal Efüzyon Elektriksel Alternans



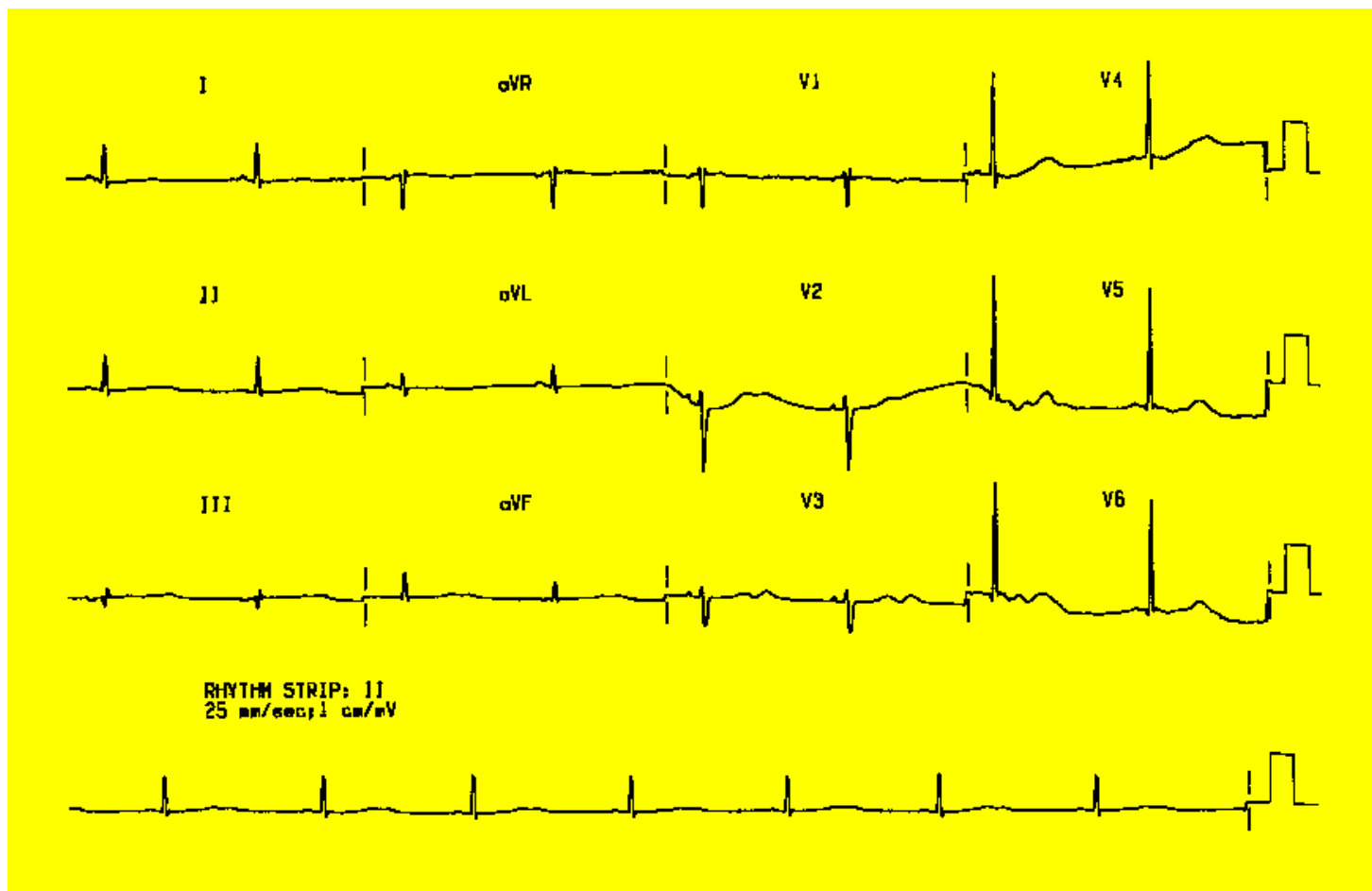
Lown Ganong Levine Syndrome



Hiperkalemi



Hipokalemi



Dijital Kullanan Hasta

