
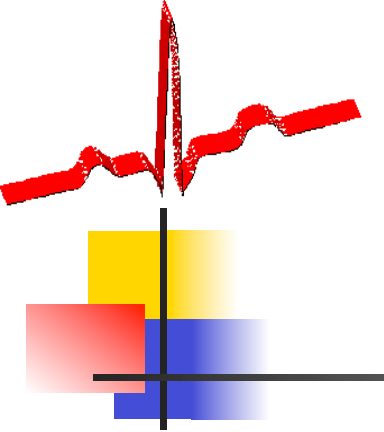


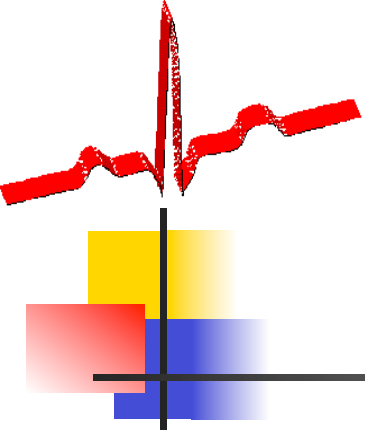
ELEKTROKARDİYOGRAFI



Prof.Dr. Deniz Kumbasar
Ankara Üniversitesi Tıp Fakültesi
Kardiyoloji Anabilim Dalı



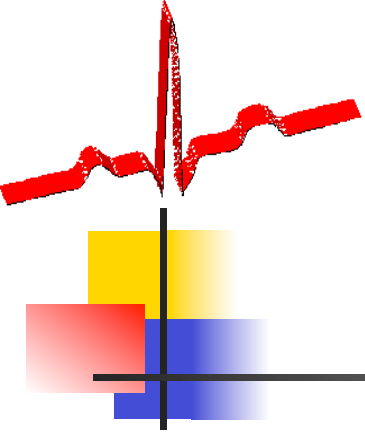
**Einthoven'in orijinal "electrocardiograph" cihazı
"Cambridge Scientific Instrument Company" Londra- 1911**



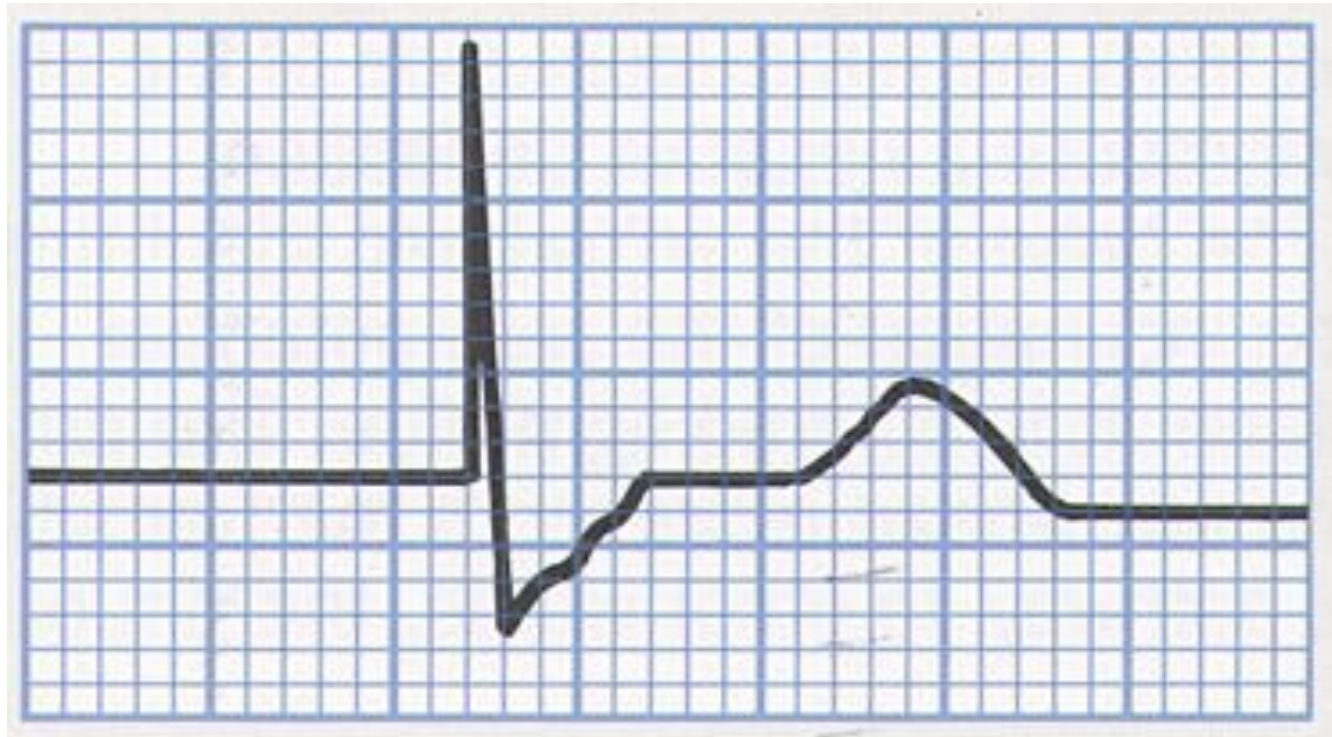13.02.18

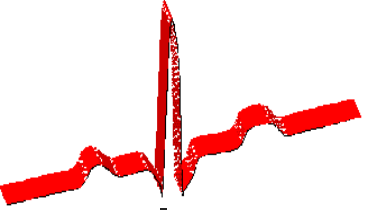
EKG

3

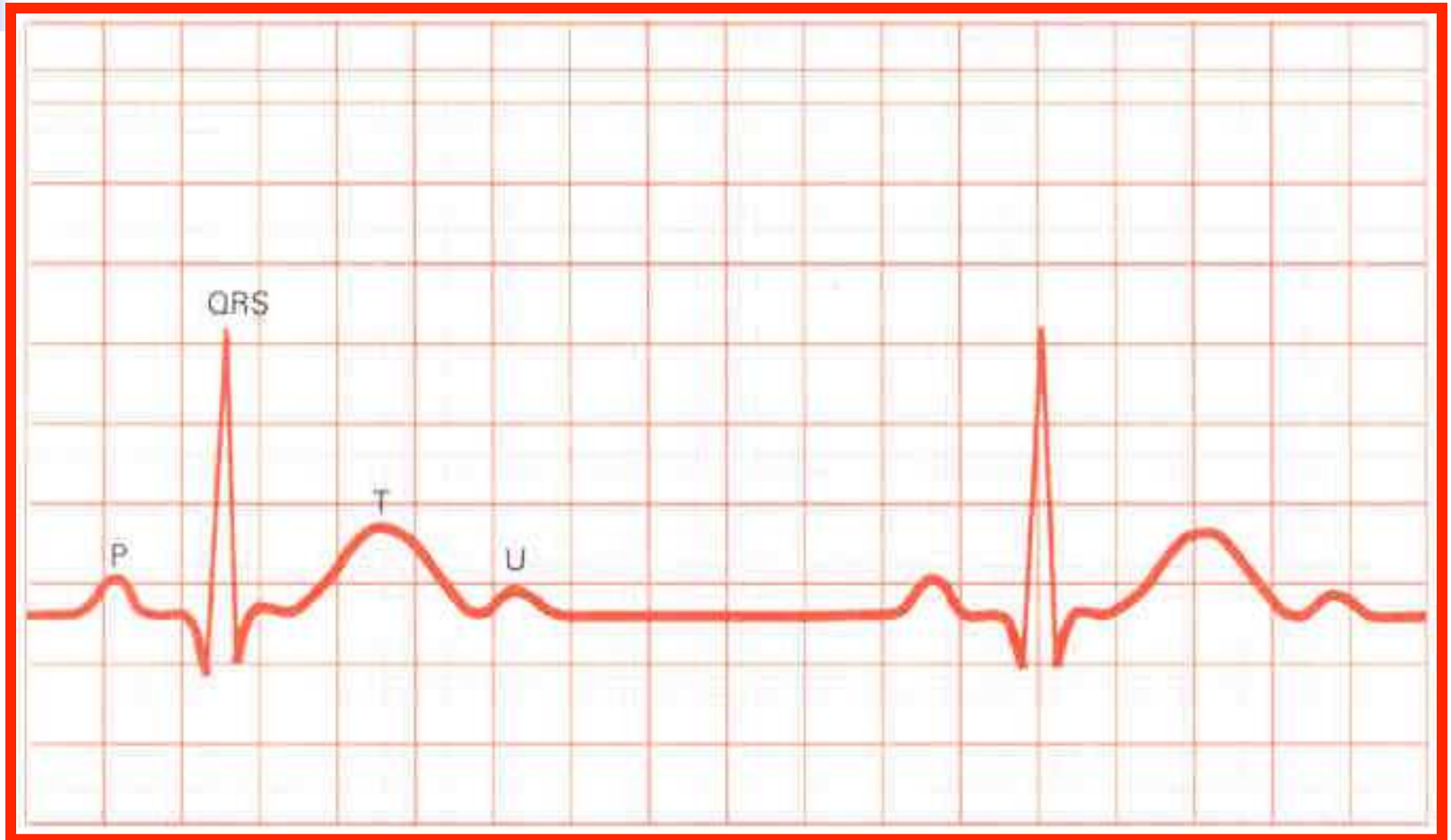


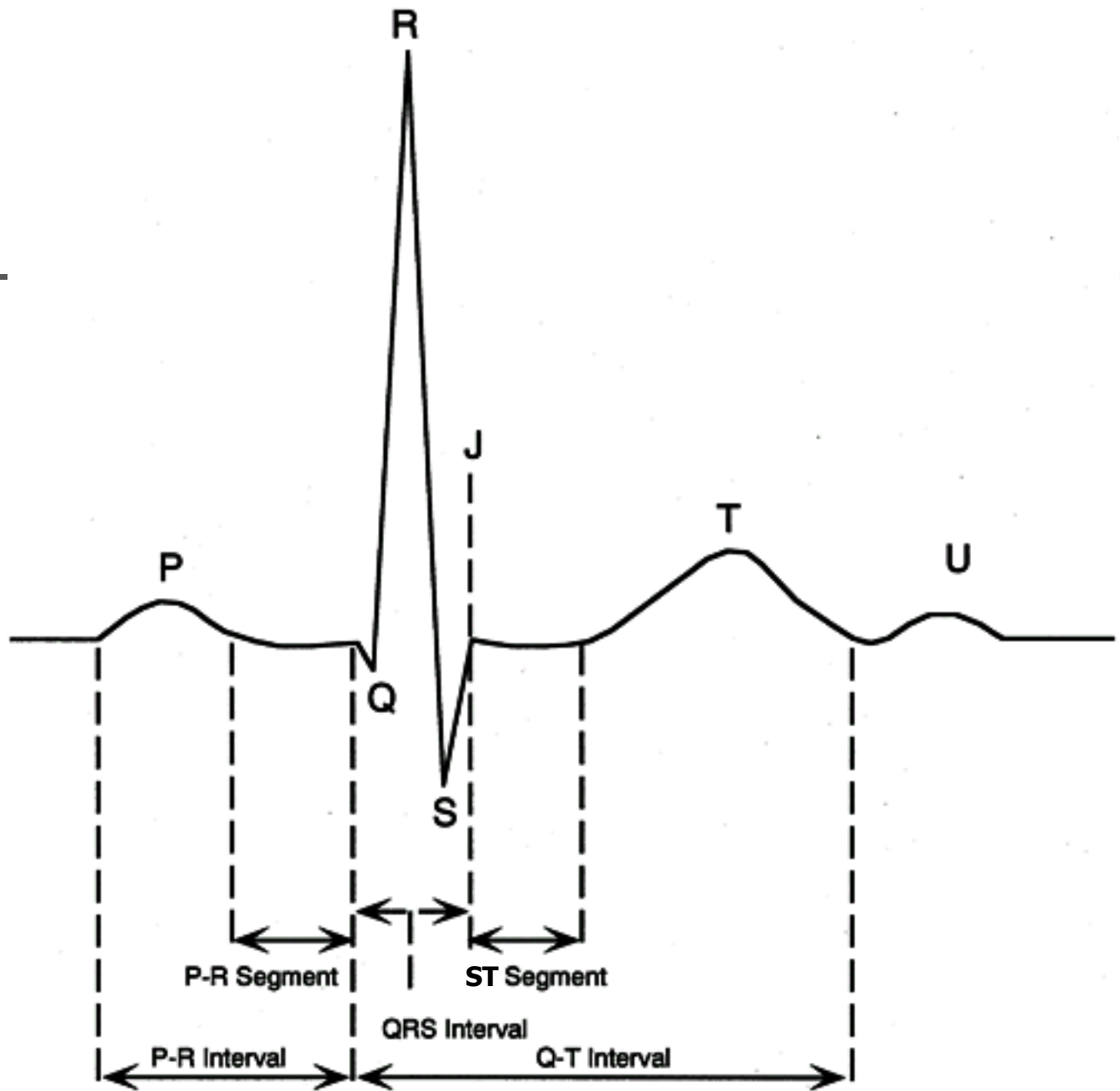
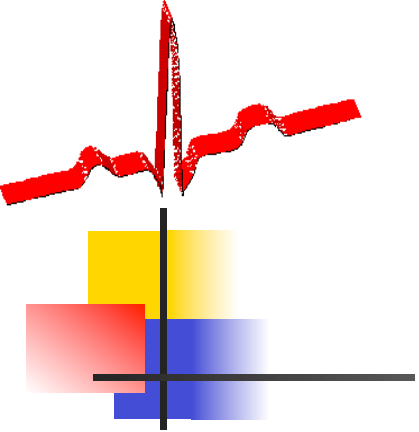
Elektrokardiyogram:

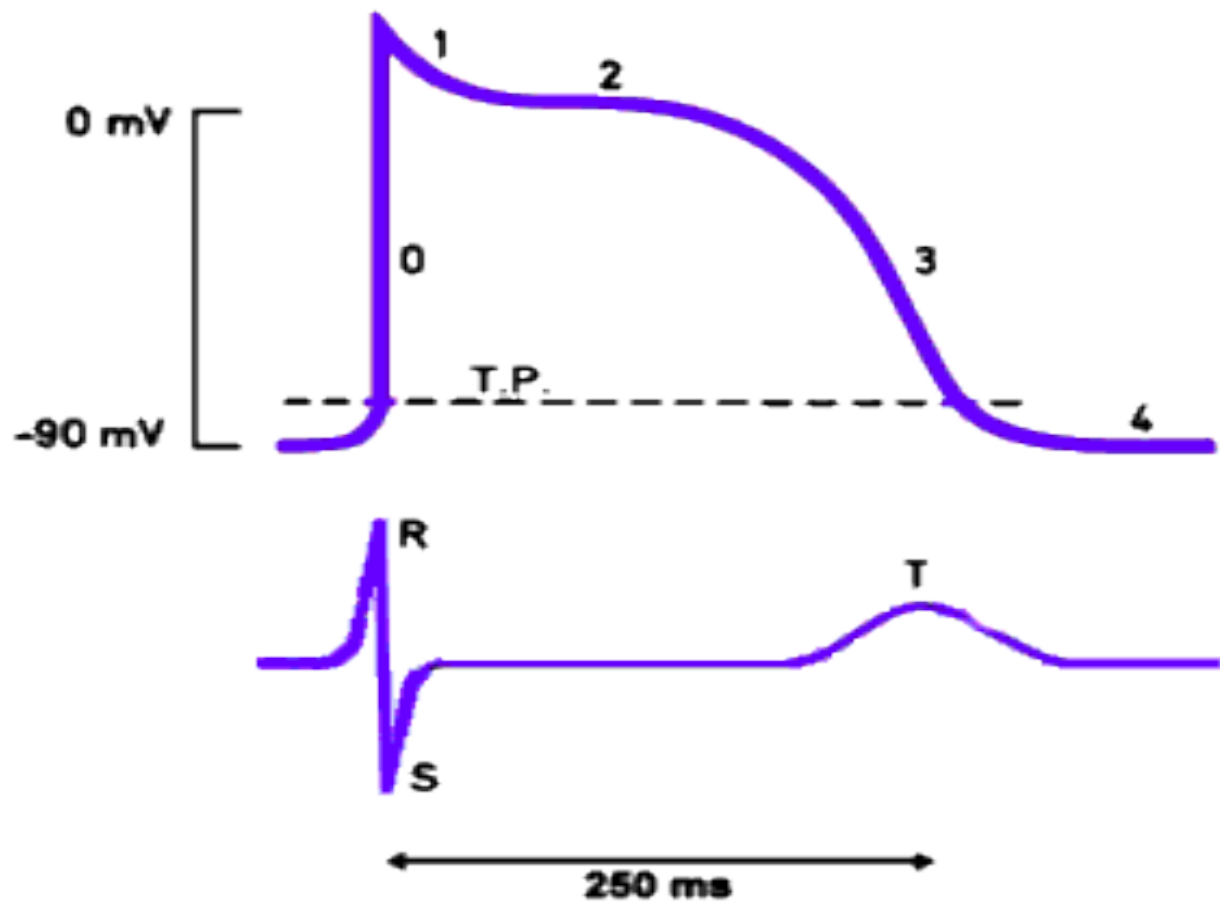
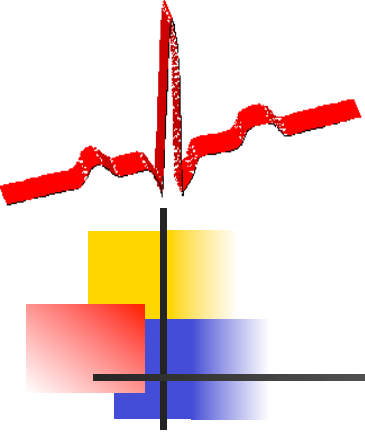


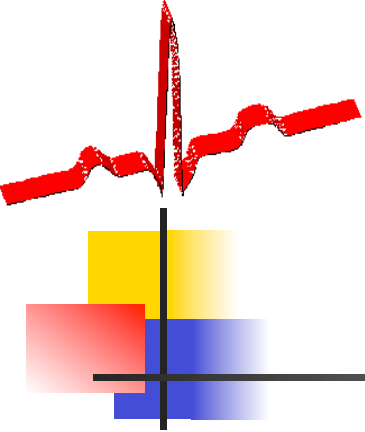


EKG terminolojisi:

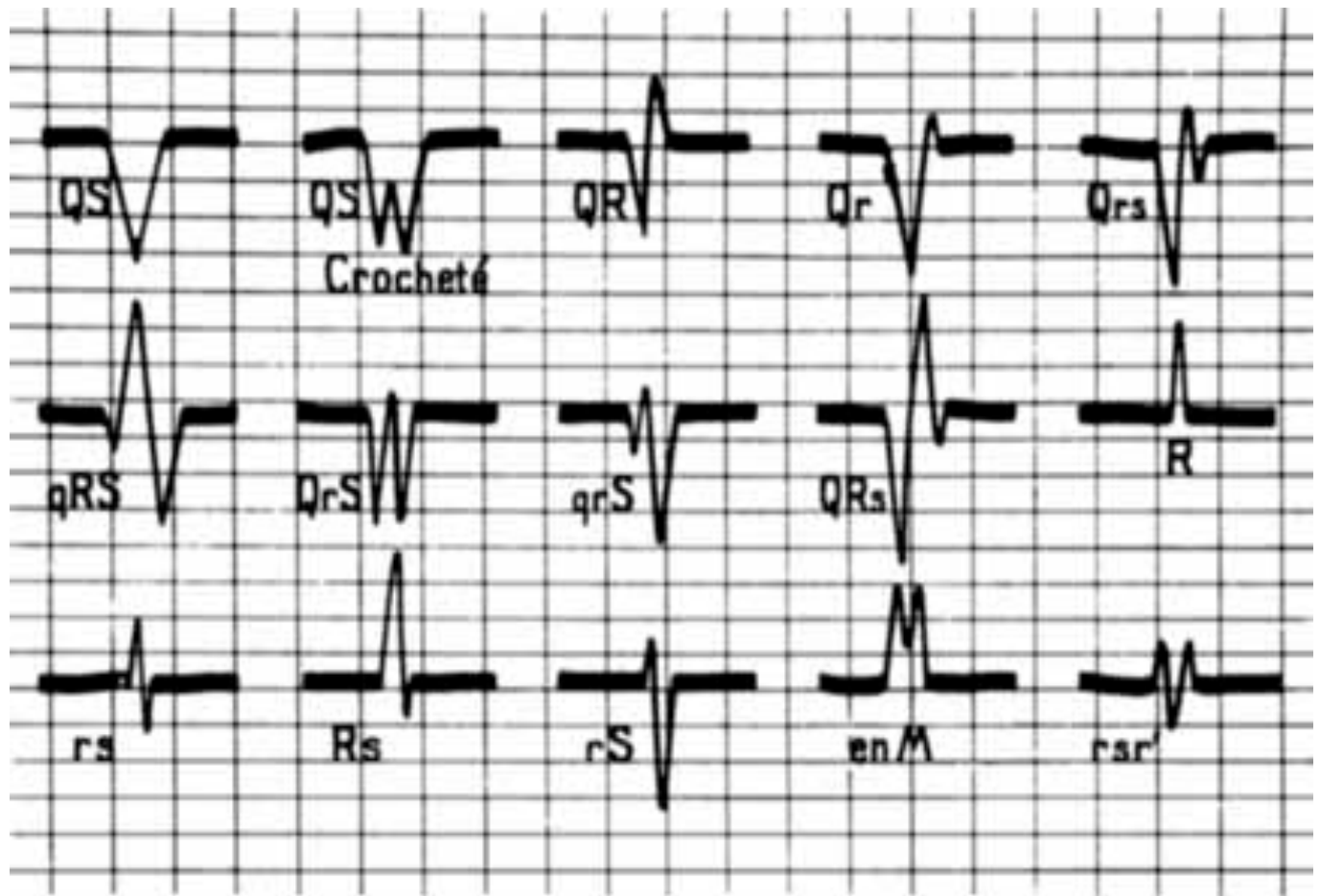


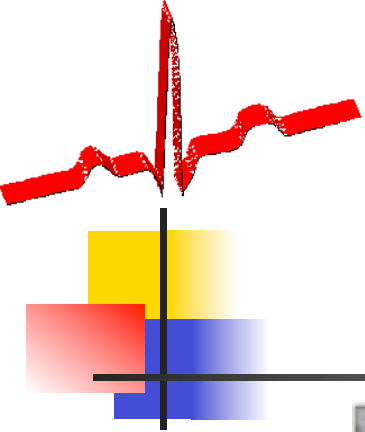




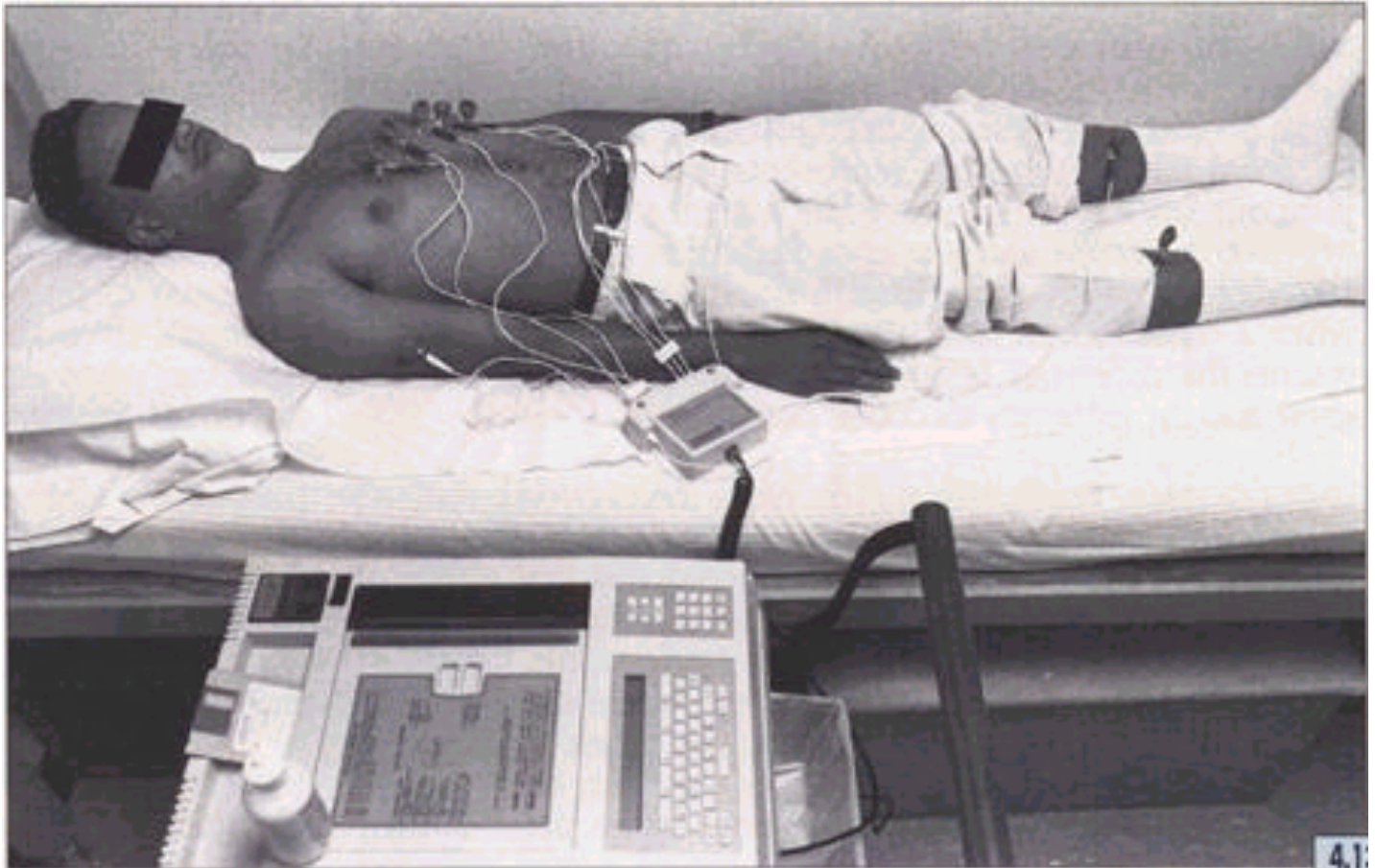


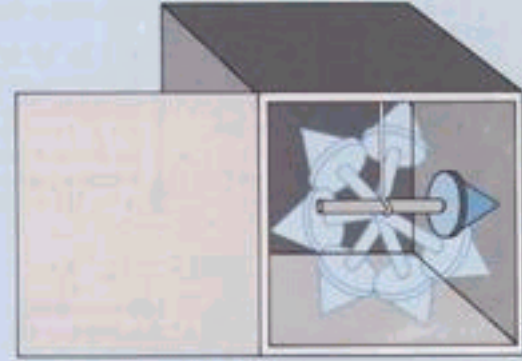
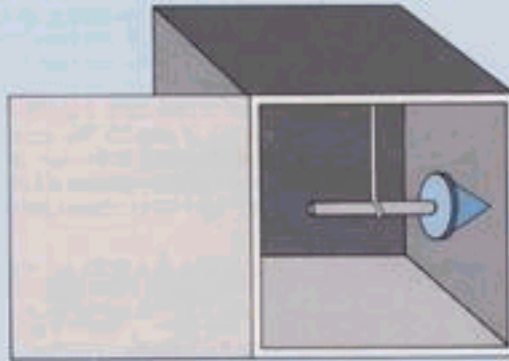

QRS kompleksi





Elektrokardiyograf:



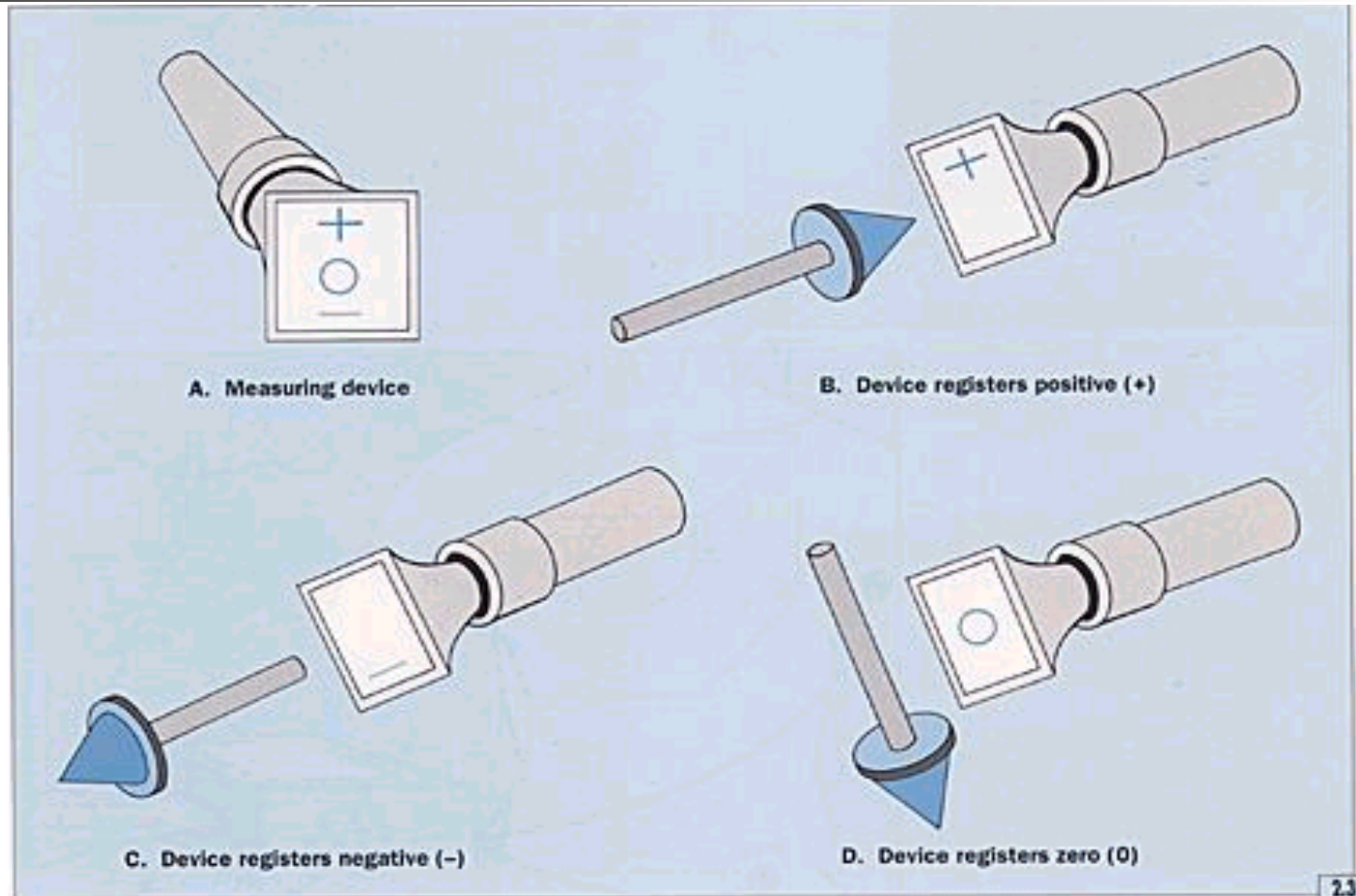
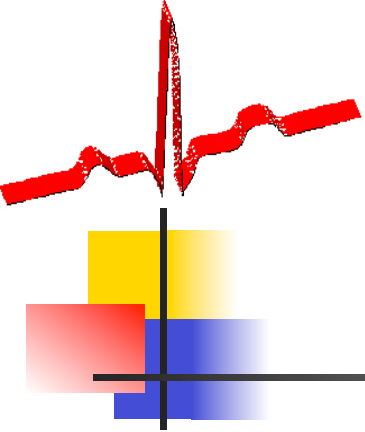


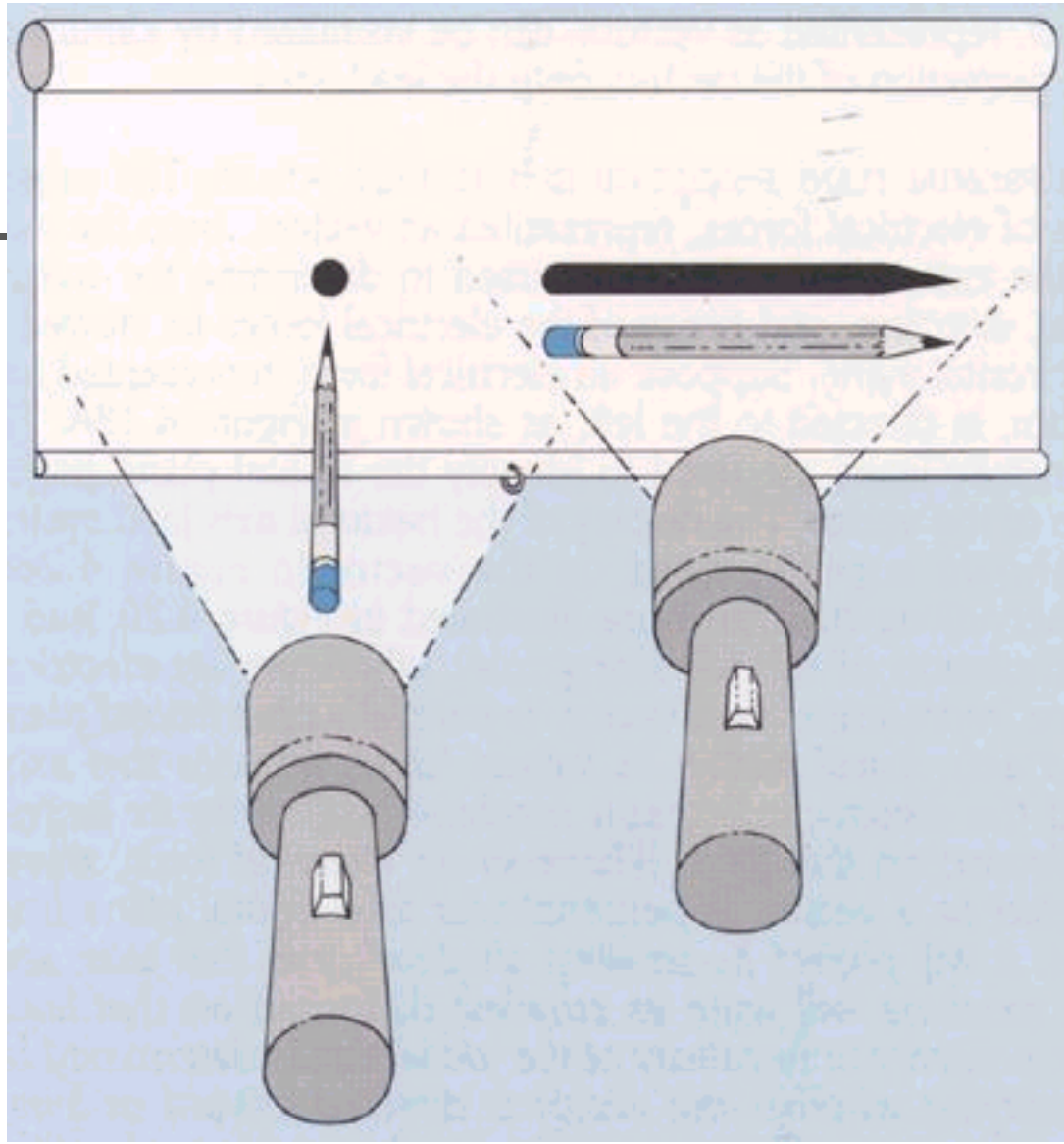
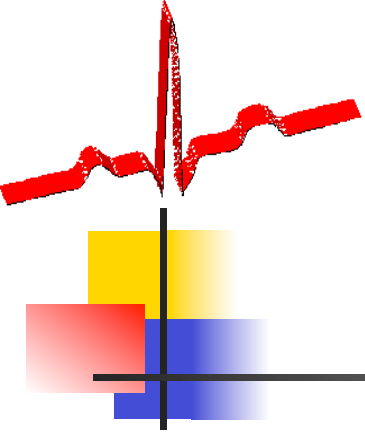
Direction deduced from distribution of (+), (-), and (0) marks

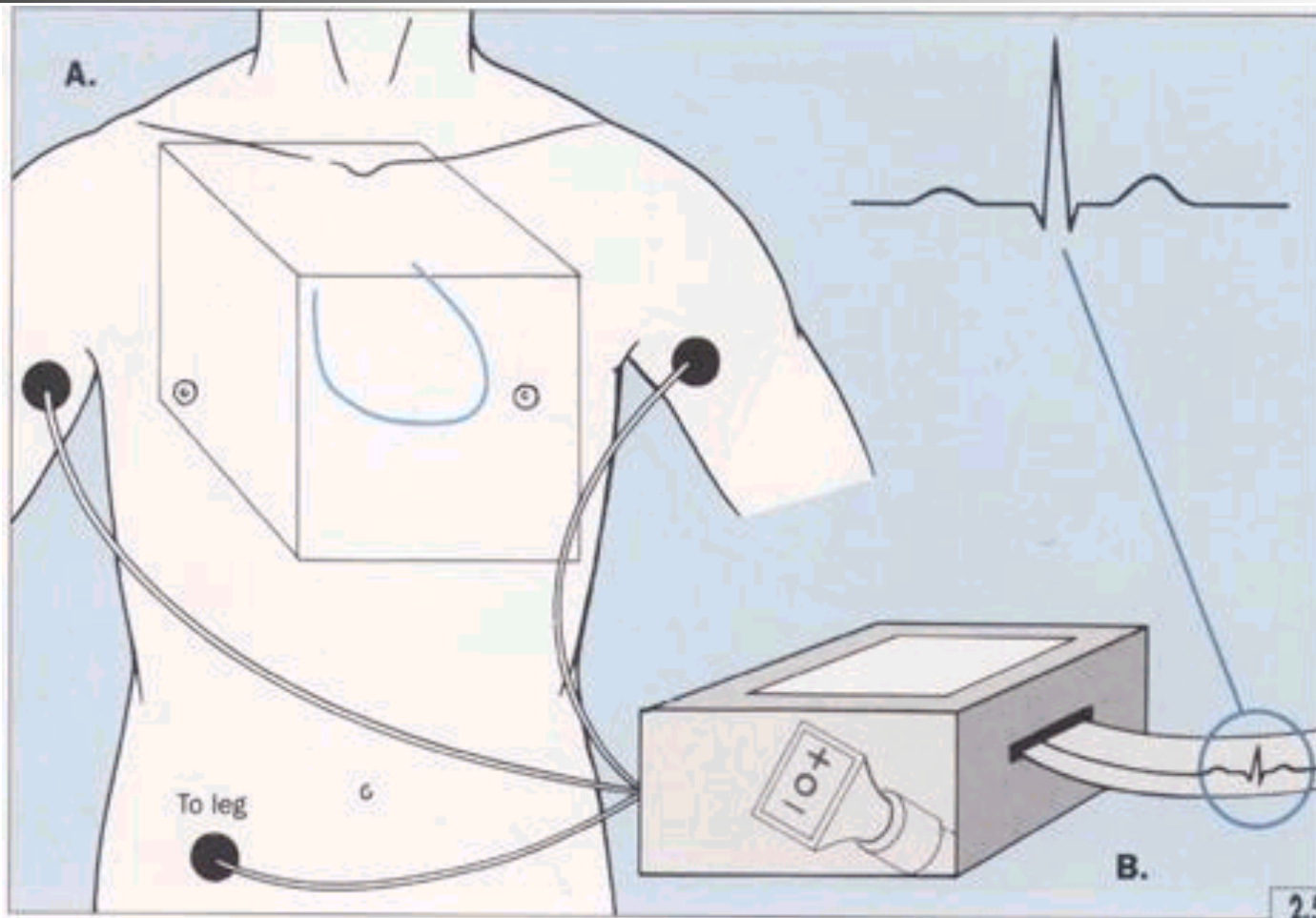
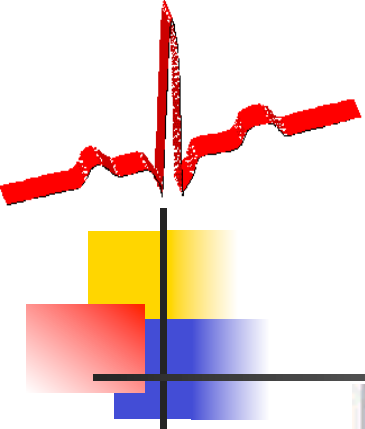
A.

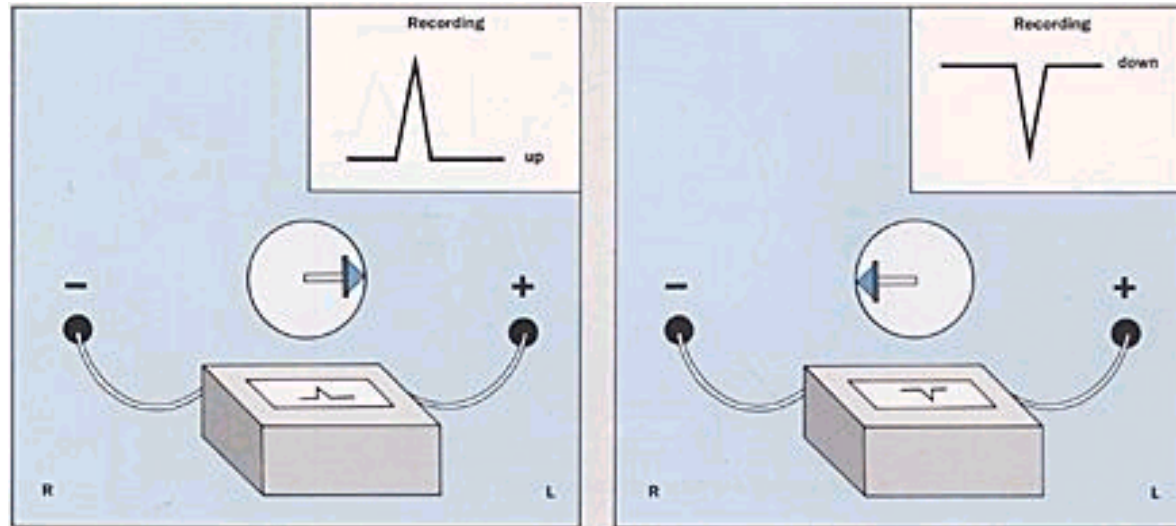
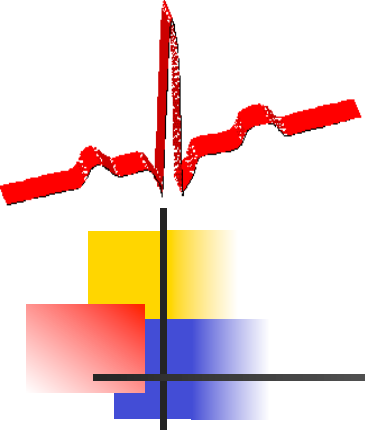
B.

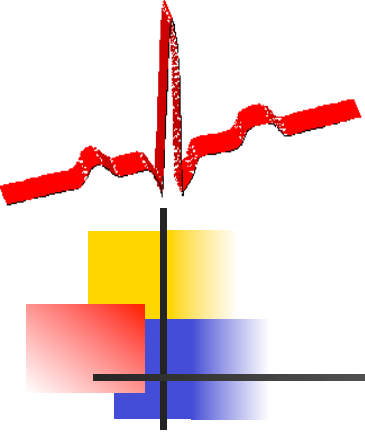
C.










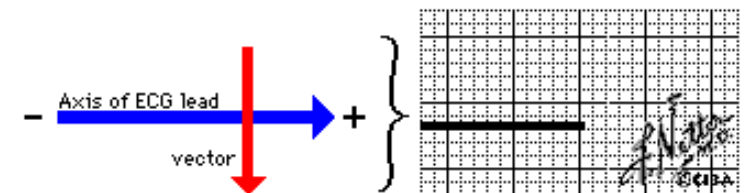
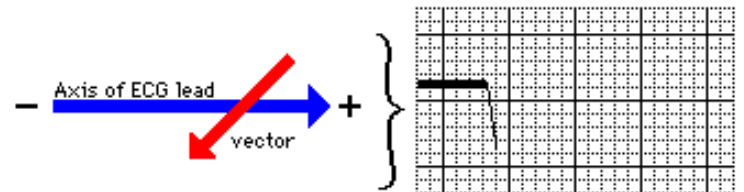
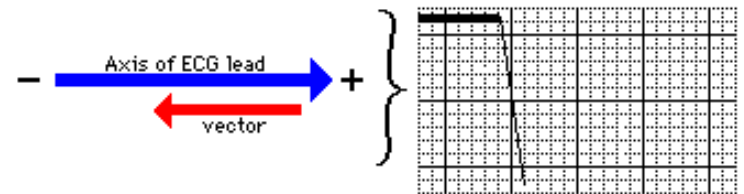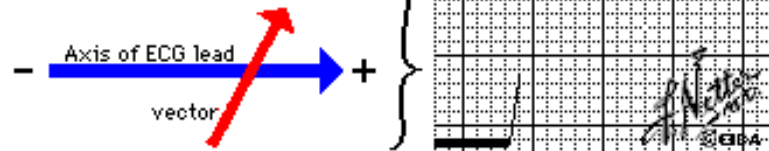
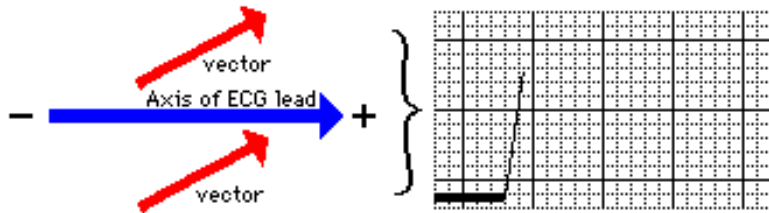
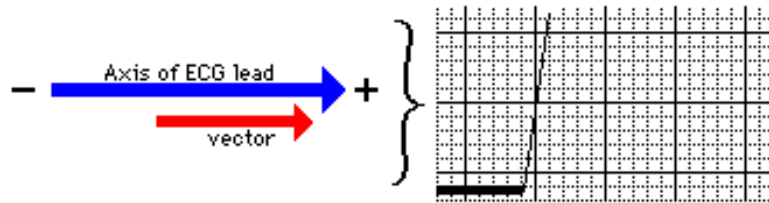


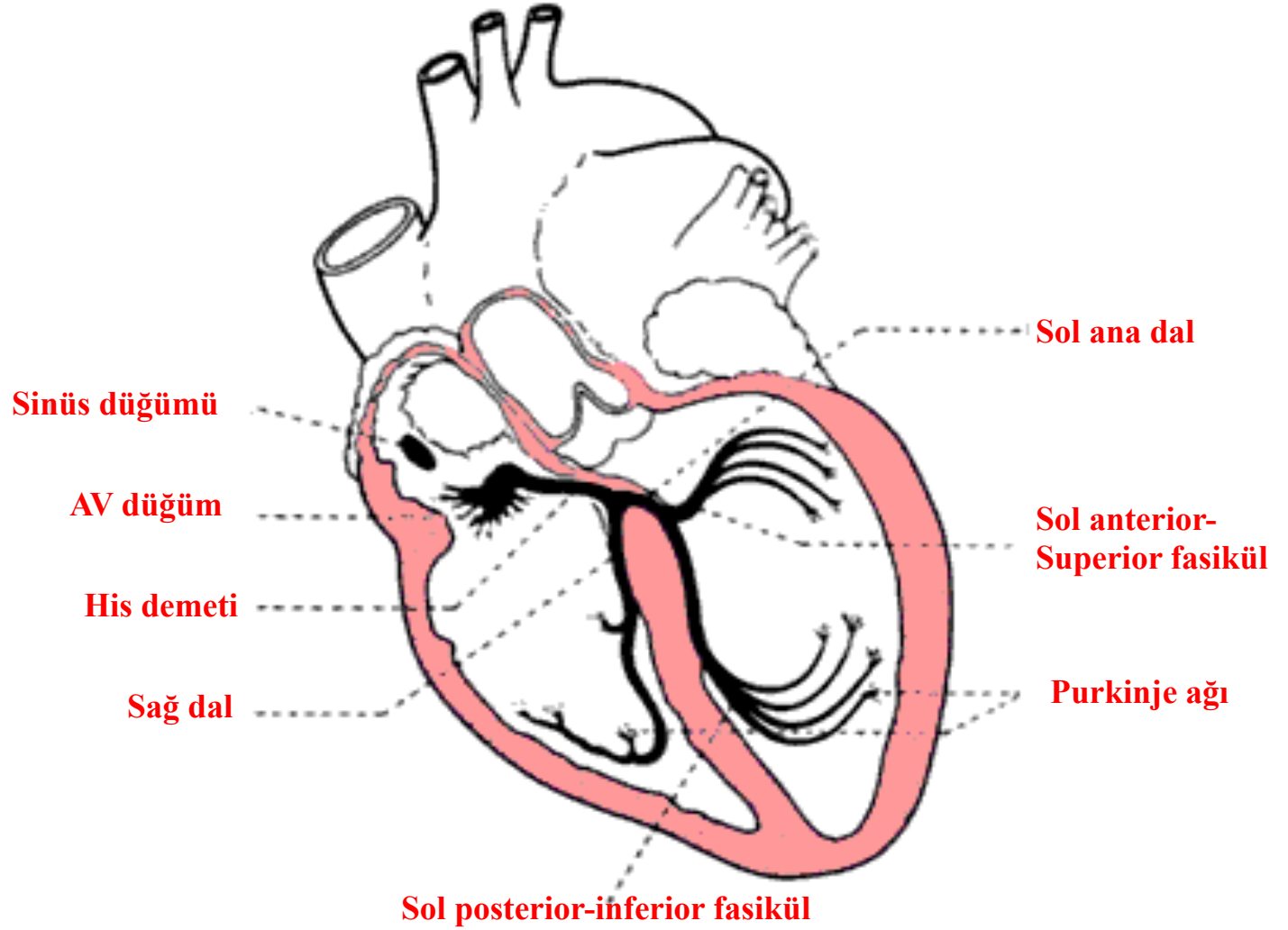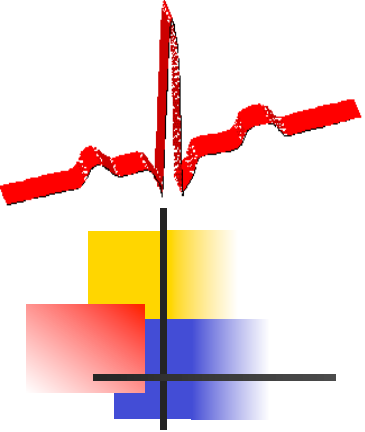


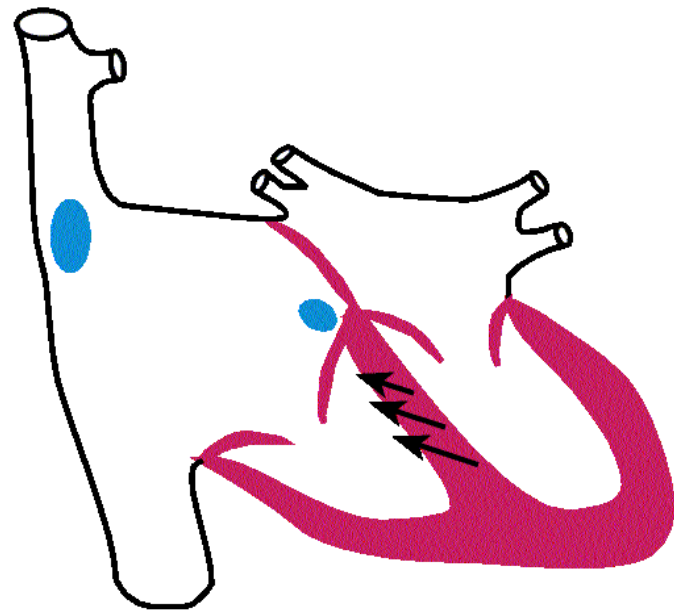
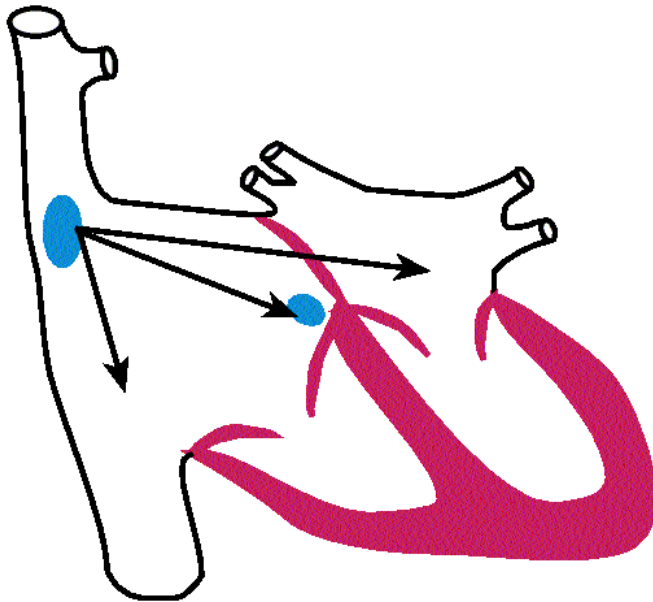
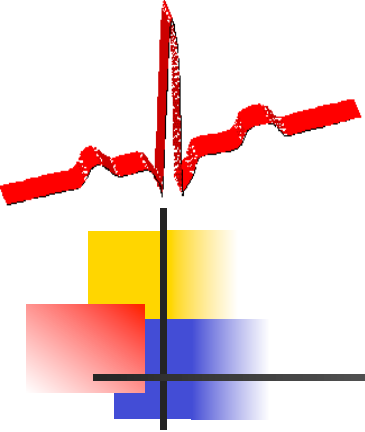
DEPOLARİZASYON


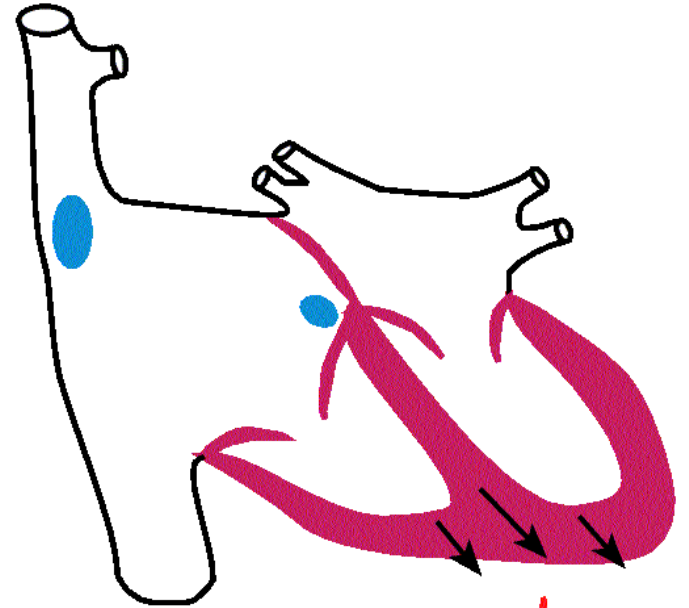
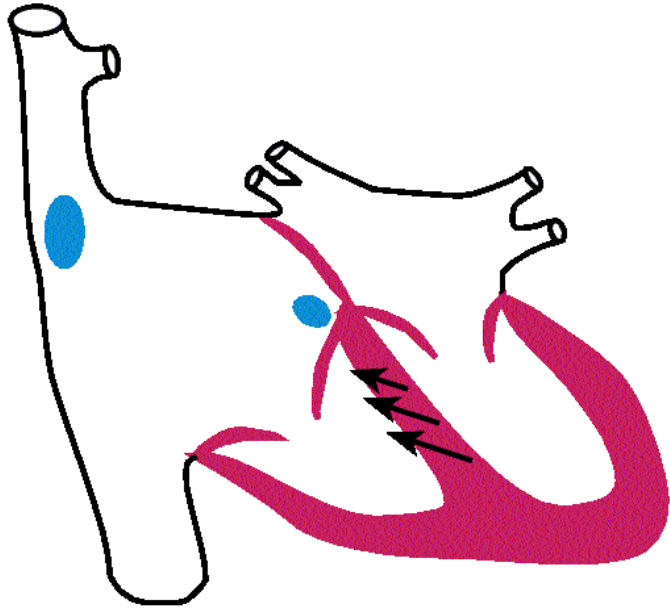
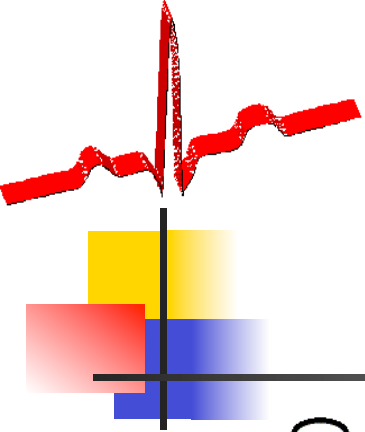


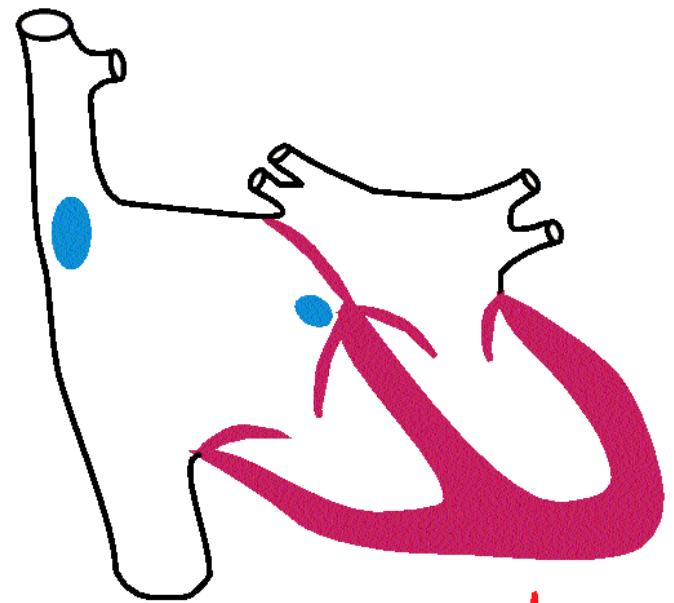
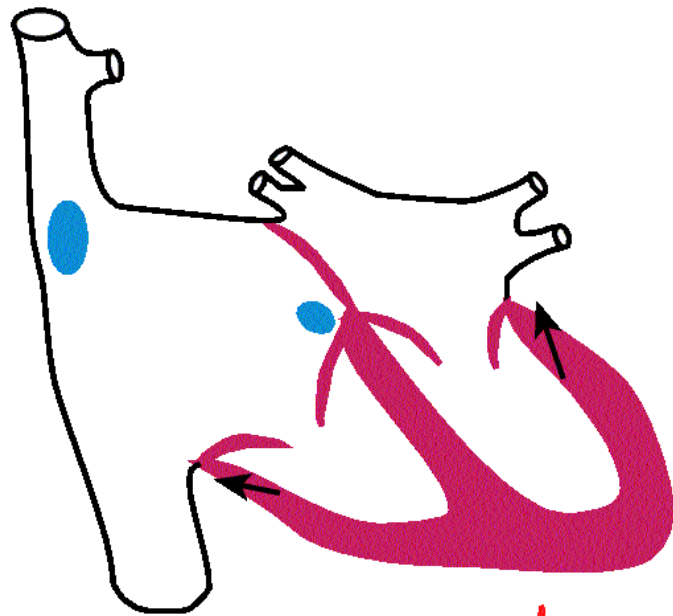
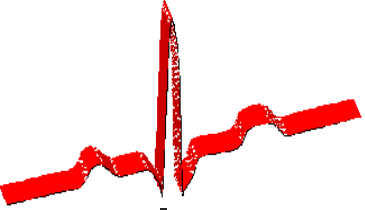
EKG TEMEL BİLGİLERİ

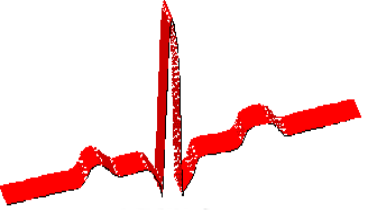




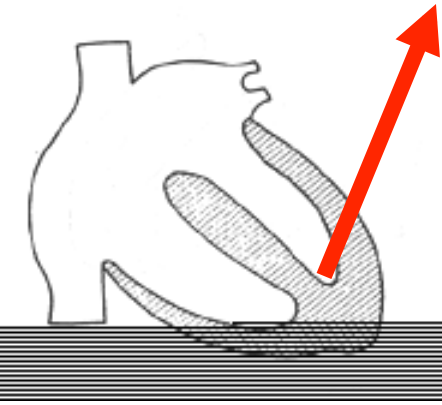
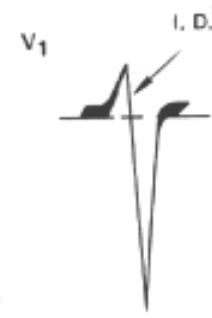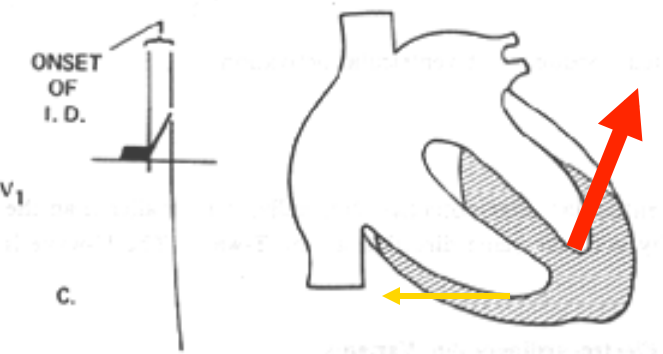
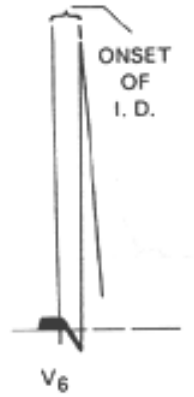
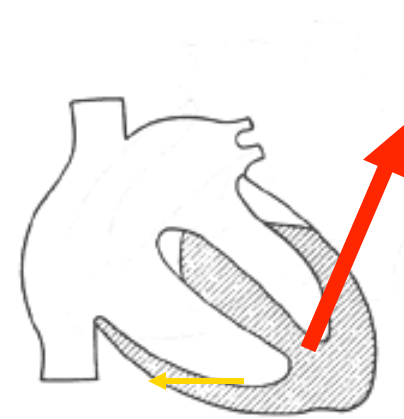
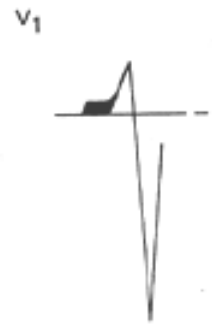
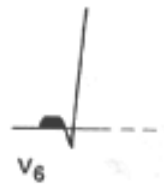
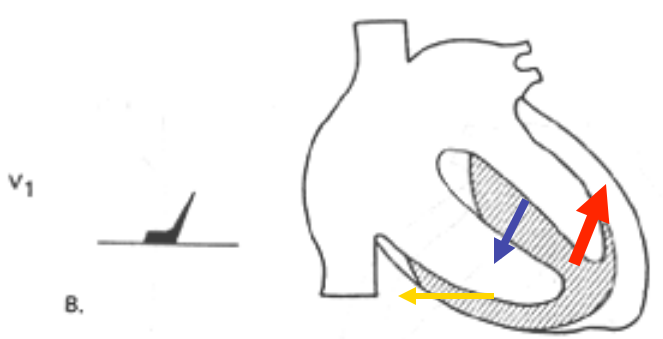
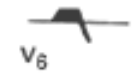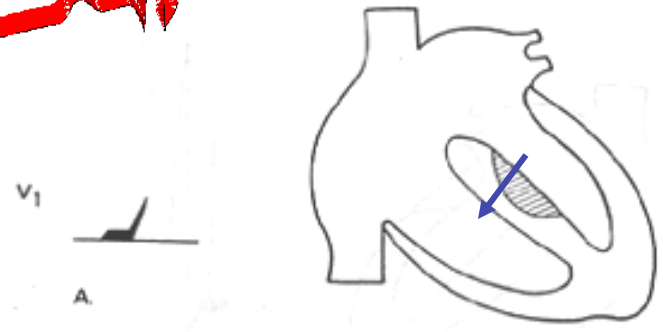


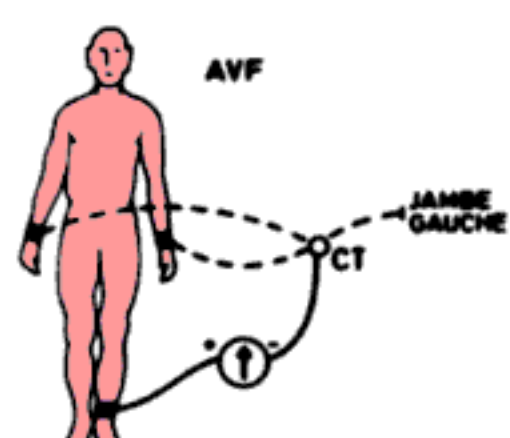
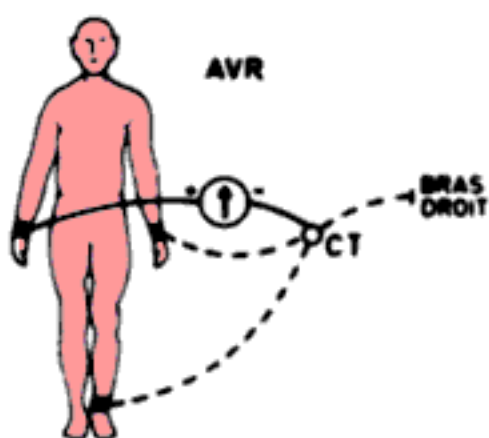
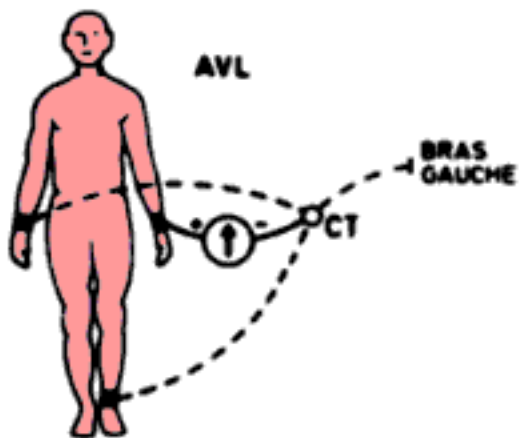
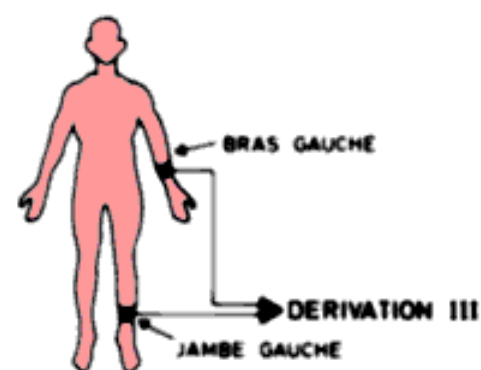
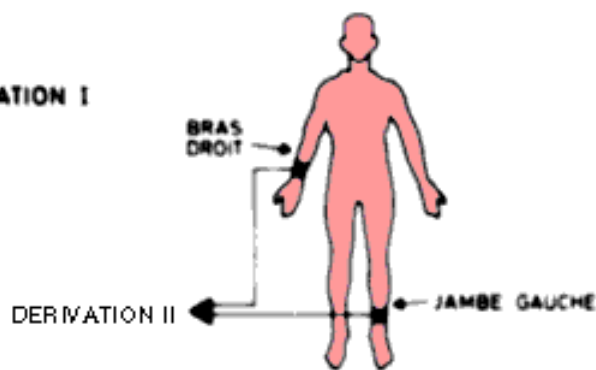
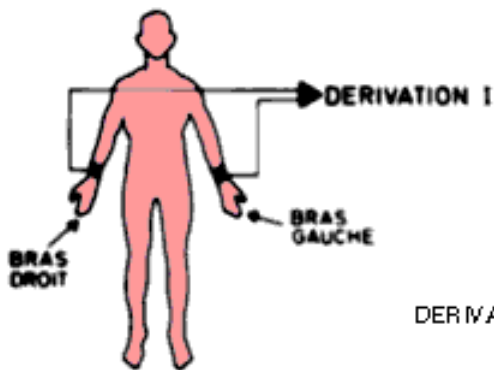
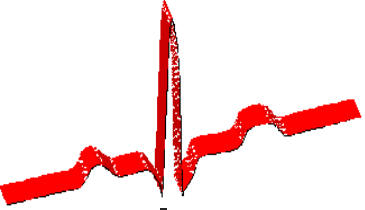


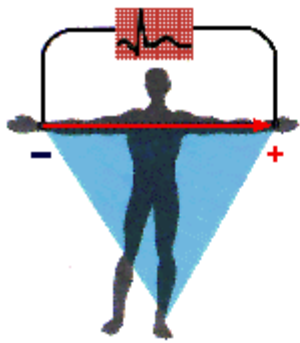




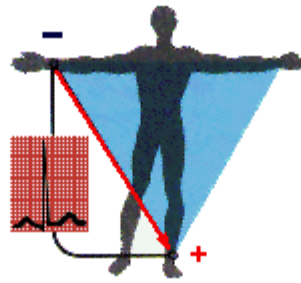
Normal ventrikül aktivasyon Sırası:





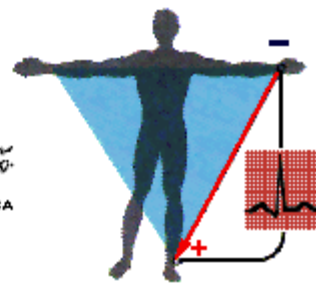


Lead I *

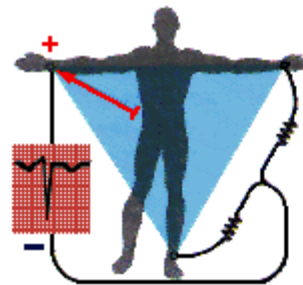


Lead II *

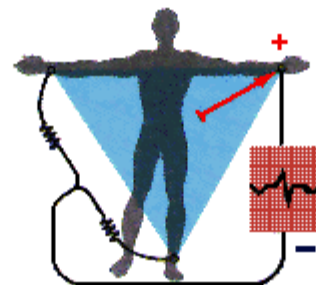
F. Netter M.D.
©CIBA



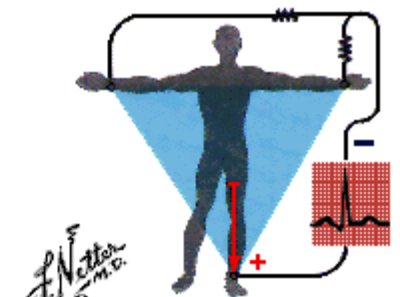
Lead III *



Lead aVR *

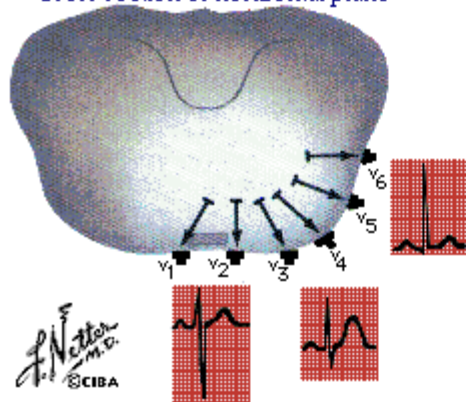


Lead aVL *

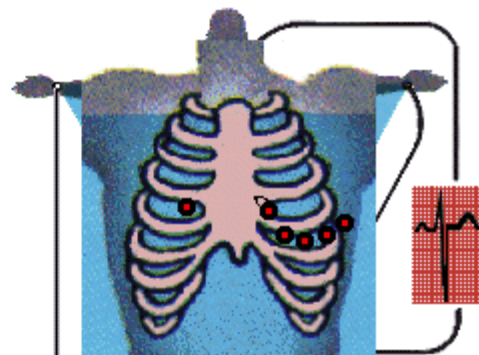


Lead aVF *

Cross section of horizontal plane

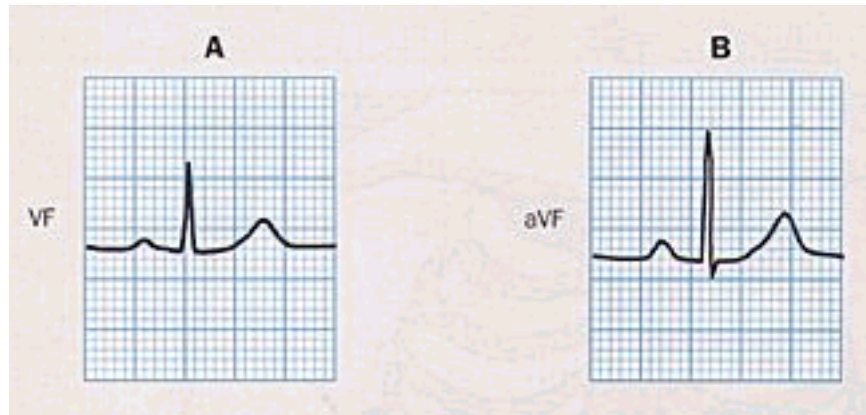
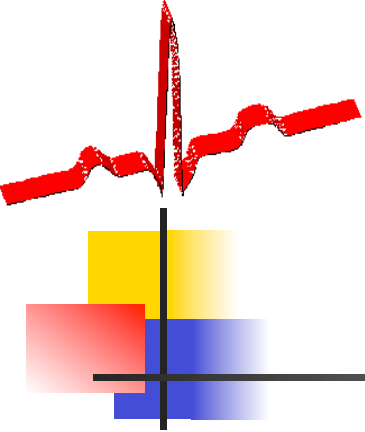


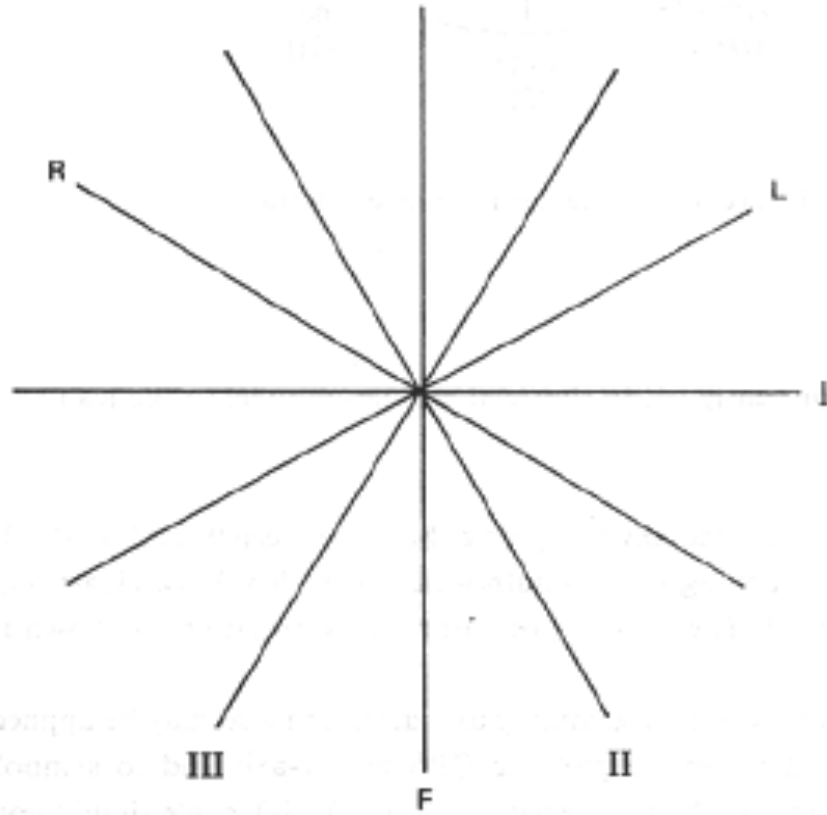
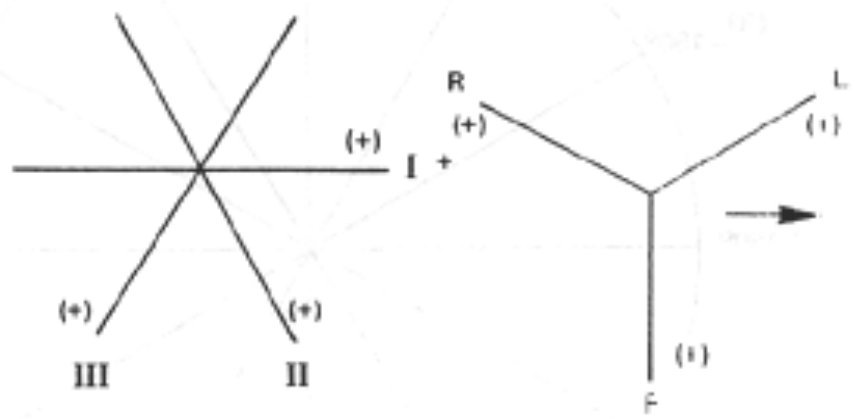
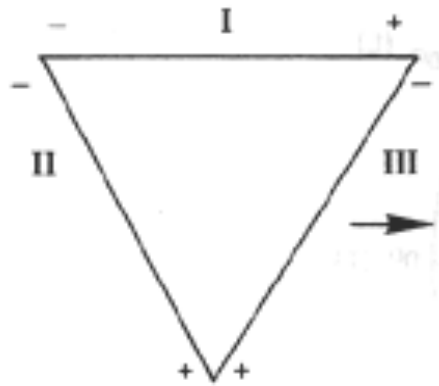
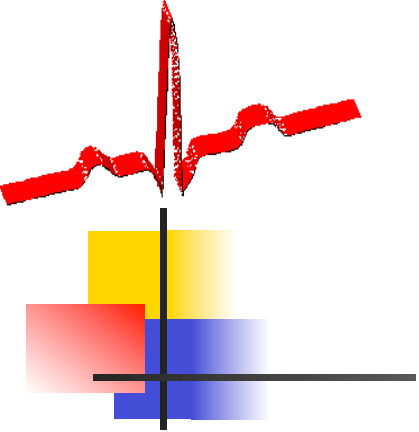
F. Netter M.D.
©CIBA

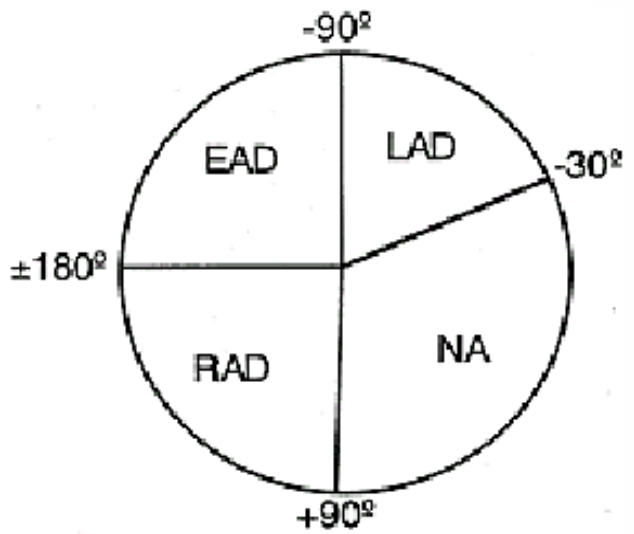
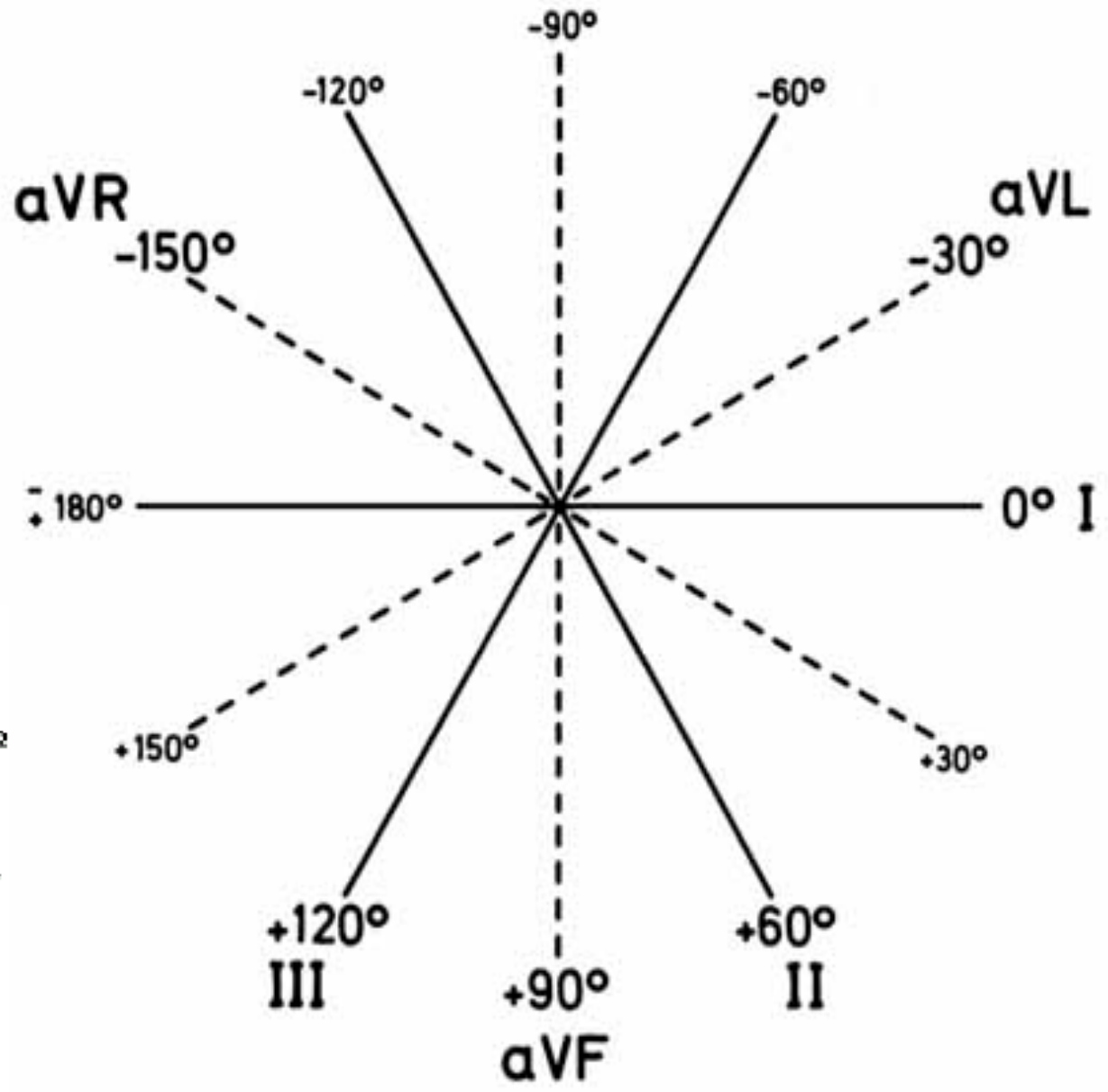
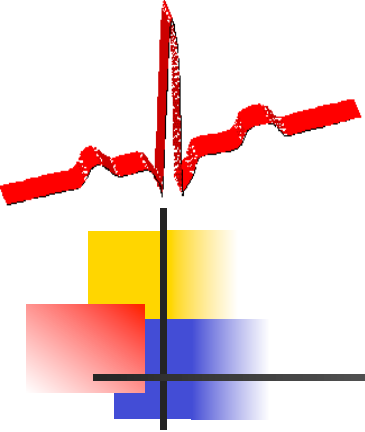


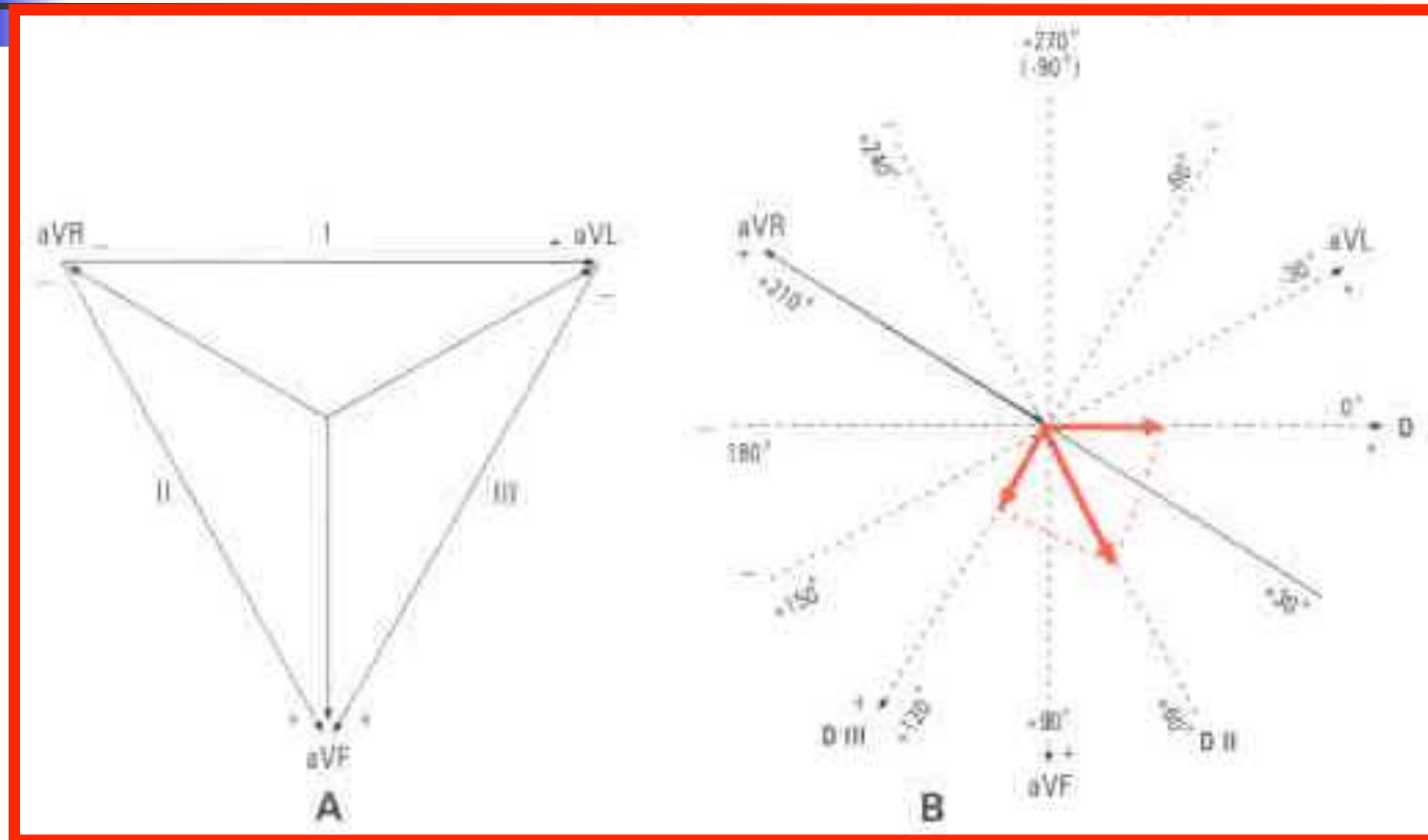
The red dots indicate the position of the chest leads. Click each dot to identify location.

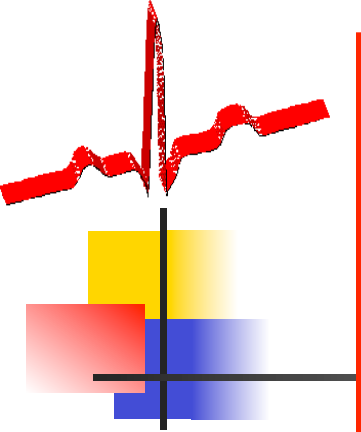
F. Netter M.D.
©CIBA



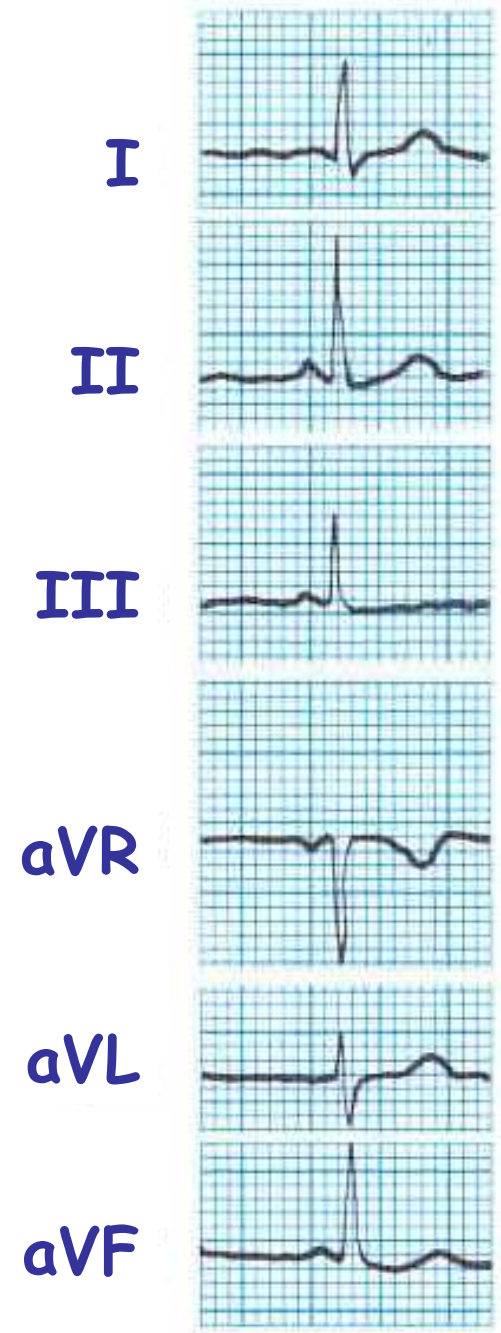
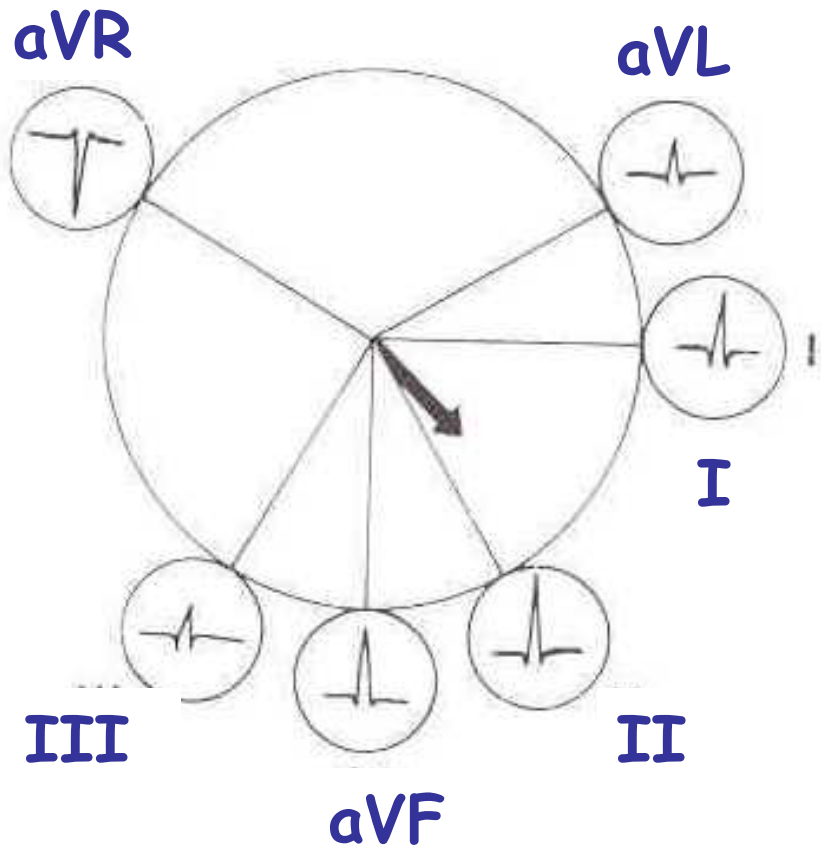


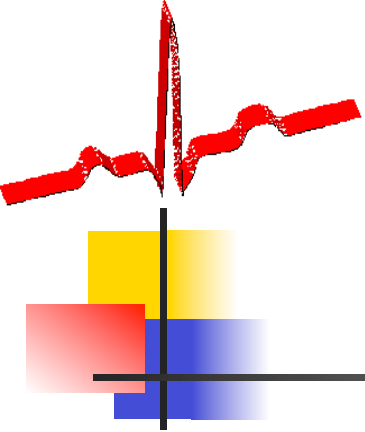




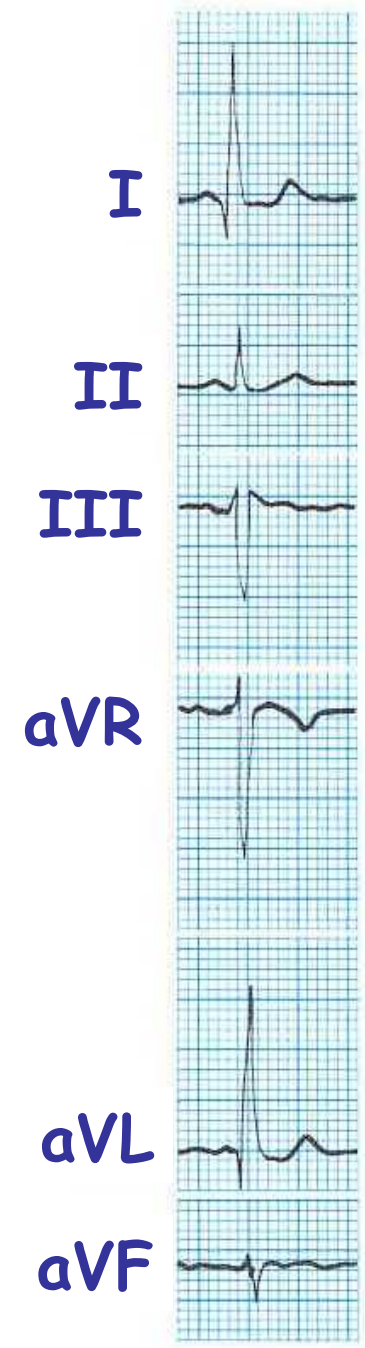
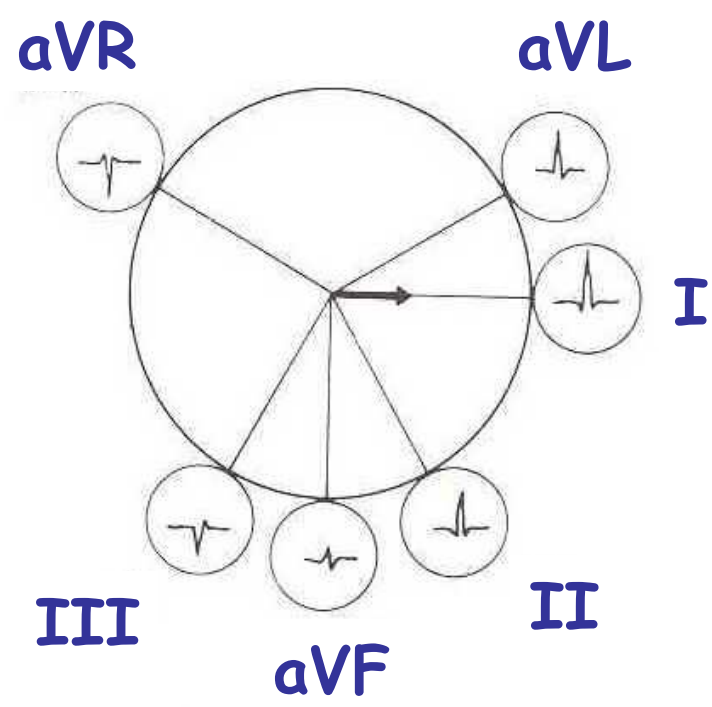


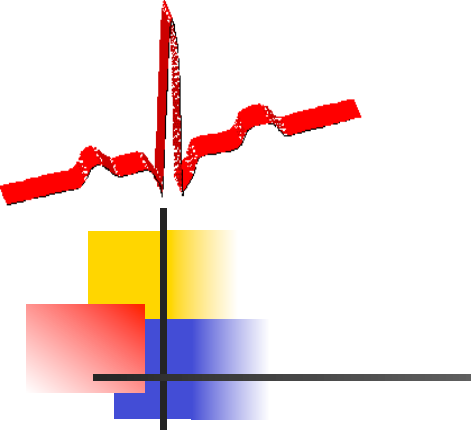
Normal eksen



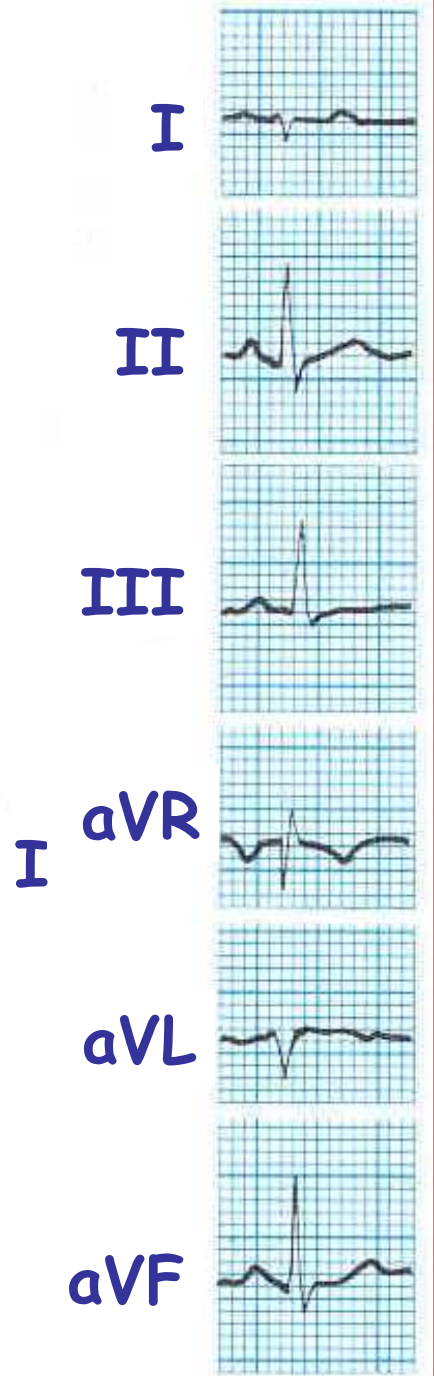
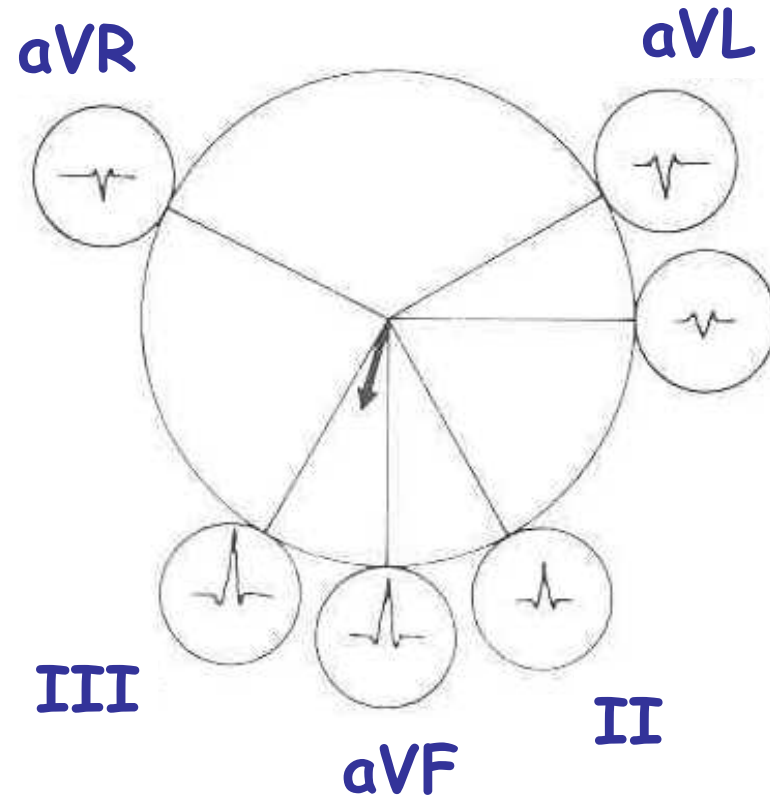


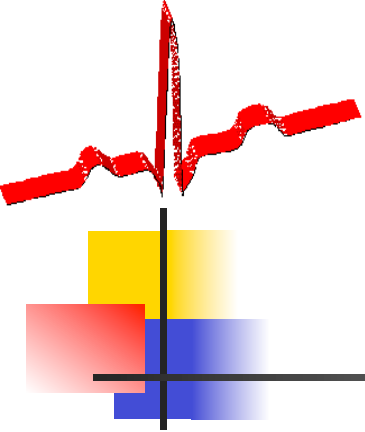
Sol eksen sapması





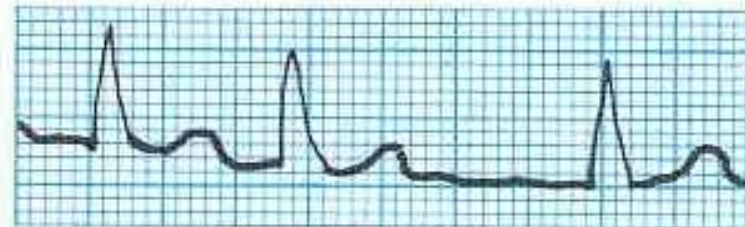
Sağ eksen sapması



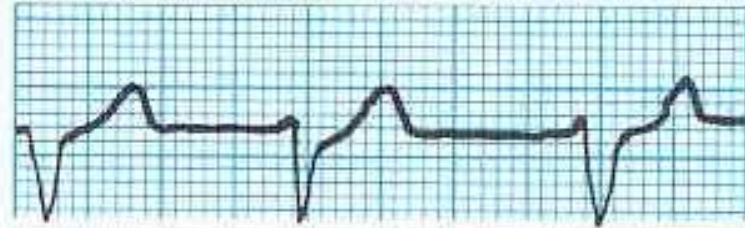

S
o
l
e
k
s
e
n
s
a
p
m
a
s
i

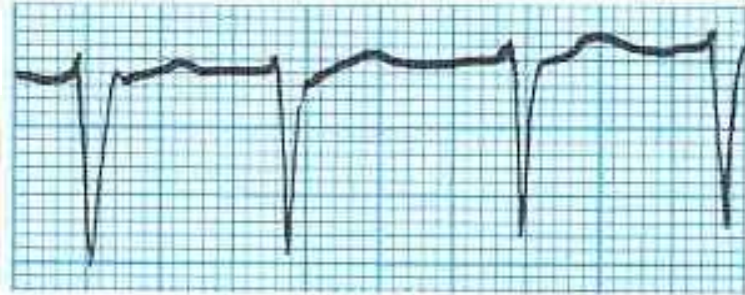
I



II



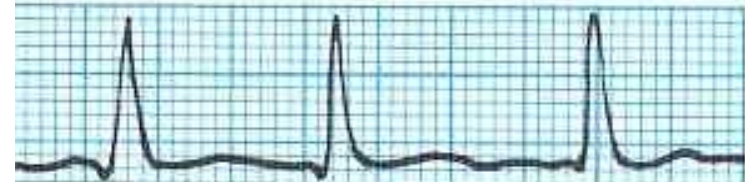
III



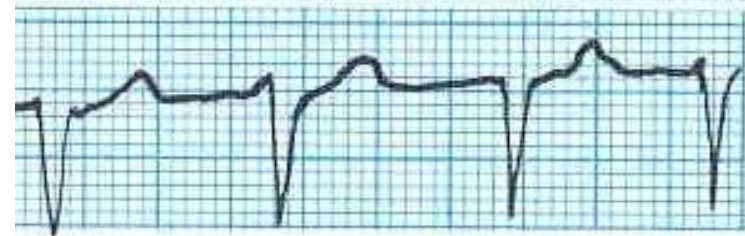aVR

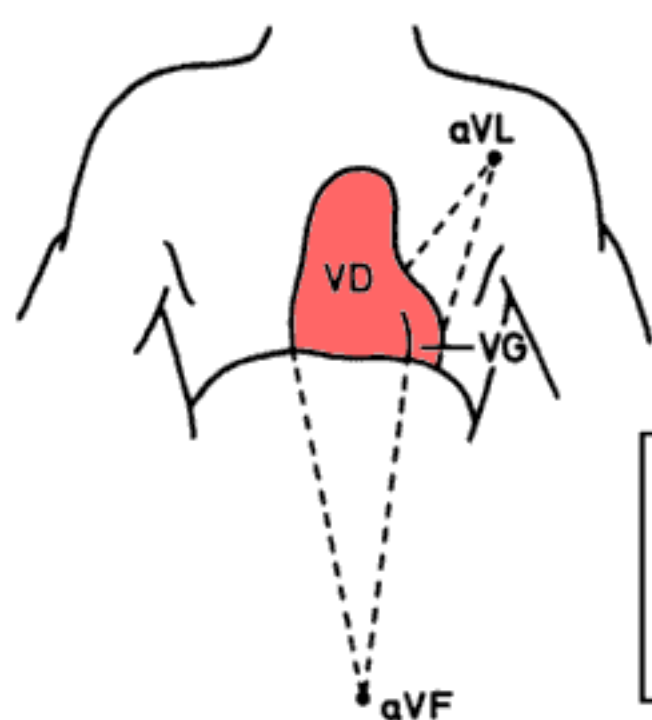


aVL

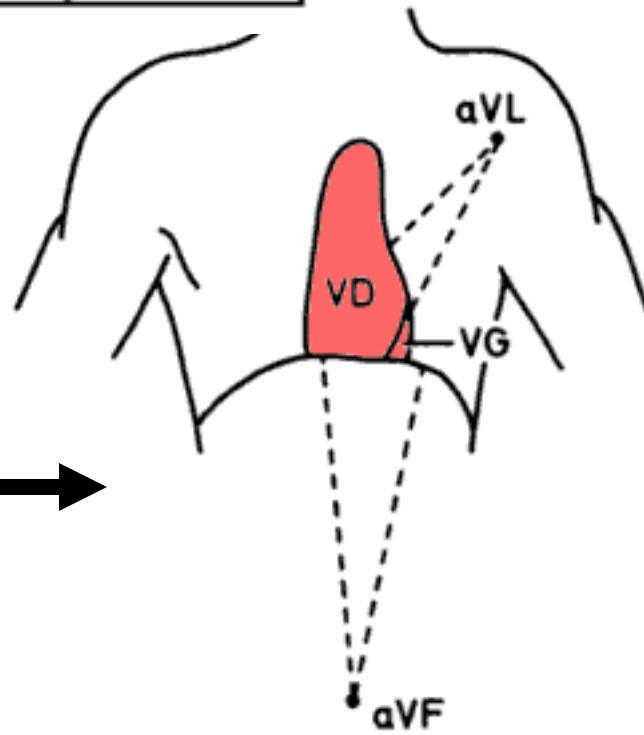
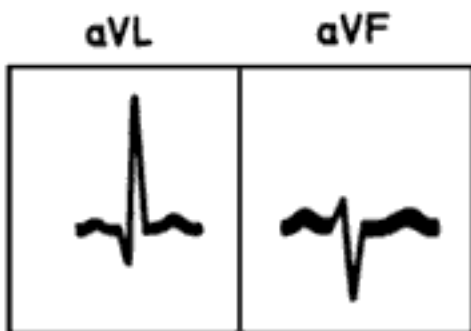


aVF

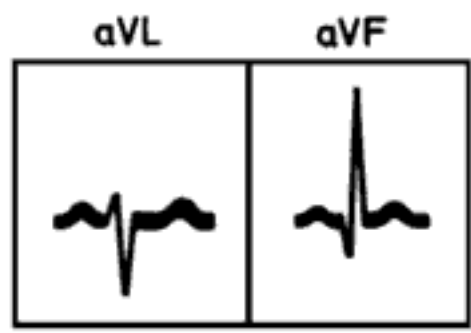

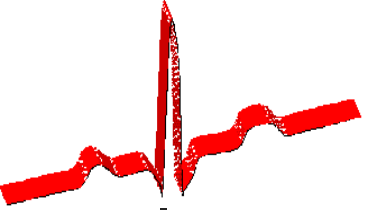


Horizontal kalp

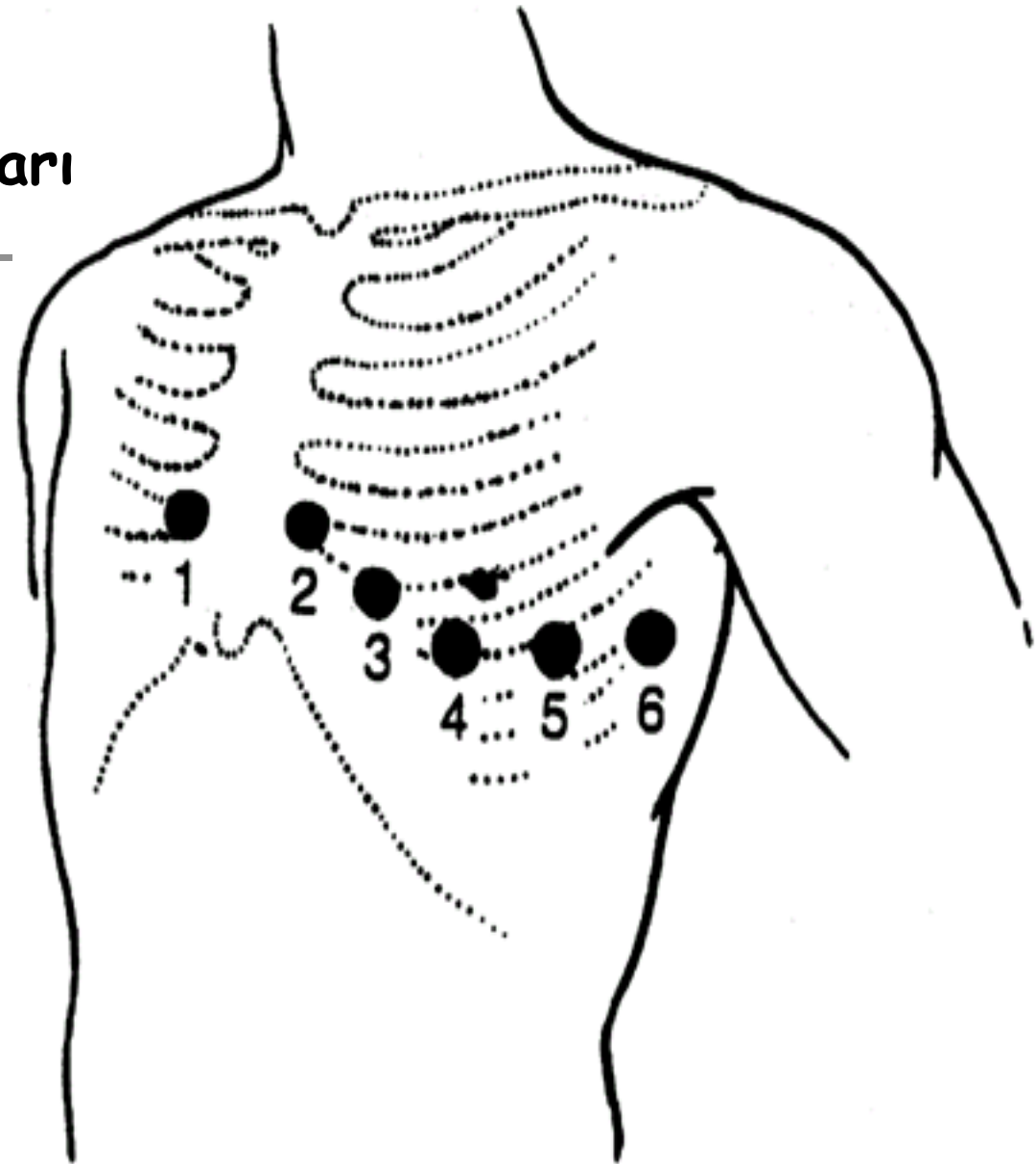


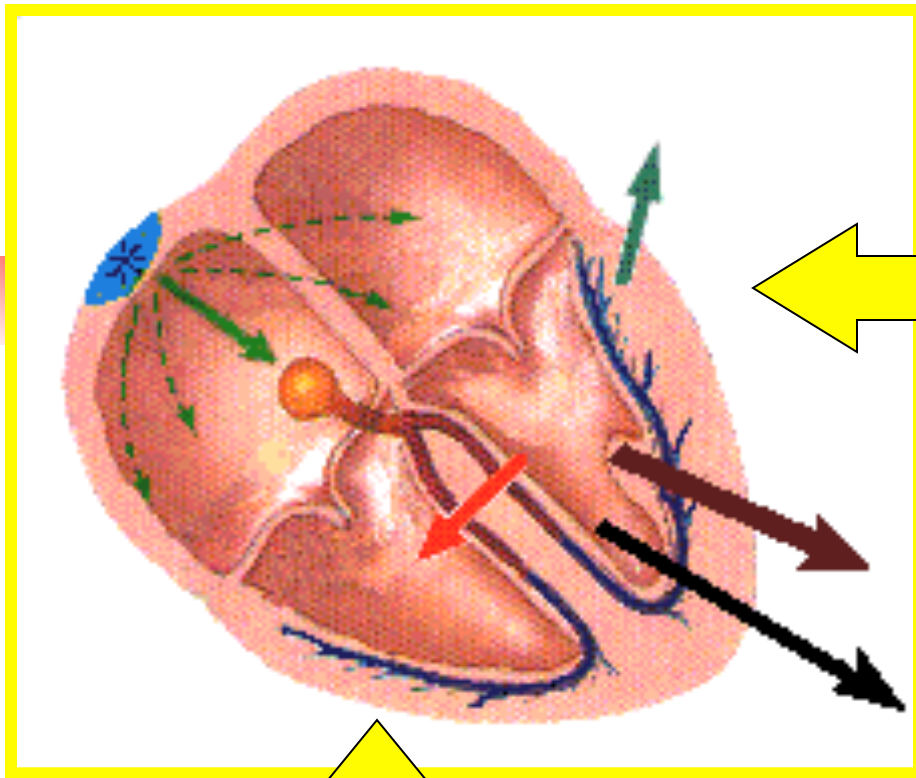
Vertikal kalp





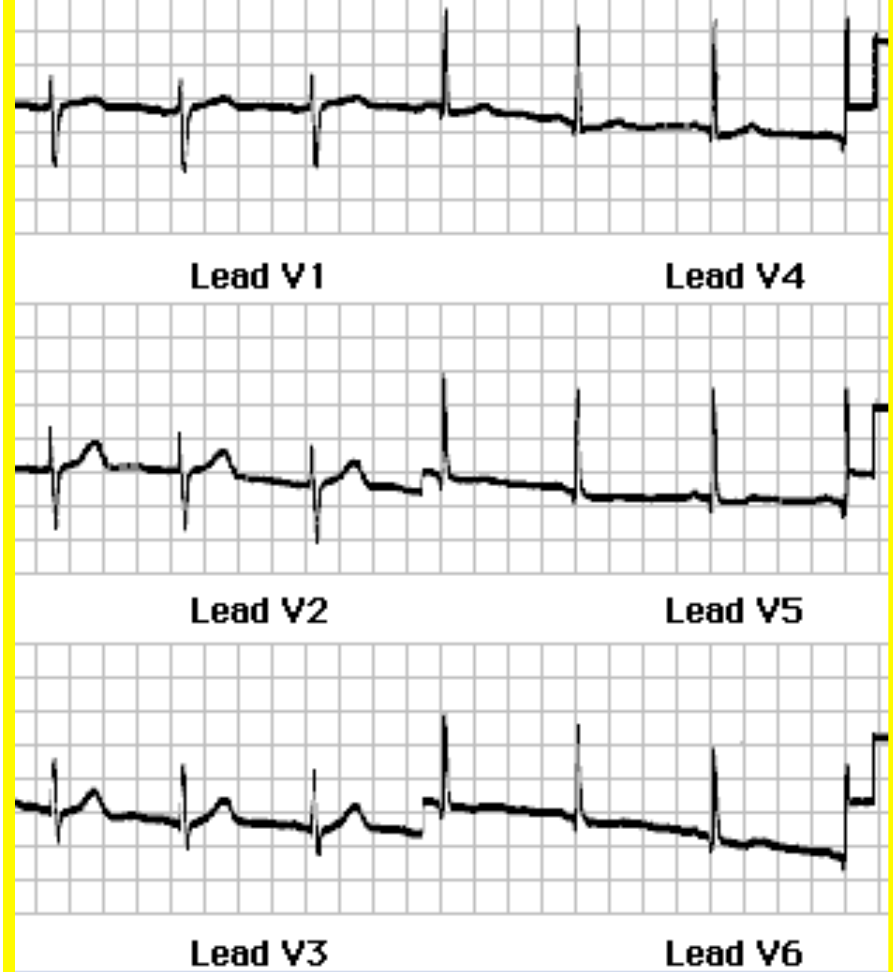
Göğüs derivasyonları

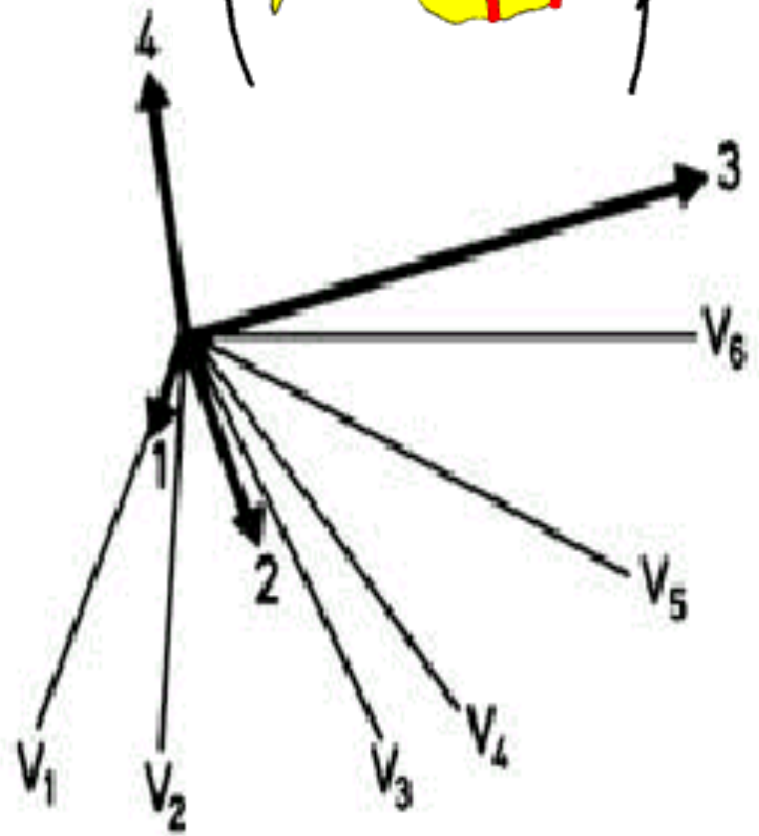
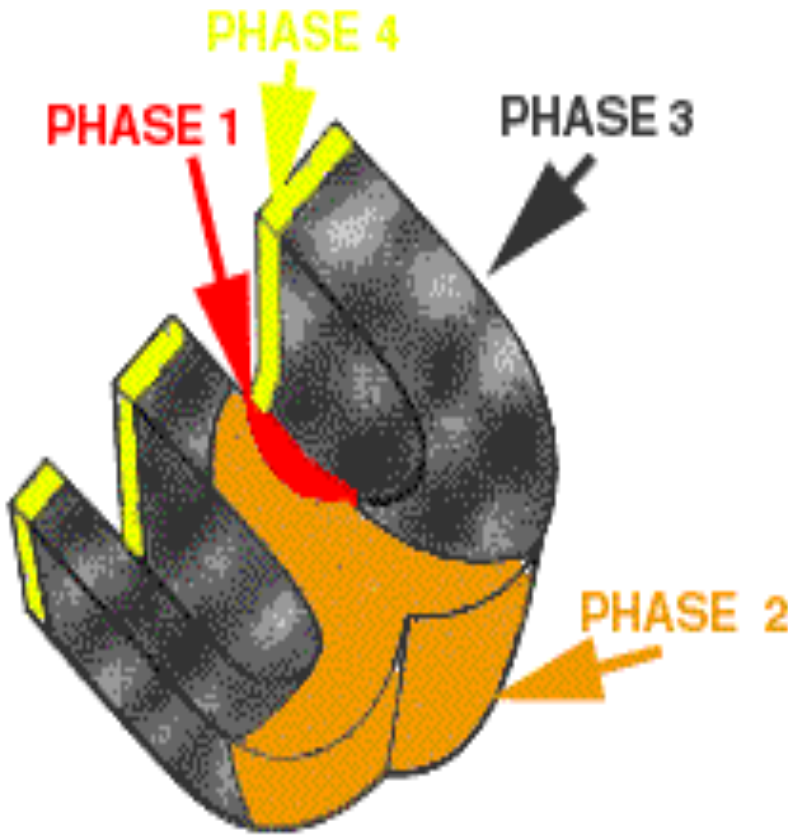
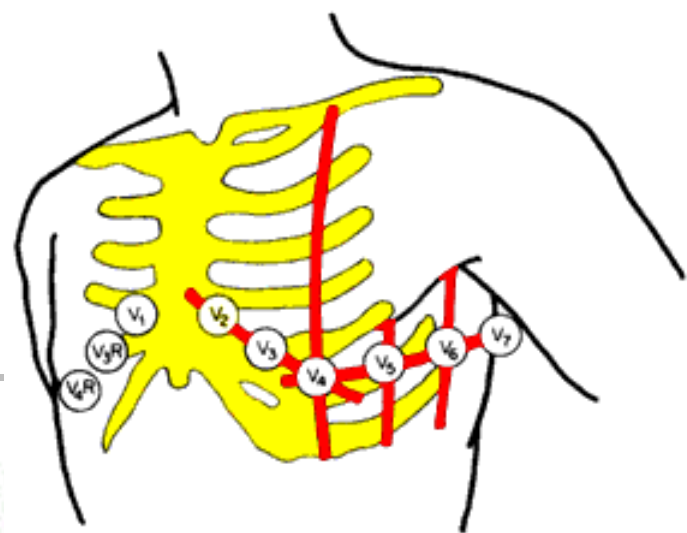
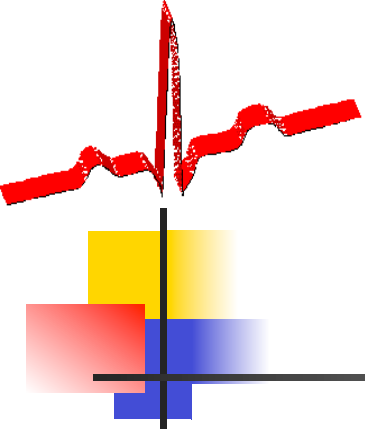


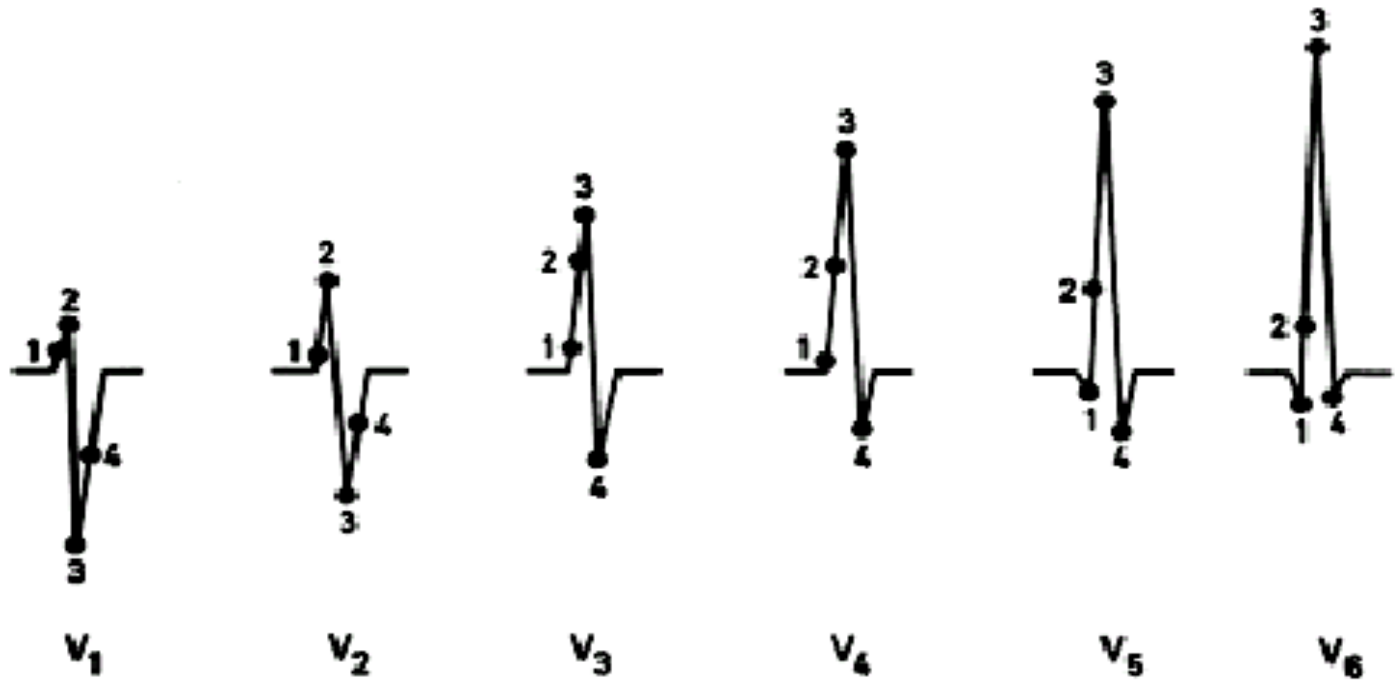
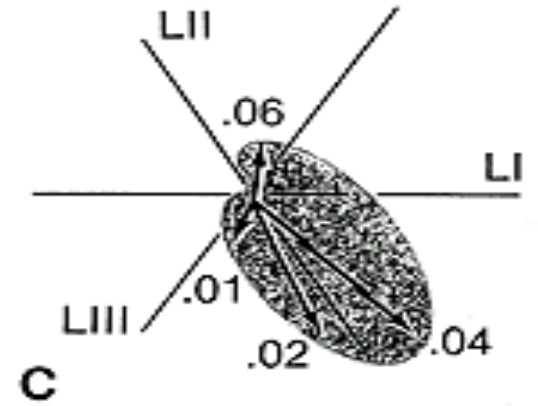
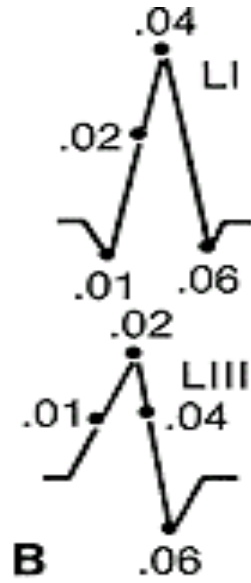
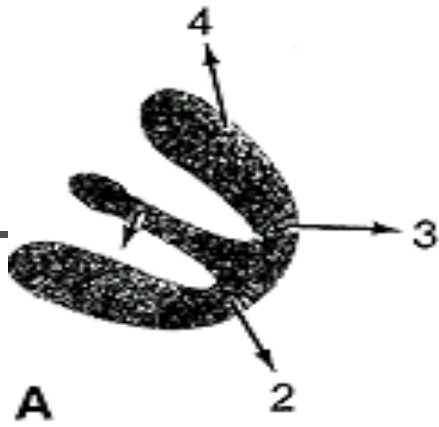
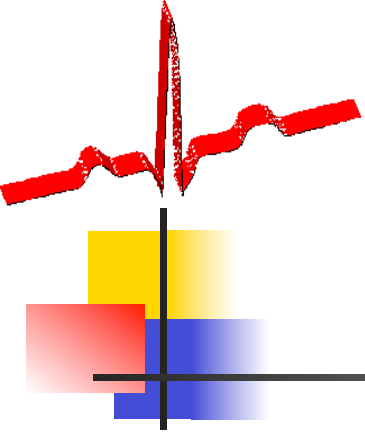


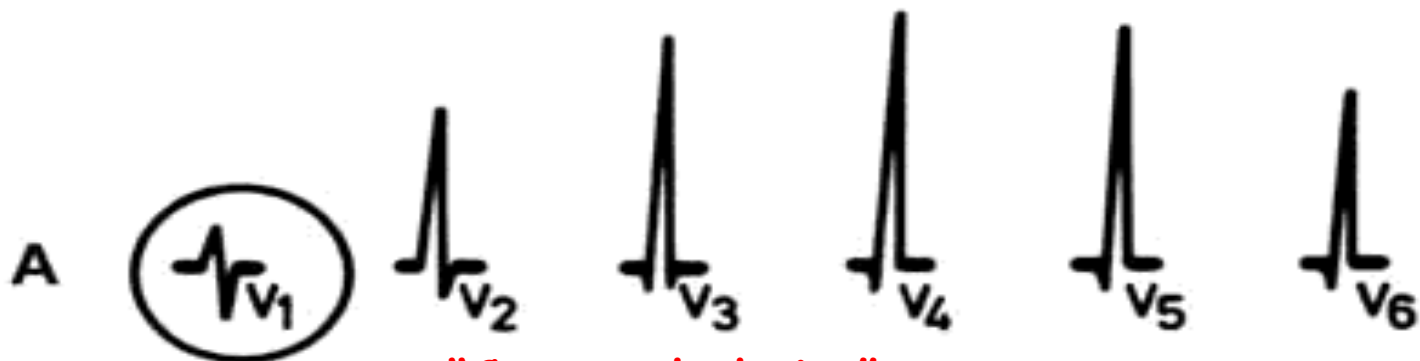
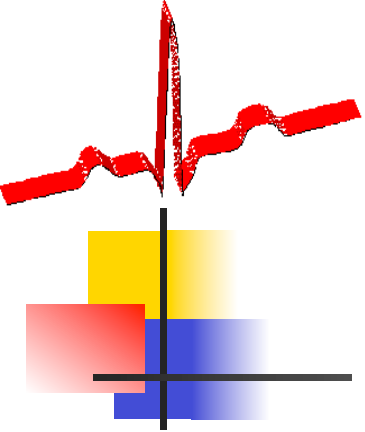
V1-2-3

V4-5-6

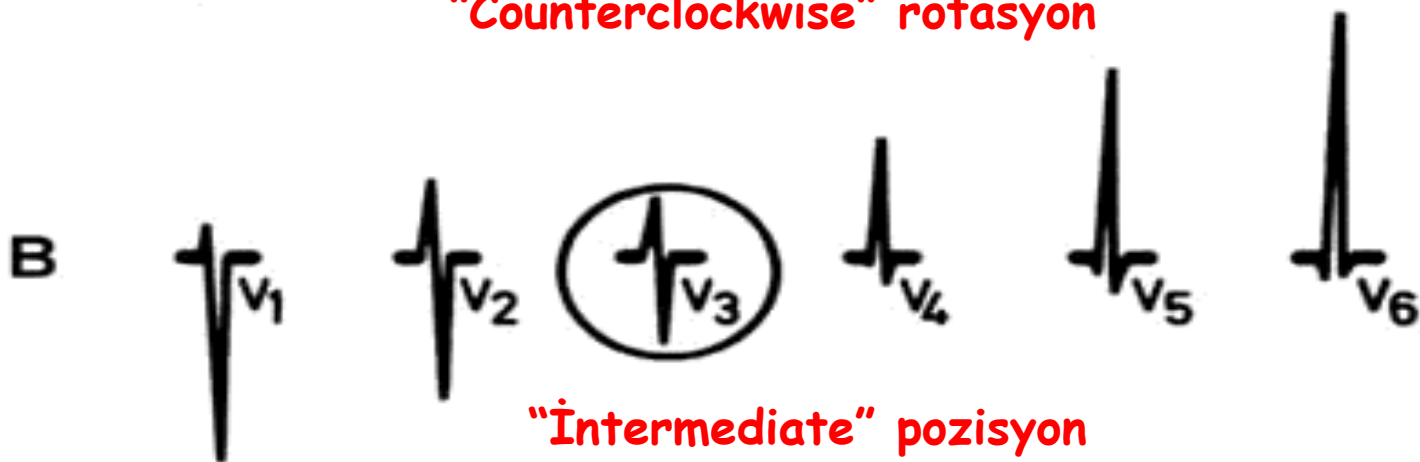









“Counterclockwise” rotasyon

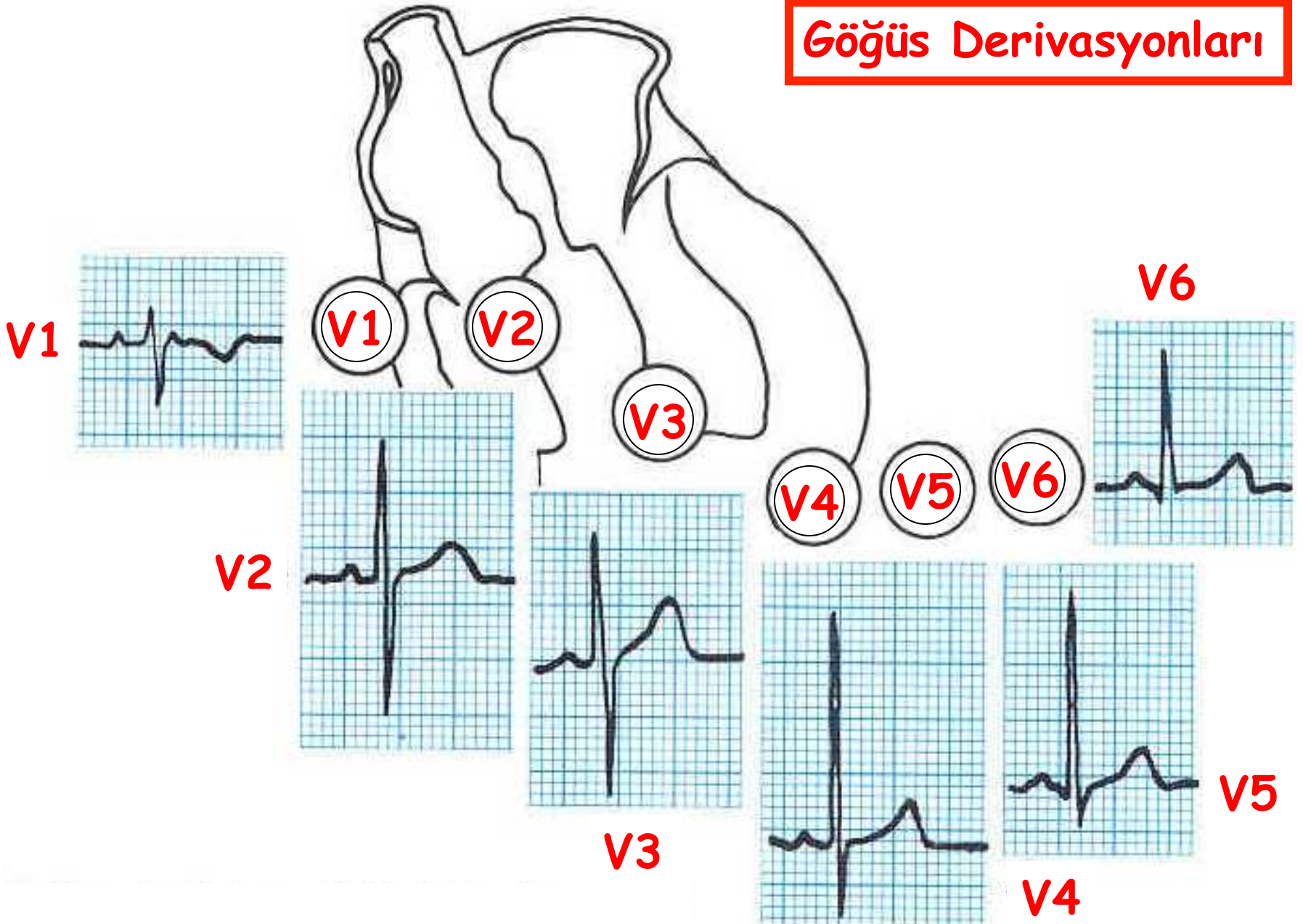


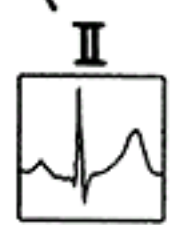
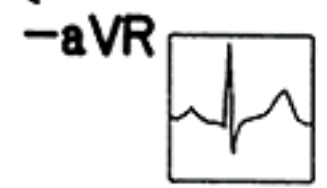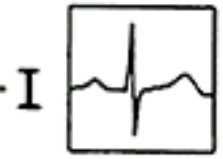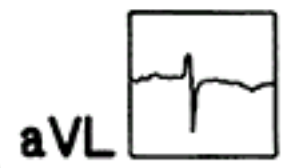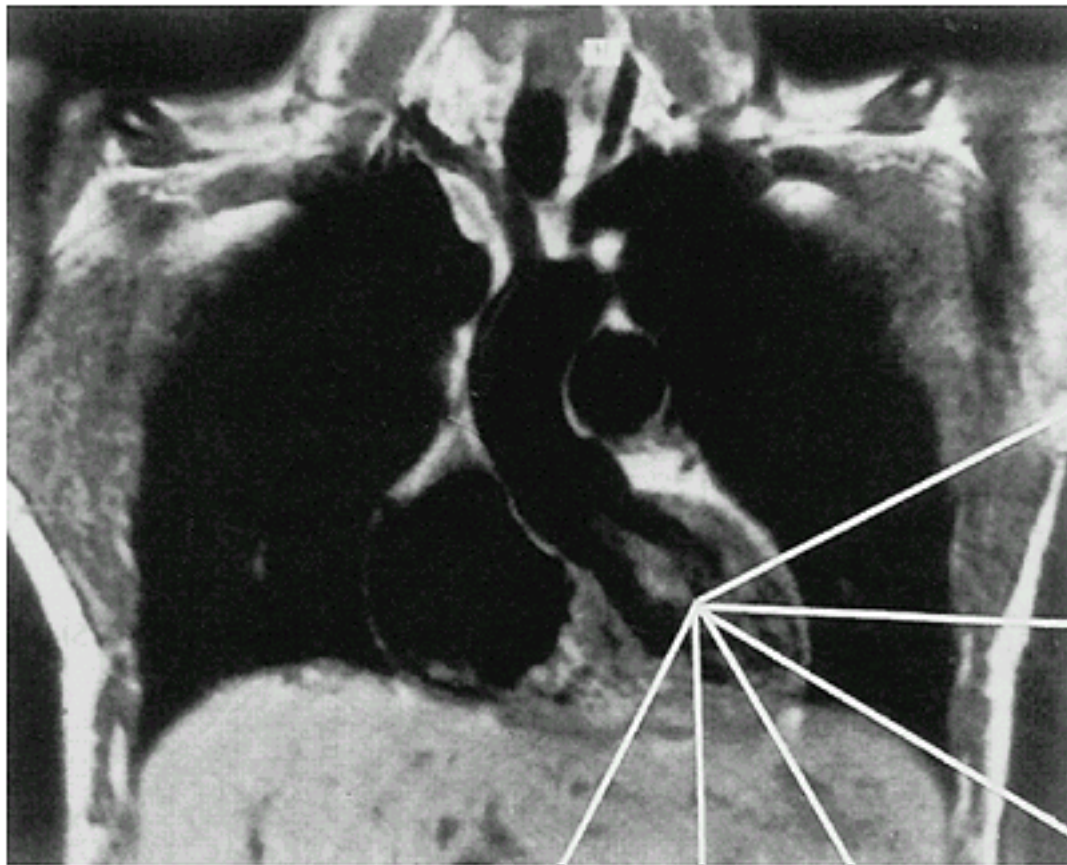
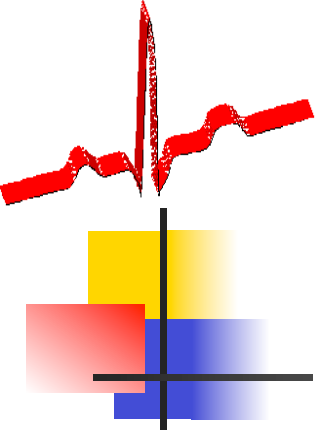
“Intermediate” pozisyon

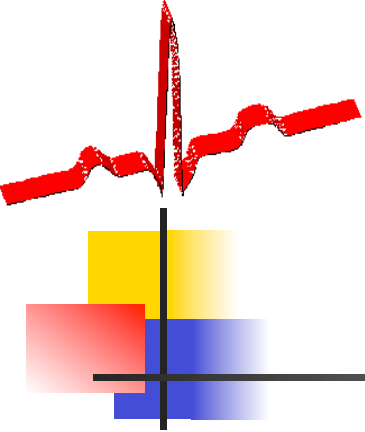


“Clock-wise” rotasyon

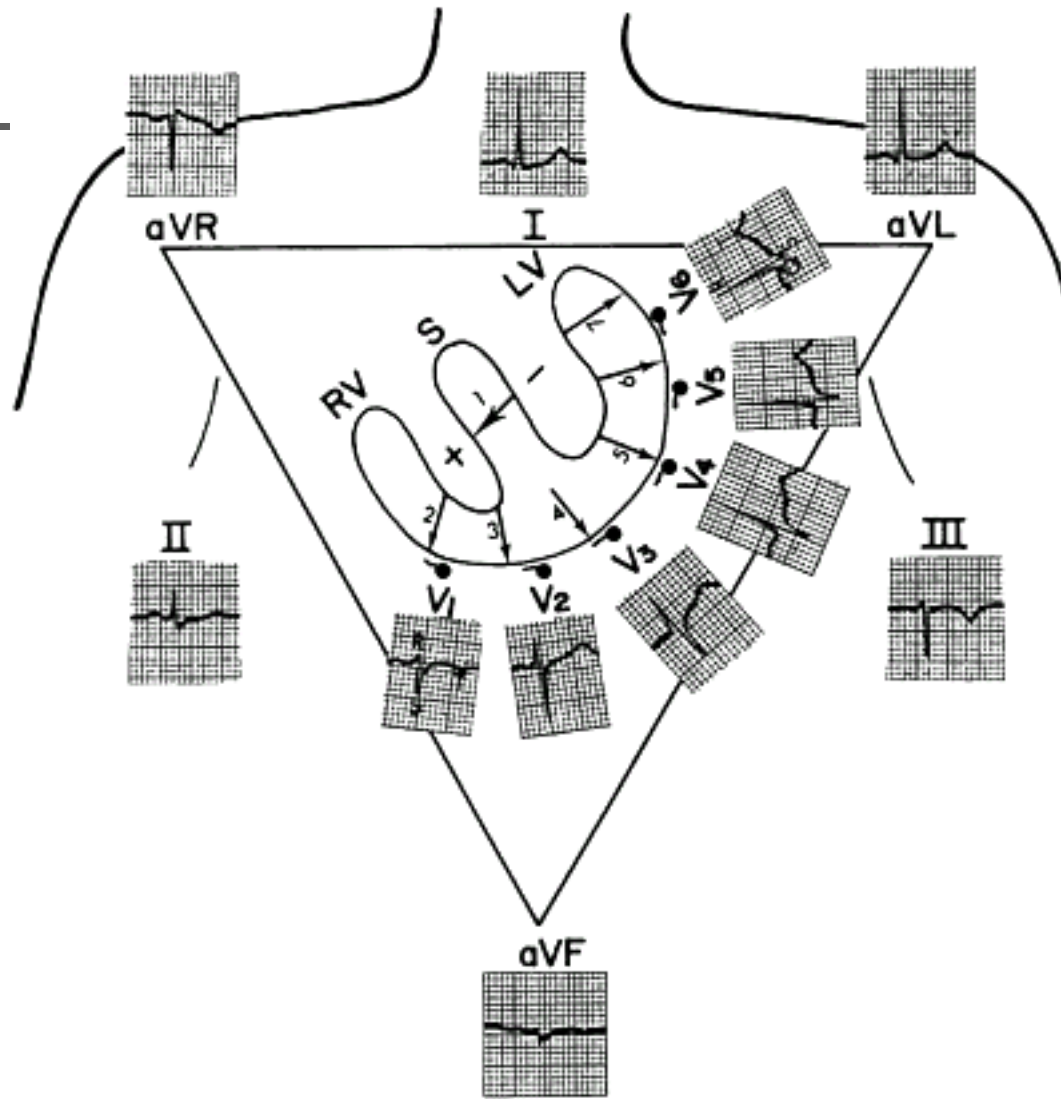
Göğüs Derivasyonları

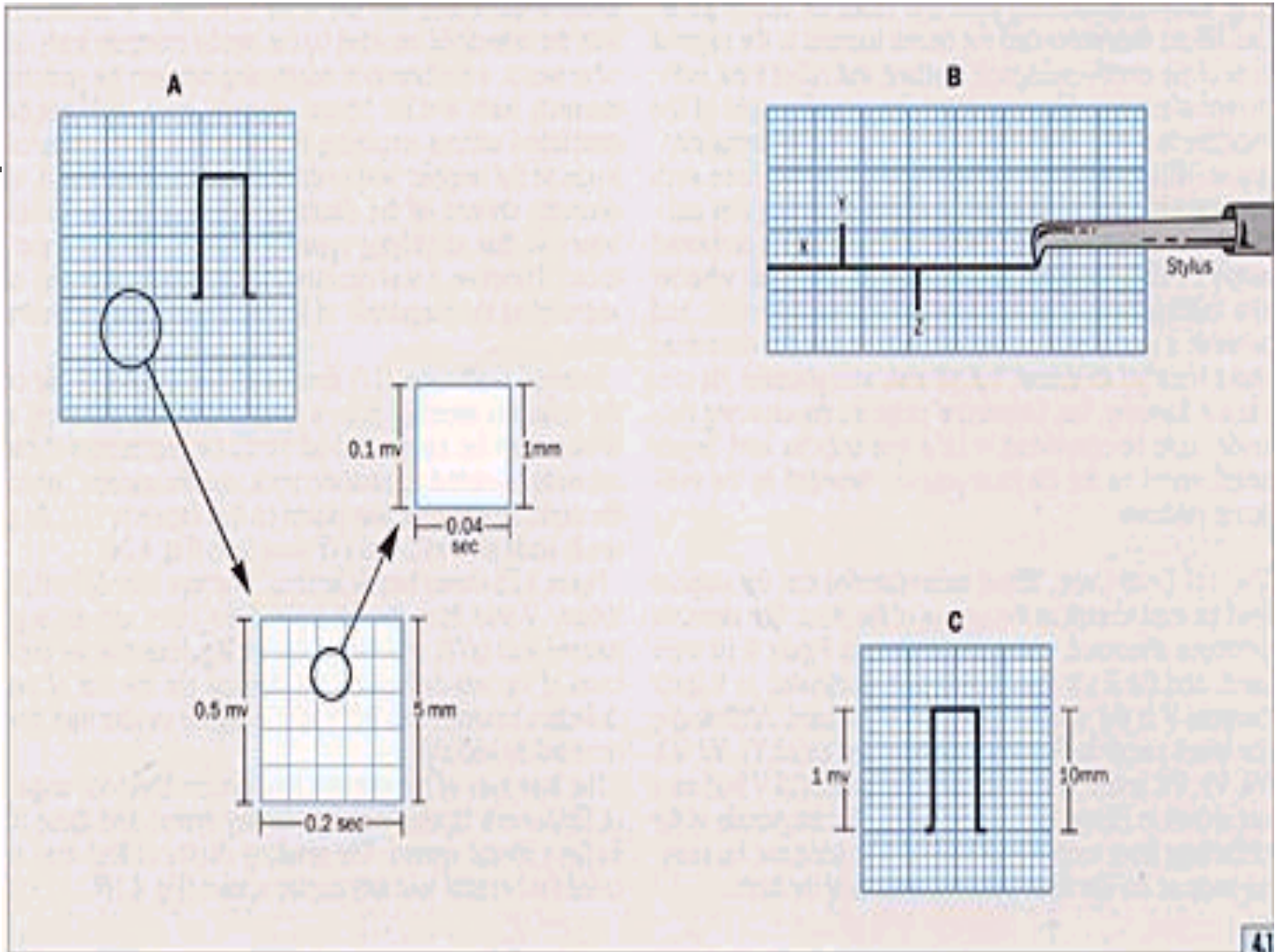
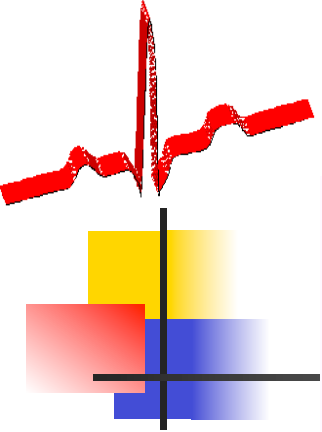


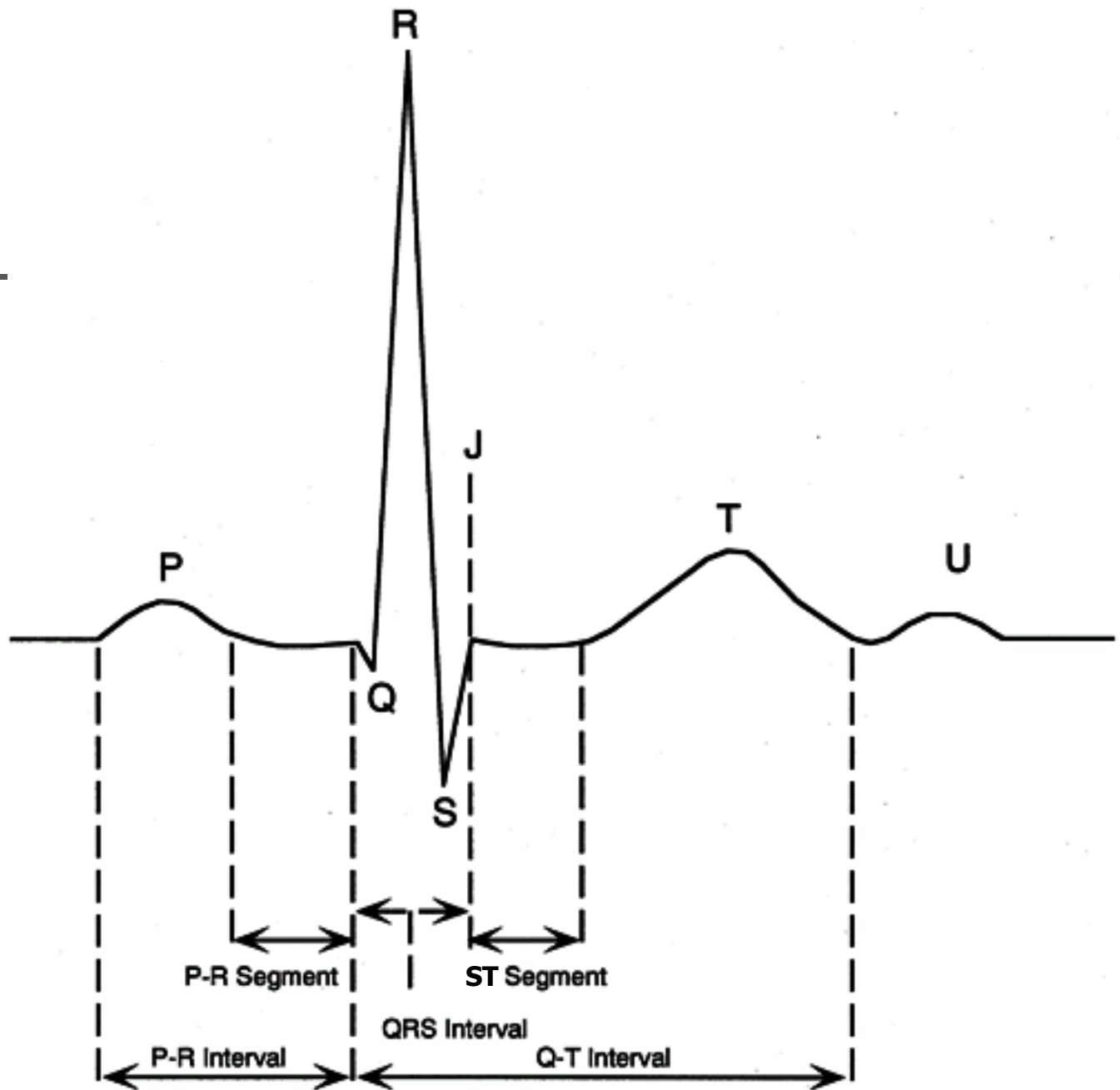
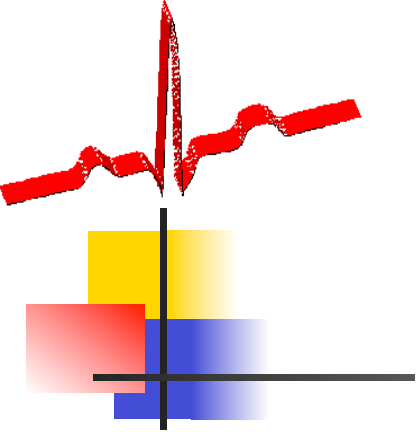


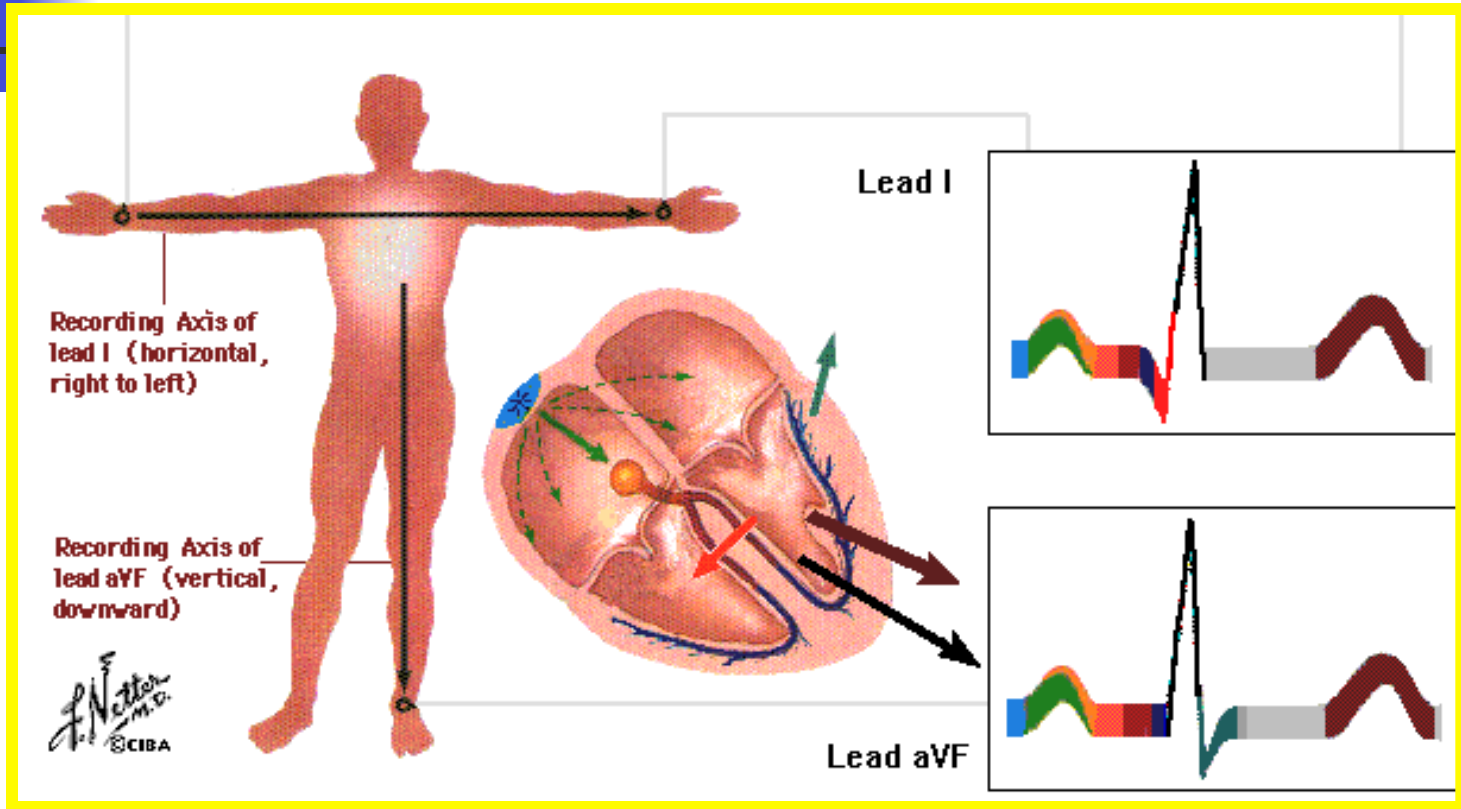


Standart 12 derivasyonlu EKG:









NORMAL DEĞERLER

- **Aks = -30 ile +110 arası**
- **P = en çok 2.5 mm yüksek, en çok 3 mm geniş, D1 de +**
- **PR = 0.12-0.20 sn**
- **QRS = 0.10 sn den kısa**
- **ST = izoelektrik**
- **T = V1-2 de (-) olabilir, kendinden önceki QRS ile aynı yönde olur, kendinden önceki R dalgasının 1/8 inden küçük veya 2/3 ünden yüksek olmamalıdır**



Altı basamakta EKG yorumu:

1) Hız ve ritm

Büyük kare (0.20 sn) kuralı (1, 2, 3, 4, 5, 6 kare için) 300, 150, 100, 75, 60, 50

Ritm sinüs değil? EVET -> aritmî analizi

2) PR intervali

PR < 0.12sn? EVET -> delta dalgası + geniş QRS? -> **Wolff-Parkinson-White**

PR > 0.20sn? (yanıtsız QRS dahil) EVET -> PR interval'ini uzatan nedenleri araştır

3) QRS interval

QRS > 0.10 sn? EVET -> QRS interval'ini uzatan nedenleri araştır (Sağ dal bloku değilse burda dur)

4) Transmural infarktüs bulguları?

Extremite derivasyonlarında Q dalgası > 0.03 sn EVET -> infarktüs

Extremite derivasyonlarında Q dalgası > R dalgasının $\frac{1}{4}$ 'ünden daha derin? EVET -> infarktüs

Extremite derivasyonlarında 1'den fazla derivasyonda Q dalgası? EVET -> infarktüs

Göğüs derivasyonlarında R dalga progresyon anormalliği? EVET -> infarktüs

5) Hipertrofi bulguları?

6) ST/QT/T dalga anormallikleri

ST çökmesi? EVET -> miyokard iskemisi

ST yüksekliği? EVET -> miyokardiyal injury

ST starain? EVET -> digital etkisi

Uzun QT + düzleşmiş T dalgaları? EVET -> hipokalemi

Erken, sivri T dalgaları? EVET -> hiperkalemi

Q dalgası olmaksızın negatif T dalgası (kalp enzimleri yükselmiş ise)? EVET -> subendokardiyal infarkt



EKG'yi değerlendirmede sistematik yaklaşım:

1. Dökümantasyon
 - Hasta adı ve tarih
2. Kayıt kalitesi
 - a) Baseline kayması
 - b) Artefakt
 - ✓ Düzensiz keskin dalgalar (İskelet kası interferensi)
 - ✓ Düzenli