

CRANIUM (BAŞ İSKELETİ)

CRANIUM CEREBRALE (Neurocranium)

- OS OCCIPITALE
- OS INTERPARIETALE
- OS PARIETALE
- OS FRONTALE
- OS ETHMOIDALE
- OS SPHENOIDALE
- OS TEMPORALE
- OS PTERYGOIDEUM
- VOMER

CRANIUM VISCERALE (Ossa Fasciei)

- OS NASALE
- OS ROSTRALE
- OS LACRIMALE
- OS ZYGOMATICUM
- OS MAXILLARE
- OS INCISIVUM
- OS PALATINUM
- MANDIBULA
- OS HYOIDEUM

CRANIUM CEREBRALE (Neurocranium)

OS OCCIPITALE

SQUAMA OCCIPITALIS

PARS LATERALIS

FOR.
MAGNUM

PARS LATERALIS

PARS BASILARIS

Pars basilaris

Synchondrosis sphenoccipitalis
Tuberculum musculare
Impressio pontina
Impressio medullaris
Foramen lacerum (eq , su.)

Pars lateralis

Condylus occipitalis
Processus jugularis – Proc.paracondylaris
Fossa condylaris ventralis
Canalis condylaris (su. ve eq. yok)
For. hypoglossi – Canalis ni hypoglossi
Fossa condylaris dorsalis

Squama occipitalis

Crista nuchae (car. , eq. , su.) – Linea nuchae (ru.)
Crista sagittalis externa (car.,eq.)
Linea temporalis
Protuberantis occipitalis externa (su. yok)
Protuberantis occipitalis interna (su.,ru.)
Processus tentoricus (car.,eq.)
Tentorium cerebelli osseum

OS INTERPARIETALE

Processus tentoricus
(car.,eq.)

OS PARIETALE

Tuber parietale
Crista sagittalis externa
Crista sagittalis interna
Processus tentoricus
Planum nuchale (B.ru.)
Planum temporale (B.ru.)
Linea temporalis
Planum parietale (K.ru.)
Planum temporale (K.ru.)

OS FRONTALE

-Squama frontalis

proc. cornualis
protuberantia intercornualis
proc. zygomaticus
fossa glandulae lacrimalis
arcus orbitae
lig. orbitale
for. supraorbitale
sulcus supra orbitalis (su.,rum.)

-Pars orbitalis

foramen ethmoidale – foramina
ethmoidalia (car.)

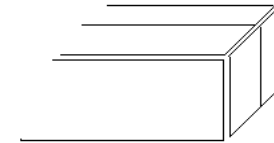
-Pars nasalis

-Pars temporalis

Sinus frontalis
Septum sinuum frontaliu

OS ETHMOIDALE

Lamina perpendicularis (mediana)
crista galli
Lamina cribrosa – fossa ethmoidalis
Lamina tectoria
Lamina basalis
Lamina orbitalis



ethmoturbinale

ectoturbinalia

endoturbinalia

{ Endoturbinale I = Concha nasalis dorsalis
Endoturbinale II = Concha nasalis media }

OS SPHENOIDALE

OS PRESPHENOIDALE

- Ala (orbitalis)

for. ethmoidale
for. opticum
fissura orbitalis
for. rotundum
for. alare orale (for. alare rostrale) (eq.,car.)
for. orbitorotundum (ru.)

- Corpus

sulcus chiasmatis
canalis opticus
sinus sphenoidalis (ru.yok)
rostrum sphenoidale
crista transversa
synchondrosis intersphenoidale

OS BASISPHENOIDALE

-Ala (temporalis)

for.rotundum (car.,eq.)
incisura carotica (car.,eq.)
for. ovale (ru. , car.)
inc. ovalis (su, eq)
for.spinosum (car.)
incisura spinosa (su.,eq.)

-Proc. pterygoideus

canalis alaris (eq , car.)
for.alare caudale

-Corpus

sella turcica
fossa hypophysialis
dorsum sellae



❖ Fossa cranii nasalis

crista transversa

❖ Fossa cranii media

crista sphenoccipitalis

❖ Fossa cranii caudalis

OS TEMPORALE

PARS SQUAMOSA

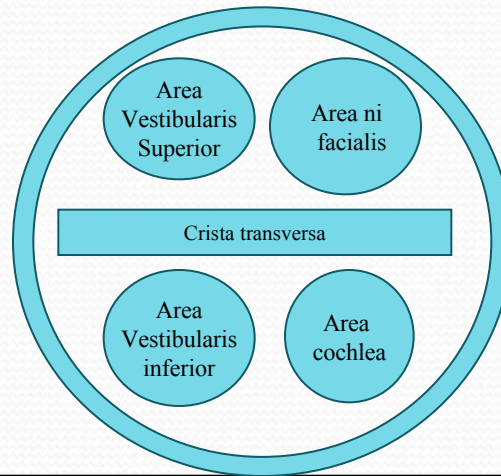
facies temporalis
facies cerebralis
proc. zygomaticus
tuberculum articulare
fossa mandibularis
facies articularis
proc. retroarticularis
for. retroarticulare

PARS PETROSA

facies medialis
porus acusticus internus
meatus acusticus internus
fundus meatus acusticus internus
proc. mastoideus
proc. styloideus (eq.ru.)
for. stylomastoideum

PARS TYMPANICA

bulla tympanica
cavum tympani
porus acusticus externus
meatus acusticus externus
proc. muscularis



(Sol)

VOMER

Crista vomeris
Ala vomeris
Sulcus septalis

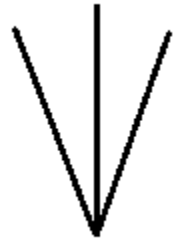
OS PTERYGOIDEUM

Hamulus pterygoideus

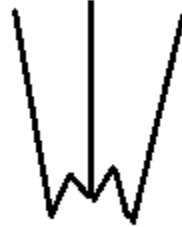CRANIUM VISCERALE (OSSA FACIEI)

OS NASALE

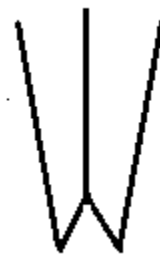
Facies externa
Facies interna
Proc.septalis
Crista ethmoidalis
Processus nasalis
Inc. nasoincisiva



at,koyun



sığır,keçi



köpek

OS LACRIMALE

Facies facialis
Facies orbitalis
Facies nasalis

Margo orbitalis
Fossa sacci lacrimalis
For.lacrimalis
Canalis lacrimalis
Foramina lacrimalia (su.)
Bulla lacrimalis
Fossa lacrimalis externa (ov., su.)

Sinus lacrimalis (ru.,su.)

OS ZYGOMATICUM

Facies lateralis
Facies orbitalis
Processus temporalis
Processus frontalis (ru.)
Crista facialis
Arcus zygomaticus

MAXILLA

Corpus maxillae

Facies facialis
Crista facialis
Tuber faciale
For. infraorbitale
Canalis infraorbitalis
Canalis alveolaris (ru.yok)
Fossa canina (su.)
Juga alveolaria
Facies nasalis
Crista conchalis
Facies orbitalis (car.,eq.)

Sinus maxillaris
Septum sinuum maxillaris (eq.)

Proc.alveolaris

Margo alveolaris
Margo interalveolaris
Alveoli dentales
Tuber maxilla
Fossa pterygopalatina
For. maxillare
For. sphenopalatinum
For. palatinum aborale (caudale)

Sinus maxillaris
Atta oral ve aboral

Proc.palatinus

Sutura palatina mediana
Sulcus palatinus
For.palatinum majus
Canalis palatinus
Crista nasalis

OS INCISIVUM

Corpus ossis incisivi

Facies labialis
Facies palatina
Sutura interincisiva
Foramen incisivum
Canalis inter incisivus
Processus alveolaris
Fissura inter incisiva (ru.)

Processus palatinus

sulcus septi nasi
fissura palatina

Processus nasalis

Incisura nasoincisiva

OS ROSTRALE

Os nasale'nin processus septalis'i ile corpus ossis incisivi arasında yer alır.
(Su.)

OS PALATINUM

-Lamina horizontalis

facies nasalis
facies palatina
margo liber
crista nasalis
crista palatina

For.palatinunum majus (bo.)

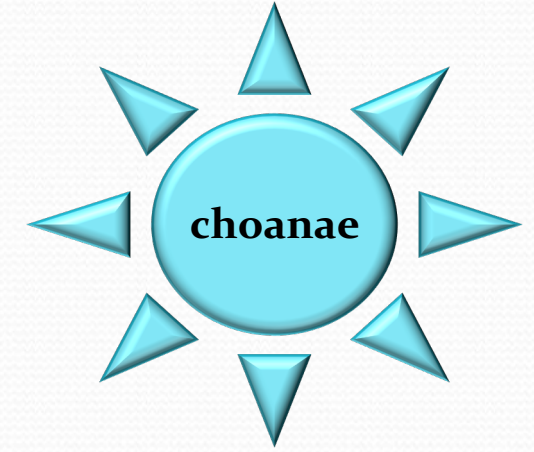
-Lamina perpendicularis

facies nasalis
facies maxillaris

Sinus palatinus

Ru. (lamina horizontalis)

Eq. (lamina perpendicularis)



MANDIBULA

Corpus mandibulae

PARS INCISIVA

Facies labialis
Facies lingualis
Margo alveolaris
Alveoli dentales
Margo interalveolaris
Foramen mentale
Foramina mentalia (car.)

PARS MOLARIS

Margo alveolaris
Margo ventralis
Facies buccalis
Facies lingualis
Inc. vasorum facialium

Symphysis intermandibularis
Angulus mentalis
Spatium mandibulare
Articulatio temporomandibularis

Ramus mandibulae

Angulus mandibulae
Processus angularis (ca.)
Fossa masseterica
Fossa pterygoidea
Foramen mandibulae
Canalis mandibulae
Processus muscularis (proc. coronoideus)
Processus articularis (proc. condylaris)
Caput mandibulae
Collum mandibulae
Incisura mandibulae

OS HYOIDEUM

❖ Basihyoideum

Proc. lingualis (ru.,eq.)

❖ Thyreohyoideum (cornu majus)

❖ Ceratohyoideum (cornu minus)

Epihyoideum

Stylohyoideum

Tympanohyoideum

