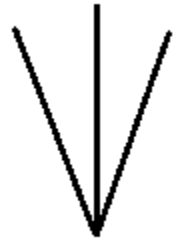


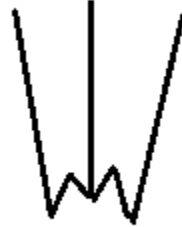CRANIUM VISCERALE (OSSA FACIEI)

OS NASALE

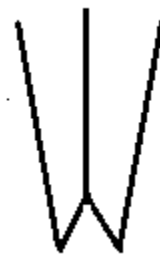
Facies externa
Facies interna
Proc.septalis
Crista ethmoidalis
Processus nasalis
Inc. nasoincisiva



at,koyun



sığır,keçi



köpek

OS LACRIMALE

Facies facialis
Facies orbitalis
Facies nasalis

Margo orbitalis
Fossa sacci lacrimalis
For.lacrimalis
Canalis lacrimalis
Foramina lacrimalia (su.)
Bulla lacrimalis
Fossa lacrimalis externa (ov., su.)

Sinus lacrimalis (ru.,su.)

OS ZYGOMATICUM

Facies lateralis
Facies orbitalis
Processus temporalis
Processus frontalis (ru.)
Crista facialis
Arcus zygomaticus

MAXILLA

Corpus maxillae

Facies facialis
Crista facialis
Tuber faciale
For. infraorbitale
Canalis infraorbitalis
Canalis alveolaris (ru.yok)
Fossa canina (su.)
Juga alveolaria
Facies nasalis
Crista conchalis
Facies orbitalis (car.,eq.)

Sinus maxillaris
Septum sinuum maxillaris (eq.)

Proc.alveolaris

Margo alveolaris
Margo interalveolaris
Alveoli dentales
Tuber maxilla
Fossa pterygopalatina
For. maxillare
For. sphenopalatinum
For. palatinum aborale (caudale)

Sinus maxillaris
Atta oral ve aboral

Proc.palatinus

Sutura palatina mediana
Sulcus palatinus
For.palatinum majus
Canalis palatinus
Crista nasalis

OS INCISIVUM

Corpus ossis incisivi

Facies labialis
Facies palatina
Sutura interincisiva
Foramen incisivum
Canalis inter incisivus
Processus alveolaris
Fissura inter incisiva (ru.)

Processus palatinus

sulcus septi nasi
fissura palatina

Processus nasalis

Incisura nasoincisiva

OS ROSTRALE

Os nasale'nin processus septalis'i ile corpus ossis incisivi arasında yer alır.
(Su.)

OS PALATINUM

-Lamina horizontalis

facies nasalis
facies palatina
margo liber
crista nasalis
crista palatina

For.palatinum majus (bo.)

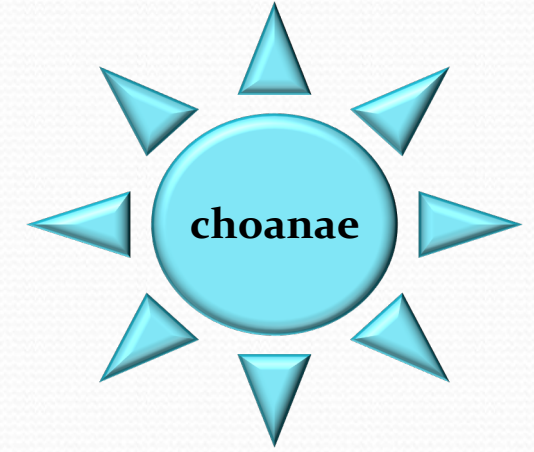
-Lamina perpendicularis

facies nasalis
facies maxillaris

Sinus palatinus

Ru. (lamina horizontalis)

Eq. (lamina perpendicularis)



MANDIBULA

Corpus mandibulae

PARS INCISIVA

Facies labialis
Facies lingualis
Margo alveolaris
Alveoli dentales
Margo interalveolaris
Foramen mentale
Foramina mentalia (car.)

PARS MOLARIS

Margo alveolaris
Margo ventralis
Facies buccalis
Facies lingualis
Inc. vasorum facialium

Symphysis intermandibularis
Angulus mentalis
Spatium mandibulare
Articulatio temporomandibularis

Ramus mandibulae

Angulus mandibulae
Processus angularis (ca.)
Fossa masseterica
Fossa pterygoidea
Foramen mandibulae
Canalis mandibulae
Processus muscularis (proc. coronoideus)
Processus articularis (proc. condylaris)
Caput mandibulae
Collum mandibulae
Incisura mandibulae

OS HYOIDEUM

❖ Basihyoideum

Proc. lingualis (ru.,eq.)

❖ Thyreohyoideum (cornu majus)

❖ Ceratohyoideum (cornu minus)

Epihyoideum

Stylohyoideum

Tympanohyoideum

