

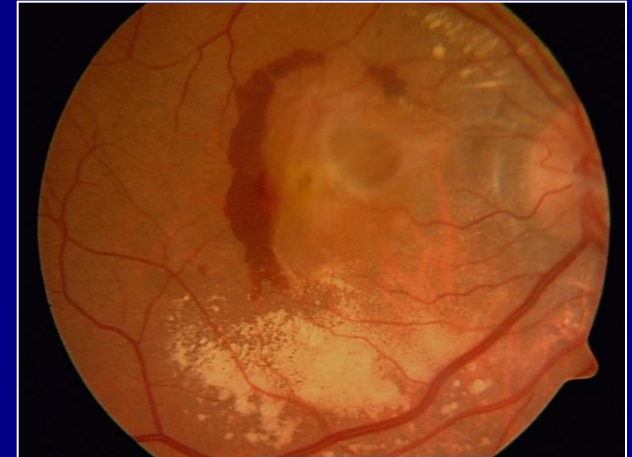

KURU TİP YBMD: TANI VE TAKİP

Prof. Dr. Emin ÖZMERT
AÜTF Göz Hastalıkları ABD
Vehbi Koç Göz Hastanesi
Ankara - 2015

Yaşa Bağlı Maküla Dejenerasyonu

- 60 yaş üzeri legal körlüklerin en önemli nedeni
- Genel prevalansı: % 0.2 – 3.2
- Neovasküler ARMD prevalansı: % 0.2 – 1.2
- Görme kaybı % 80-90 KNV sonucu

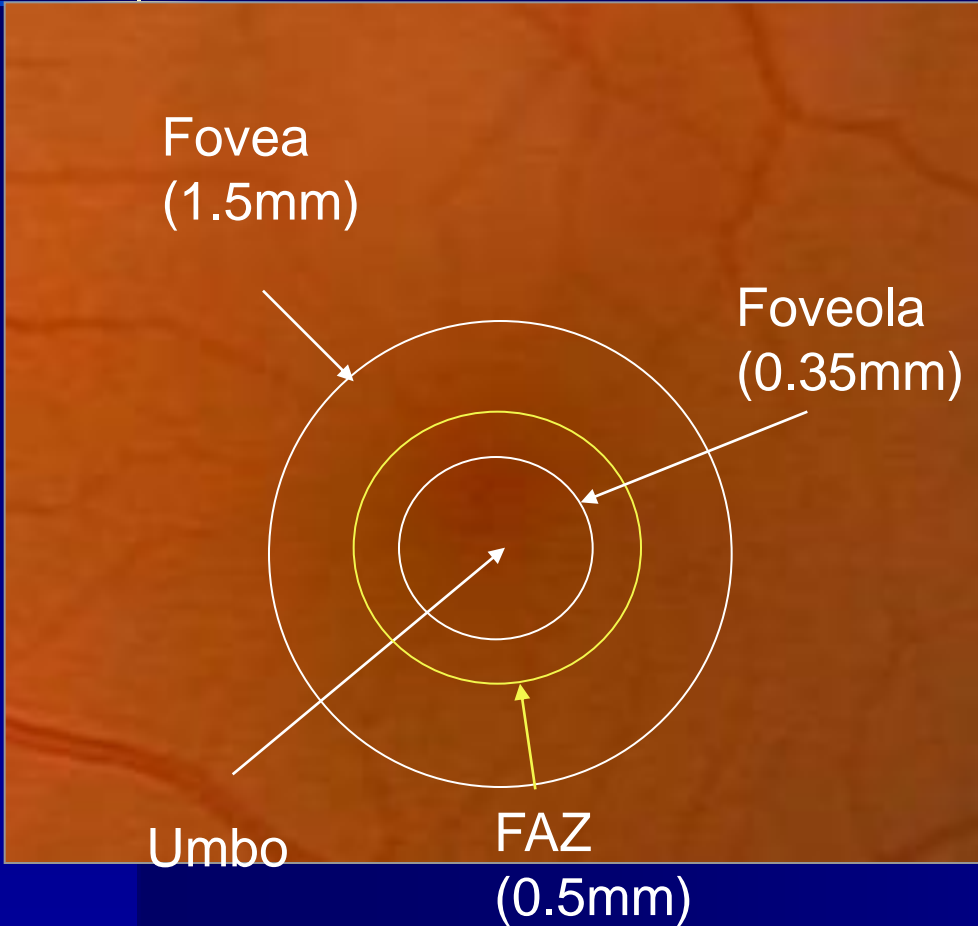


Yaşa Bağlı Maküla Dejenerasyonu

- Hastanın hissettiği yetersizlik, doktorun tahmininden % 96 – 750 defa daha fazladır
- Ciddi maküla etkilenmesinin verdiği sıkıntı; ileri prostat kanseri veya ciddi felç ile aynı
- Bağımsızlığın kaybı
- Depresyon (1 / 3 hastada)
- Kalça kırıkları
- Ekonomik kayıp
- **Erken tanı, erken ve etkin tedavi önemli**

Topografik Anatomi

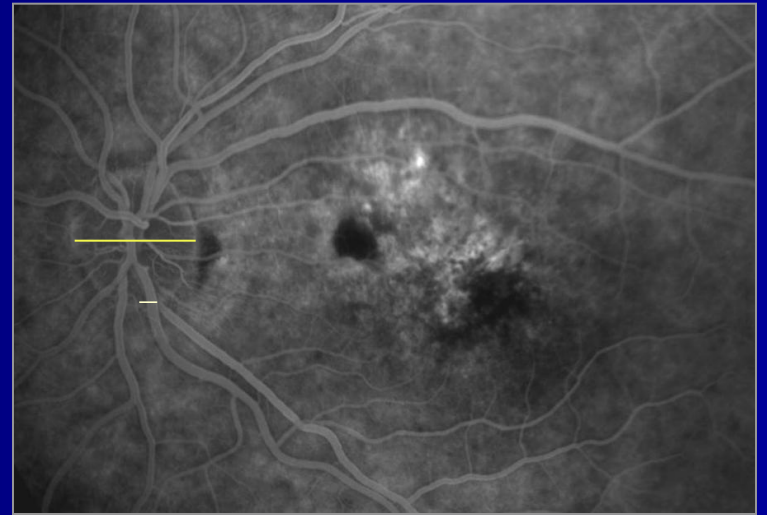
Fovea: Makulanın merkezinde, iç retinal yüzeydeki çukurluk



- **Foveola:**
 - * Fovea ve makulanın merkezi
 - * Kon ve Müller hücresi
- **Umbo:**
 - * Foveola ve tüm area santralisin merkezi
 - * İnce bir bazal lamina, Müller hücresi ve konlar
 - * 0.13 mm kalınlıkta










Büyükklük / Referans ölçüm

- Optik disk çapı
(1.77 ± 0.33 mm)
- Optik disk sınırındaki
ven çapı
(0.149 ± 0.026 mm)



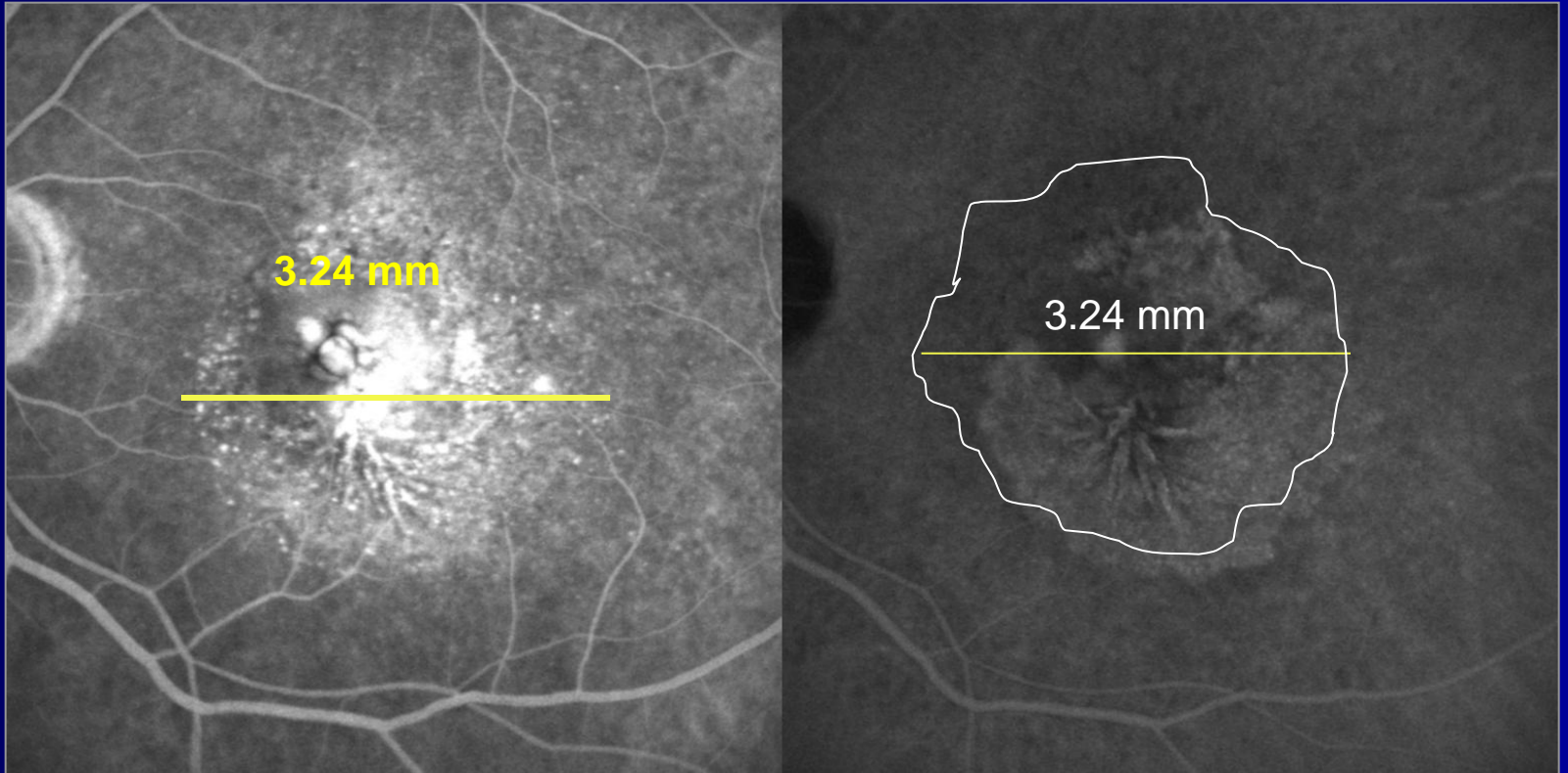
Jonas JB. Klin Monatsbl Augenheilkd 1988;192:325-8

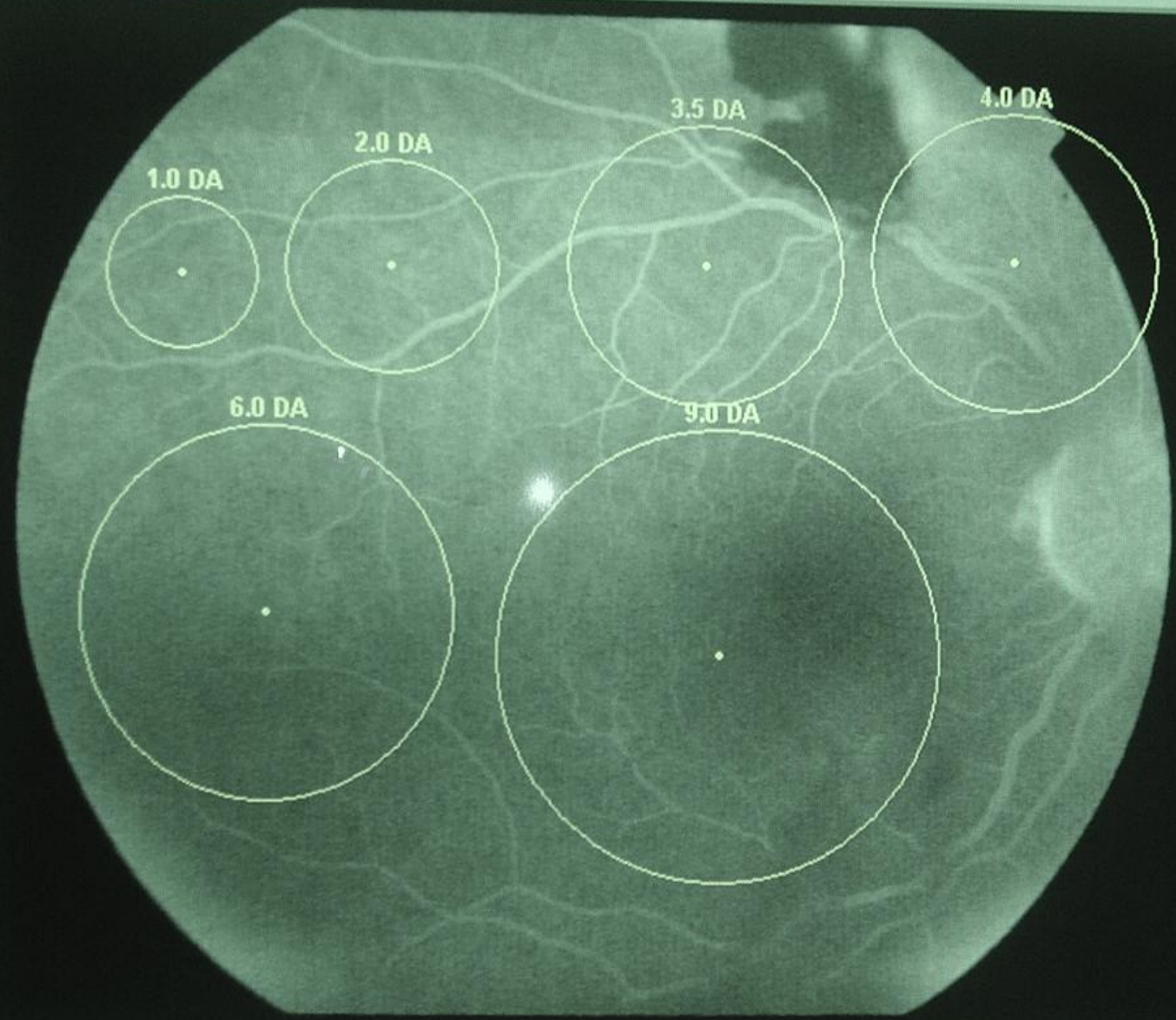
Büyükük / MPS Disk Alanları

					1 DA	1.77 mm ²
1	2	3	3.5	4	2 DA	3.5 mm ²
					3.5 DA	6.2 mm ²
					4 DA	7.1 mm ²
6	9	12	16		6 DA	10.6 mm ²

Disk alanlarını içeren saydam asetat, 30 derecede çekilmiş 35mm'lik fundus fotoğrafı üzerine yerleştirilerek lezyon büyüklüğü belirlenir

Büyüklik / Dijital Sistem





AREA
MPS DA
PDT



Change Circle Size

9.0 DA

PDT Additional Area

0.5 mm
 Add to GLD
 Add to Area

5 17:03

Hemodinamik Teori: Koroid dolaşımı

- Anjiyografide koroid dolum gecikmesi
- Artmış skleral rijidite
- Serebrovasküler direnç (SVD)

Koroid direnç artışı > SVD



Koroid kan dolaşımı azalır




Drusen, RPE atrofisi, Bruch kalınlaşması

Koroid direnç artışı < SVD

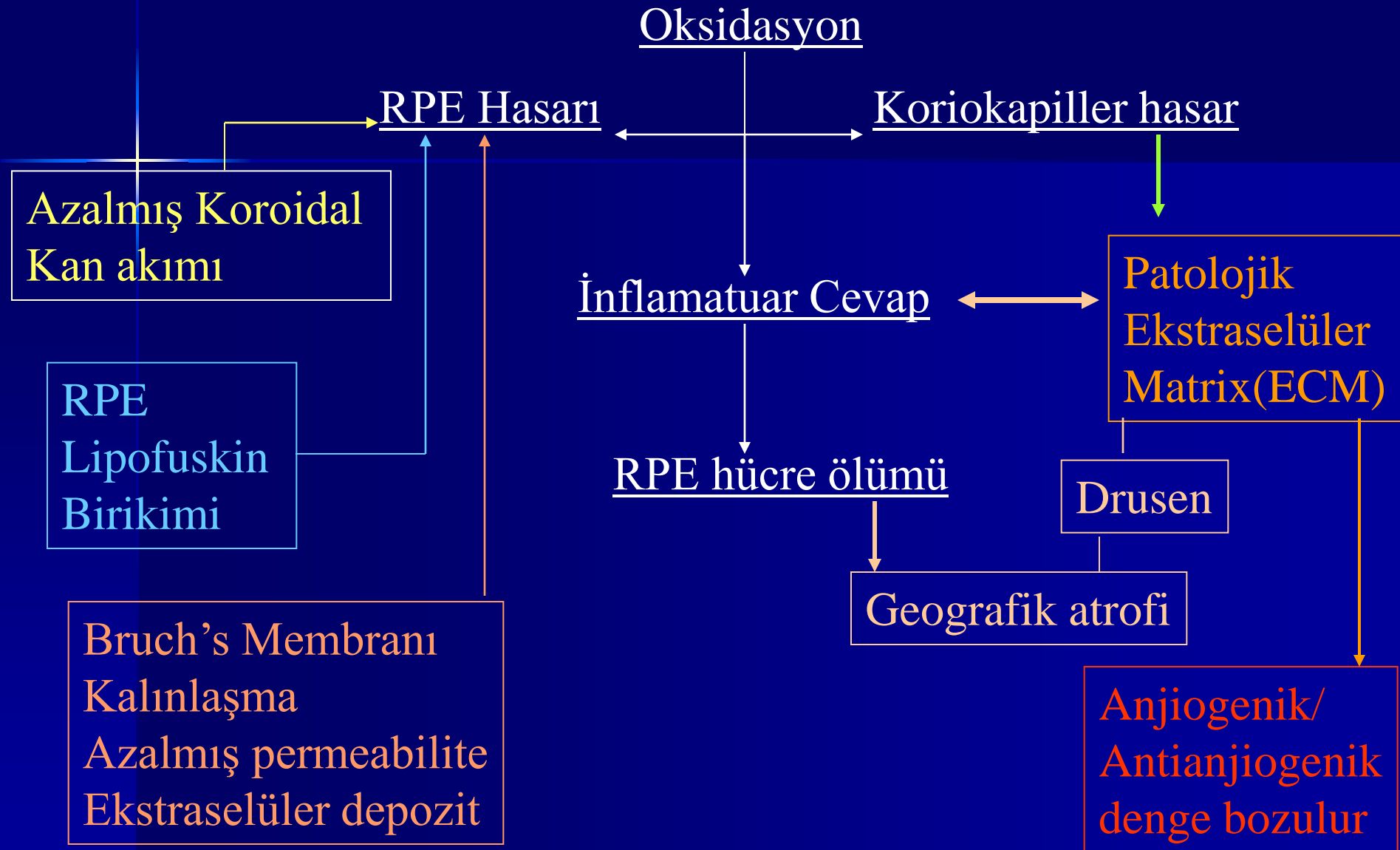


**Koroid perfüzyonu artması
Yüksek koriokapiller basınç**



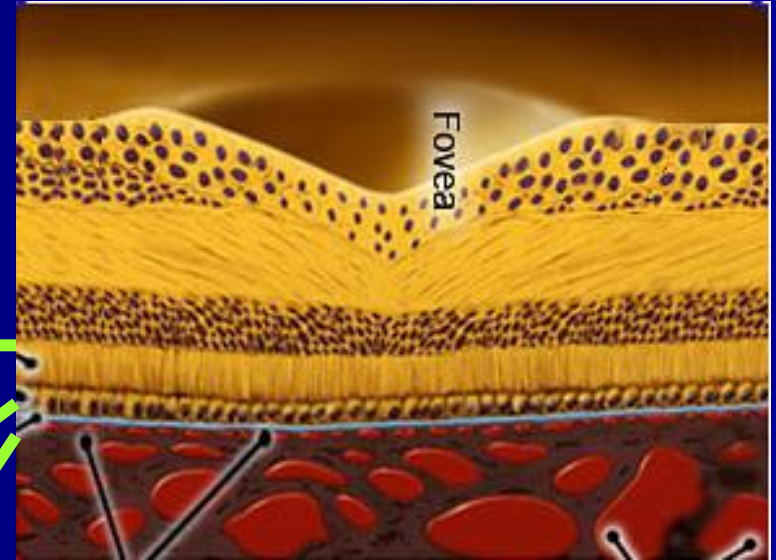
RPE dekolmanı, KNV

Yaş, Genetik, Çevresel faktörler



YBMD / Etyopatogenez

Koriokapillaris
Retina Pigment Epiteli
Bruch' s Membranı



Rod ve konlar

Retina Pigment Epiteli

Bruch' s membranı

Koriokapillaris

Fotoreseptör Kaybı

SINIFLAMA

Uluslararası Sınıflama

*International ARM Epidemiological Study Group,
1995*

Erken Yaşa Bağlı Maküla Dejenerasyonu

- Yumuşak drusen
- Drusen + hiperpigmente alanlar
- Drusen + hipopigmente alanlar

Geç Yaşa Bağlı Maküla Dejenerasyonu

- **Kuru YBMD** (veya geografik atrofi)
En az 175 μ çaplı atrofi alanı
- **Yaş YBMD** (neovasküler, dissiform veya eksudatif)

AREDS Sınıflama sistemi

AREDS Research Group, Report No : 6, 2001

YBMD düzeyi

Kriterler

1

Drusen $< 63\mu$

Drusen toplam alanı $< 125\mu$

2

* $63 \mu < \text{Drusen} < 125 \mu$

* Drusen toplam alanı $\geq 125 \mu$

* RPE pigment anormallikleri:

- Depigmentasyon

- Artmış pigment $\geq 125 \mu$

- Artmış pigment ve depigmentasyon

AREDS Sınıflama sistemi

AREDS Research Group, Report No : 6, 2001

YBMD düzeyi

Kriterler

3

- * Drusen maks $\geq 125\mu$
- * Drusen maks $\geq 63\mu$, TA $> 125 \mu$, yumuşak?
- * Drusen maks $\geq 63\mu$, TA $> 125 \mu$, yumuşak
- * Geografik atrofi (santralde değil)

4

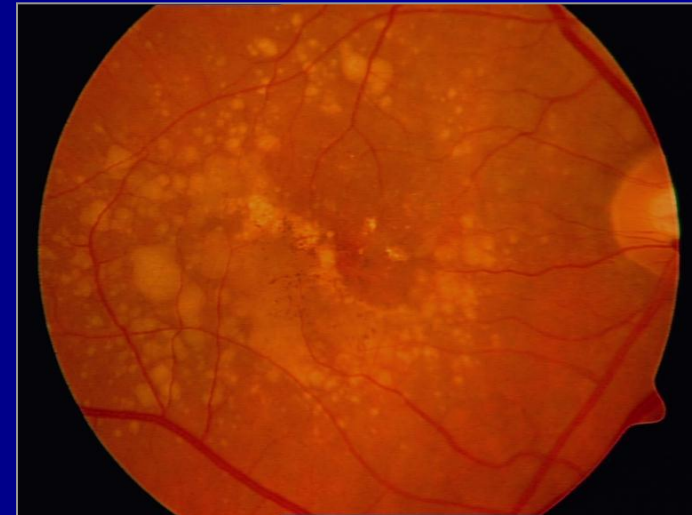
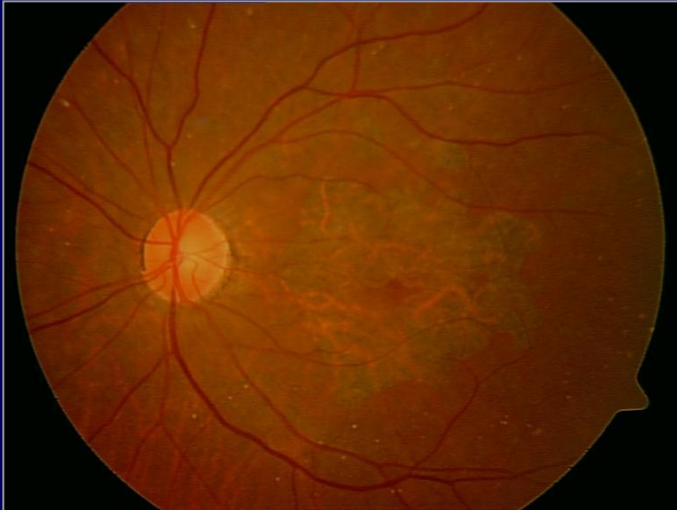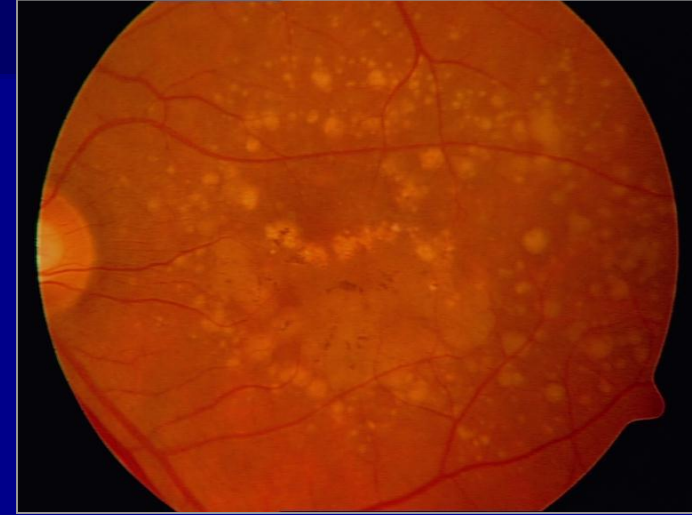
- * Geografik atrofi (santral)
- * Neovasküler YBMD
 - Fibrovasküler/seröz PED
 - Retina / RPE altı kanama
 - Retina altı fibröz doku

RISK FAKTÖRLERİ

Erken YBM → Ge YBM

Risk faktörleri:

- * Büyük drusen ($> 125 \mu$)
- * Toplam drusen alanı
- * Hiperpigmentasyon
- * Hipopigmentasyon
- * Bilateral tutulum
- * Sistemik hipertansiyon ($>160 / 95$ mmHg)
- * Yüksek risk grubunda katarakt cerrahisi
- * Geografik atrofi



Risk Faktörleri

AREDS :

- 1 veya fazla sayıda büyük drusen
- Pigmenter değişiklikler
- Diğer gözde KNV
- Her iki gözde orta büyüklükte drusen

} KNV

5 yılda

0 faktör - % 0,5
1 faktör - % 3
2 faktör - % 12
3 faktör - % 25
4 faktör - % 50

10 yılda

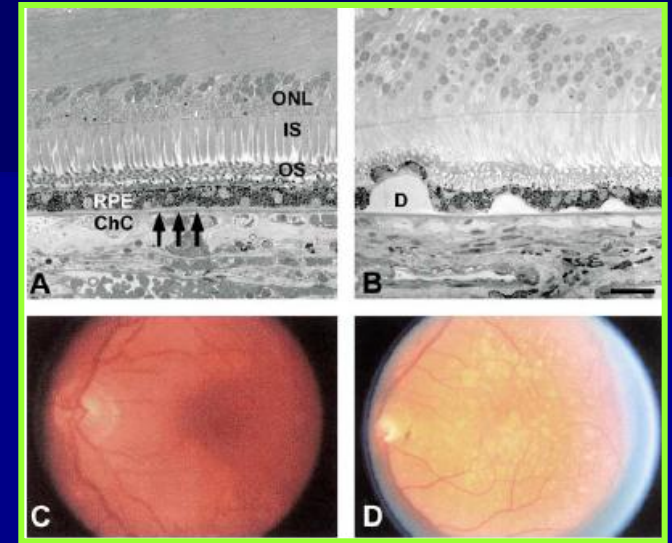
0 faktör - % 1
1 faktör - % 7
2 faktör - % 22
3 faktör - % 50
4 faktör - % 67

Risk Faktörleri

Drusen:

Küçük drusen: $< 65 \mu\text{m}$

Büyük drusen: $>125 \mu\text{m}$



İyi görme keskinliği + iki gözde drusen: % 8 KNV / 3 yıl

5 veya daha fazla drusen

Fokal RPE değişiklikleri

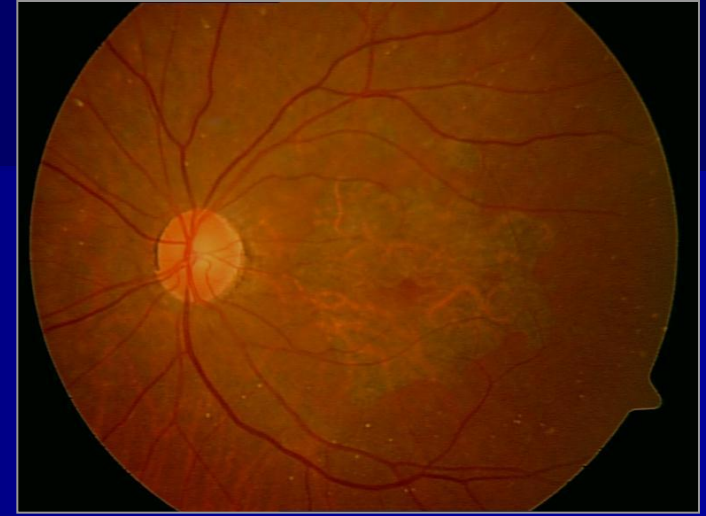
1 veya daha fazla büyük drusen

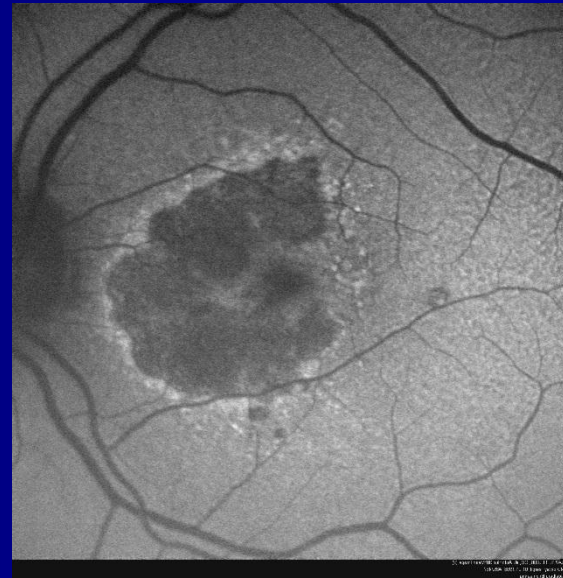
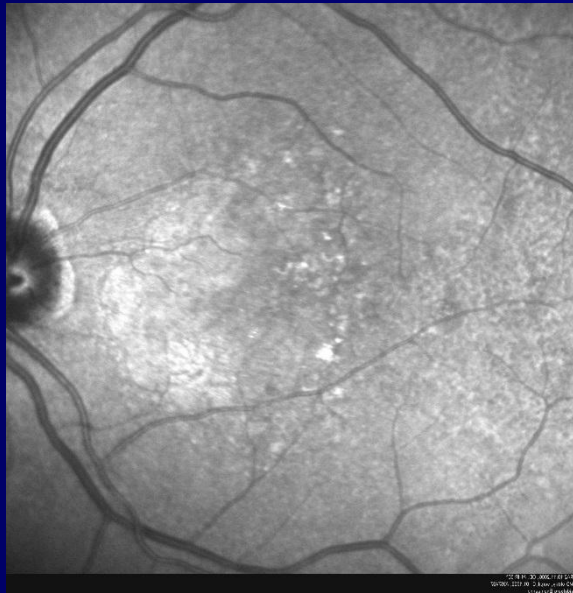
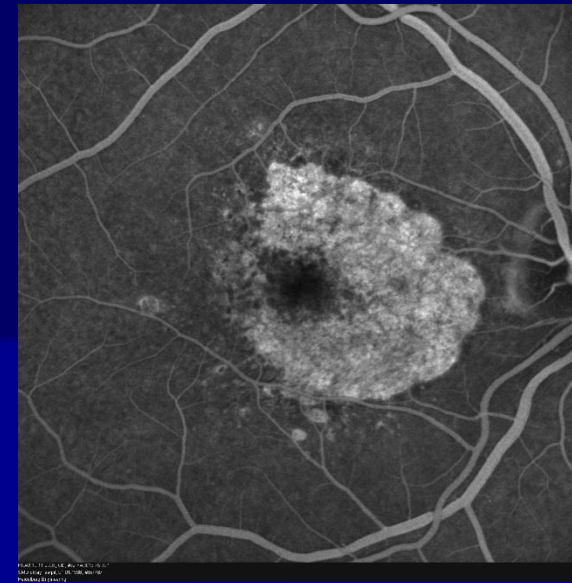
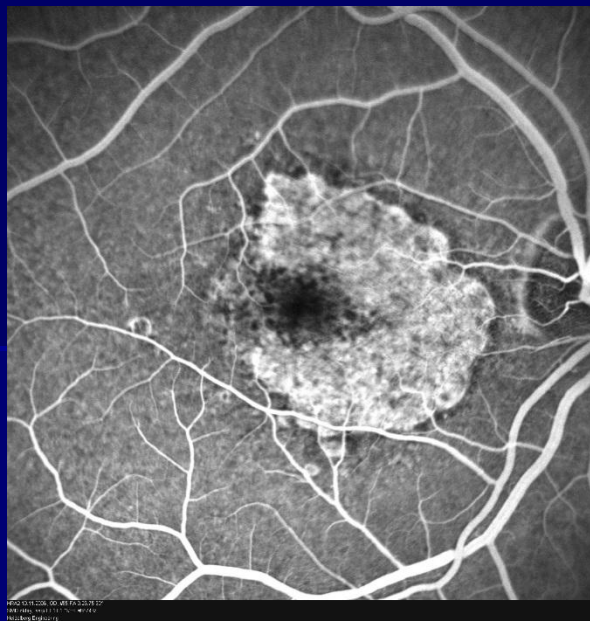
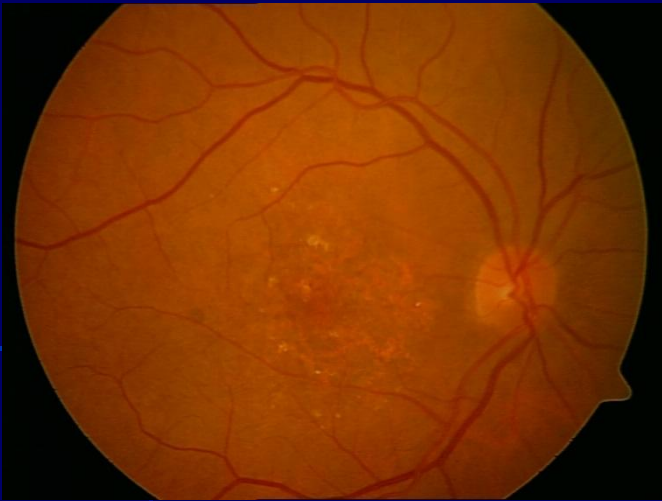} KNV %35 /5 yıl

Risk Faktörleri

Geografik Atrofi :

- % 50 bilateral
 - RPE dekolmanı yatışması,
 - KNV sonrası gelişebilir.
- KNV : sağlam RPE komşuluğunda yada korunmuş foveal alandan gelişir
 - Bilateral geografik atrofi : % 2-4 KNV / 2 yıl
 - Bir göz KNVM - diğeri geografik atrofi: % 30-50 KNV / 5 yıl





GEOGRAFİK ATROFİ

YBMD-Katarakt Cerrahisi

Ophthalmic Surg Laser Imaging -2006;37(1):20

Yüksek riskli Grup :Diğer gözde Neovasküler YBMD bağlı skar
Katarakt Cerrahisi:

Ekstrakapsüler Cerrahi

Nd:Yag Kapsülotomi

Komplikasyonlu cerrahi

Intraoküler Lens tipi



Enflamasyon-angiogenezis

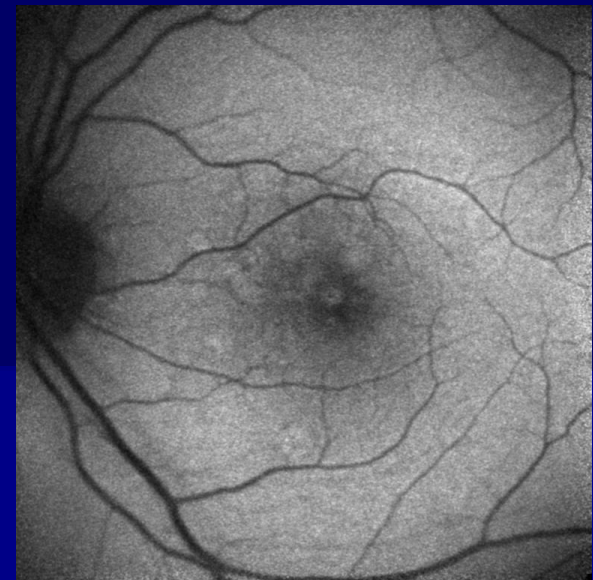
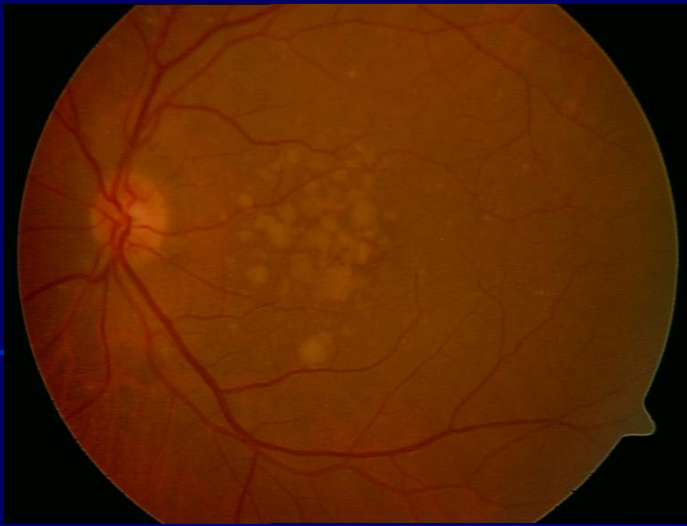
KMÖ

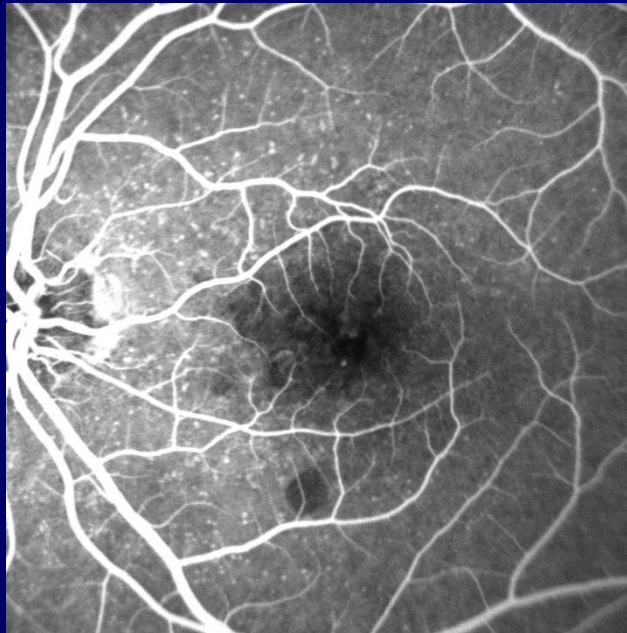
Mavi ışık bloke eden İOL

Cerrahi ile **düşük -orta risk**
grubunda neovaskülerizasyon
riski artmaz

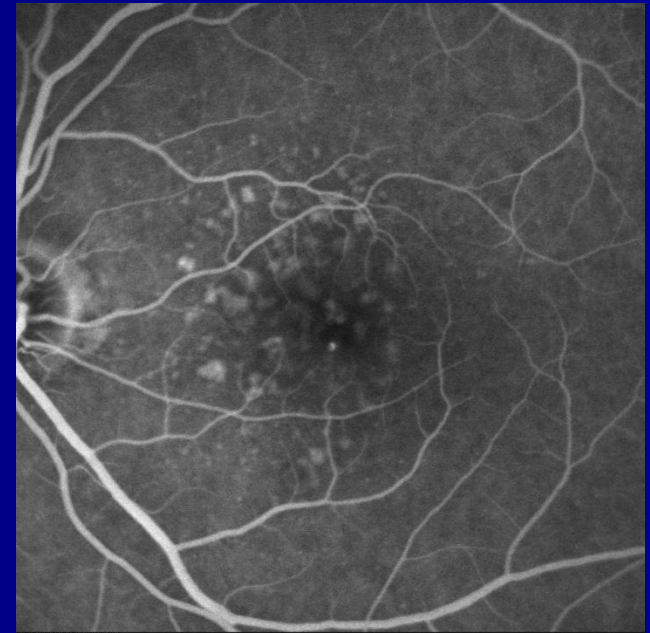
DRUSEN TİPLERİ



HR20 25.04.2007, OS, #4 AutoFluor 307 Mean Image (9)
oztekin, müzeyyen_01.01.1933, #222690
Heidelberg Engineering

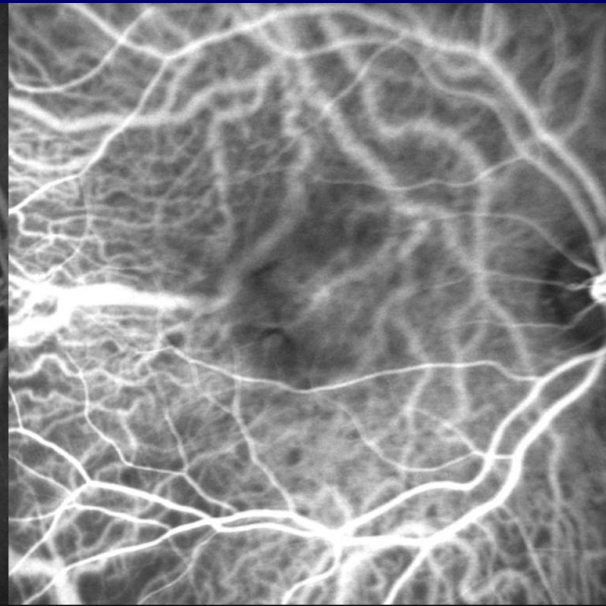
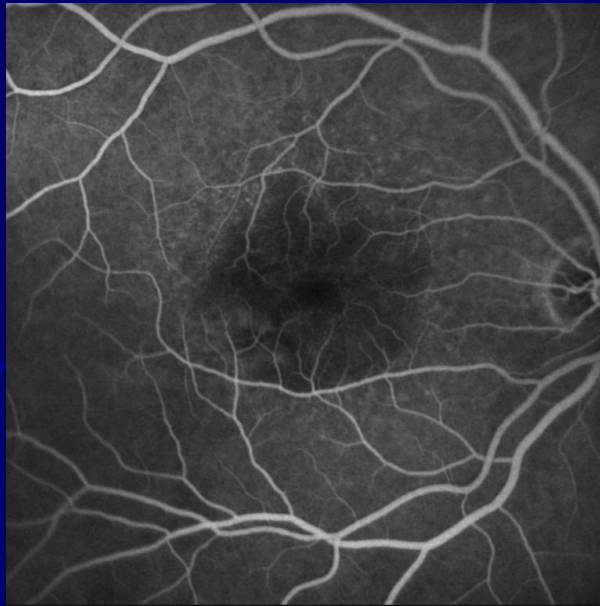

HR20 25.04.2007, OS, #4 F12.2.0.01
oztekin, müzeyyen_01.01.1933, #222690
Heidelberg Engineering



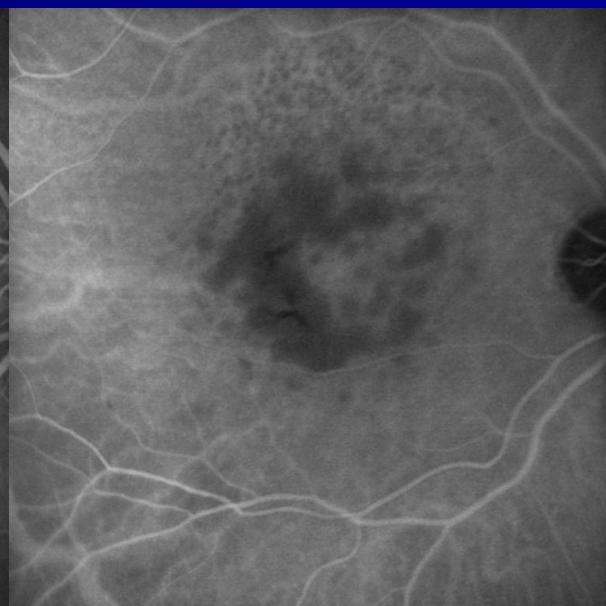
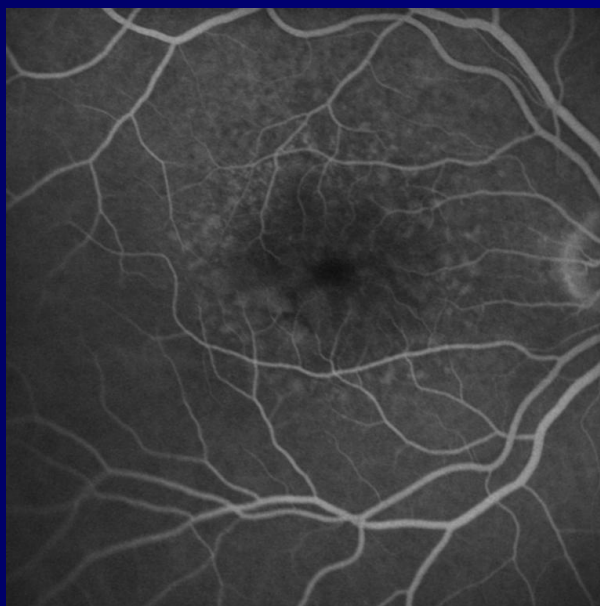HR20 25.04.2007, OS, #4 F12.2.0.01
oztekin, müzeyyen_01.01.1933, #222690
Heidelberg Engineering

YUMUŞAK DRUSEN



ERKEN

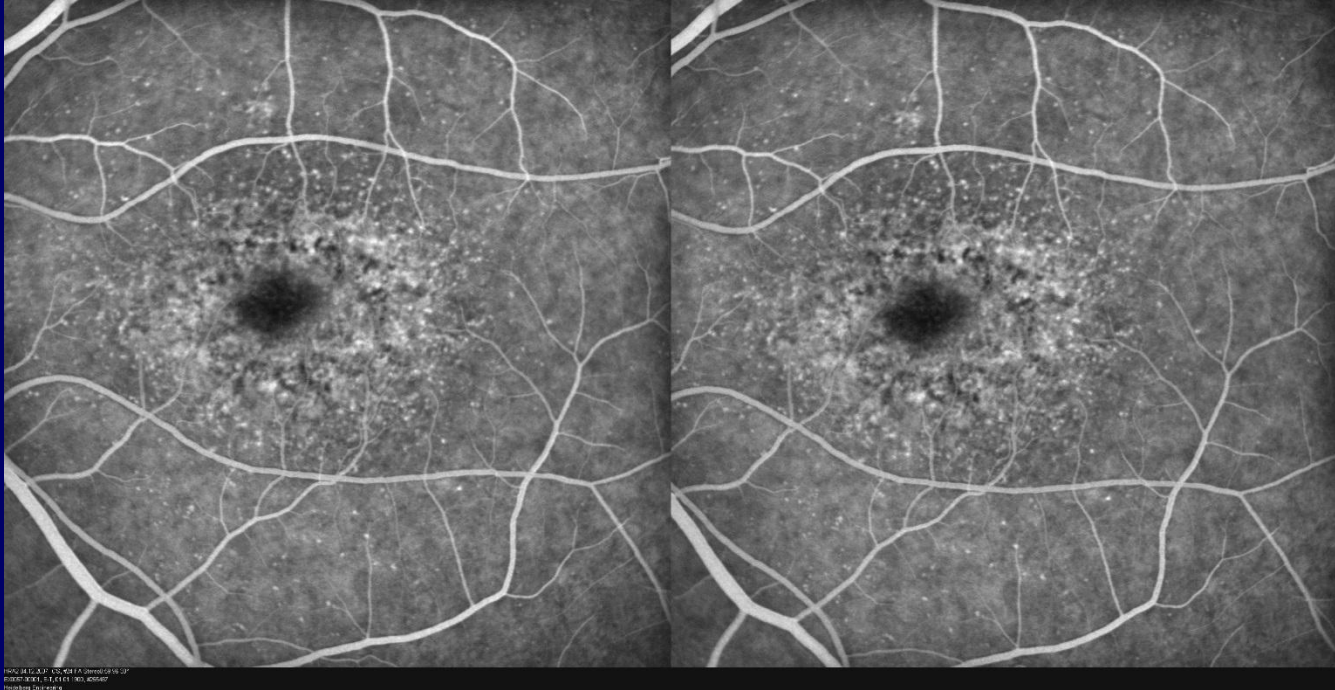
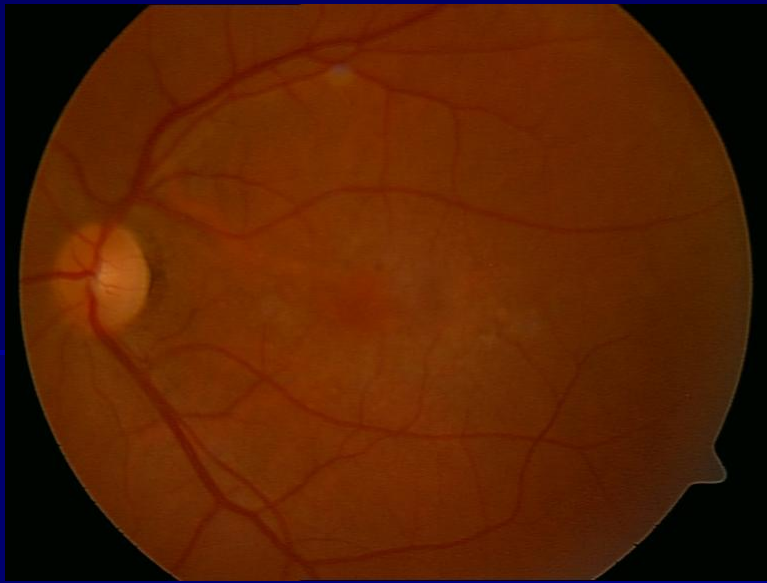
HRA2 03.10.2006, OD, #219 FA&ICGA 1:36:14 30" 1:36:10 30"
Sevim, Nurten, 01.01.1950, #015538
Heidelberg Engineering



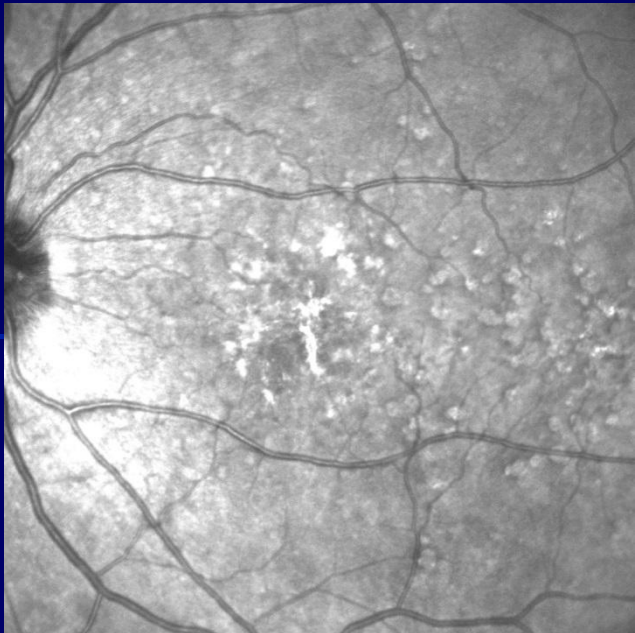
GEÇ

HRA2 03.10.2006, OD, #259 FA&ICGA 15:30:43 30" 15:30:40 30"
Sevim, Nurten, 01.01.1950, #015538
Heidelberg Engineering

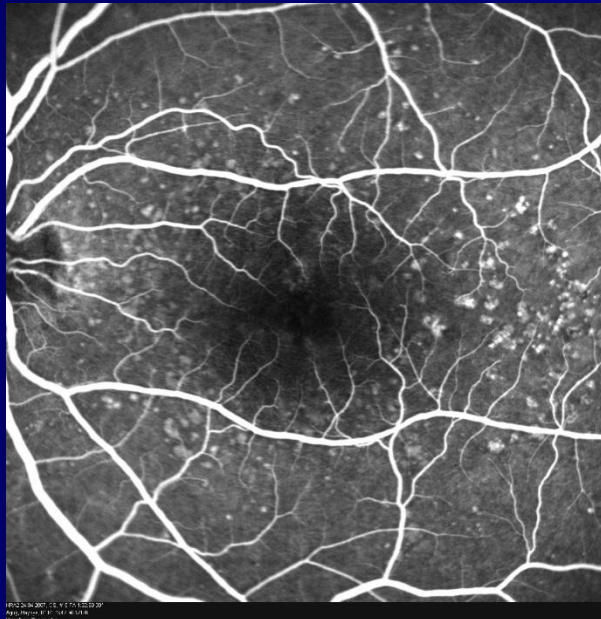
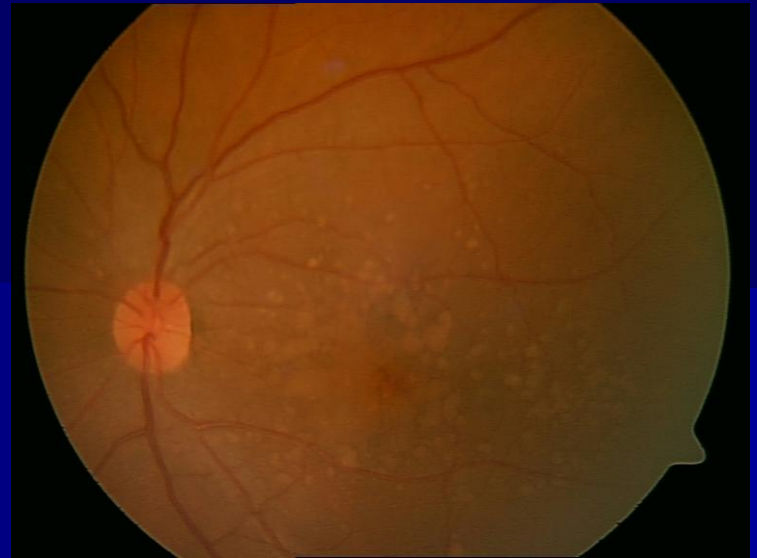YUMUŞAK DRUSEN / FFA + ICG



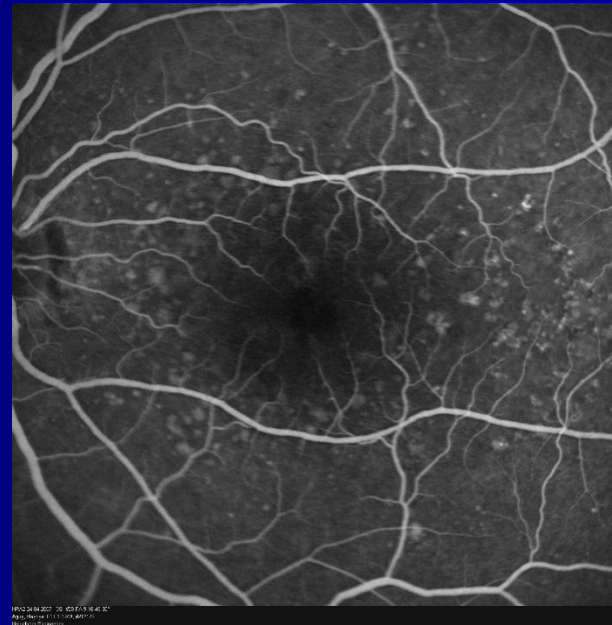
DRUSEN + RPE DEĞİŞİKLİKLERİ (stereoskopik)



HPD 2011 007 05 01 01 07
Apto. HMI/CS, U.F. de São Carlos
Heliópolis, São Carlos



HPD 2011 007 05 01 01 01 07
Apto. HMI/CS, U.F. de São Carlos
Heliópolis, São Carlos

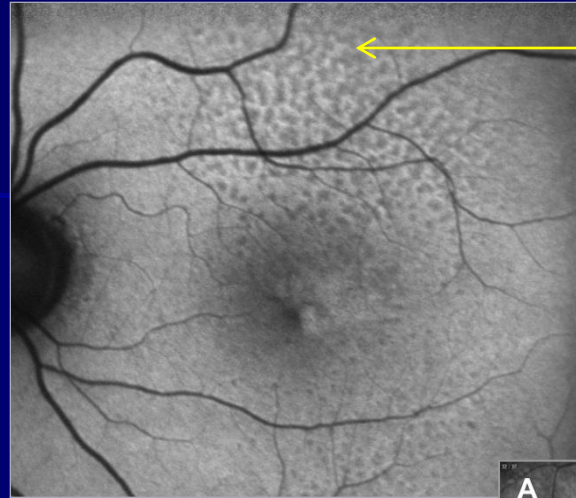
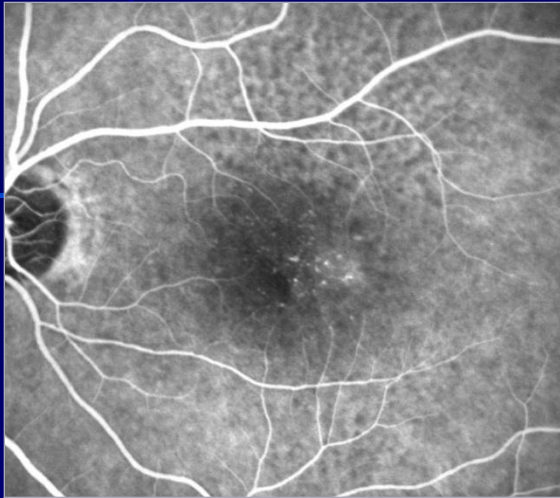


HPD 2011 007 05 01 01 01 07
Apto. HMI/CS, U.F. de São Carlos
Heliópolis, São Carlos

MIKS TIP DRUSEN

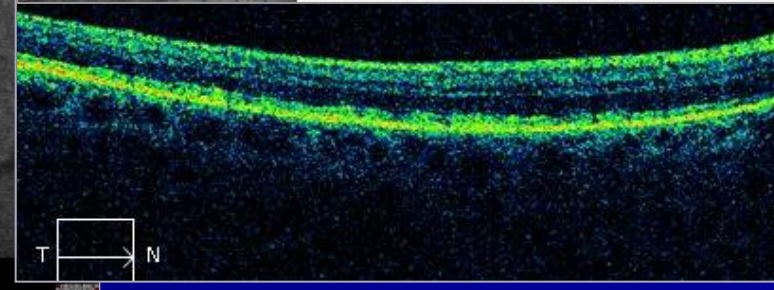
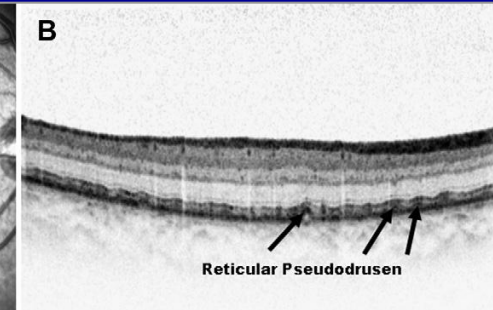
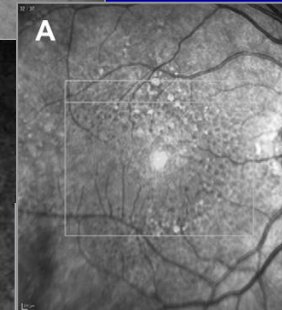
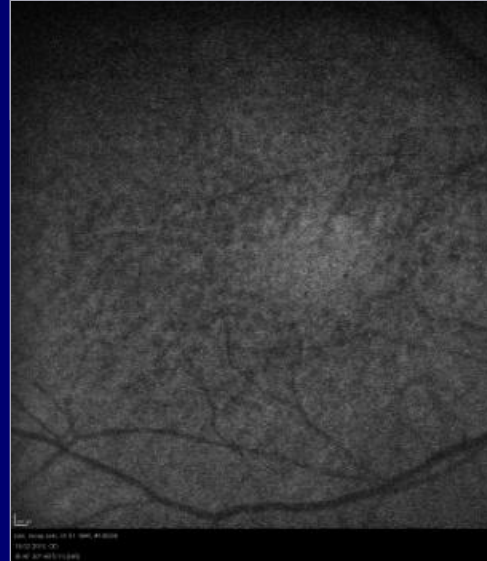
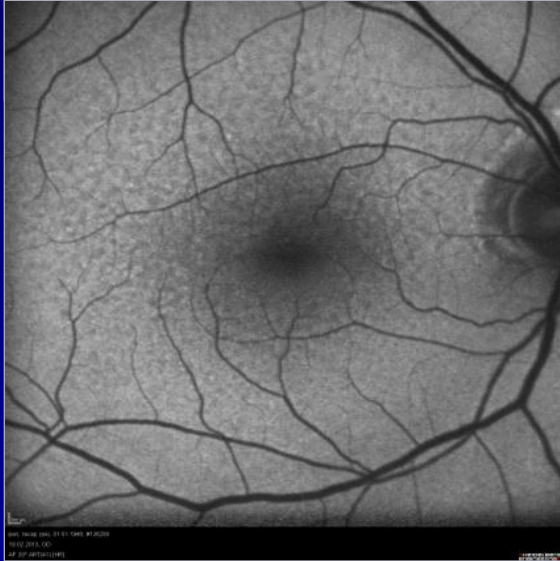HYPO FLUORESCENT DRUSENS

(Pseudo reticular drusen)



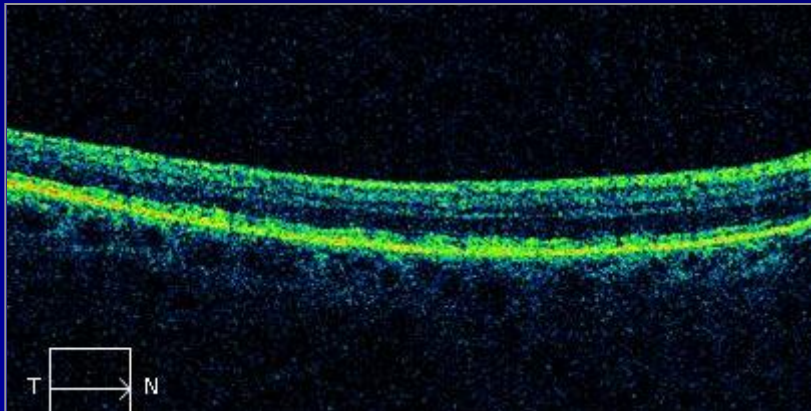
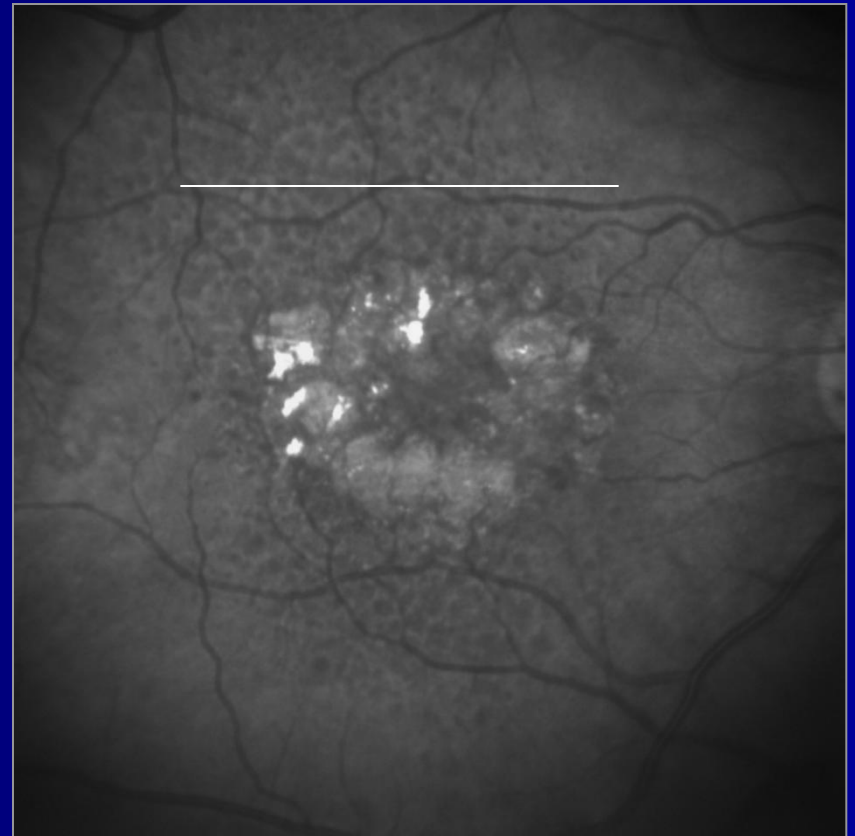
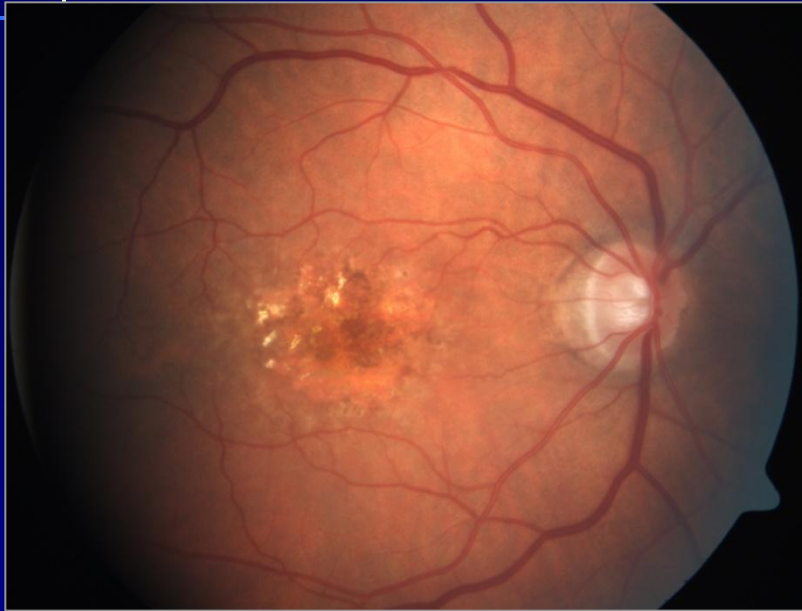
Hypofl spots in superotemporal and macular location

Thin choriocapillaris + fibrosis

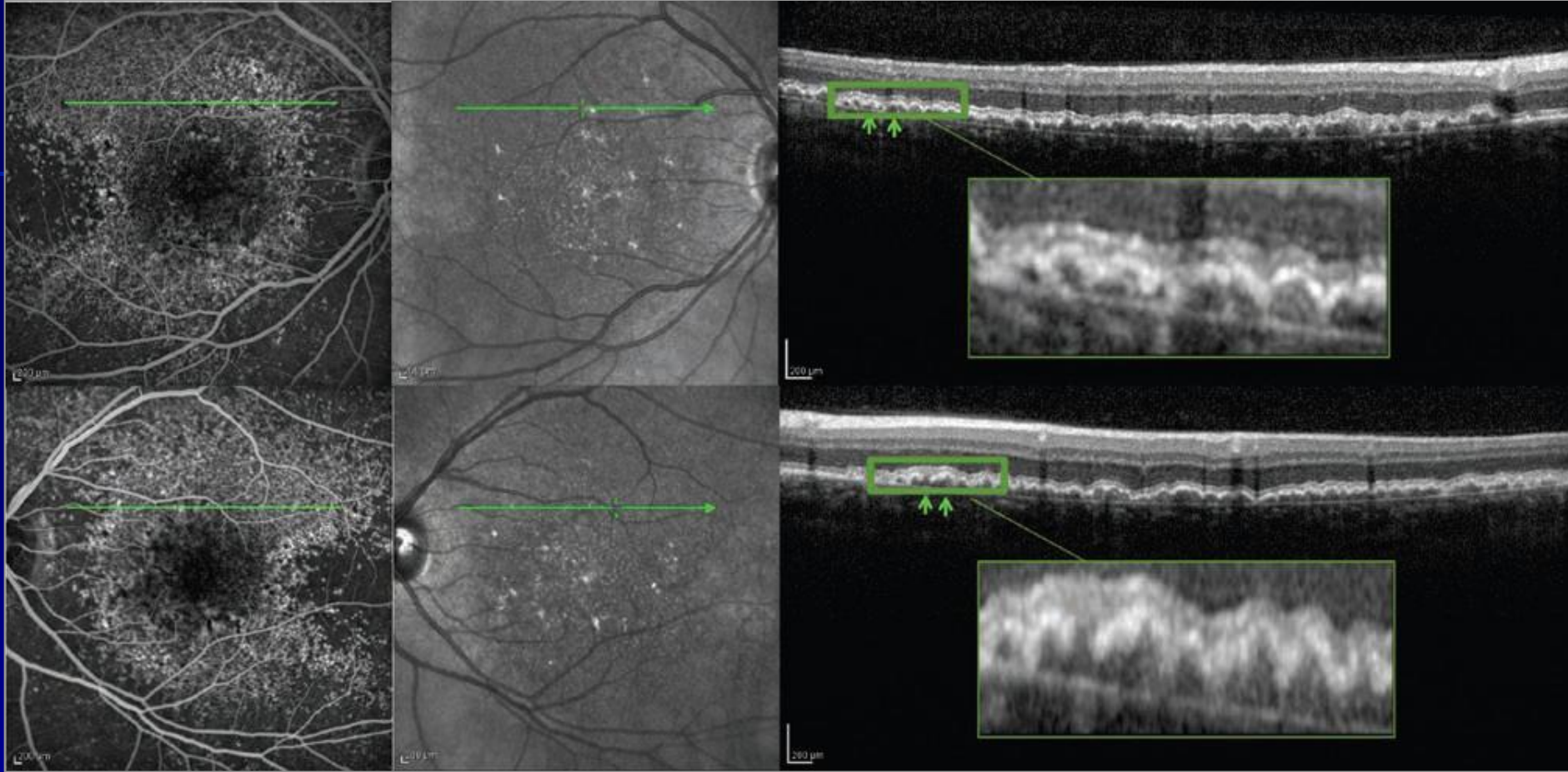


Reticular = pseudodrusen: deposits between RPE and IS / OS (subretinal)
High risk factor for development of wet - AMD

Reticular pseudodrusen

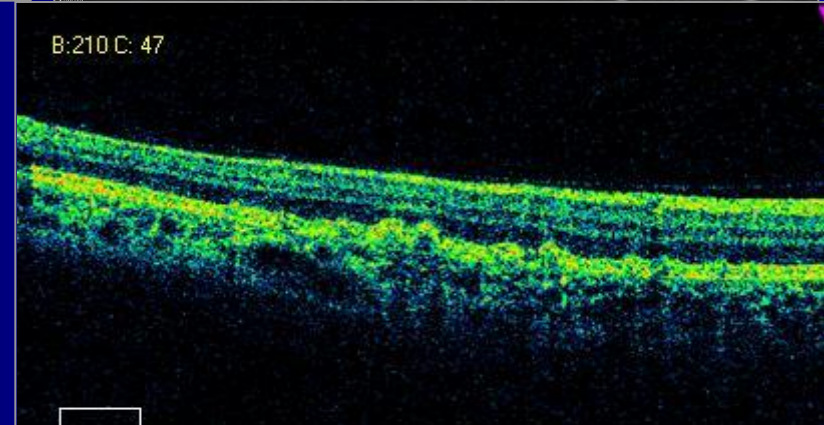
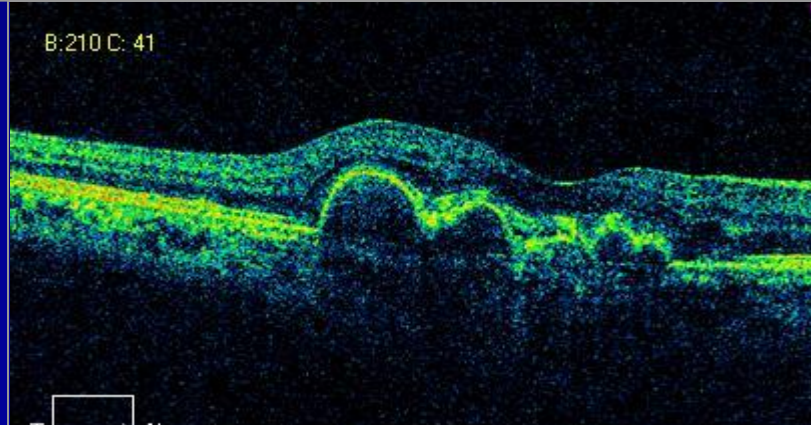
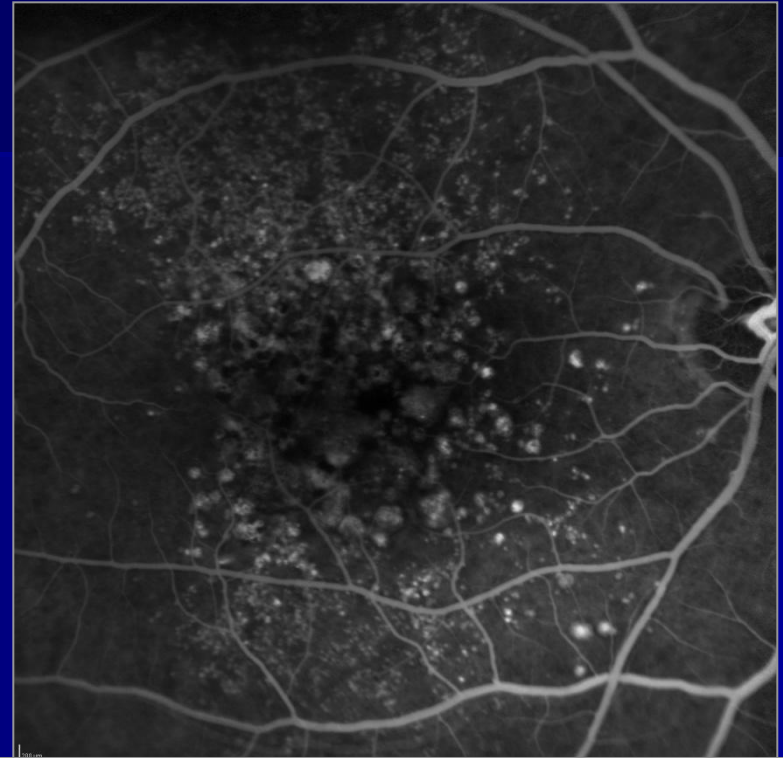
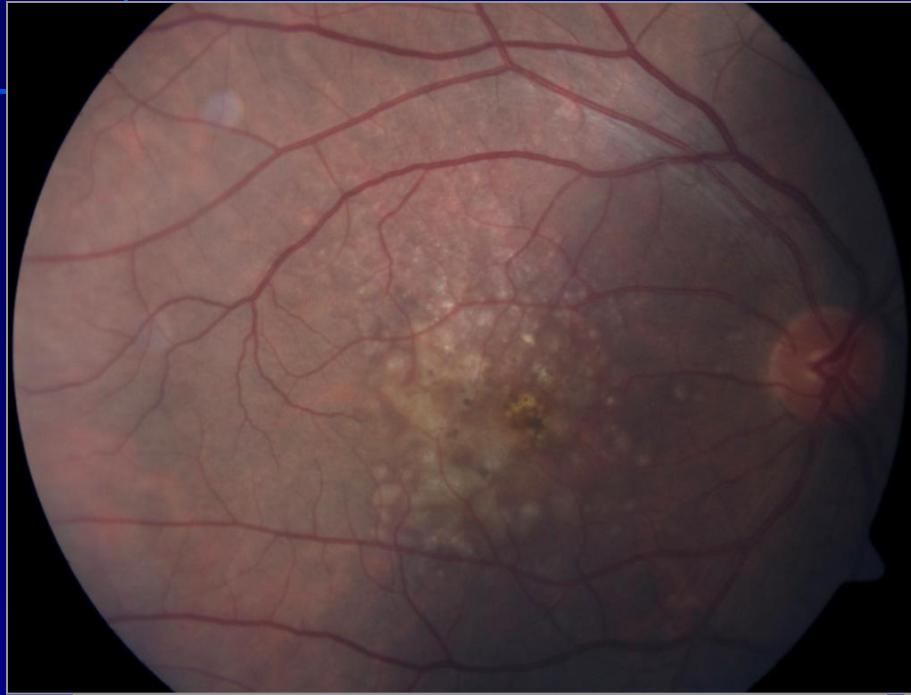


Bazal laminer drusen



RPE bazal membranında (sub-RPE) çok sayıda, küçük, yuvarlak, sarı birikintiler
FFA: erken hiperflöresans noktalar (yıldızlı açık gök yüzü)
OCT: RPE' de testere dişi gibi kabarıklıklar, ELM / IS OS hasarı

Basal laminar drusen



Tanı & takip yöntemleri

- Amsler- Grid
- Log – MAR görme keskinliği
- Kontrast duyarlılık
- Mikroperimetri
- Multifokal ERG
- SLO / Spektral OCT
- Fundus Otoflöresans

Amsler Grid

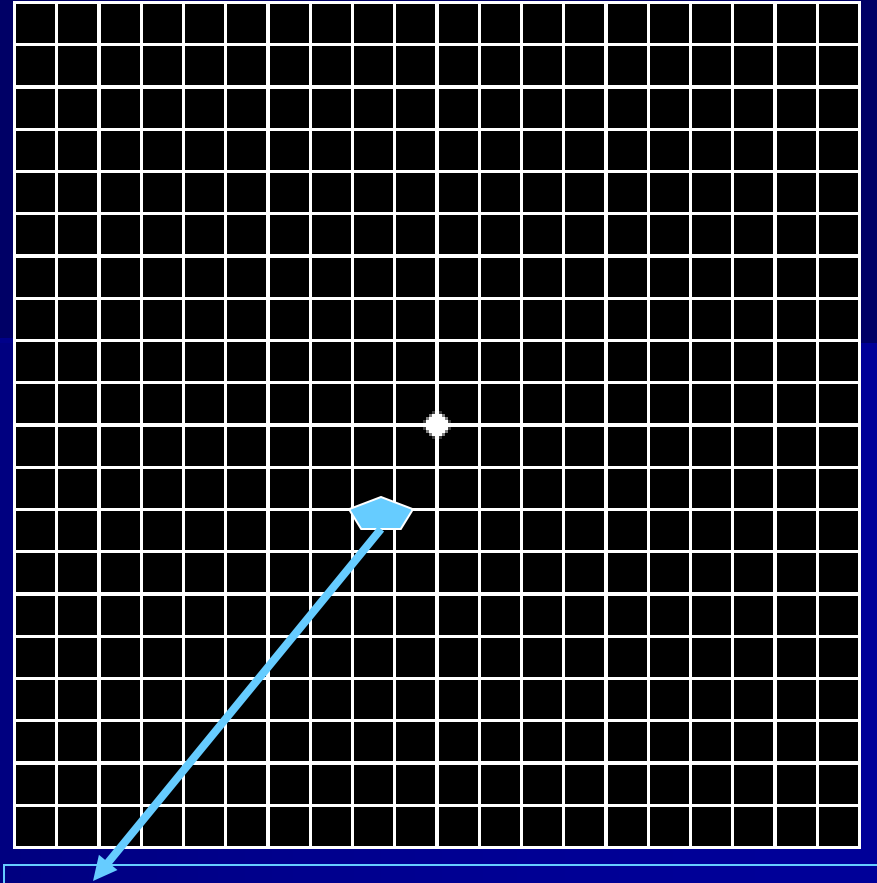
- Fovea merkezine denk gelen fiksasyon noktasının etrafındaki 10 ° lik karesel görme alanını değerlendirir.
- Tarama, takip, tanı
- 7 farklı kart



Low vision optical aids help improve vision for people with macular degeneration. Many different types of magnifying devices are available. Spectacles, hand or stand magnifiers, telescopes, and closed circuit television for viewing objects are some of the available resources. Aids are either prescribed by your ophthalmologist or by referral to a low vision specialist or center. Special lamps with brighter illumination are often beneficial. Books, newspapers, and other items available in large print offer further help.

Kart 1

- 400 adet 5X5 mm kare
- Her bir kare 1° lik görme alanına denk gelir
- Her bir kare 250X 250 µm retina alanına izdüşüm yapar (emetropi için)



Örnek: fiksasyon noktasından 2
kare uzaktaki metamorfopsi
fovea merkezinden
2X 250 µm = 500 µm uzakta lezyon

- **Kart 2**

kart 1 santralindeki fiksasyon noktasını göremeyenler için iki çapraz çizgi eklenmiş

- **Kart 3**

Kart 1 'in aynısı kırmızı çizgilerden oluşur Optik sinir hst, Klorakin kullanımında takipte

- **Kart 4**

Kare yok tesadüfi noktalardan oluşur. Nadir kullanılır

- **Kart 5**

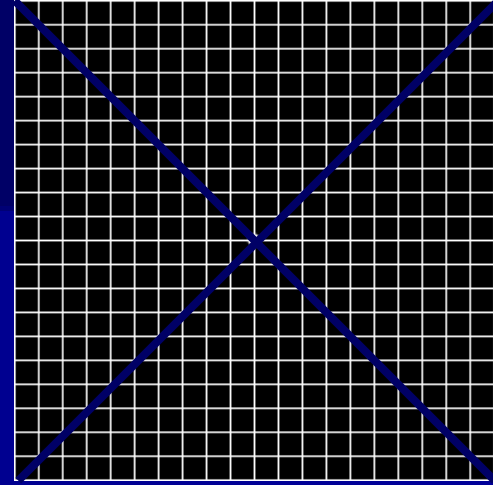
Yalnızca yatay çizgilerden oluşur.Okuma güçlüğü yatay meridyen metamorfopsisi

- **Kart 6**

Kart 5 e benzer zemin beyaz ,siyah çizgiler

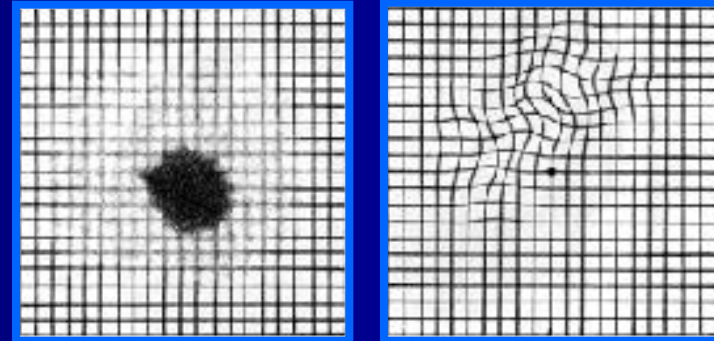
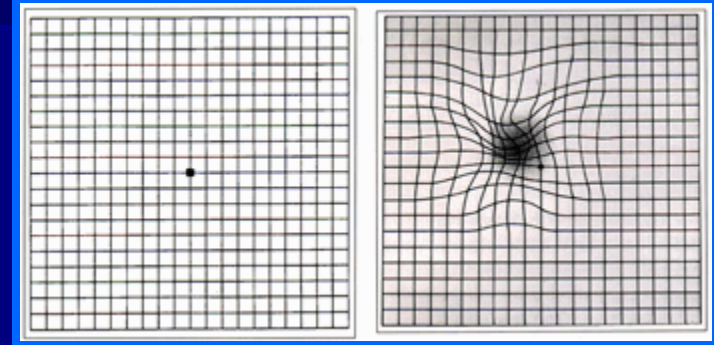
- **Kart 7**

Santralde daha küçük $0,5^{\circ}$ ' lik kareler. Daha hassas



Amsler Grid - Makülopati

- Çizgilerde kırılma eğilme
- Herhangi bir kare farklı büyüklük yada şekilde
- Herhangi bir çizgi yada alanda bulanıklık, renk değişikliği



■ Kompütürize Grid

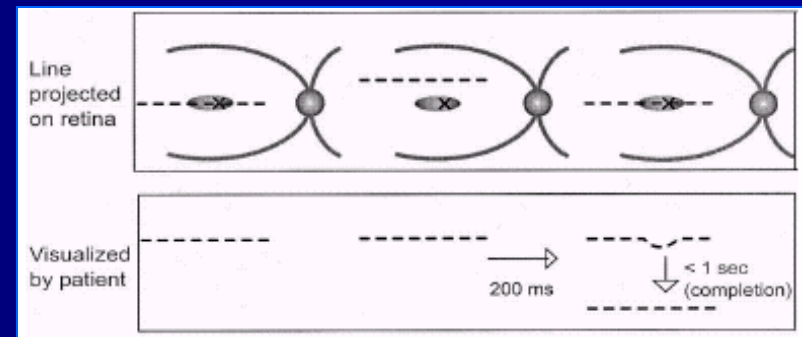
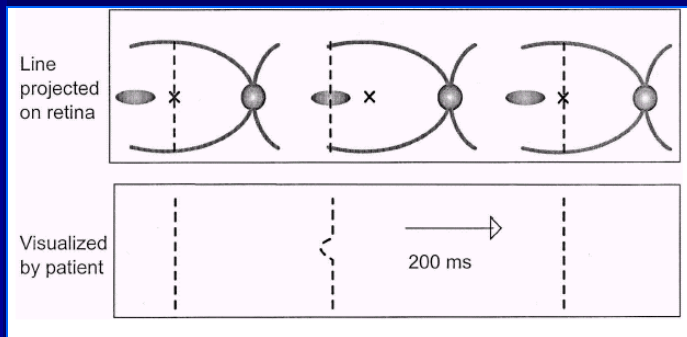
Kayıt sistemi ile karşılaştırma - takip sağlar

■ Preferential Hyperacuity Perimeter (PHP)

Santral maküler görme alanı

Ortam opasitesinden etkilenmez

14°lik görme alanı (50 cm mesafeden monitörde)



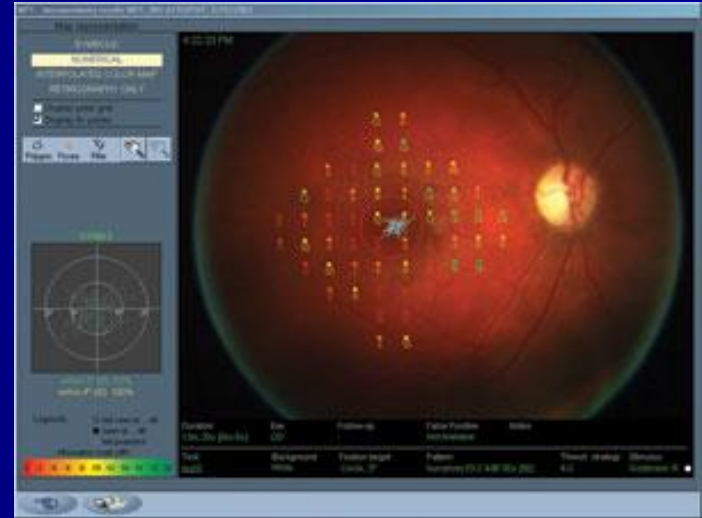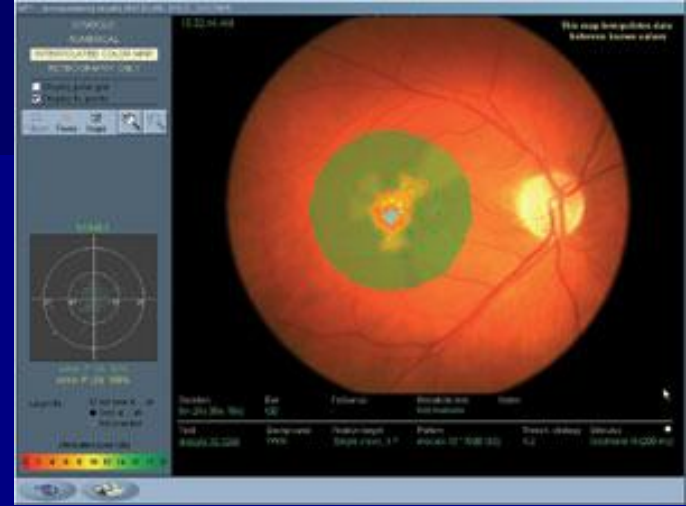
Preferential Hyperacuity Perimeter(PHP) ile Amsler Grid karşılaştırma *Retina 2005 25(3)296-303*

<u>AMD</u>	<u>PHP %</u>	<u>Amsler Grid %</u>
Neovasküler	100	53
Geografik	96	44
Non-neovasküler(geç)	70	20
Non-neovasküler(erken)	41	8
Yanlış Pozitif	18	0

Mikroperimetri-YBMD

- Erken YBMD: takip
- Geç YBMD
 - Skotomun karakterini,
 - Zamanla deęişimini ve
 - Herhangi tedaviye cevabı

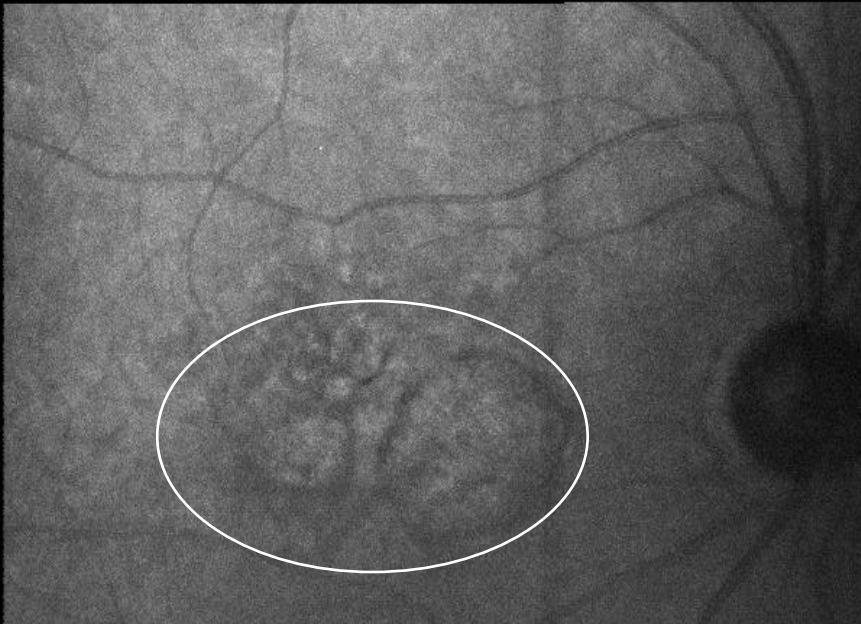
Objektif olarak
deęerlendirmeyi saęlar



SLO / SPEKTRAL OCT

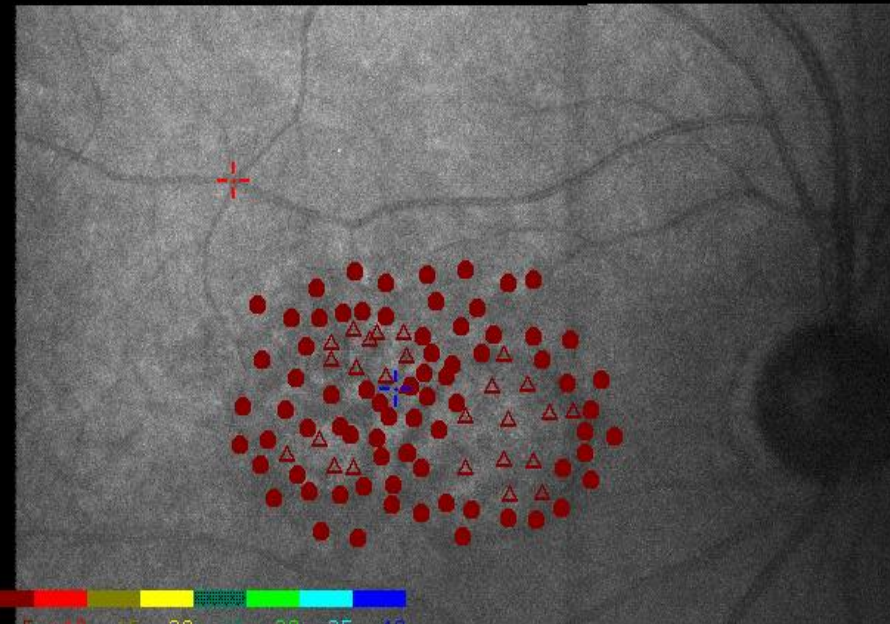
Fokal Görme Alanı Testi

Rodenstock SLO +0.00pt | He:51 Ar:0.0 IR:66 40° C2 Ch1:A 11-Sep-01 11:54:08
Green George 05/04/1945 1707791 OS | T:- 29 min



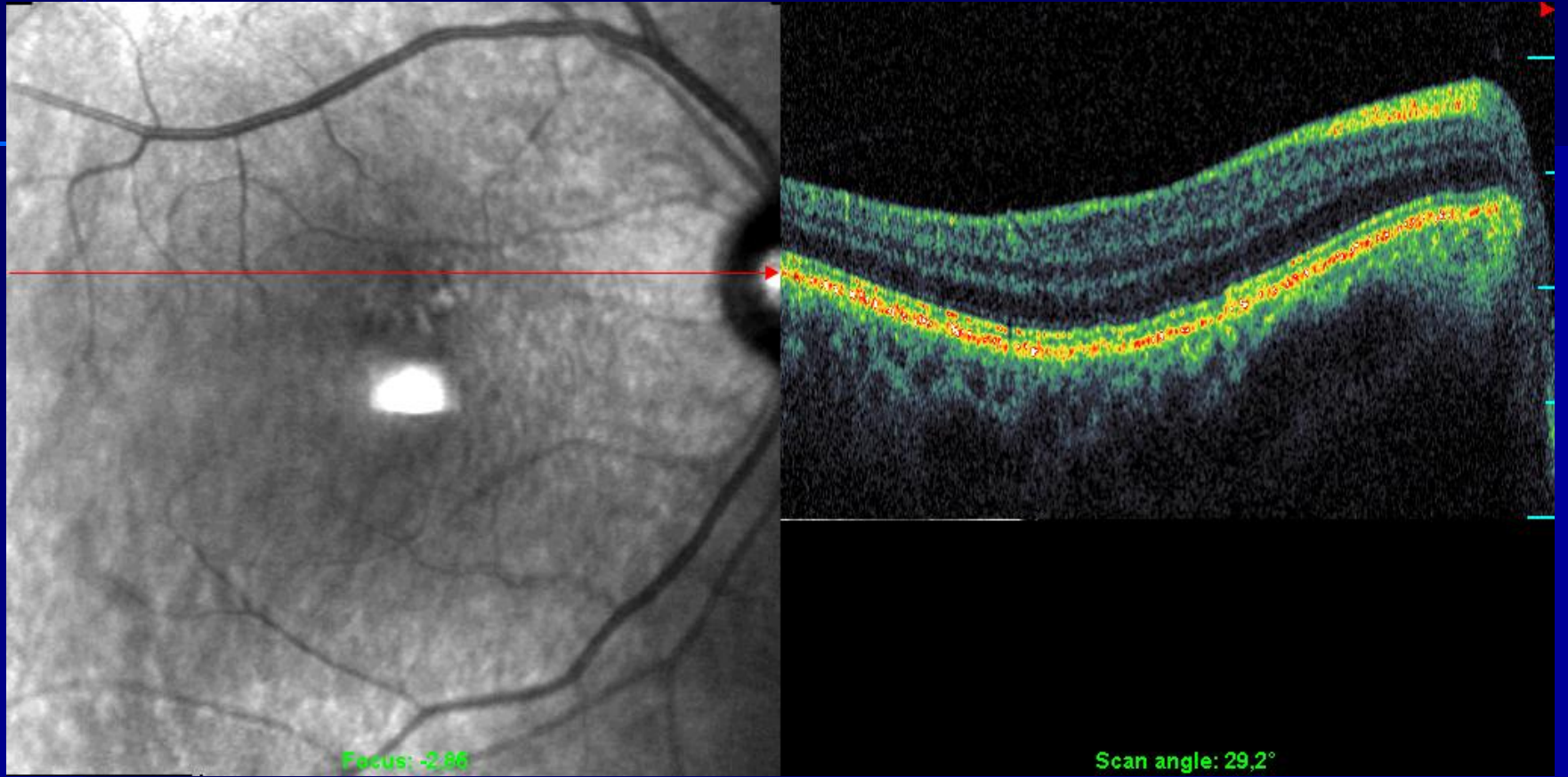
101

Rodenstock SLO +0.00pt | He:51 Ar:0.0 IR:66 40° C2 Ch1:A 11-Sep-01 11:54:08
Green George 05/04/1945 1707791 OS | T:- 29 min



Mikroperimetri

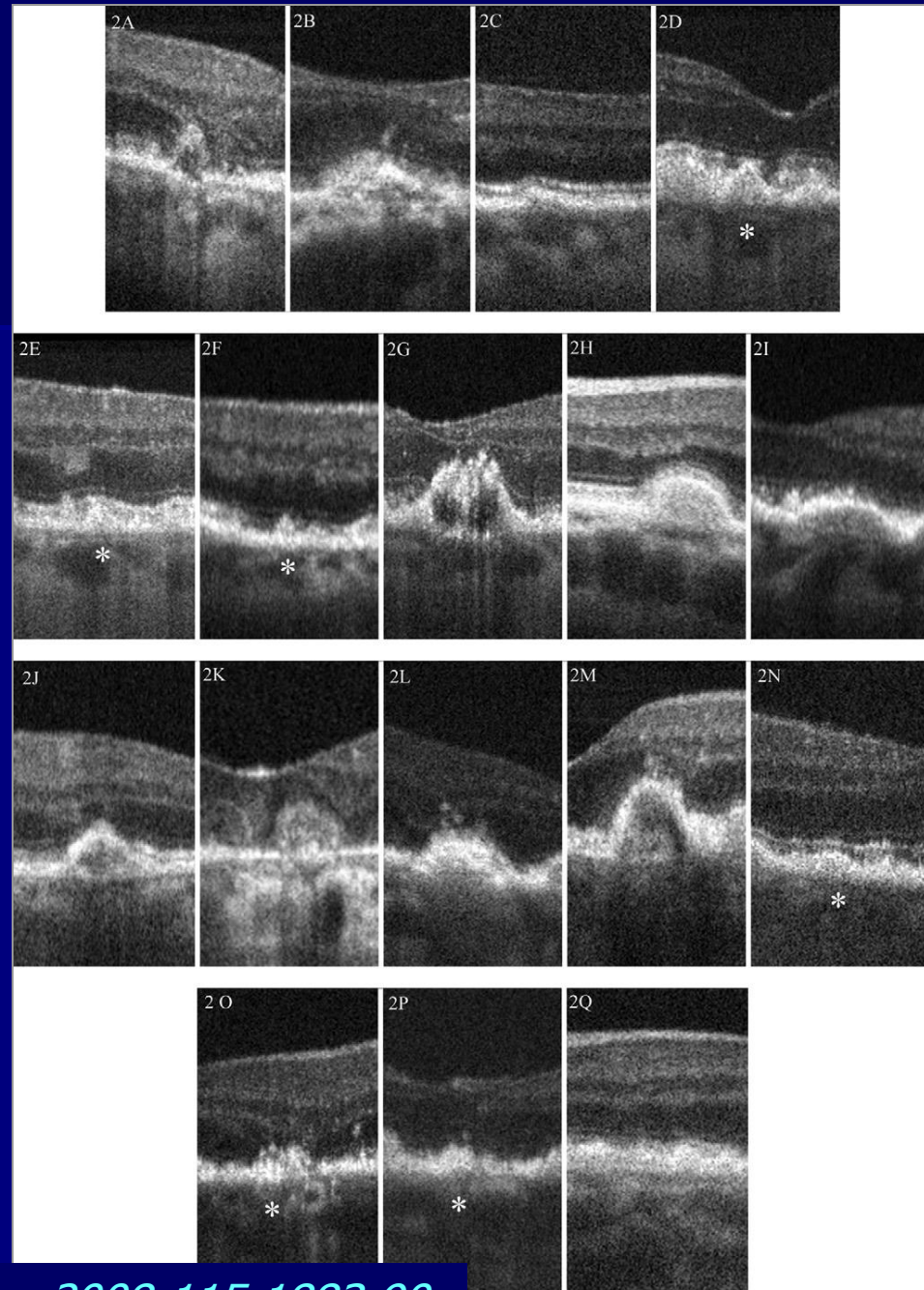
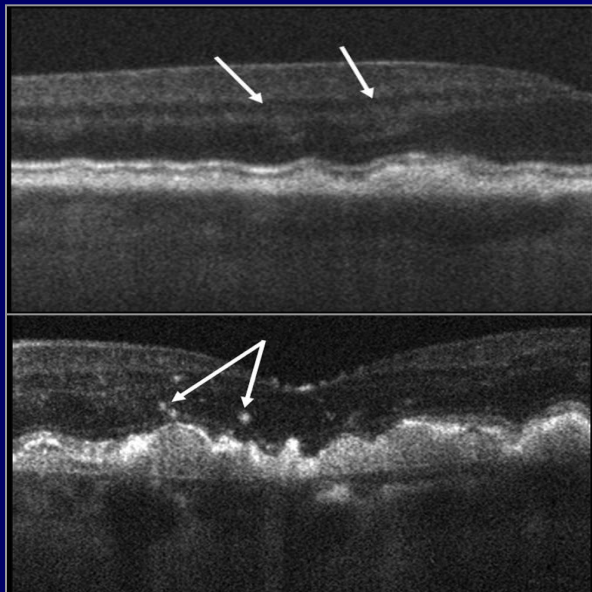
SLO / SPEKTRAL OCT

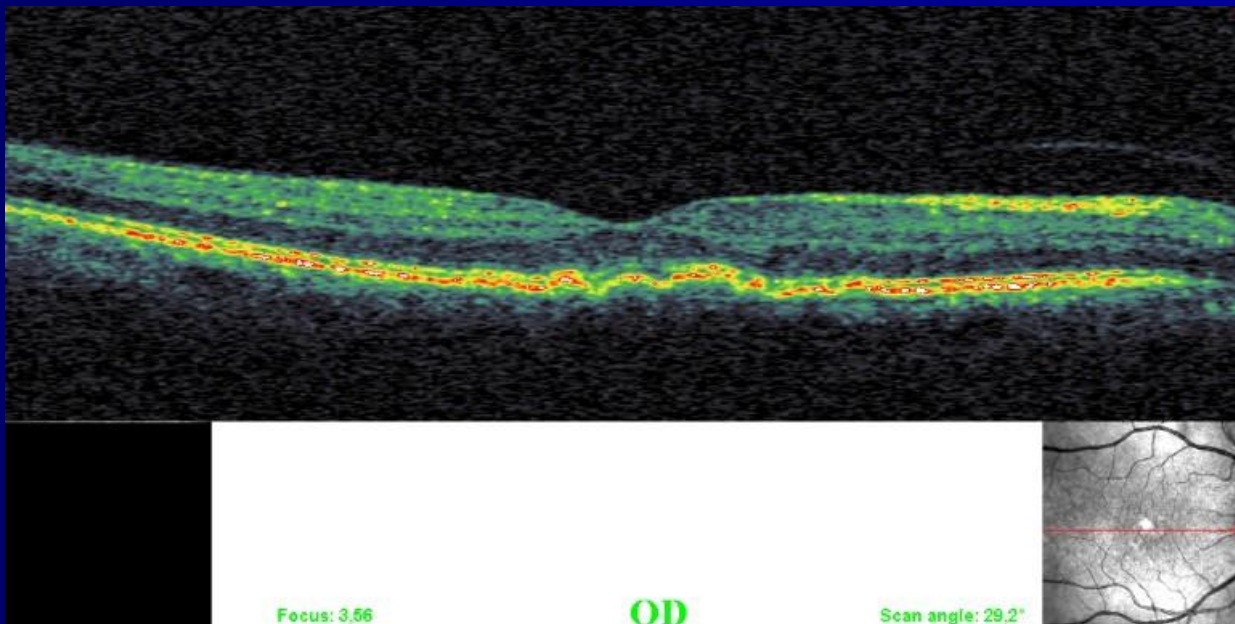
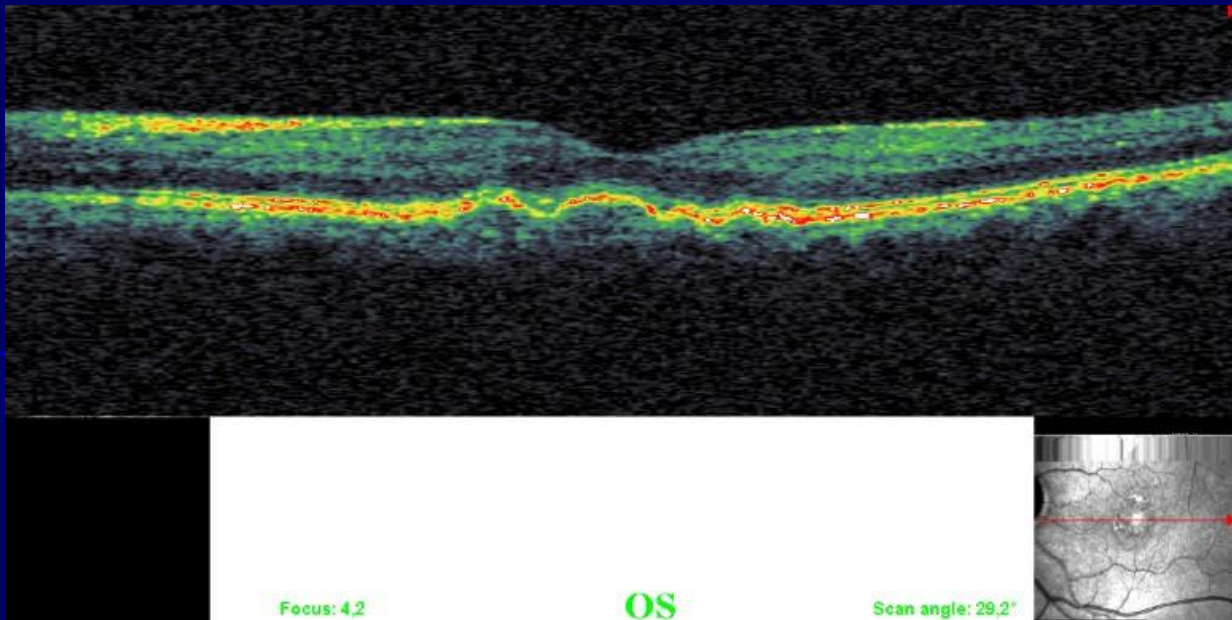


SLO / SPEKTRAL OCT İLE NOKTASAL ANALİZ

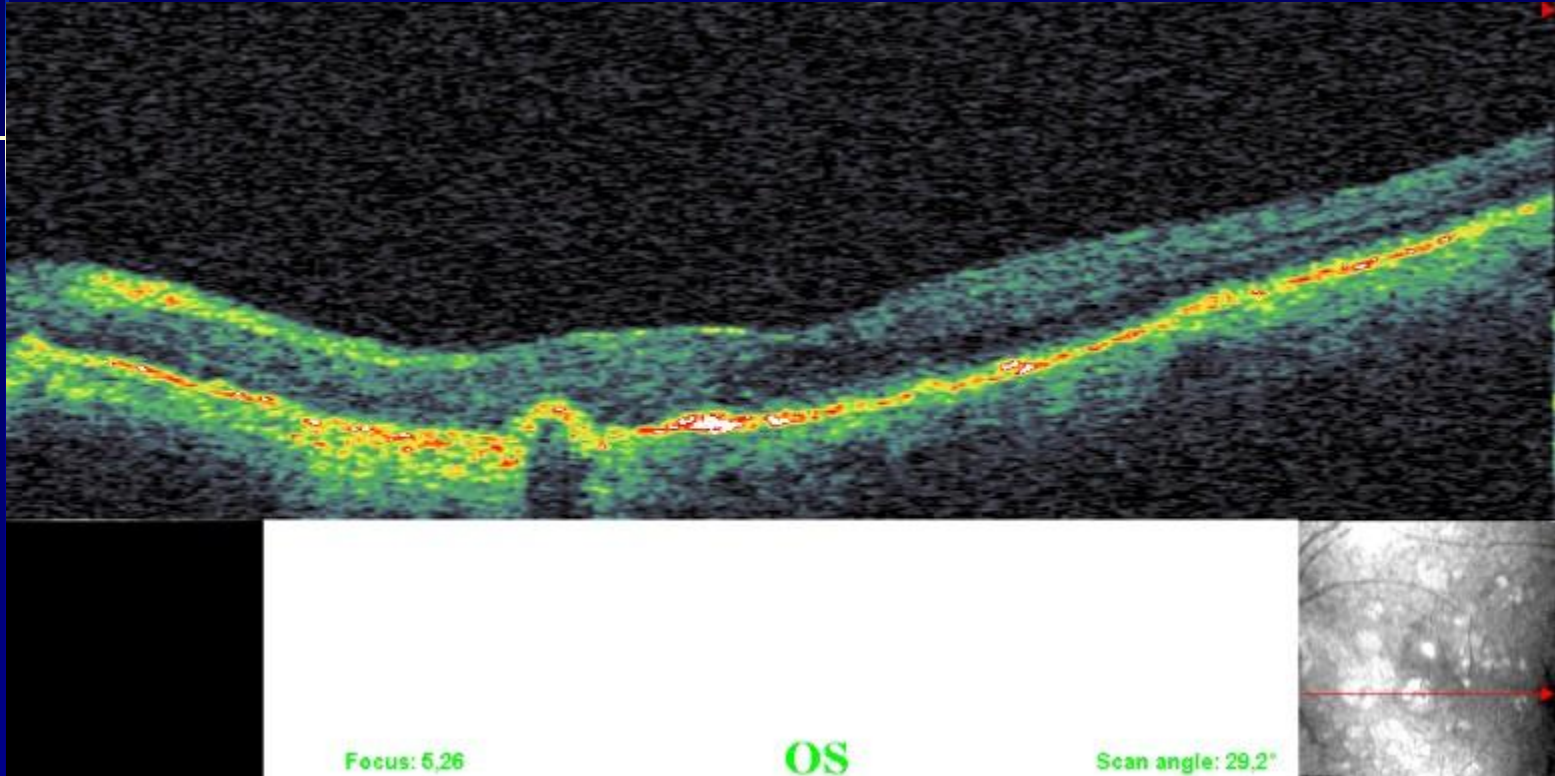
Drusen - OKT

- OKT ile 17 farklı tomografik drusen paterni
- Drusen üzerinde yüksek yansıtıcılıklı odaklar => ilerleme ? , KNV gelişimi ?

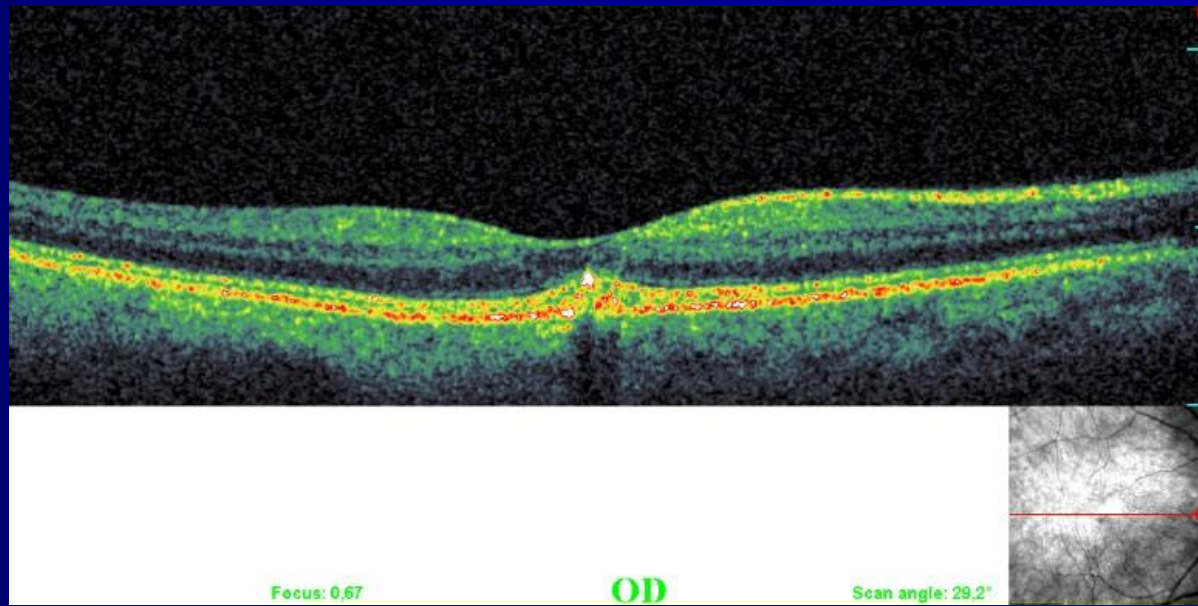
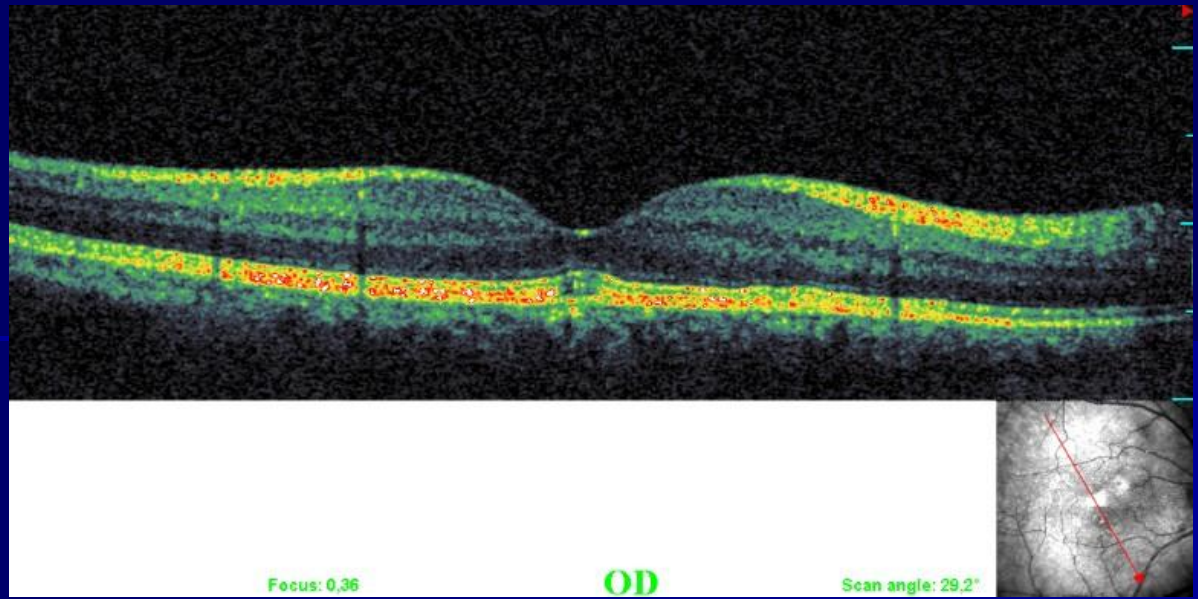




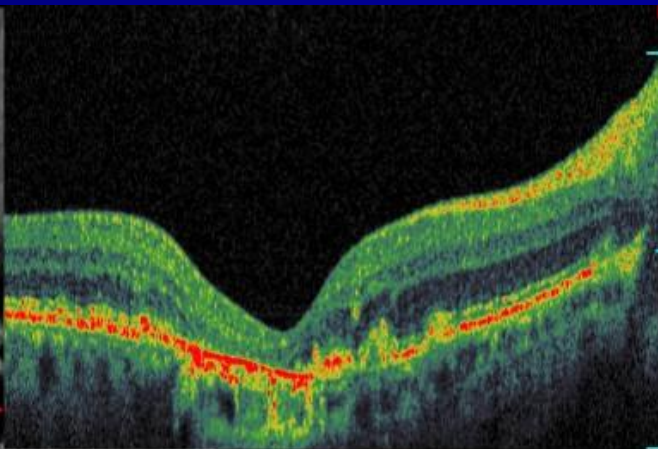
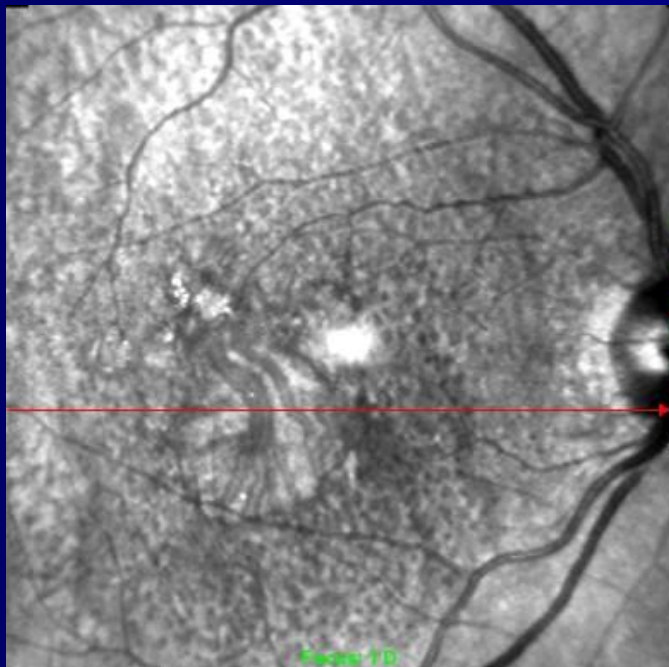
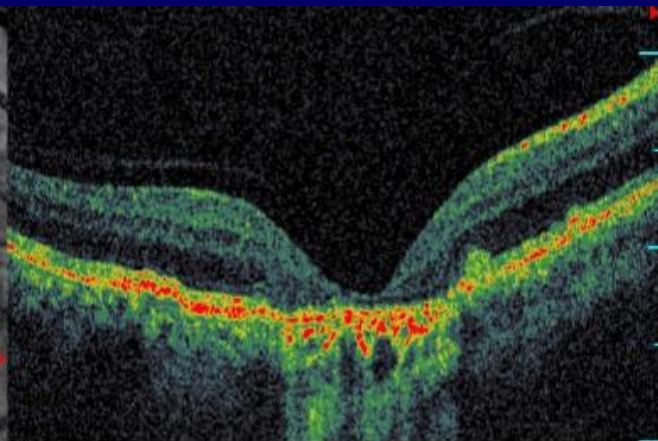
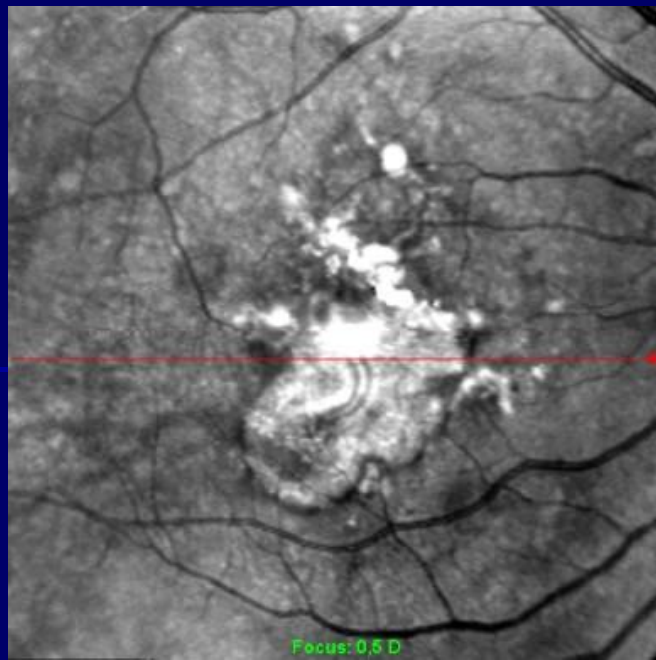
DRUSENOID PED



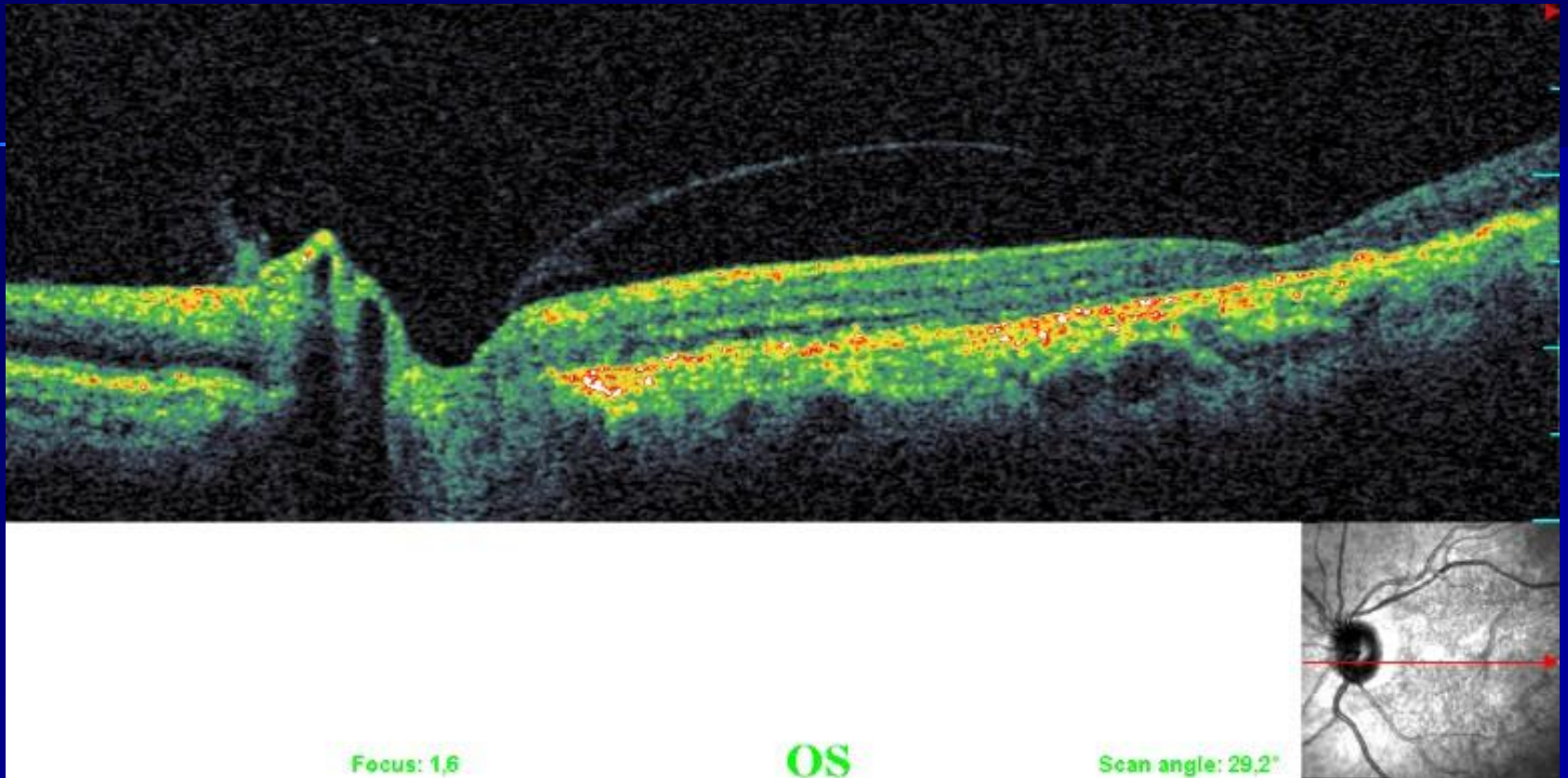
RPE ATROFİSİ – SERT DRUSEN



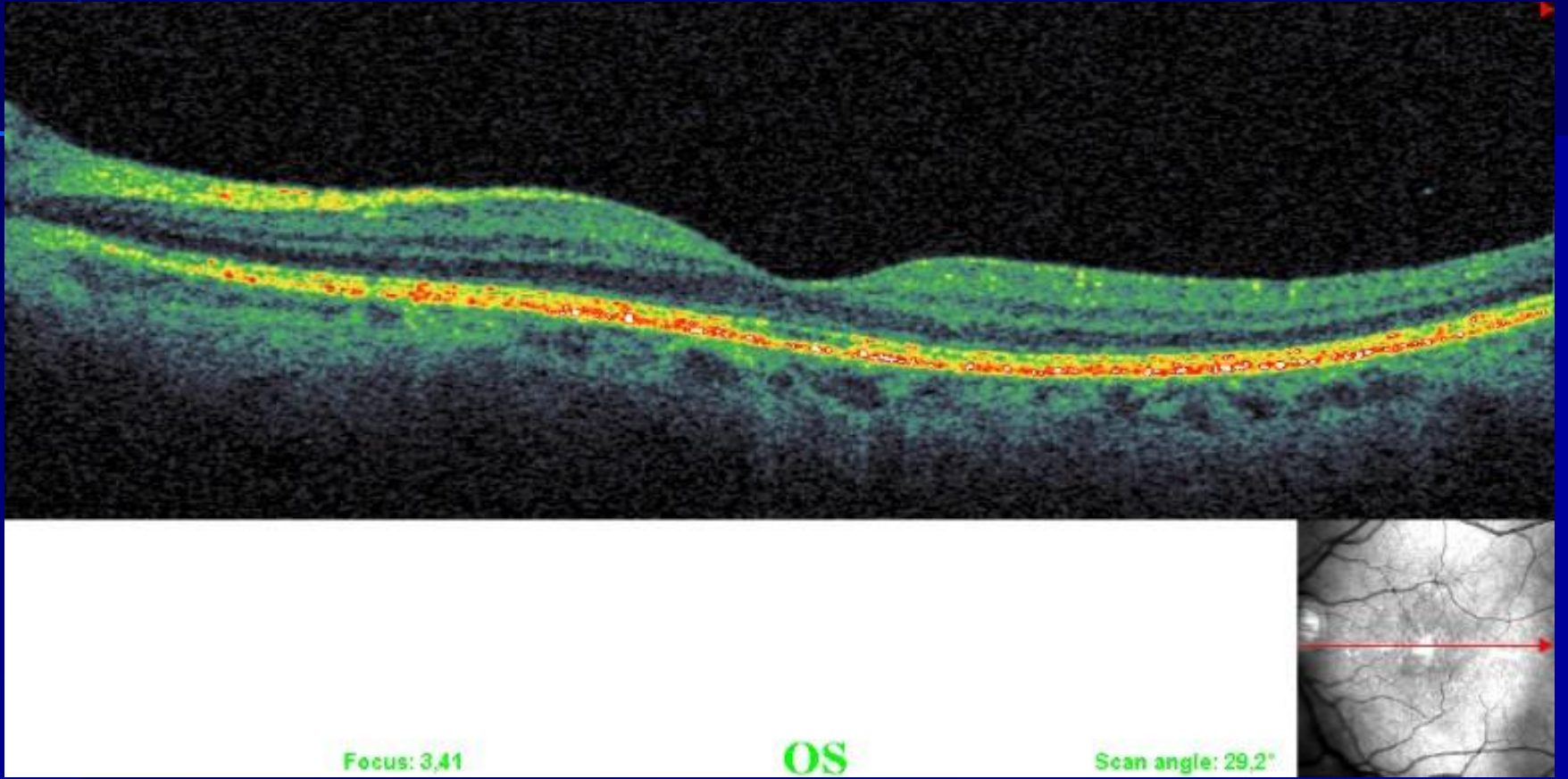
SUBFOVEAL BİRİKİNTİ



SANTRAL AREOLAR ATROFI / FOVEAL ATROFI

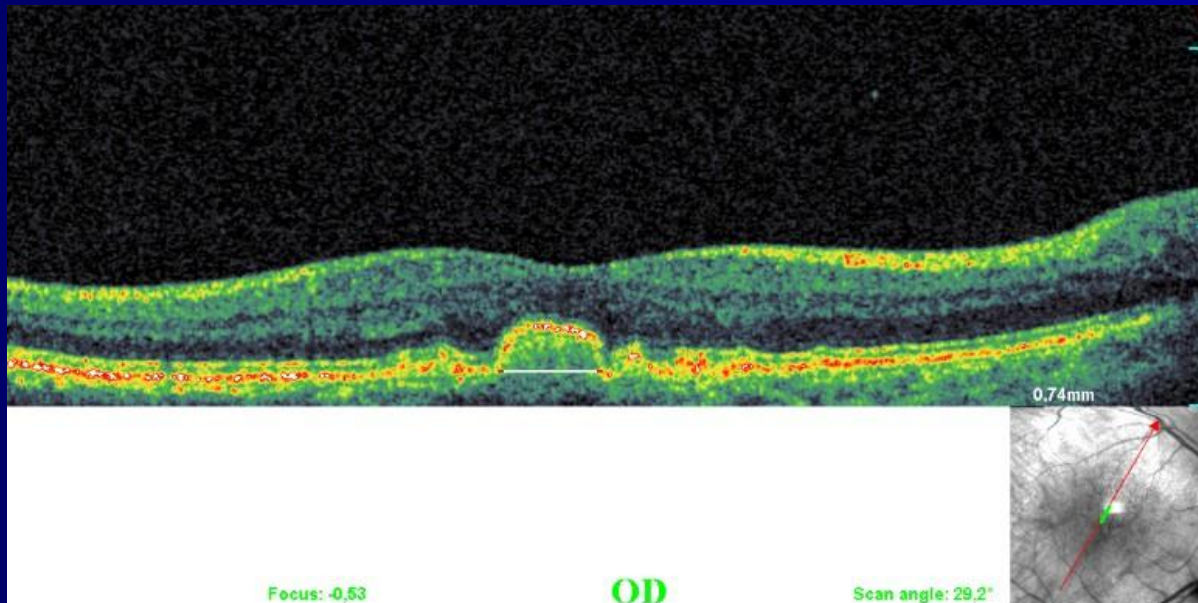
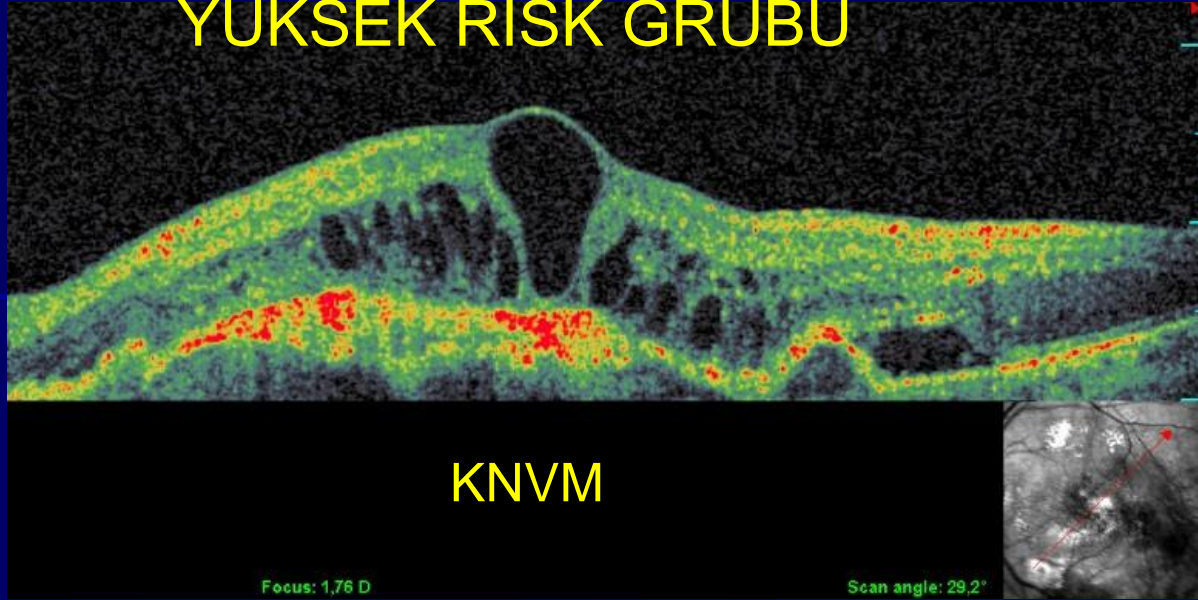


RPE ATROFİSİ /FOVEAL ATROFİ/ DRUSENLER

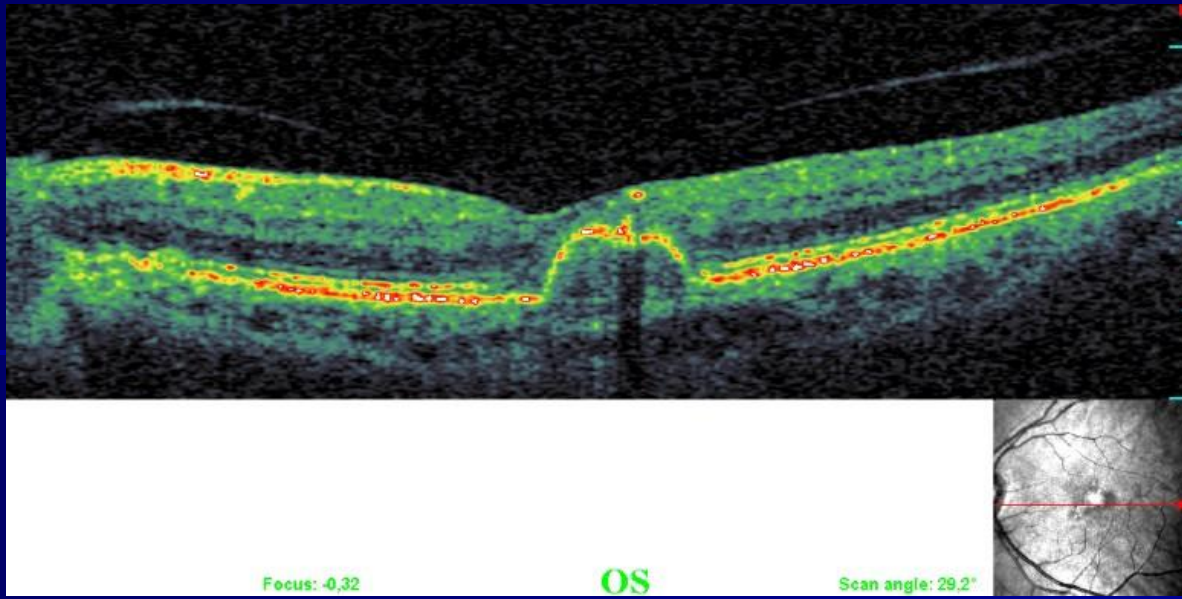


RPE İNCELMESİ - SAĞLAM İS / OS

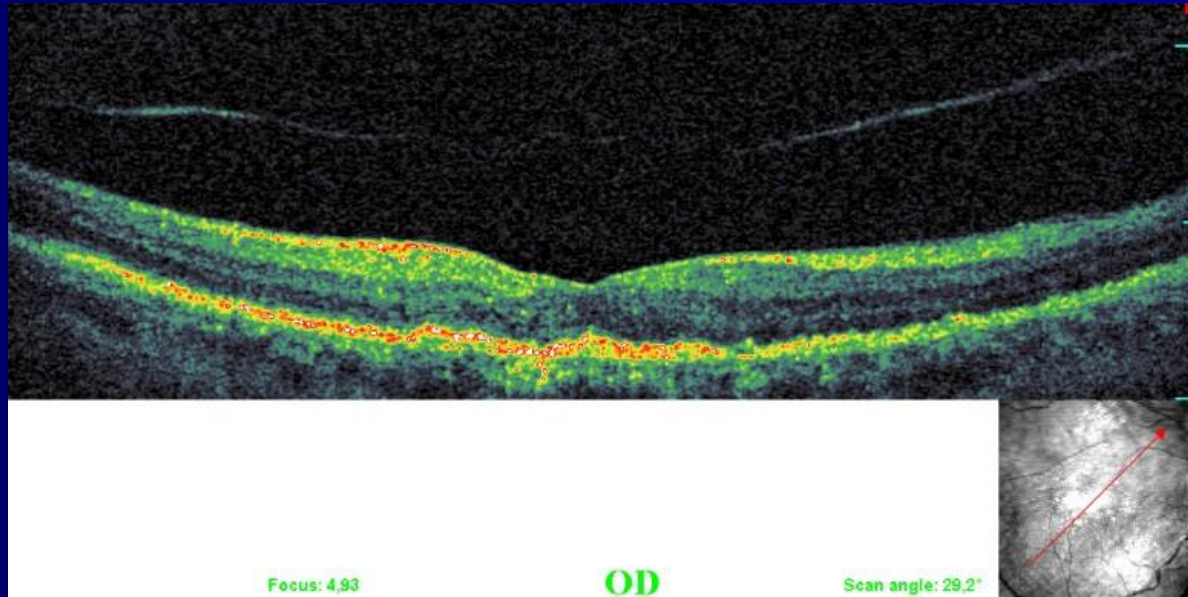
YÜKSEK RİSK GRUBU



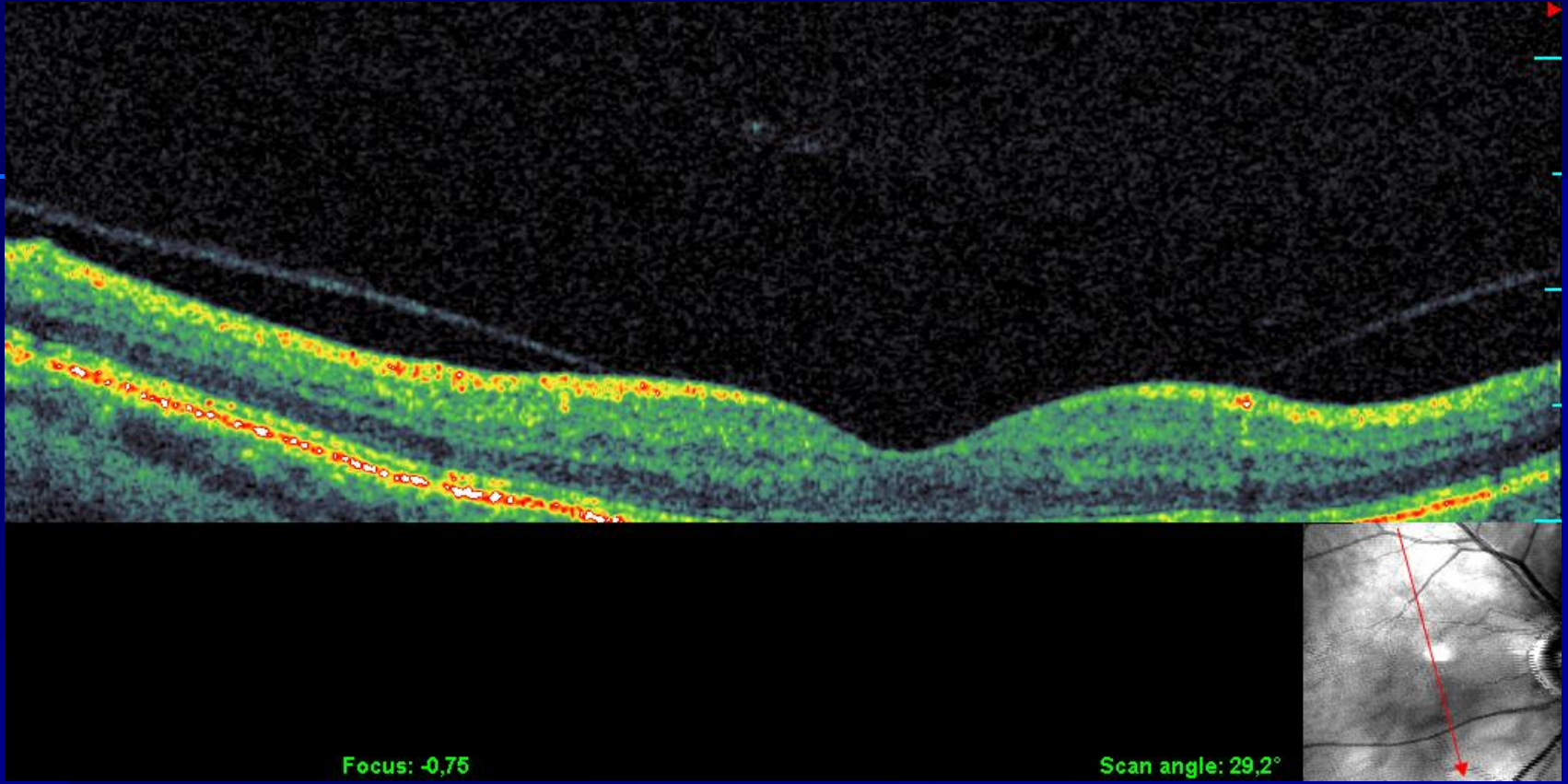
DiĞER GÖZ, DRUSENOİD PED ÖLÇÜMÜ



YAPIŞIK PVD / DRUSENOİD PED / PİGMENT PROLİFERASYONU



TOTAL PVD / BAZAL LAMİNER BİRİKİNTİLER



EVRE 0 MAKÜLER HOLE / İNCE DRUSENLER
İLERLEME İÇİN RİSK FAKTÖRÜ?

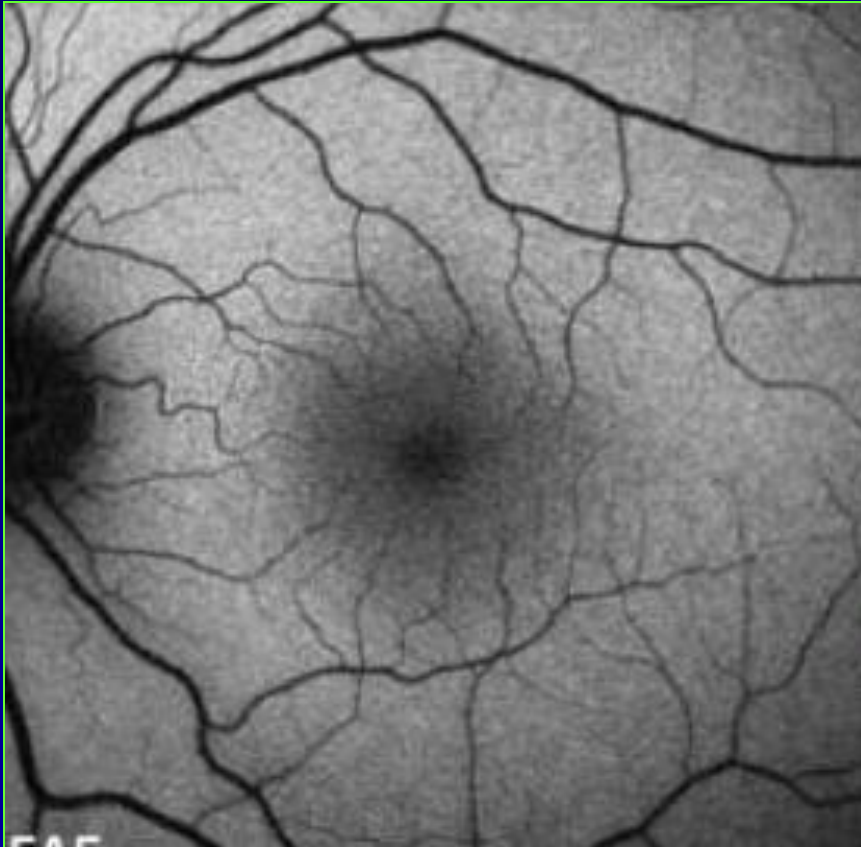
FUNDUS OTOFLÖRESANSI

Fundus Otoflöresansı tipleri

■ Lipofuscin otoflöresansı

FAF,SW-FAF

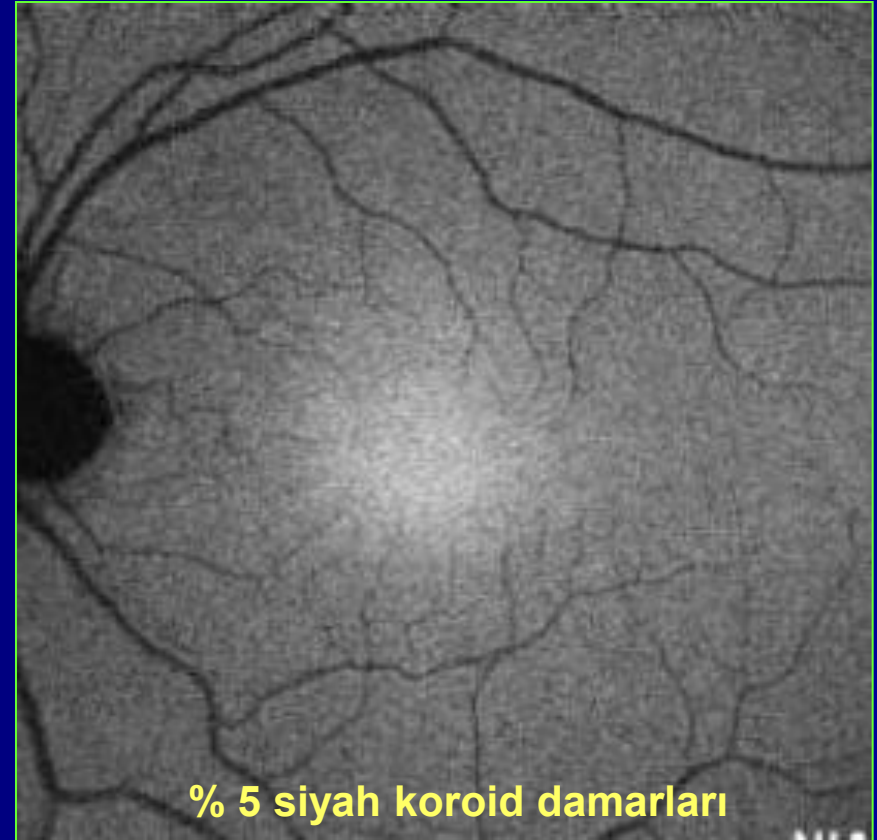
488 nm mavi argon laser ile
eksitasyon, 600 – 640 nm
emission, bariyer filtre 500 nm



■ Melanin otoflöresansı

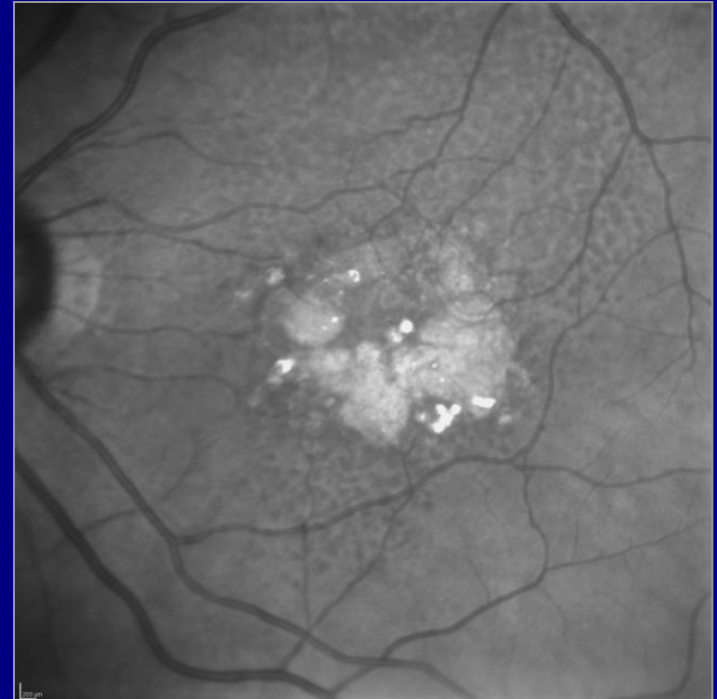
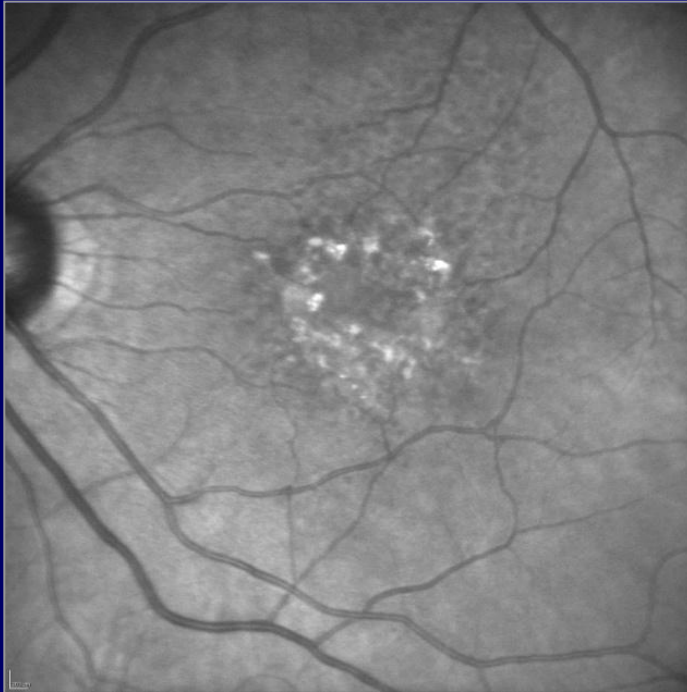
NIR - FAF

787 nm diot laser ile eksitasyon,
ICG' in 800 nm bariyer filtresi



Near IR

- Yaşlılarda avantajlı öz. lens opasitesi varlığında ışık dağılması minimal
- İnfrared ışığın derin penetrasyonu nedeniyle drusen ve KNV gibi subretinal lezyonların daha kolay izlenmesi
- Geografik atrofi sınırları belirgin



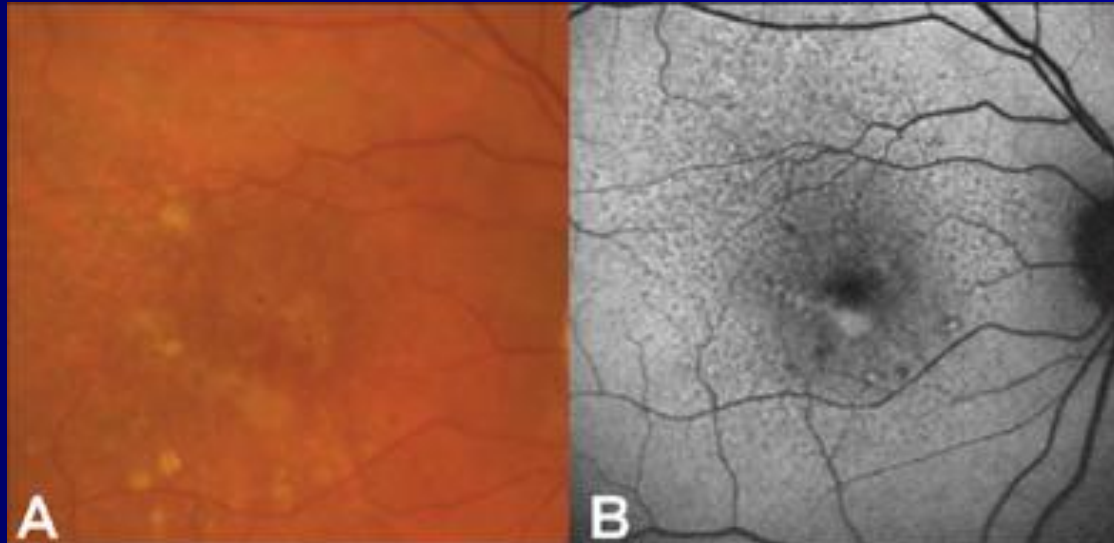
Drusen / FOF

- YBMD'nin erken belirtileri: RPE düzeyinde fokal hipopigmentasyon ve hiperpigmentasyon, Bruch membranı'nın iç kısımlarında drusen materyalinin birikimi
- Drusenin moleküler yapısı komplike
- Postmortem analizler → drusen materyalindeki bazı moleküller otoflöresan

YBM - FOF

- Erken YBMD'de FOF deęişiklikleri, anjiografi ve fundus fotoęrafı ile görülebilen drusen veya düzensiz pigmentasyon ile her zaman ilişkili deęil

Bindevald A, et al. Invest Ophthalmol Vis Sci 2005;46;3309-14

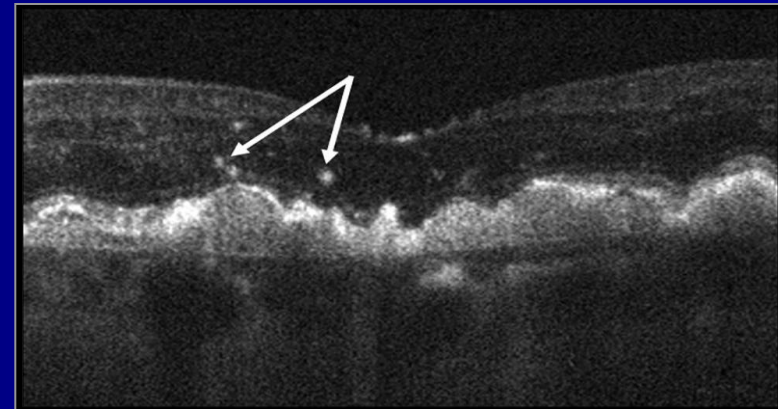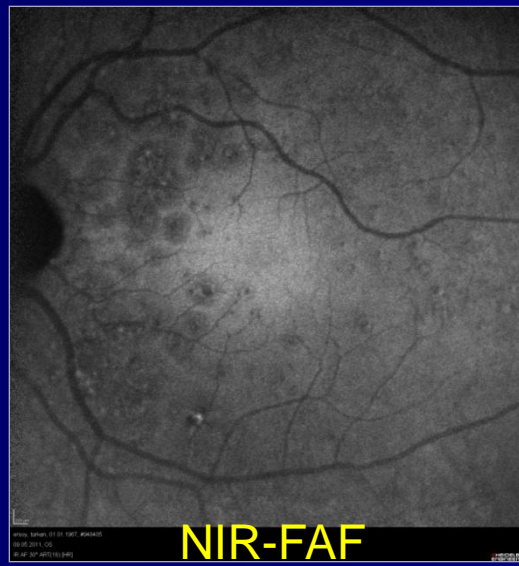
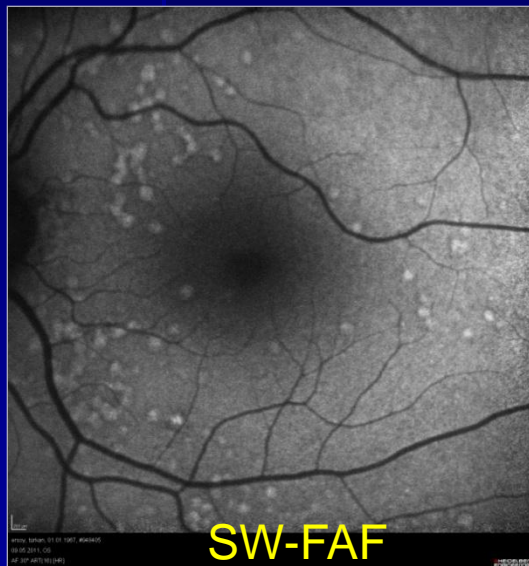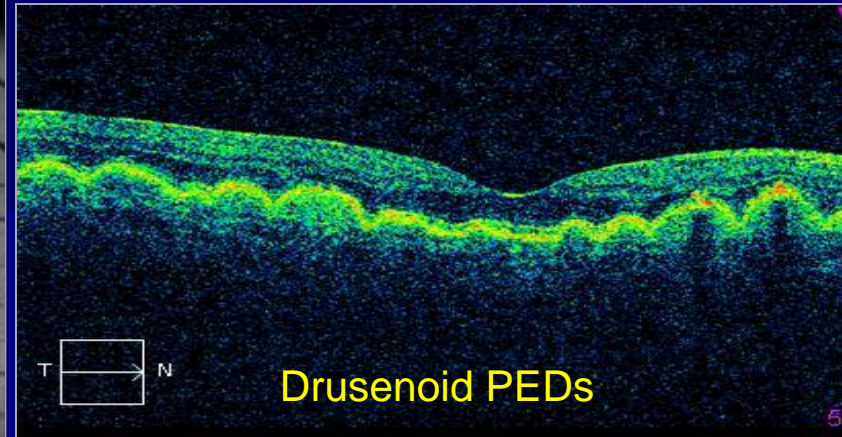
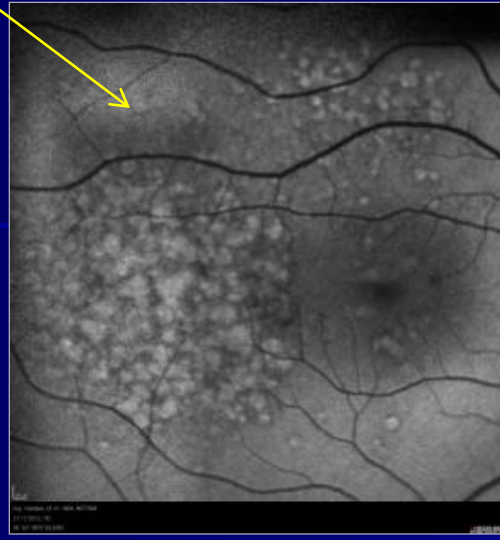
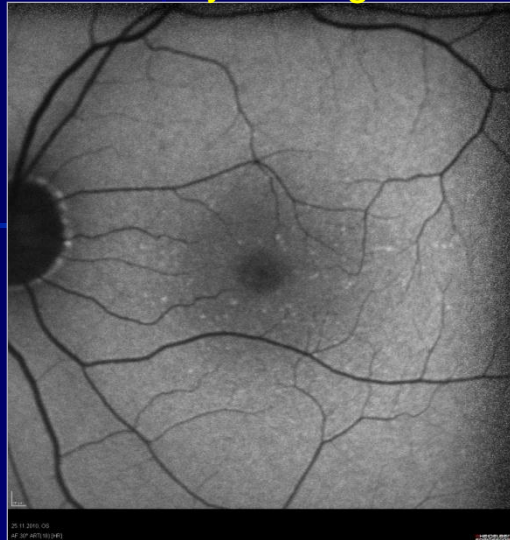


Autofluorescence characteristics

	Hyperautofluorescence	Hypoautofluorescence	Normal
Hard drusen	+	+	+
Soft drusen	+	+	+
Hyperpigmentation	+		

HYPERFLUORESCENT DRUSENS

May be large drusenoid PED

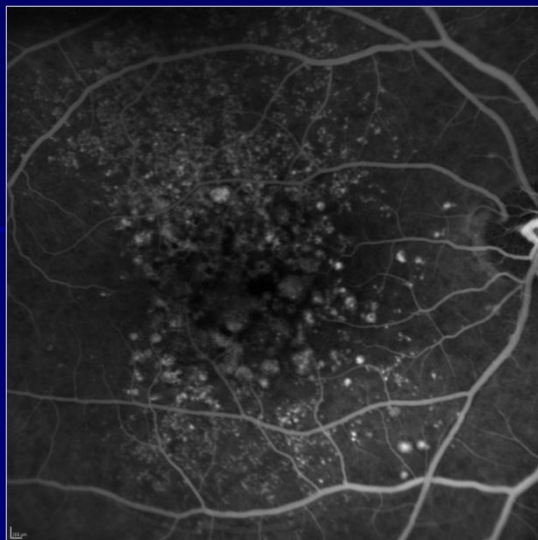
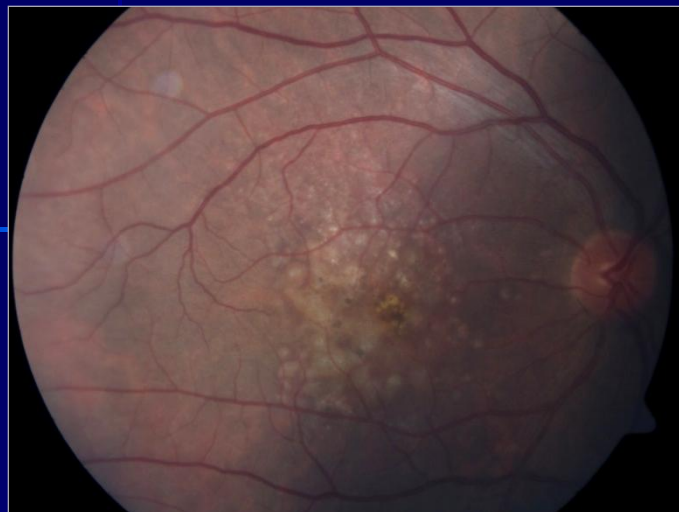


More changes on NIR-FAF

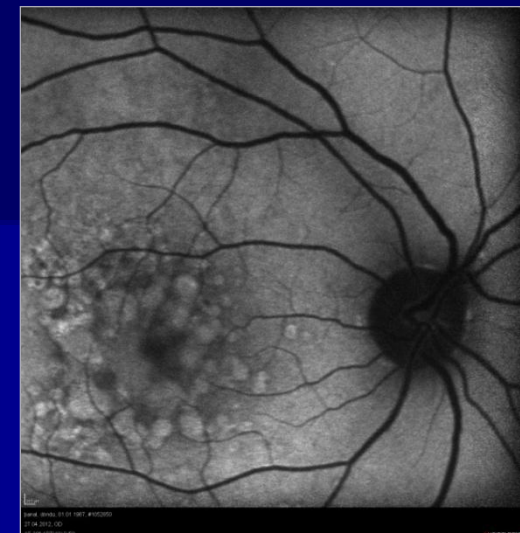
Hyper fl. dots may imply progression

Basal Laminal Depoits (Hyperfluorescent)

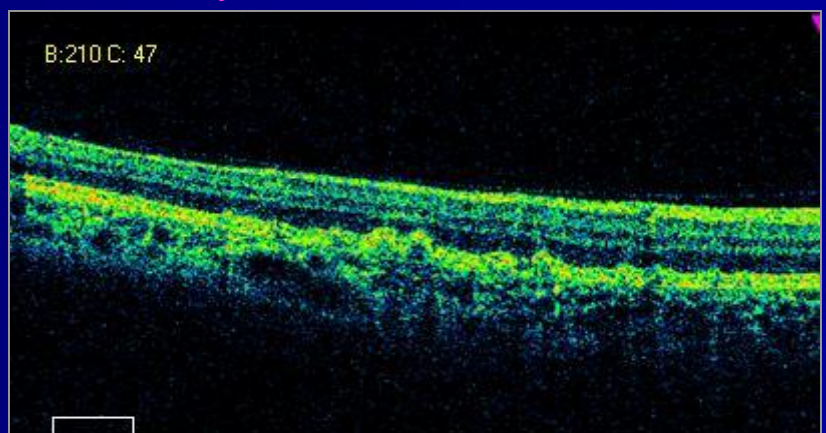
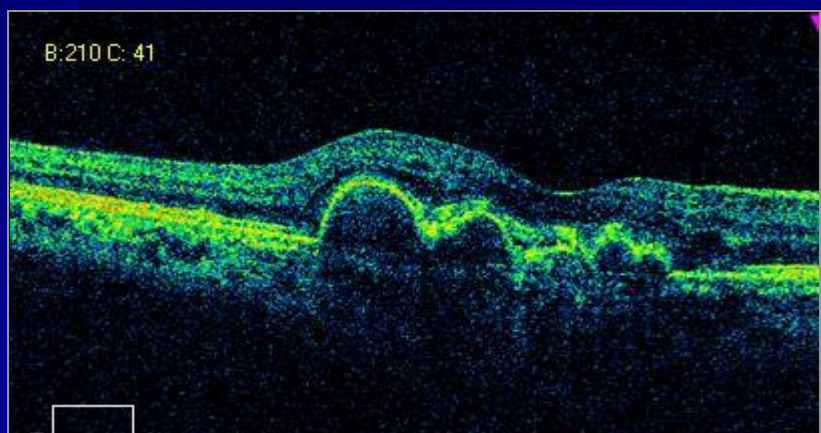
(Local nodular thickening of basal membrane of RPE)



FFA: early hyperfl.
Stars in the sky



FAF

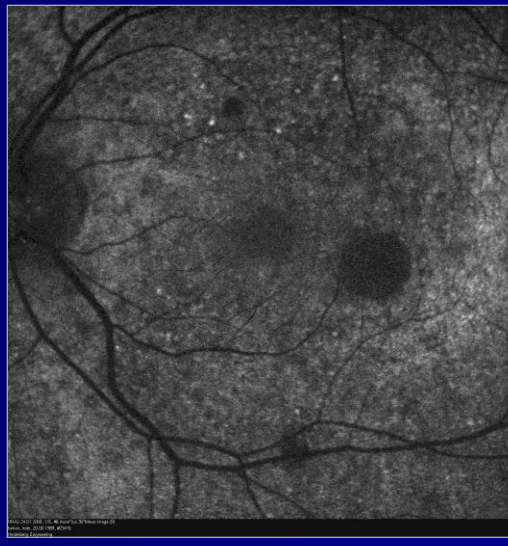
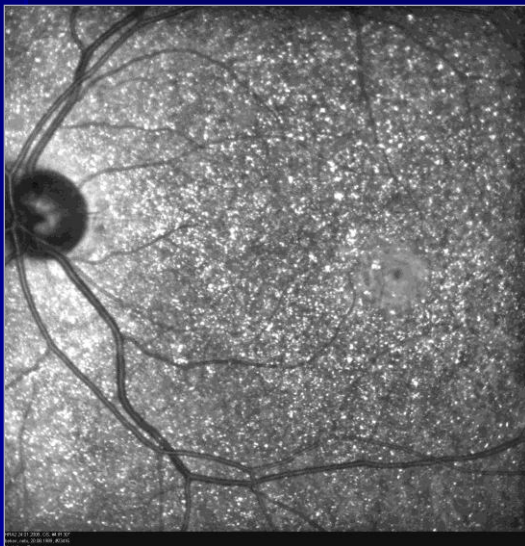
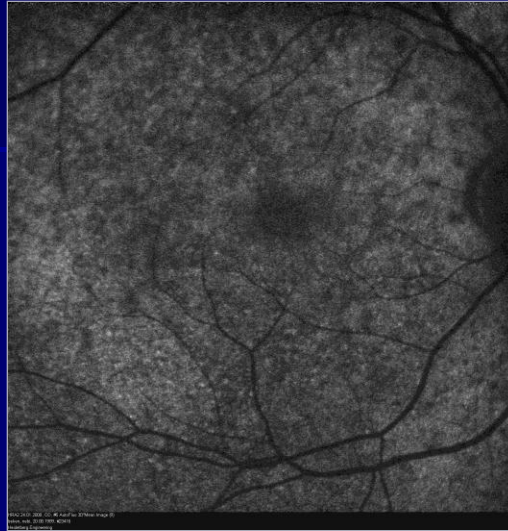
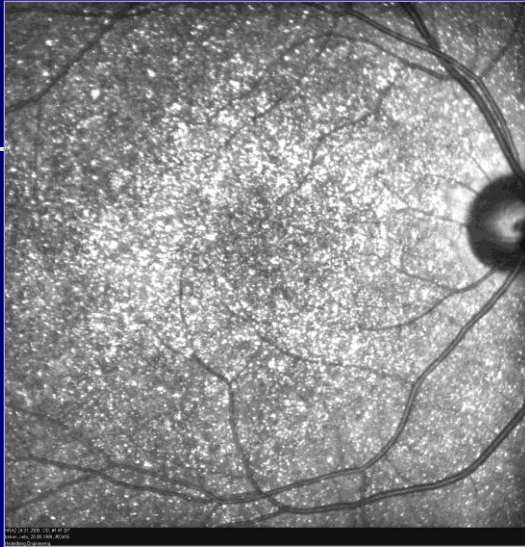


Saw teeth appearance in RPE with IS / OS and ELM damage

Hypofluorescent Drusens / Bietti

IR REFLEKTANS

SW - FOF



Severely reduced
background FAF
Hypofl crystalline drusens

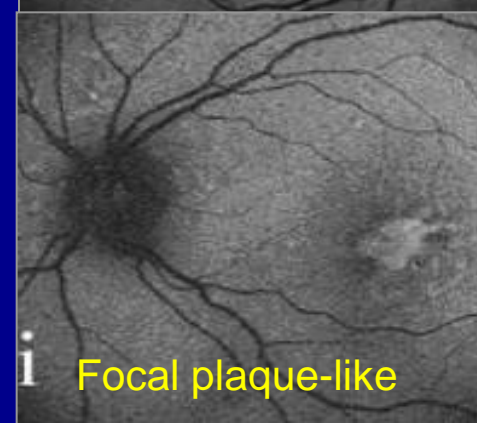
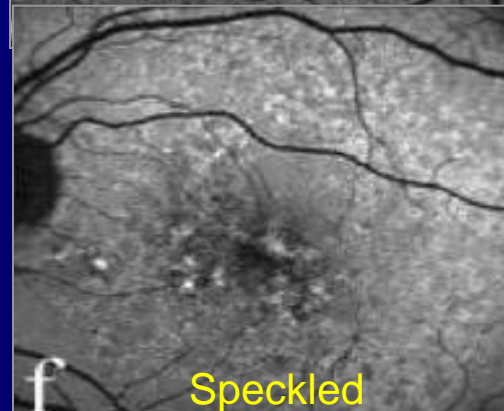
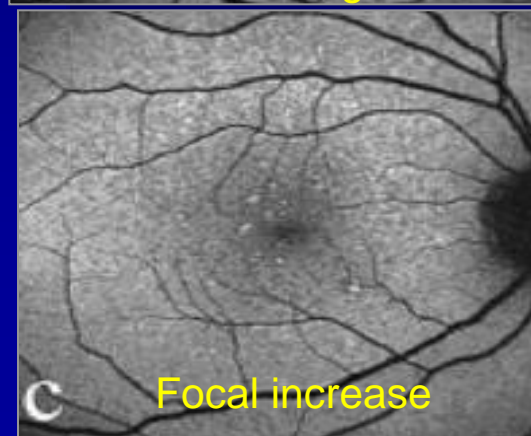
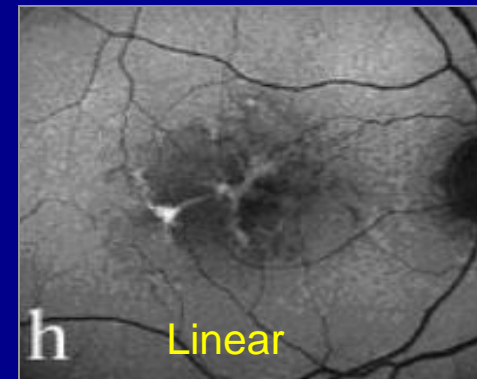
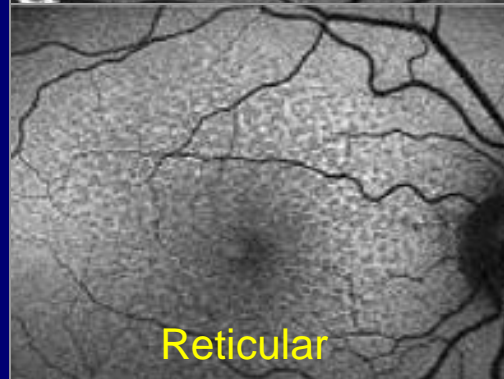
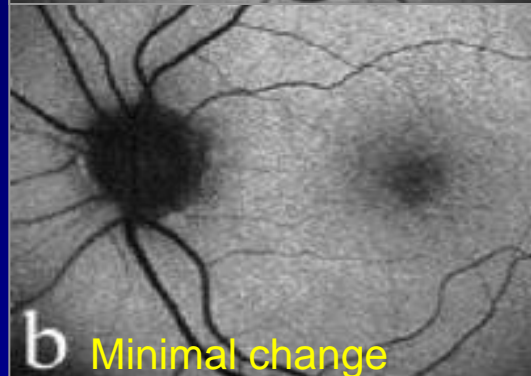
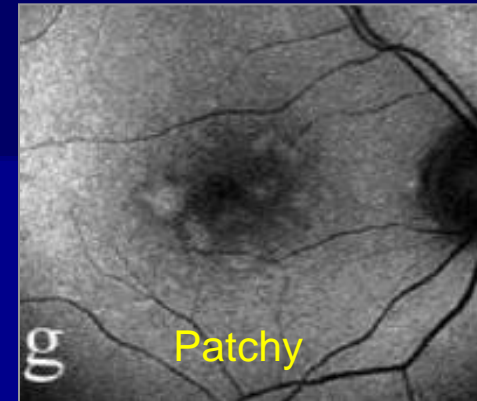
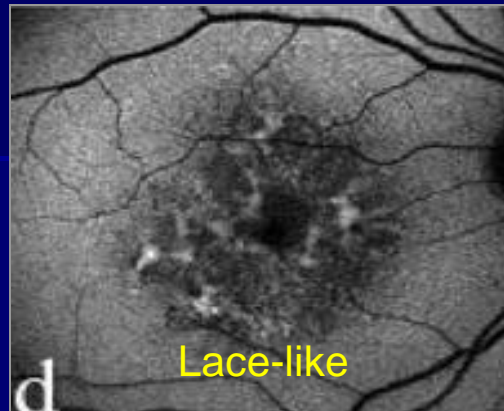
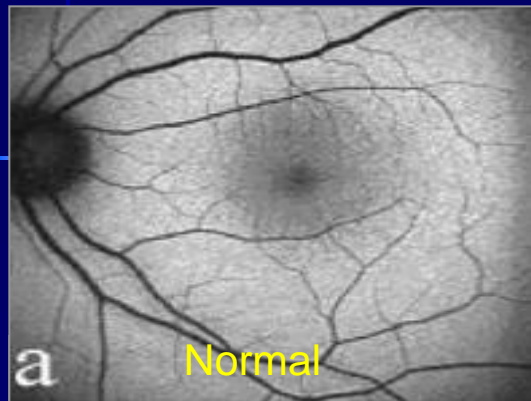
FAM sınıflaması ile:

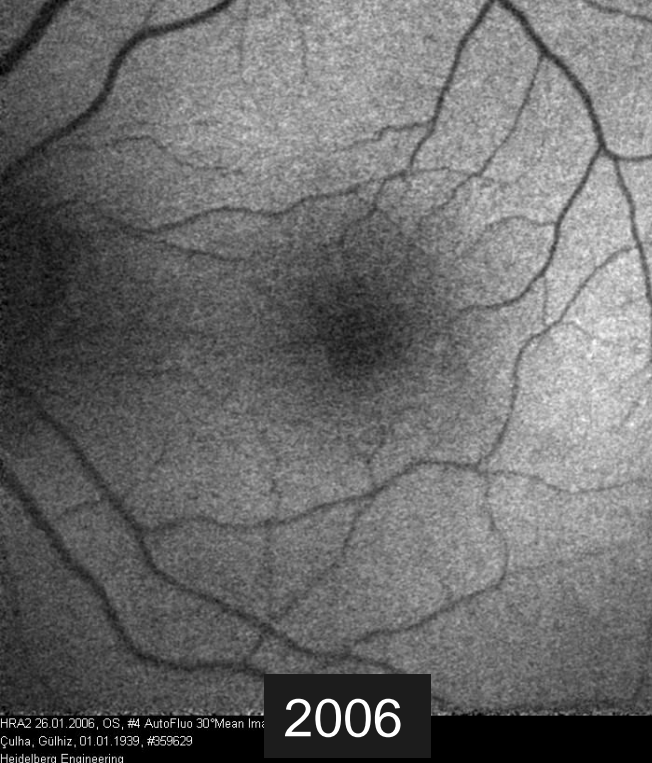
- * Yüksek riskli gözlerin belirlenmesi
- * İleriye yönelik girişimsel çalışmaların planlanması ve monitörizasyonu
- * Moleküler genetik çalışmaların kolaylaşması

Abnormal Fundus Autofluorescence

(FAM Study Group, 2005)

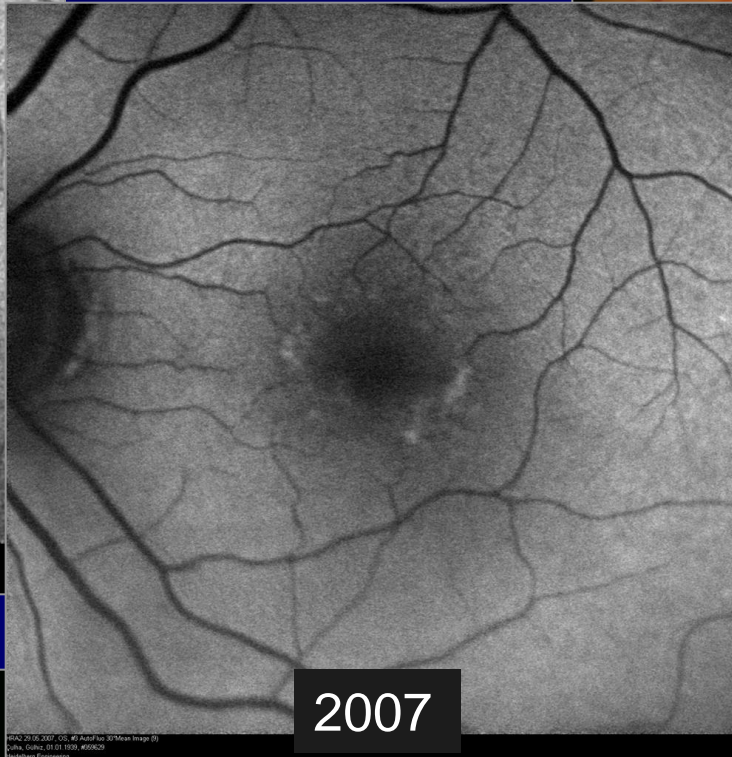
Patchy, Focal plaque, Reticular ----- n ARMD





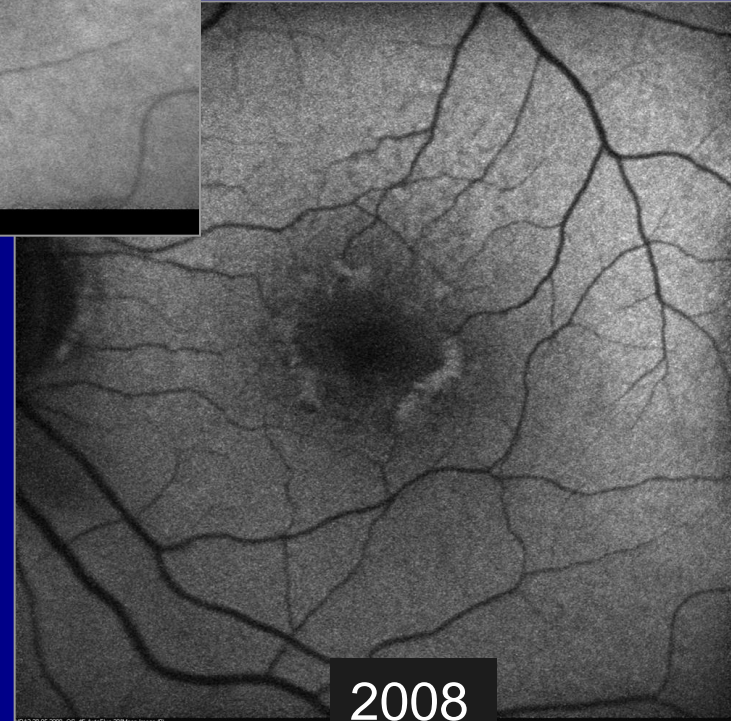
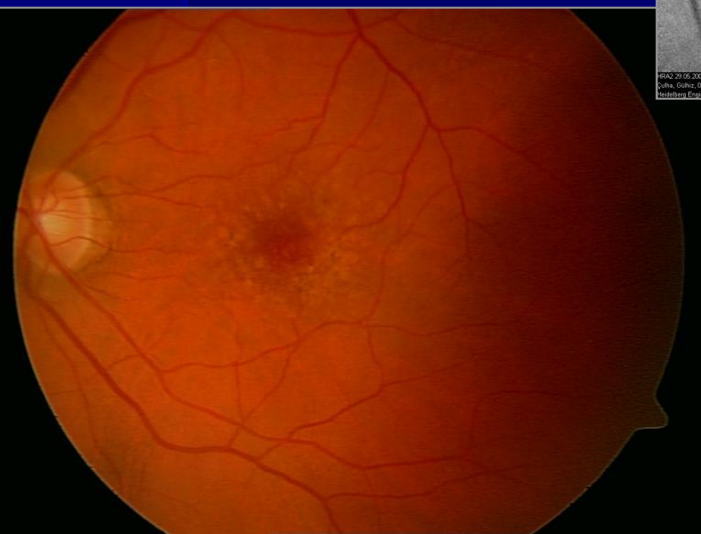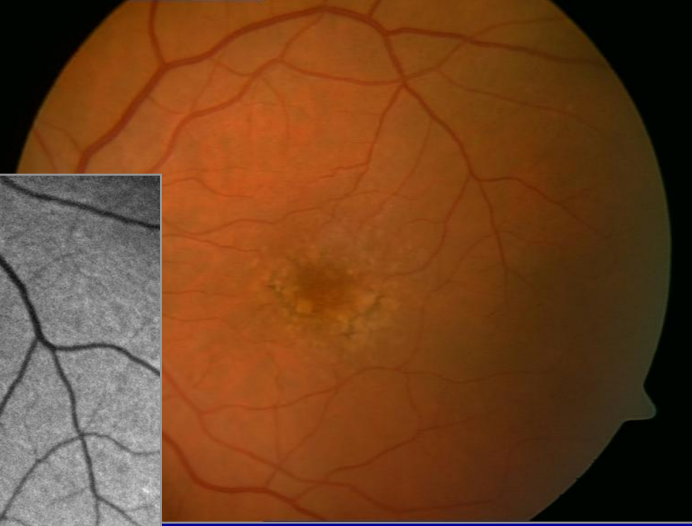2006

HRA2 26.01.2006, OS, #4 AutoFluo 30° Mean Image (F)
Çulha, Gülhiz, 01.01.1939, #659623
Heidelberg Engineering



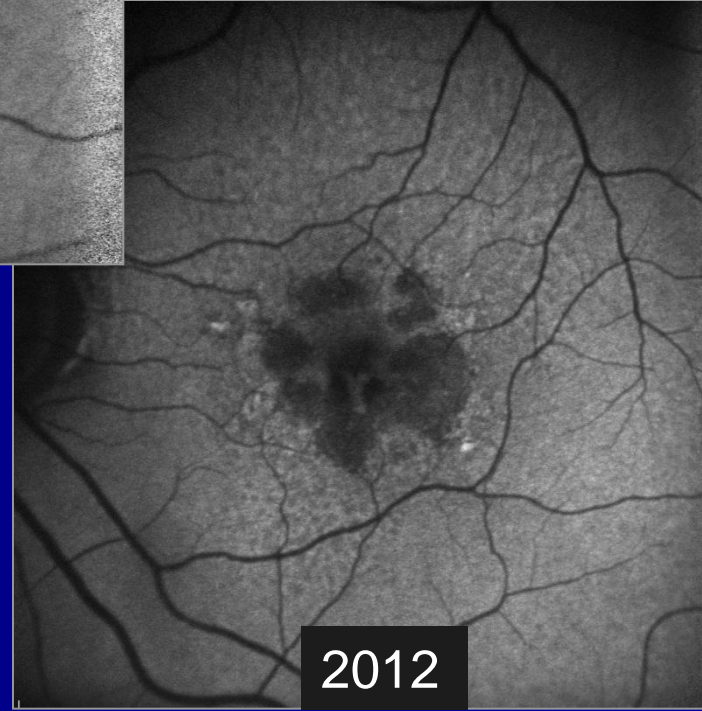
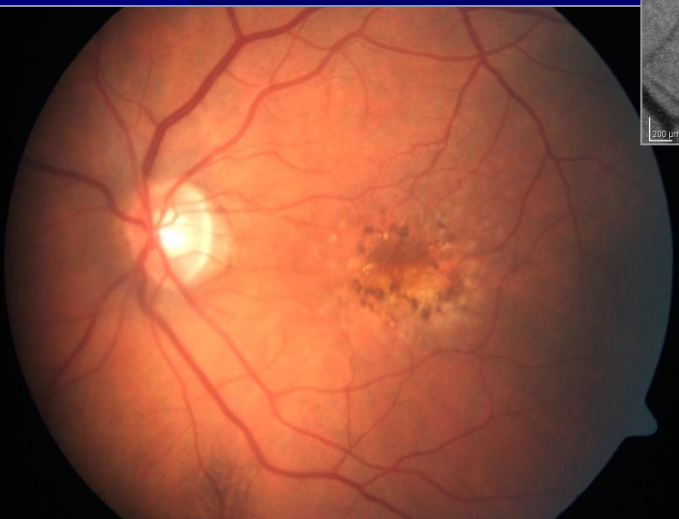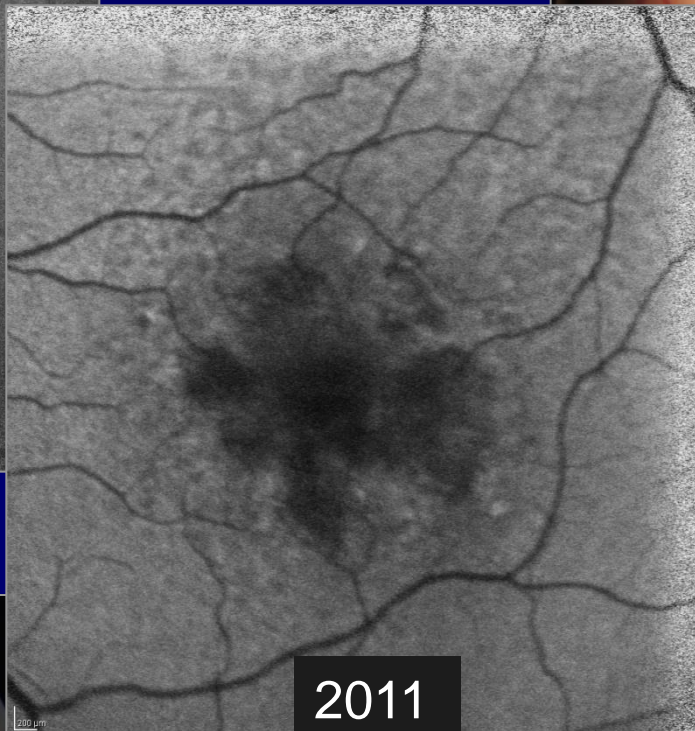
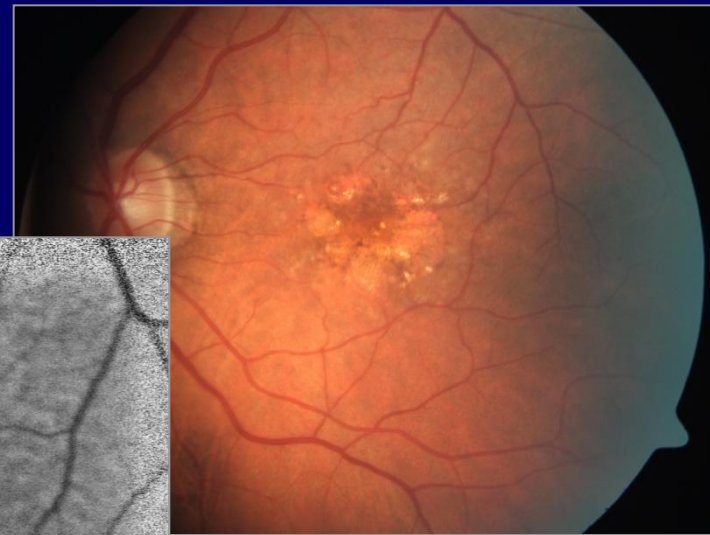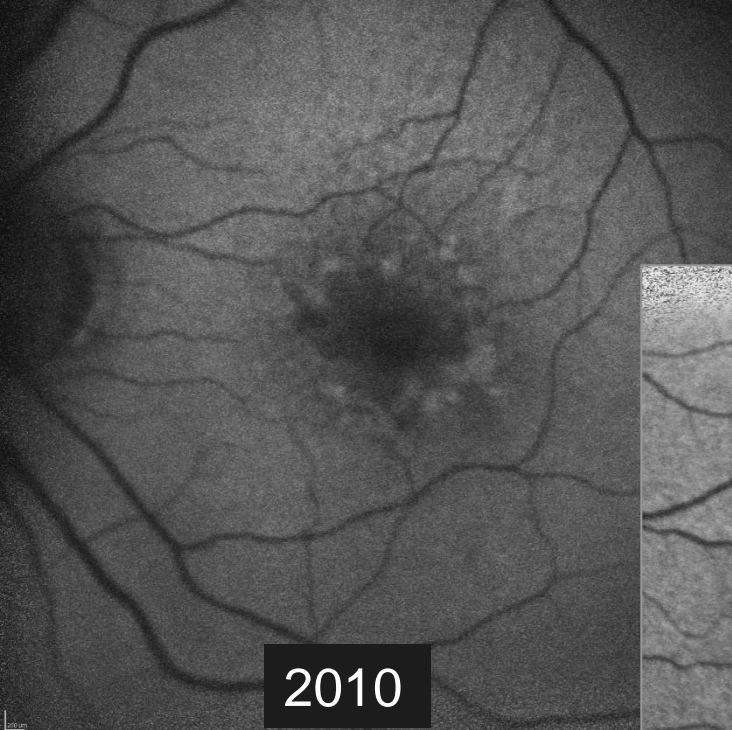
2007

HRA2 21.05.2007, OS, #6 AutoFluo 30° Mean Image (F)
Çulha, Gülhiz, 01.01.1939, #659623
Heidelberg Engineering

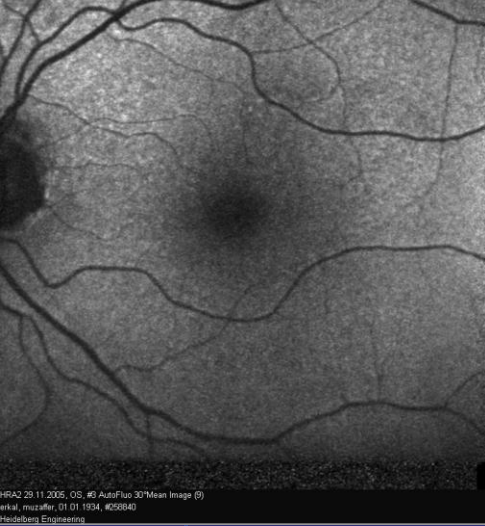

2008

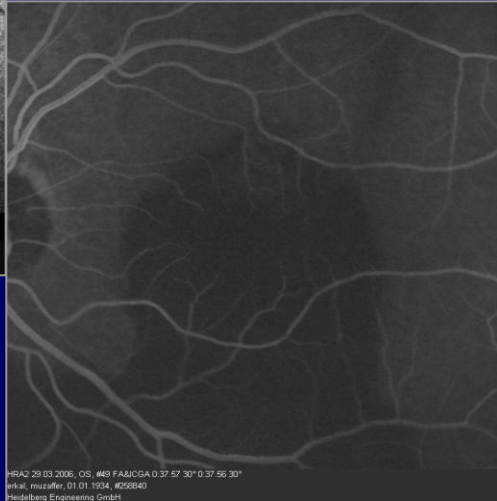
HRA2 21.05.2008, OS, #6 AutoFluo 30° Mean Image (F)
Çulha, Gülhiz, 01.01.1939, #659623
Heidelberg Engineering



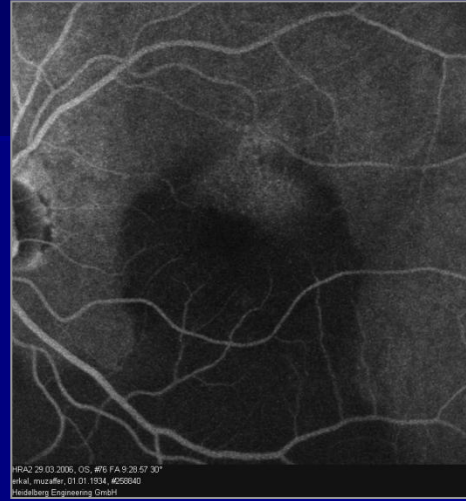
4 months later



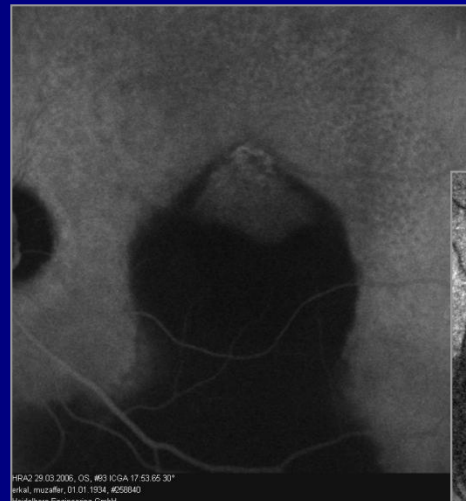
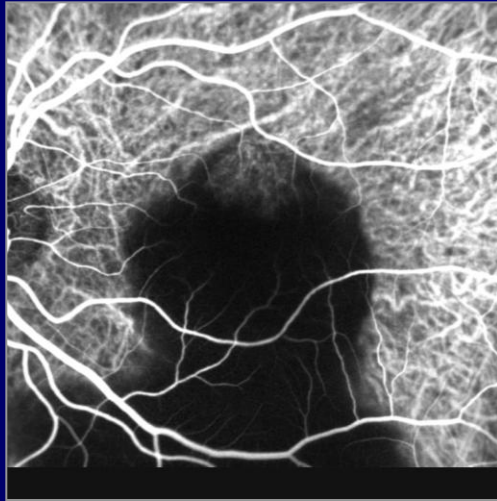
HRA2 28.11.2005, OS, #5 AutoFluo 30**Mean Image (9)
HKA1, muzafter, 01.01.1934, #258840
Heidelberg Engineering



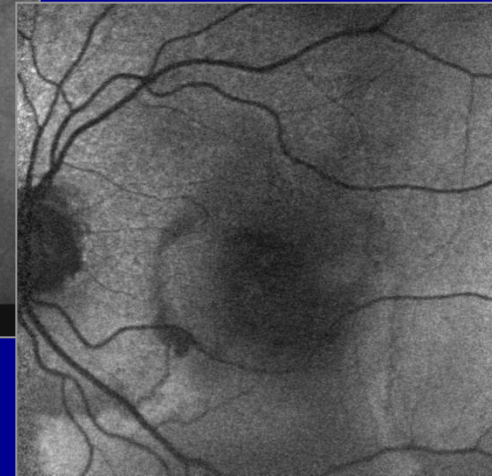
HRA2 29.03.2006, OS, #65 FA/ICGA 0:37:57 30* 0:37:56 30*
HKA1, muzafter, 01.01.1934, #258840
Heidelberg Engineering GmbH



HRA2 29.03.2006, OS, #76 FA 9:28:57 30*
HKA1, muzafter, 01.01.1934, #258840
Heidelberg Engineering GmbH



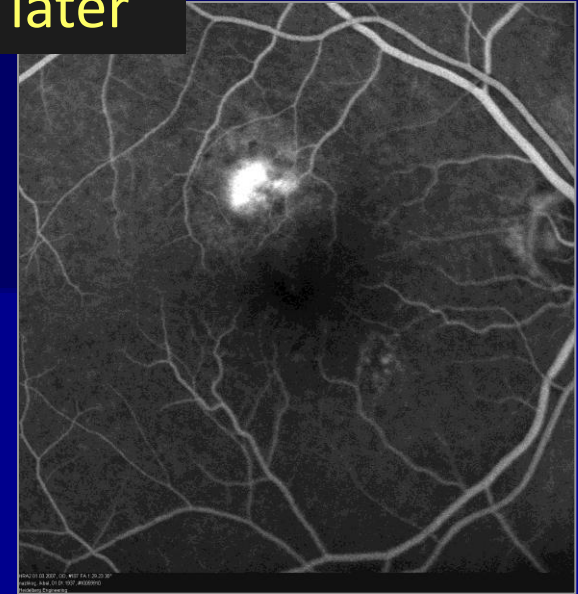
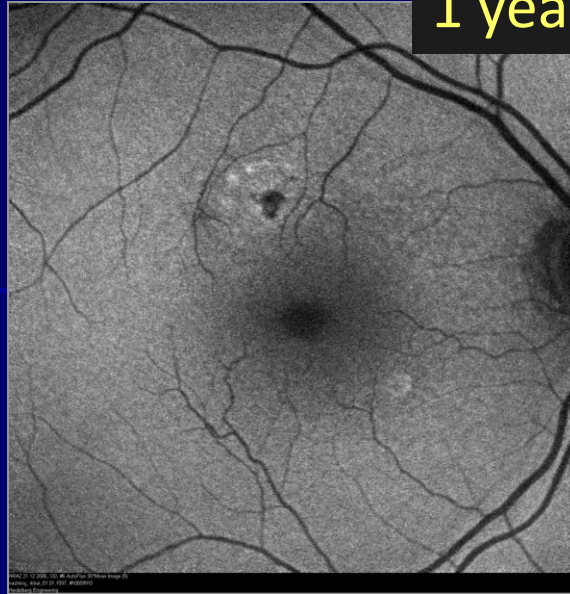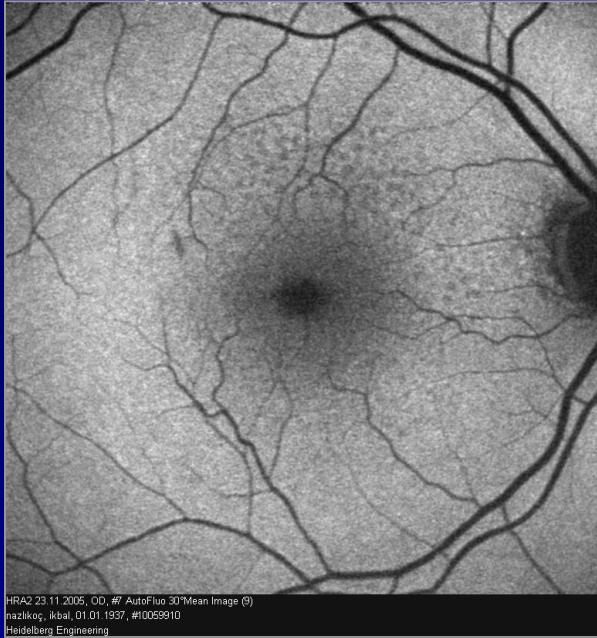
HRA2 29.03.2006, OS, #63 ICGA 17:53:66 30*
HKA1, muzafter, 01.01.1934, #258840
Heidelberg Engineering GmbH



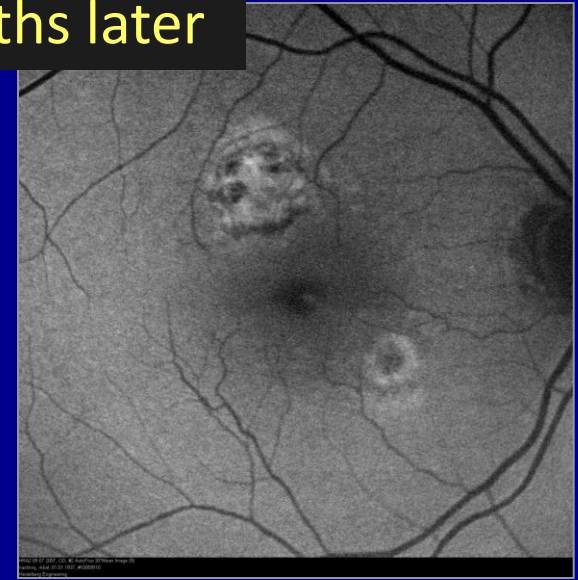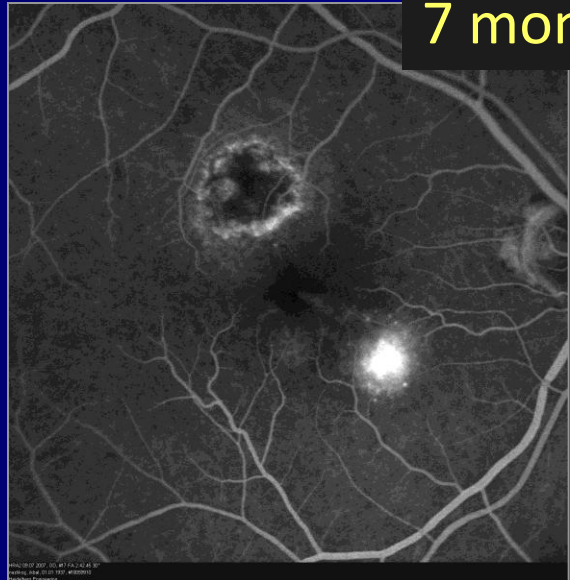
HRA2 29.03.2006, OS, #6 AutoFluo 30**Mean Image (9)
HKA1, muzafter, 01.01.1934, #258840
Heidelberg Engineering GmbH

Batioğlu (Şermet) F, et al. Optometry & Vision Science 2014

1 year later



7 months later



■ Yumuşak drusen olan 125 göz

■ Ort. 18 aylık izlemde ;

* **Yama** 6 göz (%4.8)

* Fokal plak 2 göz (1.6)

* Retiküler 1 göz (% 0.08)

eksudatif tipe
dönüş

■ Fokal artış, dantela, benekli, lineer patern olan gözlerde hiperpigmentasyon

■ Fokal 2 (%1.6)

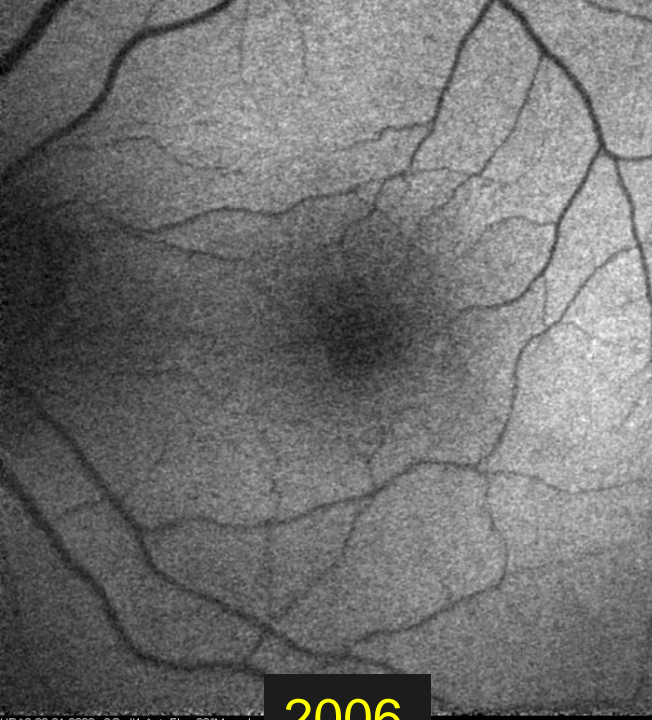
Fokal plak 1(%0.08)

geografik atrofi

Einbock W, et al. Graefe's Arch Clin Exp Ophthalmol 2004

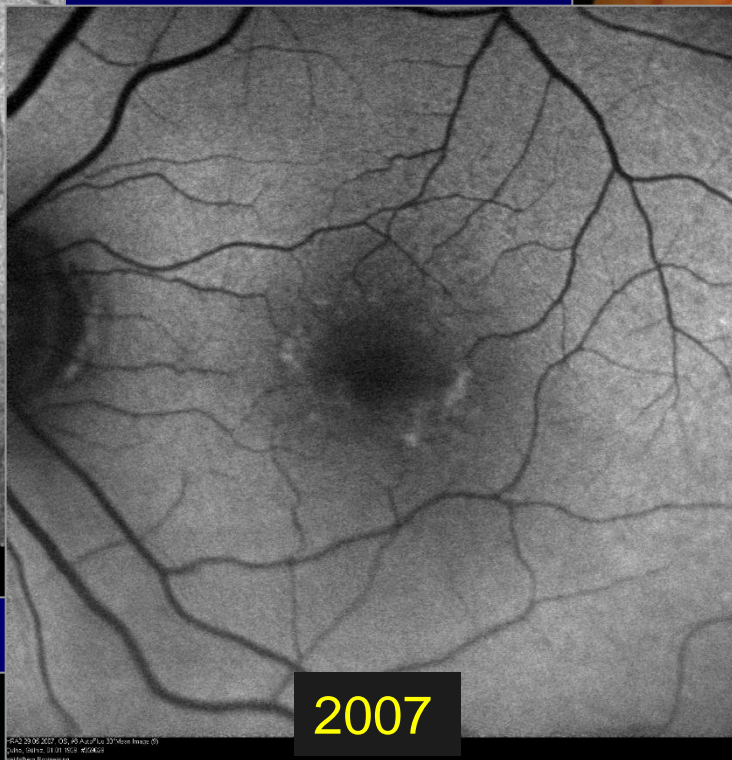
KLİNİĞİMİZ ÇALIŞMASI

- Çalışma süresi : 2005-2009
- Olgu sayısı : 93 (115 göz)
- Ort. yaş : 67.5 yıl (48-84)
- Ort. izlem : 25.2 ay
- Eksüdatif tipe geçiş : 14 (göz) (%12)
 - * 8/14 (%57) Retiküler
 - * 3/14 (%21) Yama
- Geçiş süresi : 35.1 ay



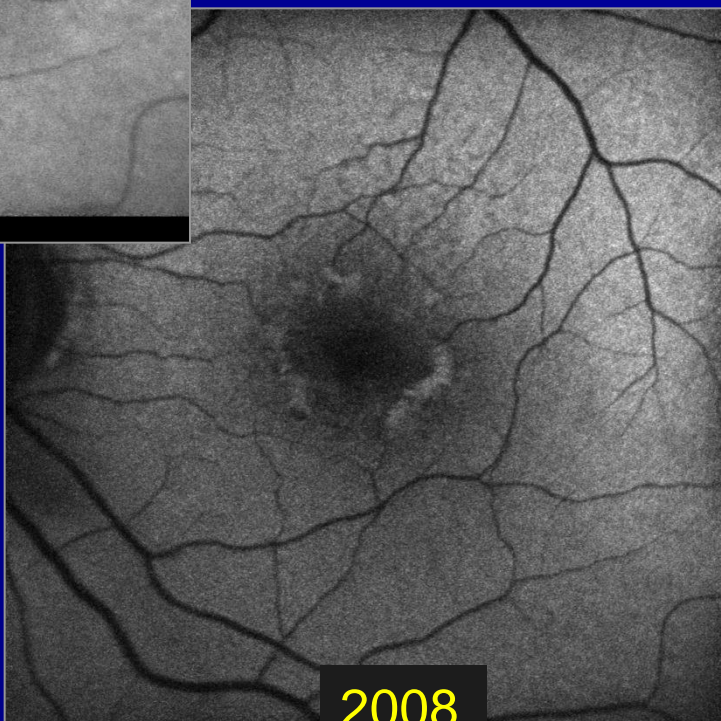
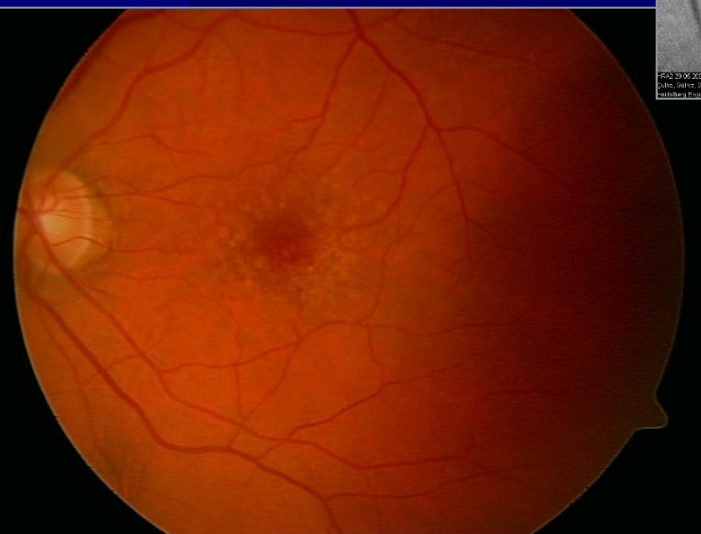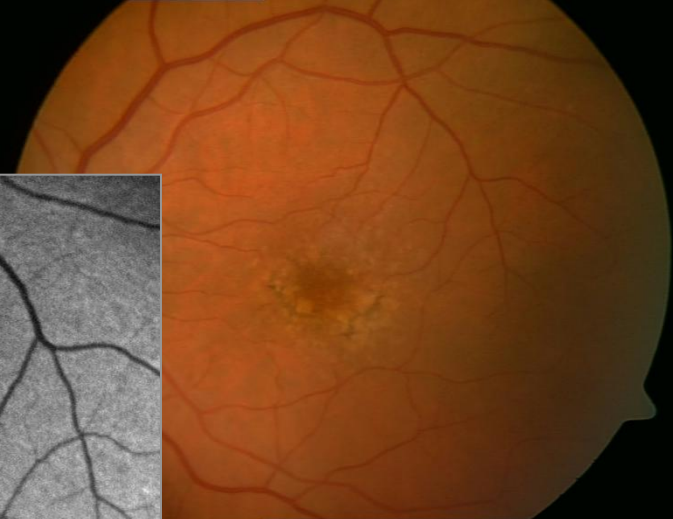2006

HRA2 26.01.2006, OS, #4 AutoFluo 30° Mean Im
Çulha, Gülhiz, 01.01.1939, #359623
Heidelberg Engineering



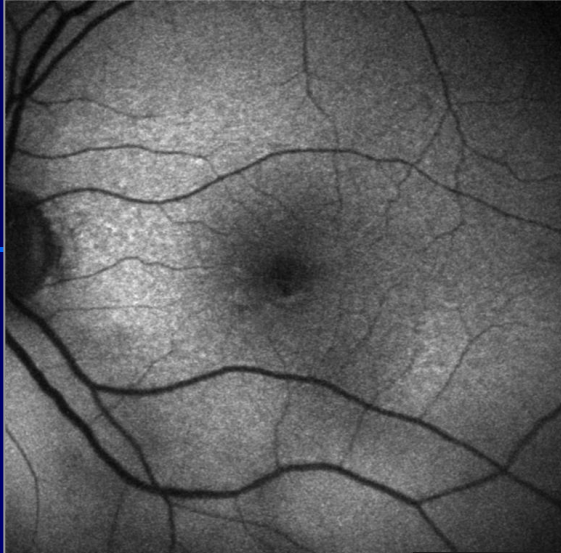2007

HRA2 20.06.2007, OS, #4 AutoFluo 30° Mean Im
Çulha, Gülhiz, 01.01.1939, #359623
Heidelberg Engineering

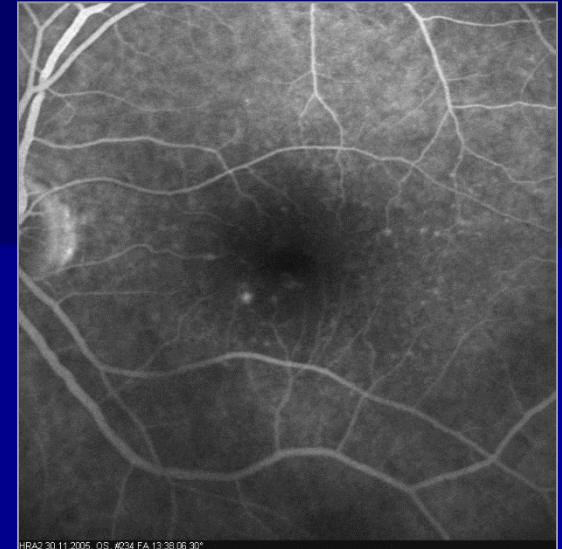
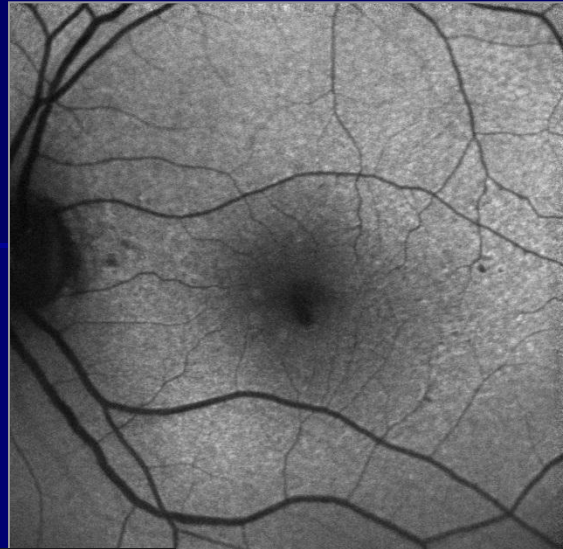

2008

HRA2 10.11.11, OS, #4 AutoFluo 30° Mean Im
Çulha, Gülhiz, 01.01.1939, #359623
Heidelberg Engineering

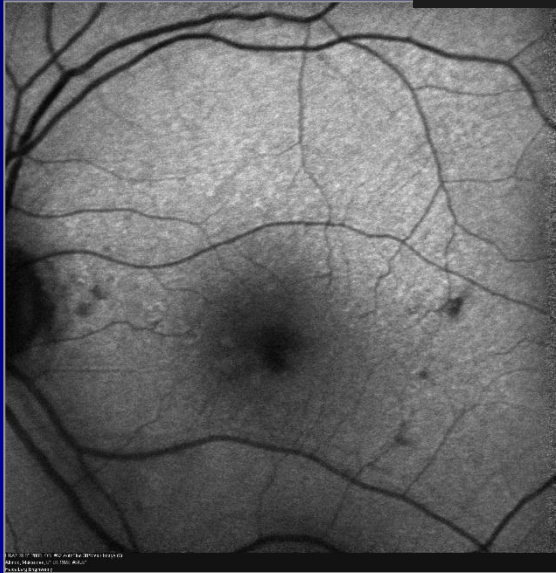

HRA2 30.11.2005, OS, #6 AutoFluo 30° Mean Image (9)
Altınok, Mukaddes, 01.01.1926, #64261
Heidelberg Engineering

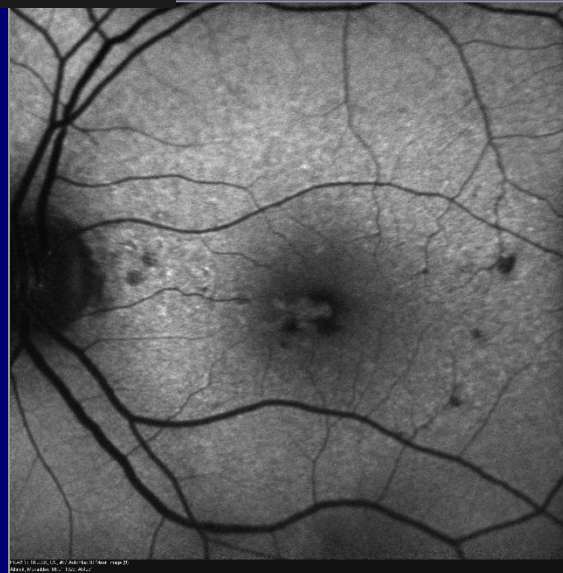


HRA2 30.11.2005, OS, #234 FA 13.38.06 30°
Altınok, Mukaddes, 01.01.1926, #64261
Heidelberg Engineering

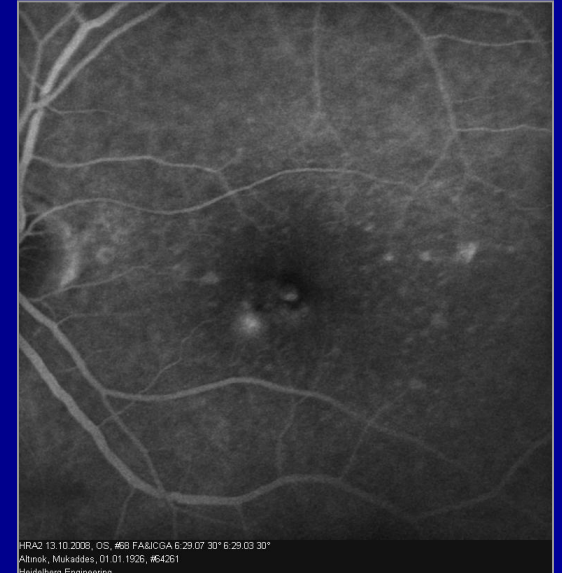3 yıl sonra



HRA2 13.10.2008, OS, #68 FA 13.38.06 30°
Altınok, Mukaddes, 01.01.1926, #64261
Heidelberg Engineering

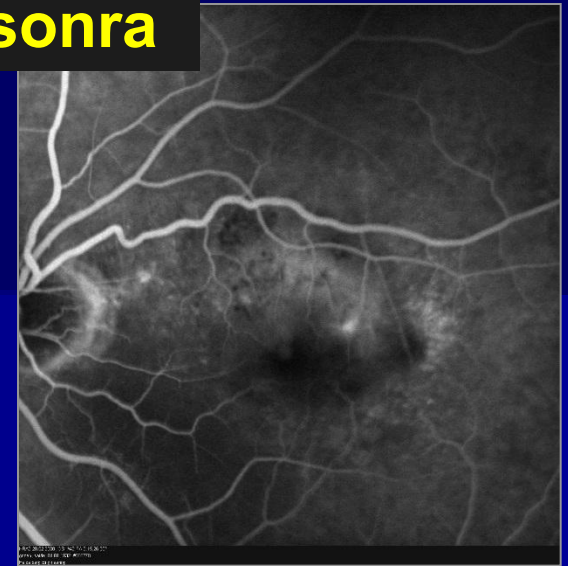
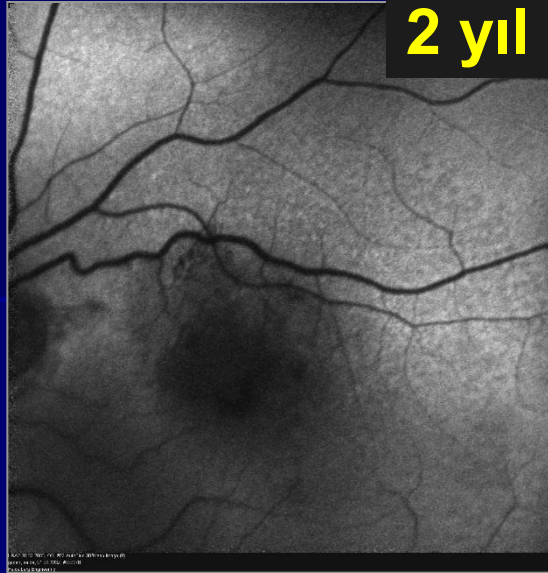


HRA2 13.10.2008, OS, #68 FA 13.38.06 30°
Altınok, Mukaddes, 01.01.1926, #64261
Heidelberg Engineering

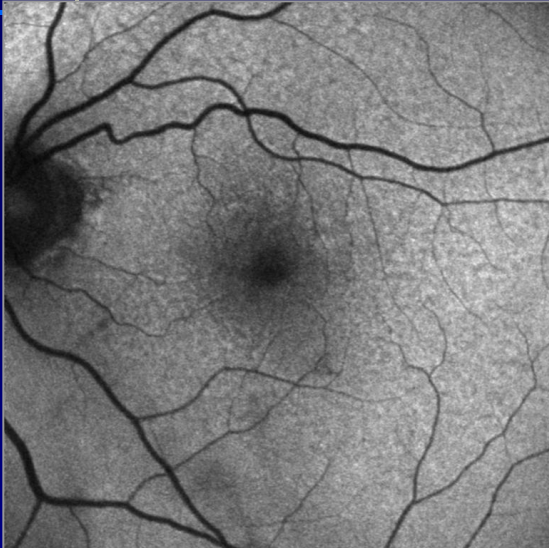
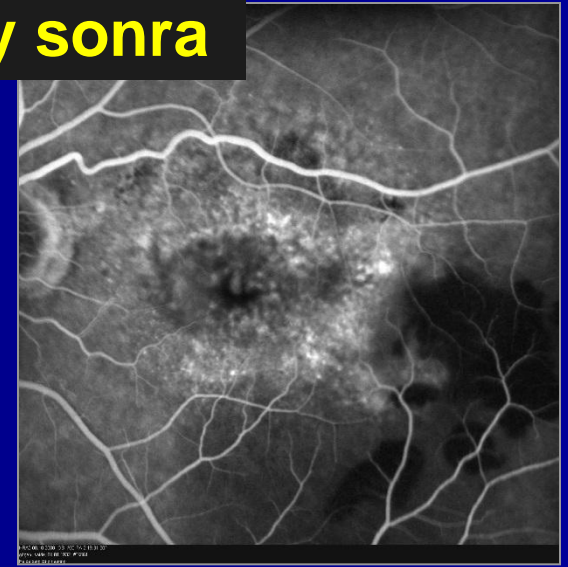
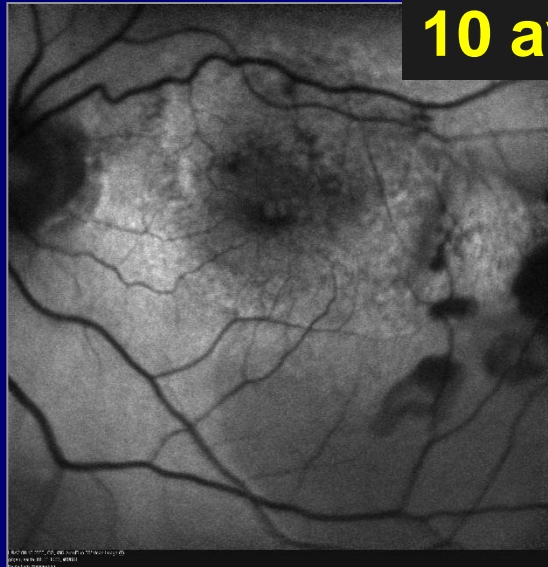


HRA2 13.10.2008, OS, #68 FA 13.38.06 30°
Altınok, Mukaddes, 01.01.1926, #64261
Heidelberg Engineering

2 yıl sonra



10 ay sonra

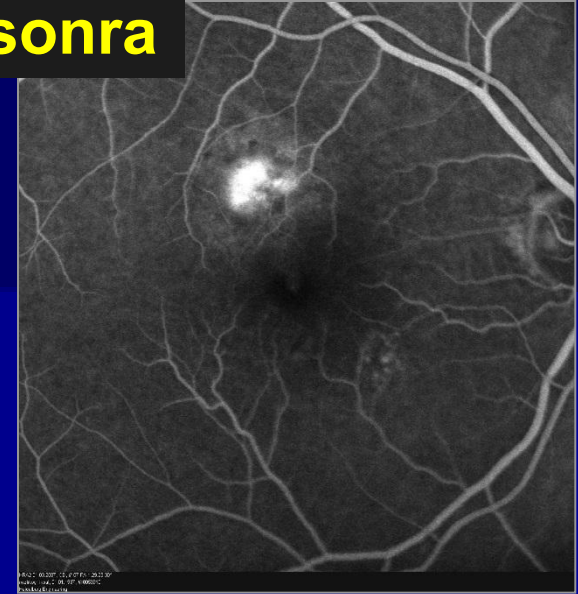
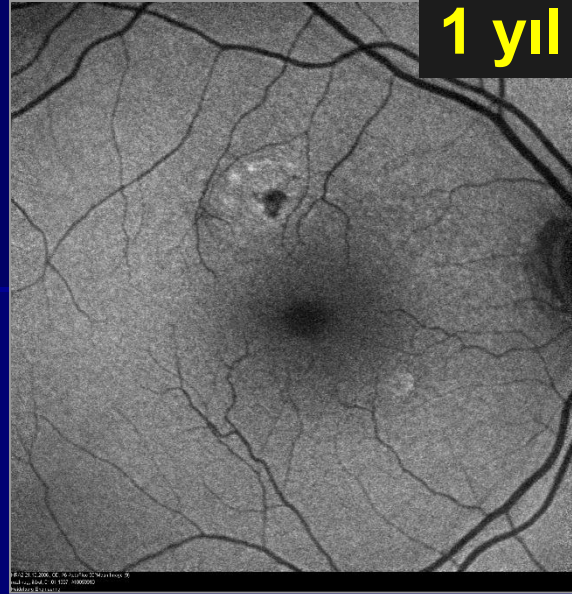


HR22 16.01.2008, 05:40 Adof Iuo 30° Mean Image (9)
ipoten, Saldig, 01.01.1952, #506278
Heidelberg Engineering

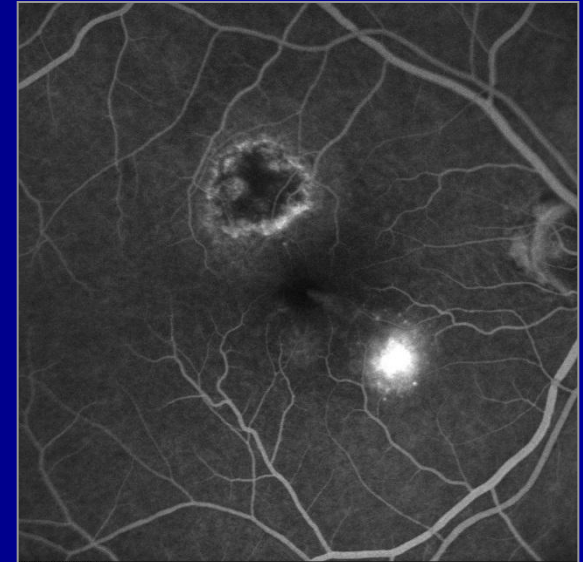
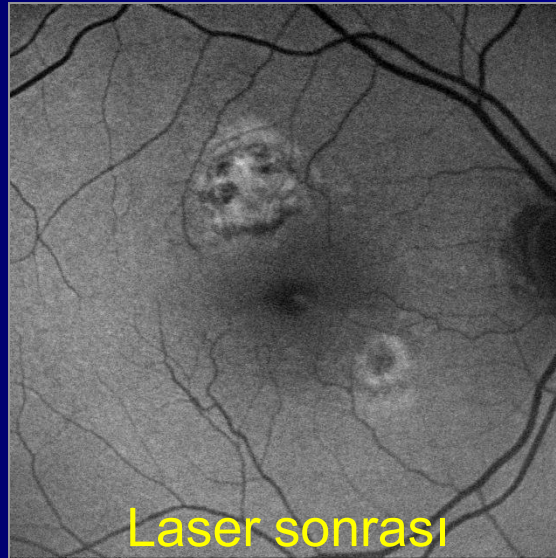
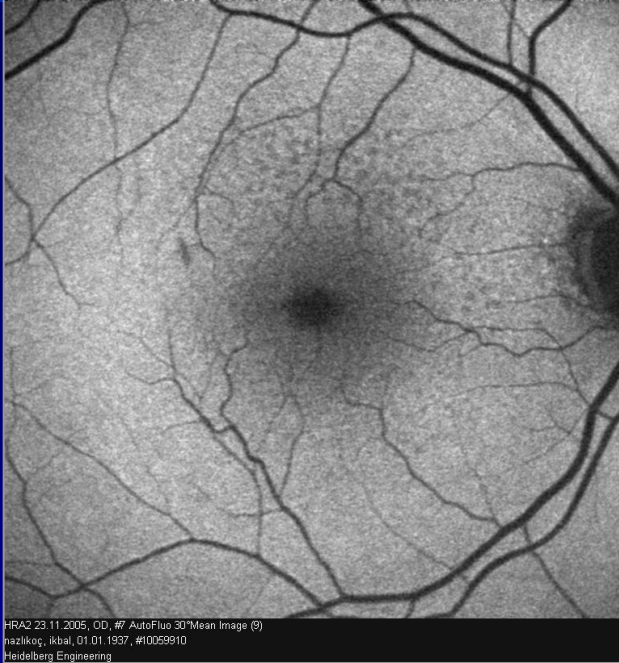HR22 16.01.2008, 05:40 Adof Iuo 30° Mean Image (9)
ipoten, Saldig, 01.01.1952, #506278
Heidelberg Engineering

HR22 16.01.2008, 05:40 Adof Iuo 30° Mean Image (9)
ipoten, Saldig, 01.01.1952, #506278
Heidelberg Engineering

1 yıl sonra



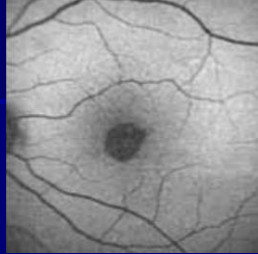
7 ay sonra



Geografik Atrofi

Geografik atrofi alanı dışında farklı paternler :

* Normal



* Fokal artış

* **Band şeklinde artış**

* Yama şeklinde artış

* **Diffüz artış** (en sık)

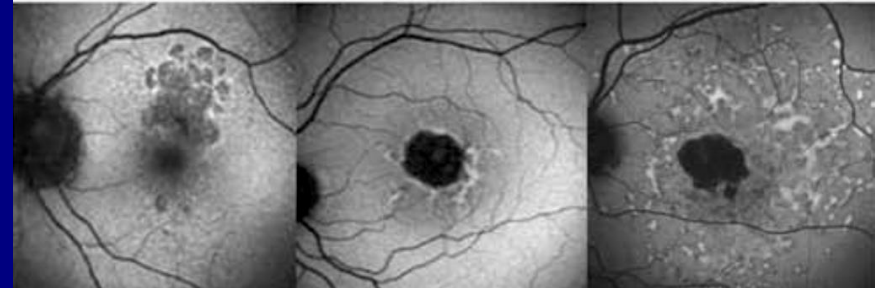
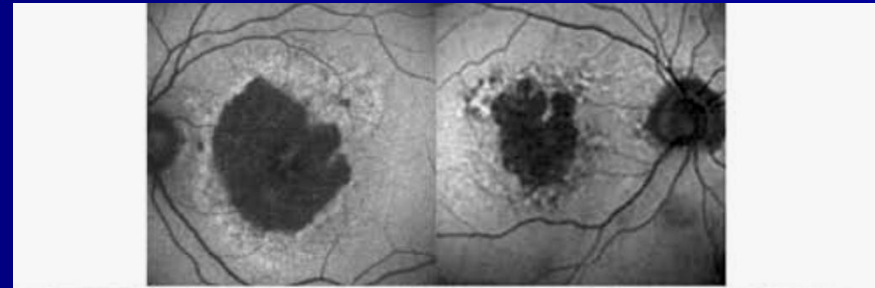
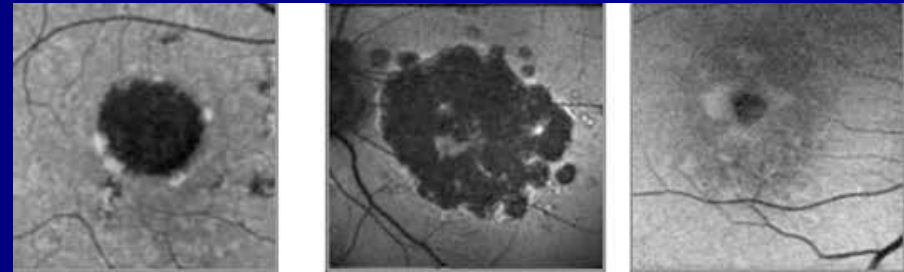
- İnce granüler

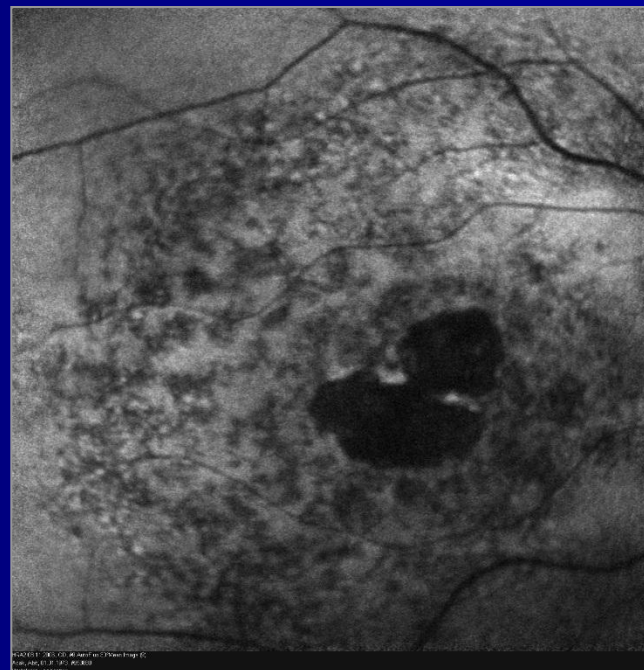
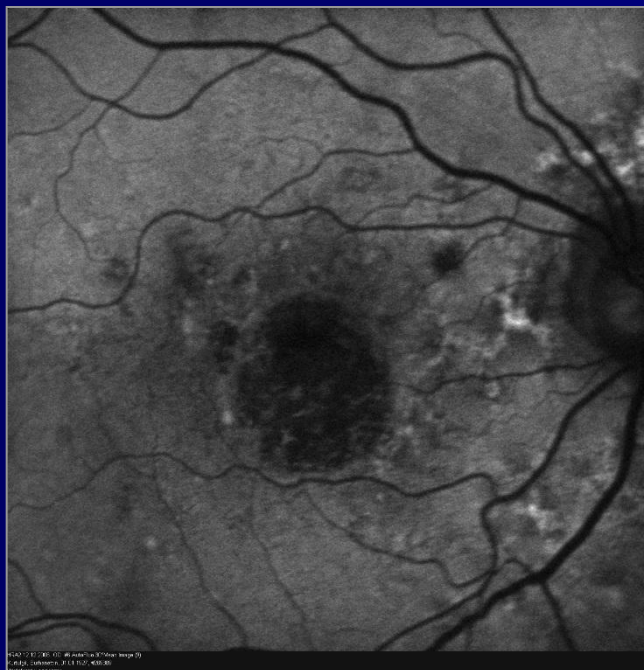
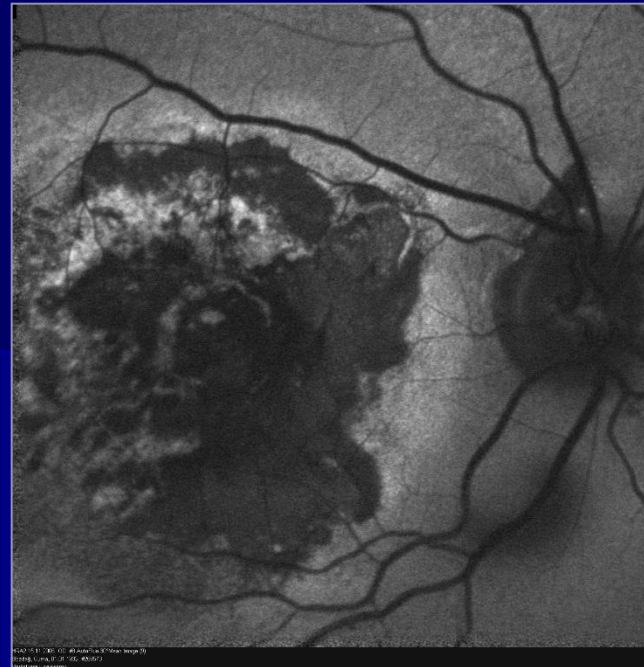
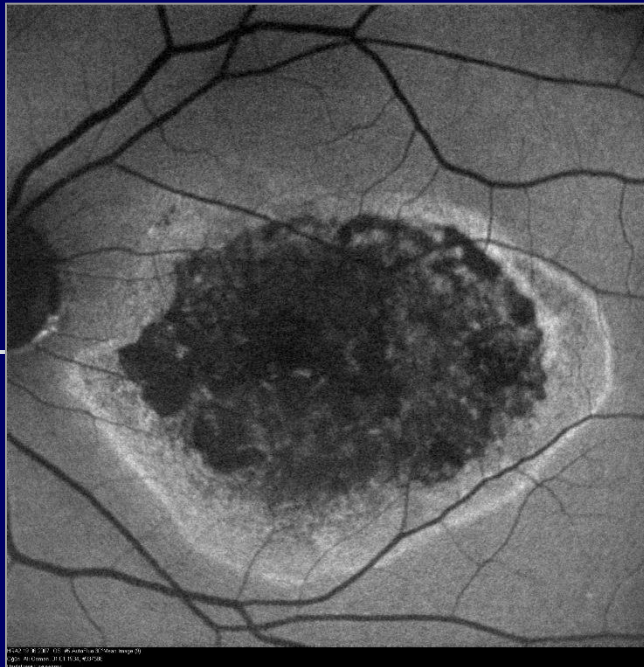
- Dallanmış

- **Damla (trickling)**

- Retiküler

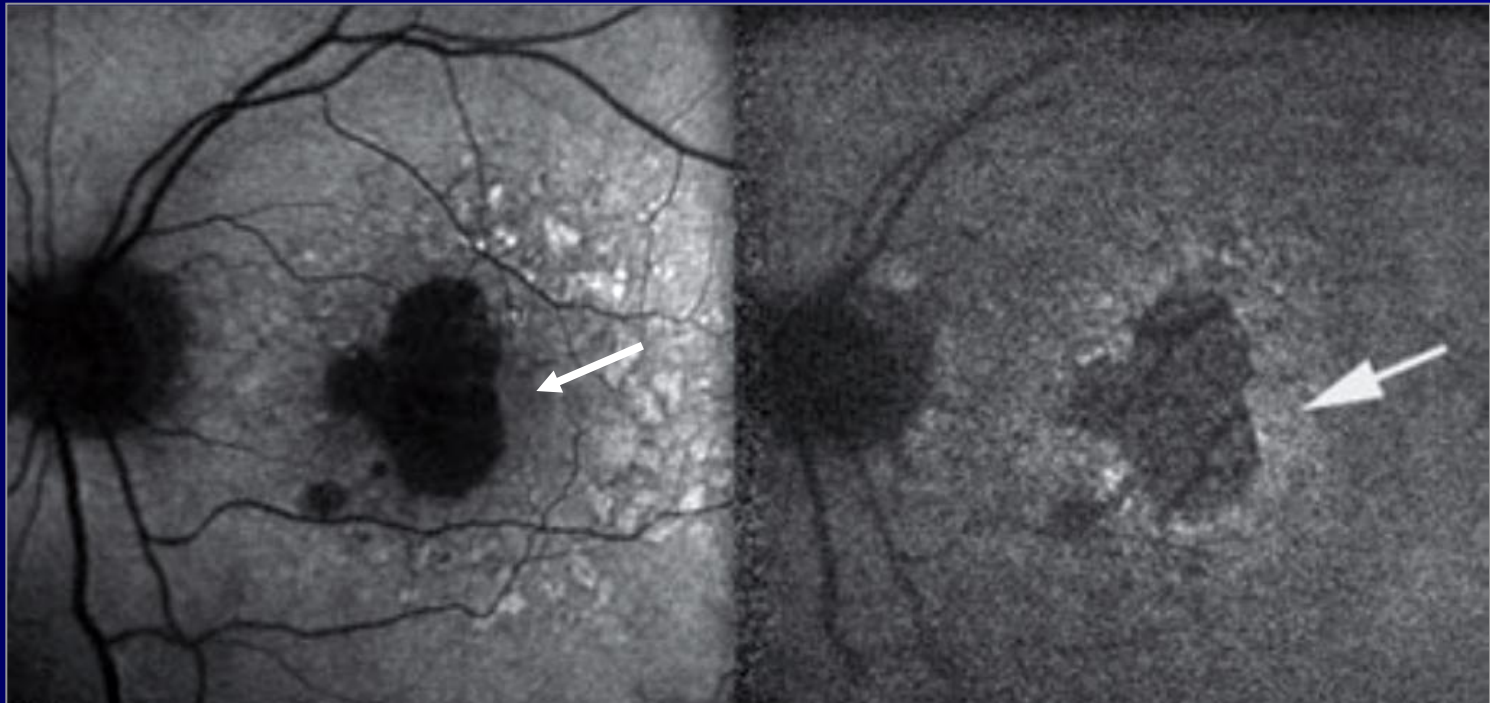
- Granüler + periferik
punktat spotlar

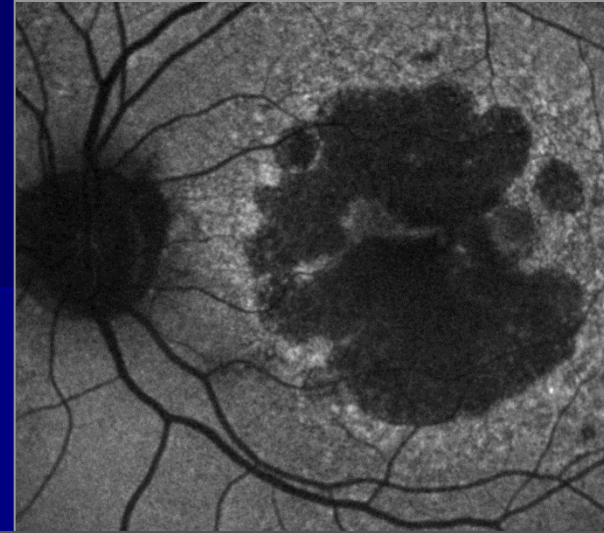
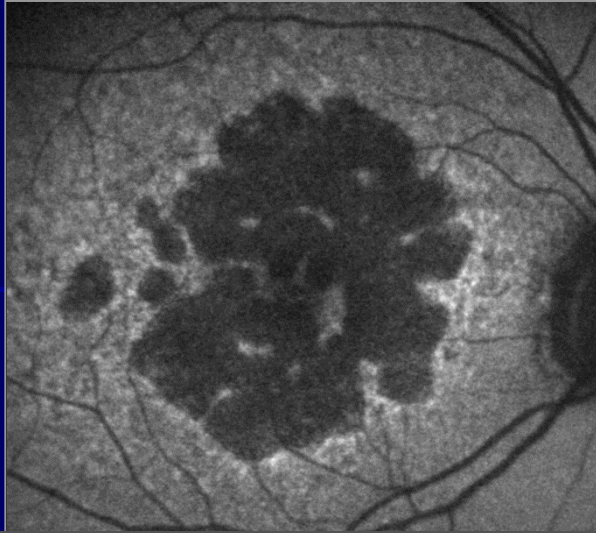




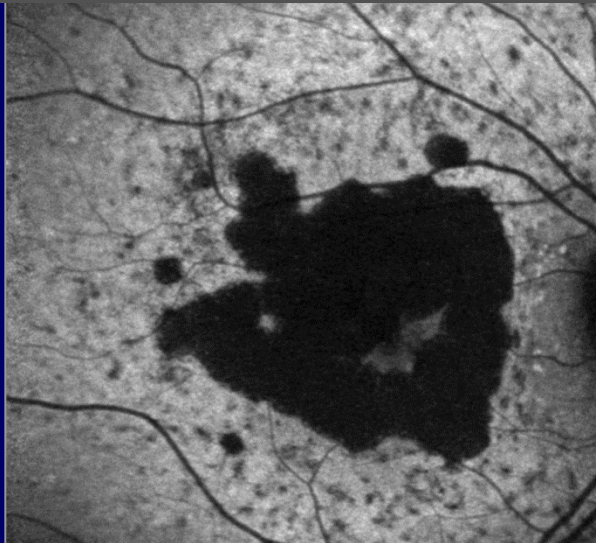
Geografik Atrofi – FOF (SW/NI)

- Atrofi alanında keskin kenarlı hipootoflöransans (etrafında deęişken otoflöransans)

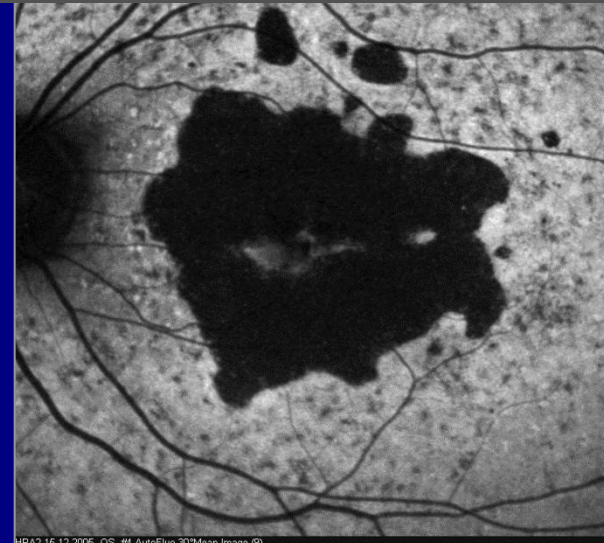




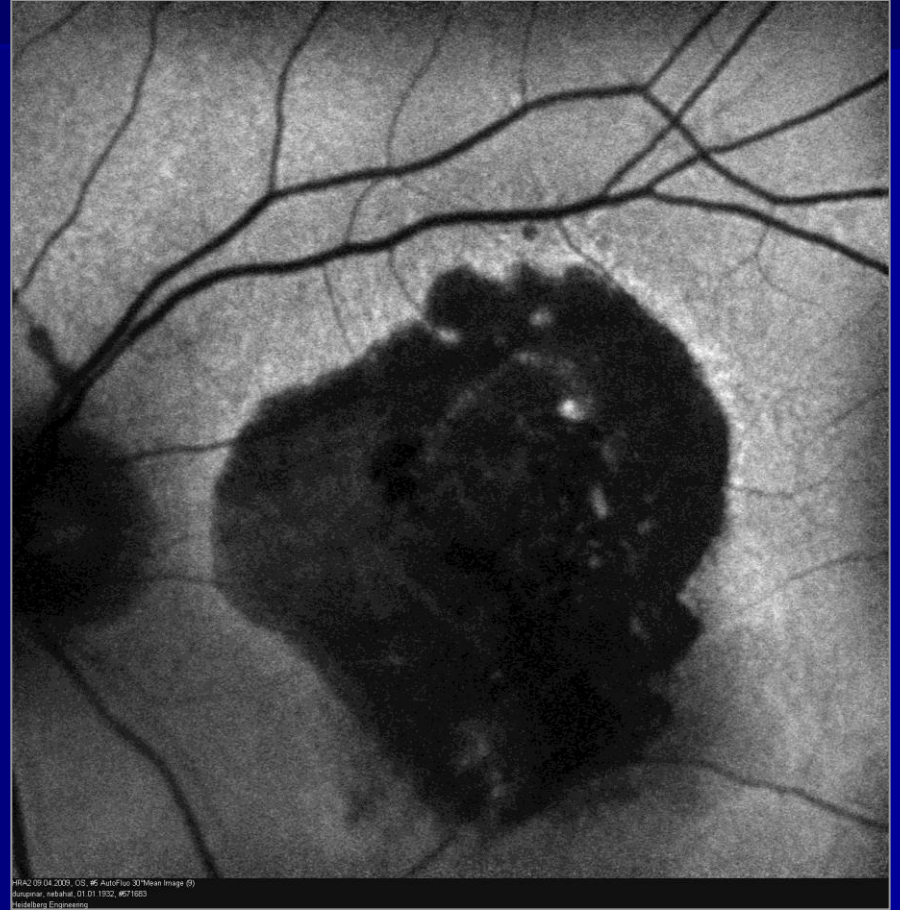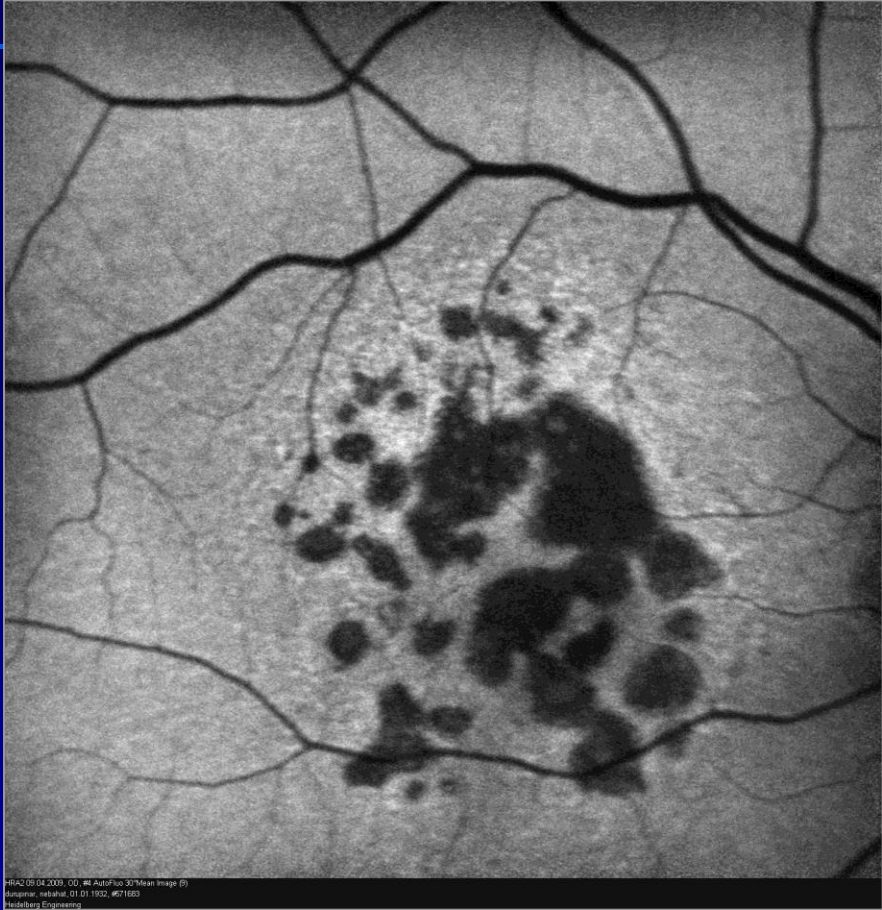
İki taraflı geografik atrofide yüksek oranda simetri



HRA2 15.12.2005, OD, #23 AutoFluo 30° Mean Image (9)
meta, sasma, 01.01.1935, #272424
Heidelberg Engineering GmbH



HRA2 15.12.2005, OS, #4 AutoFluo 30° Mean Image (9)
meta, sasma, 01.01.1935, #272424
Heidelberg Engineering GmbH



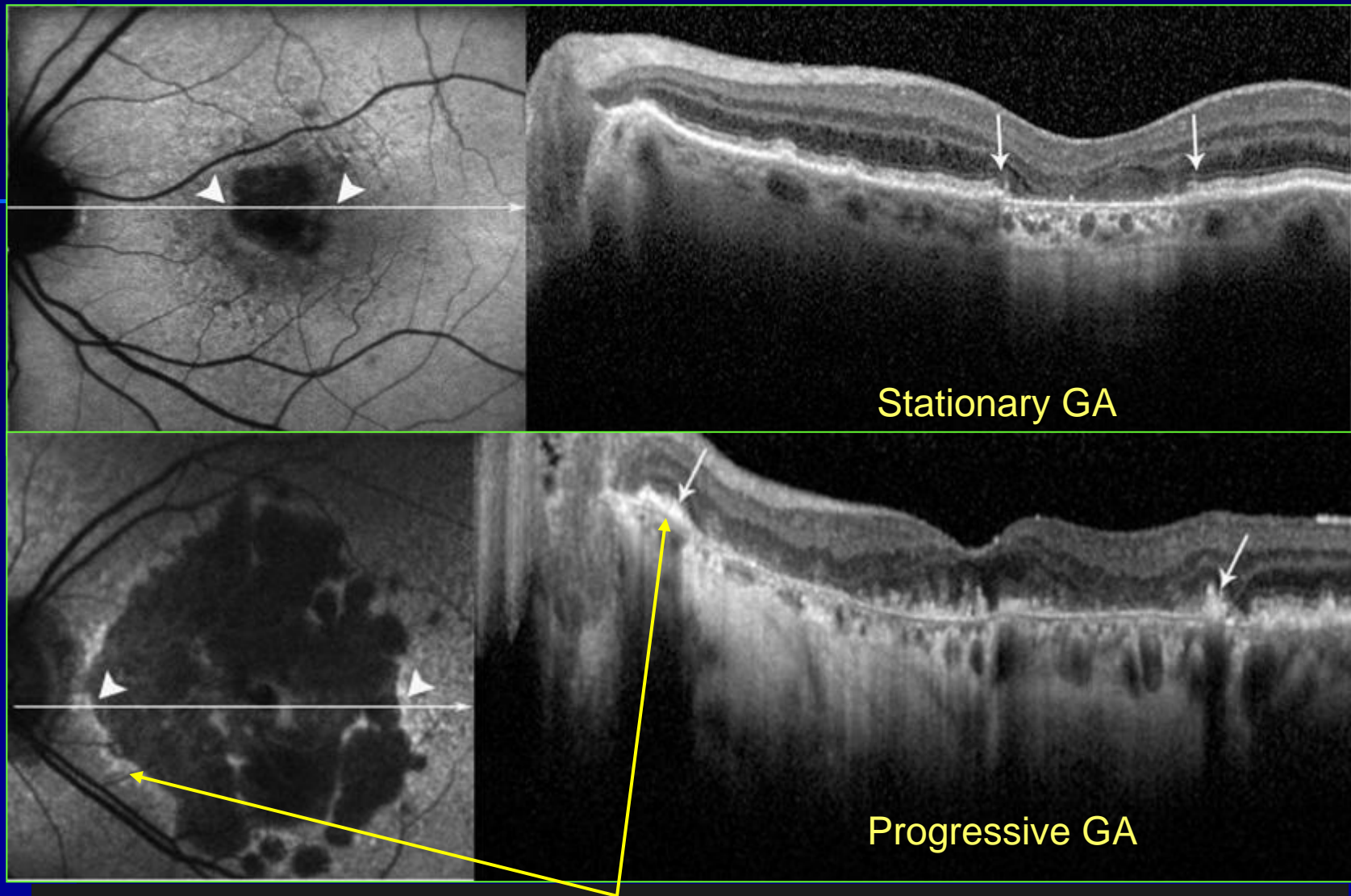
AYNI HASTANIN İKİ GÖZÜ / ASİMETRİK

Geografik Atrofi - FOF

- Geografik atrofi alanı dışında farklı otoflöresans paternleri → mevcut atrofinin farklı hızda ilerleme göstermesi
- Artmış otoflöresans => artmış lipofusin düzeyi → atrofi alanının genişlemesi, mikroperimetride azalmış retinal duyarlılık ile ilişkili
- **Etrafında otoflöresans değişikliği olmayan geografik atrofilerde ilerleme daha az**
- İki taraflı geografik atrofide simetrik FOF paterni → genetik kalıtım

YENİ GELİŐMELER

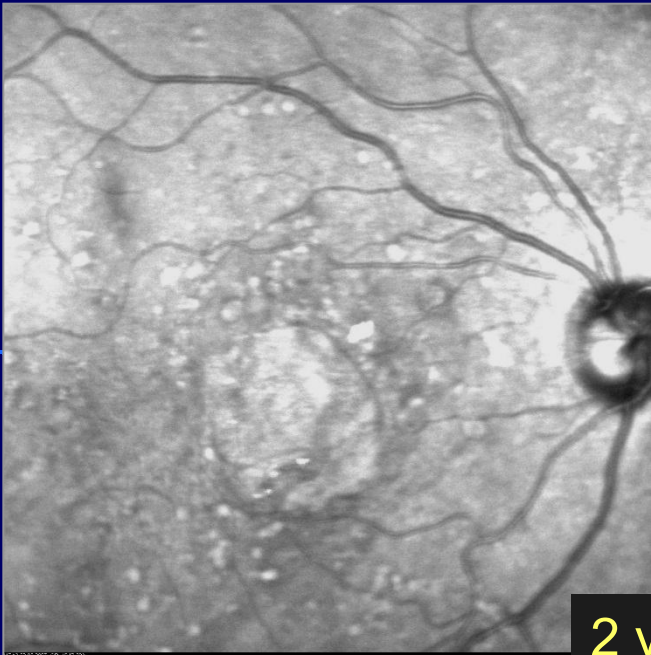
Geographic Atrophy - FAF / SD - OCT



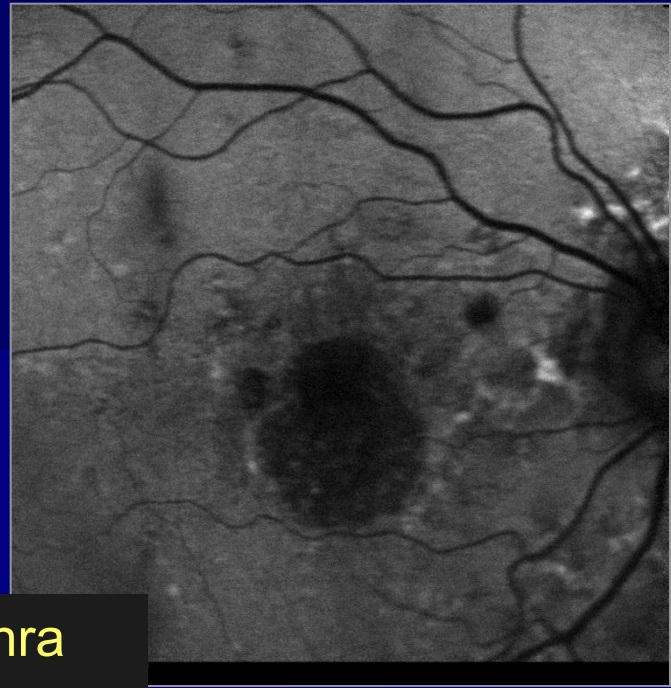
Stationary GA

Progressive GA

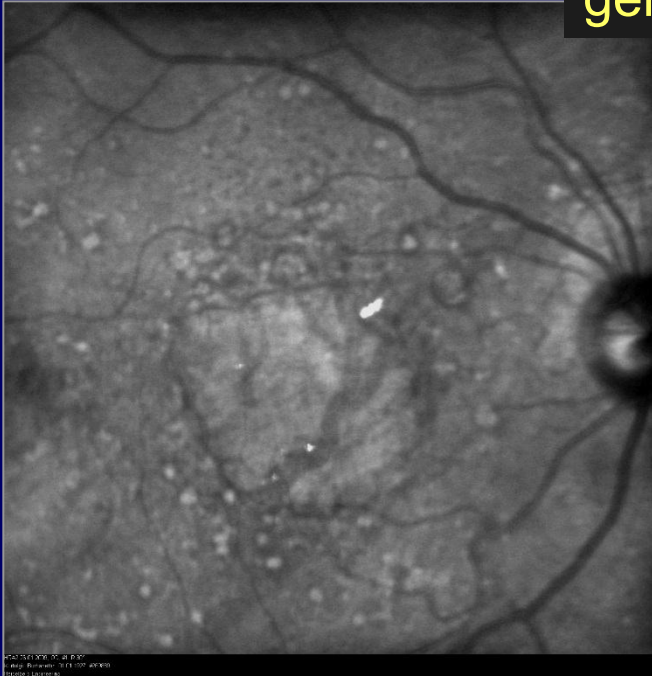
Ridge at the hyperautofluorescent zone surrounding geographic atrophy



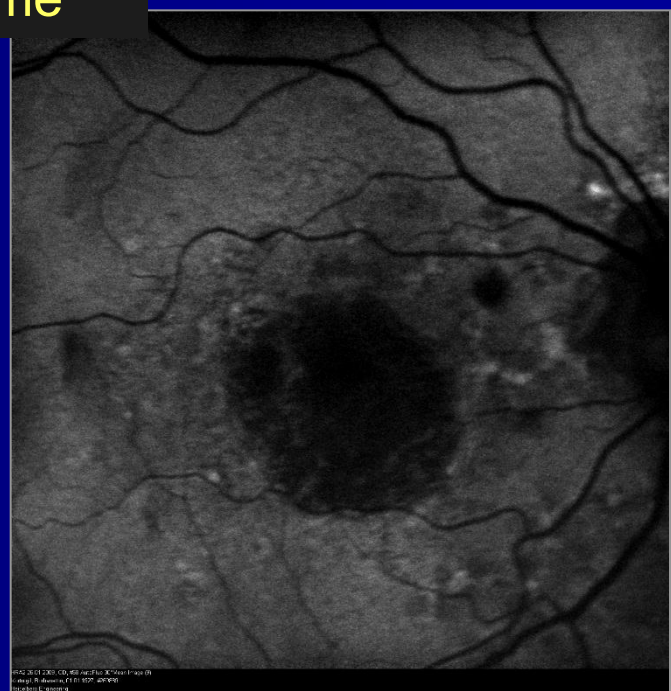
FA 13/07/07 06:47:33
1. Map: 13/07/07 06:47:33
13/07/07 06:47:33



2 yıl sonra
genişleme

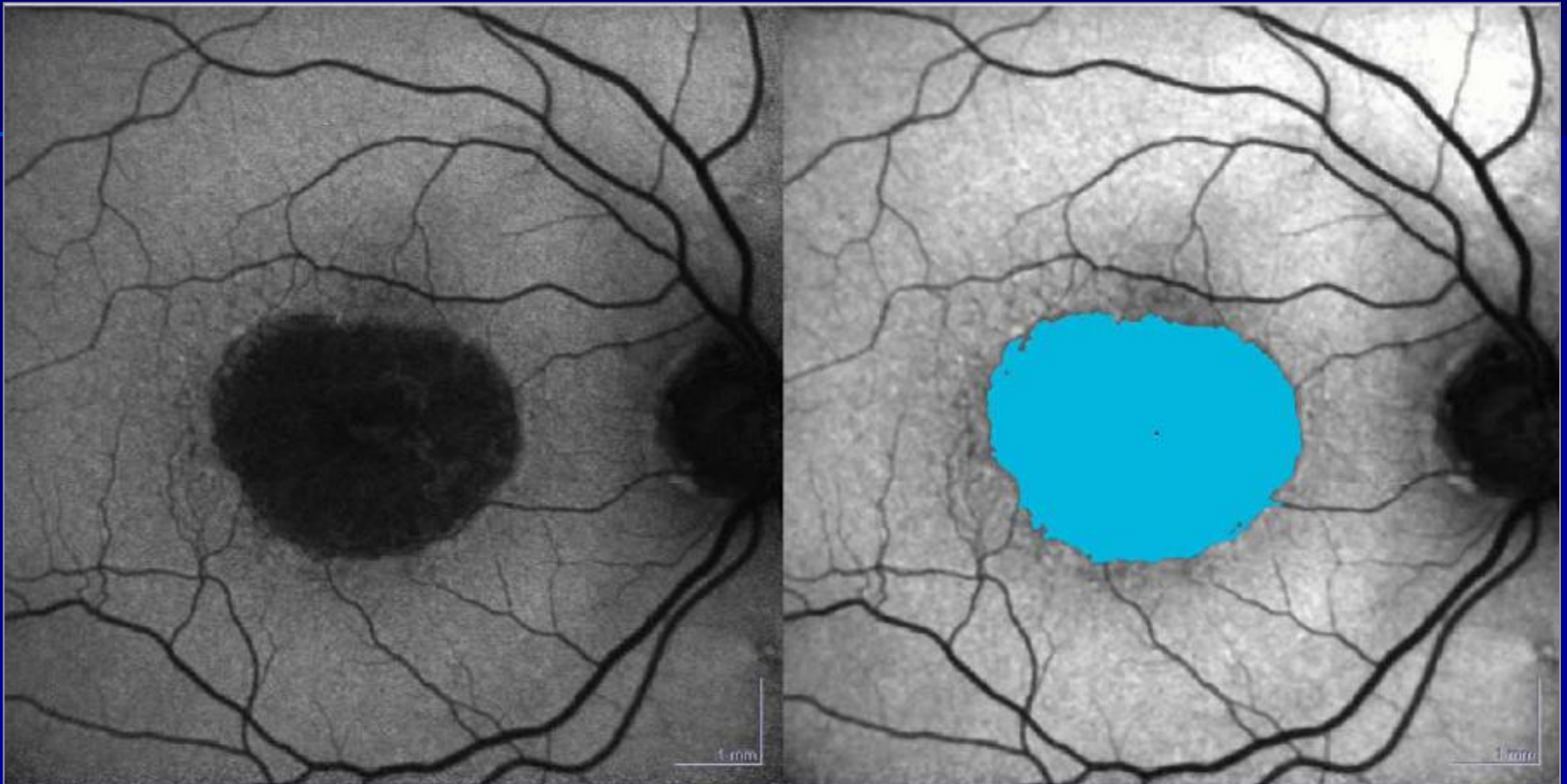


FA 13/07/07 06:47:33
1. Map: 13/07/07 06:47:33
13/07/07 06:47:33



FA 13/07/07 06:47:33
1. Map: 13/07/07 06:47:33
13/07/07 06:47:33

HRA2-RegionFinder



Results

Regions:

ID	Size [mm ²]
1	8.034

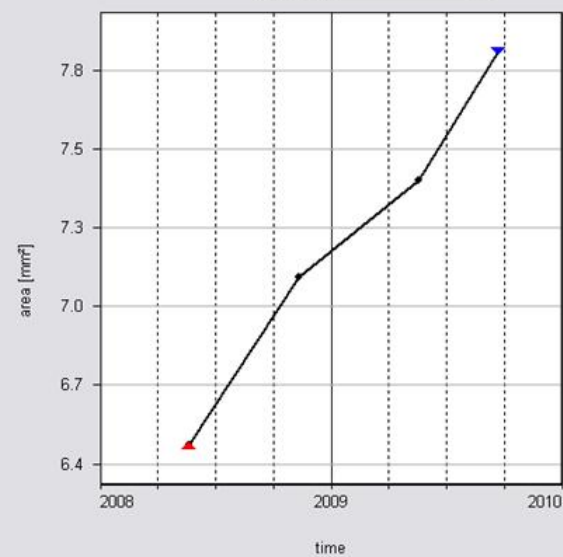
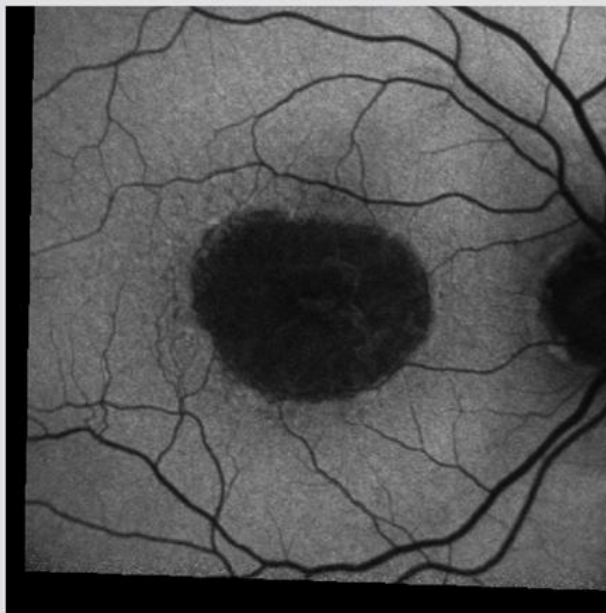
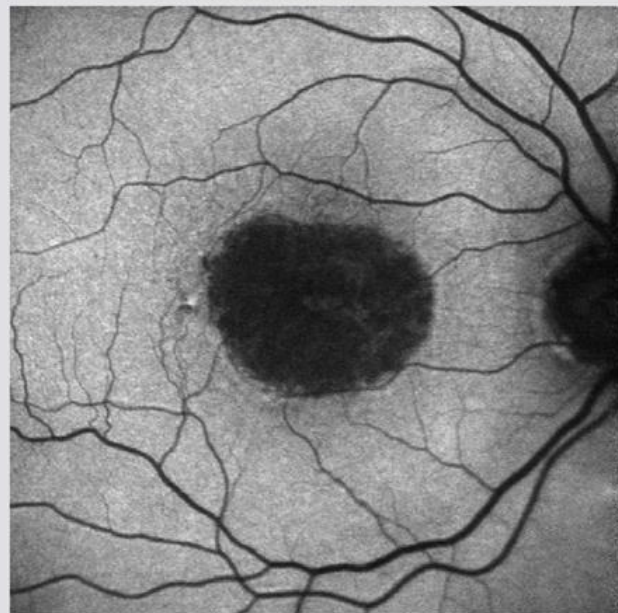
Total identified area size
8.034 mm² in
1 region (overall).

Software for semiautomated quantification of atrophic areas allowing reproducible and rapid detection and measurement of the size and progression

Reference image: 21.05.2008 AF 1(4)

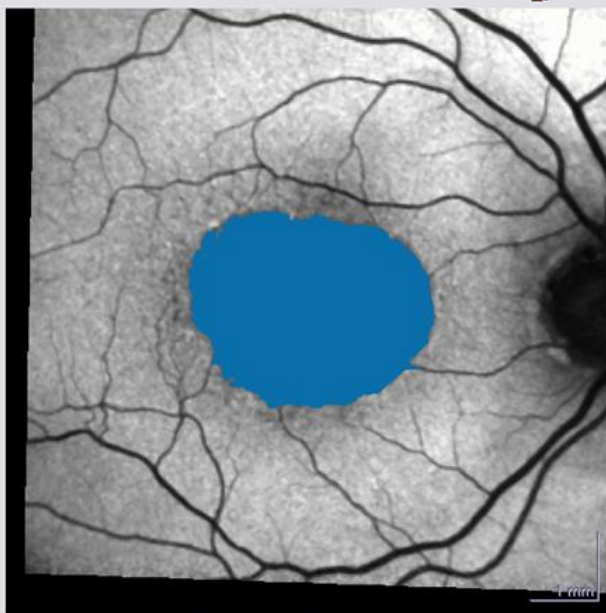
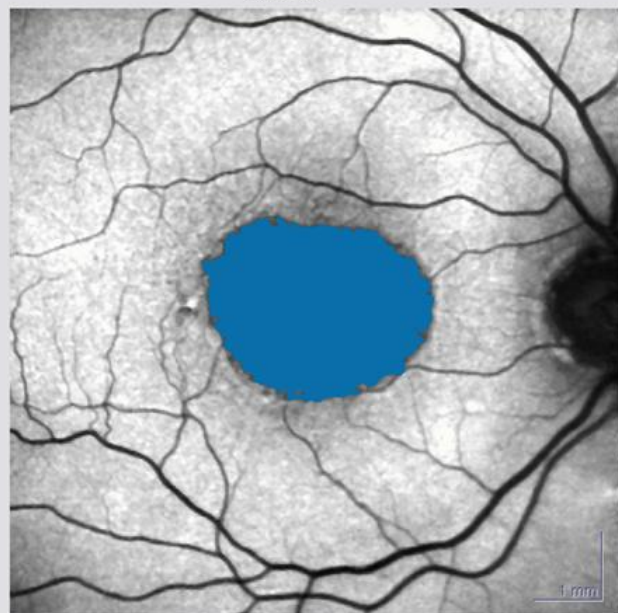
Follow-Up Image 22.09.2009 AF 4(4)

Analysis Parameter Total Area



21.05.2008

22.09.2009



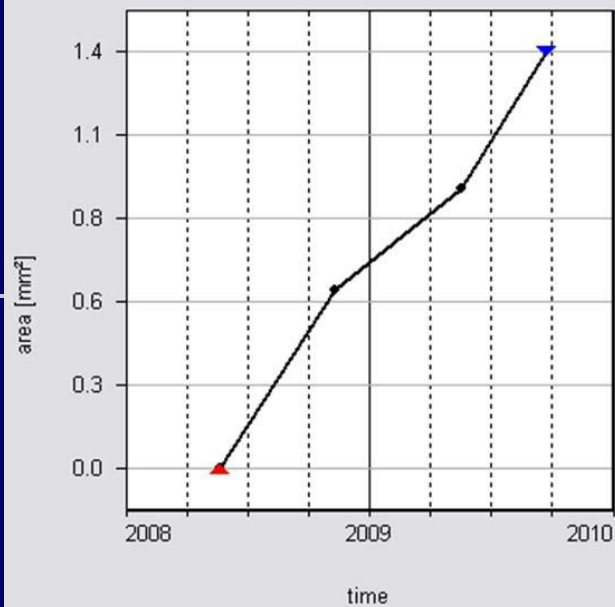
Analysis Summary

Date	No. Regions	Total Area [mm²]	Change from Reference [mm²]	Change from Previous Exam [mm²]	Change from Previous Exam [%]	Rate of Change [mm²/year]
21.05.2008	1	6.497	0.000	-	-	-
10.11.2008	1	7.092	0.596	0.596	9.2	1.264
18.05.2009	1	7.436	0.939	0.343	4.8	0.663
22.09.2009	1	7.894	1.398	0.459	6.2	1.318

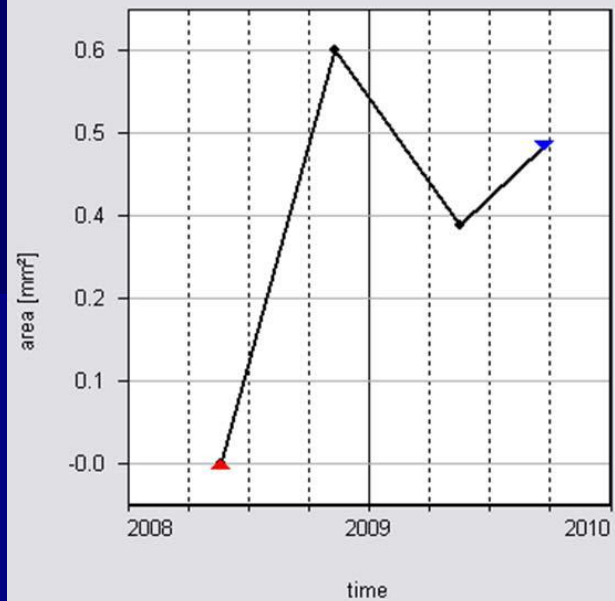
Total identified area size 6.497 mm² in 1 region (overall).

Total identified area size 7.894 mm² in 1 region (overall).

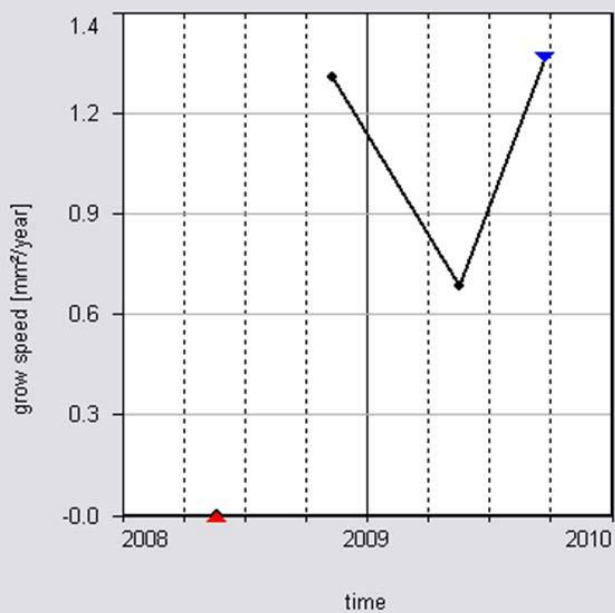
Analysis Parameter



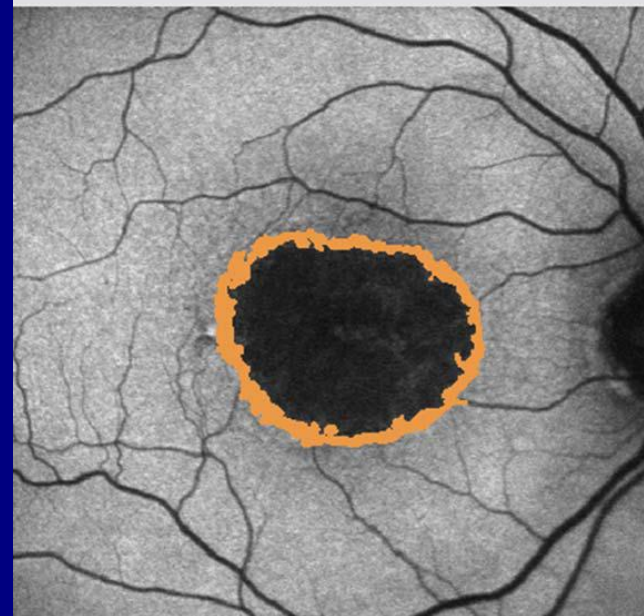
Analysis Parameter



Analysis Parameter

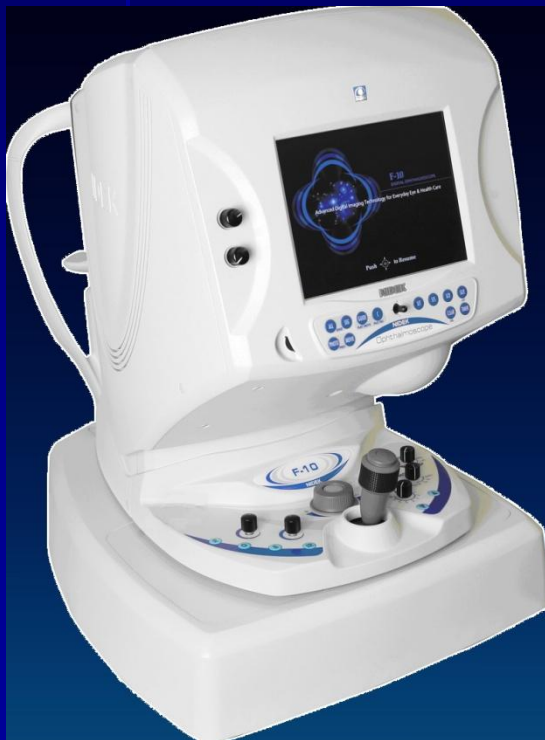

Analysis Parameter



Scanning laser ophthalmoscope

F10 / Digital Scanning Laser Ophthalmoscope



- Fluorescein Angiography
- Indocyanine Green Angiography
- Simultaneous FA/IA Angiography
- Non-Mydriatik IR
- **Non-invasive Retro Mode**
- Fundus Autofluorescence

Confocal aperture



Small aperture
1.5 mm

Wide aperture
7 mm

Annular aperture



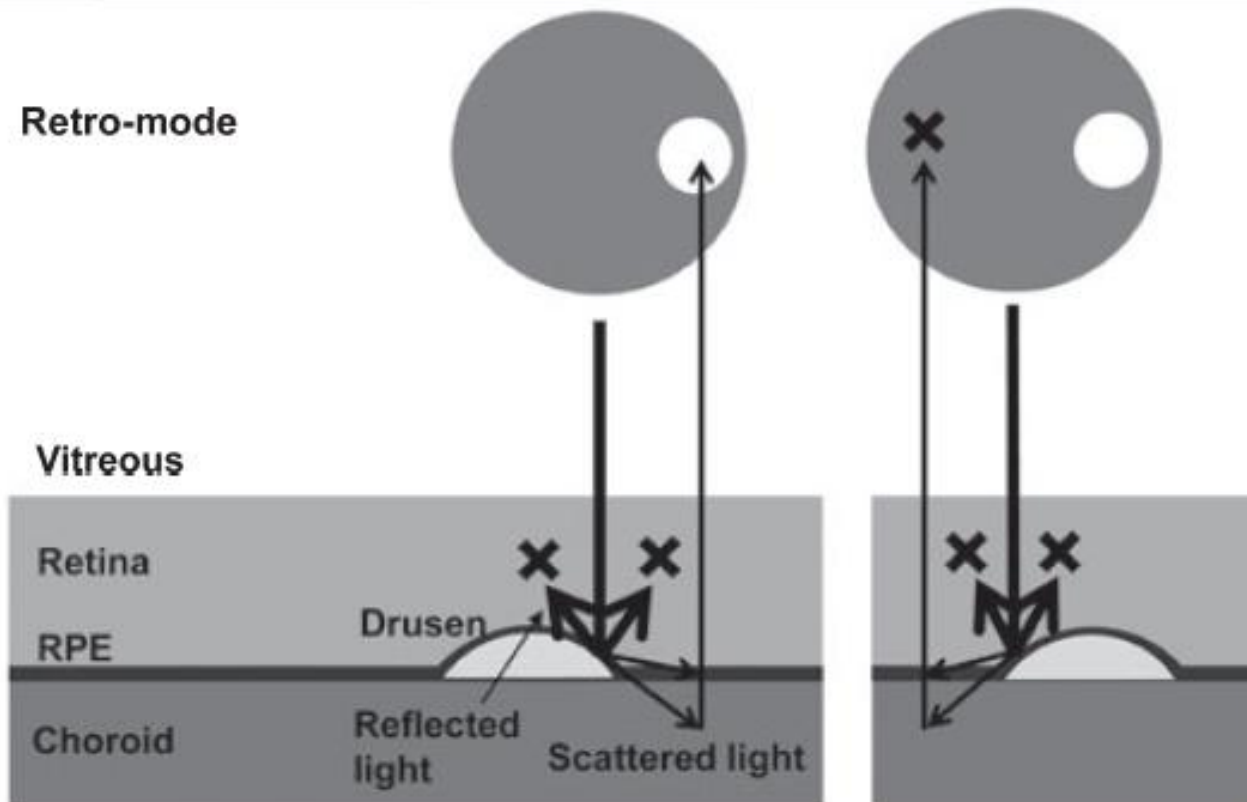
Indirect mode

Retro-mode aperture



Aperture can be on
right or left side

Retro-mode



Vitreous

Retina

Bruch's
Membrane

Choroid

Nerve
fiber
layer

Rod &
Cone


RPE

Blue (490nm)

Green (532nm)

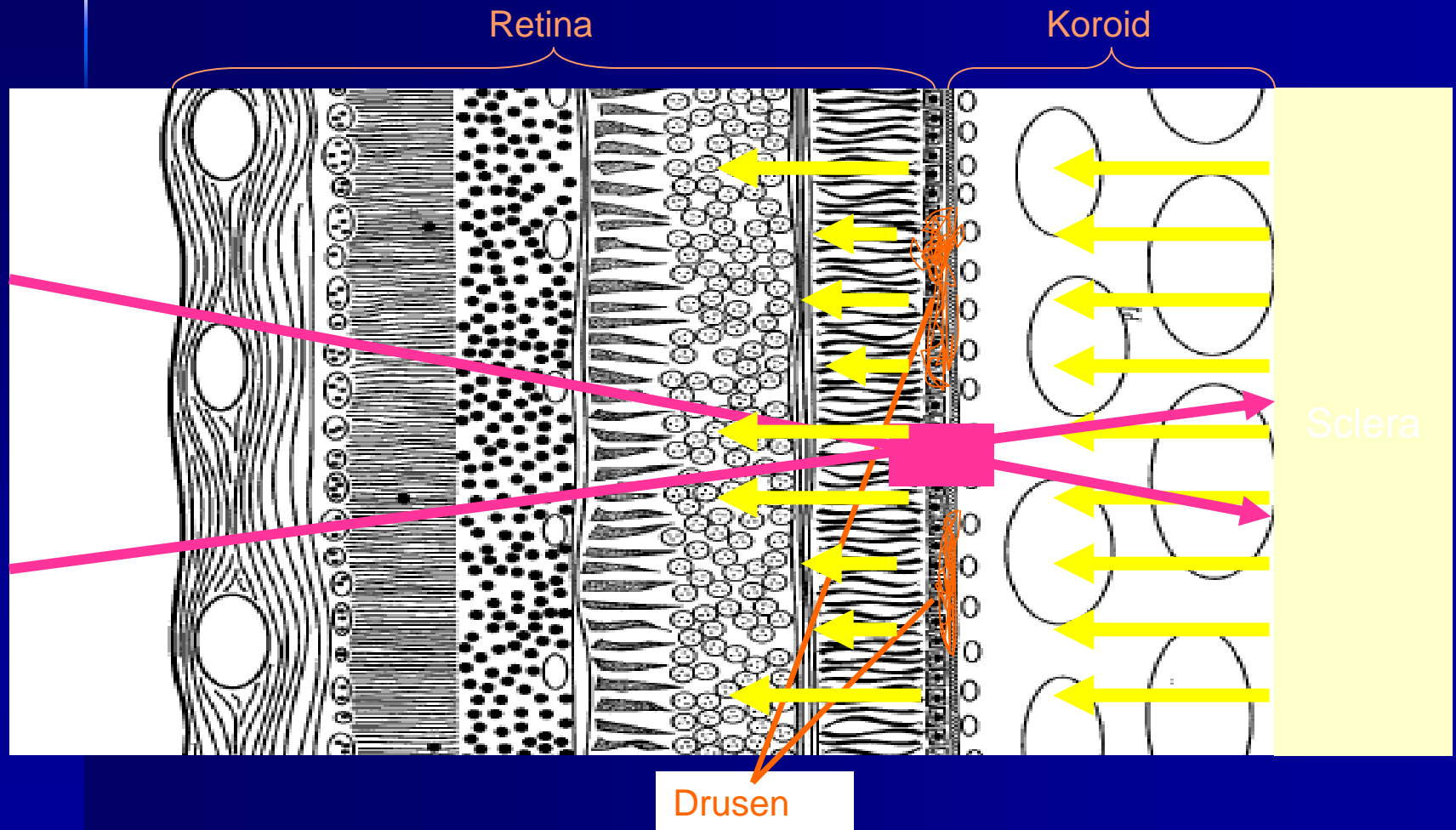
Red (660nm)

IR (790nm)

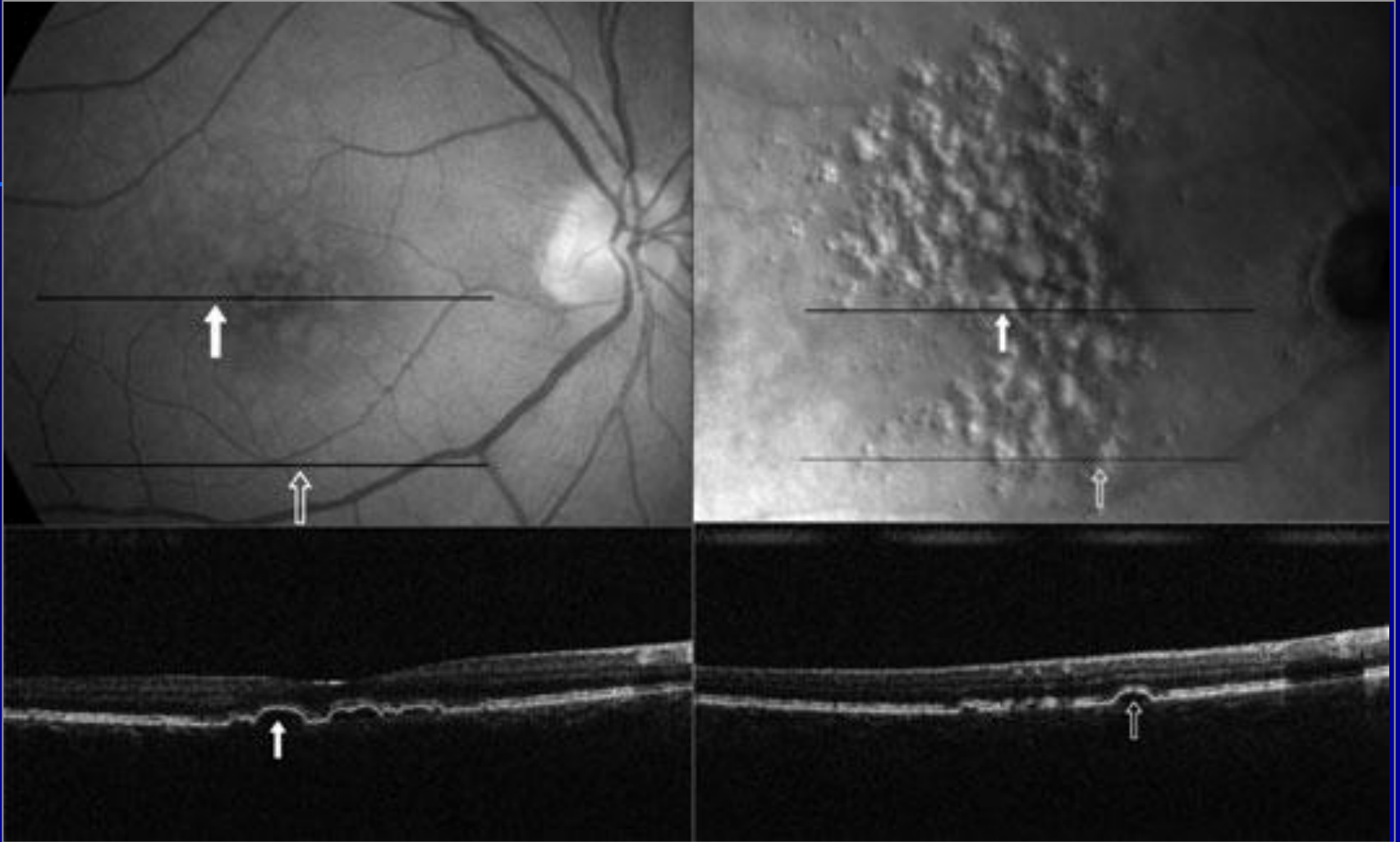


Non-Invasive Retro Mode

Only retinal structures that scatter incident light are detected

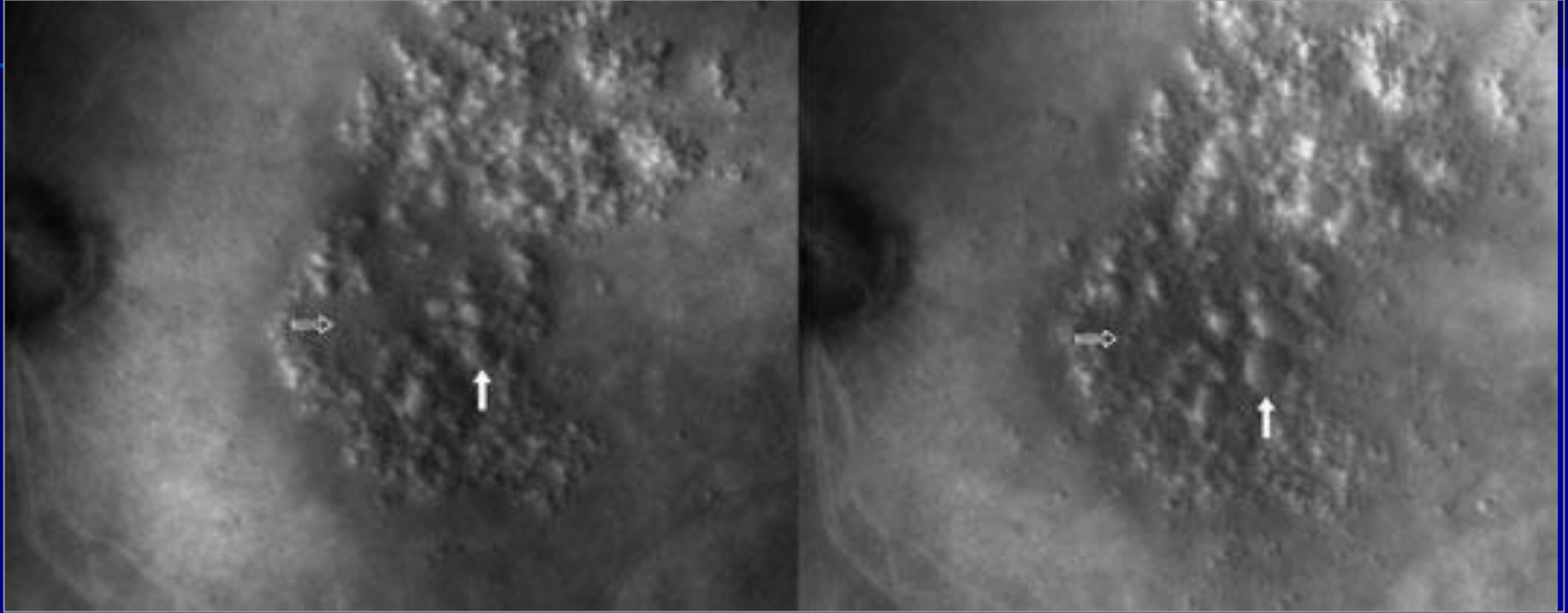


Retro Mode



- Fundus fotoğrafına göre daha çok sayıda drusen
Acton JH, et al. Acta Ophthalmol 2011;89:404-11

Retro Mode

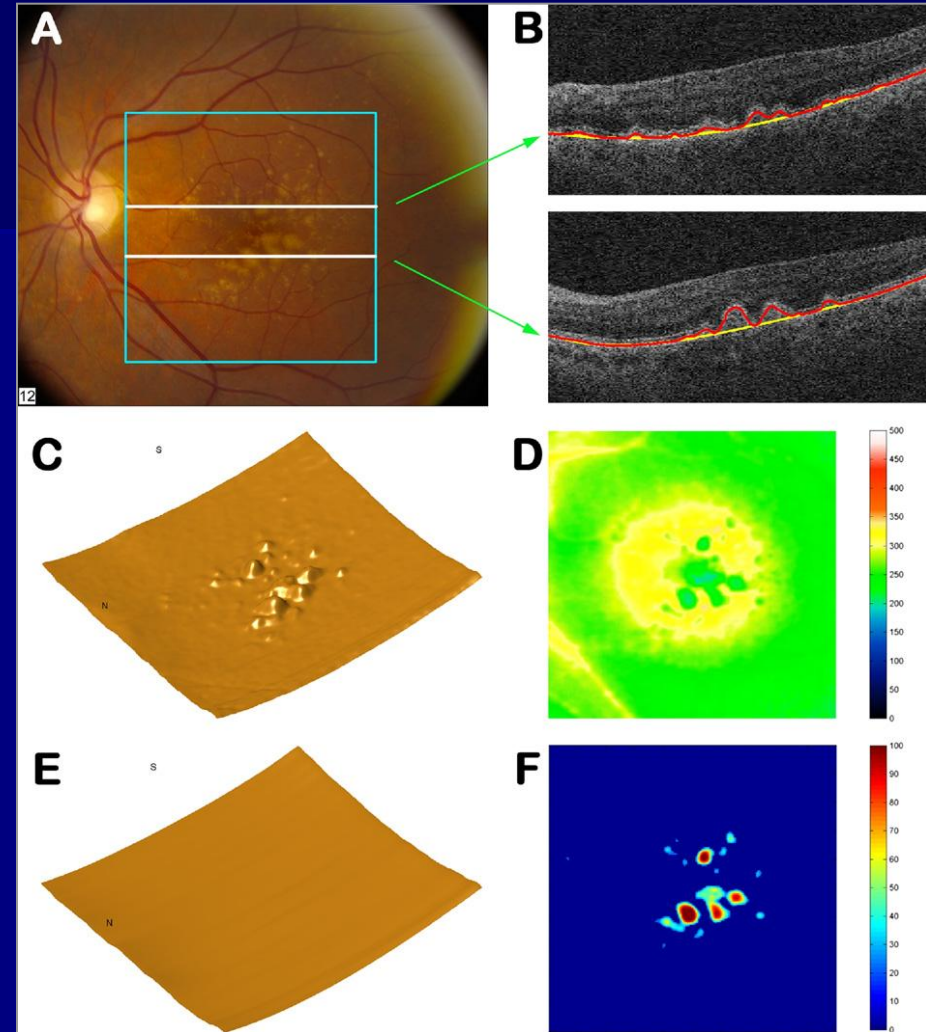


- Takipte drusen sayısında ve büyüklüğündeki artışın saptanması

Acton JH, et al. Acta Ophthalmol 2011;89:404-11

Drusen - OKT

- Drusenin alan ve hacim ölçümleri ile niceliksel analizi
- Drusenin doğal seyri ve hastalık ilerlemesinin belirlenmesinde yararlı



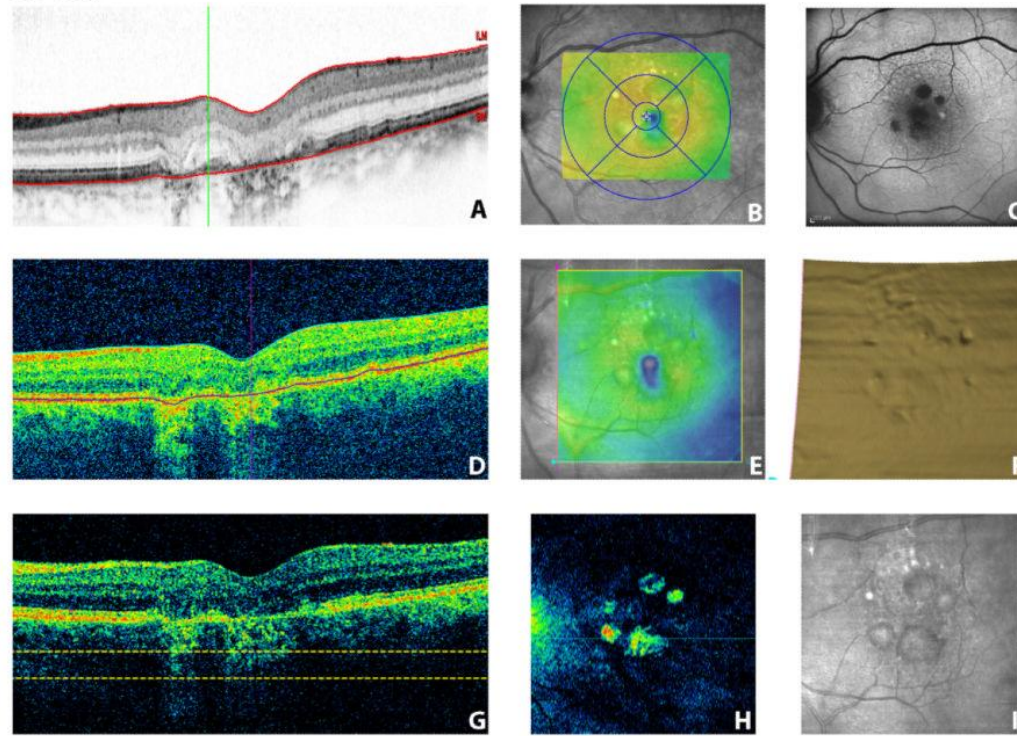
Gregori G, et al. Ophthalmology, 2011

Polarizasyon sensitif OKT

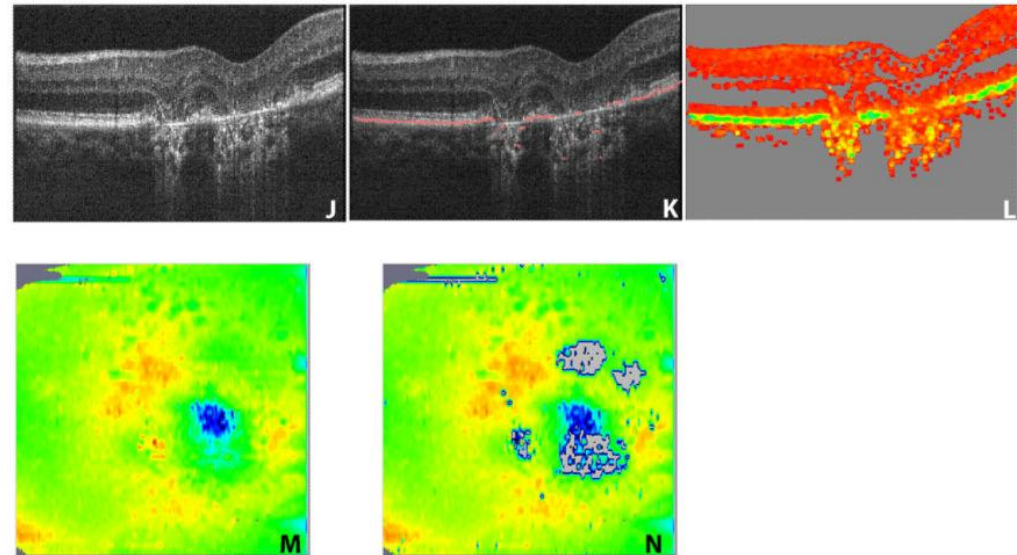
*Ahlers C, et al. Invest Ophthalmol Vis Sci
2010;51(4):2149-57*

- Standart SD - OKT bulguları ile birlikte ışığın polarizasyon özellikleri kullanılarak RPE'nin intrinsik doku özellikleri değerlendirilir
- SD-OKT ile izlenemeyen fokal kaçak atrofi alanları tesbit edilir
- Diğer görüntüleme yöntemlerinden farkı, derinlik çözünürlü görüntüleme yöntemi olması

SD-OCT



Polarization sensitive SD-OCT





CATARACT SURGERY IN A PATIENT WITH AGE-RELATED MACULAR DEGENERATION (AMD)

Emin ÖZMERT, M.D

Ankara University Faculty of Medicine

Department of Ophthalmology

Ankara / TURKEY

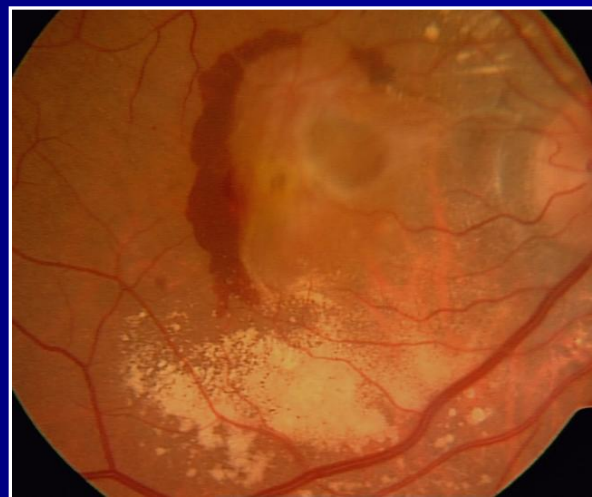
Prague-2012

Disclosures

I do not have any financial interest or
relationship
with any companies

Cataract & AMD

- Age-related cataract and AMD share common risk factors (age, smoking, nutrition, cardiovascular disease), that could cause them to progress simultaneously (Hiller 1997, Jacques 2005, Seddon 2006)
- They have overlapping symptoms in people over age 50
- 15-20 % of cataractous eye have AMD
(Casparis et al, 2012; The Cochrane Collaboration)



Cataract Surgery & AMD

The relationship between cataract surgery and AMD has been the subject of much debate over recent years

There is still controversy about;

- Possible benefits or risks
- Promote progression
- Trigger for the development of AMD

(Mönestam E, et al: J Cataract Refract Surg 2012; 38:409 – 414)

Cataract Surgery & AMD / Studies-1

■ Cataract Surgery: worsening

There are many case series regarding deterioration after surgery:

- * Stolba 1989
- * Pollack 1996
- * Van der Schaft 1997
- * Cugati 2006
- * Donoso 2006
- * Lundqvist 2006
- * Kaiserman 2007

- Possible limitations of these studies (number of patients, design, randomization ..)
- Older techniques of cataract surgery and IOL designs
- Most of them did not use preoperative or early postoperative FA, OCT
(CNV may be overlooked because of lens opacity)

Cataract Surgery & AMD / Studies-2

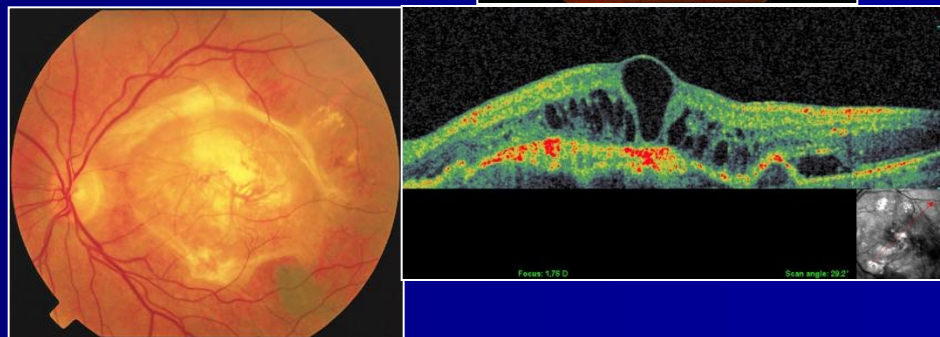
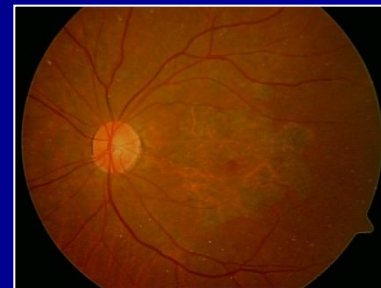■ Population-based, well-designed epidemiologic studies

- * Beaver Dam Eye Study (Klein, Ophthalmol 2012, 119: 1628 – 1633)
- * Combined cross-sectional data from Salisbury Eye Evaluation and Baltimore Eye Survey (Freeman, Am J Ophthalmol 2003; 135: 849-856)
- * The Beaver Dam Eye Study and the Blue Mountains Eye Study (Wang, Ophthalmology 2003; 110: 1960 – 1967)
- * The Copenhagen City Eye Study

- Cataract surgery increased the risk for late AMD, but further studies are needed to clarify this issue
- No clear causal effect

Chew EY, et al: Ophthalmology 2009; 116:297-303

Casparis et al, 2012; The Cochrane Collaboration



Cataract Surgery & AMD / Studies-3

■ Modern cataract surgery: no harmful effect, some benefit

* Armbrecht, J Cataract and Refractive Surg, 2003; 29 (4):686-93

* Sutter, IOVS 2007; 48: 1472 – 1475

* Baatz, IOVS 2008; 49 (3): 1079-83

* Dong, Arch Ophthalmol 2009; 127: 1412 – 1419

* Klein, Arch Ophthalmol 2009; 127: 1528 – 1529

* AREDS Report 25, Ophthalmology 2009; 116: 297 – 303

* Casparis, The Cochrane Collaboration, 2012, Issue 7

- Modern cataract surgery techniques, advanced IOL design

* Smaller incision, less surgical time

* Less hypotony, inflammation

* Less light exposure, retinal phototoxicity

* Less blood – retinal barrier breakdown

- Diagnostic improvements: SD – OCT, ICG

Despite conflicting evidence, recent data suggest that modern cataract surgery does not have a negative impact on preexisting AMD; may improve vision without worsening of AMD on long-term basis

* Banta JT et al: International Ophthalmology Clinics, 2012; 52 (2): 73-80

* Mönestam E, et al: J Cataract Refract Surg 2012; 38:409 – 414

Cataract Surgery & AMD / Studies-4

- The more recent AREDS not only failed to show a detrimental effect of cataract surgery on the progression of AMD, but actually demonstrated an average improvement in VA after cataract surgery in patients with varying severities of AMD

Banta JT et al: *International Ophthalmology Clinics*, 2012; 52 (2): 73-80

- Many cases of presumed progression to neovascular AMD following cataract surgery may have been present prior to cataract surgery, but not recognized owing to lens opacity

Dong LM, et al, *Arch Ophthalmol* 2009; 127 (11):1412 - 1419

Ankara University Study - 2012

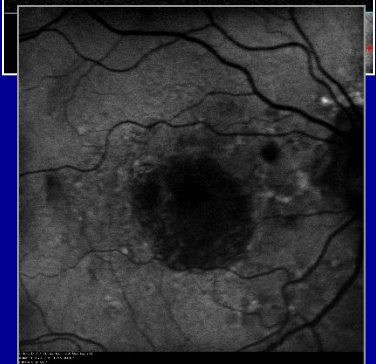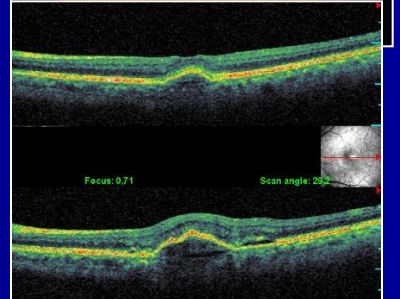
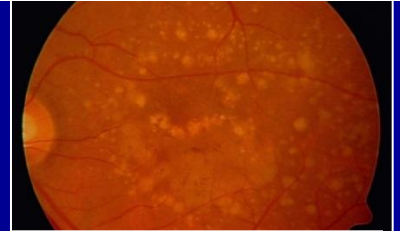
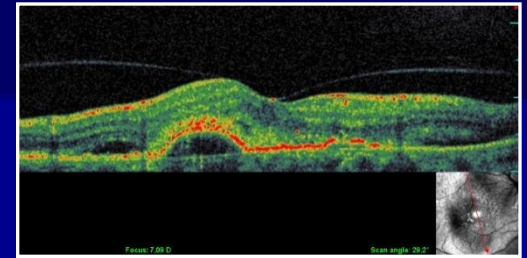
- 328 eyes (203 patients) with various degree of AMD , retrospective, Mean follow-up : 33.28 months (6 – 218)
 - **Control group:** 209 eyes with AMD who did not have cataract surgery
 - **Study group:** 119 eyes with AMD that has a history of cataract surgery at baseline or had cataract surgery during the follow-up
 - Both groups are similar for gender, age, and diagnosis
 - **AMD + Cataract surgery: 29,6 %**
AMD without surgery: 33,0 % **early AMD progressed to late AMD**
 - There were no statistically significant difference in progression rate, and VA
- * Our results did not support the hypothesis that cataract surgery increases the risk of AMD progression
- * Cataract surgery improved the VA significantly compare to the patients not having surgery

Cataract Surgery & AMD

Ocular high-risk factors for progression of AMD

- Partial Posterior Vitreous Detachment (PVD) & Chronic Vitreomacular Traction
- Large / Soft Drusen $> 125 \mu\text{m}$, Drusenoid PED Associated with focal pigmentary abnormality
- CNV presence in the fellow eye
- Certain Fundus Autofluorescence (FAF) patterns:
early, GA

Cataract surgery may be a more important risk factor in those who are already at relatively high risk factors



PVD / CATARACT SURGERY / AMD

- The occurrence and significant progression of PVD after cataract surgery were frequent

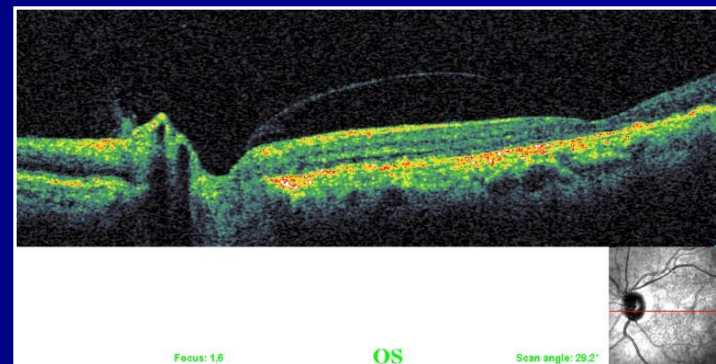
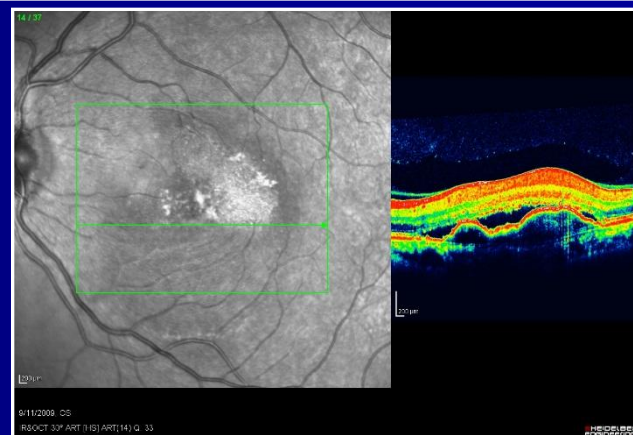
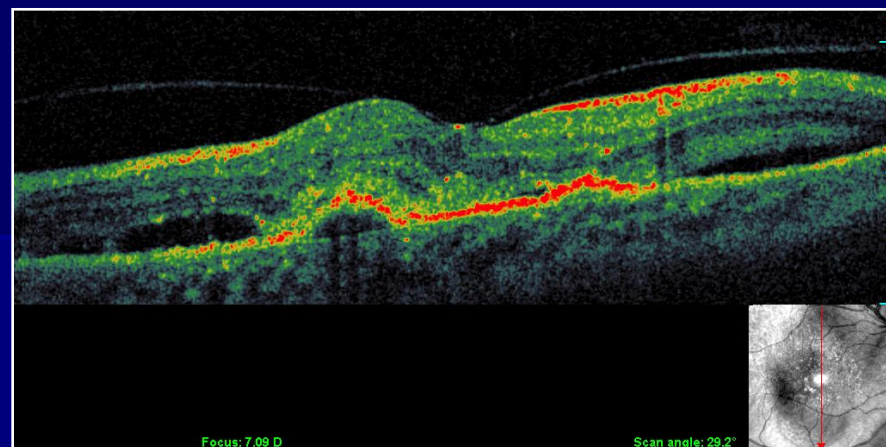
J Cataract Refract Surg 2009; 35: 987 – 991
Am J Ophthalmol 2012; 153:705 – 709

- Chronic vitreomacular traction may be a risk factor for the development of exudative AMD

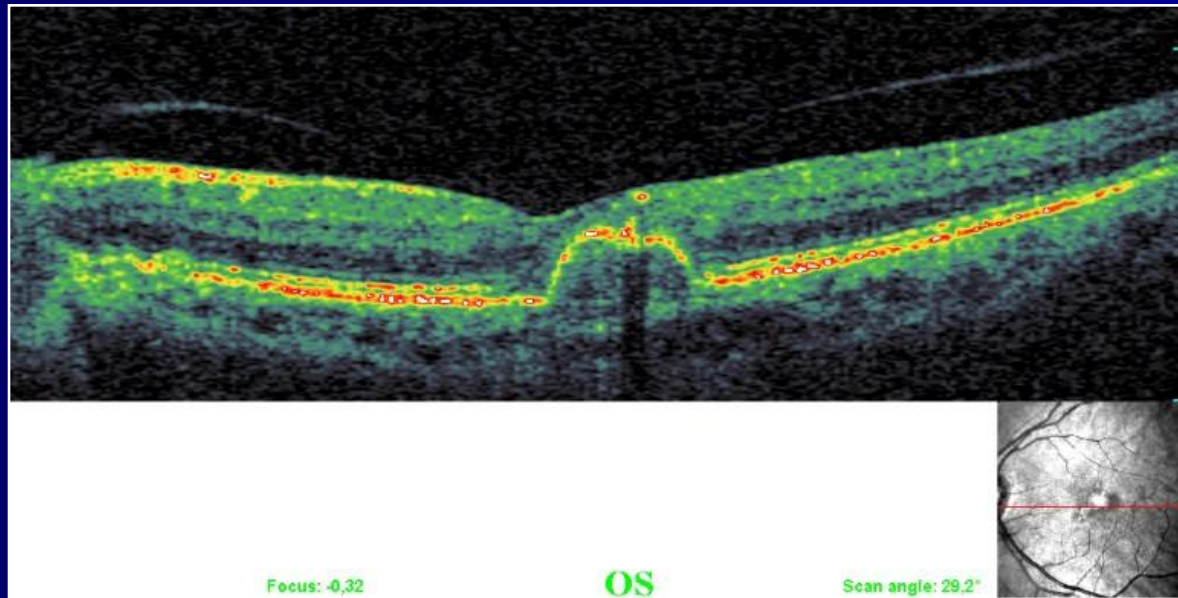
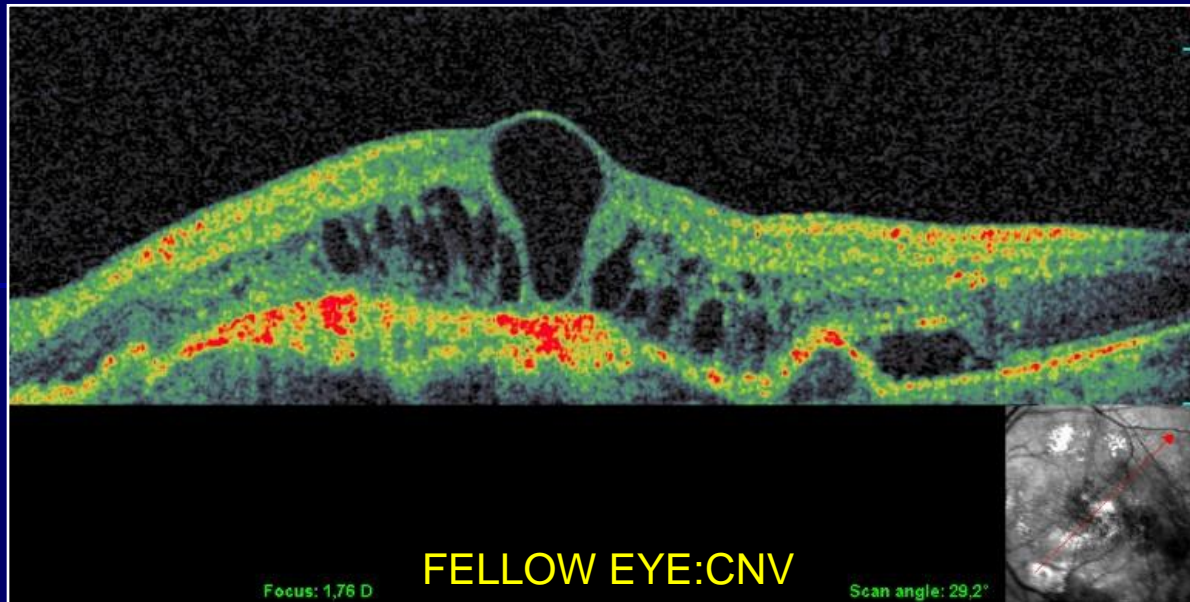
* Upregulate the VEGF expression, possibly inducing CNV proliferation or recurrence

* Induce low-grade inflammation or release of cytokines / free radicals

Invest Ophthalmol Vis Sci 1999; 40:3287 -3291
Am J Ophthalmol 2009; 147: 621 - 626



HIGH RISK GROUP

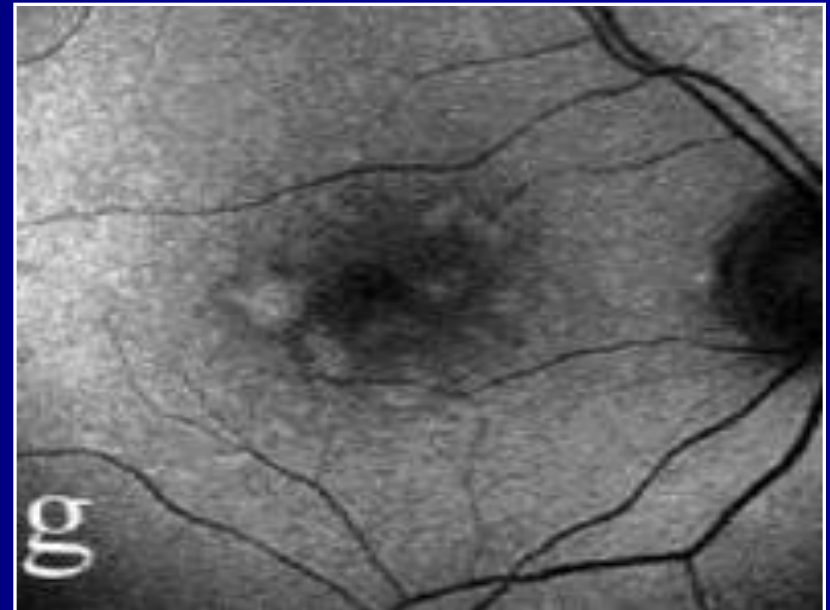


PARTIAL PVD / DRUSENOID PED / PIGMENT PROLIFERATION

Fundus Autofluorescence (FAF) / FAM study Group

Patchy pattern of FAF
indicates a relatively high
risk of progression to wet AMD

Einbock W, Moessner A, Schnurrbusch
UEK, Holz FG, Wolf S for the FAM
Study Group. Graefe's Arch Clin Exp
Ophthalmol 2005;243(4):300-5.



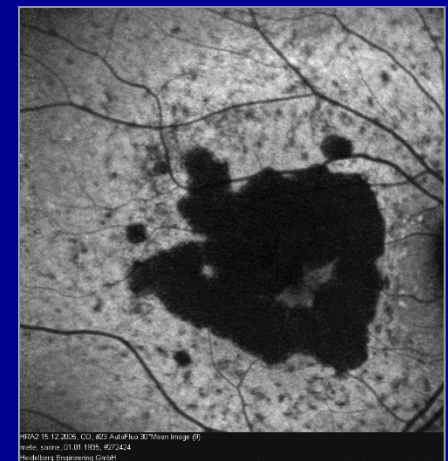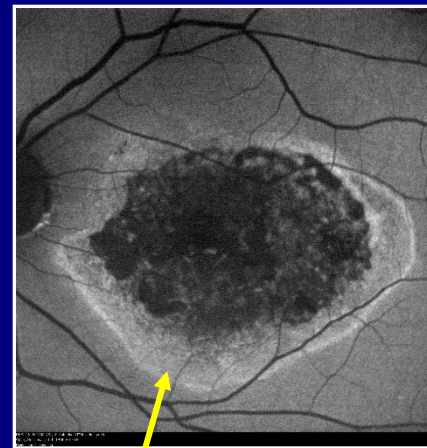
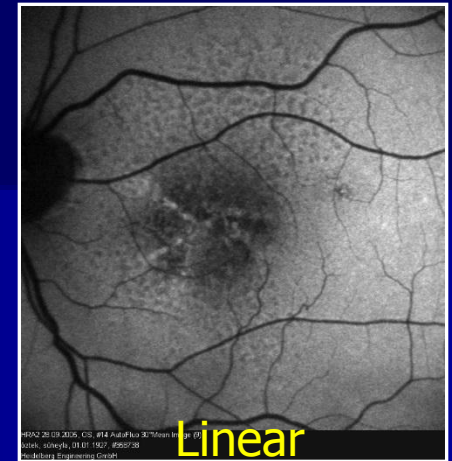
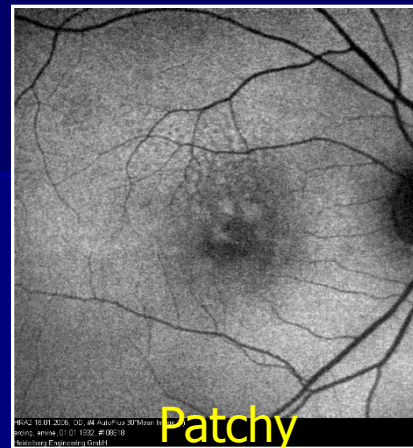
Patchy pattern FAF

Ankara University FAF Study

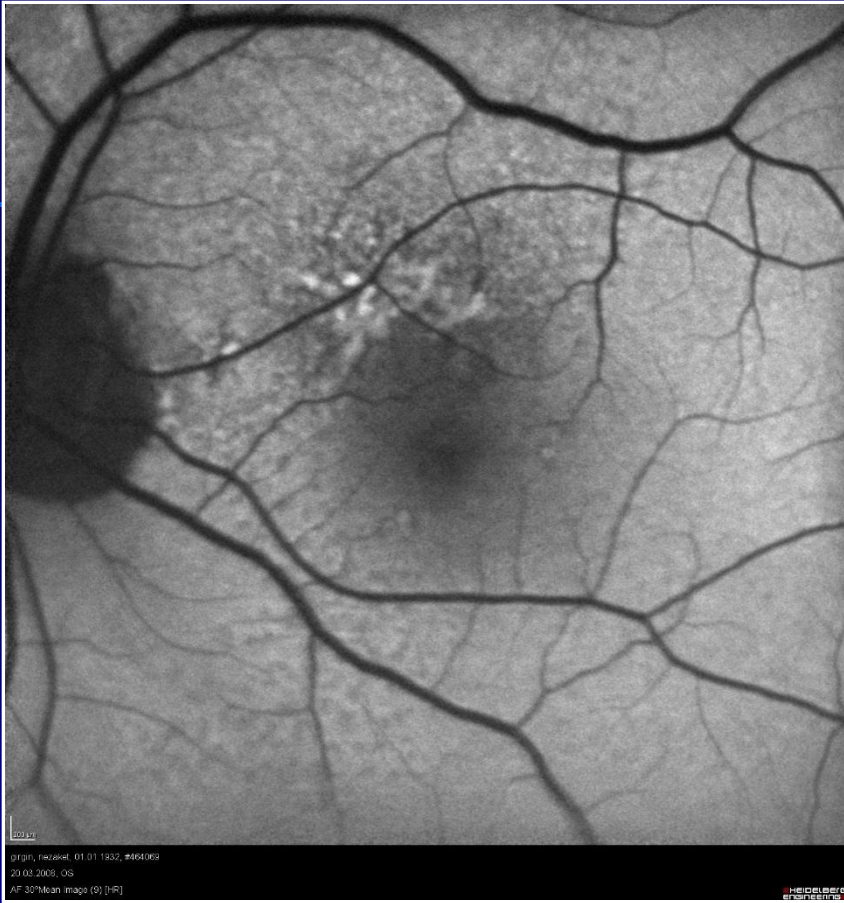
- To test if FAF patterns have an impact on the development of choroidal neovascularisation (CNV) or geographic atrophy progression
- 105 patients with early and advanced dry - AMD
- Fundus autofluorescence imaging (HRA II)
- Classification of “International Fundus Autofluorescence Classification Group”
- Mean follow-up: 25.3 ± 8.1 months

Ankara University FAF Study / Conclusion

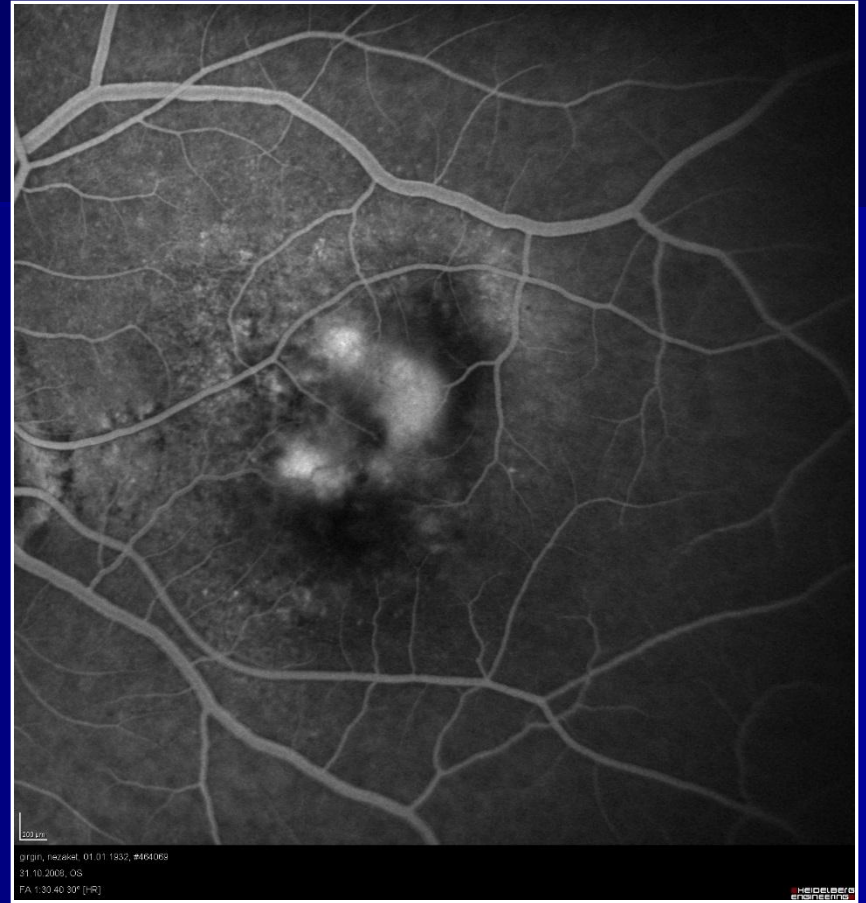- Patchy and linear patterns of FAF indicate a relatively high risk of CNV in AMD
- In eyes with geographic atrophy, banded patterns in the junctional zone carry high-risk for progression as well as CNV development
- FAF imaging is a useful, non-invasive tool to identify high-risk characteristics in patients with nonexudative AMD



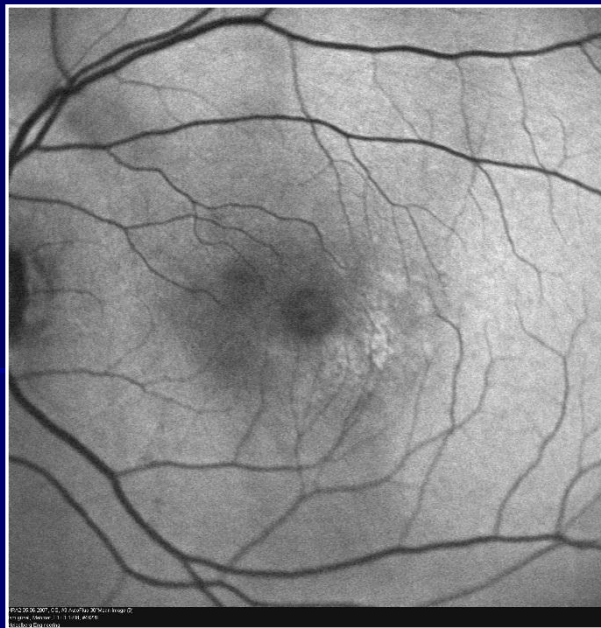
Hyperautofluorescence band surrounding GA



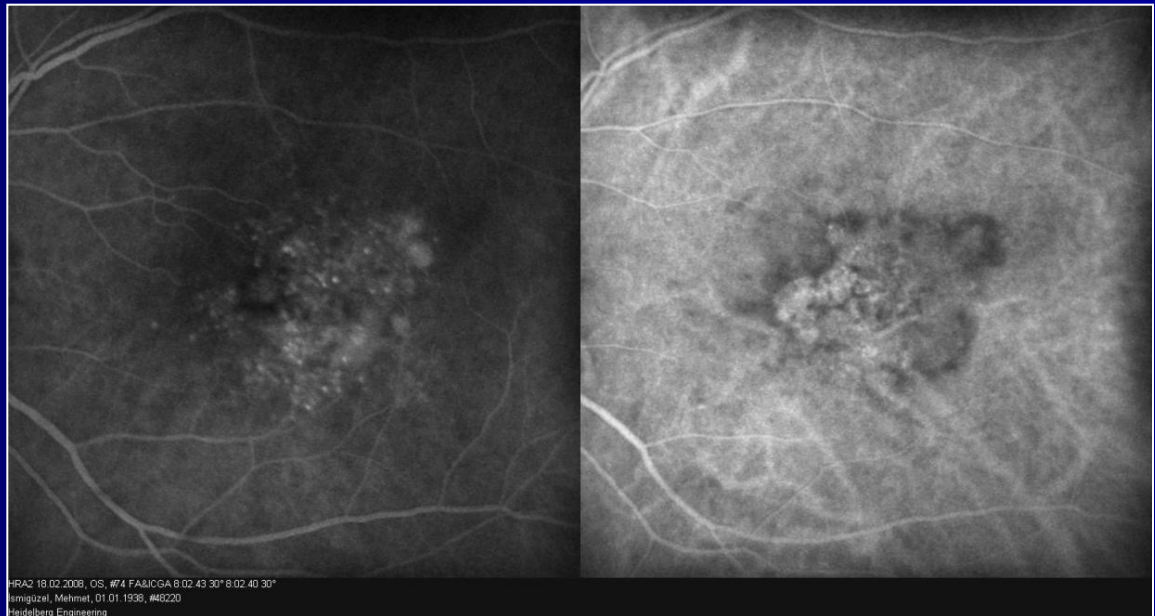
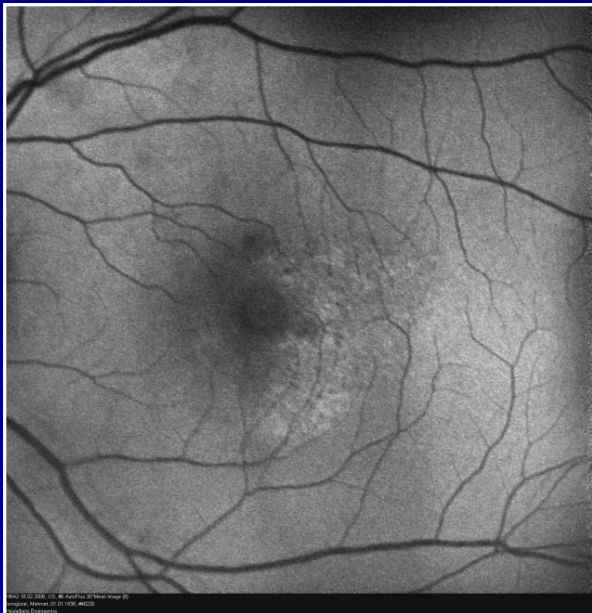
Linear pattern at baseline



CNV developed during the follow-up

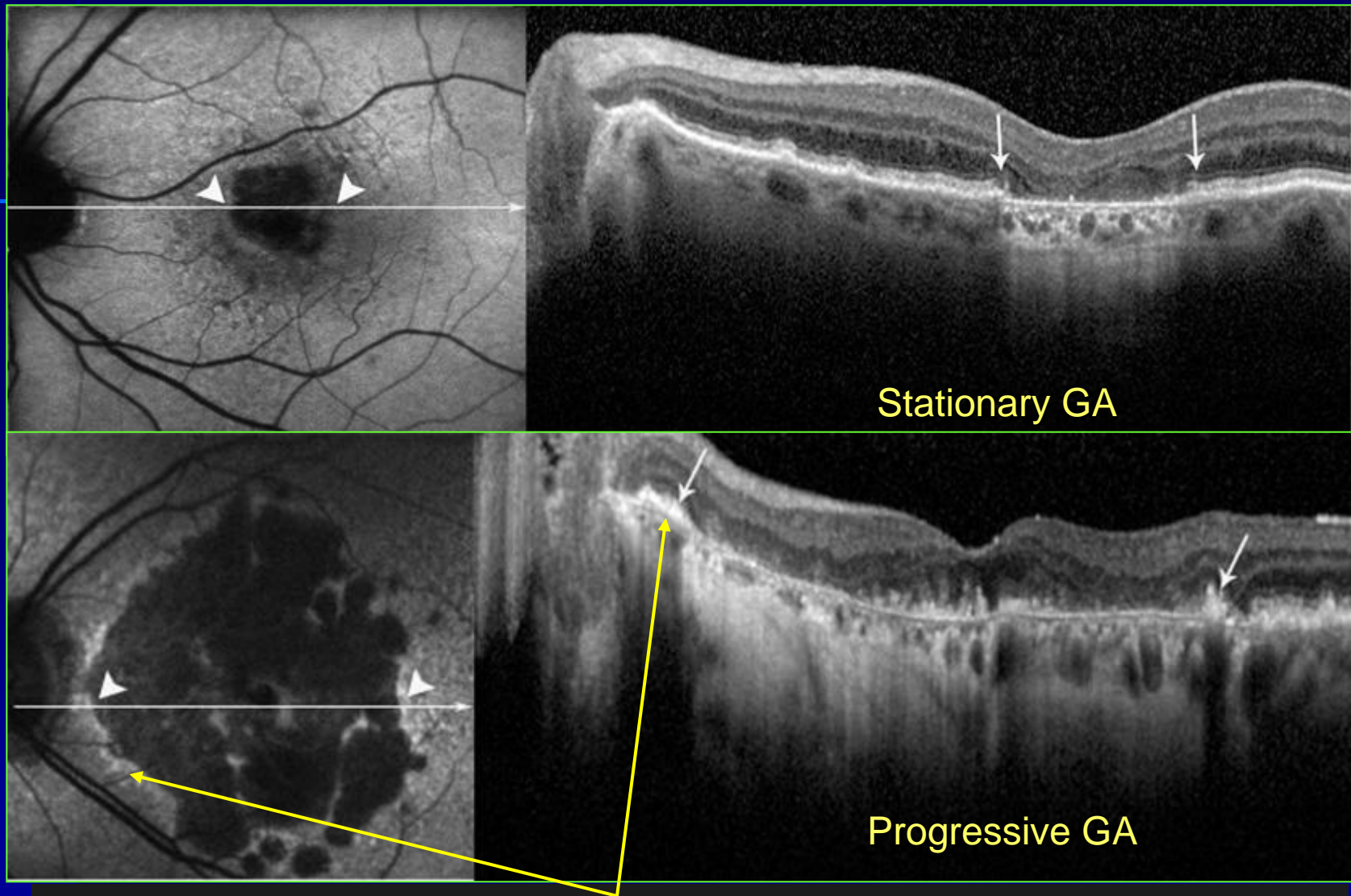


Patchy pattern at baseline



CNV development during the follow-up

Geographic Atrophy - FAF / SD - OCT



Stationary GA

Progressive GA

Ridge at the hyperautofluorescent zone surrounding geographic atrophy

Cataract Surgery & Neovascular AMD

- Before the introduction of anti – VEGF therapy, cataract surgery was considered unsuitable for most patients with wet-AMD
- In the era of anti-VEGF therapy, cataract surgery is associated with visual improvement with no increased incidence of perioperative complications, recurrence, and injection number
- Wet - AMD requires treatment and stabilization before cataract surgery
- Prophylactic anti-VEGF therapy for dry-AMD can not be recommended

Tabandeh H, et al: j Cataract Refract Surg 2012; 38 : 677 – 682

Banta JT, et al: International Ophthalmology Clinics 2012; 2: 73 - 80

Clinical approach in patient with AMD who undergoes modern cataract surgery

- **Fundus assessment** (+ 90 or 78 D lens, fundus contact lens, FA, ICG)
- **SD - OCT imaging** to clarify AMD type, and vitreomacular traction
- **Preoperative, intraoperative:**
 - * Topical anti-inflamatur treatment / contemporary cataract surgery
 - * The use of preoperative (within 2 weeks) or simultaneous intraoperative anti- VEGF agents is recommended in patients with recently active neovascular AMD
- **Postoperative:**
 - * AREDS anti-oxidant, UV protection, no smoking
 - * If eye has high-risk characteristics, patient should follow-up closely with cautious after cataract surgery (non - invasive SD – OCT, FAF)

Tabandeh H, et al: *J Cataract Refract Surg* 2012; 38 : 677 – 682

Banta JT, et al: *International Ophthalmology Clinics* 2012; 2: 73 – 80

Furino C, et al: *J Cataract Refract Surg* 2009; 35:1518-1522

Cataract Surgery – IOL types / AMD

- Avoid to reduce contrast sensitivity
- The use of multifocal IOLs is a relative contraindication in patients with any degree of maculopathy
- Monofokal +
Aspheric +
Toric +
Accommodative +, -
Multifocal ?
- UV - blocking +
Blue - blocking ? (reduced contrast sensitivity)