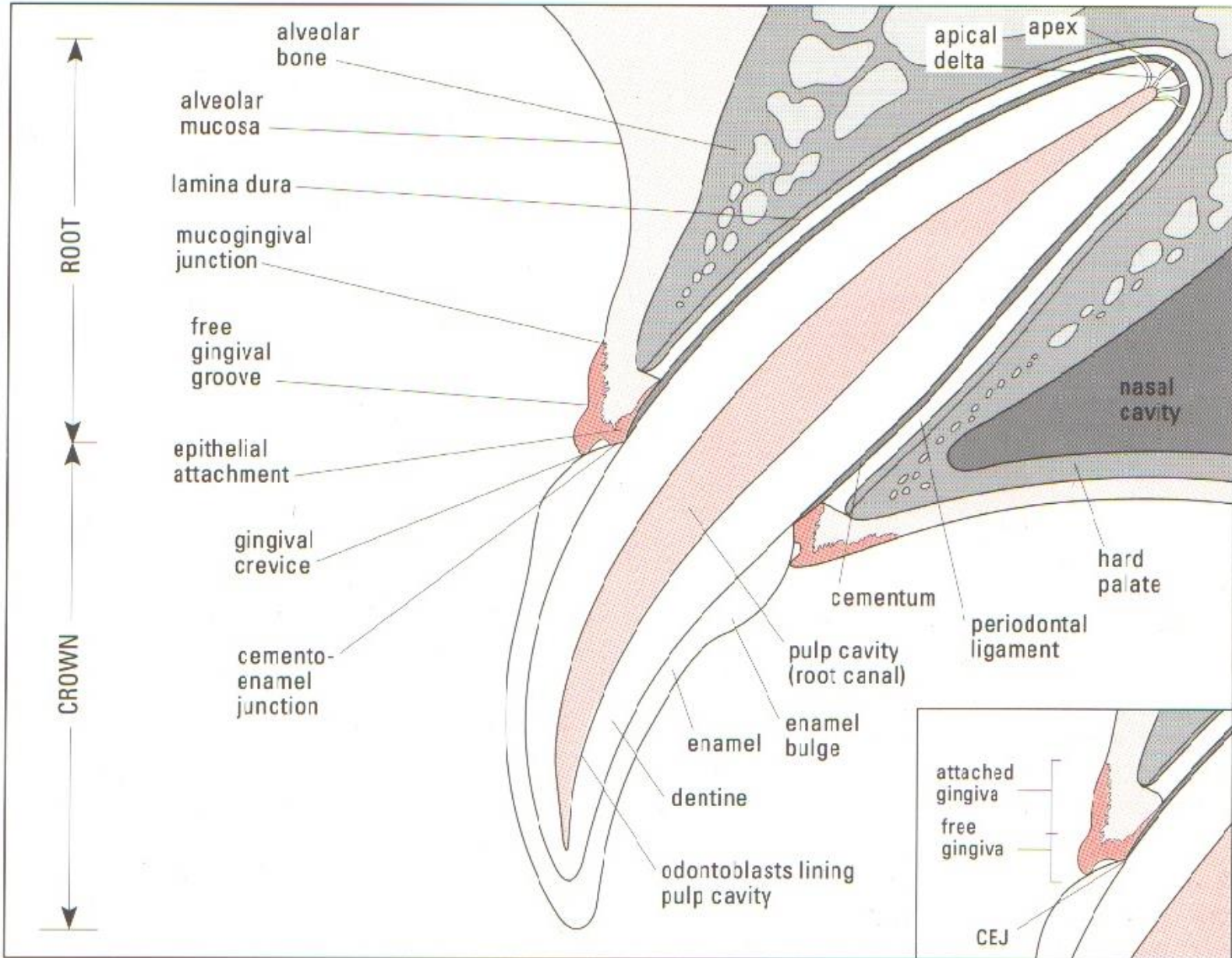

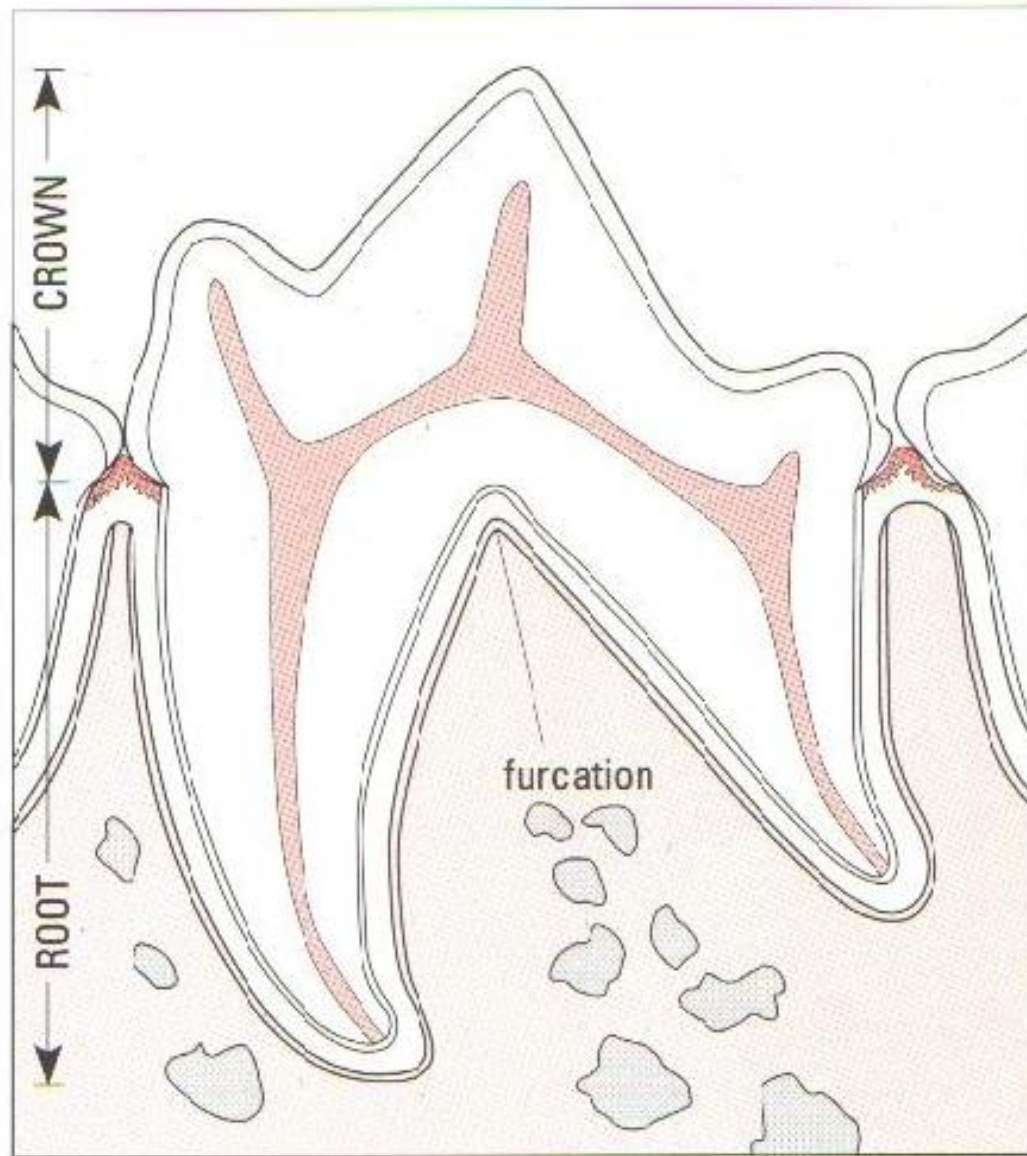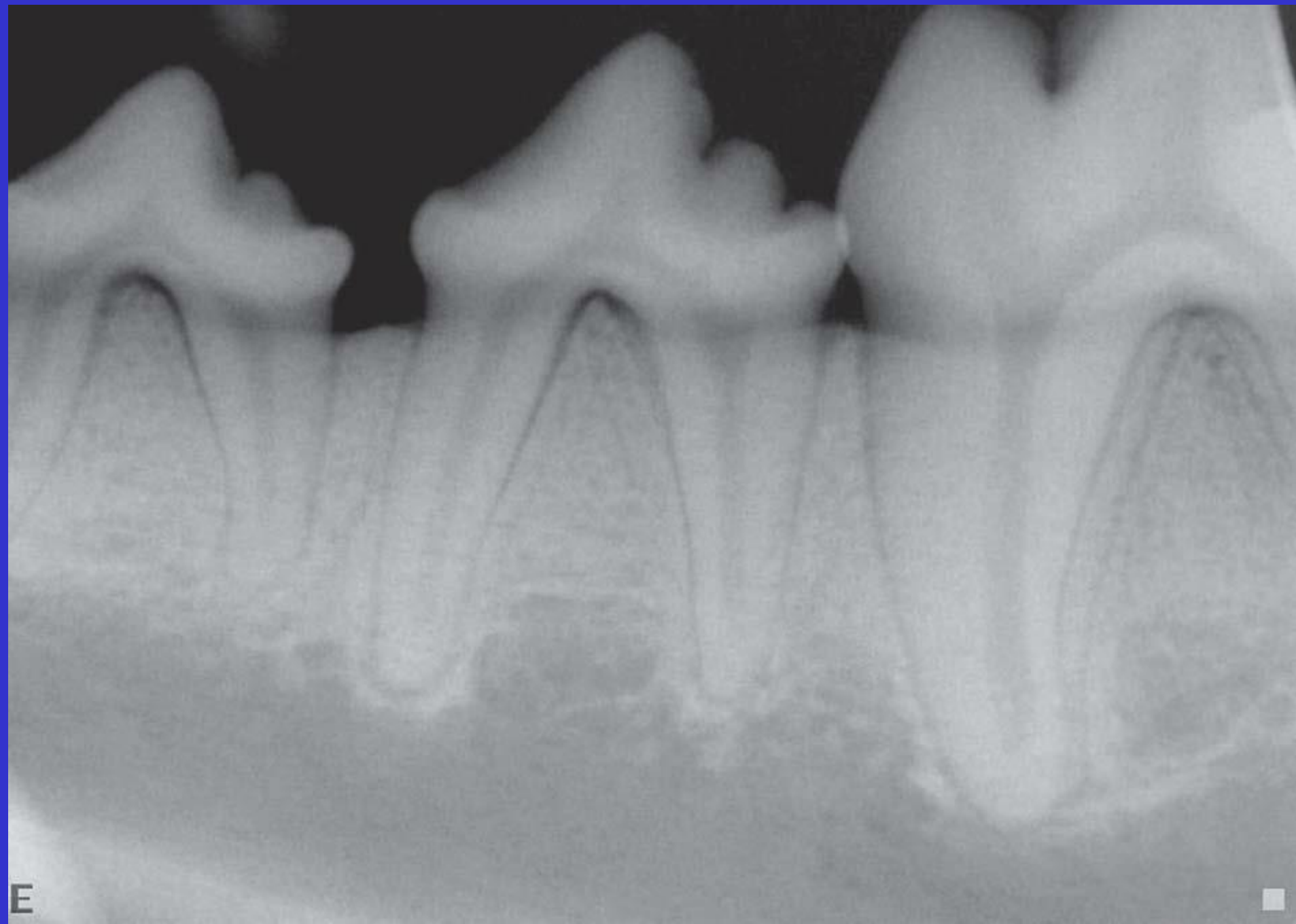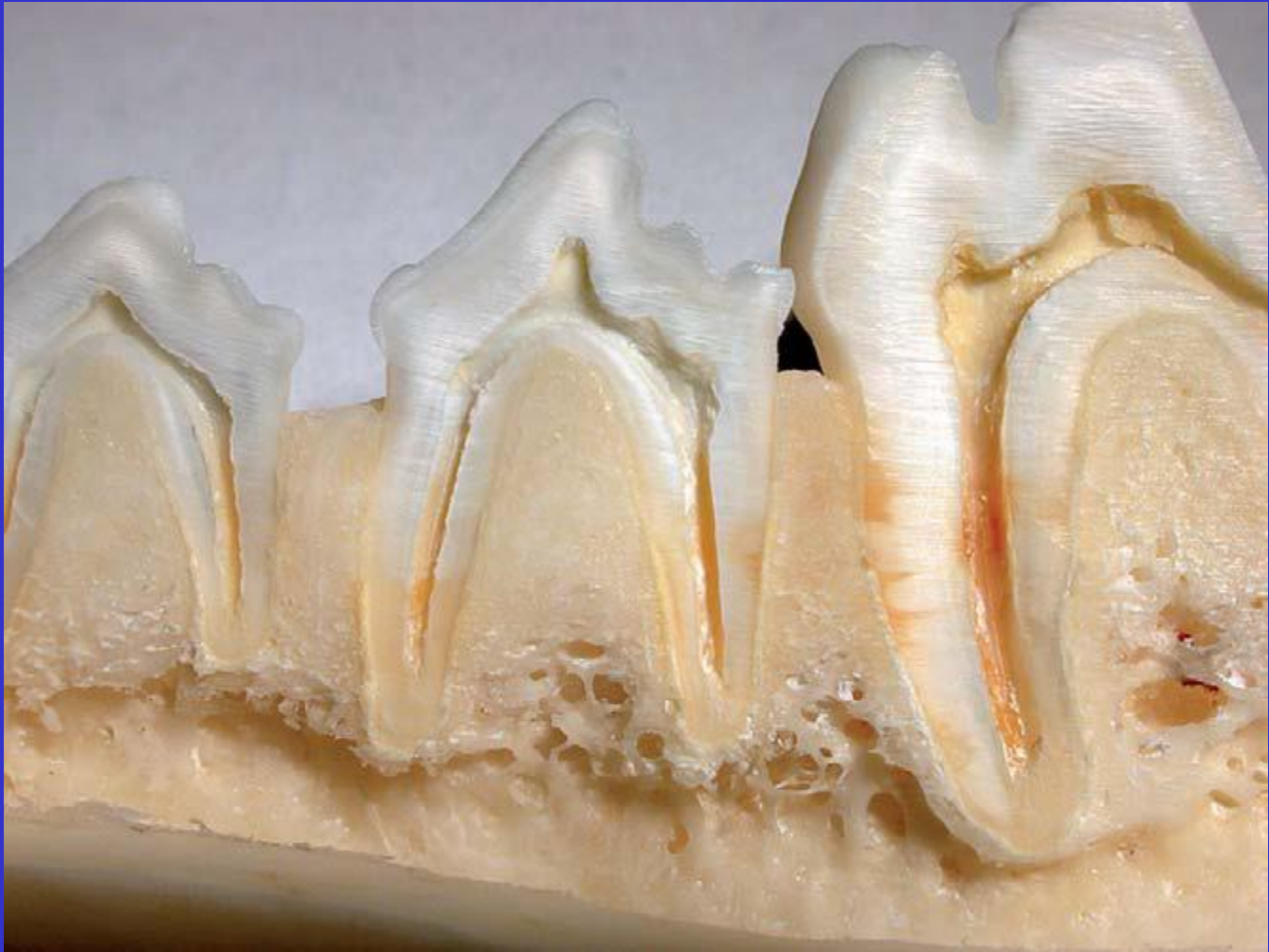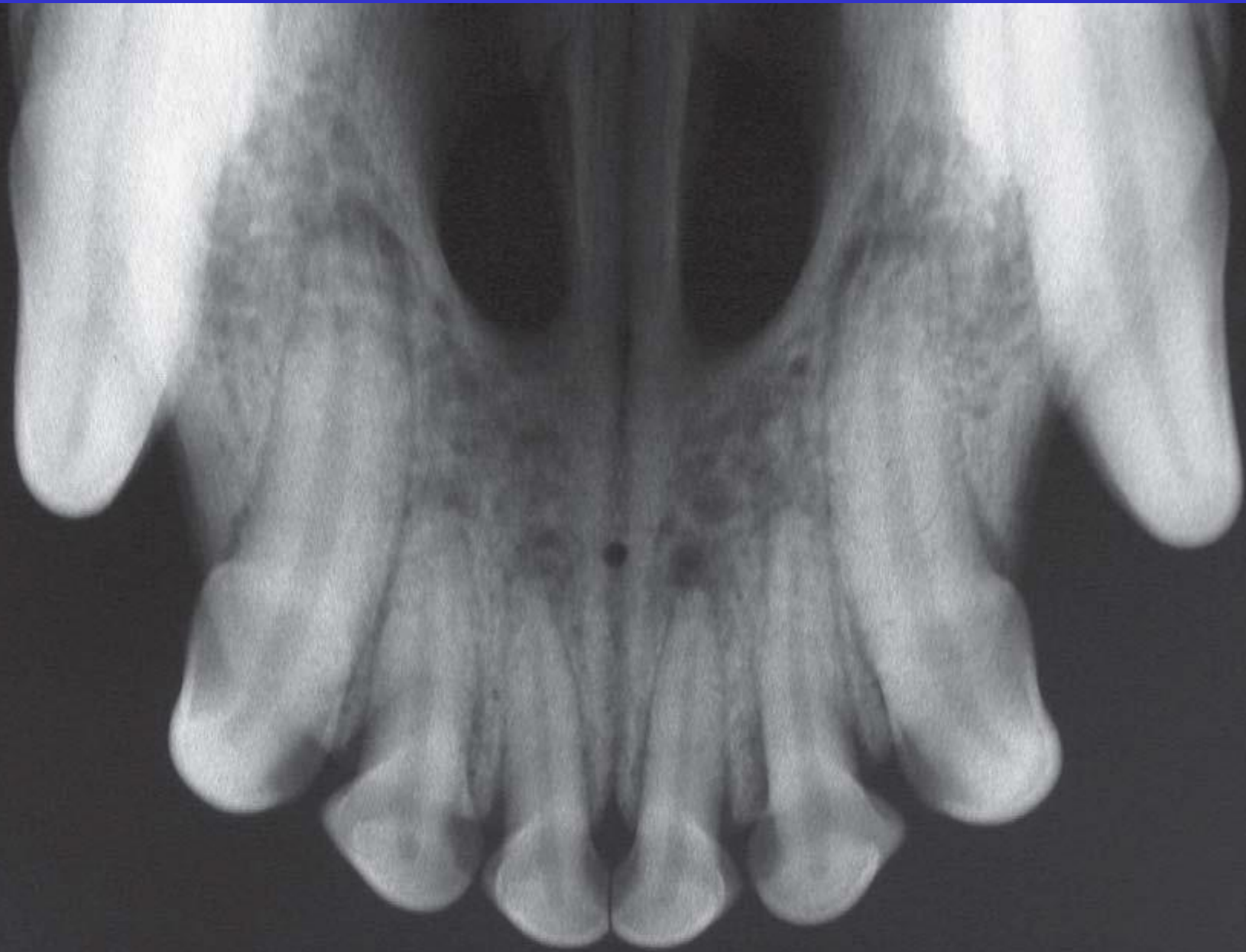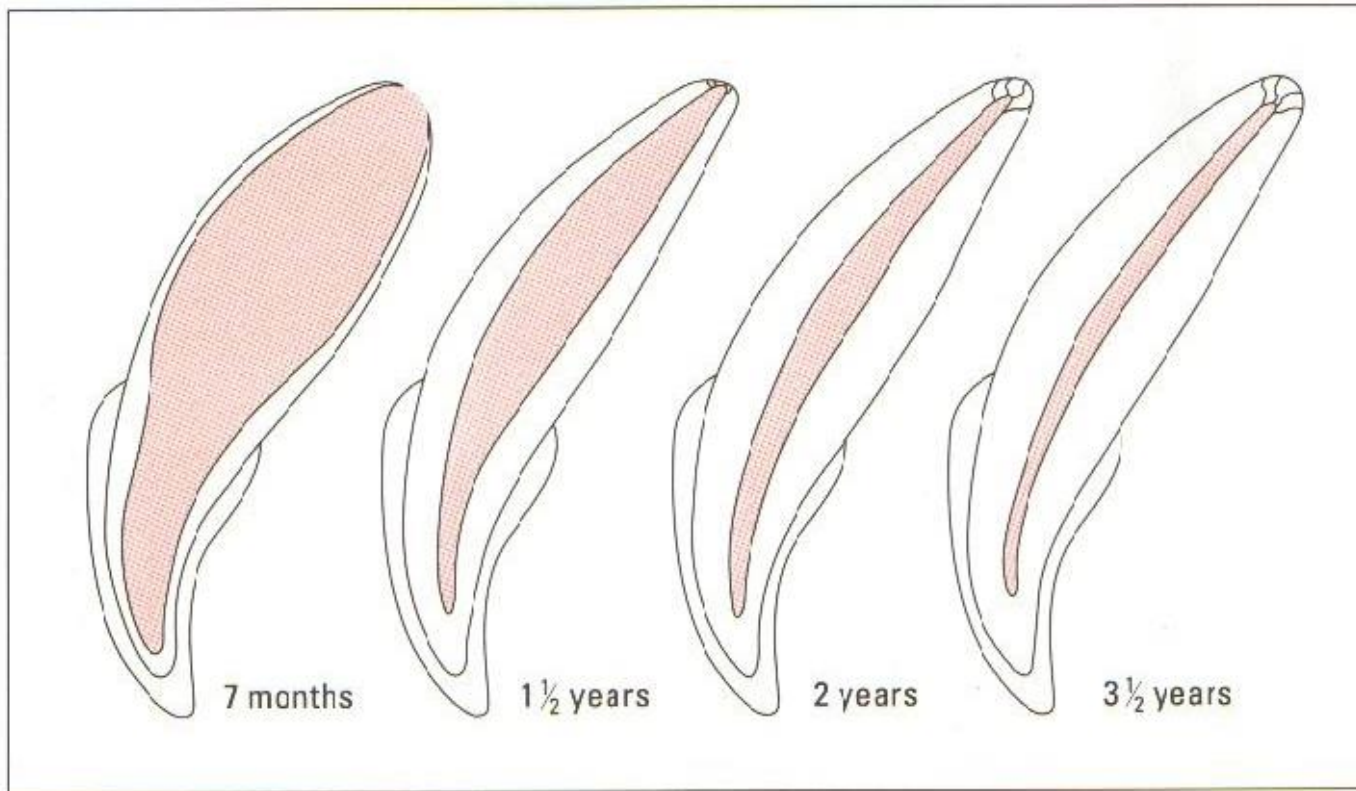
FIG. 1.11 Diagrammatic section through a lower first molar of an adult dog.



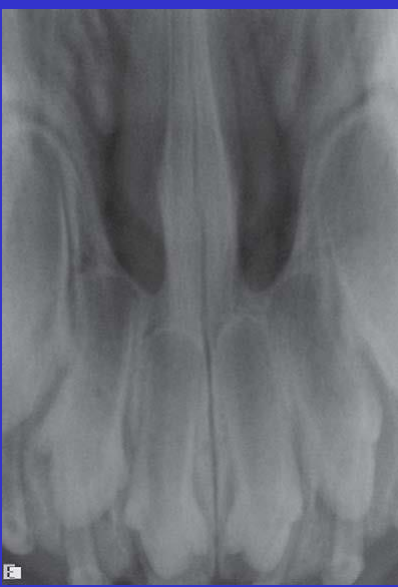E



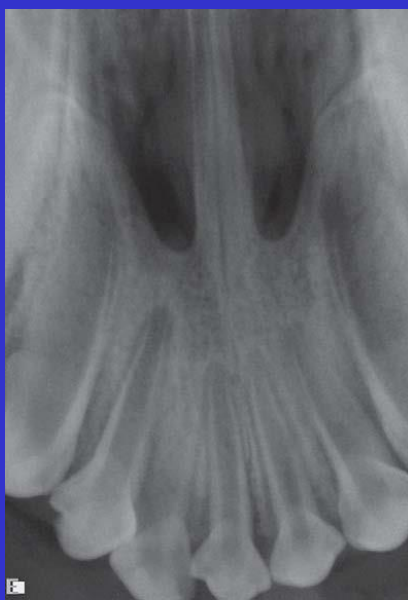



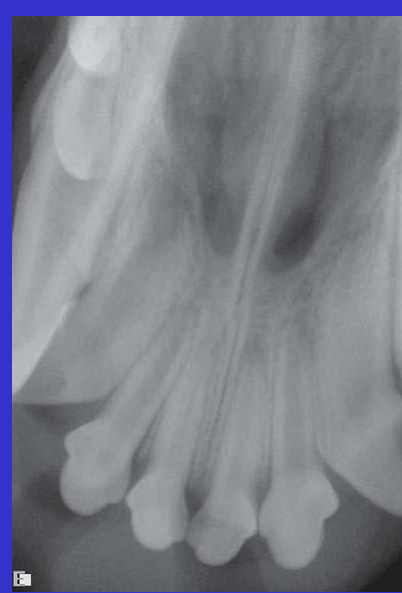2 The development of the dentine of an upper canine tooth from the completion of eruption to maturity. The dentine wall thickens, the pulp chamber narrows, and the root canal narrows from the apical to the coronal foramen. Adapted from H. Schmidt and P. Fehsekrug.



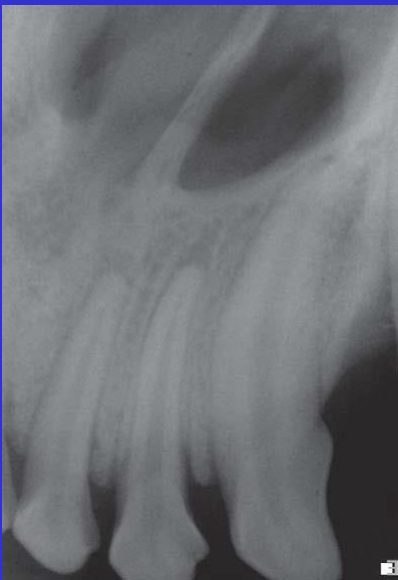3 ay



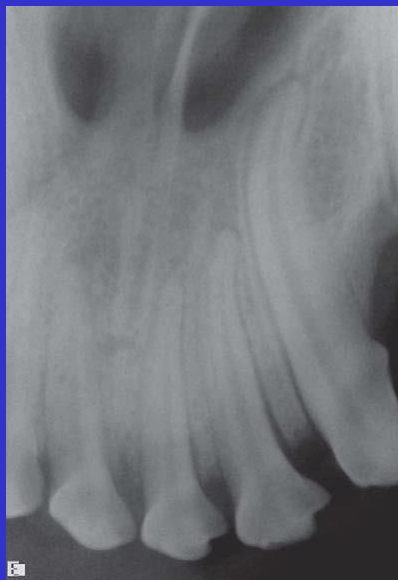
5 ay



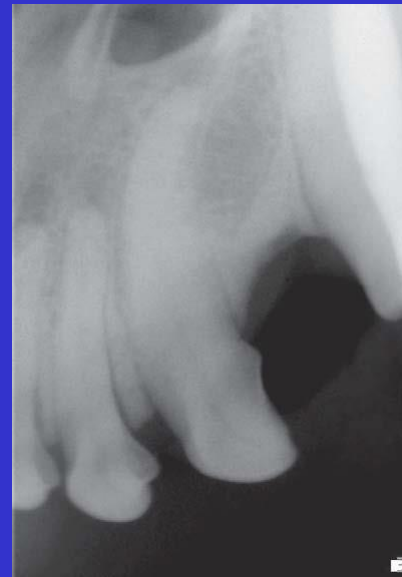8 ay



15 ay



18 ay



7 Yaş

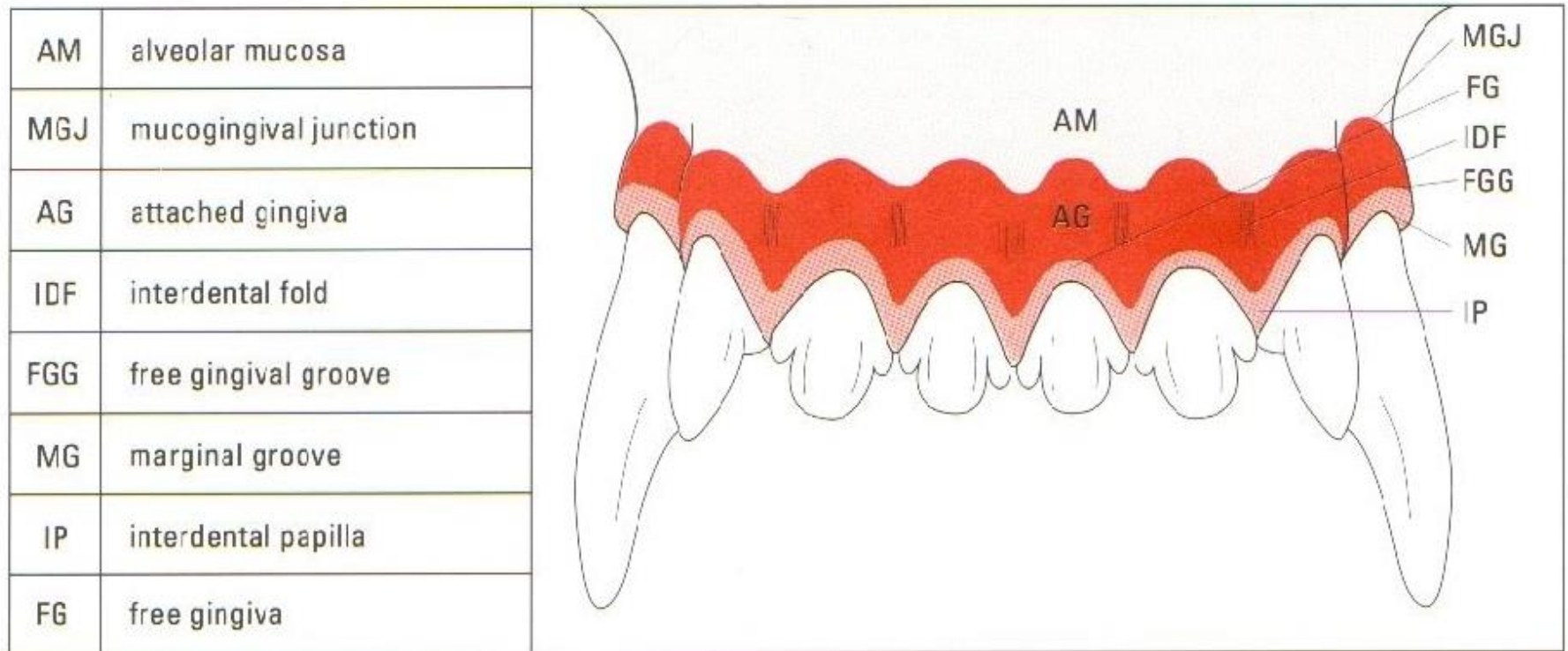


FIG. 1.14 The visible landmarks of clinically normal gingiva.

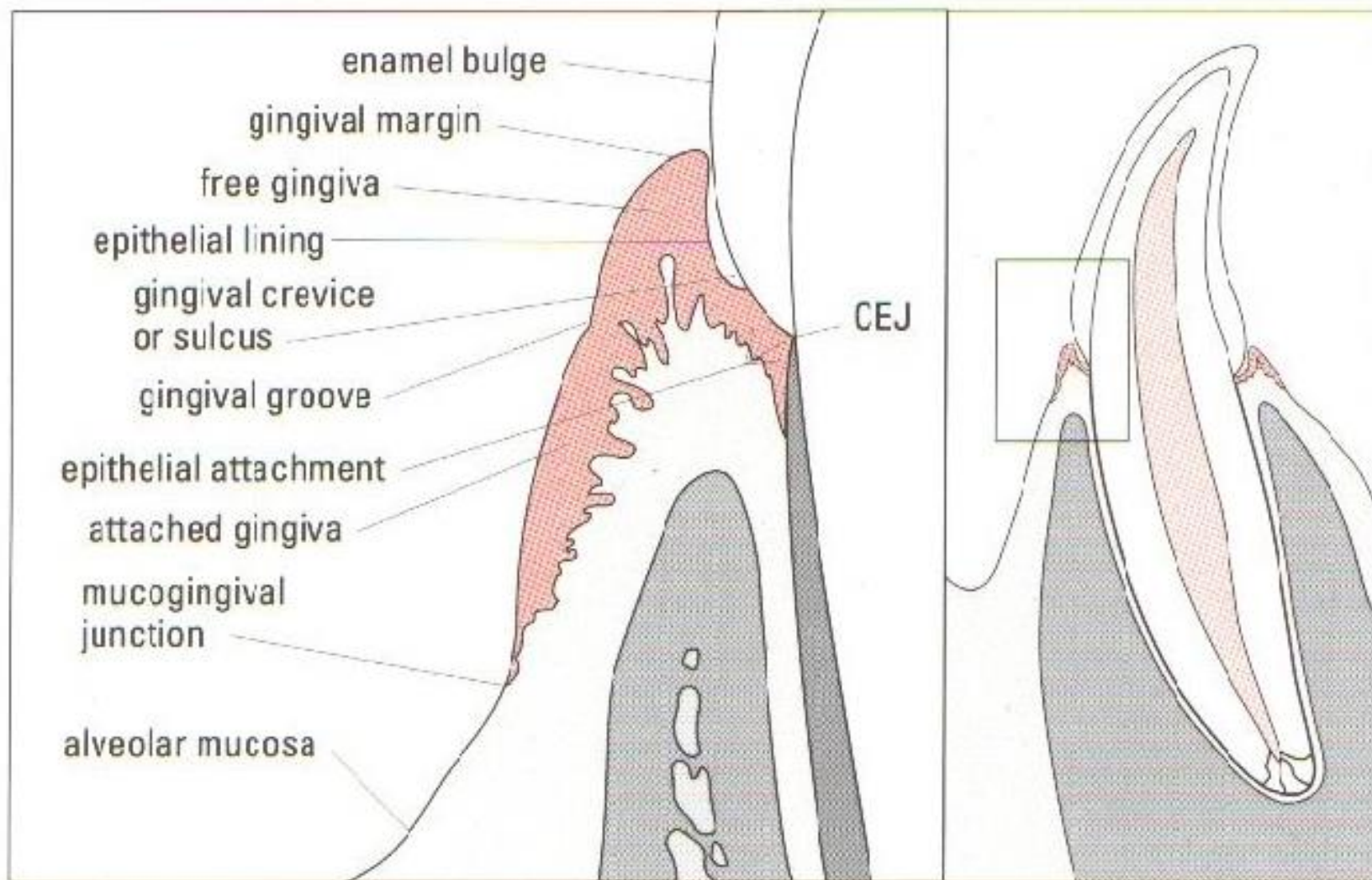


FIG. 1.15 The normal relationship between the gingiva and the tooth.

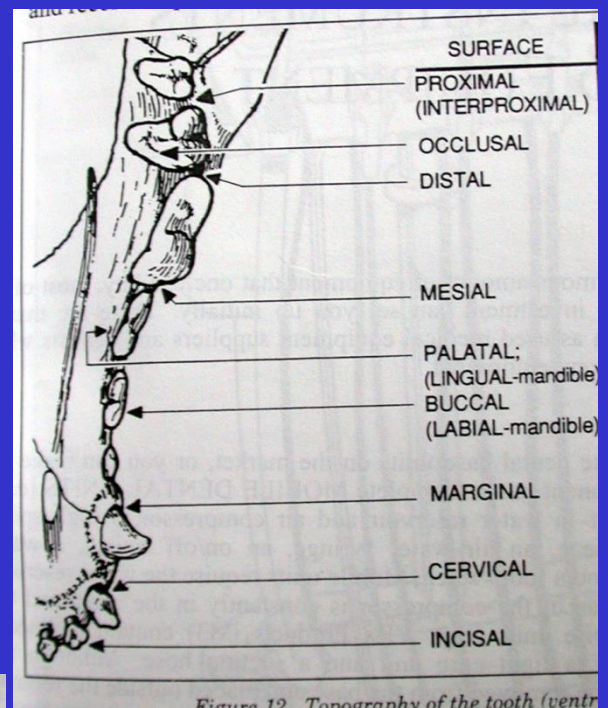
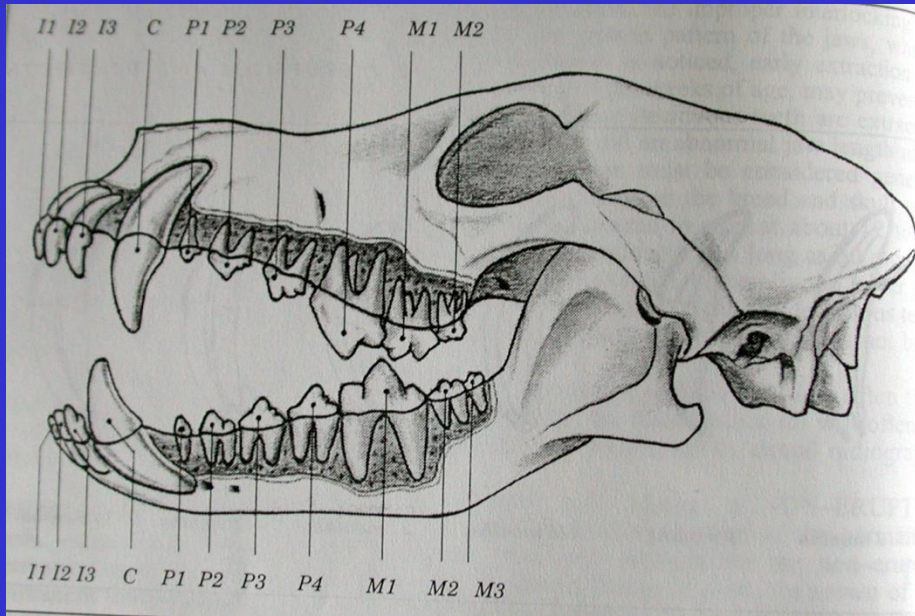



Figure 12. Topography of the tooth (ventr



TERMINOLOJİ

