

MİNE DİSPLAZİSİ ve RENK DEĞİŞİMİ

Mine displazisi : mine defekti vey tam olmayan mine gelişimini ifade eder

Hereditör, Çevresel (lokal yaralanma, enfeksiyon, florozis

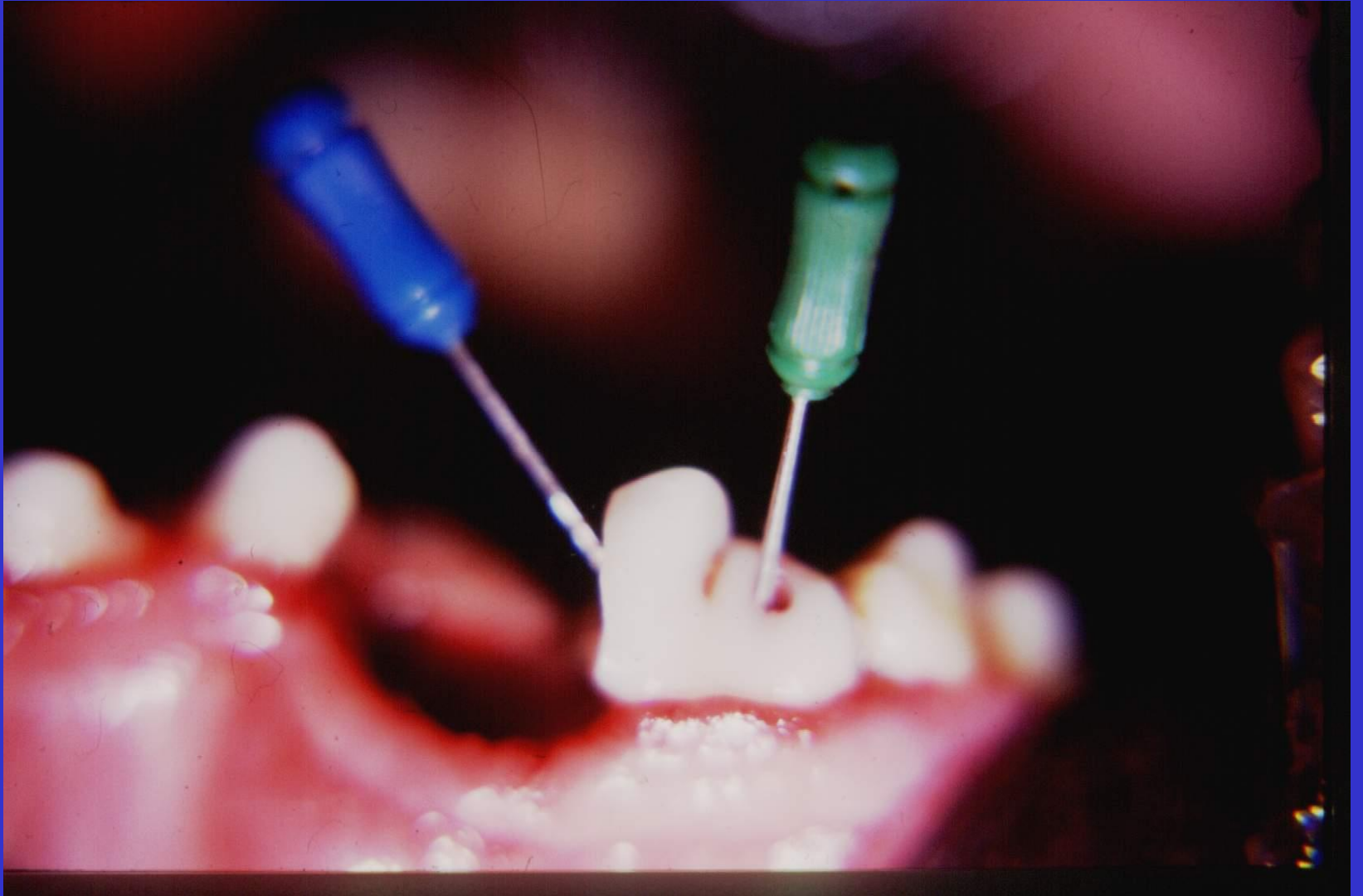
Dentin açığa çıkarsa klinik önem taşır

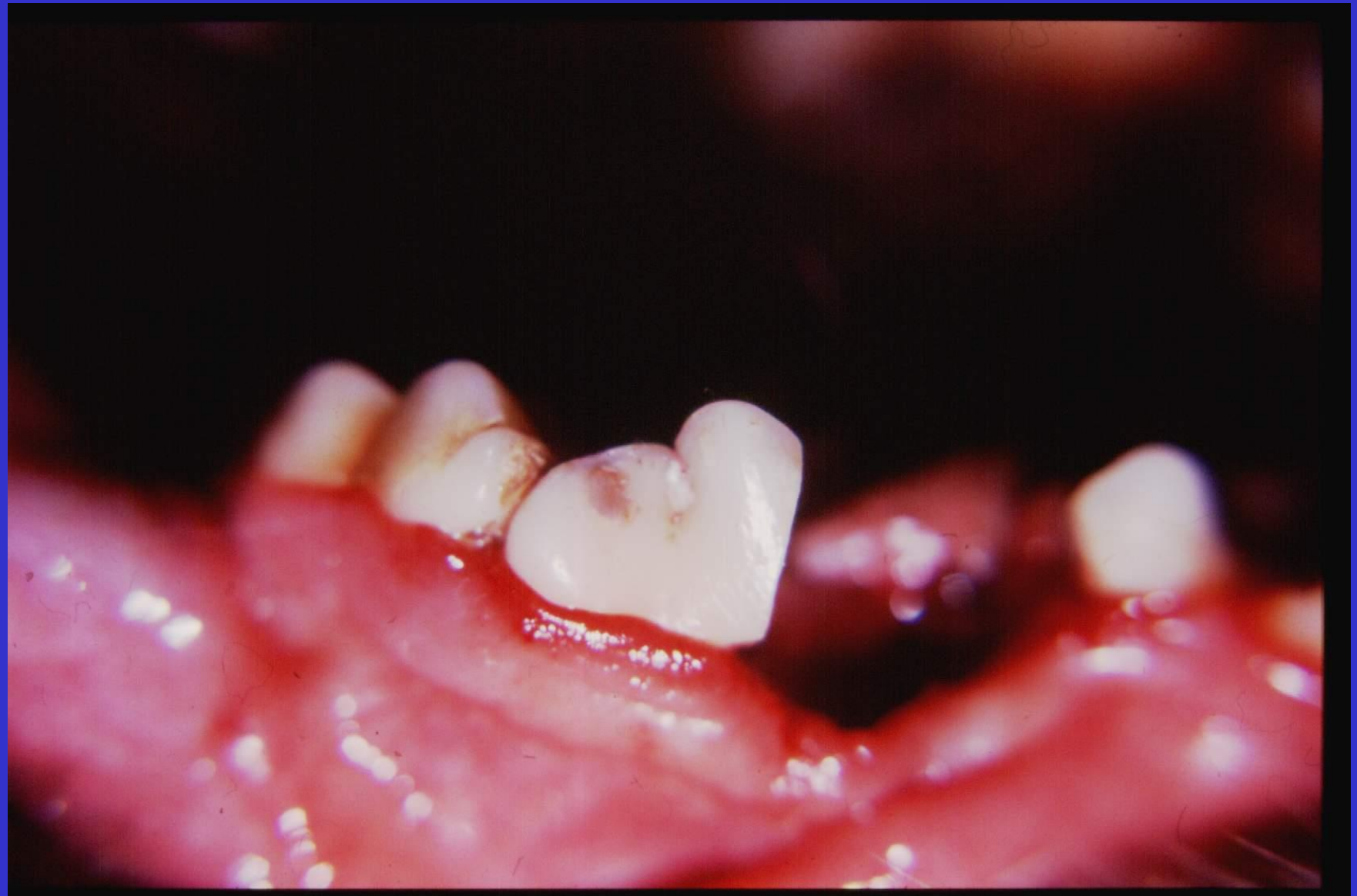Renk değişimi: Tetrasiklin, estetik sorun

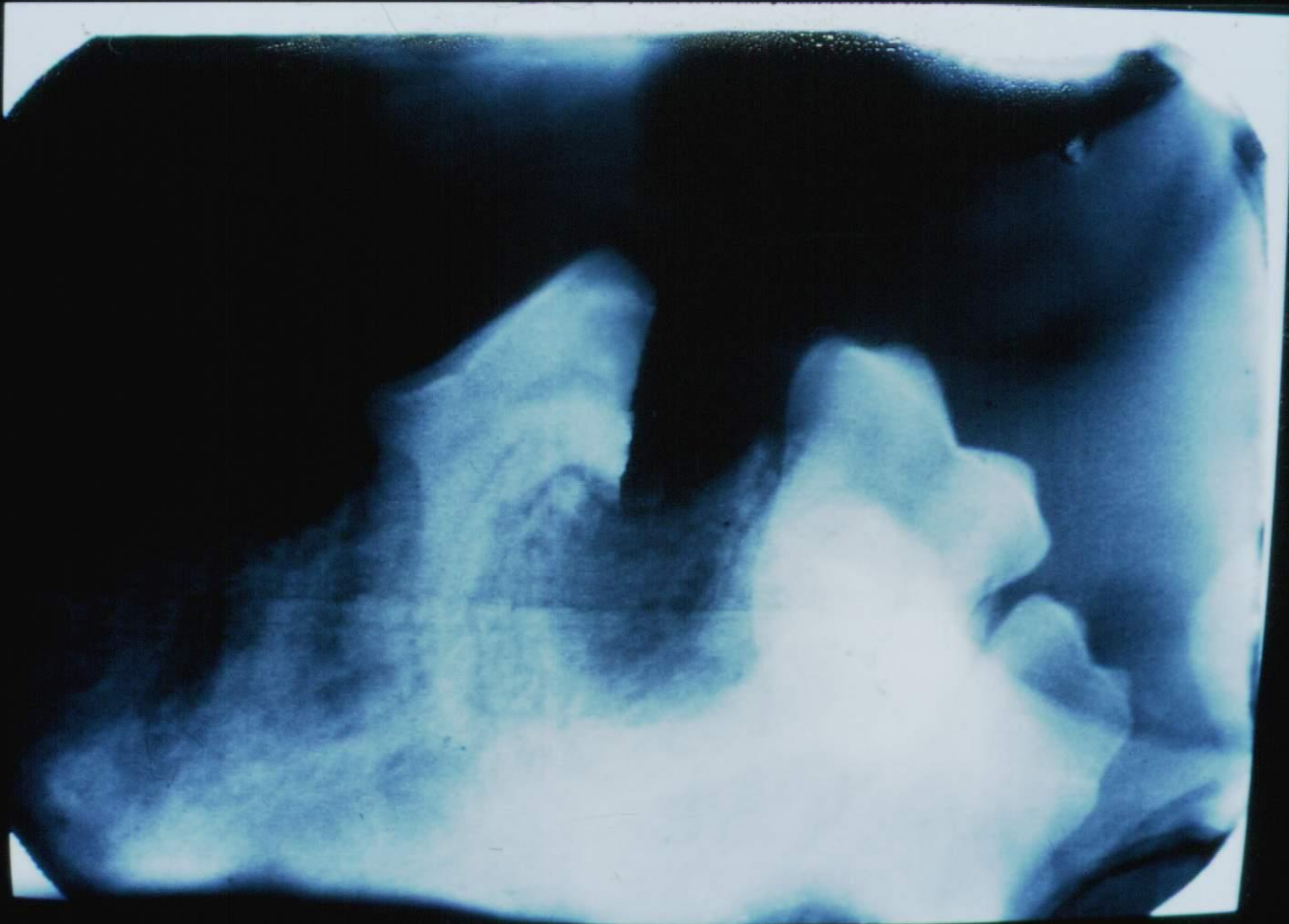
ENDODONTİ

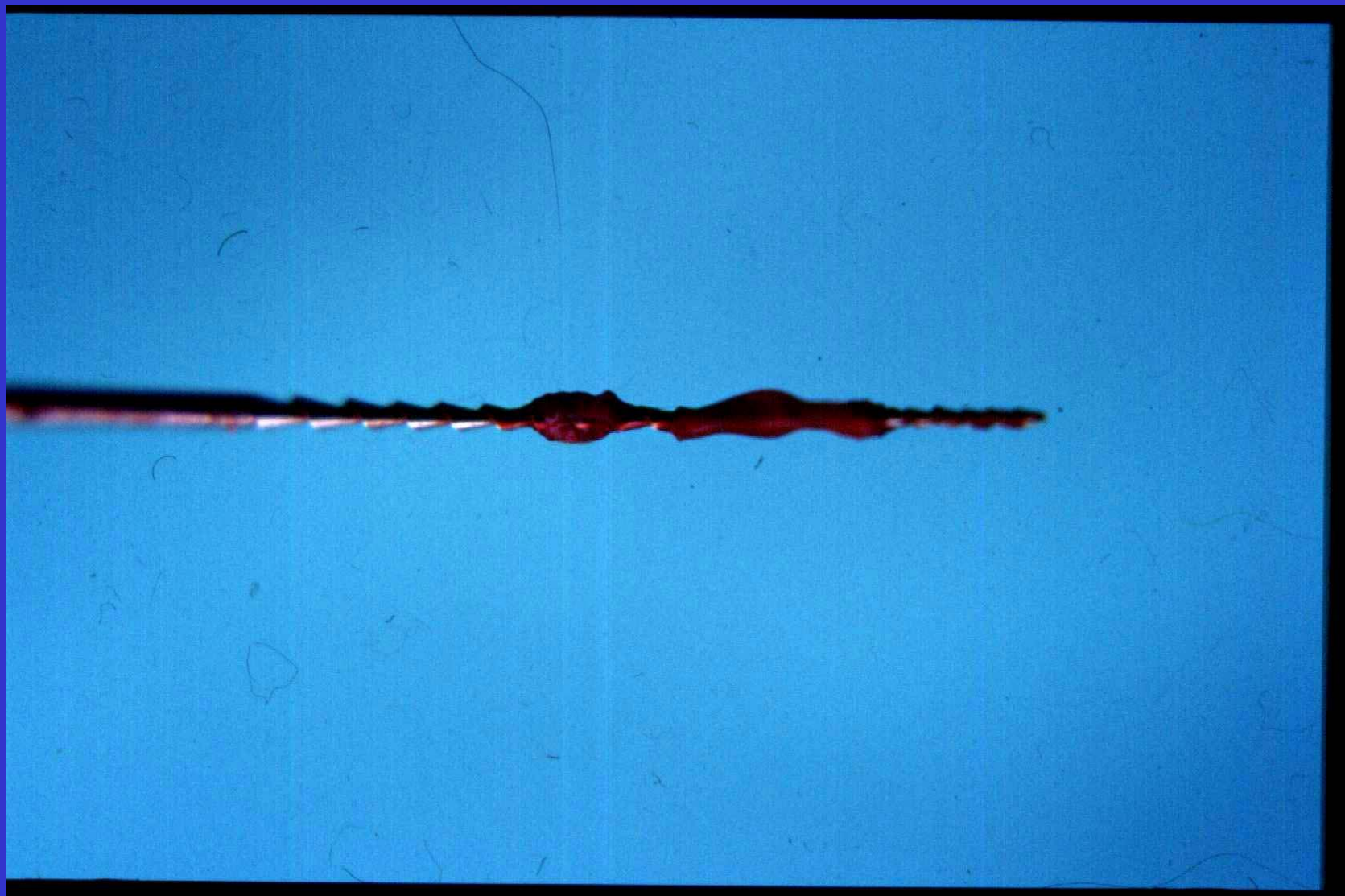
- *Kron kırıkları
- *Apikal kan dolaşımının bozulması
- *Karies
- *Kedi kariesi
- *Termal hasar
- *Hematojen enfeksiyon

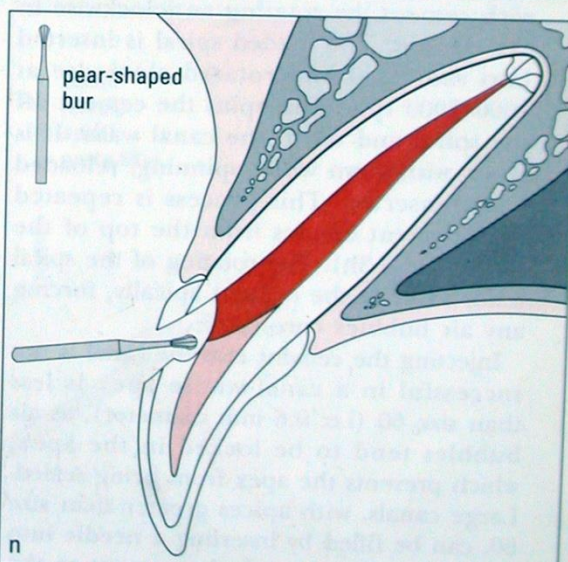
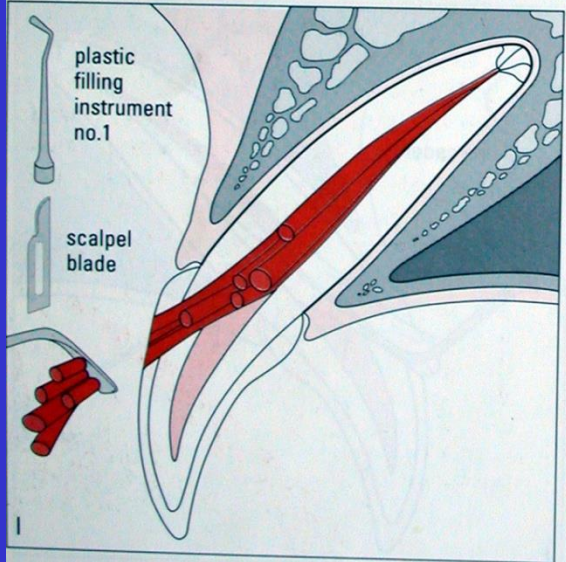
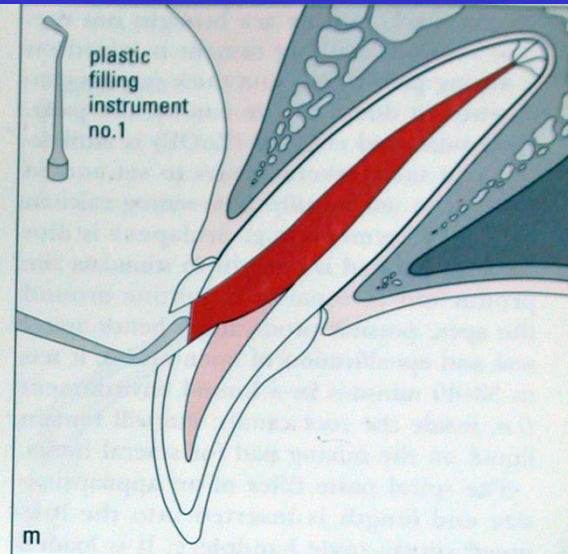
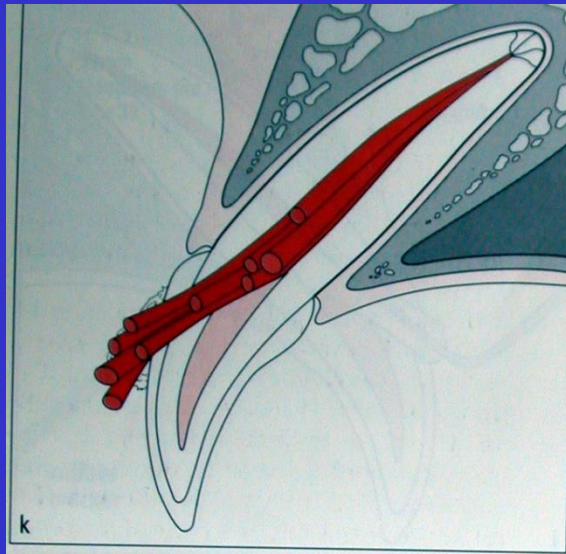
KANAL TEDAVİSİ

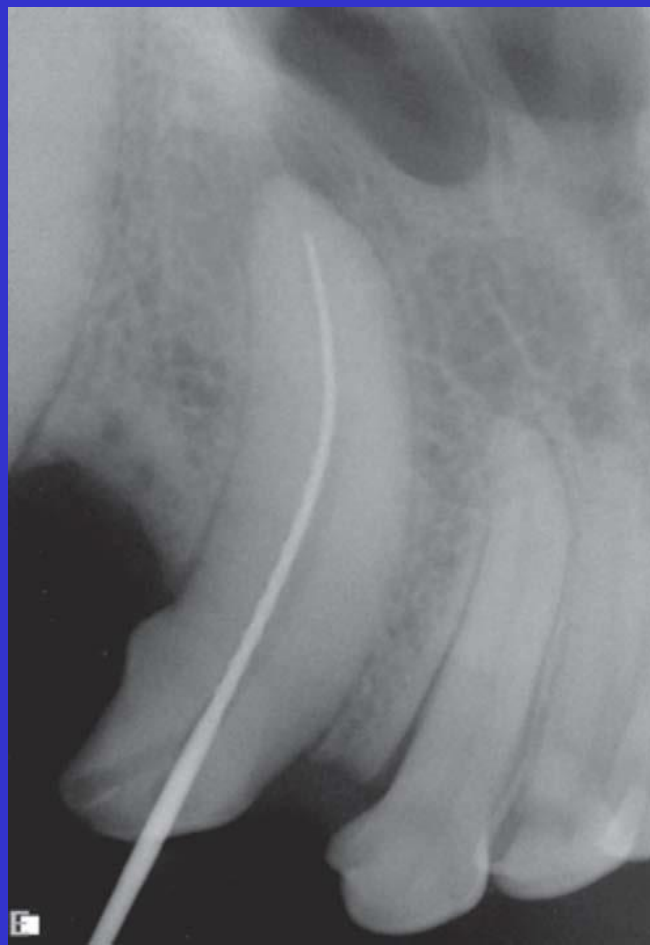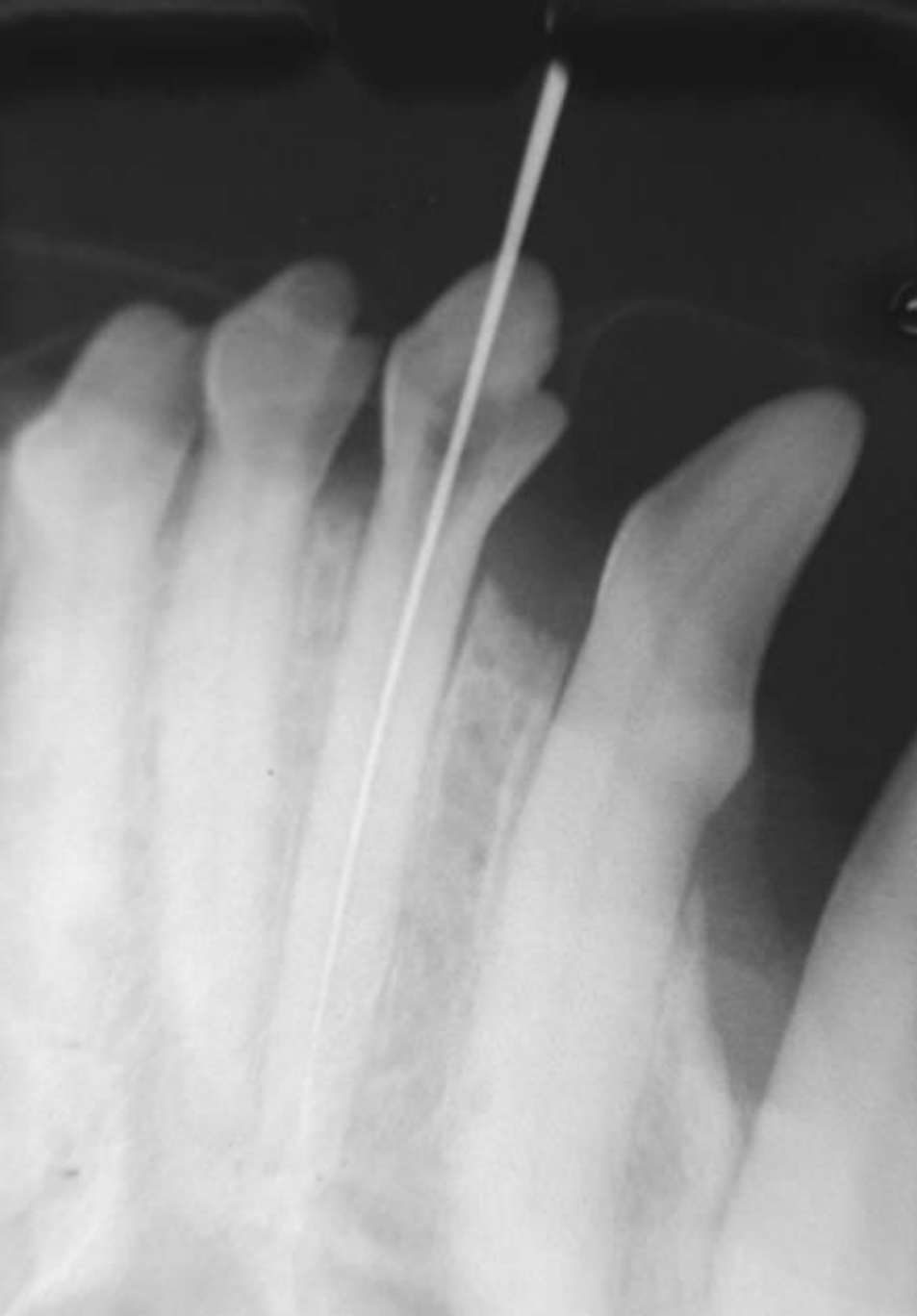



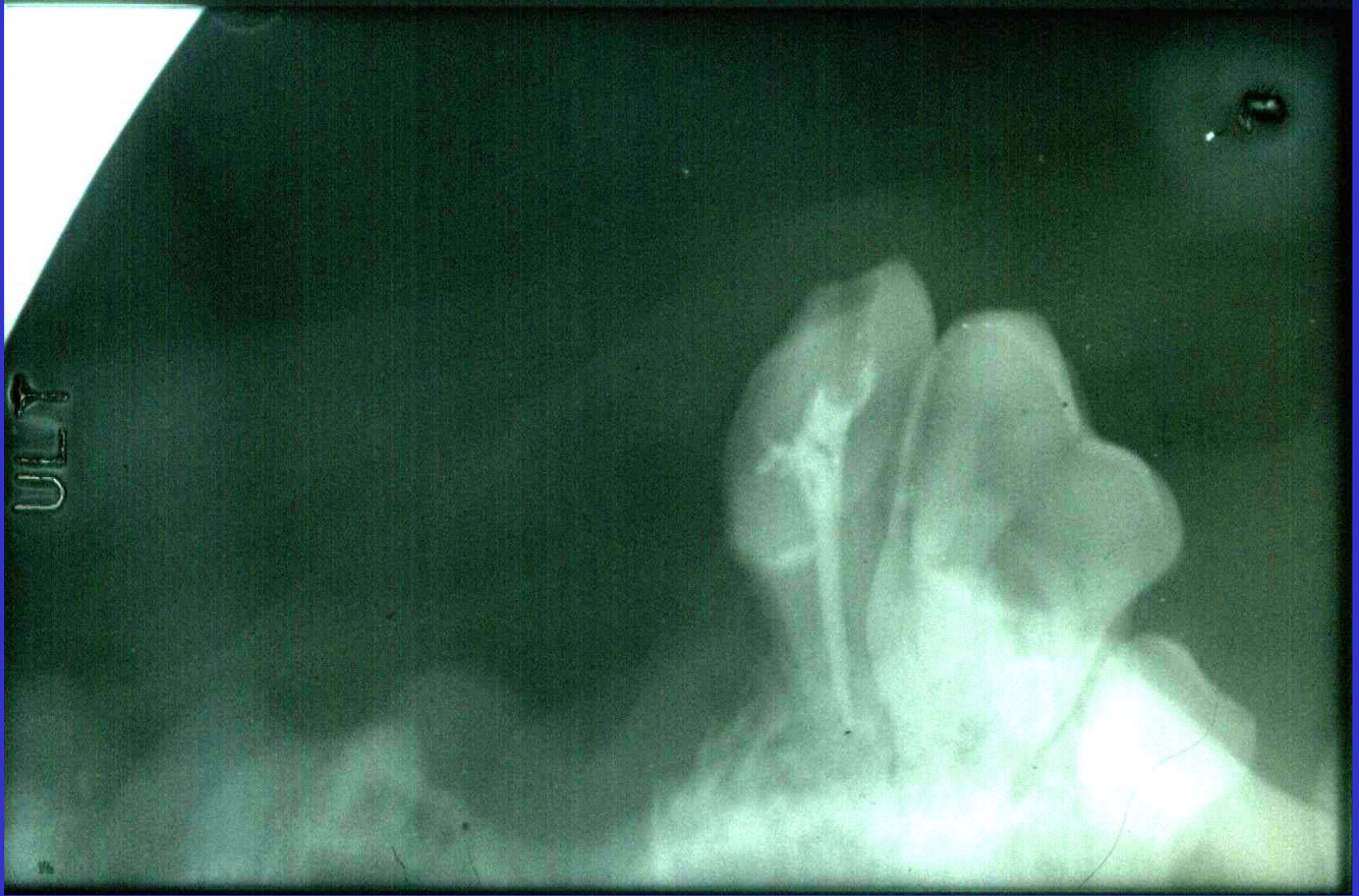


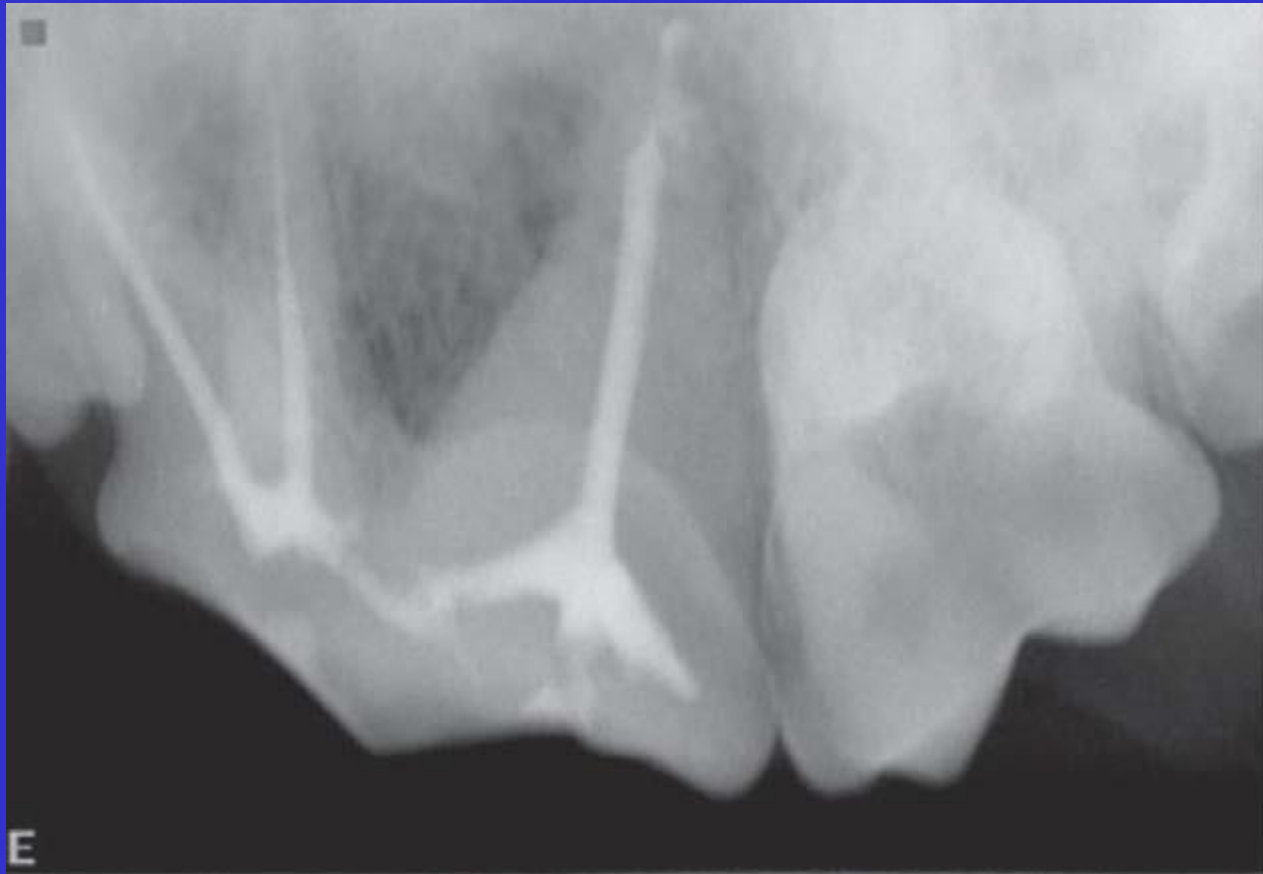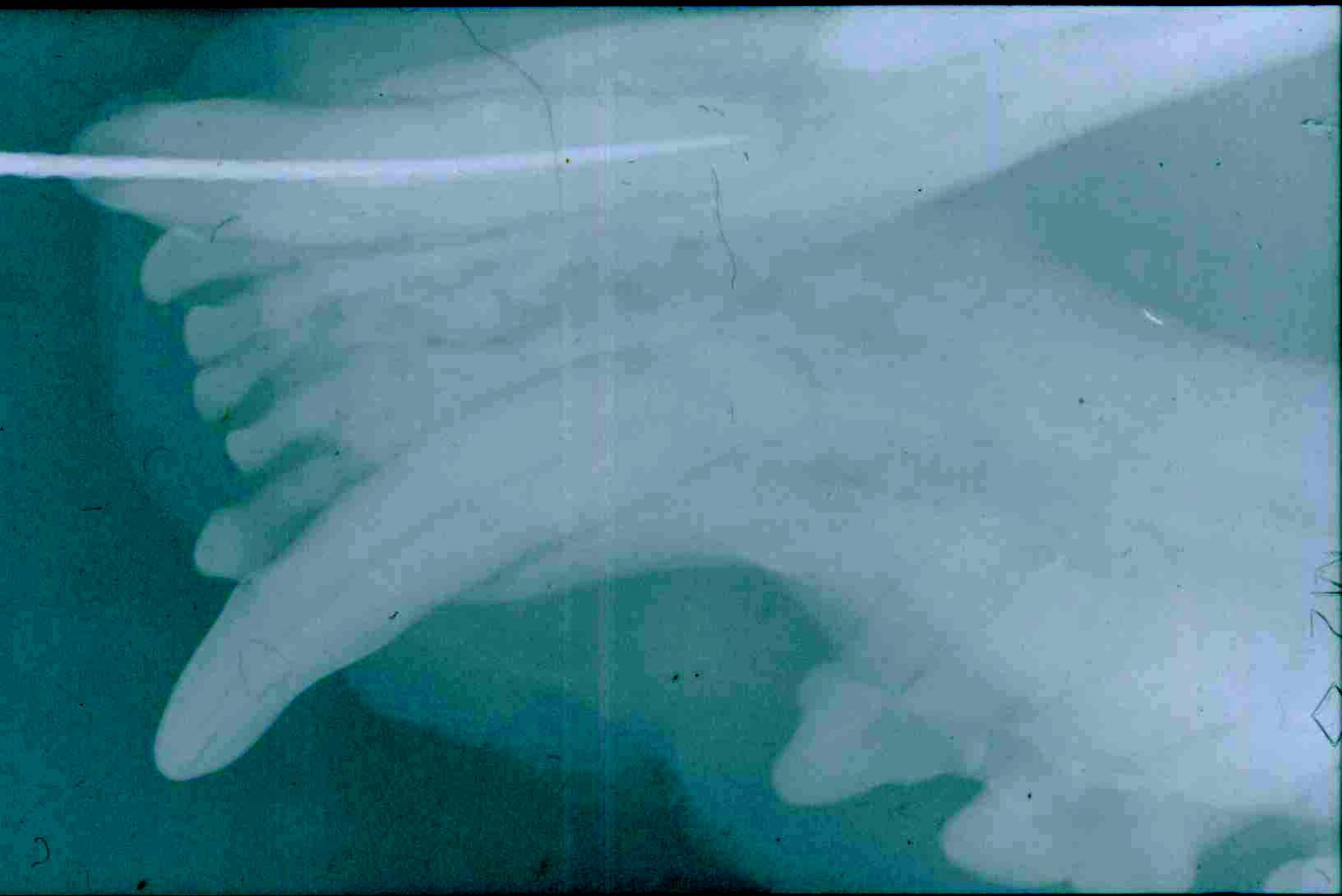












12
◇

