
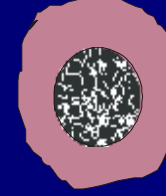


Köken hücre




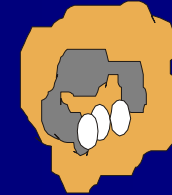


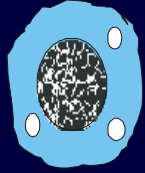
Lenfoid seri

Myeloid seri



Polimorfnükleer seri (Granülosit)

Mononükleer seri



NK hücre

T-lenfosit

B-lenfosit

Mast hücresi

Bazofil

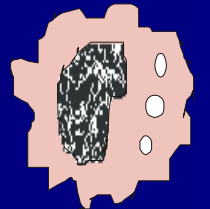
Eozinofil

Nötrofil

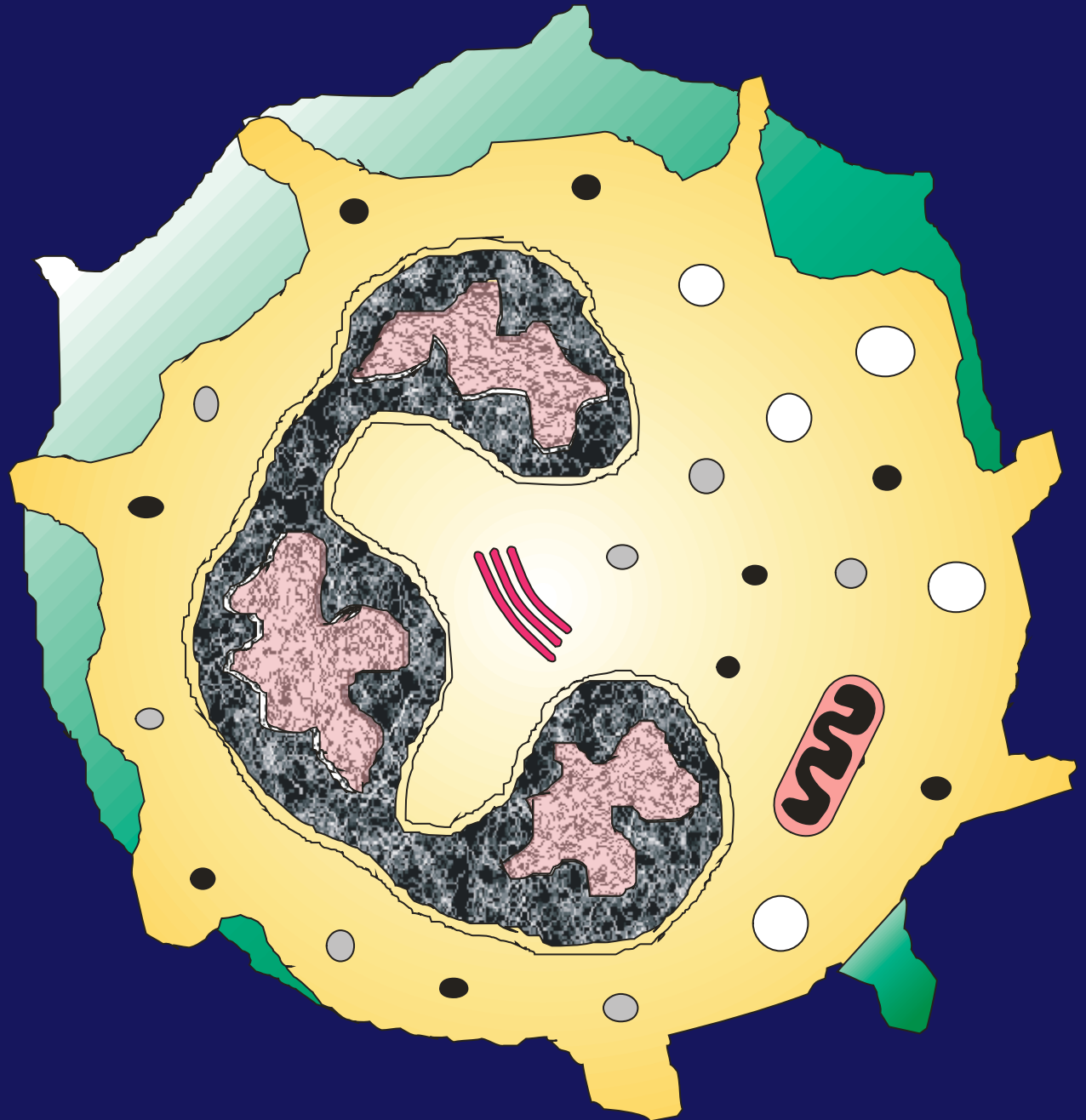
Monosit

Plazma hücresi


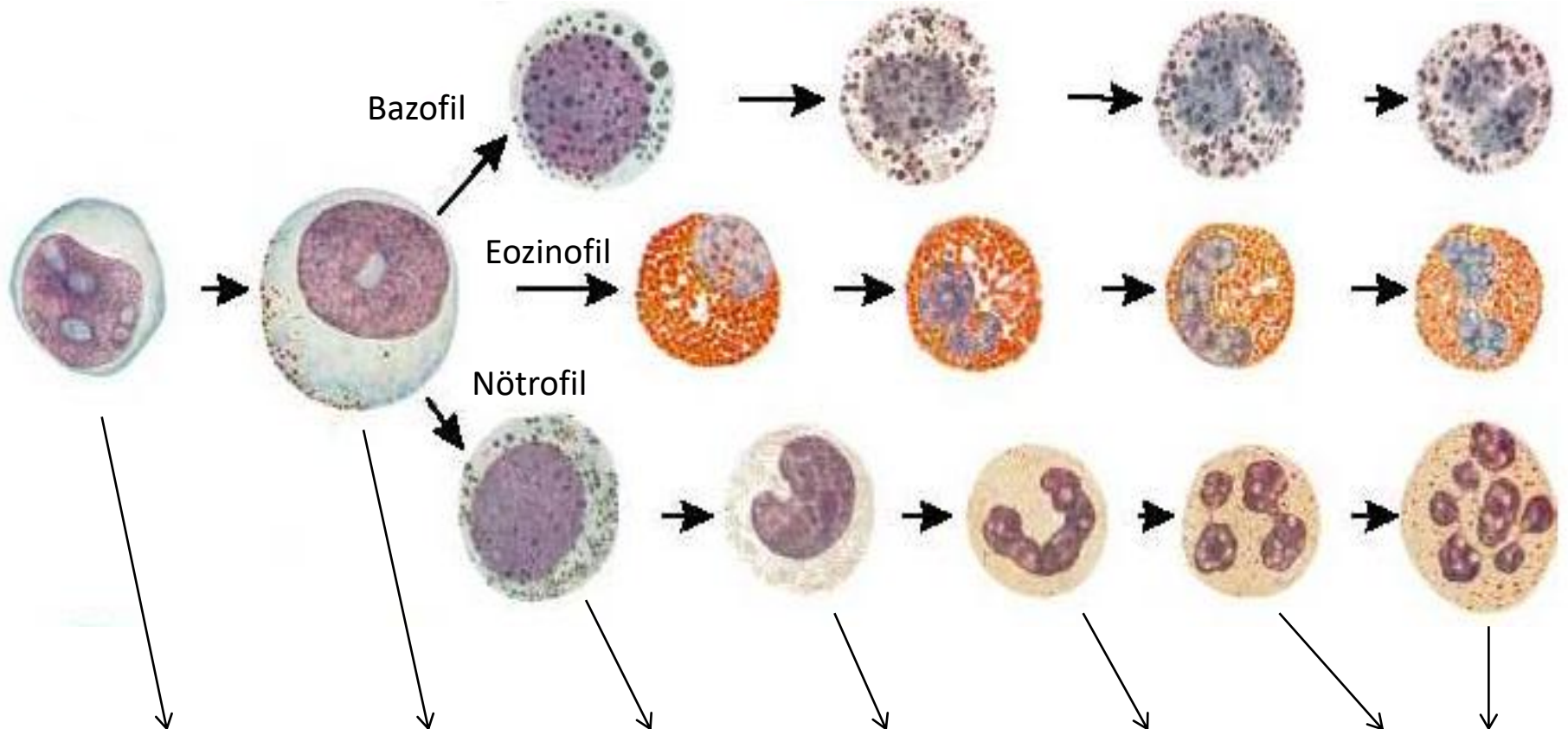
Makrofaj



# Nötrofil



# Granülositlerin Gelişim Aşamaları



Myeloblast

Promyelocyte

Myelocyte

Metamyelocyte

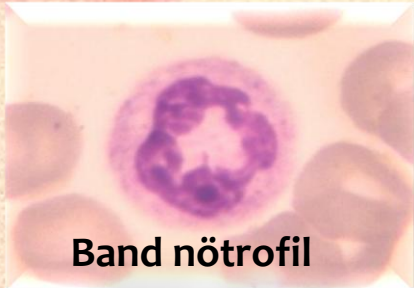Band  
granulocytes

Segmented  
granulocytes



## Nötrofillerin Gelişim Formları

Band nötrofil

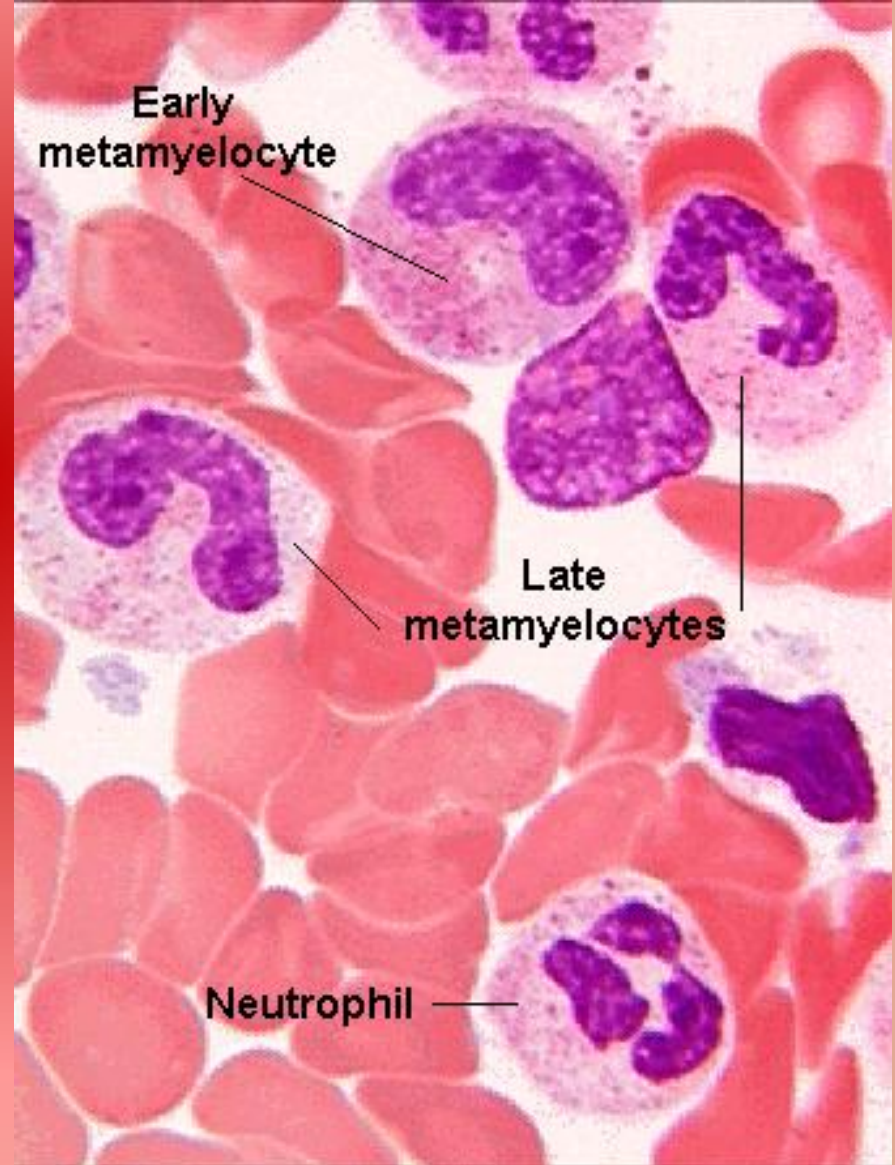


Band nötrofil

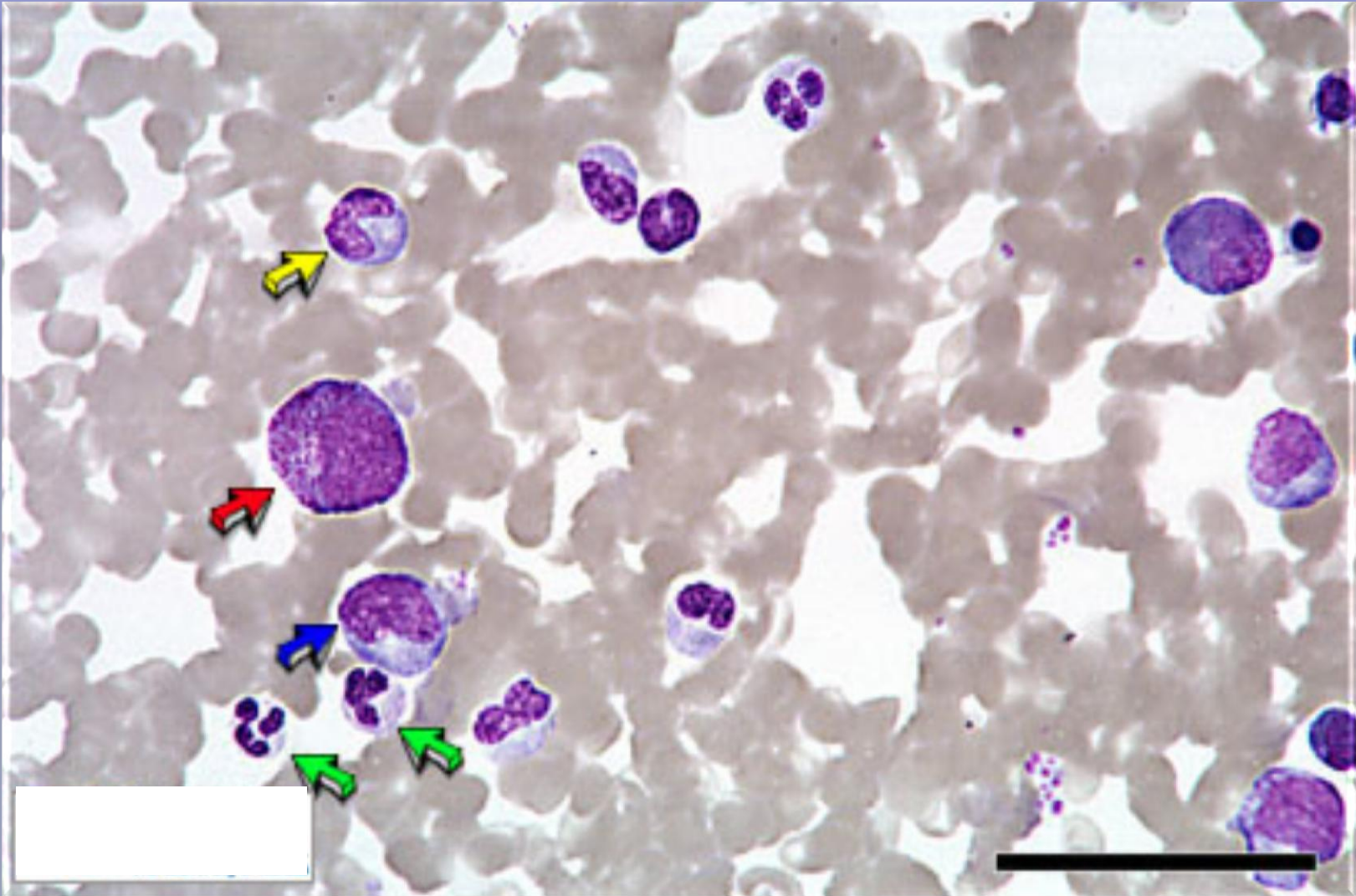
Early  
metamyelocyte

Late  
metamyelocytes

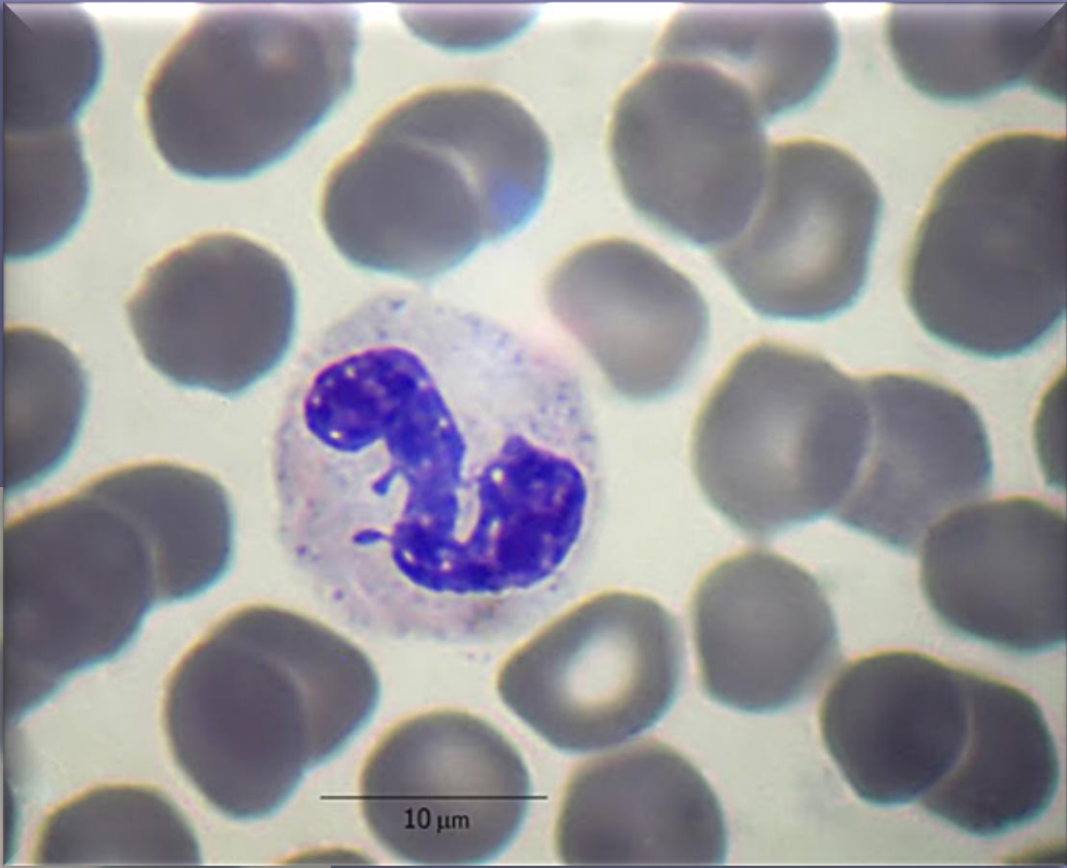
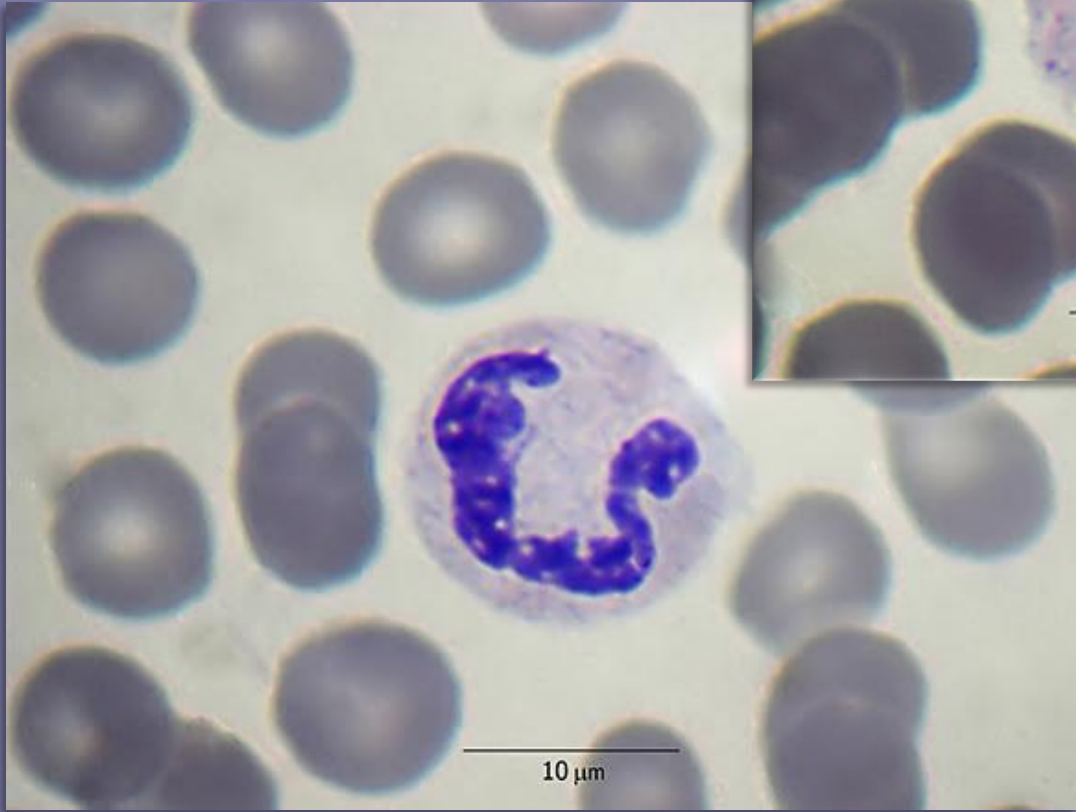
Neutrophil







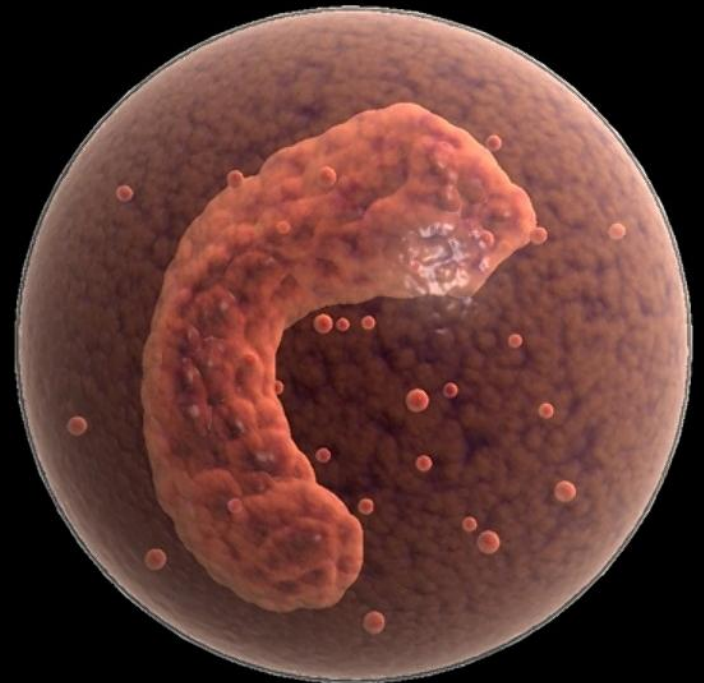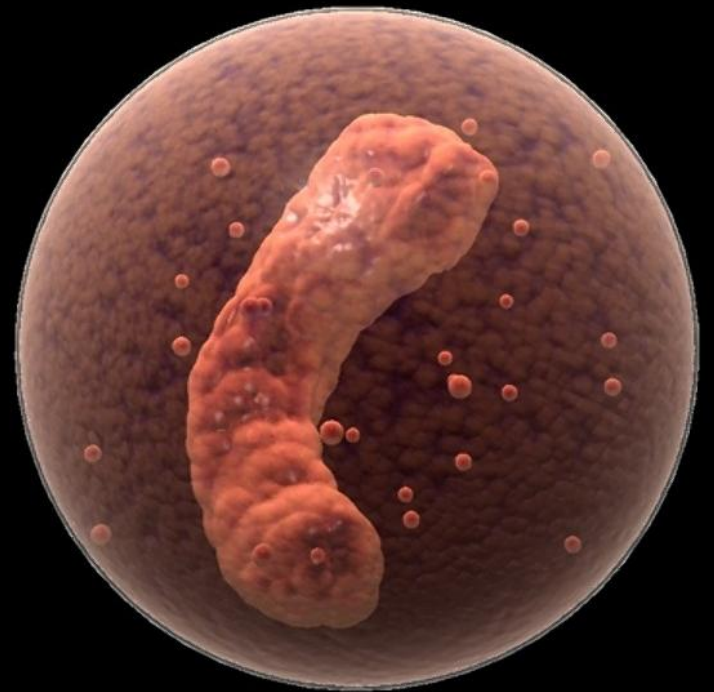
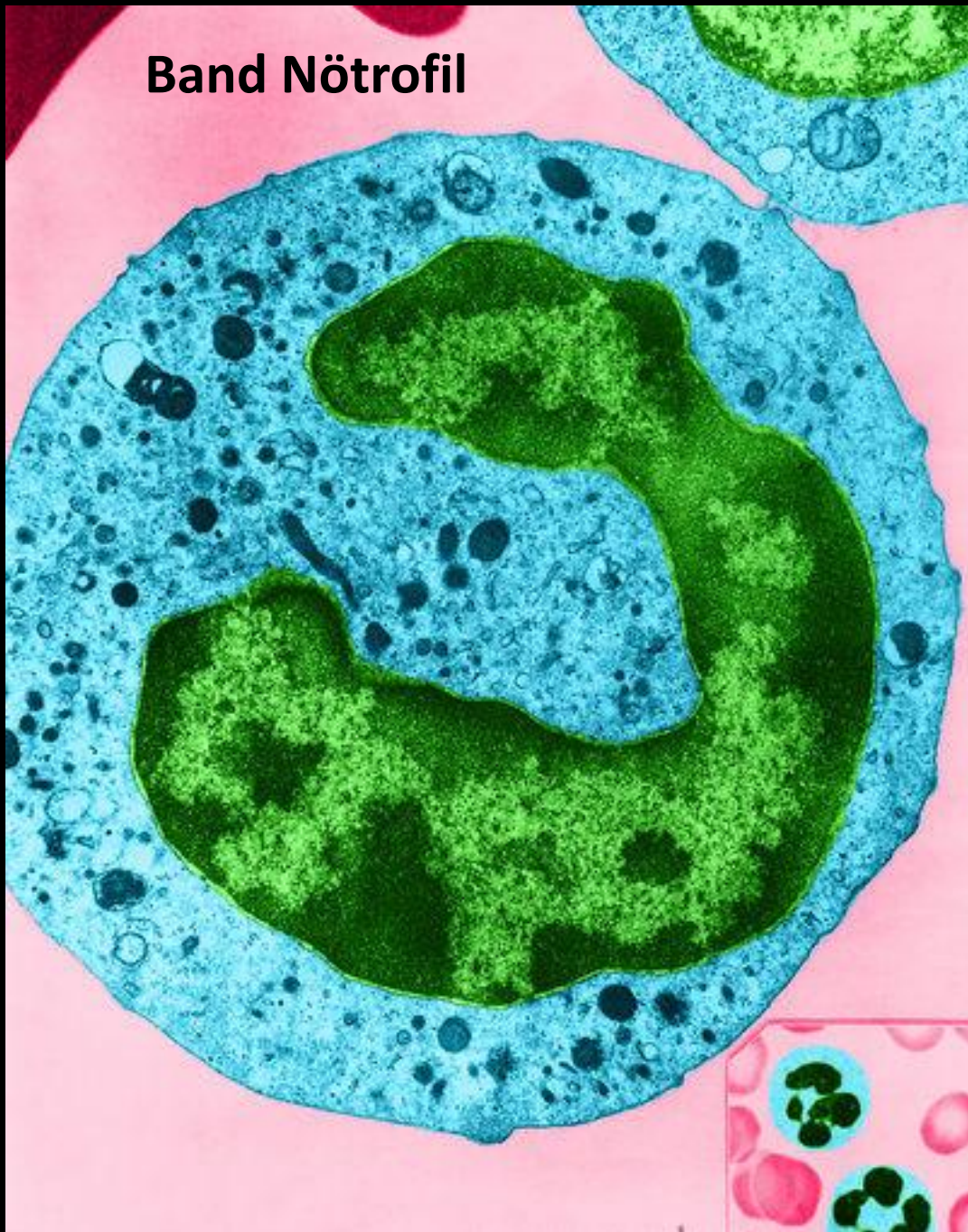 Nötrofil  Band Nötrofil  Promyelosit  Myelosit



Band Nötrofil

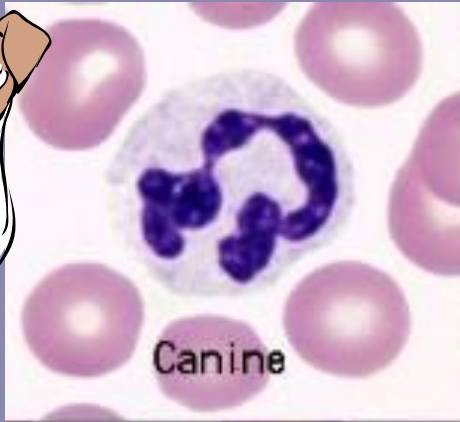


**Band Nötrofil**

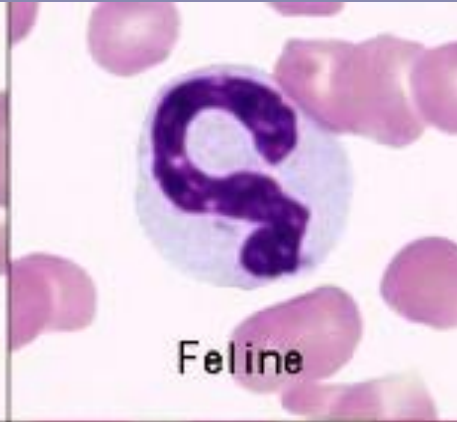



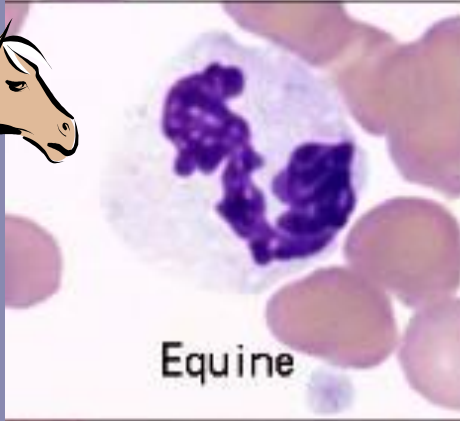

# Hayvan Türlerinde Nötrofiller



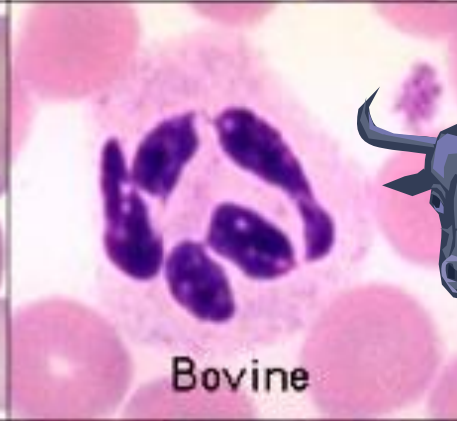Canine



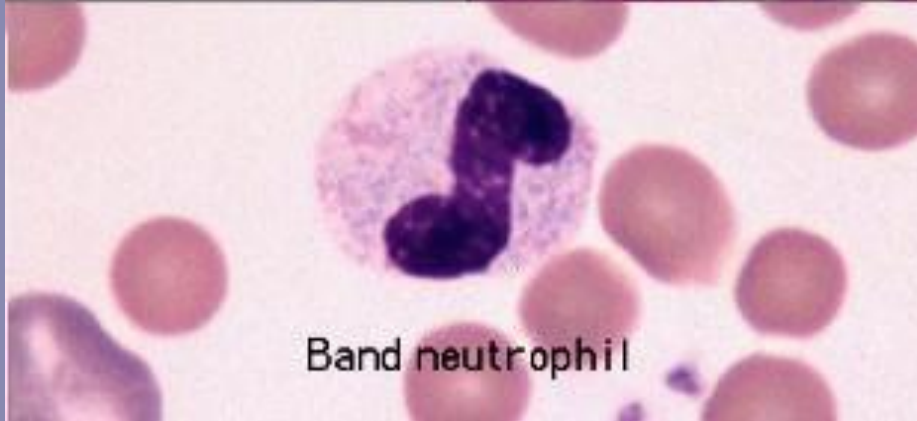Feline



Equine

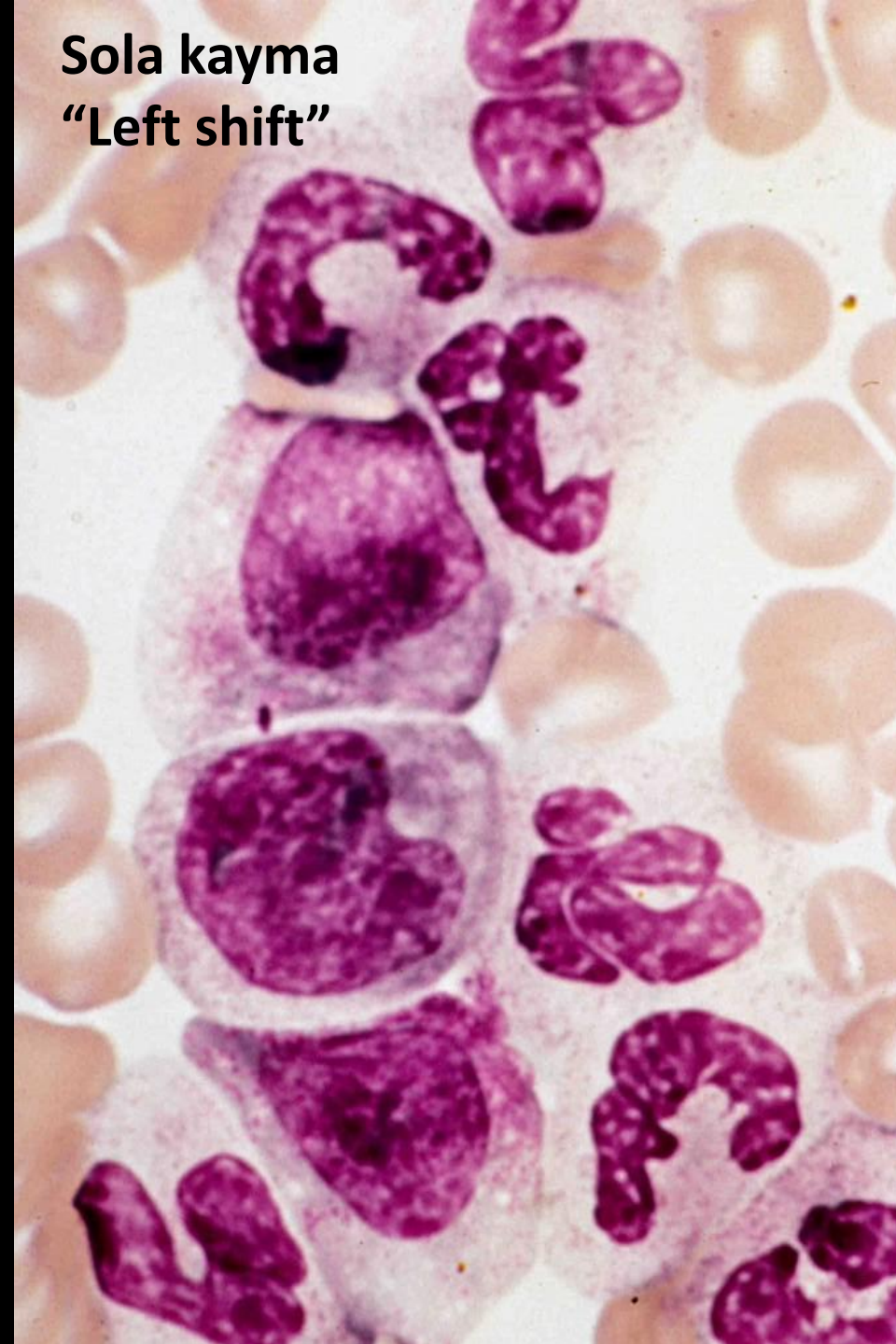
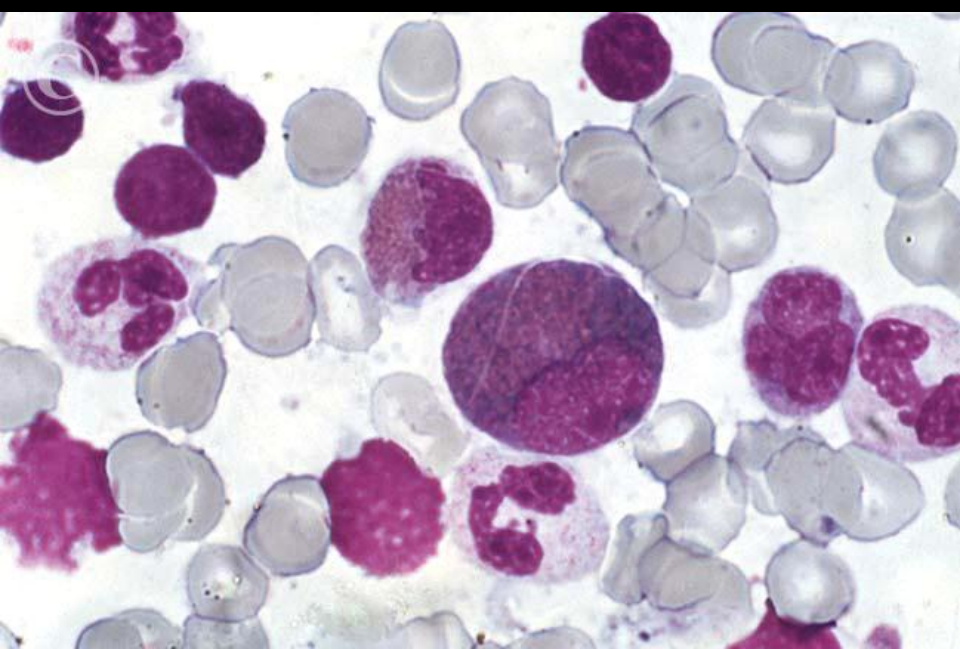
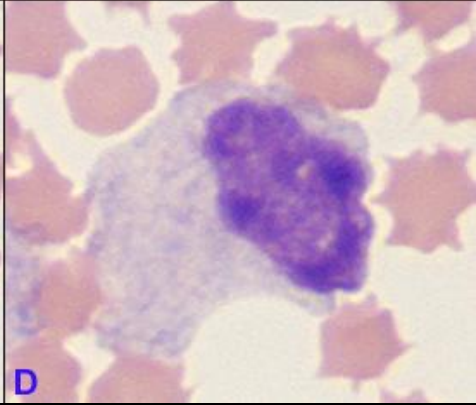
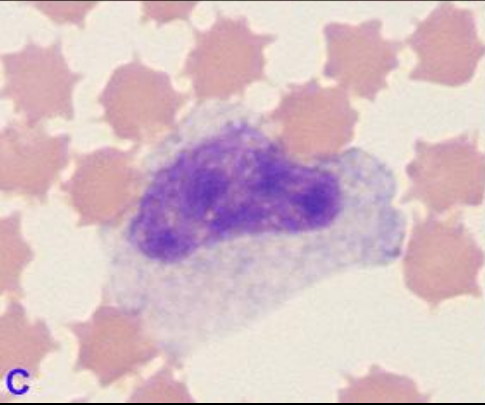
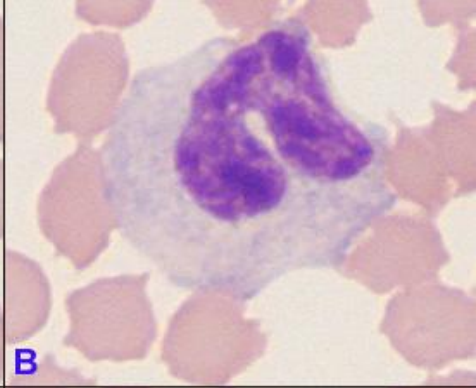
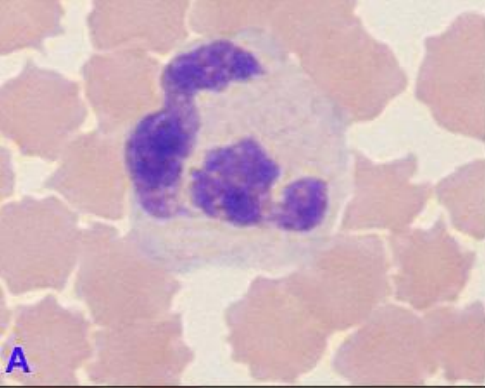


Bovine



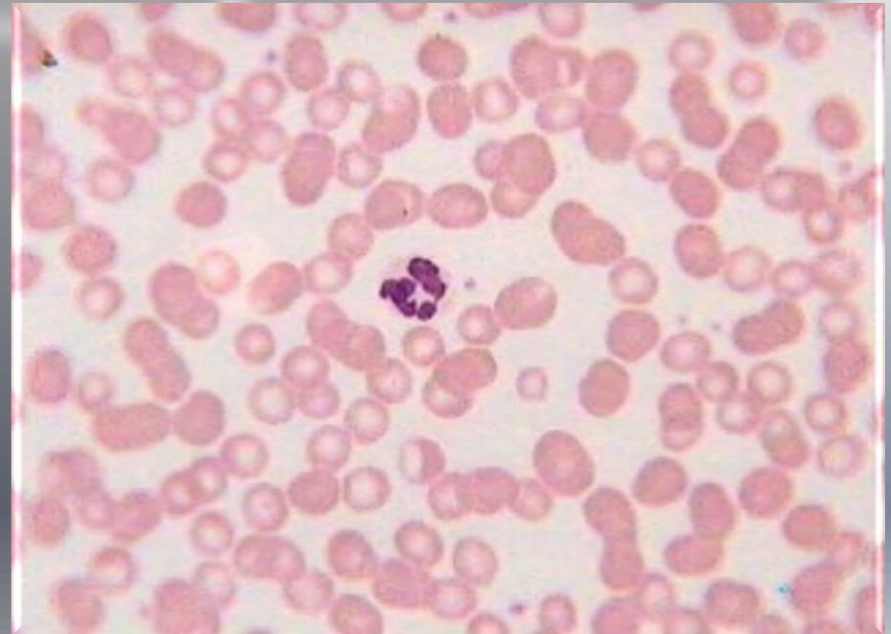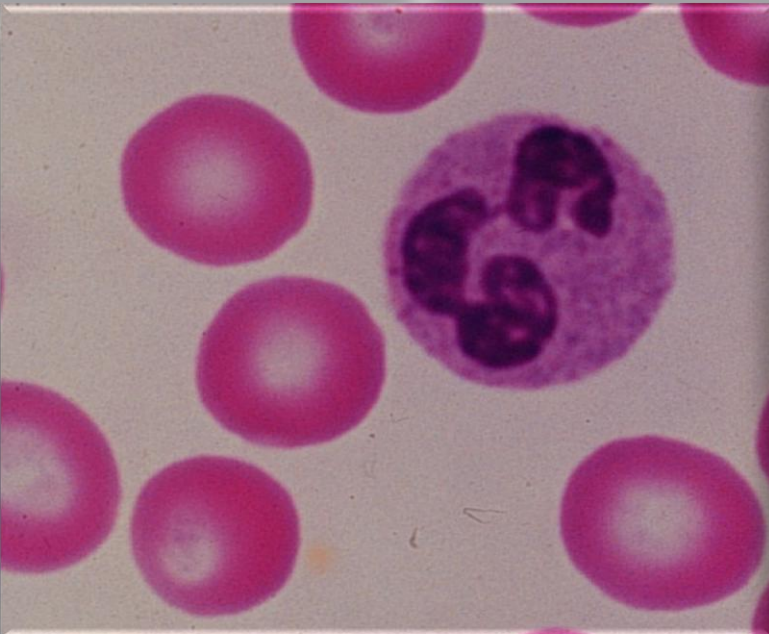
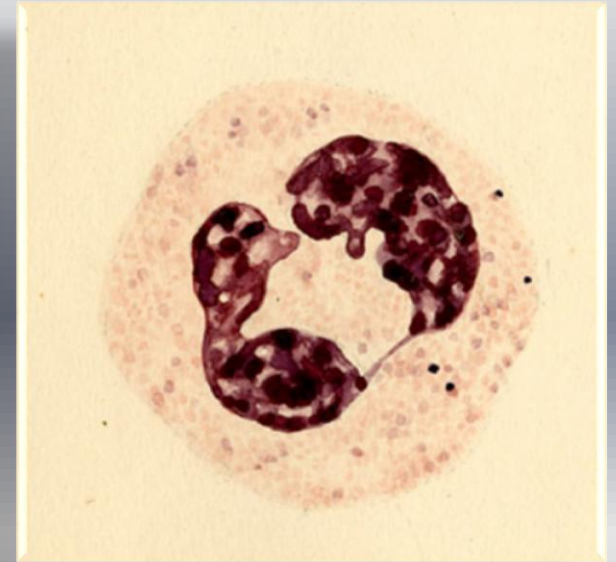
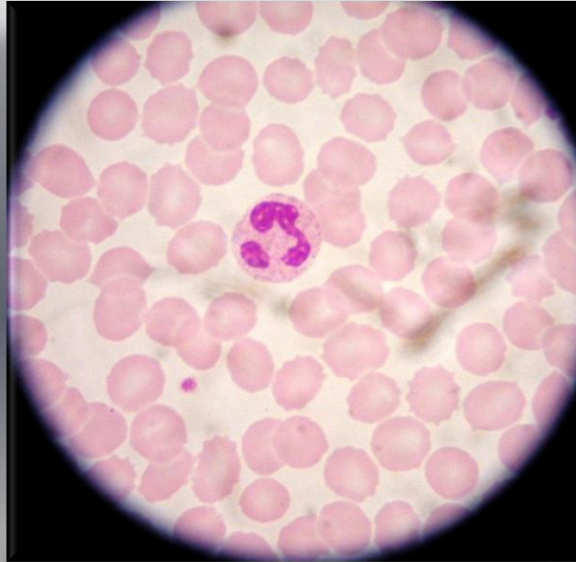
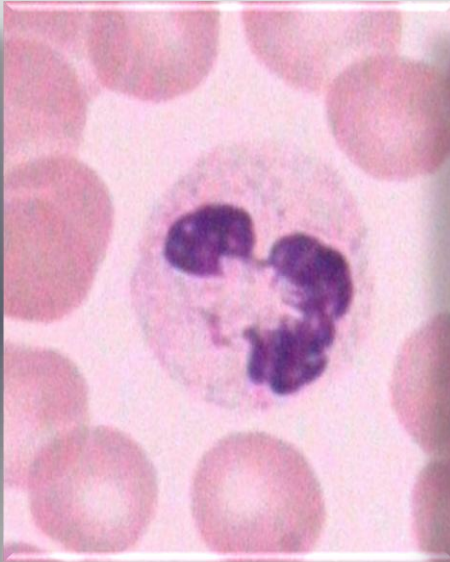
Band neutrophil

Sola kayma  
"Left shift"



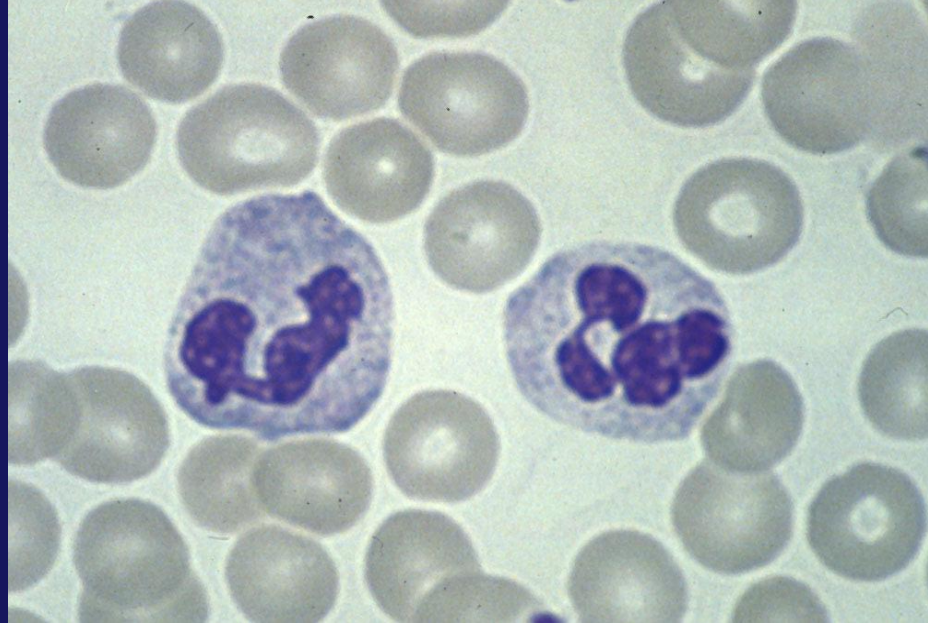
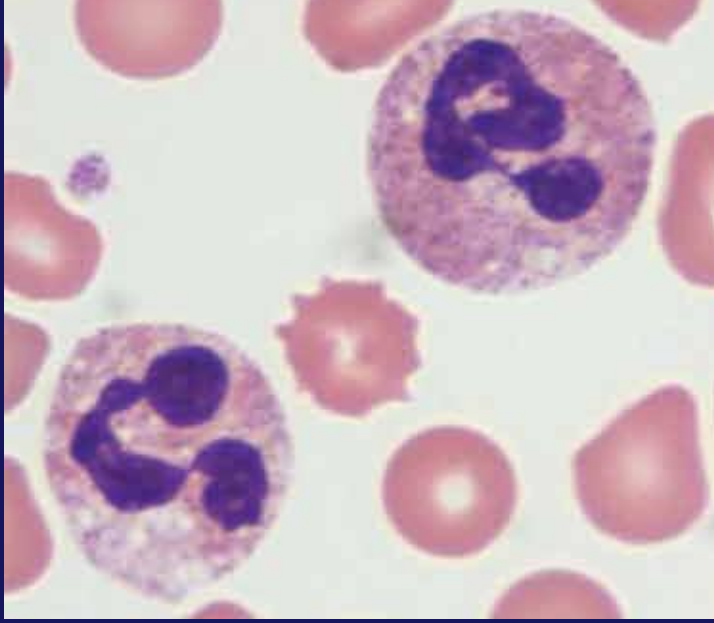
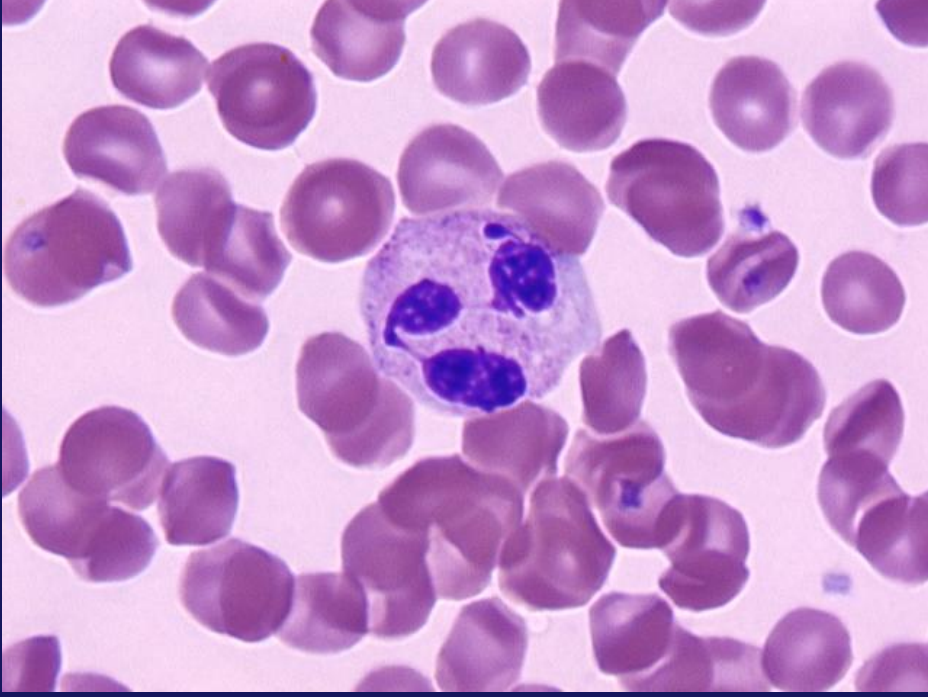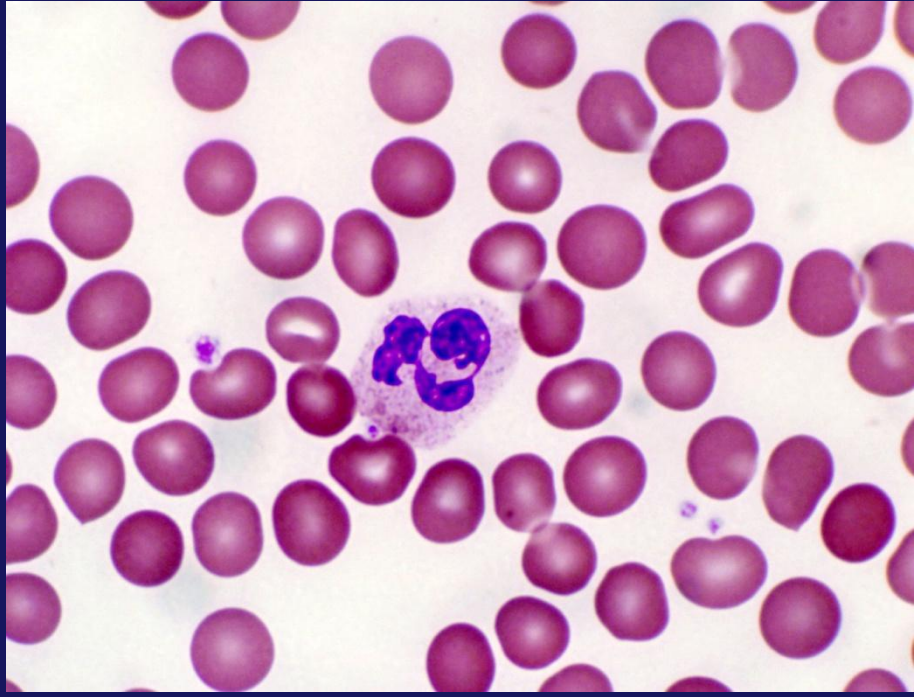


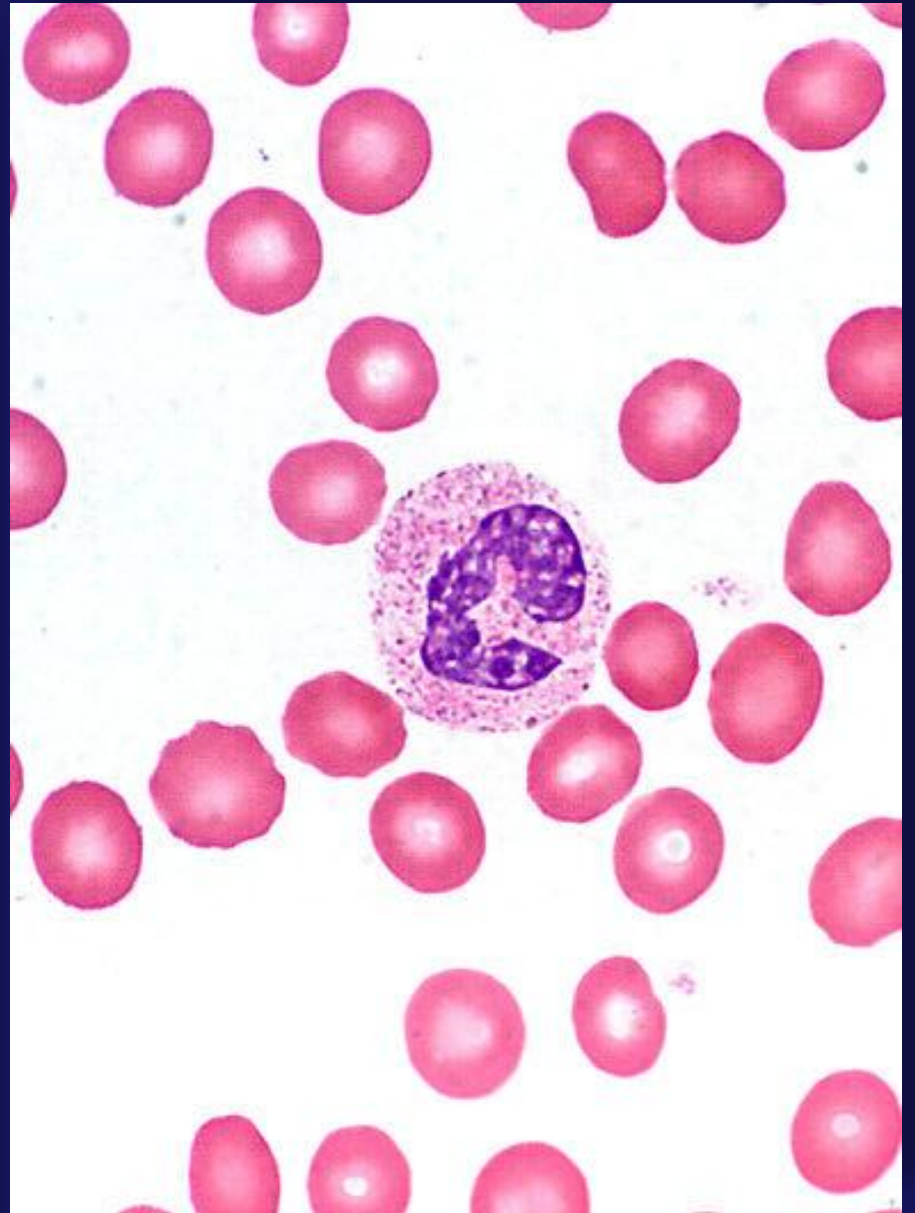
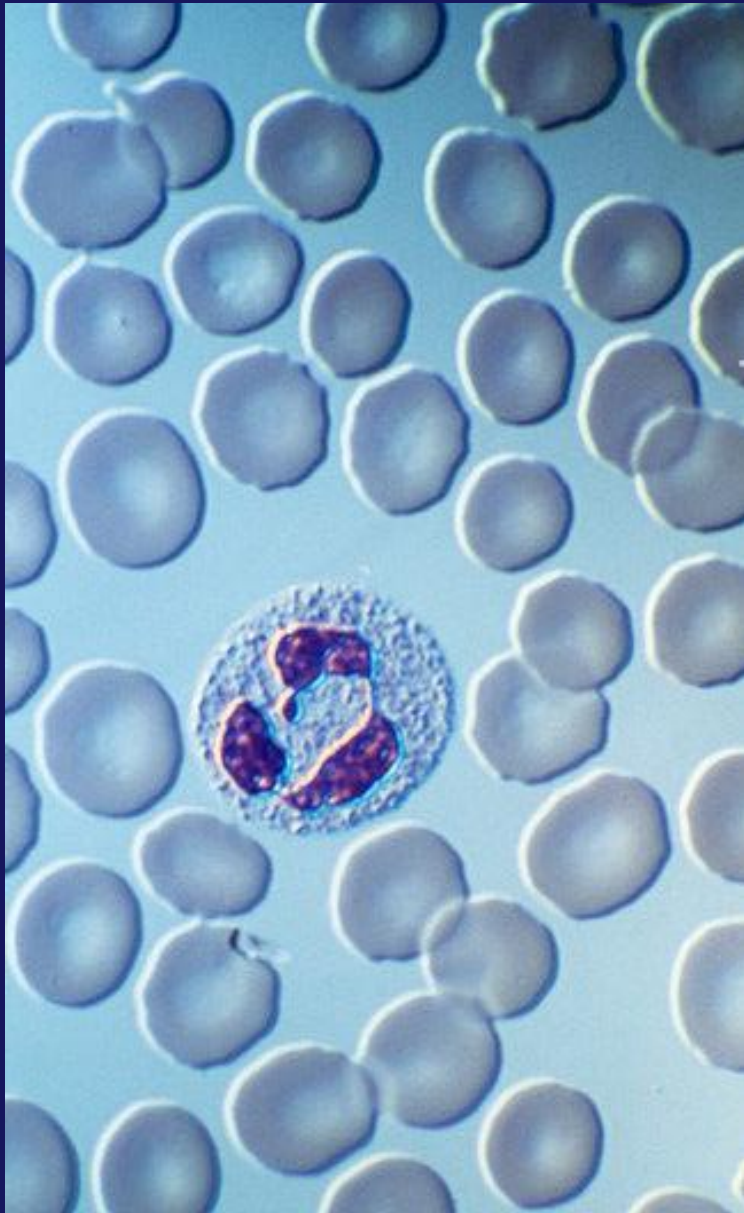
# *Sürme frotilerde nötrofiller*





Sürme frotilerde nötrofiller

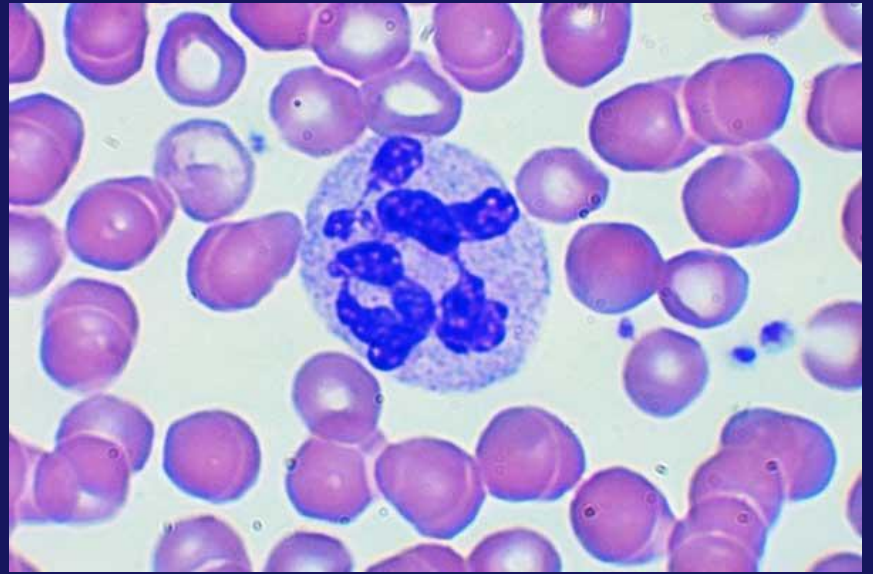
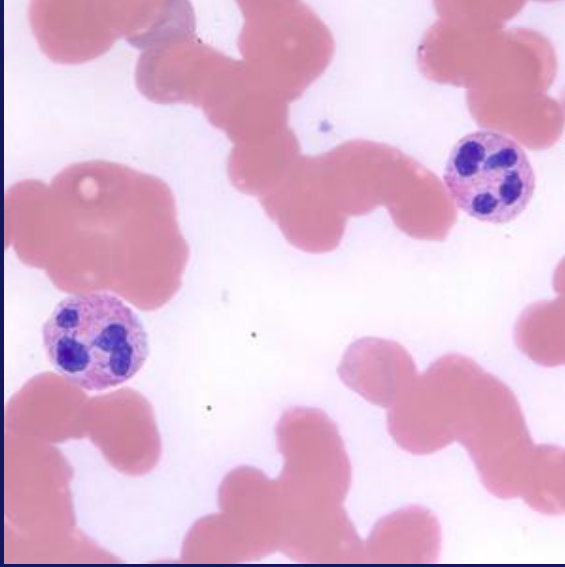
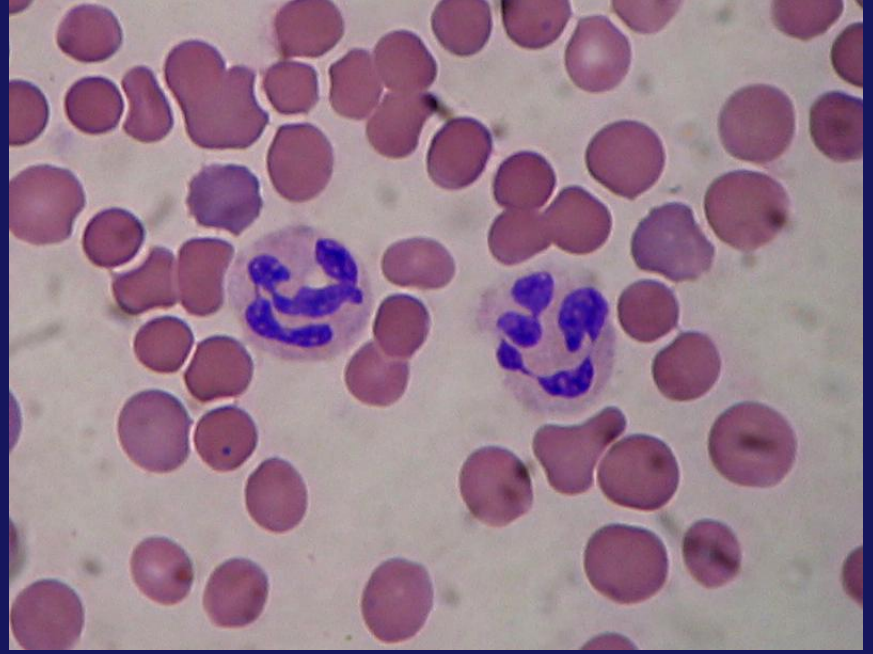
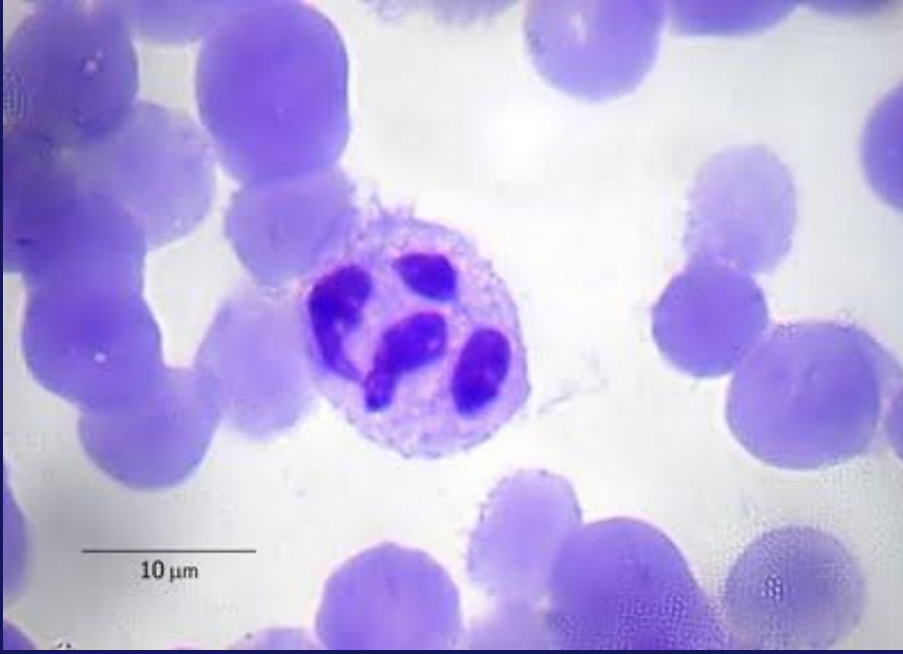



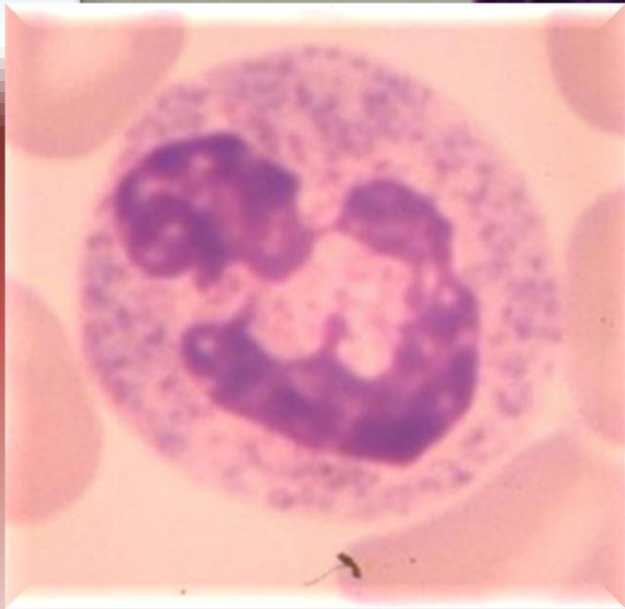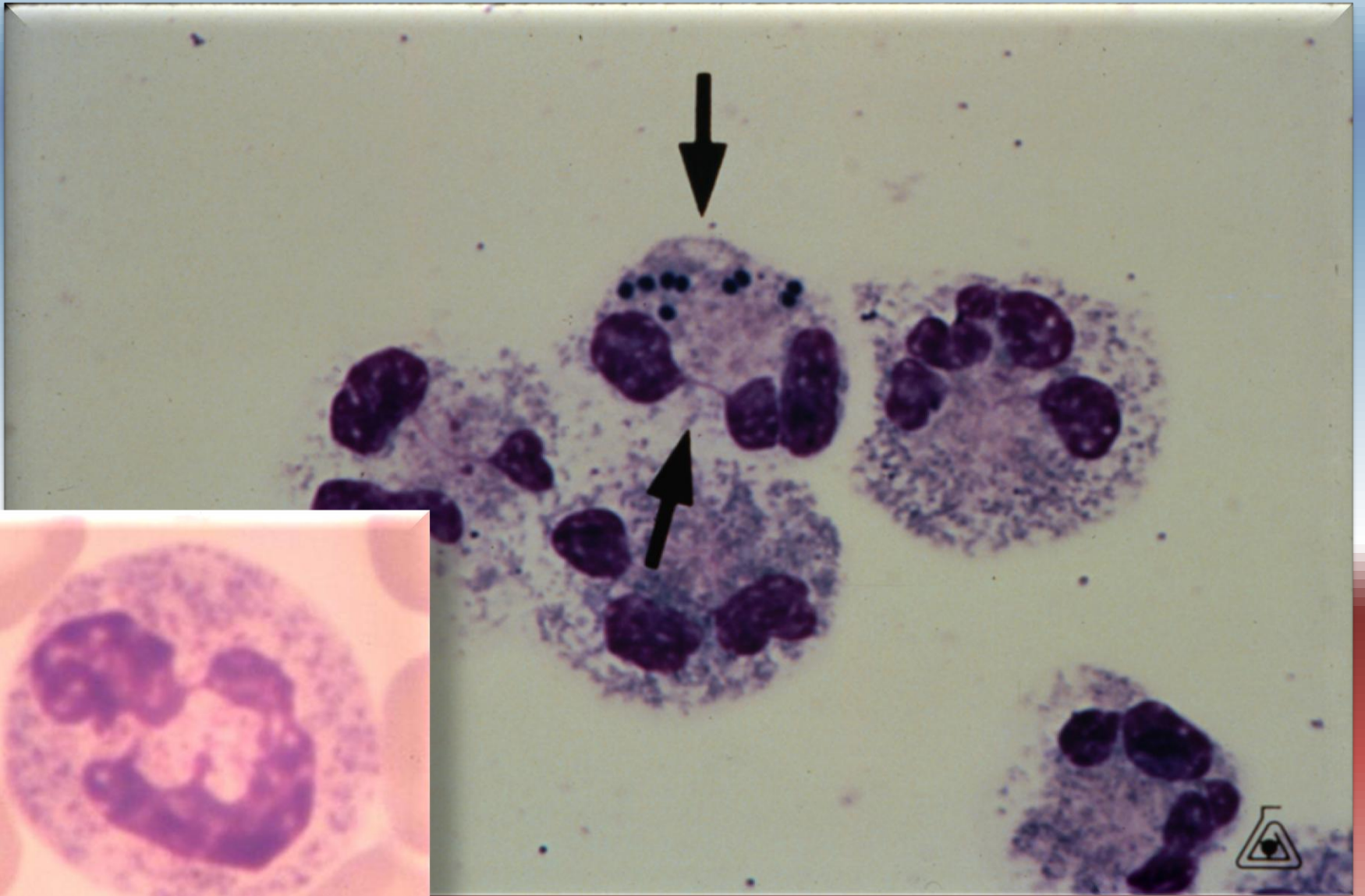
*Sürme frotilerde nötrofiller*



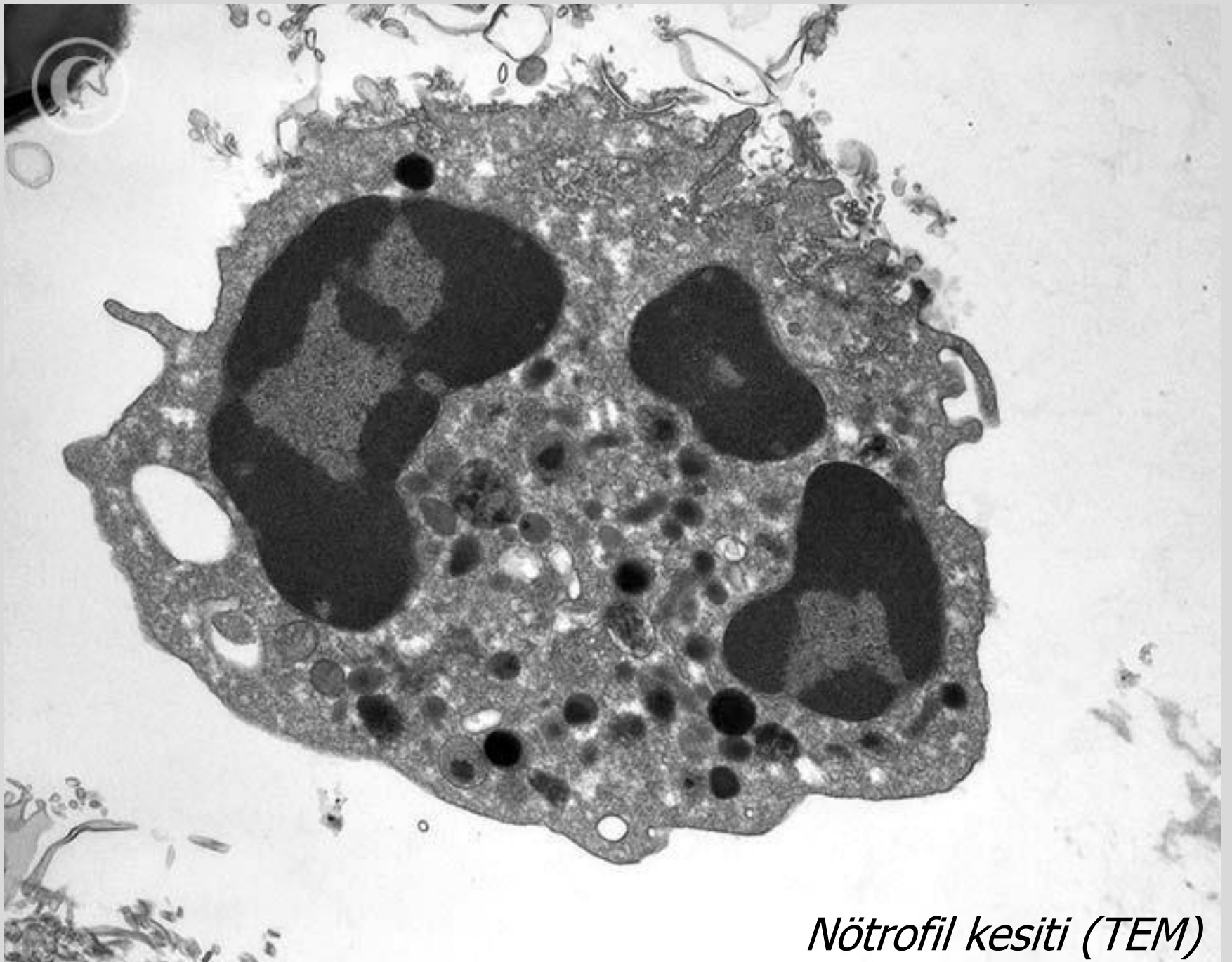
Hipersegmente nötrofiller





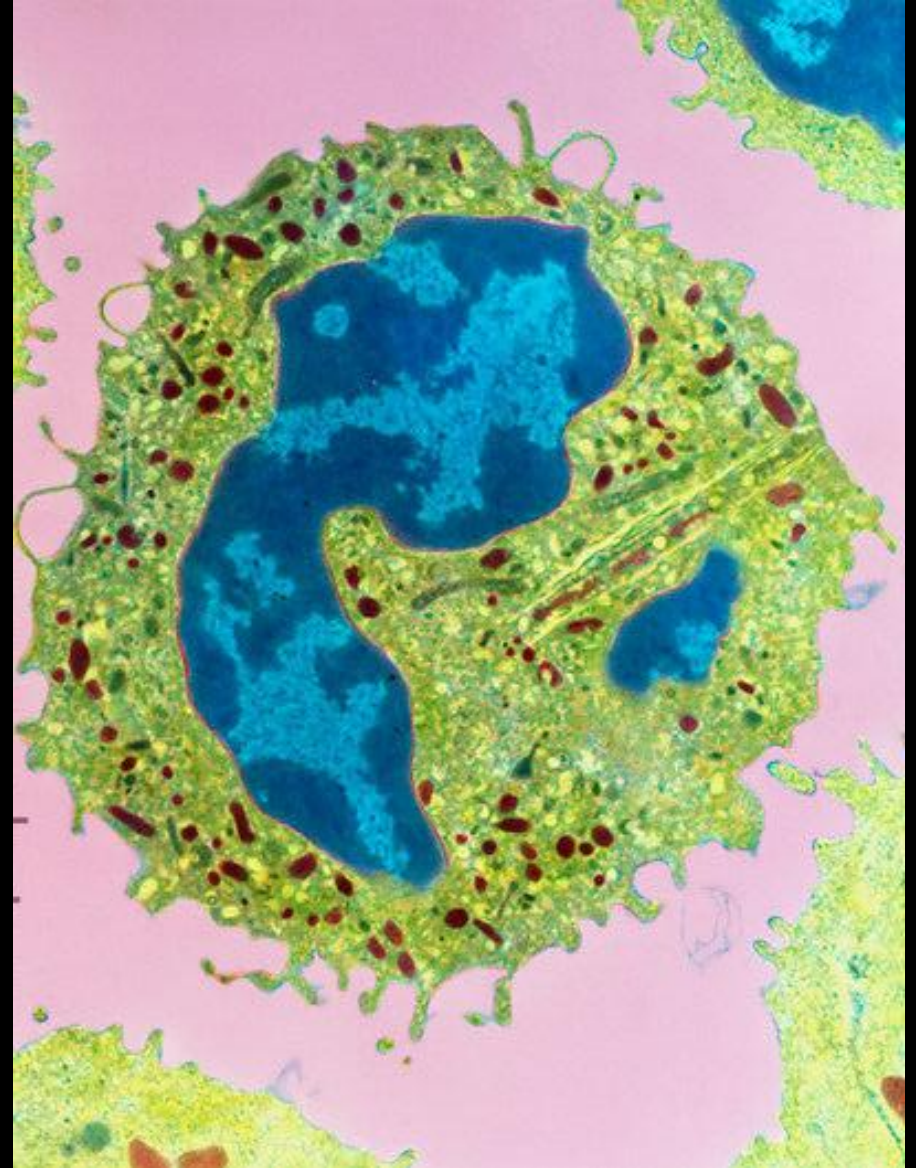
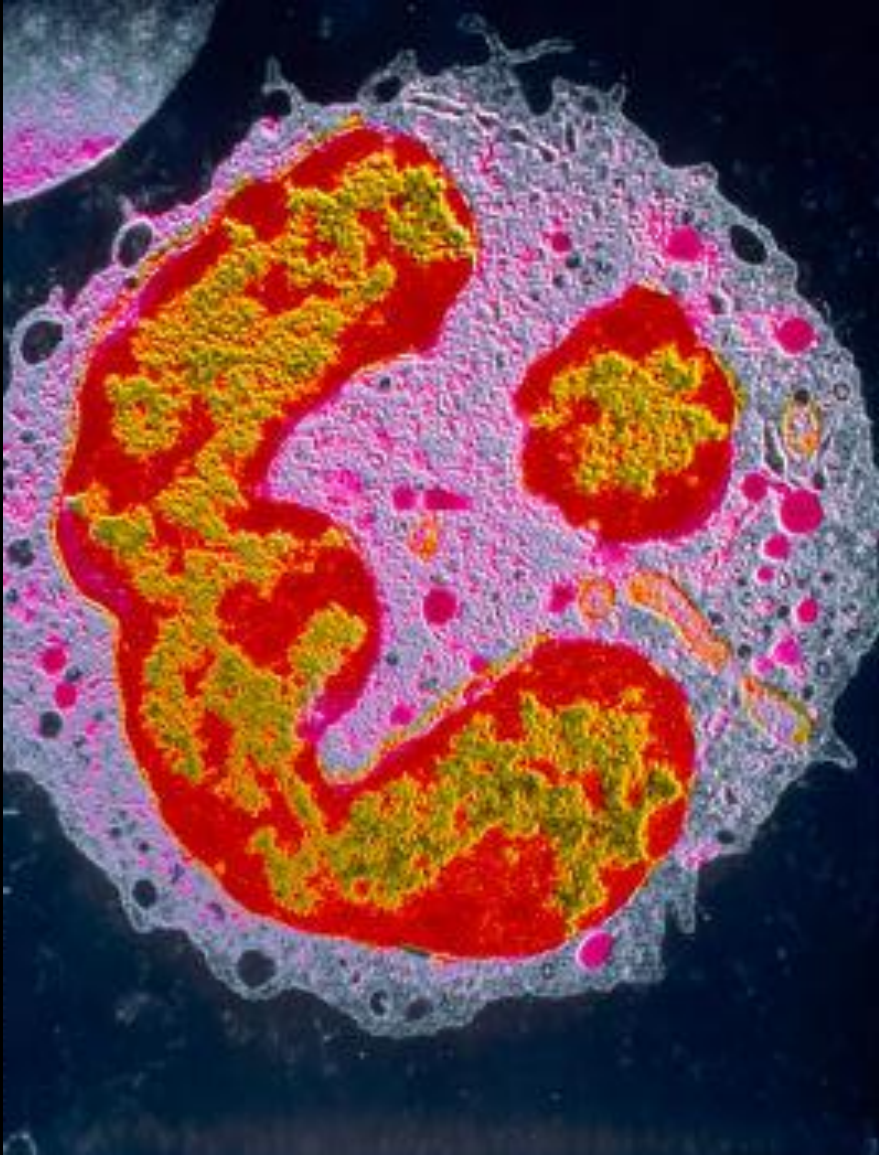

! "Toksik" Nötrofil



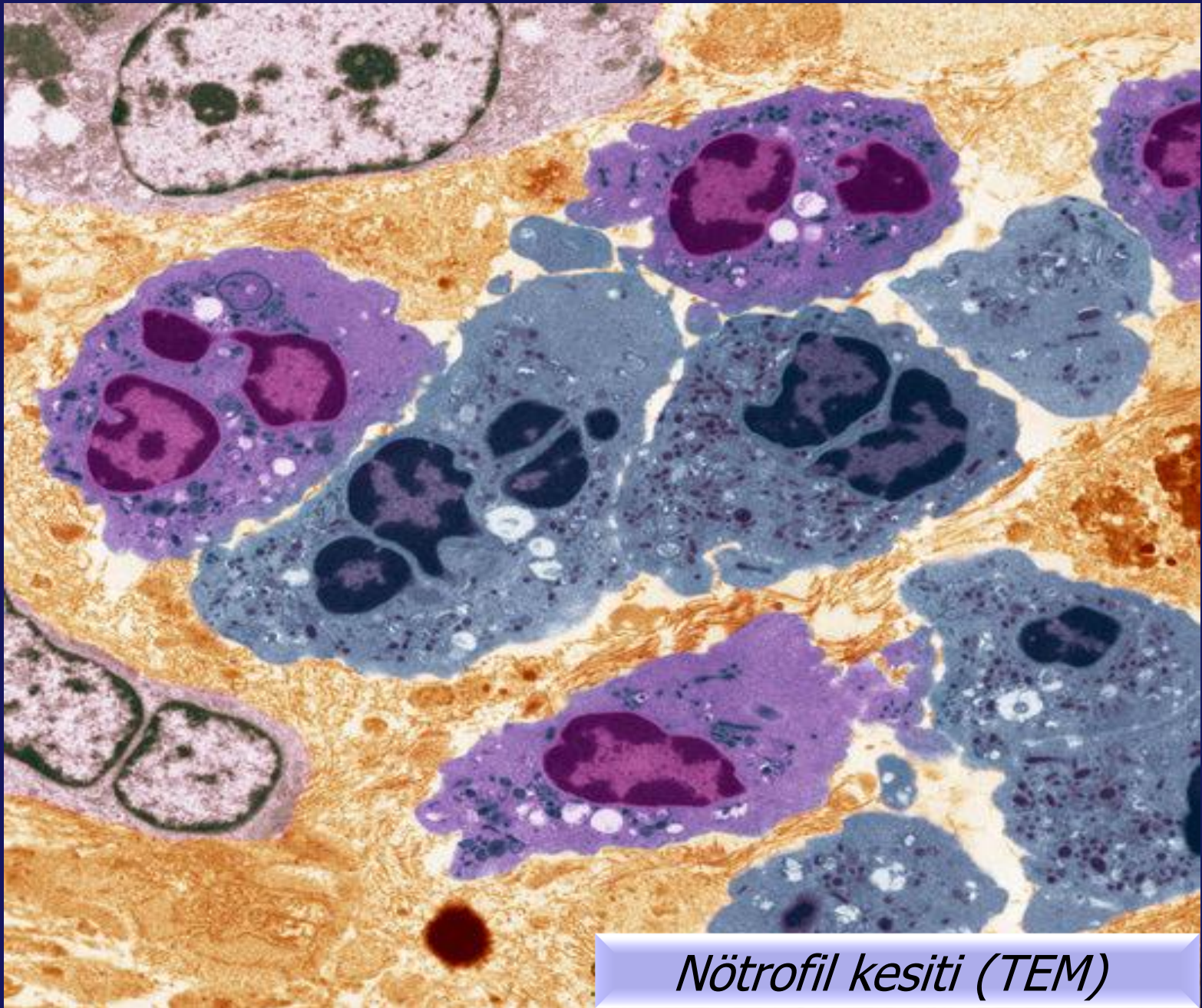
*Nötrofil kesiti (TEM)*





*Nötrofil kesiti (TEM)*

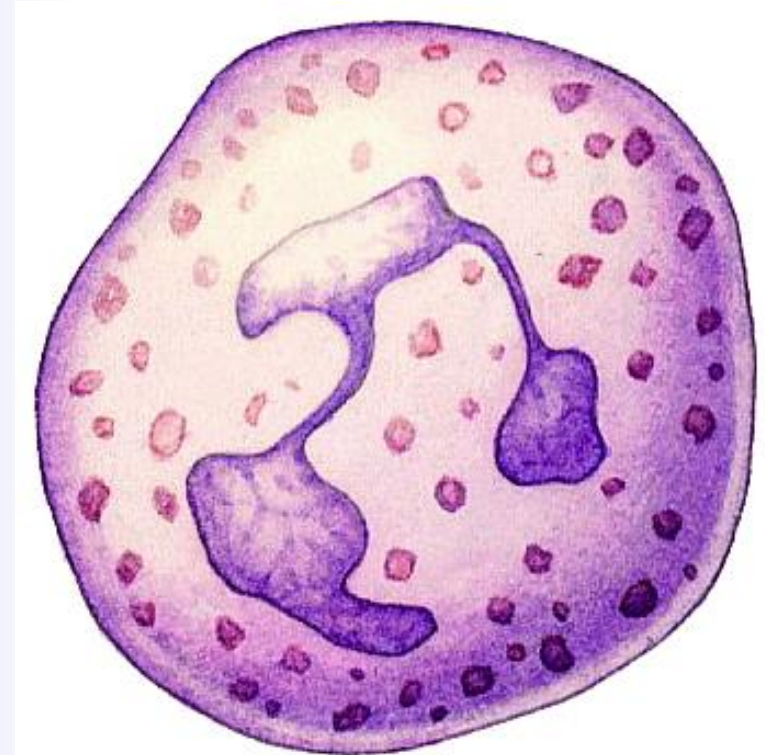
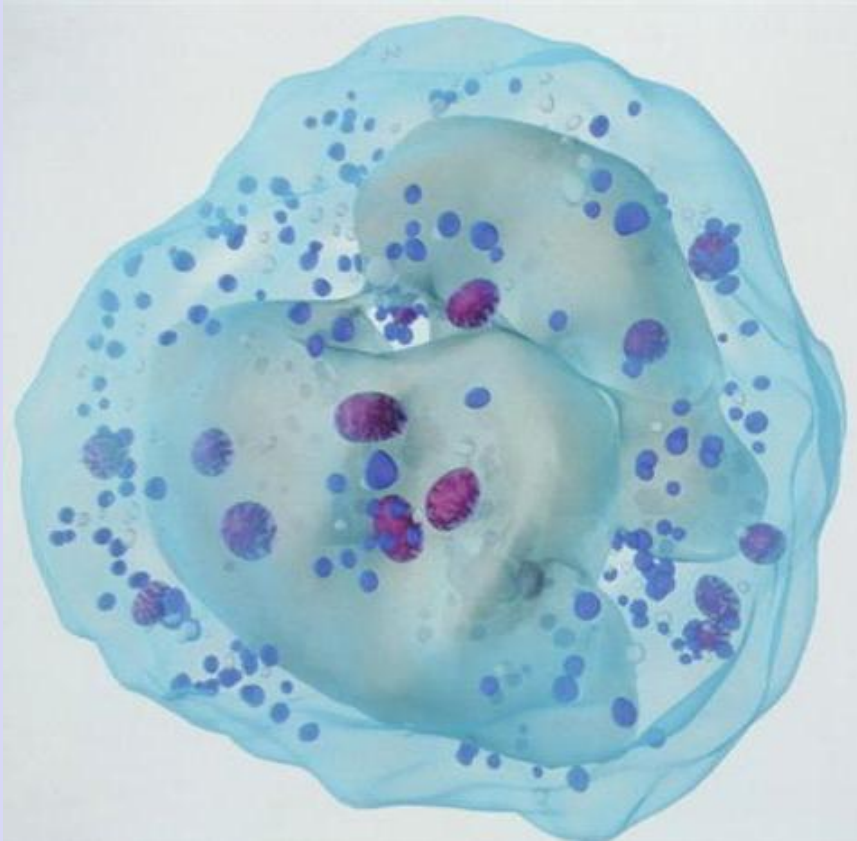
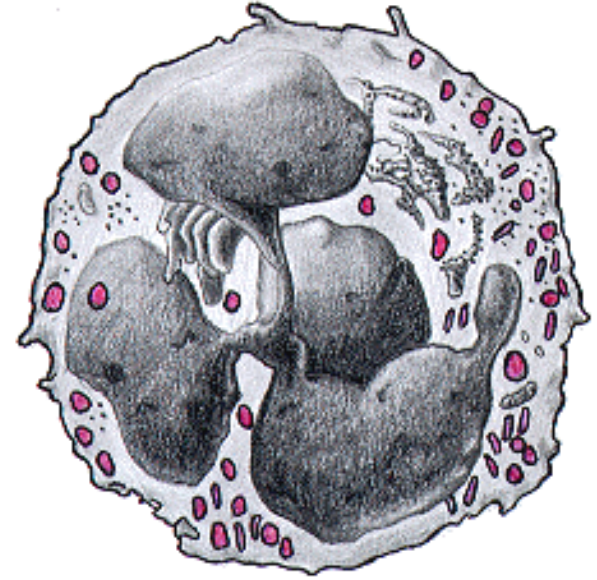




*Nötrofil kesiti (TEM)*

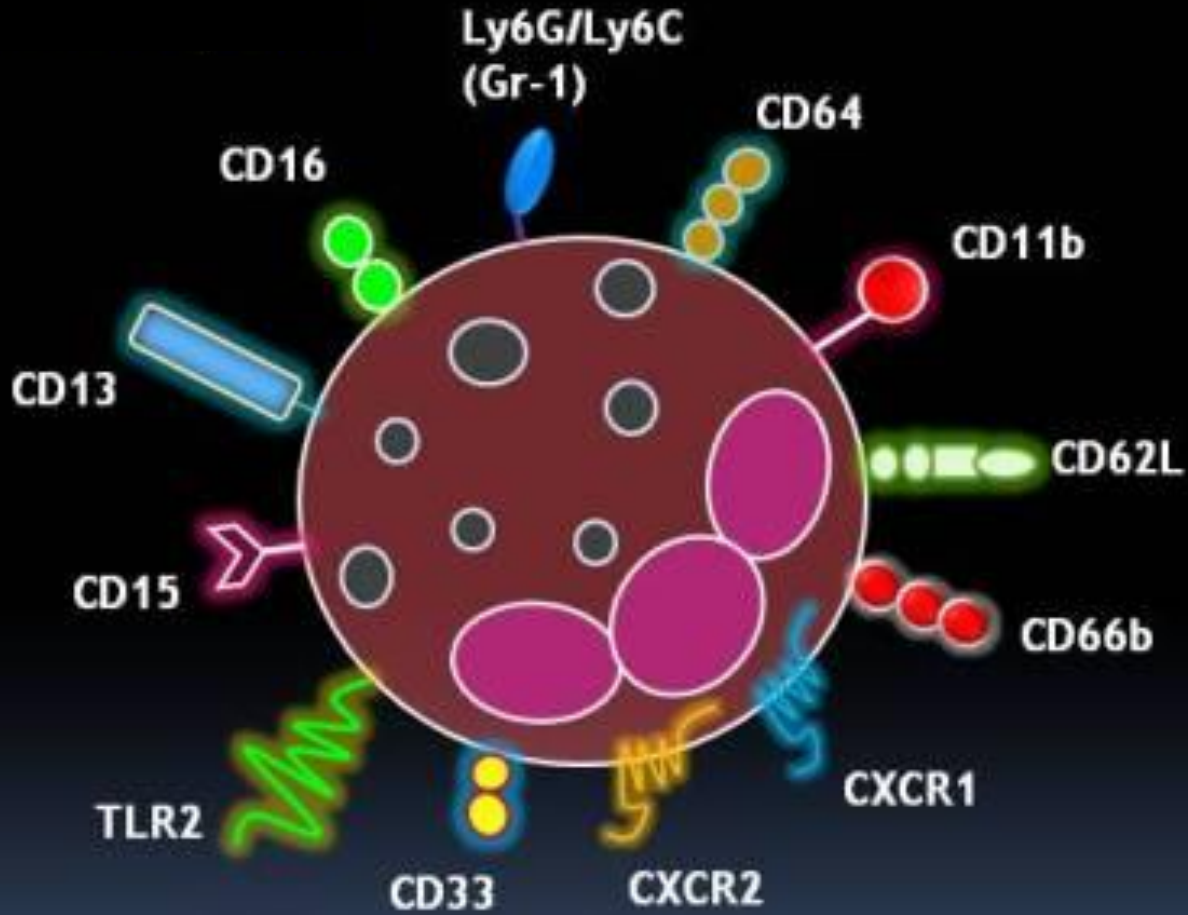


# Nötrofil Çizimleri

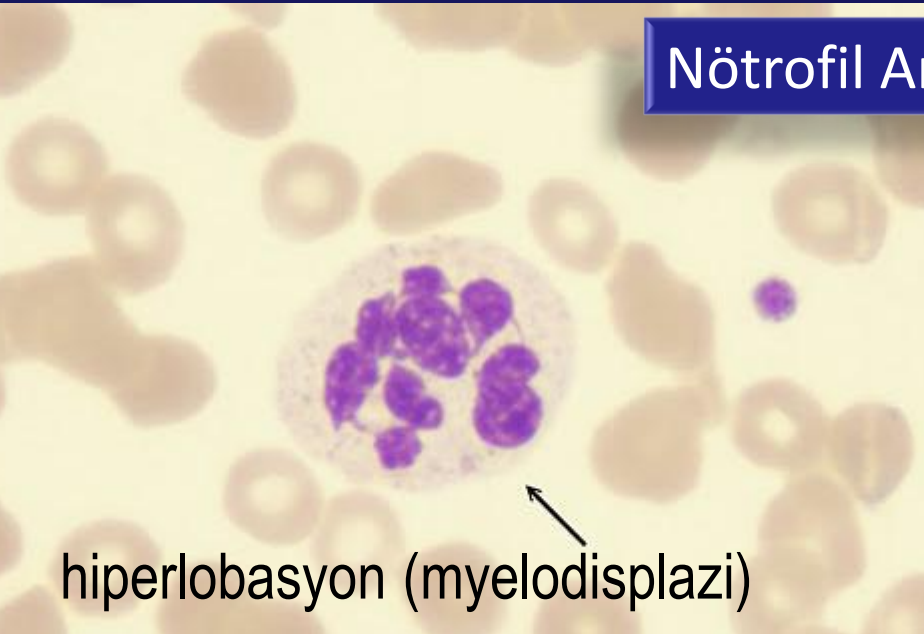




# Bazı Nötrofil Yüzey Molekülleri



## Nötrofil Anomalileri



hiperlobasyon (myelodisplazi)

This panel shows a neutrophil with a nucleus that is highly lobated, with several distinct, rounded lobes. The background contains numerous other cells, likely erythrocytes, which are stained pinkish-red.



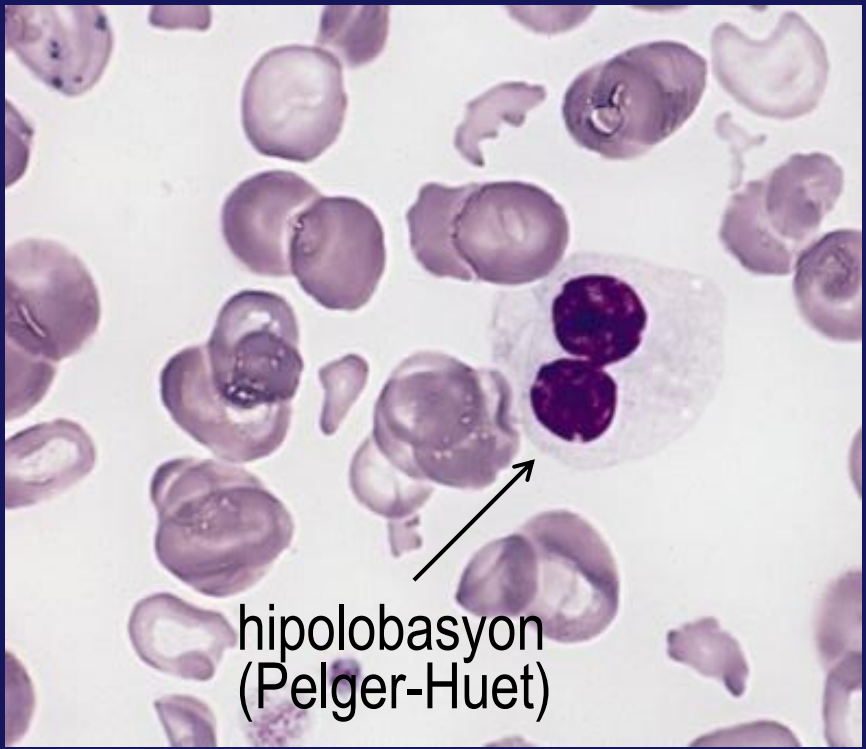
hemofagositoz

This panel shows a neutrophil with a multi-lobed nucleus. One of the lobes is engulfed by the cytoplasm of the cell, a process known as hemophagocytosis. The engulfed cell is visible as a darker, more condensed mass within the cytoplasm.



apoptoz

This panel shows a neutrophil with a nucleus that is condensed and fragmented, characteristic of apoptosis. The surrounding field is filled with many other neutrophils, some of which also show signs of nuclear condensation.

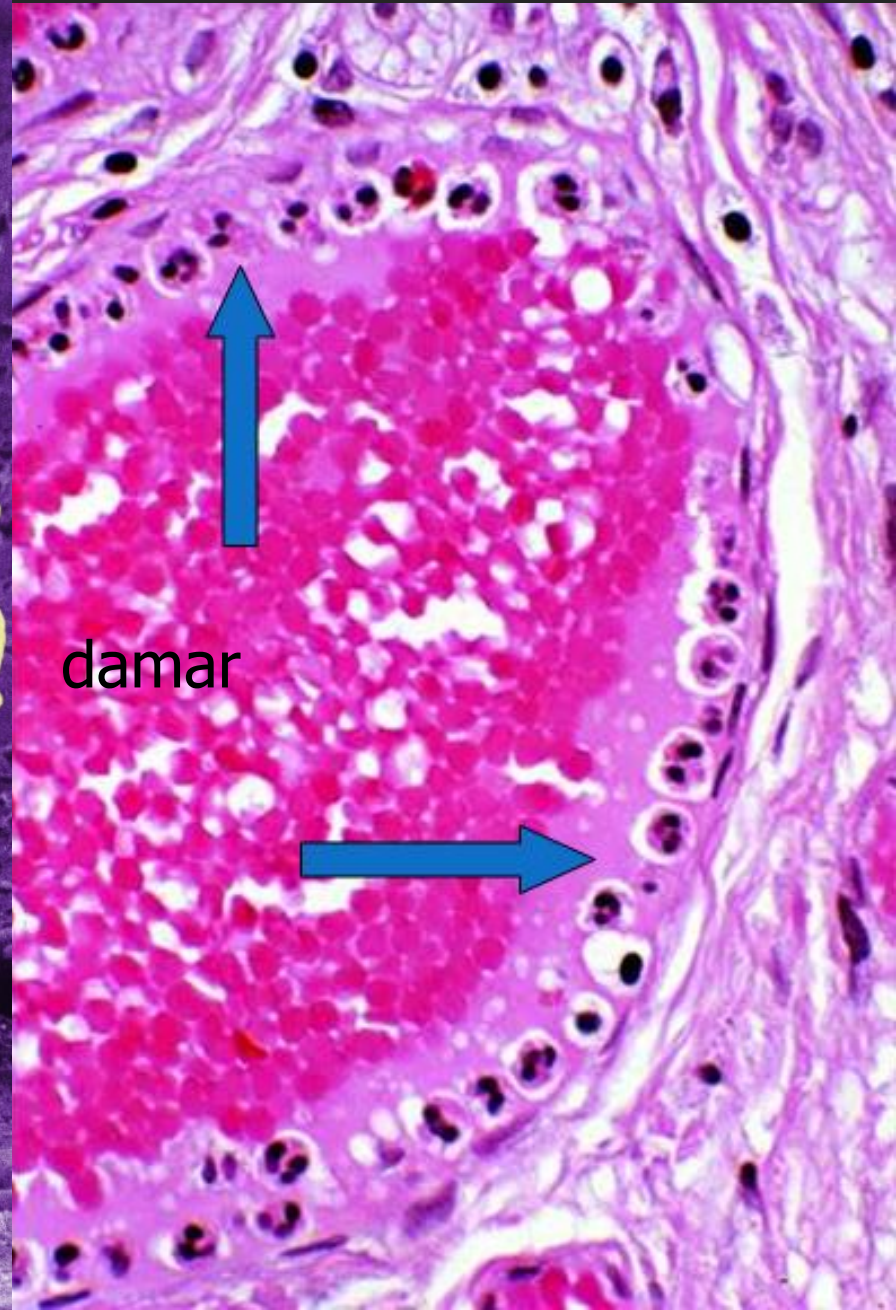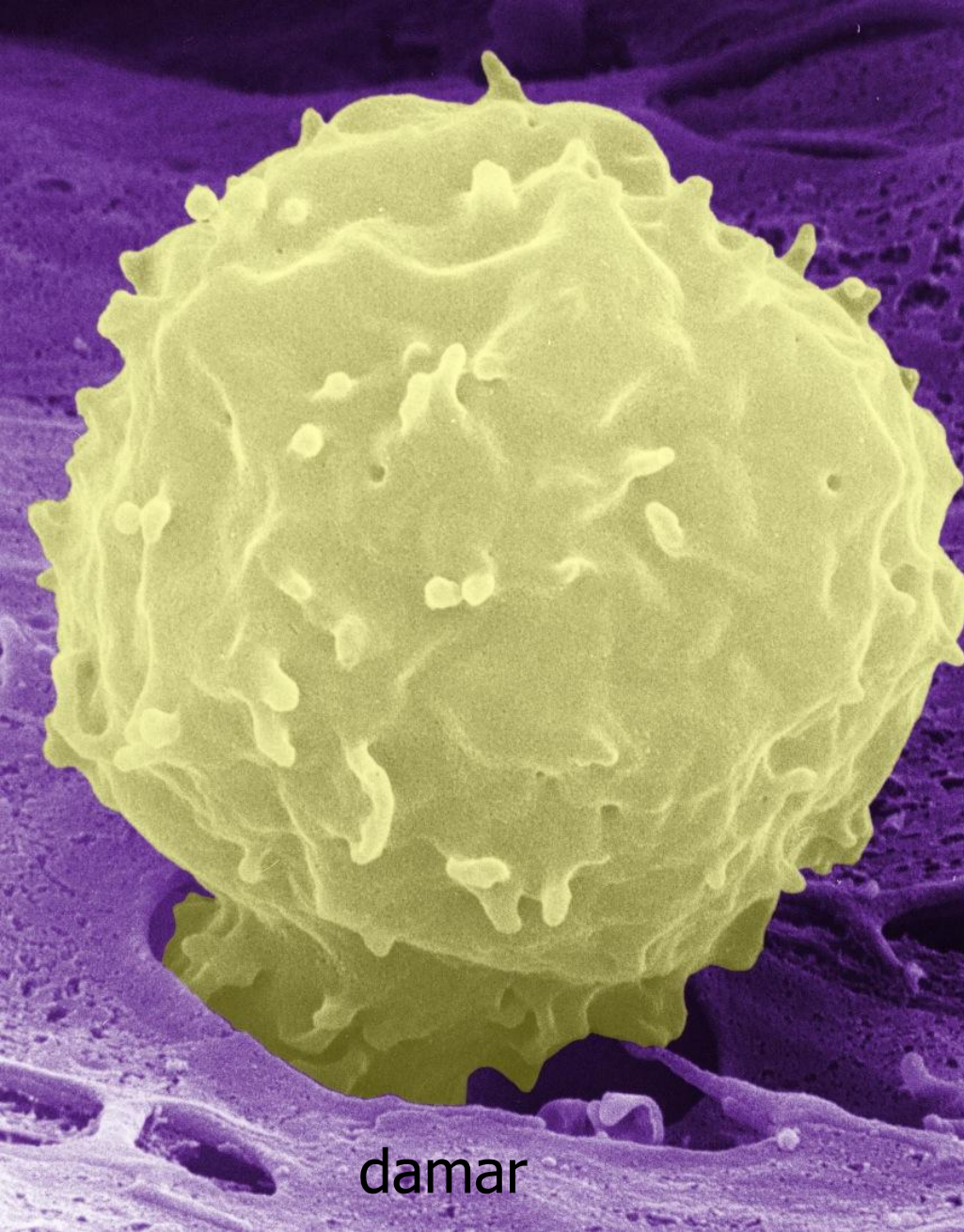


hipolobasyon  
(Pelger-Huet)

This panel shows a neutrophil with a nucleus that is hypolobated, meaning it has fewer lobes than normal. The nucleus appears as a few large, dark, rounded segments. The surrounding field contains many erythrocytes.

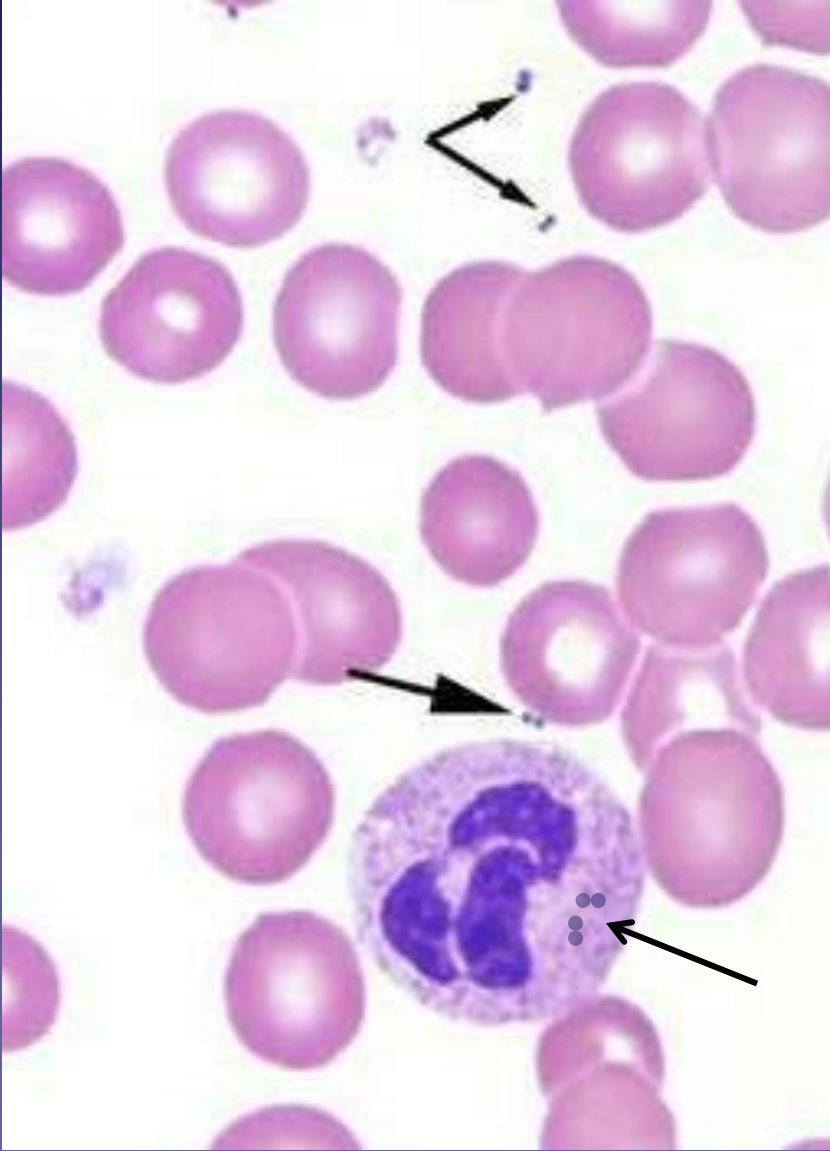


# Nötrofilin damar dışına çıkışı

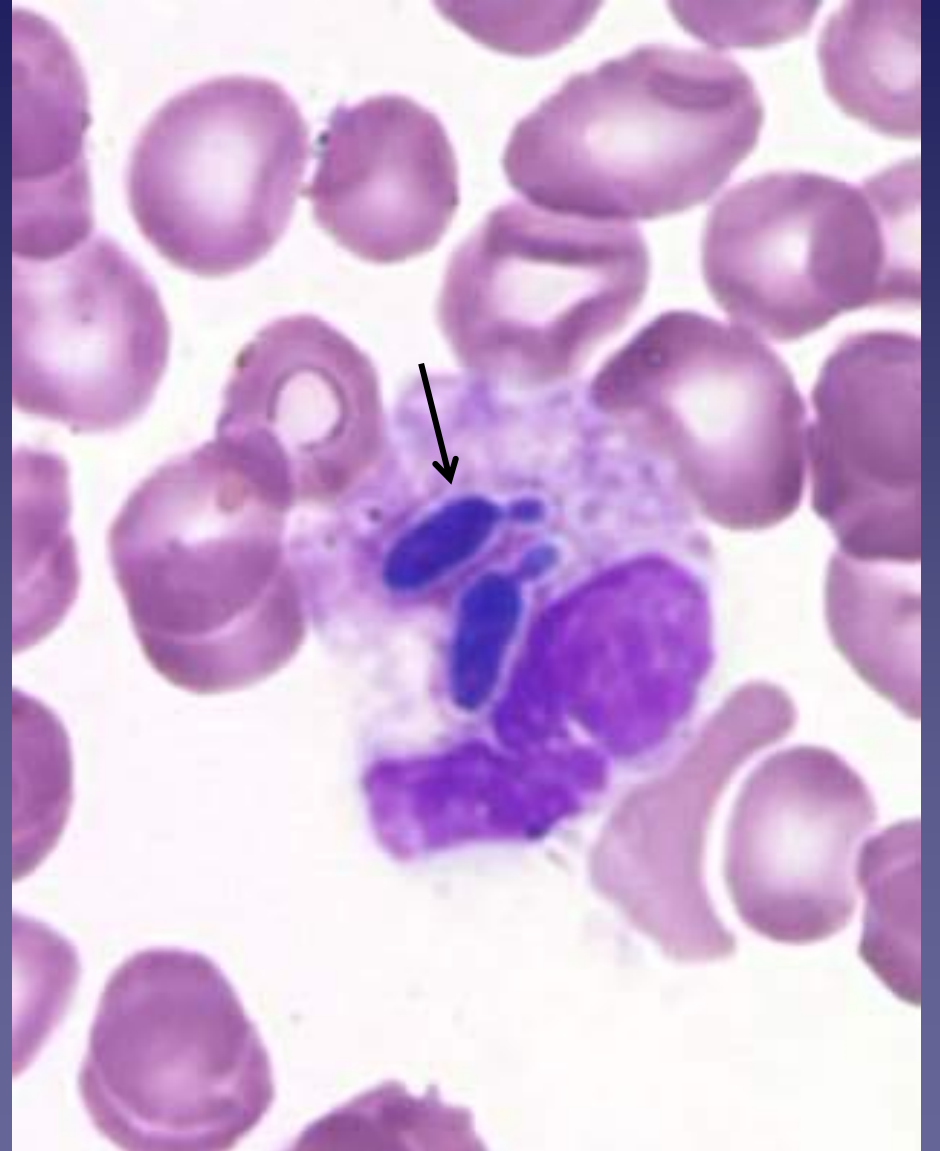



# Nötrofilin görevi: Fagositoz

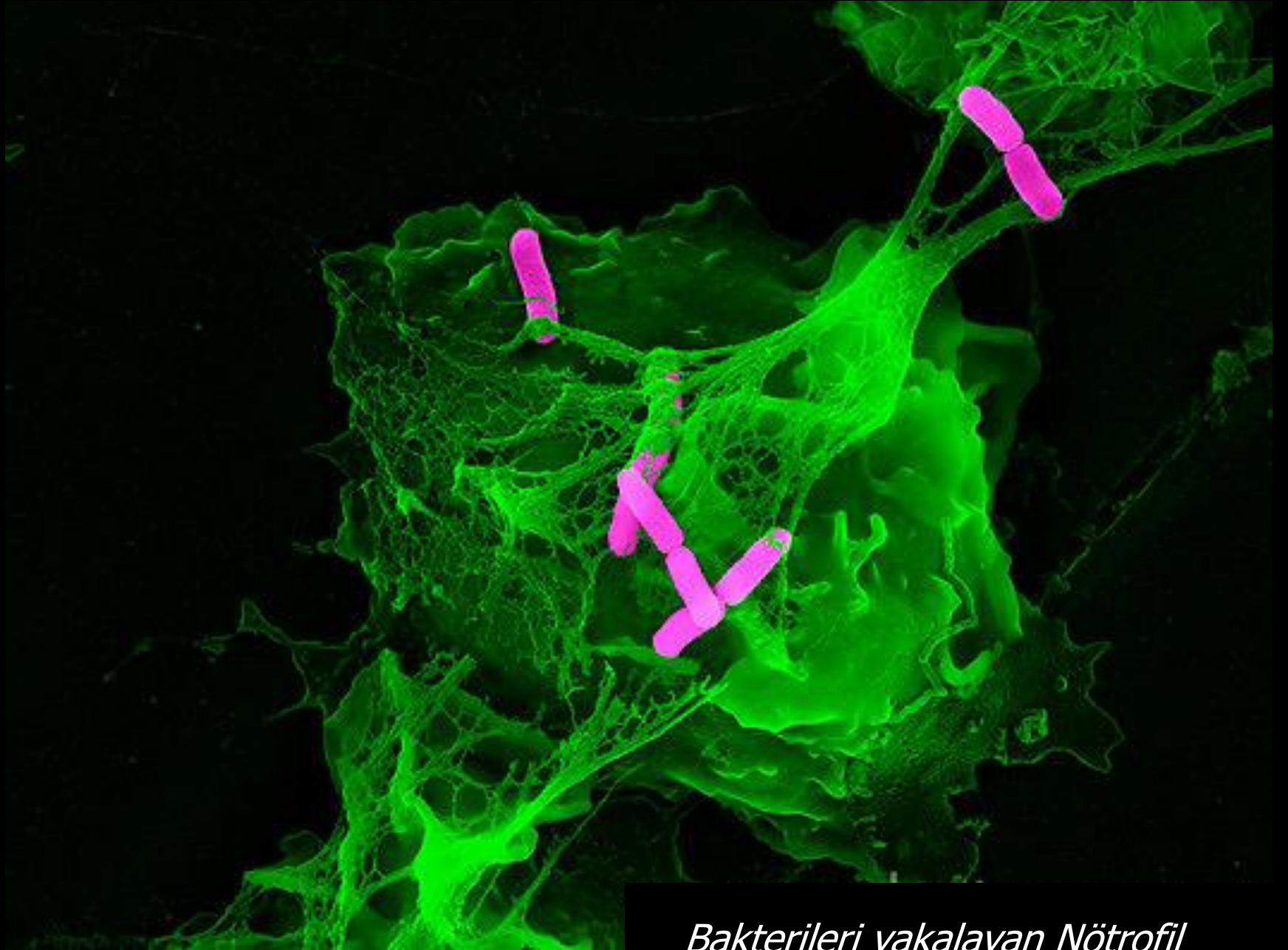


bakteri

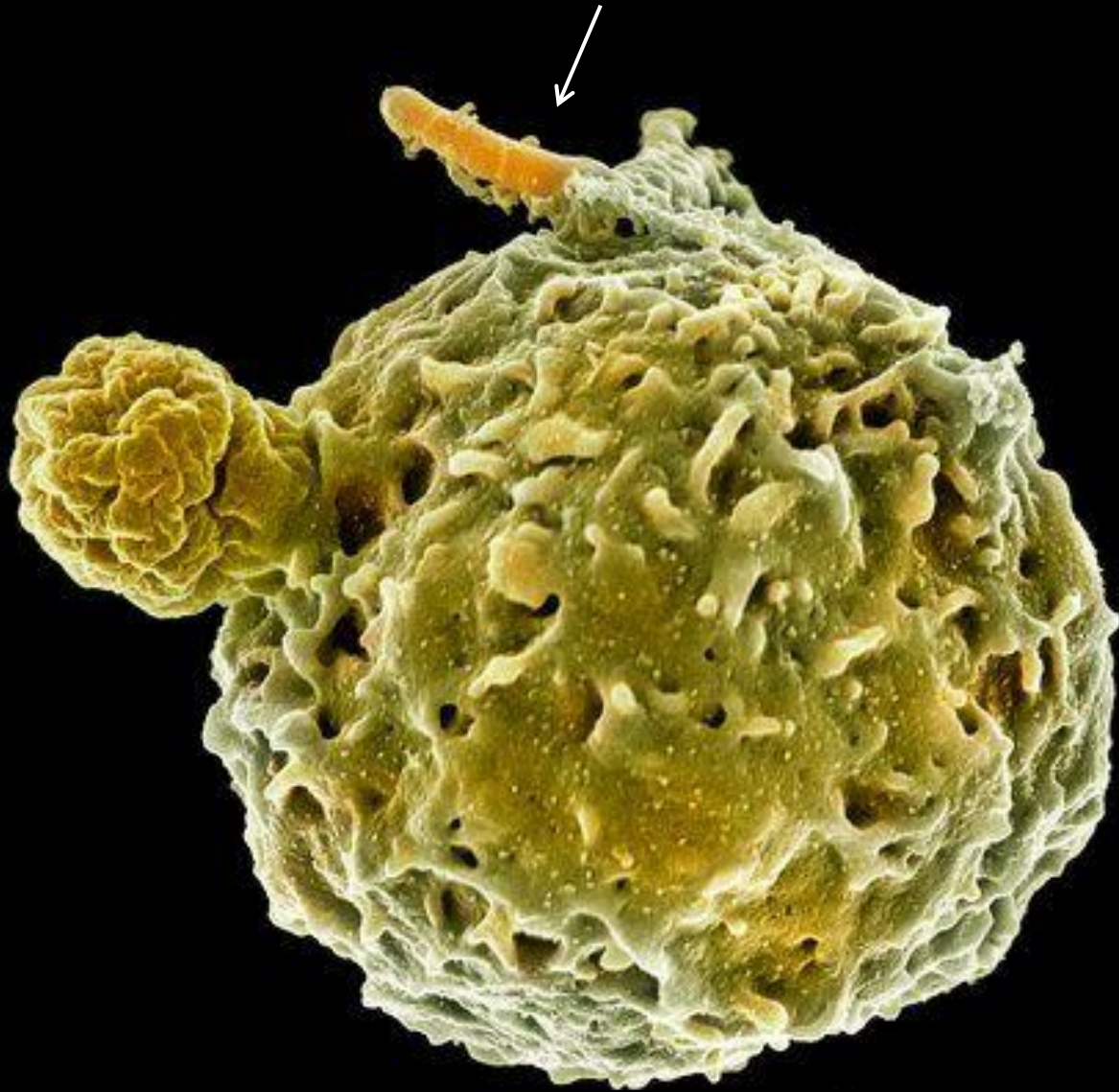


maya



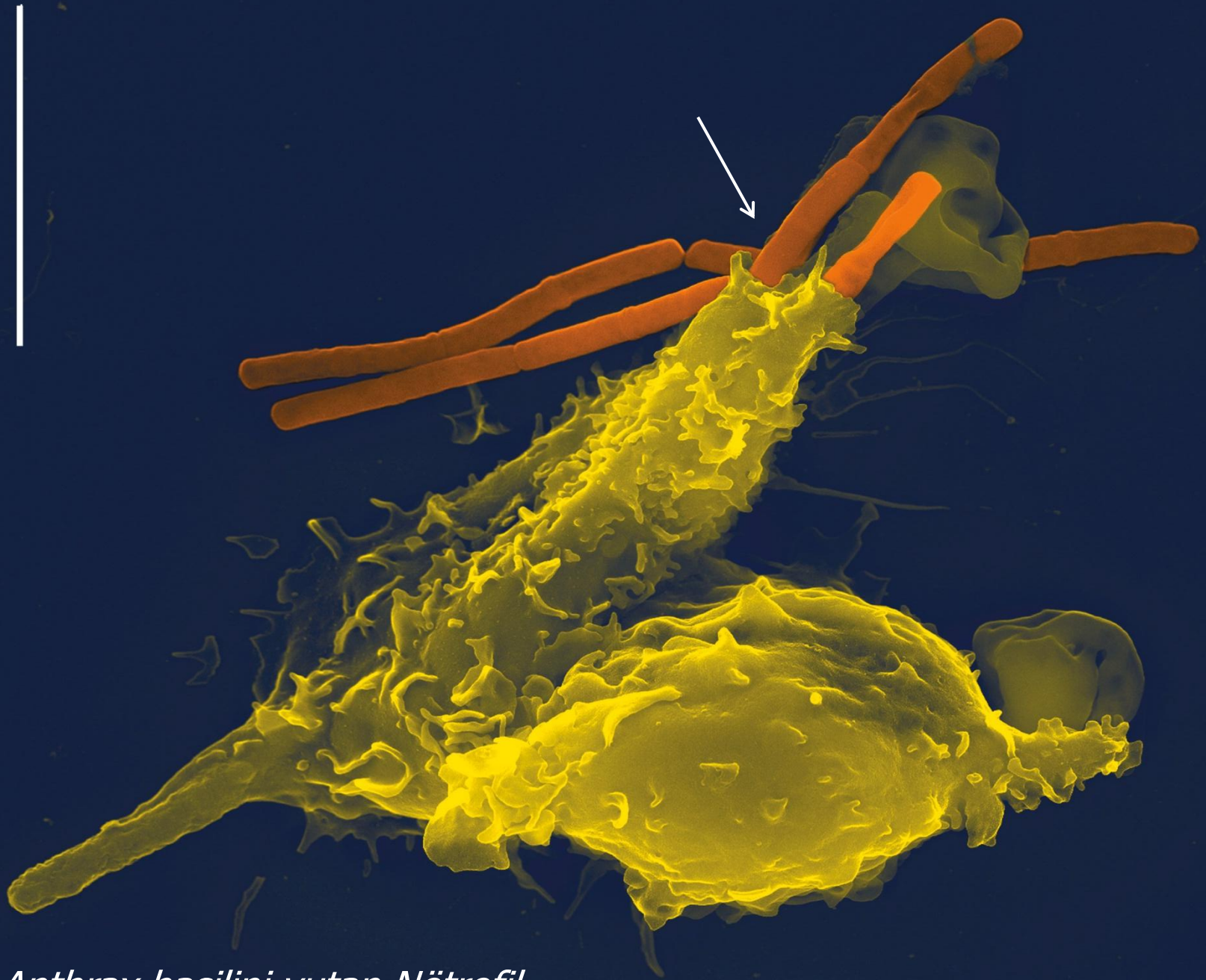


*Bakterileri yakalayan Nötrofil*

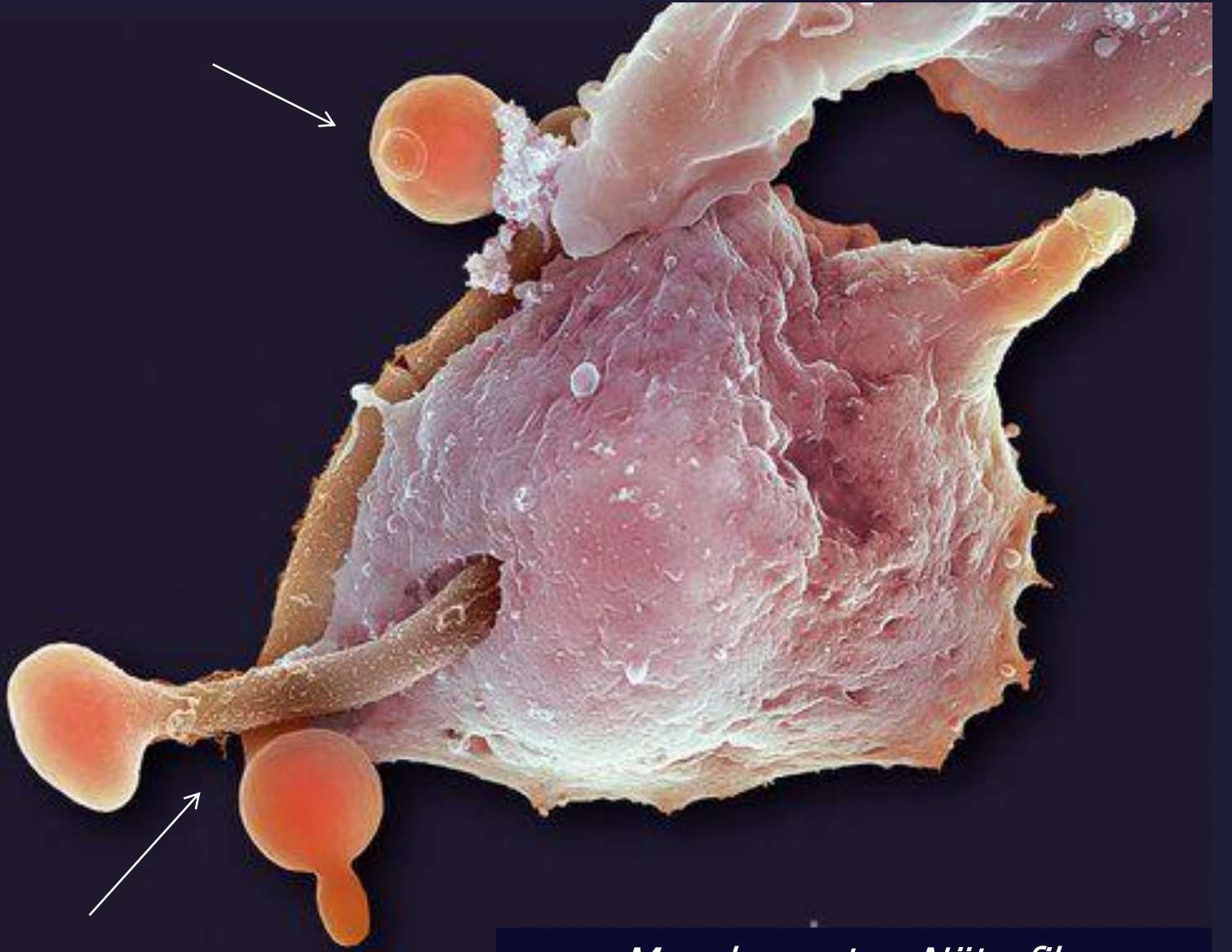


*Tüberküloz basilini yutan Nötrofil*



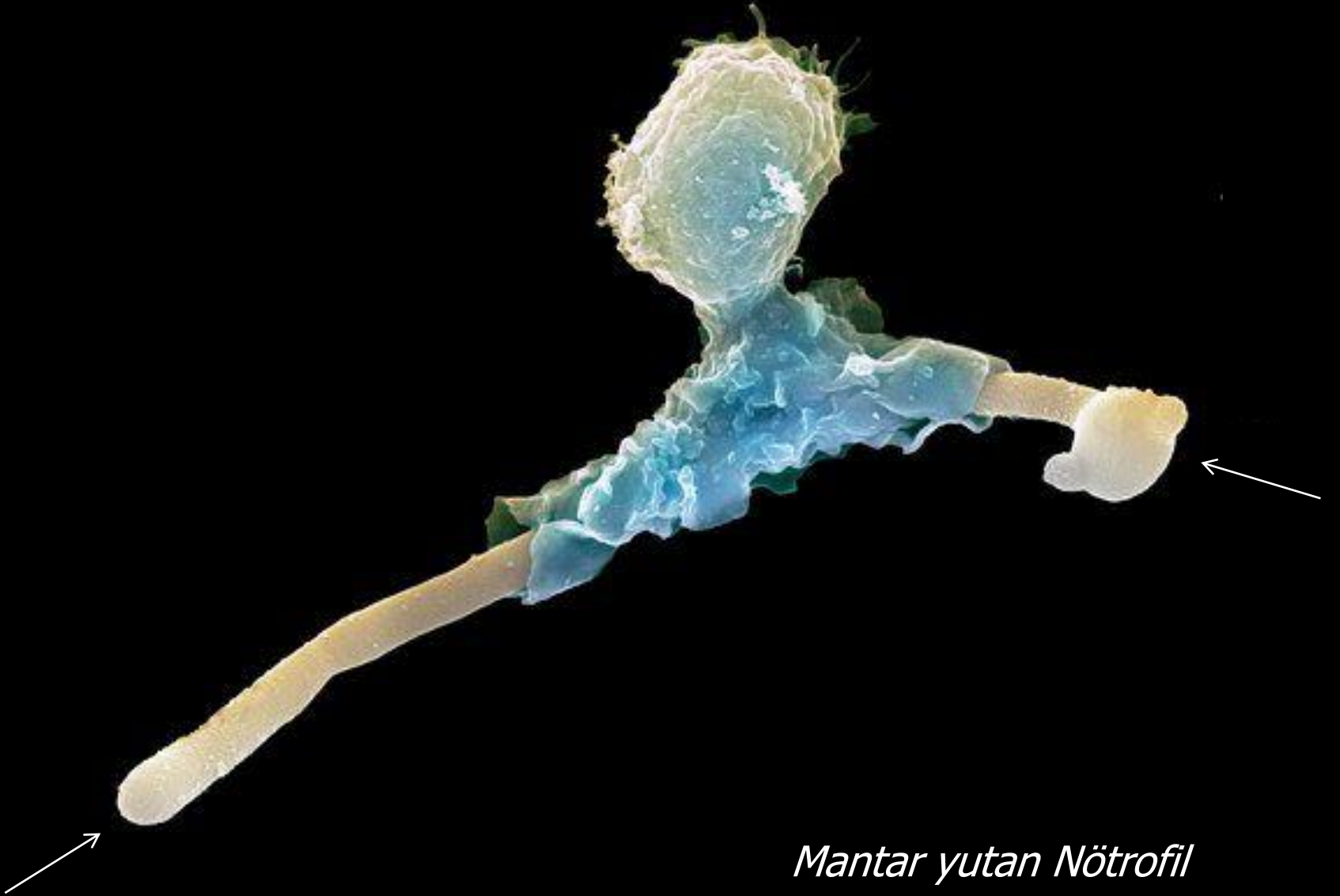

*Anthrax basilini yutan Nötrofil*

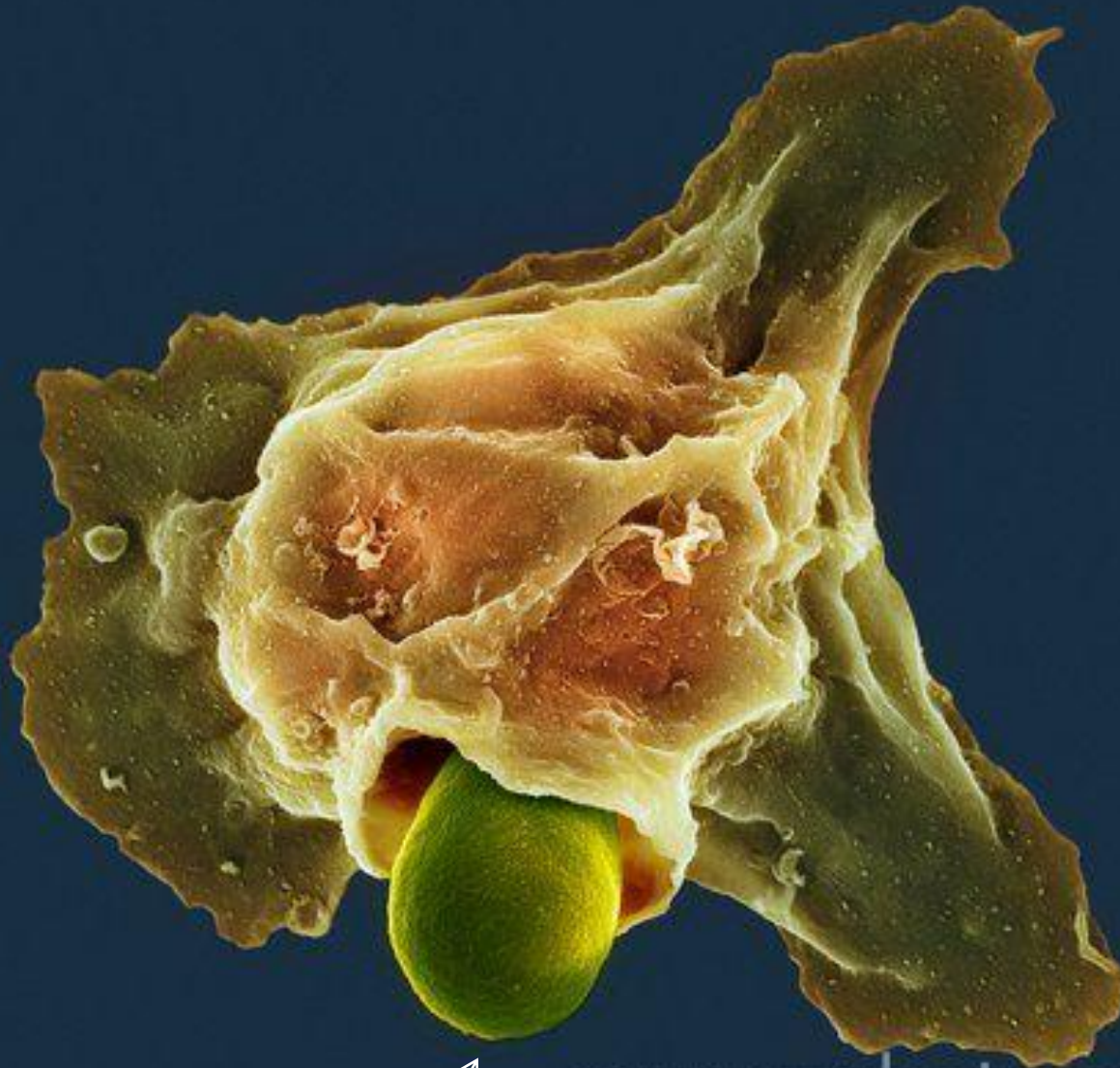


*Mayaları yutan Nötrofil*



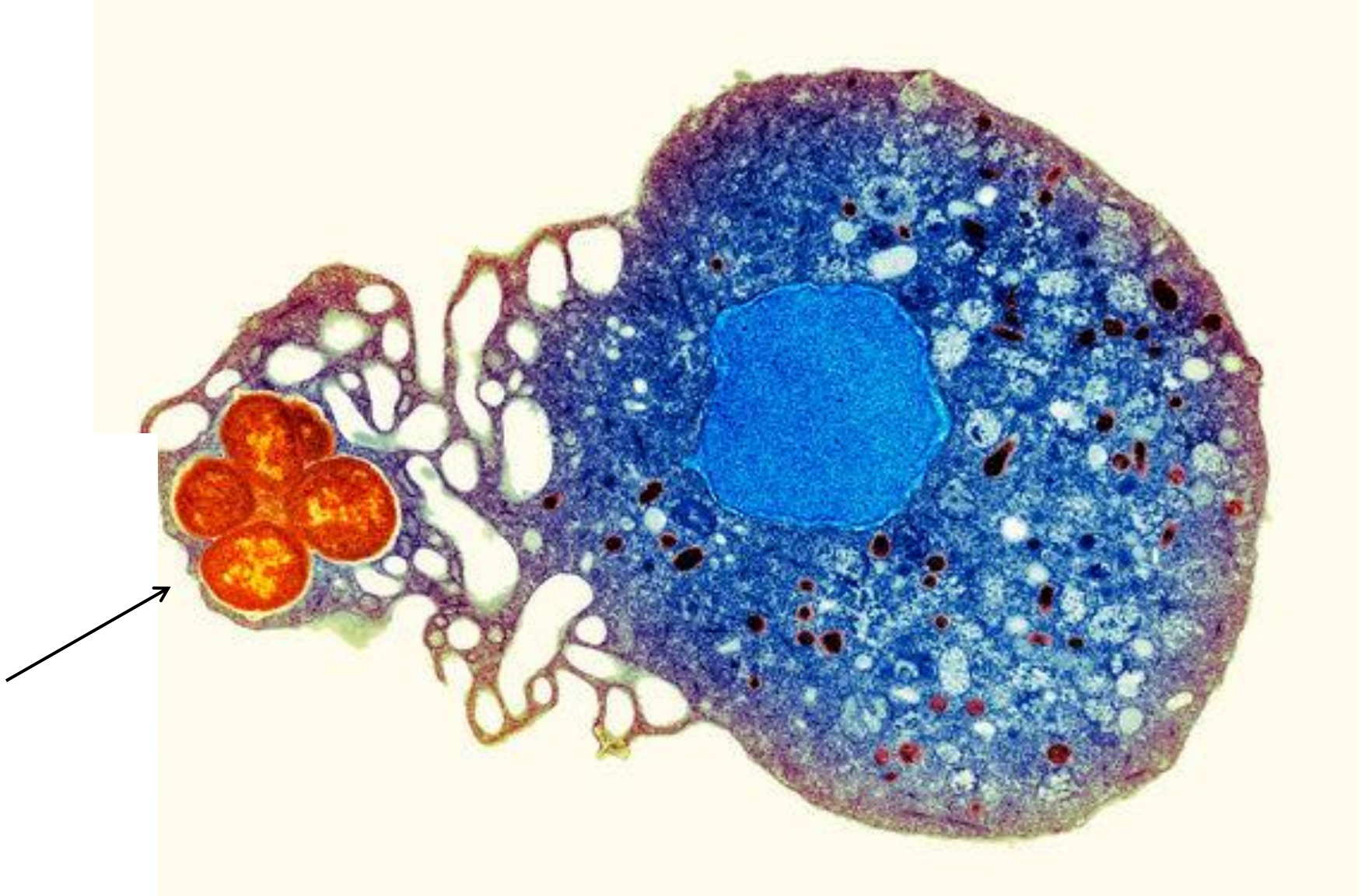

*Mantar yutan Nötrofil*



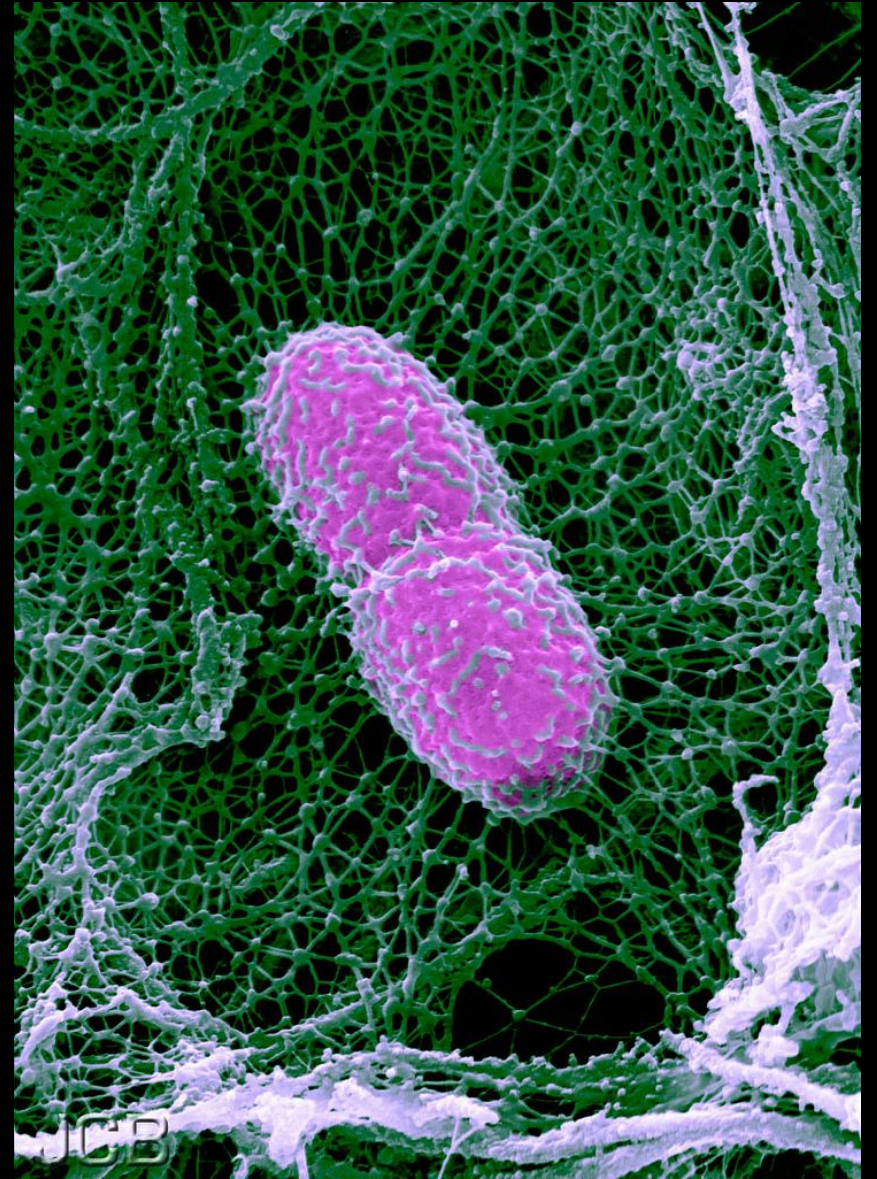
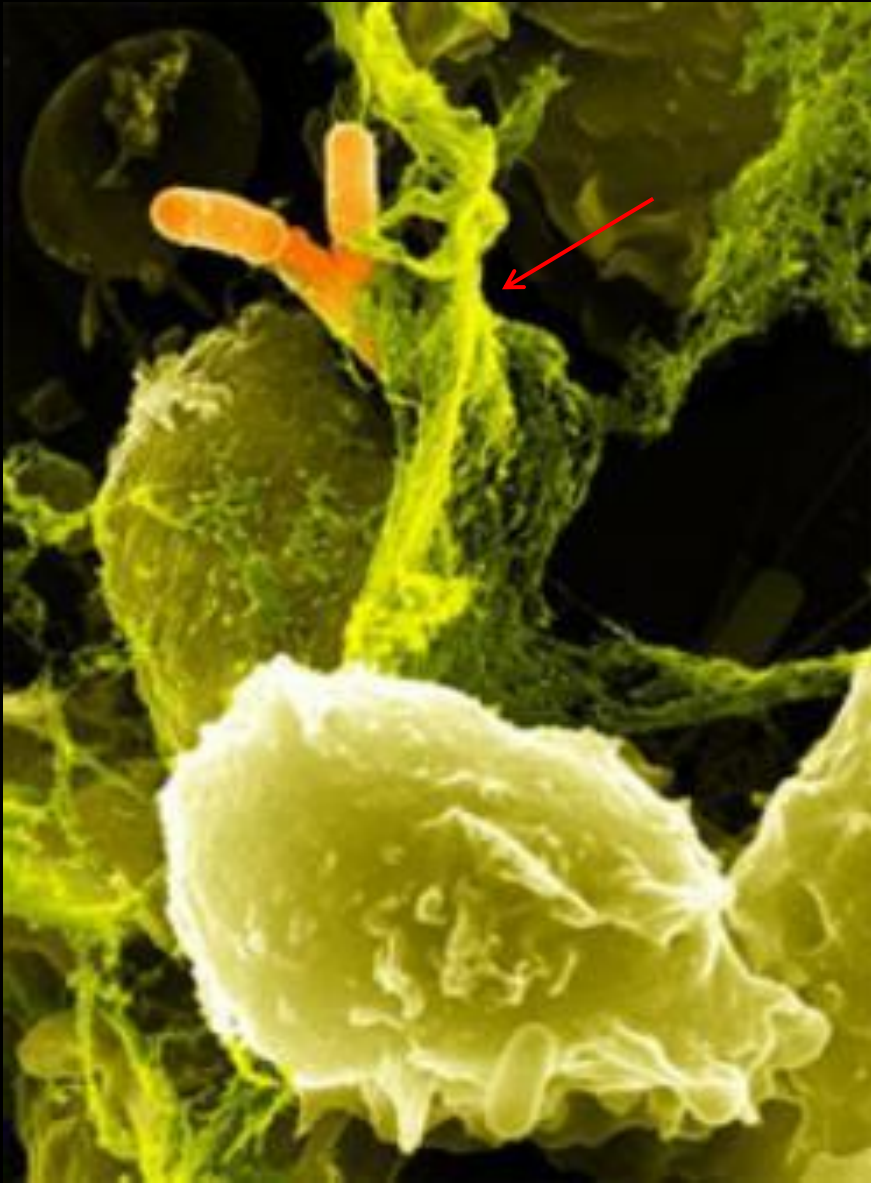
*Mantar yutan Nötrofil*





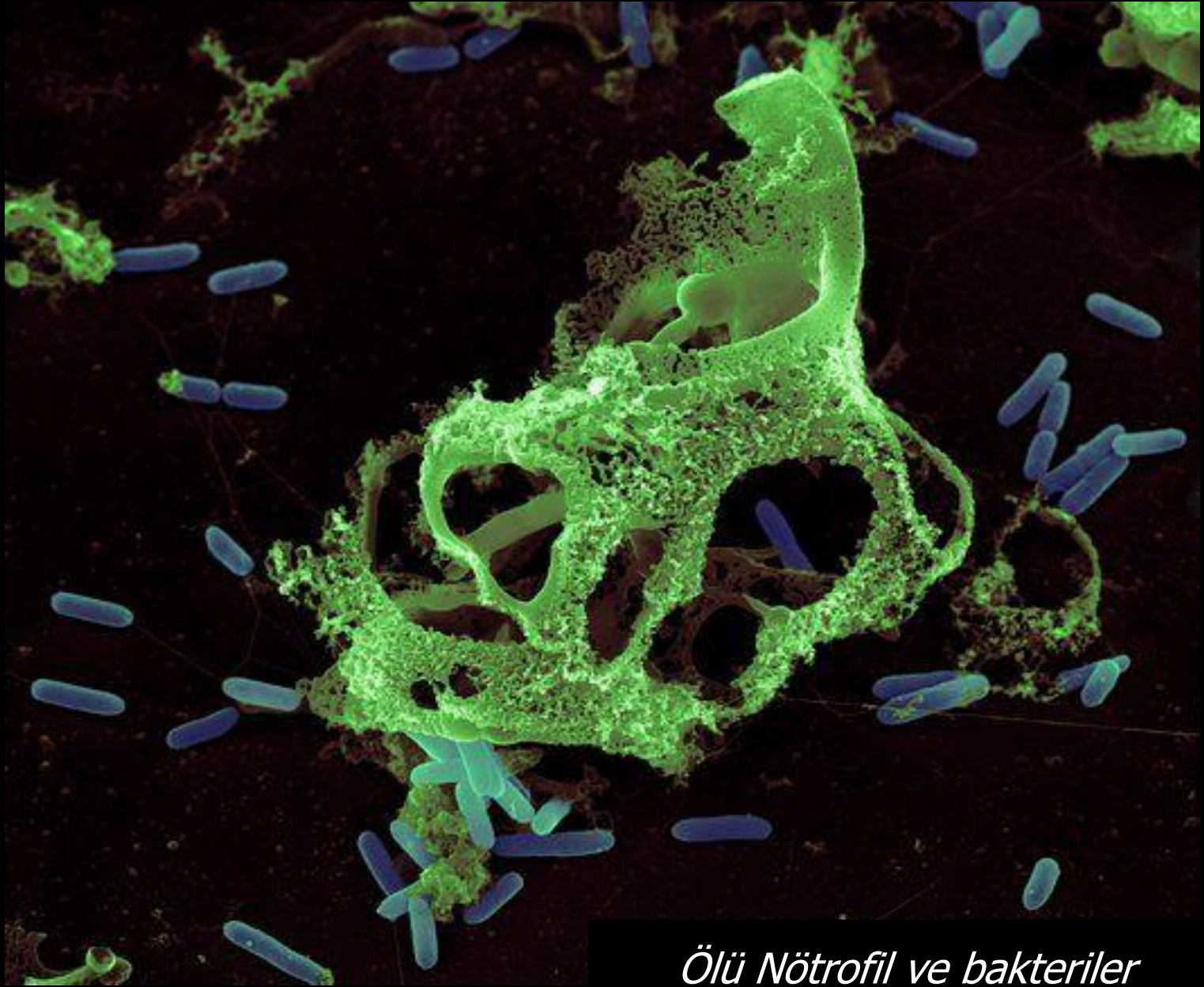*Fagositoz yapan Nötrofil kesiti*



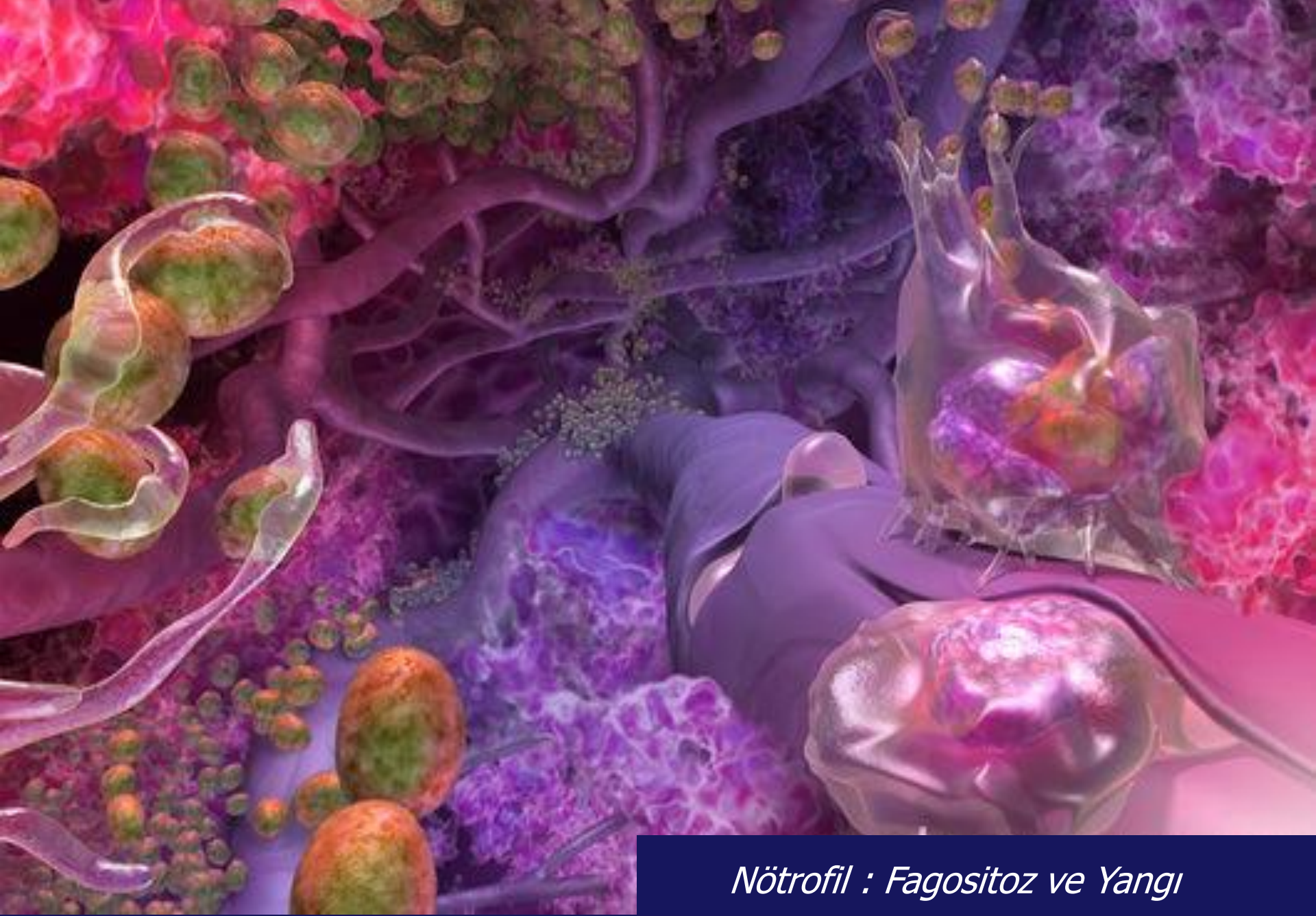


*Nötrofilin hücre membranı uzantıları*





*Ölü Nötrofil ve bakteriler*



*Nötrofil : Fagositoz ve Yangı*



# THE NEUTROPHIL

polymorphonuclear leukocyte

## PHAGOCYTOSIS

the final destination for thousands  
of dead and dying bacteria

## SYMBOLISM

these depict the multilobular form  
of the Neutrophil's nucleus.



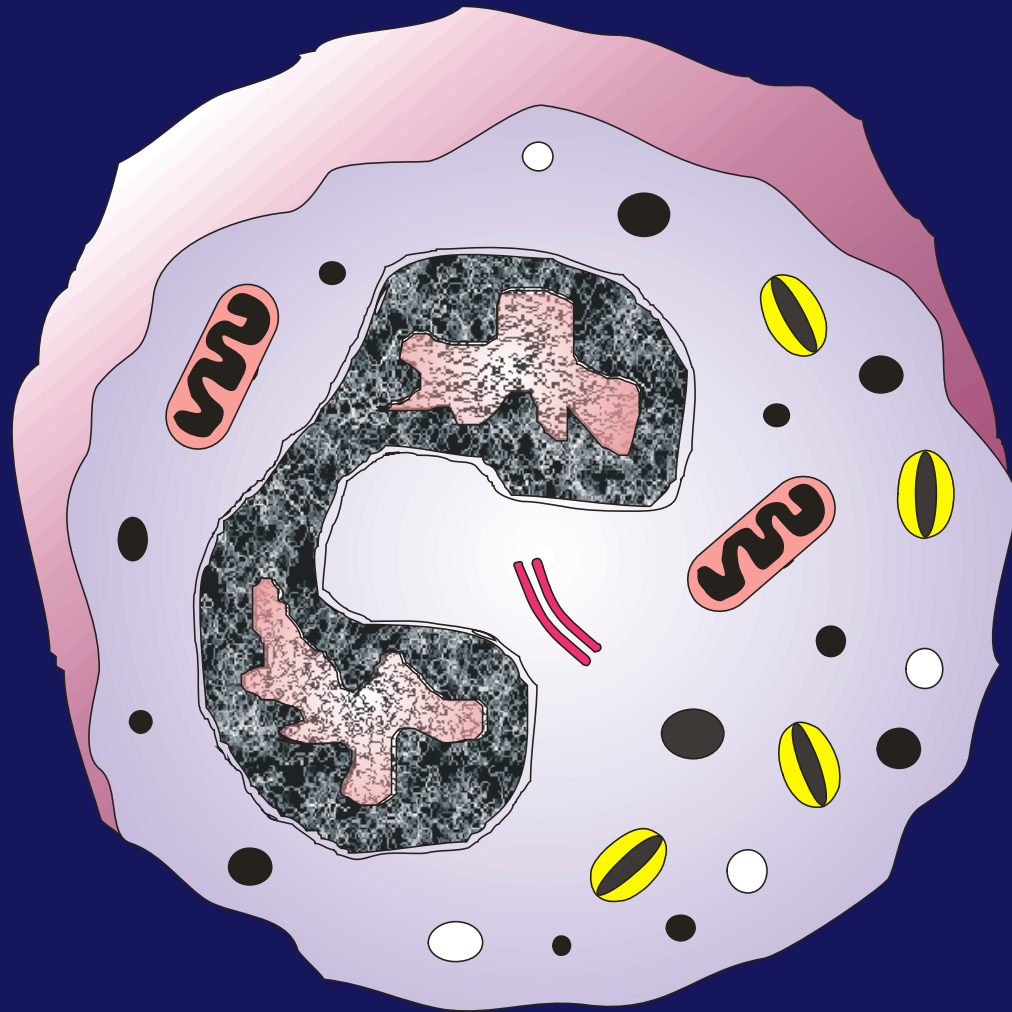
## THE BALL AND CHAIN

symbolizes not only the multi-lobed nucleus but also the weaponry of the Neutrophil.

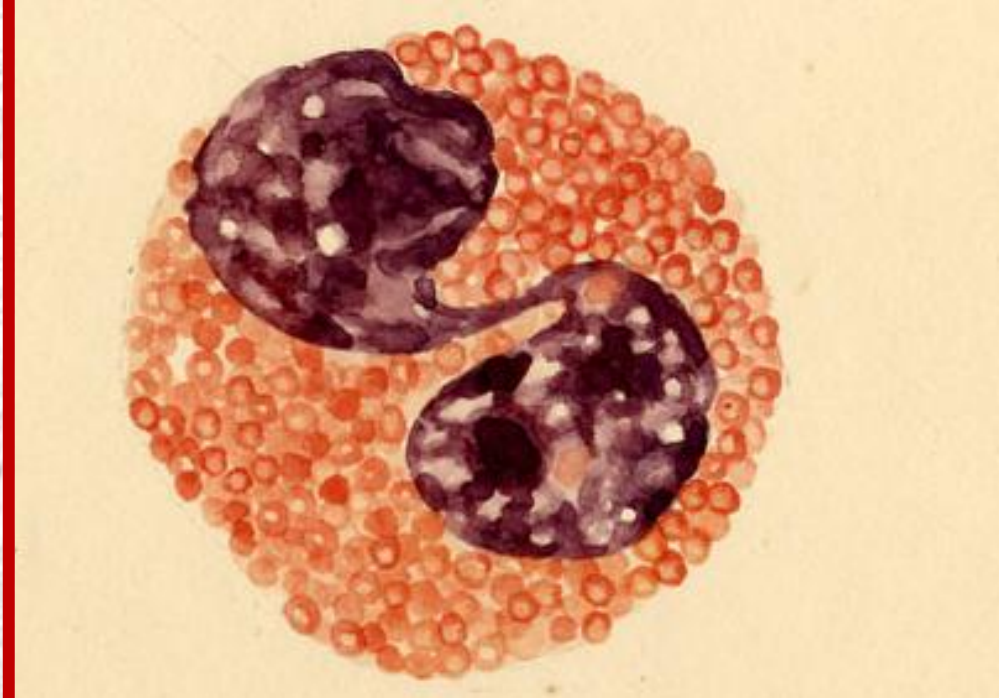
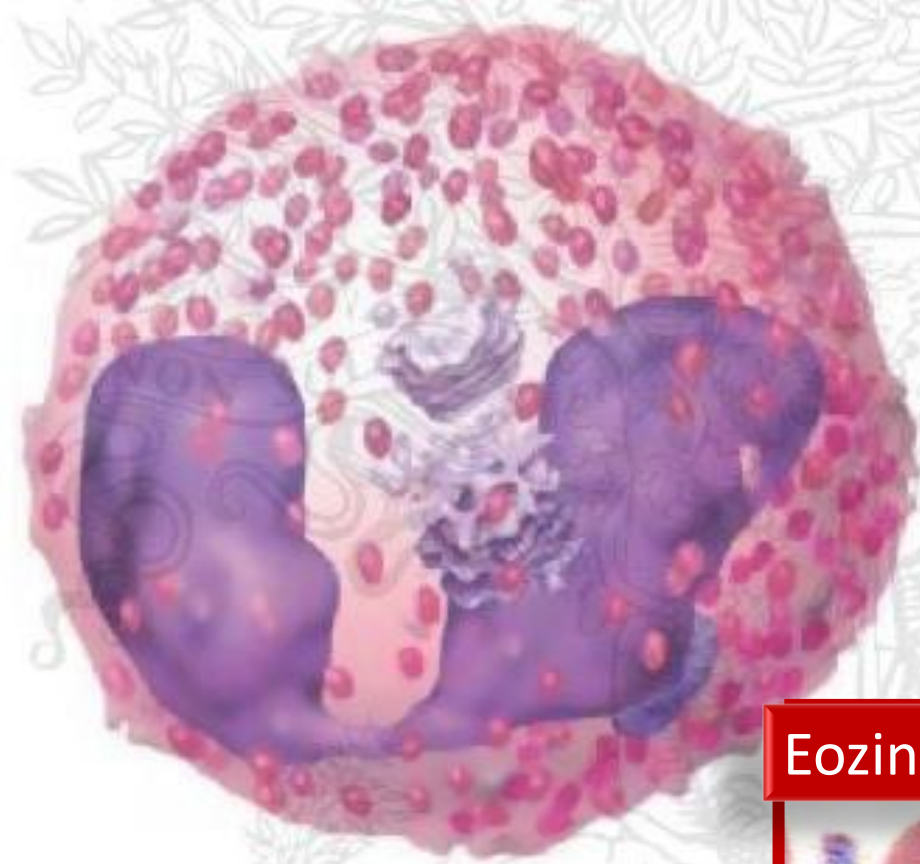The symbol represents the anti-bacterial nature of the Neutrophil's weaponry. The balls can represent specific and azurophilic granules full of powerful anti-bacterial agents like lysozyme, lactoferrin, myeloperoxidase and defensins.

The "kamikaze" nature of the Neutrophil made me think of brute force, giving the ball and chain a more appropriate weapon for a brutal killer that attacks without regard to its own survival.

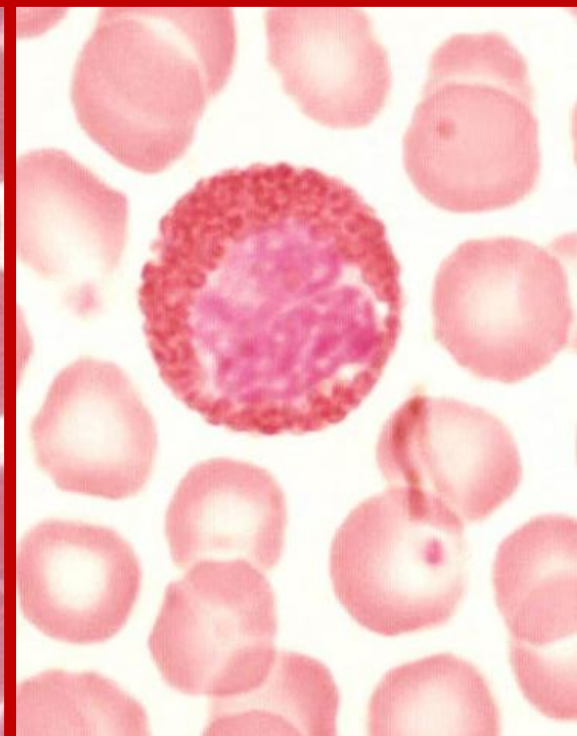
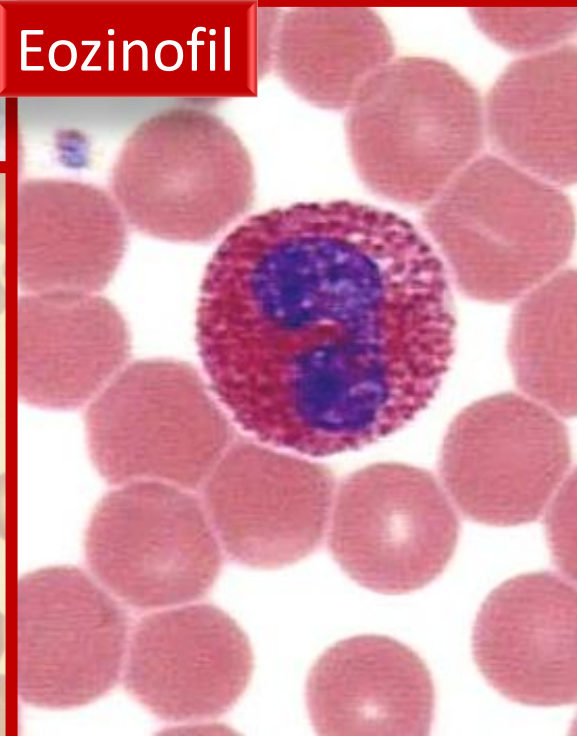
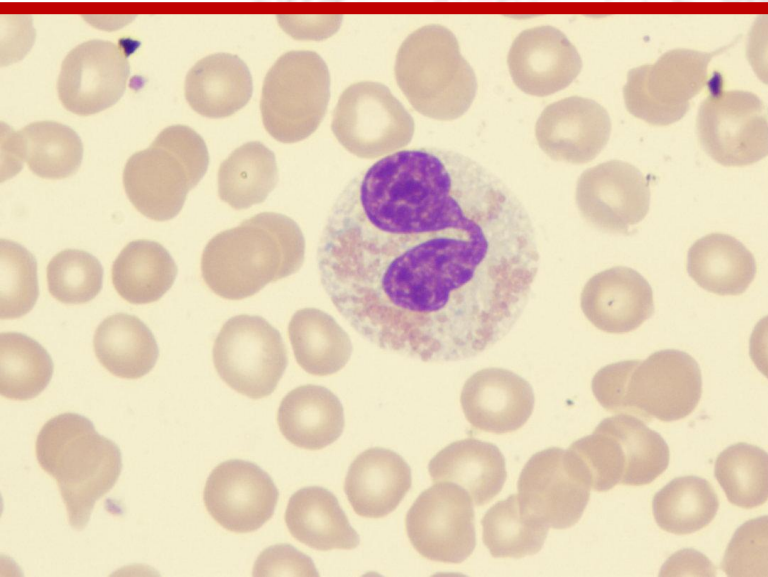
# Eozinofil



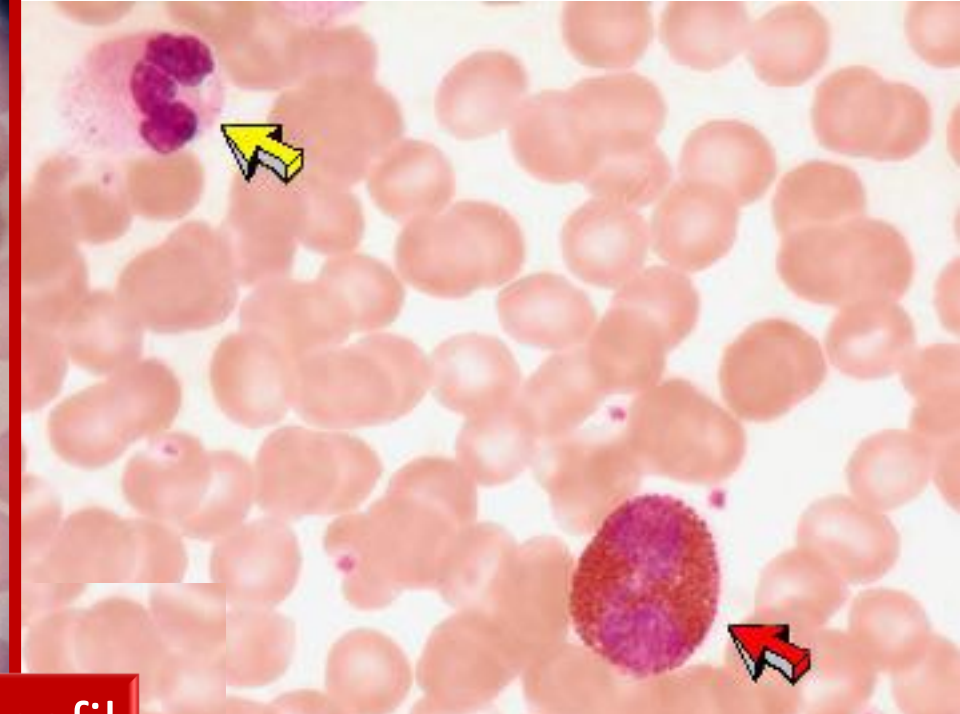
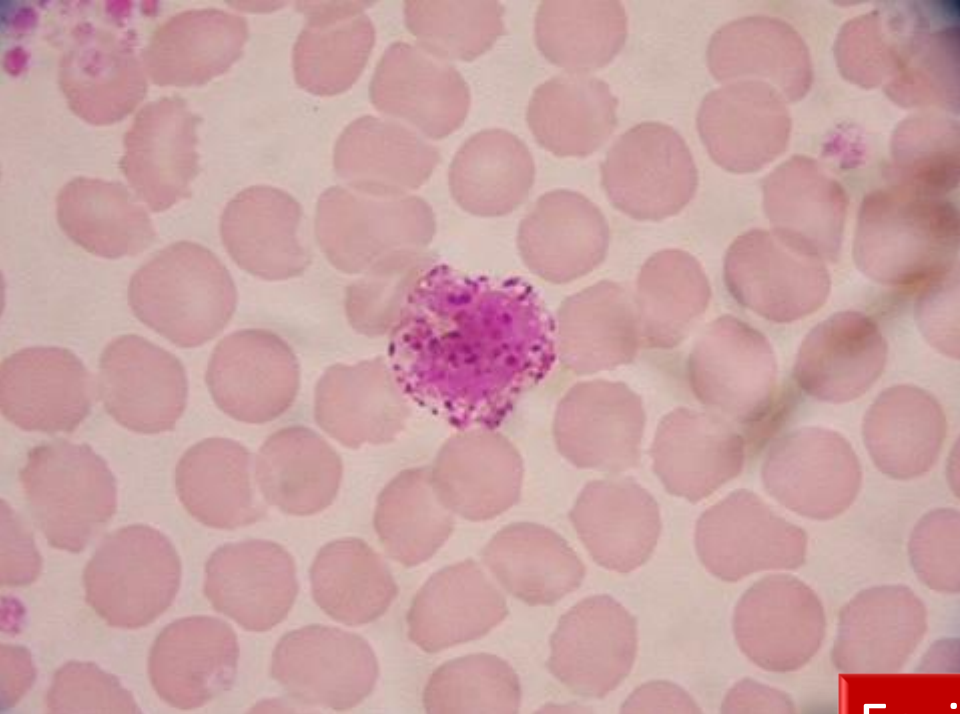




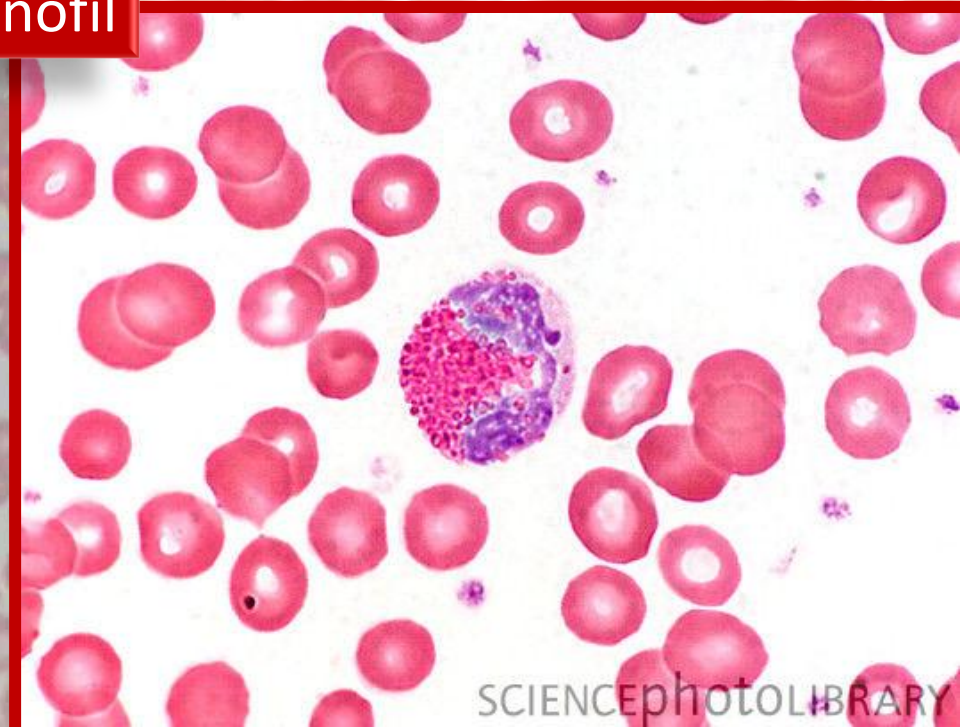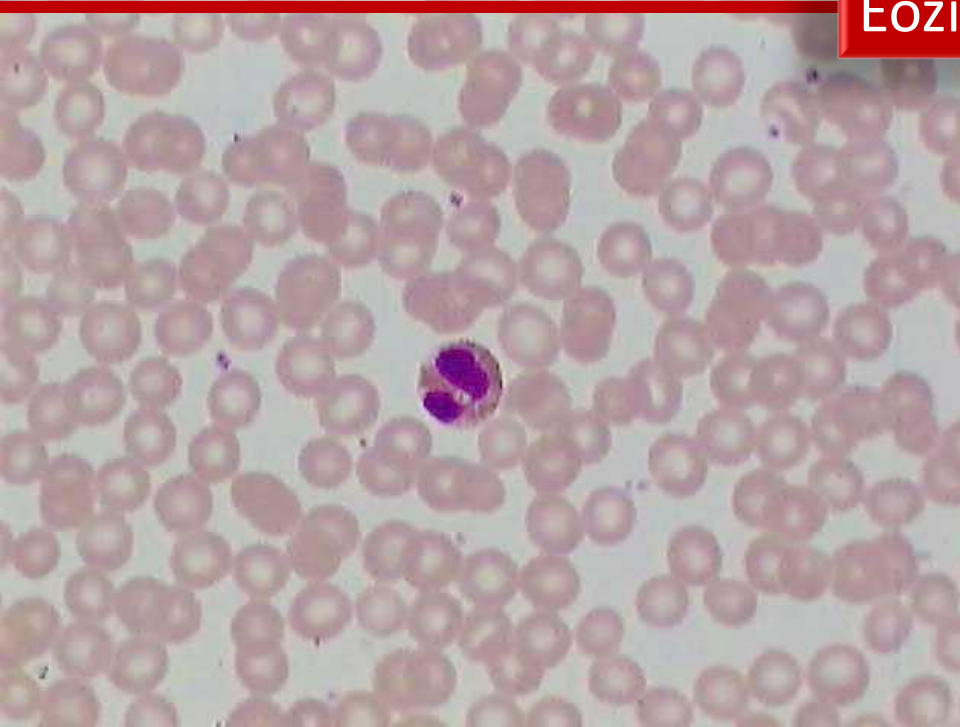
Eozinofil



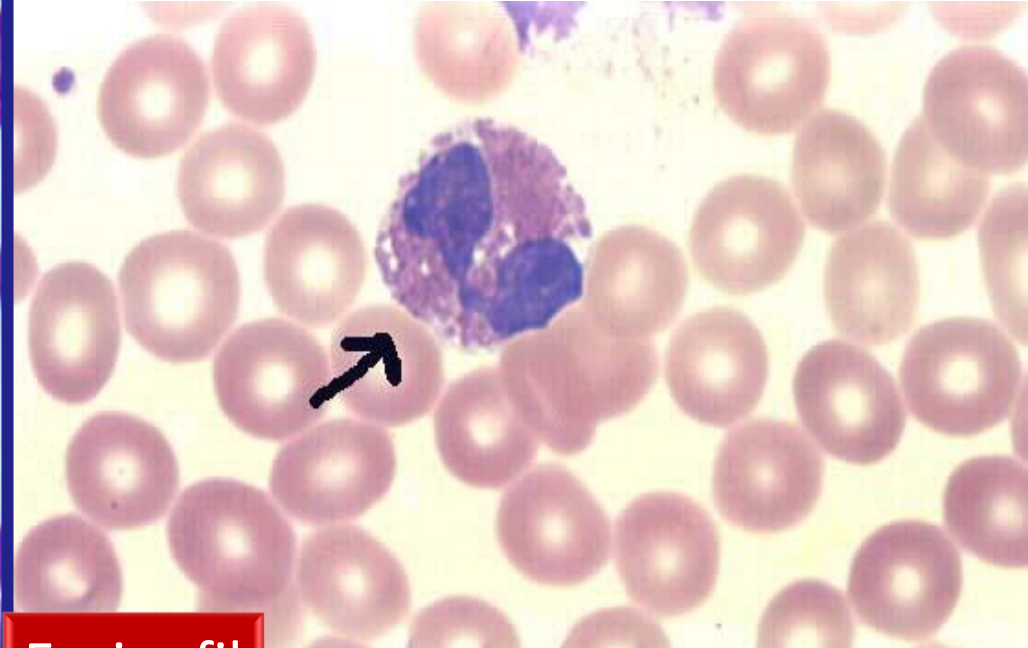
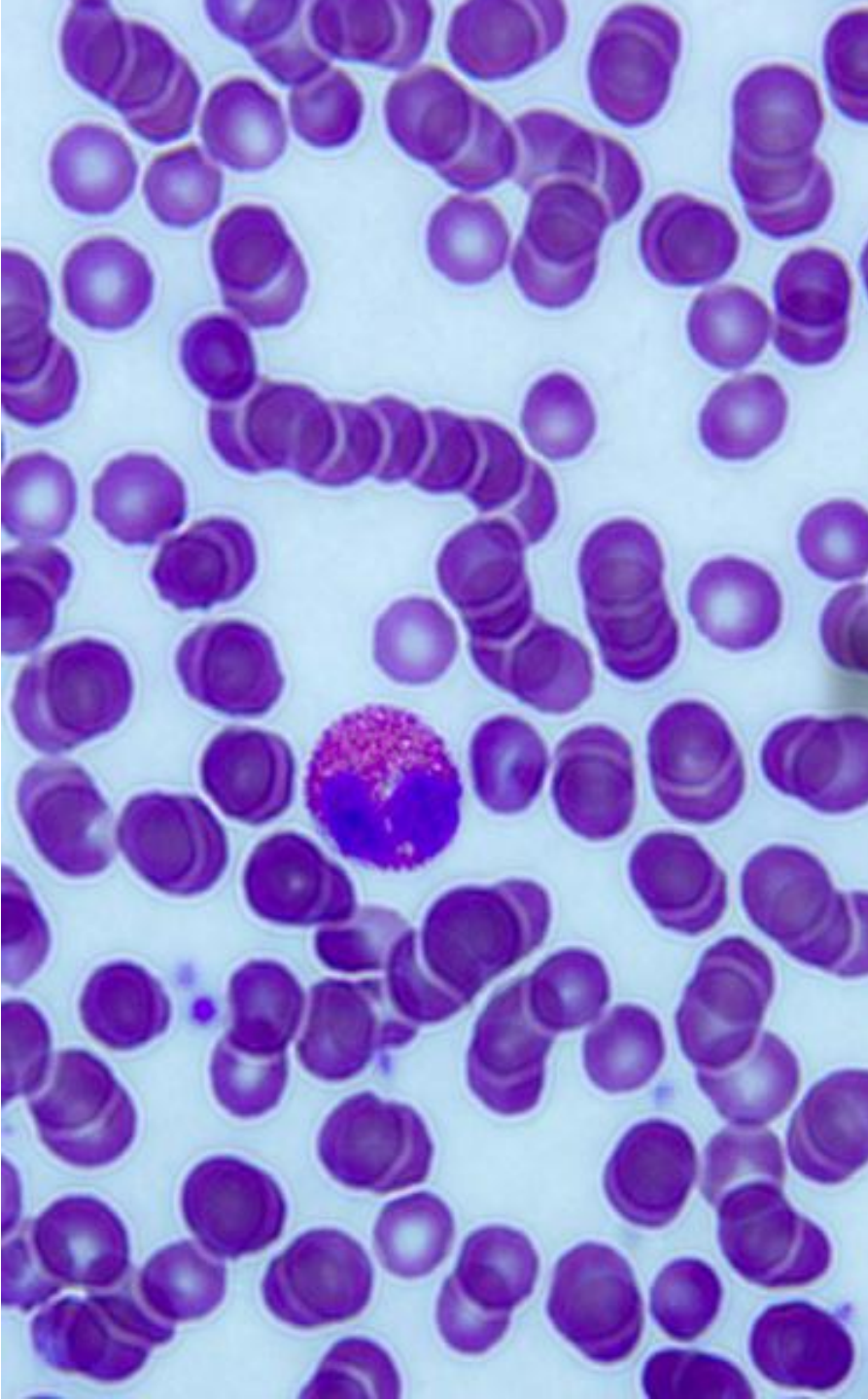




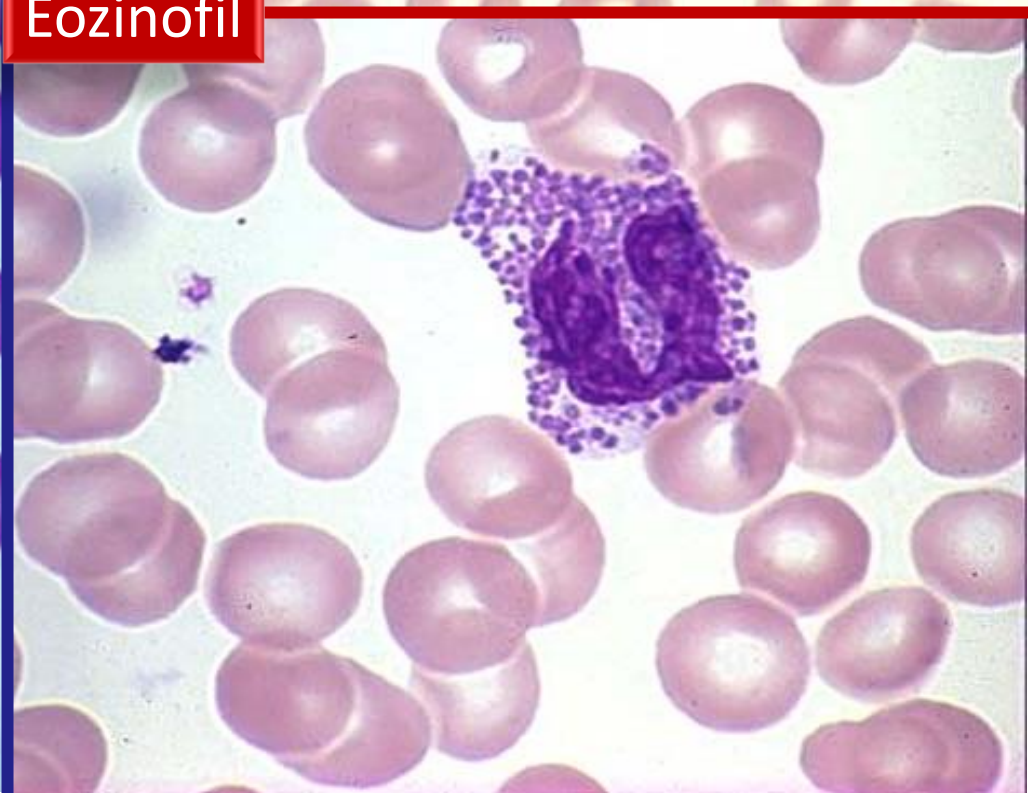Eozinofil



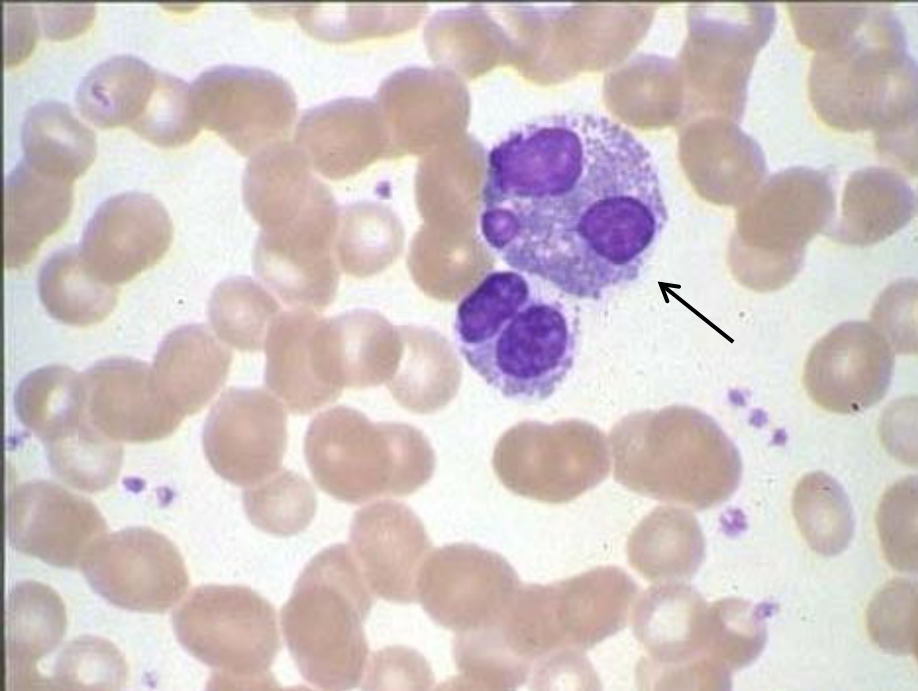




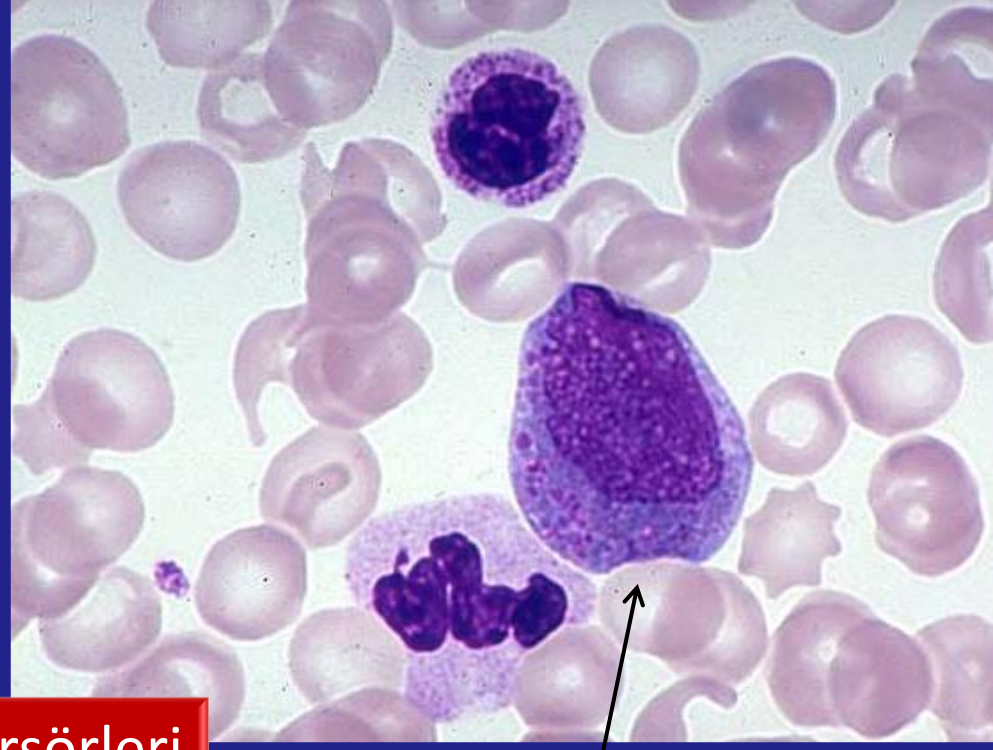
Eozinofil



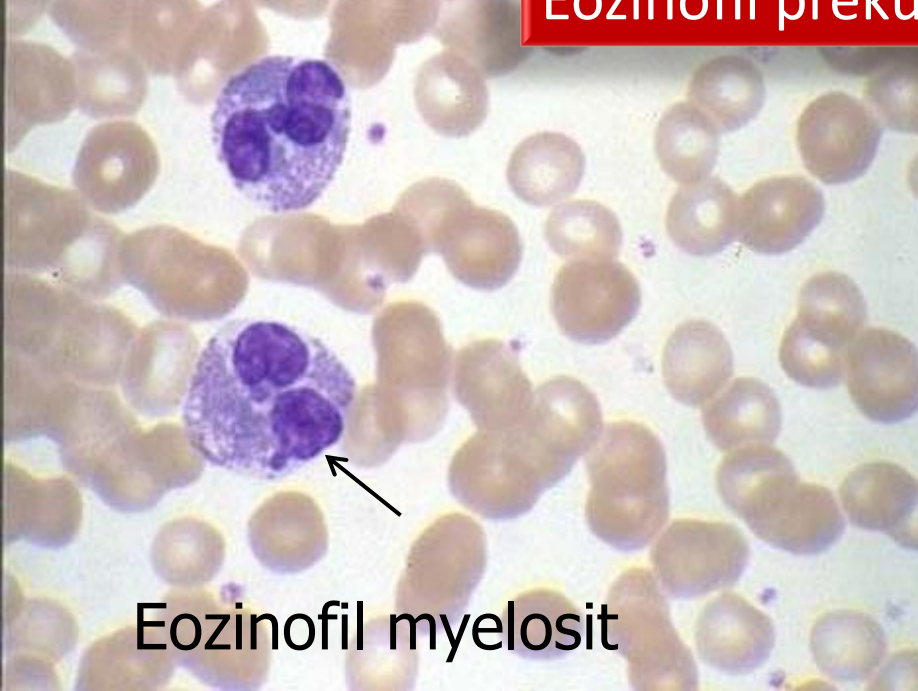




Eozinofil prekürsörleri



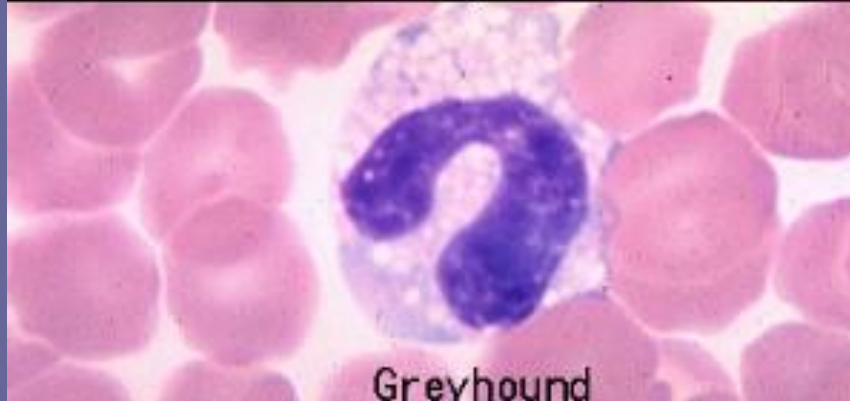
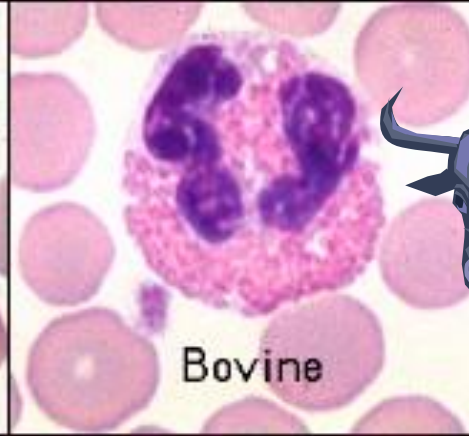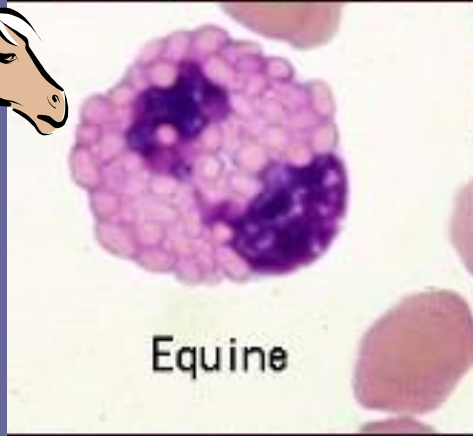
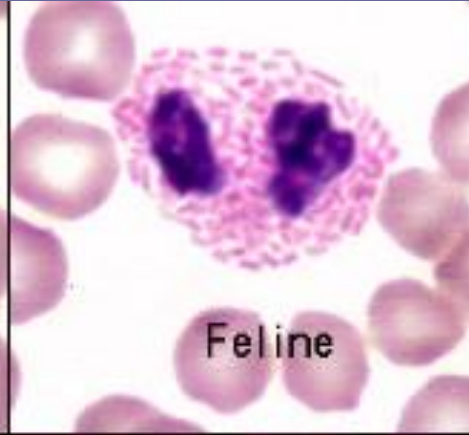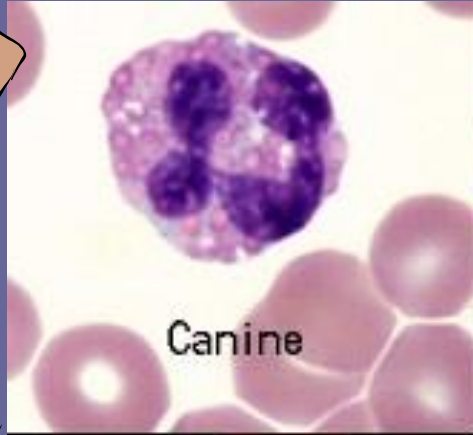
Eozinofil promyelosit



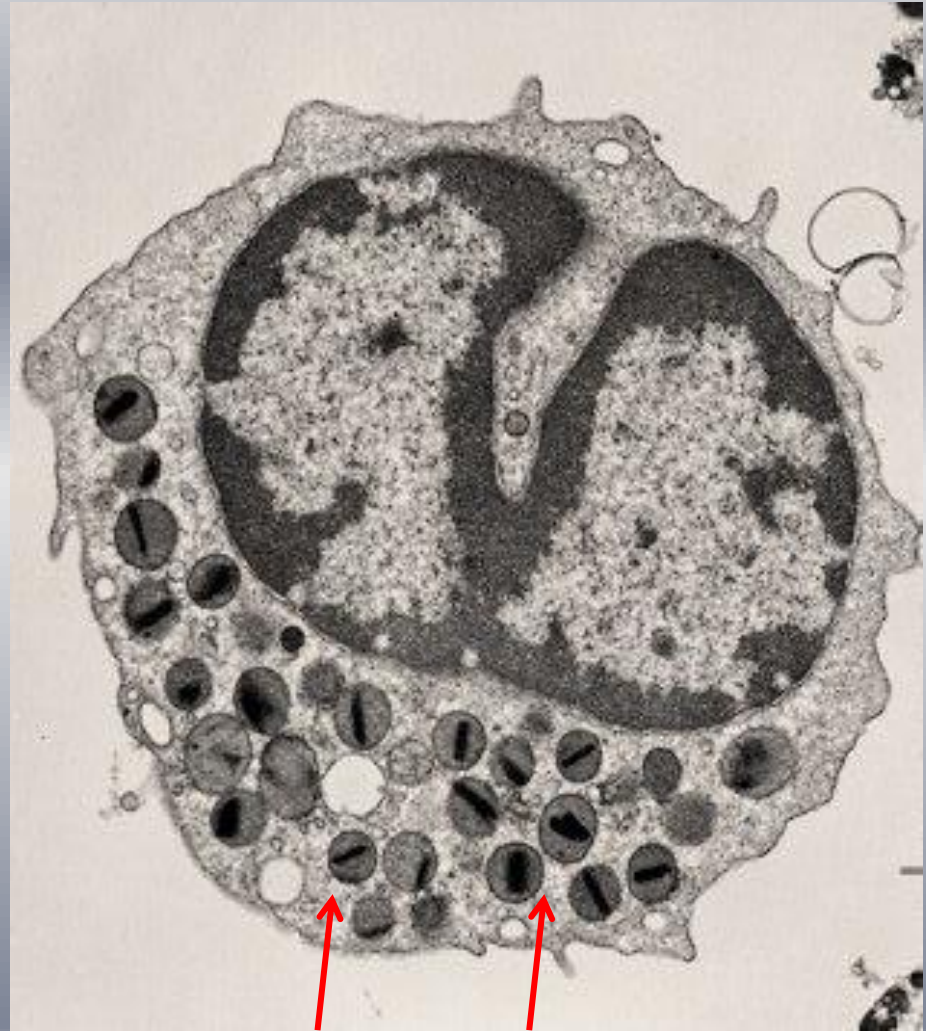
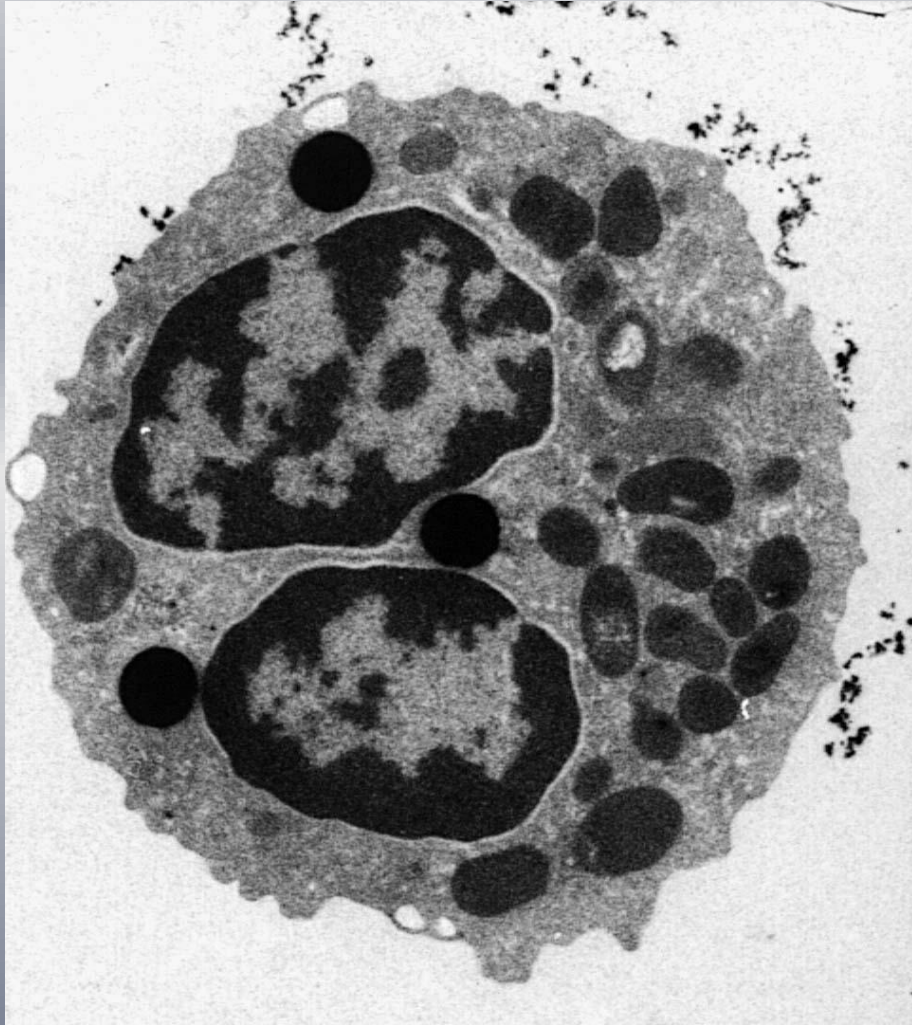
Eozinofil myelosit



# Hayvan Türlerinde Eozinofiller



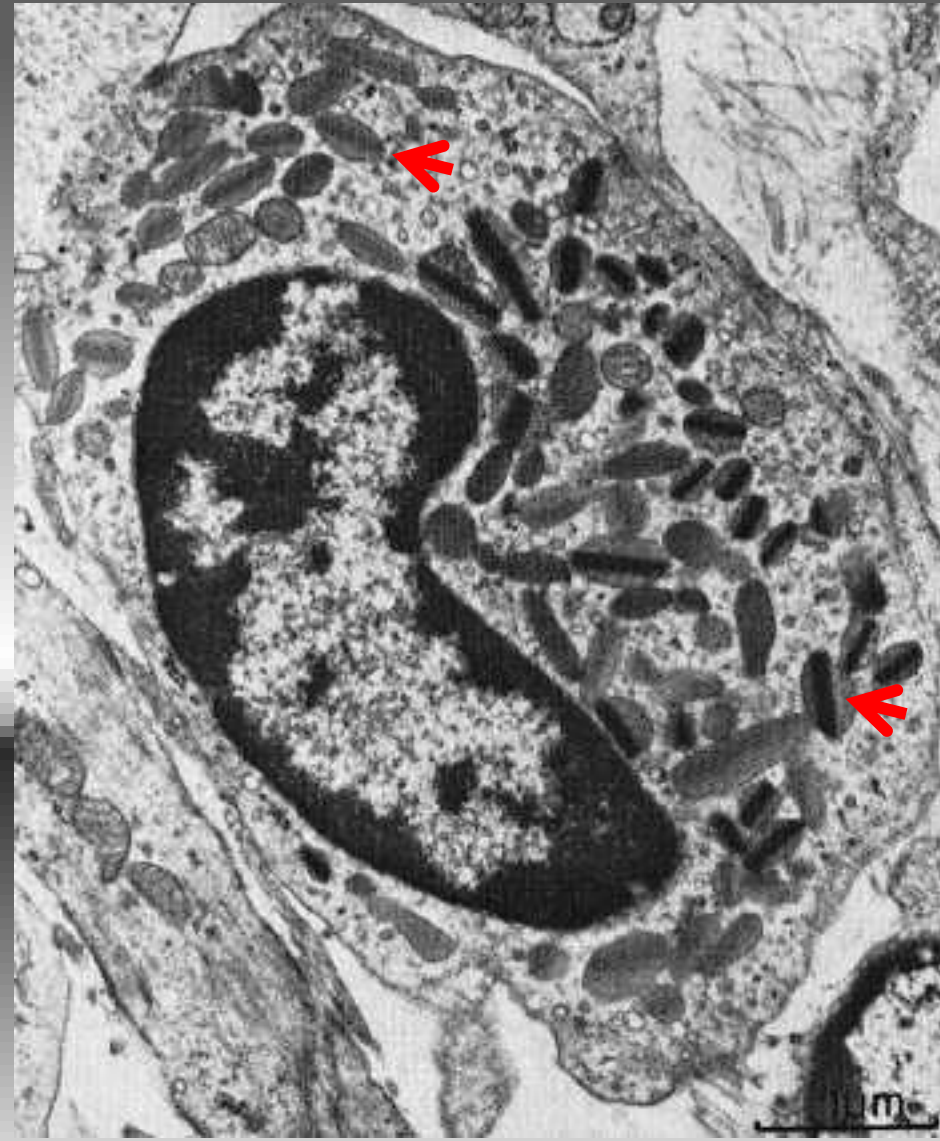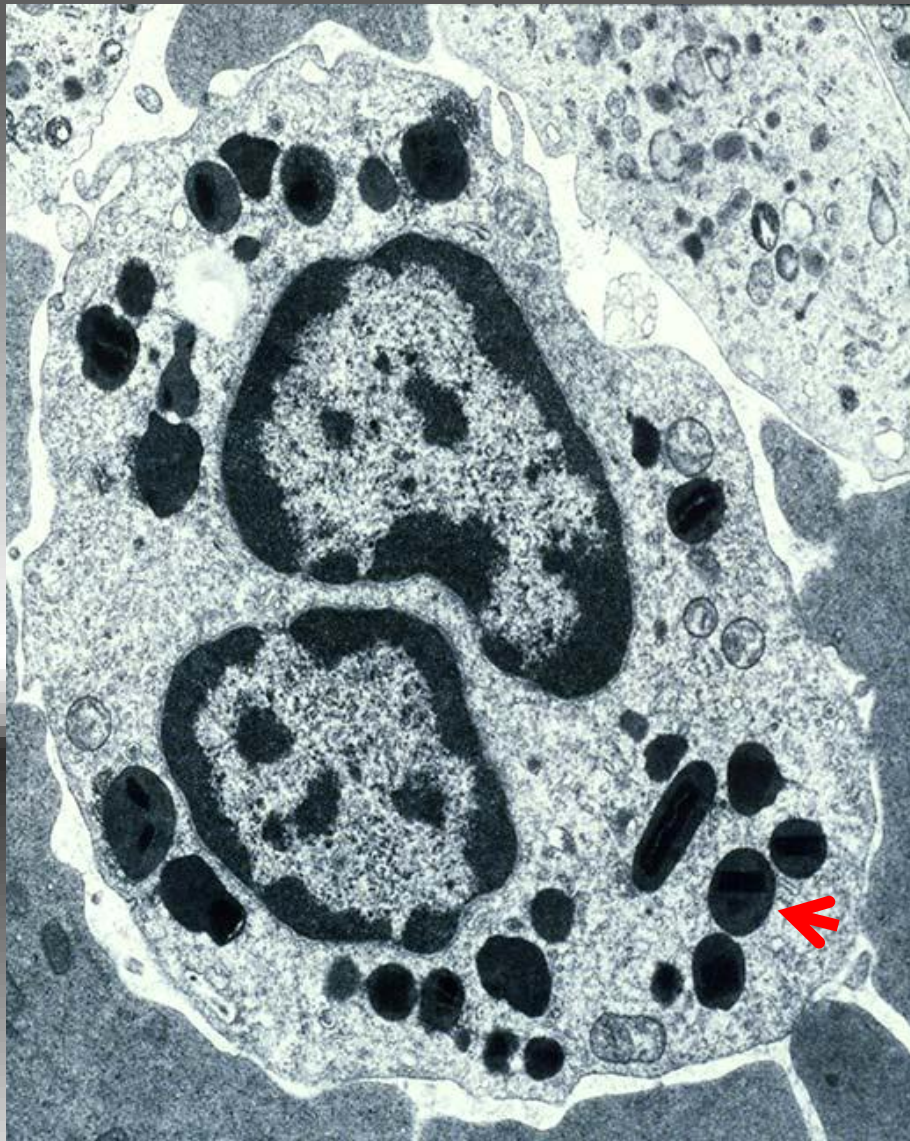*Eozinofil kesiti (TEM)*



kristaloid granül

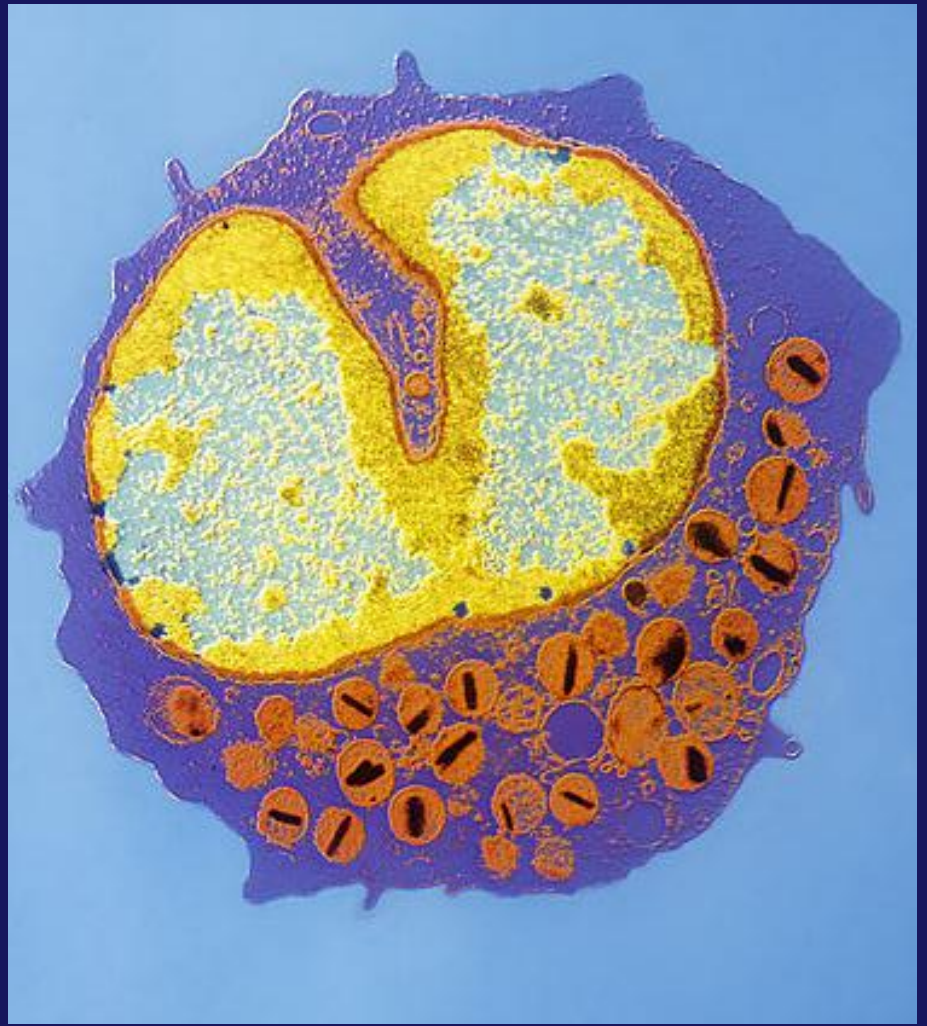
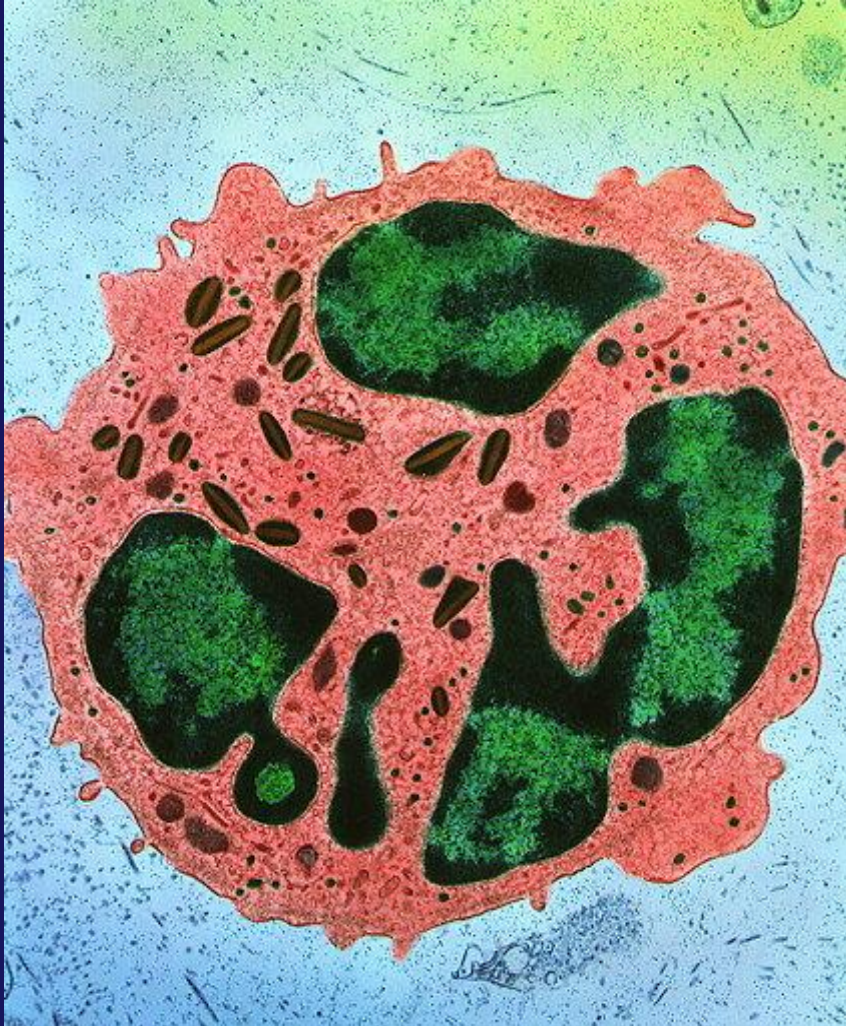


*Eozinofil kesiti (TEM)*

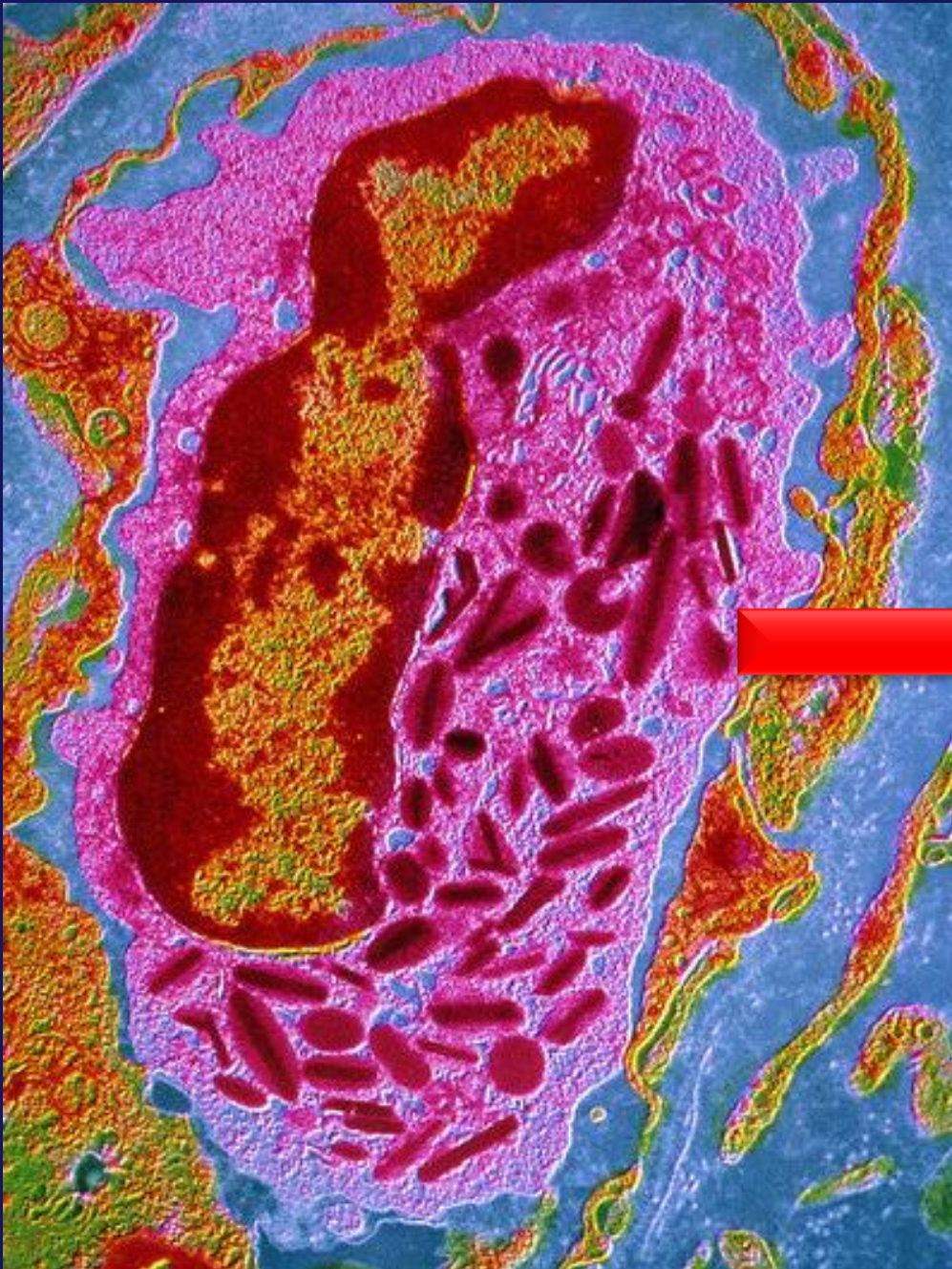




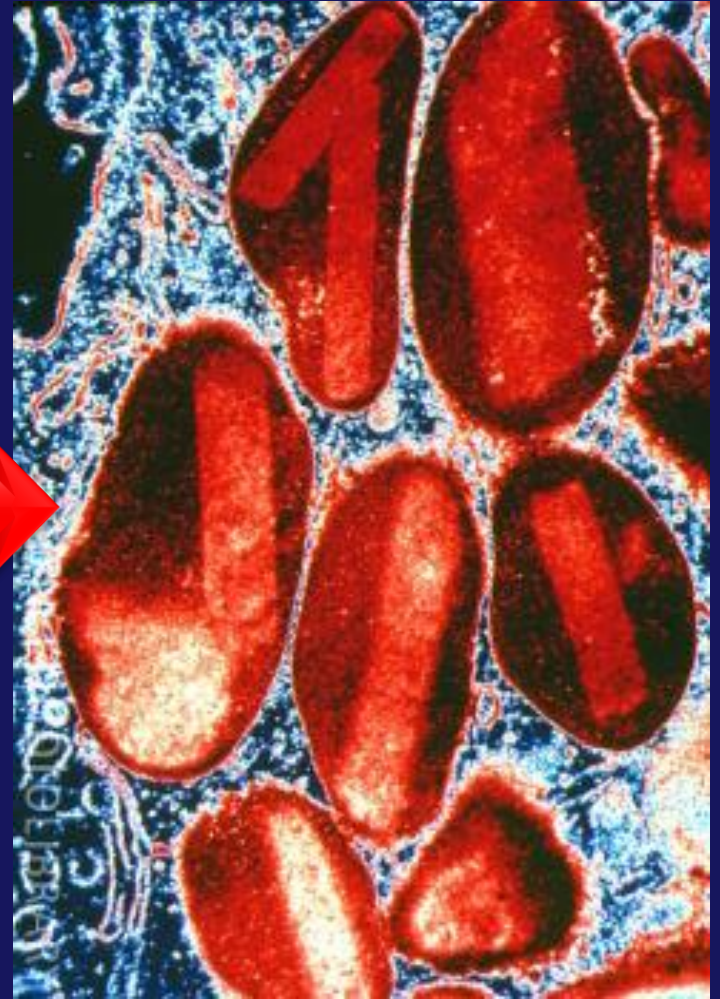
*Eozinofil kesiti (TEM)*







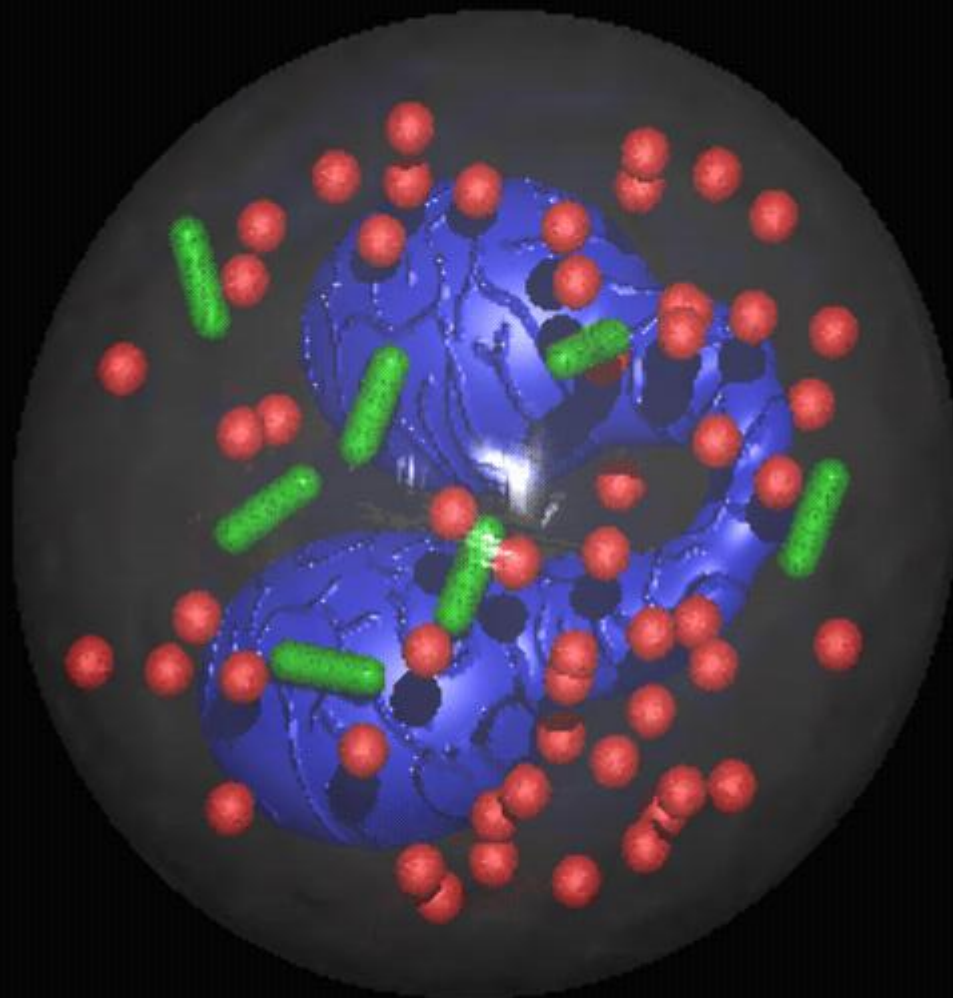
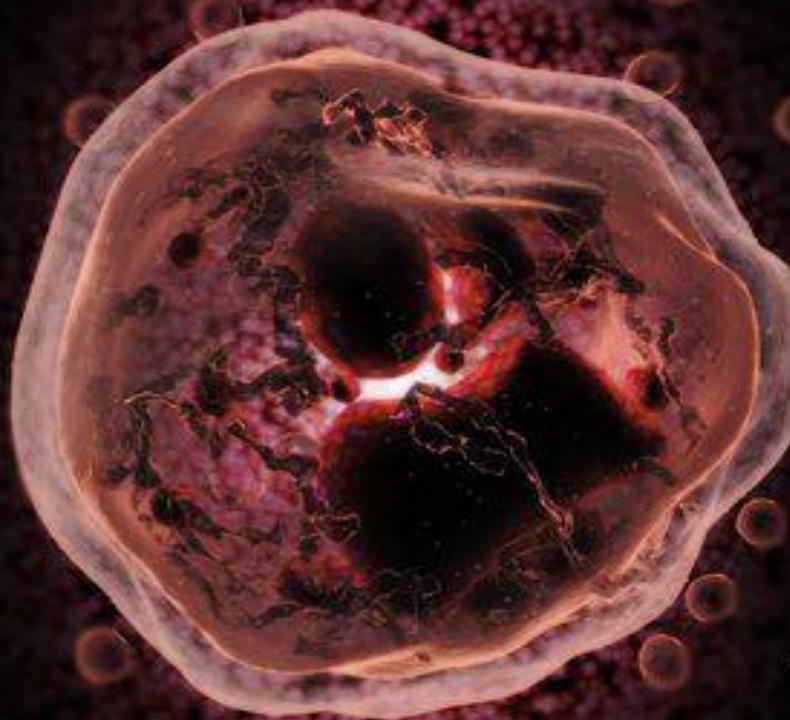
*Eozinofil kesiti (TEM)*



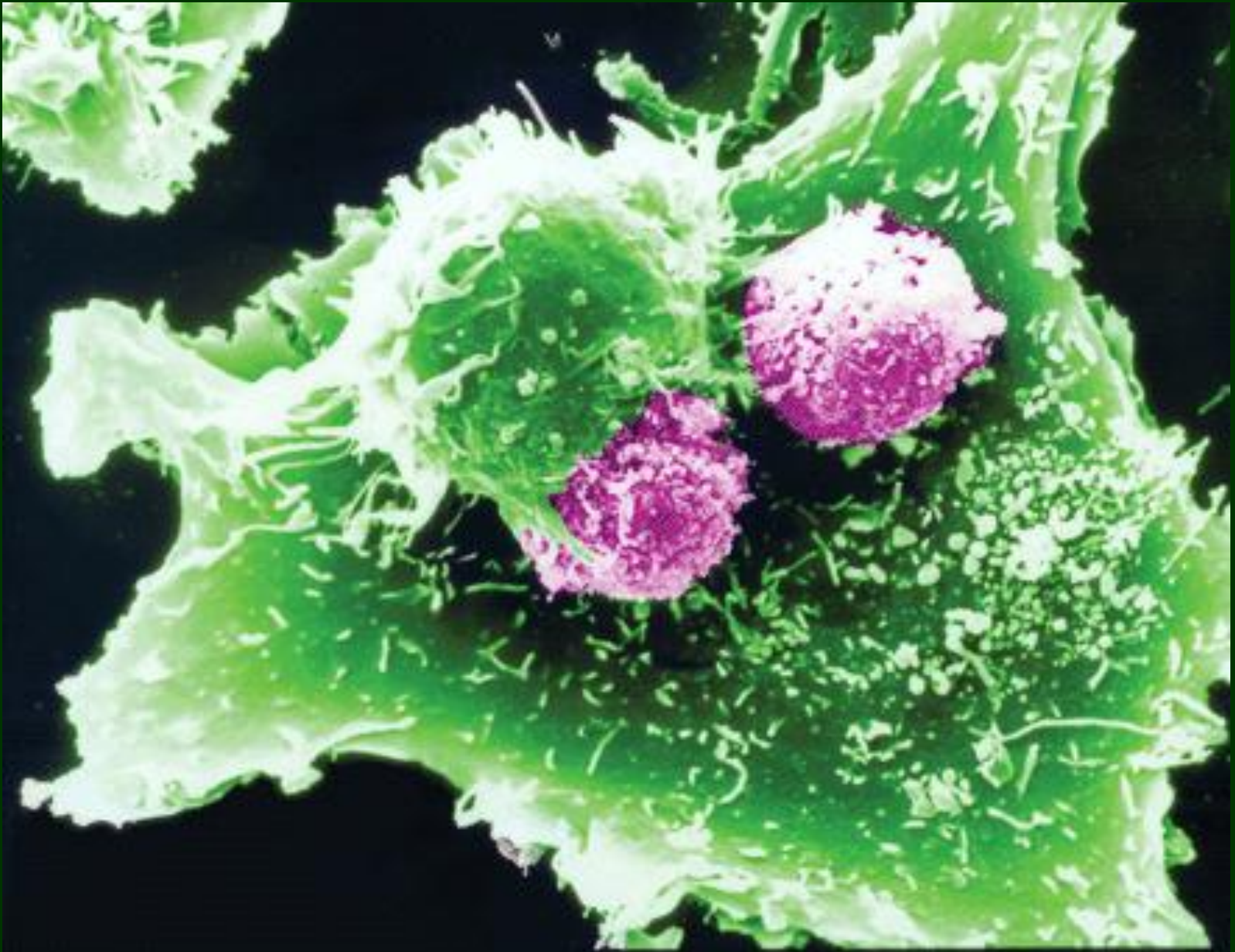
kristaloid granül



*Eozinofil 3D dijital*







*Eozinofil (SEM)*

# THE EOSINOPHIL

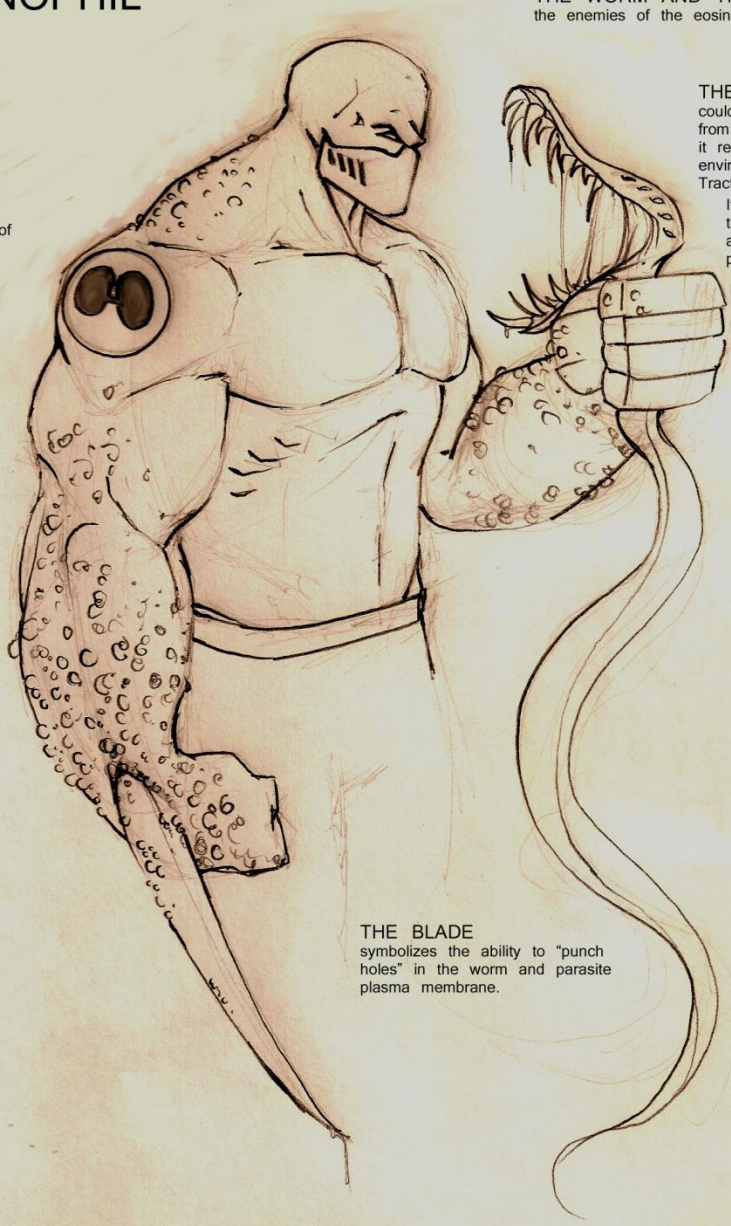
THE WORM AND THE PARASITE  
the enemies of the eosinophil.

SYMBOLISM  
the bilobed nucleus of  
the eosinophil

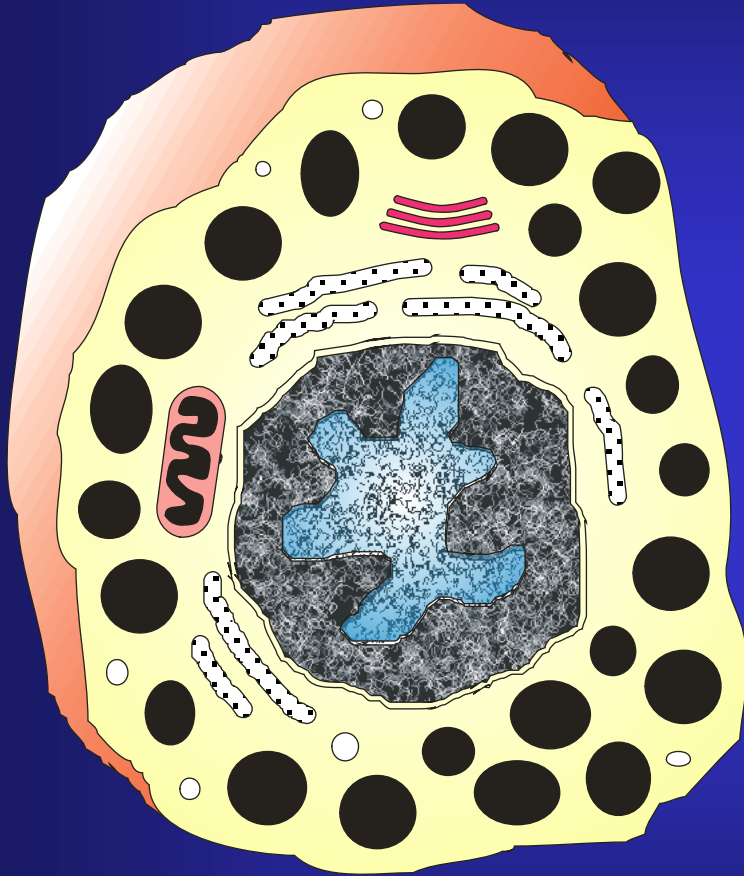
THE MASK  
could represent protection  
from the toxic chemicals  
it releases or the toxic  
environment of the GI  
Tract in which it resides.  
It could also represent  
the connection to  
asthma that the eosino-  
phil seems to have.

THE GRANULES  
no other granulocyte has  
them quite like the eosinophil.  
Neurotoxins,  
Peroxidases,  
Cationic Proteins,  
and Major Basic Proteins, all  
give the eosinophil worm  
killing power

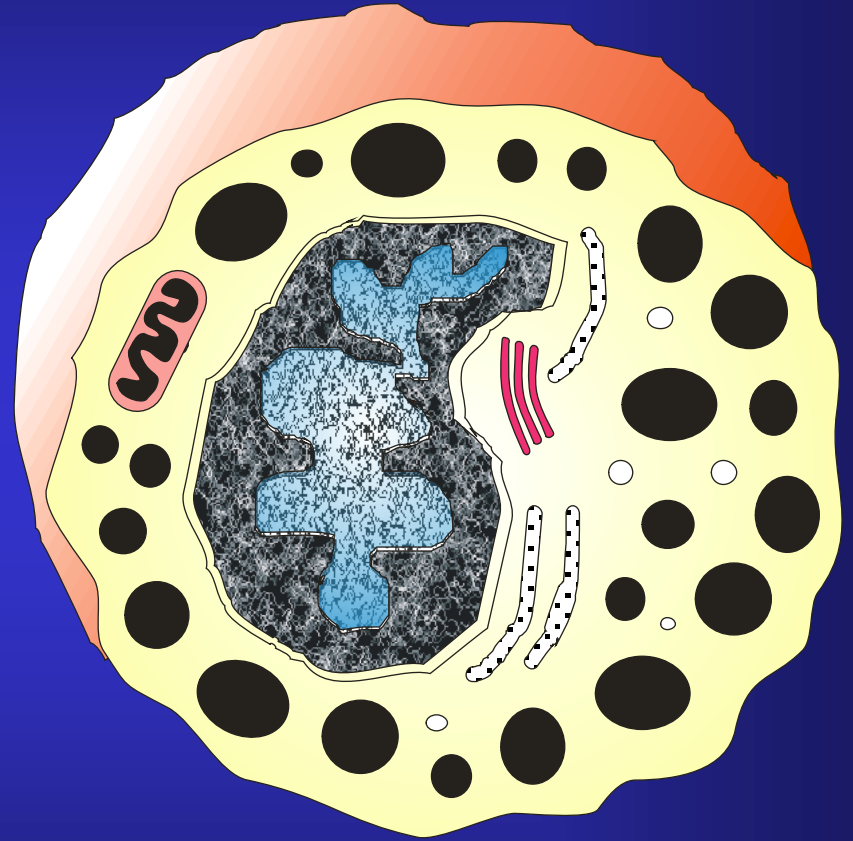
THE BLADE  
symbolizes the ability to "punch  
holes" in the worm and parasite  
plasma membrane.



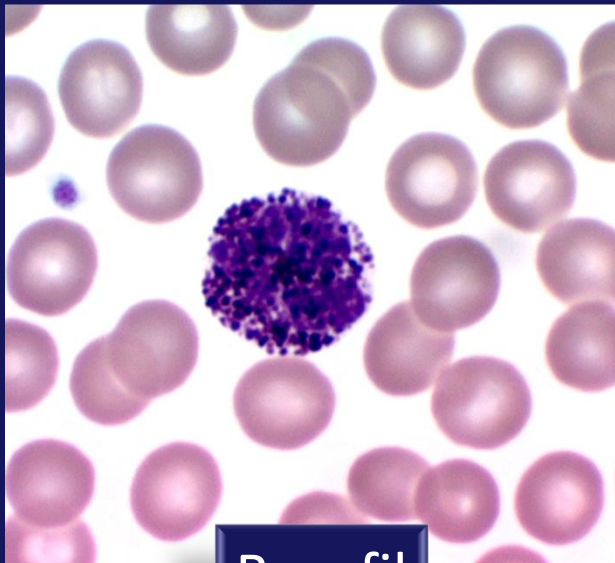




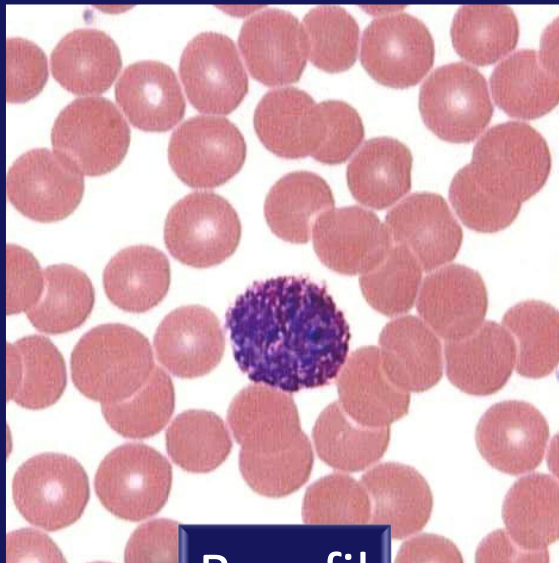
Mast hücresi



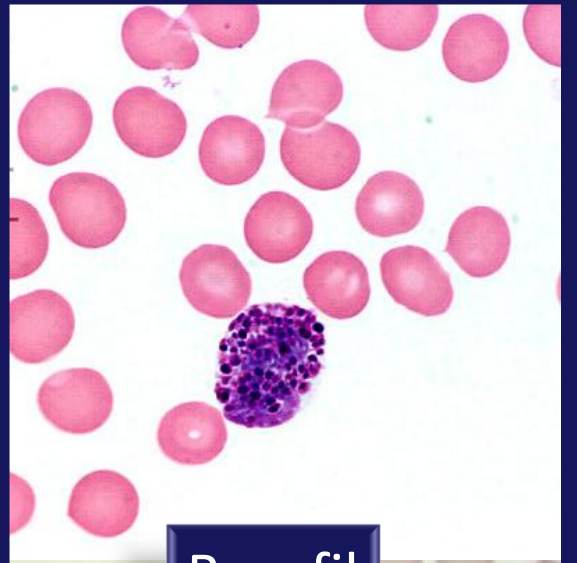
Bazofil



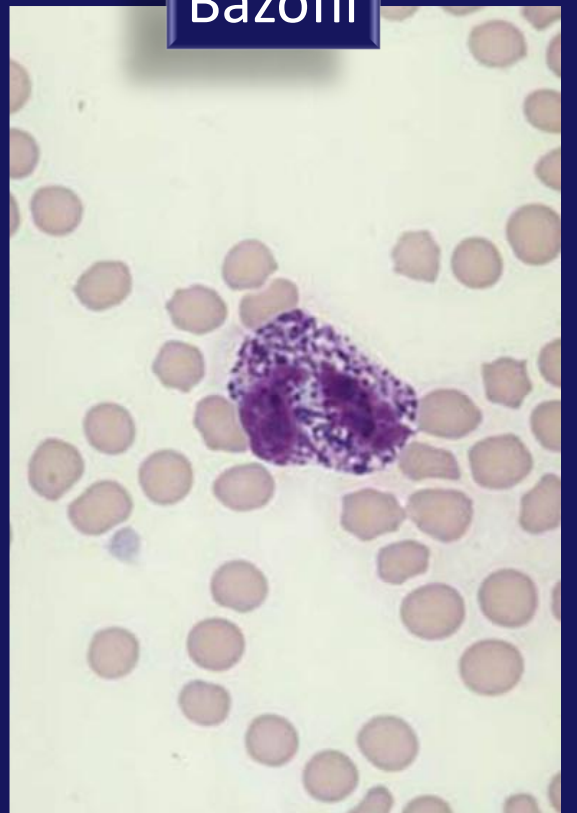
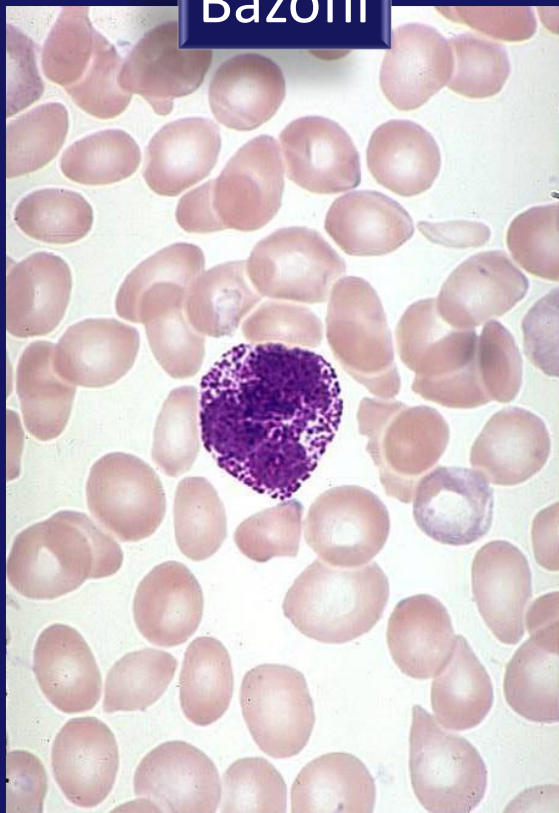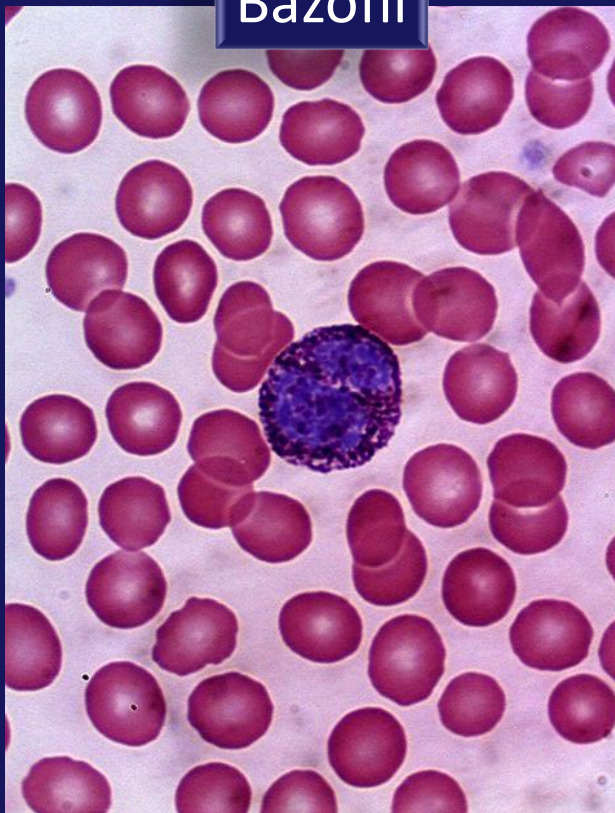
Bazofil



Bazofil

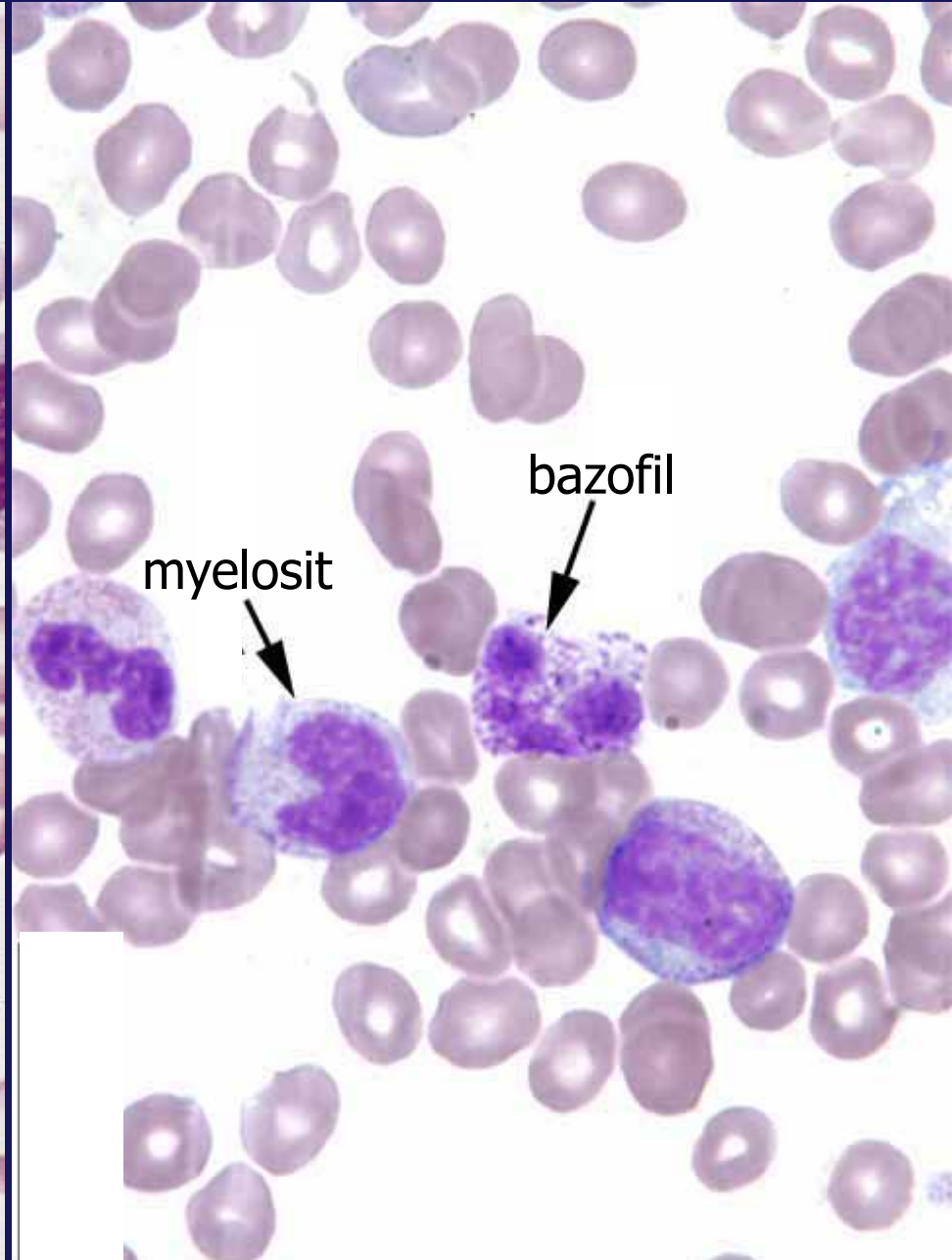
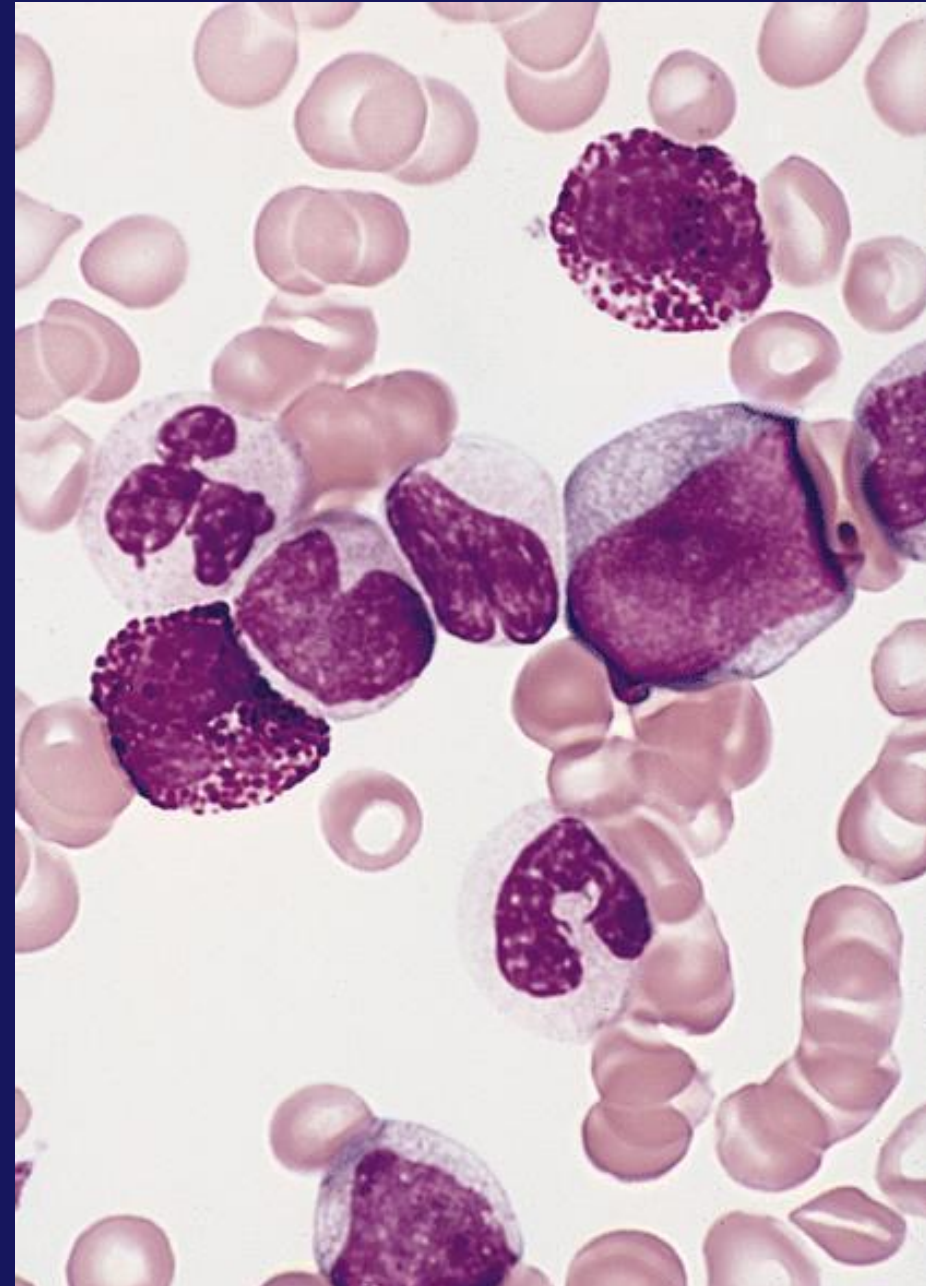


Bazofil

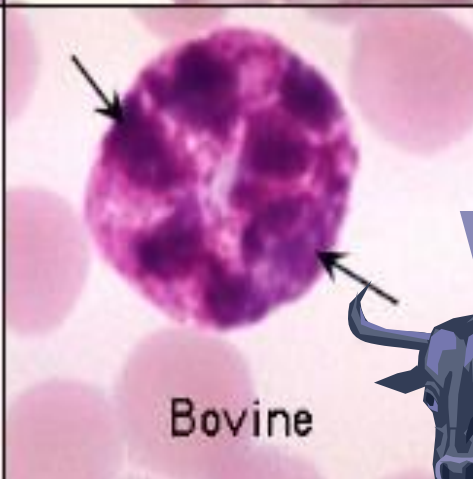
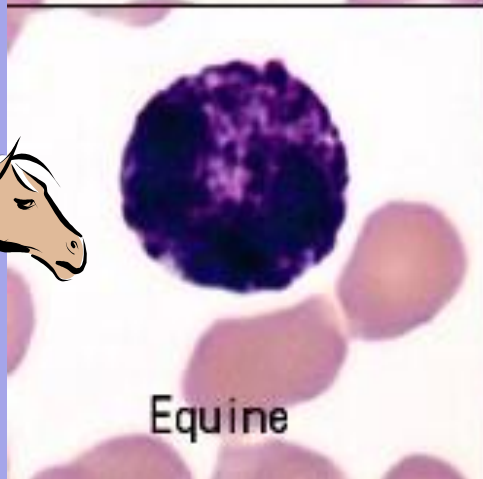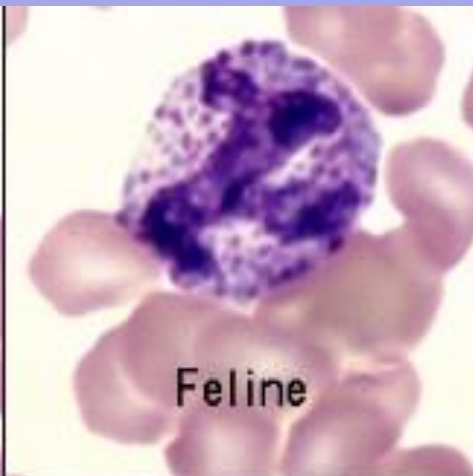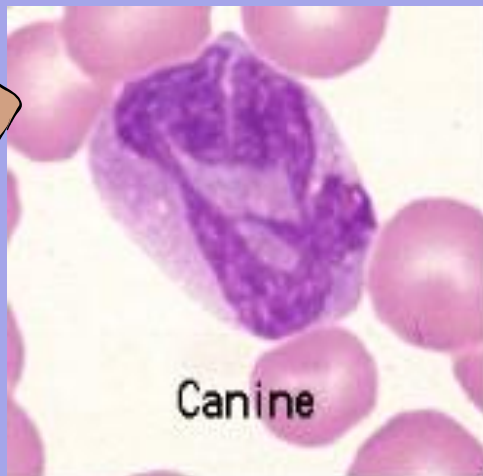





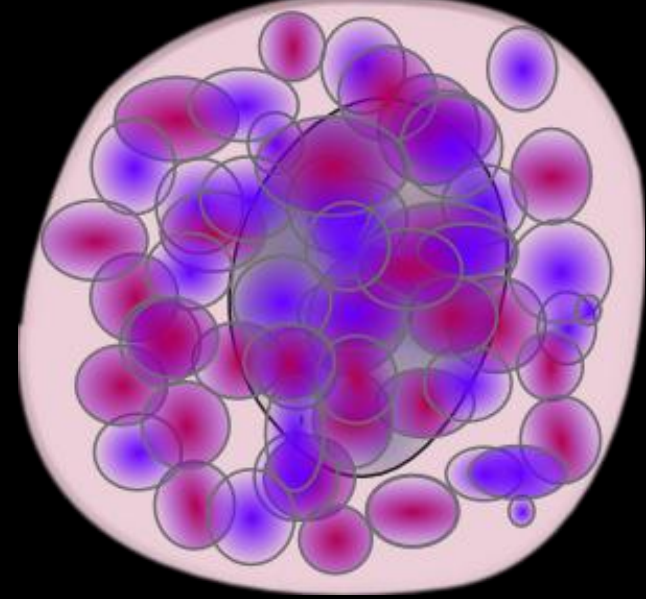
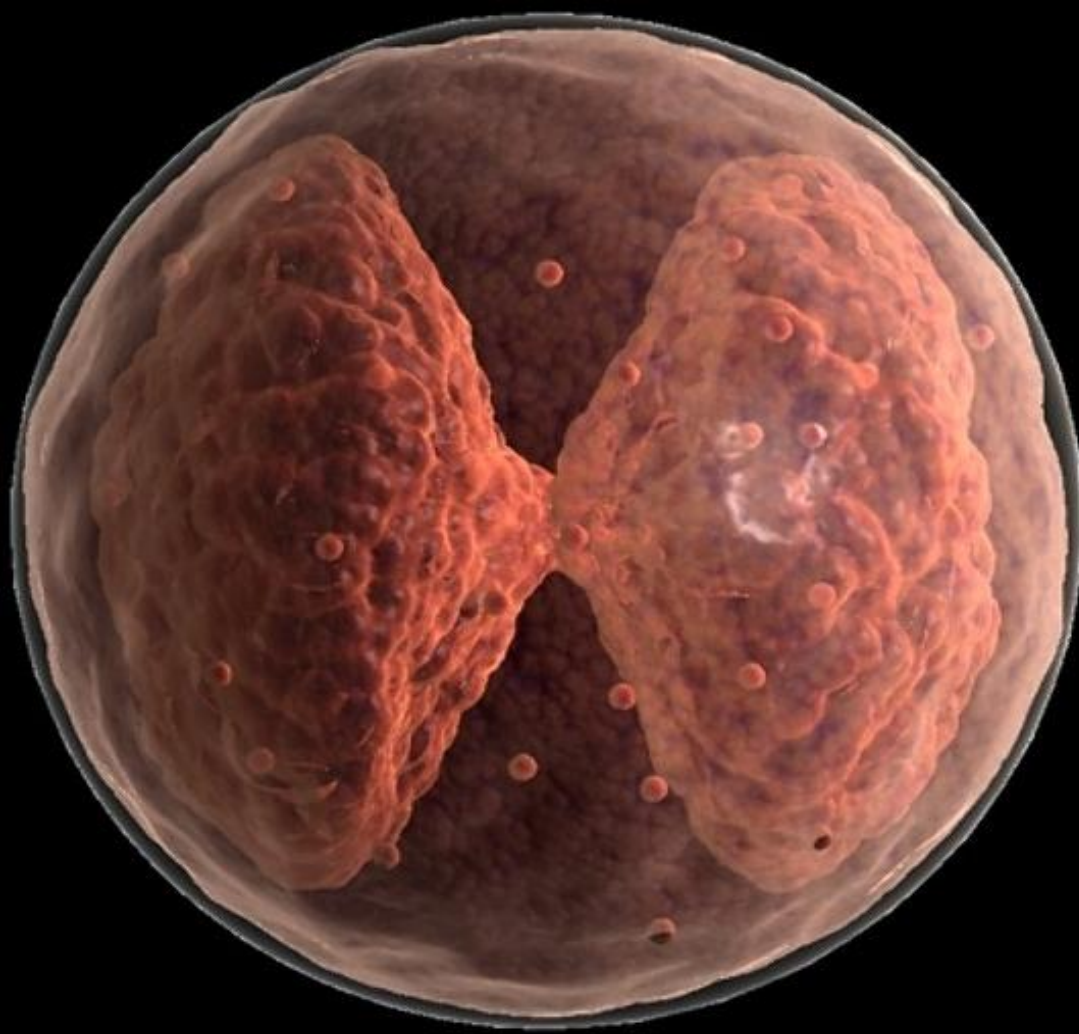
# Bazofillerin Gelişim Formları



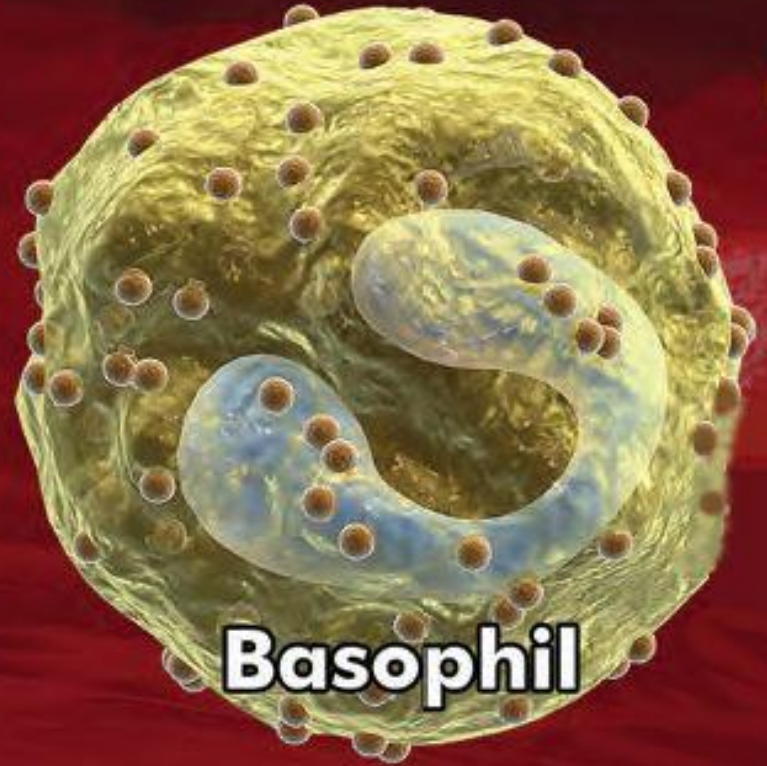
# Hayvan Türlerinde Bazofiller



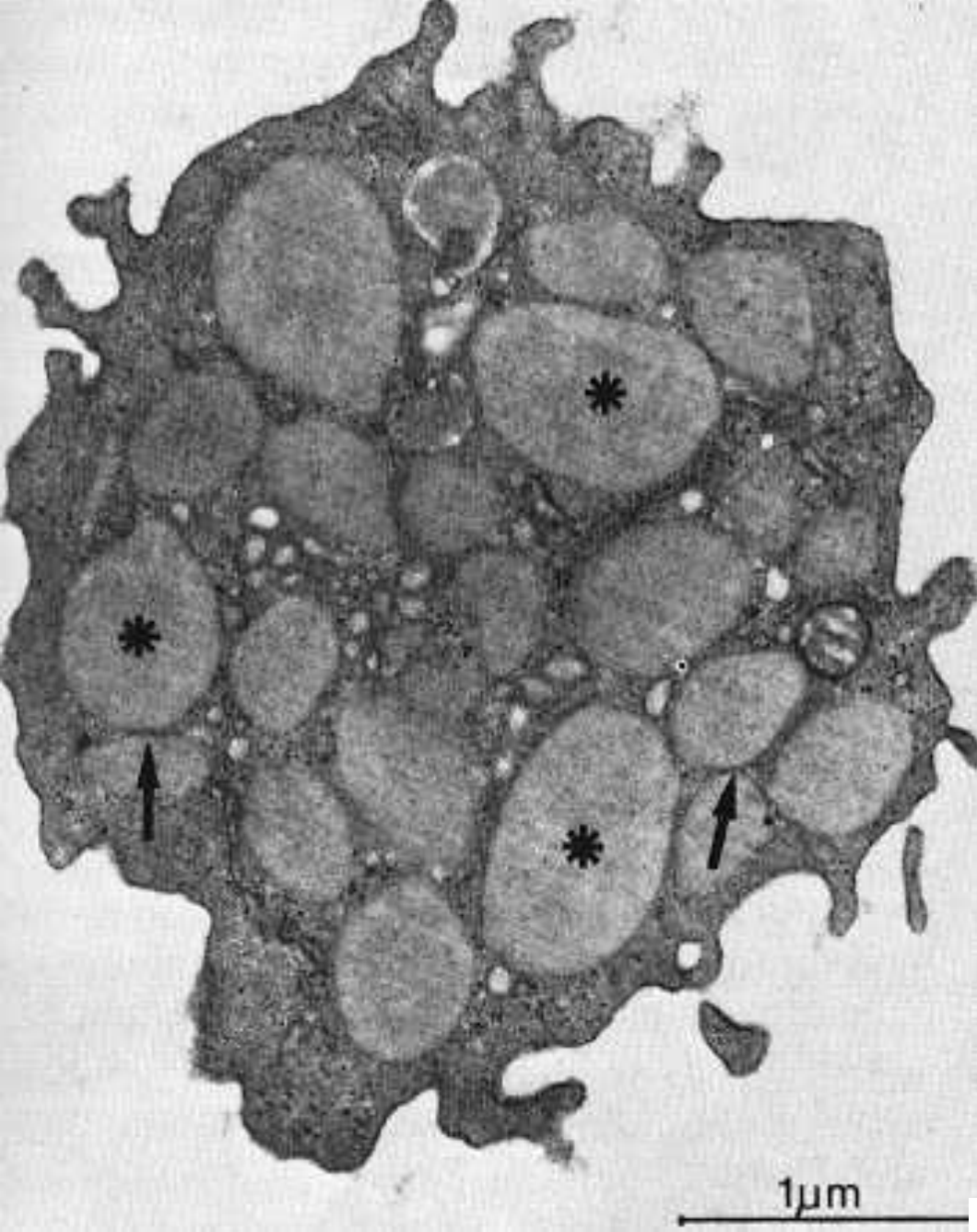




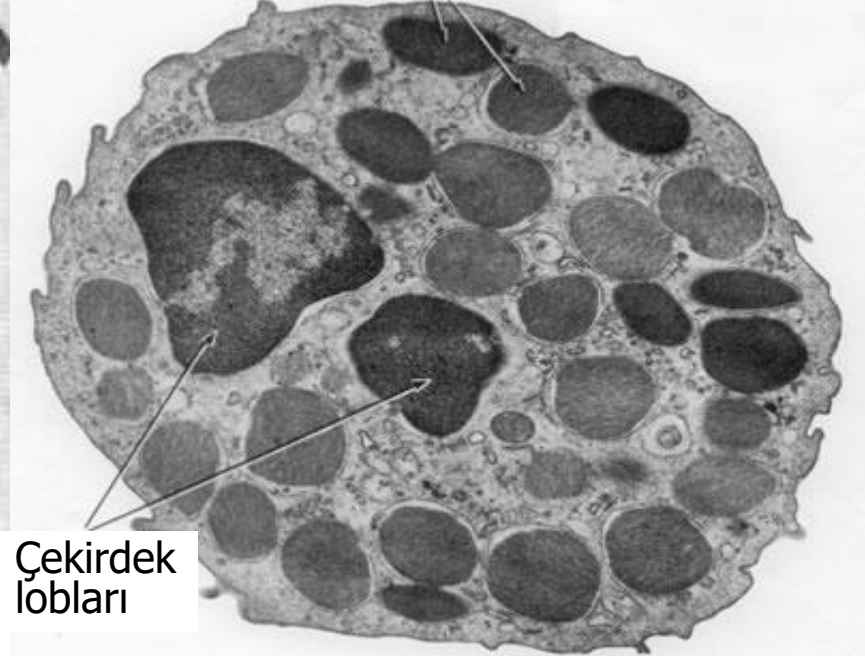
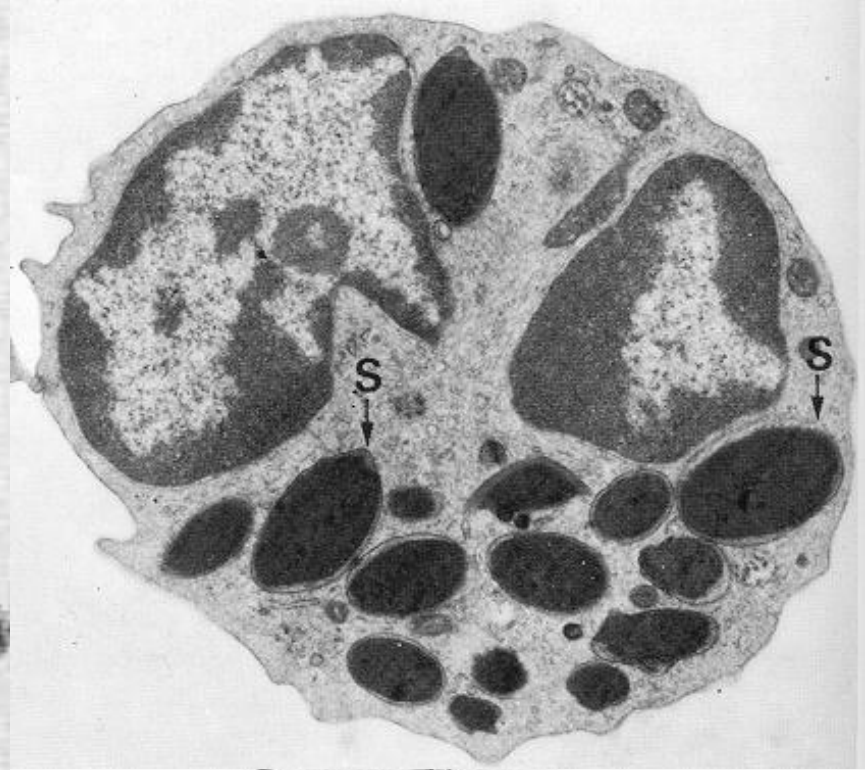
*Bazofil: çekirdek formları*



**Basophil**



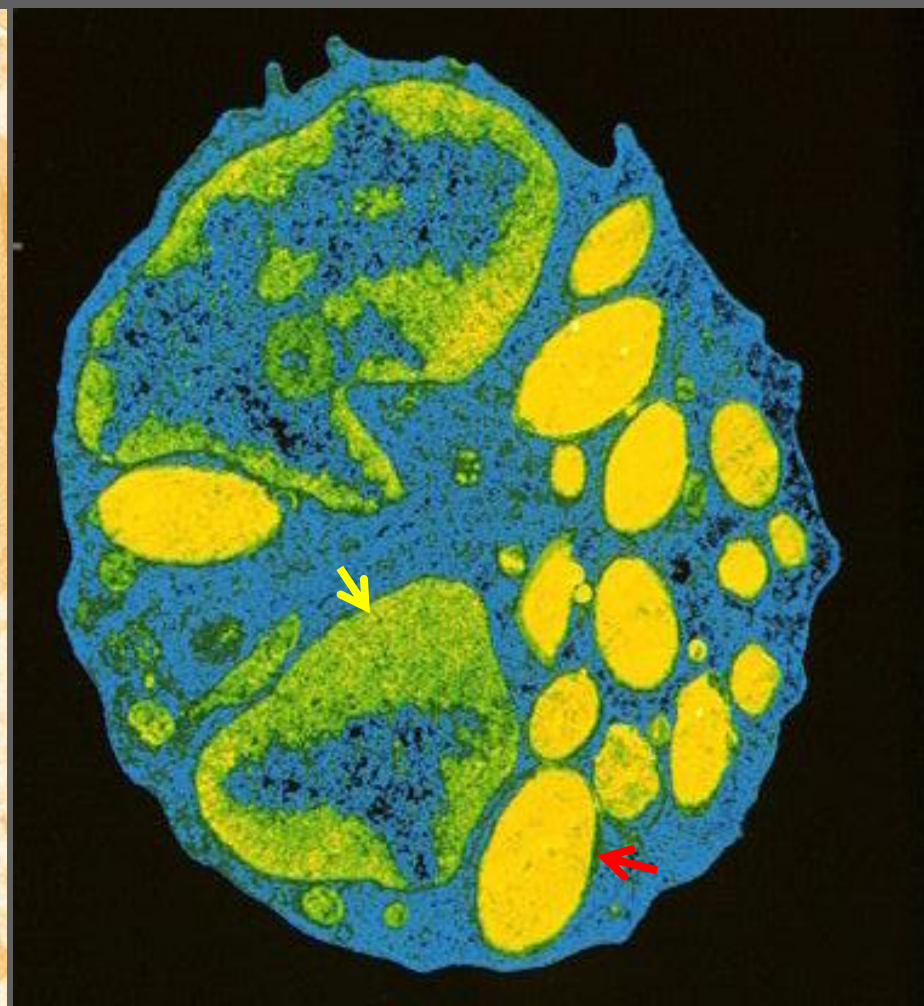
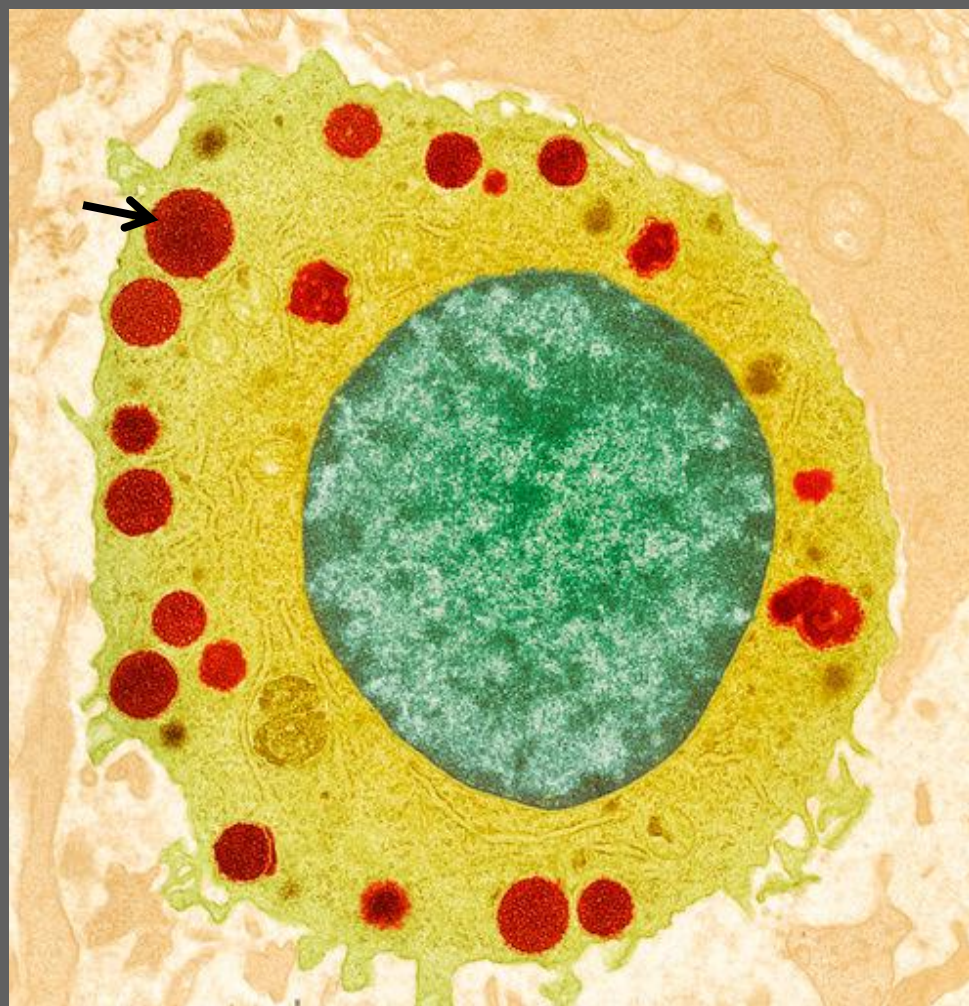*Bazofil (TEM)*



Çekirdek lobları

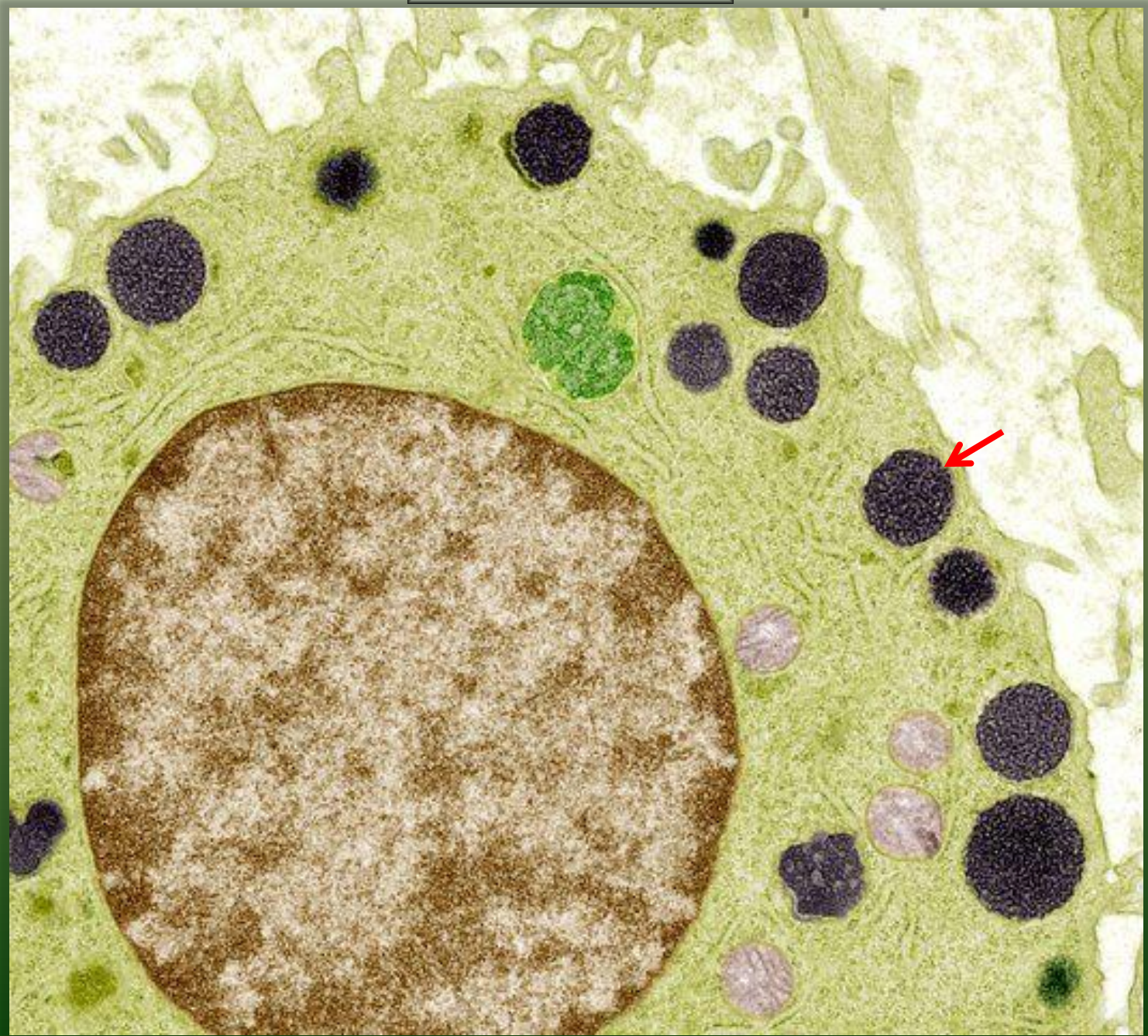


*Bazofil (TEM)*



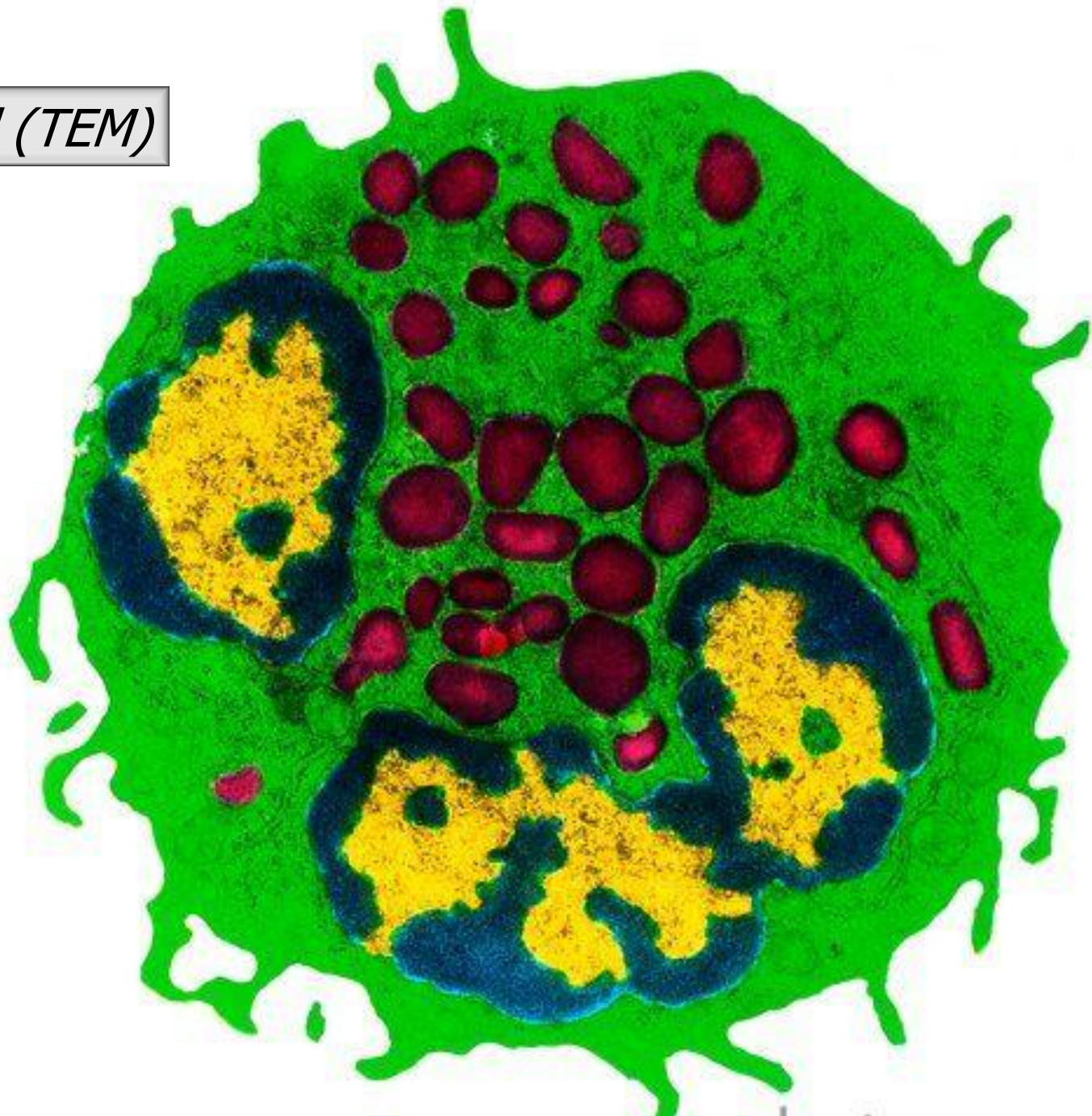


*Bazofil (TEM)*

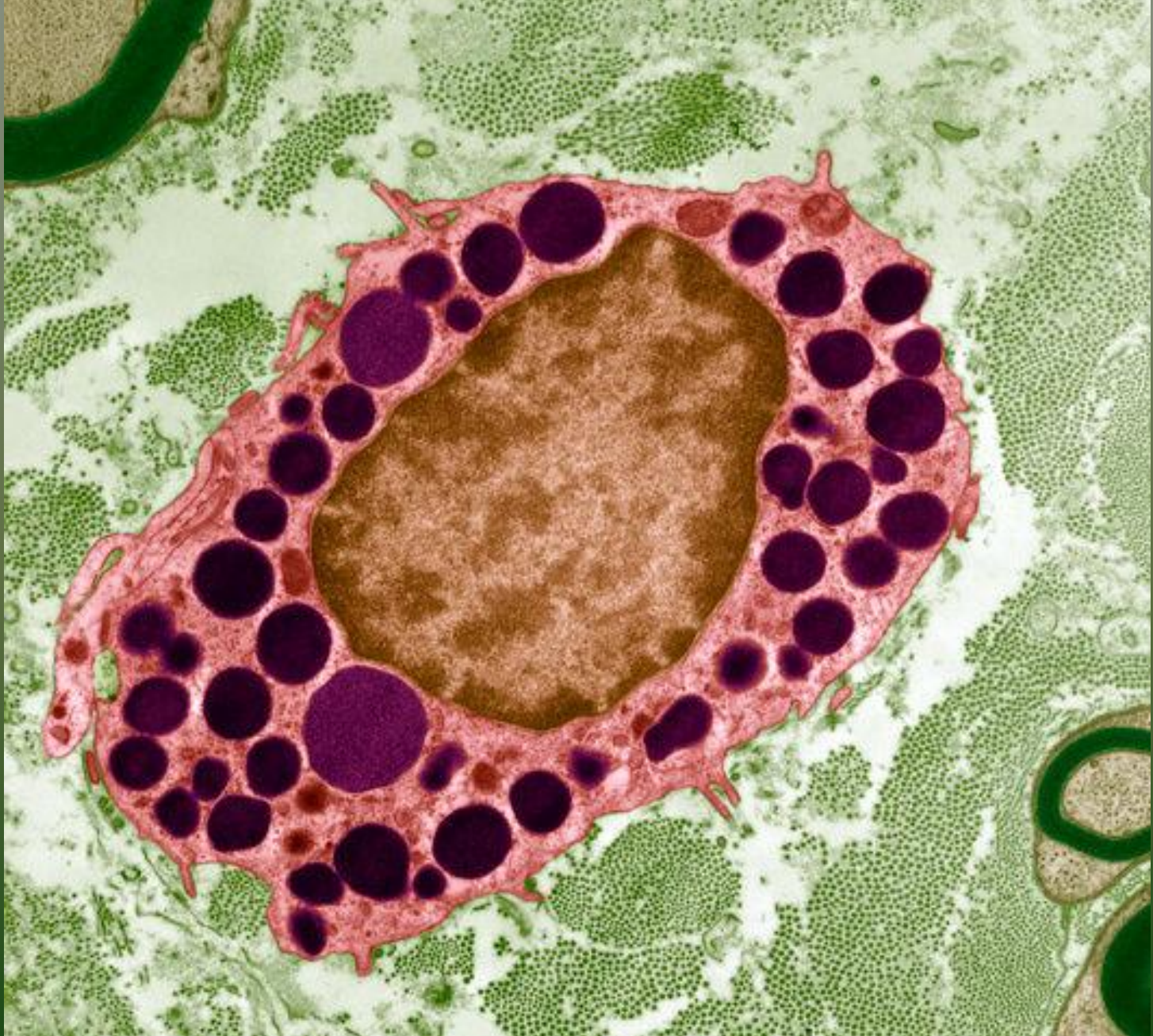




*Bazofil (TEM)*



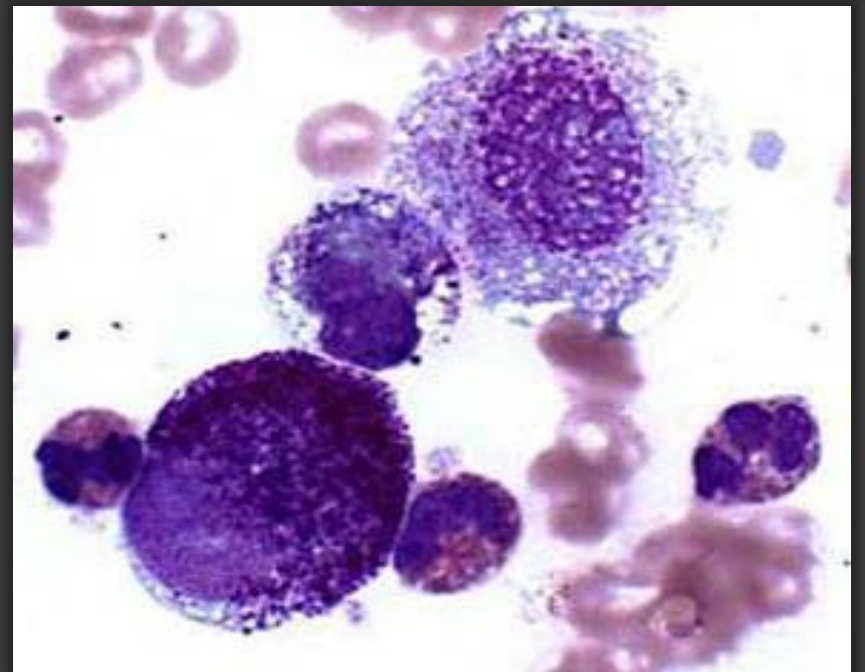
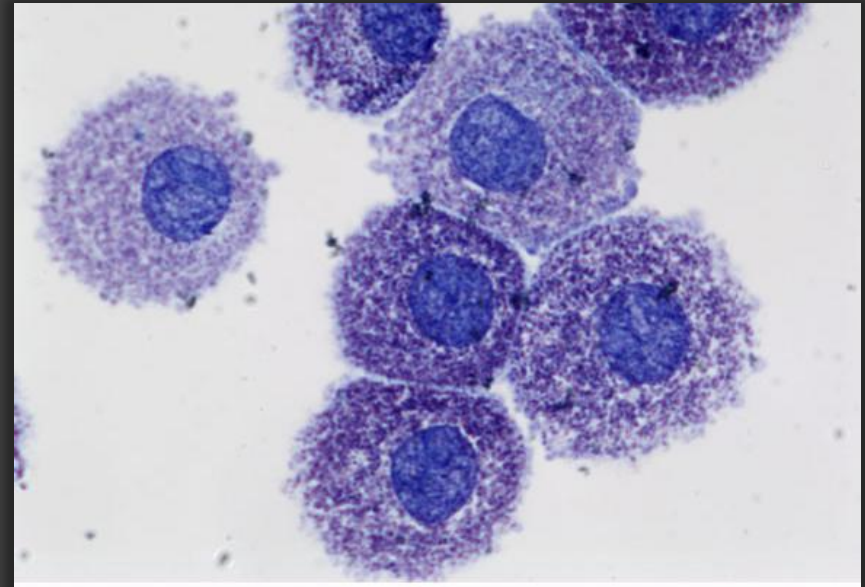
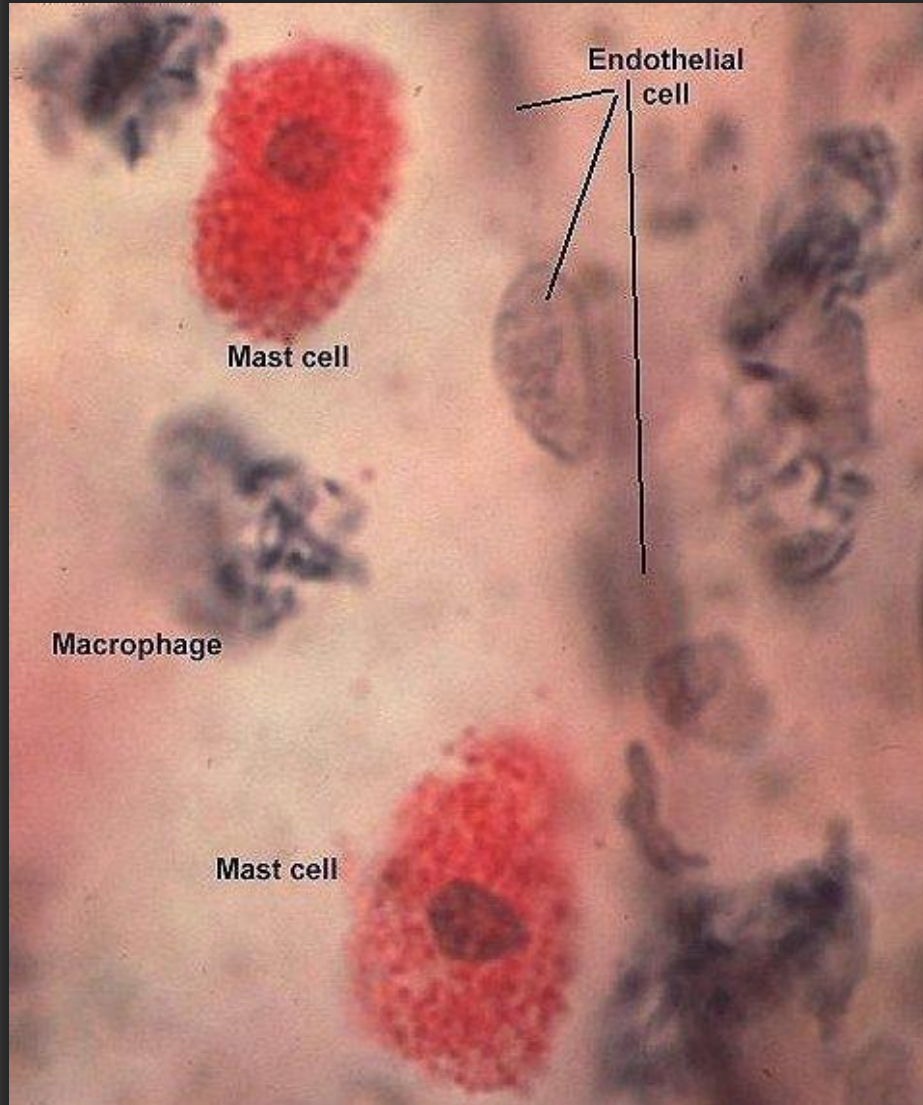




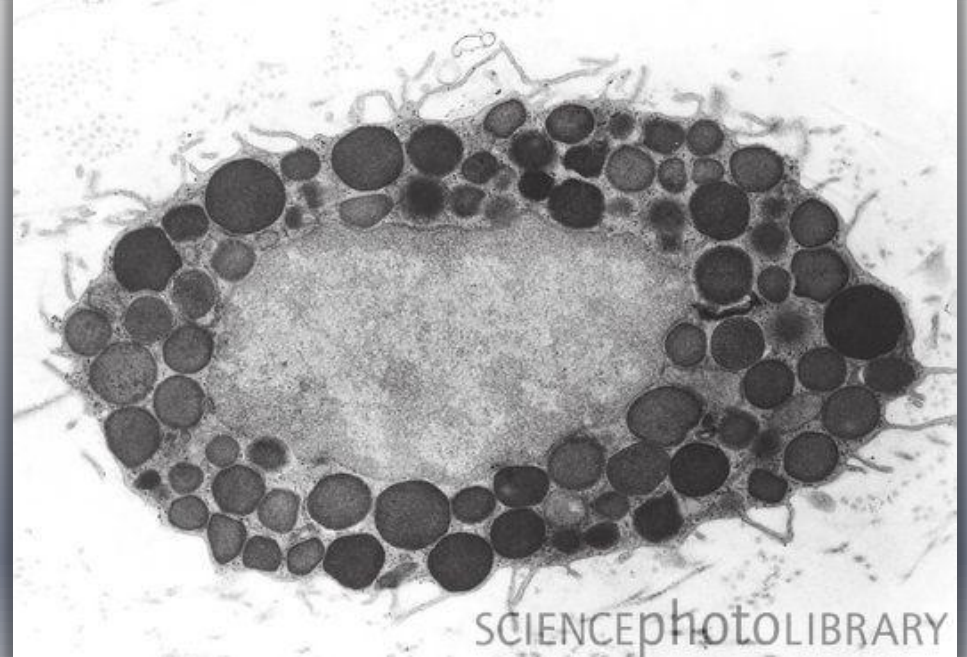
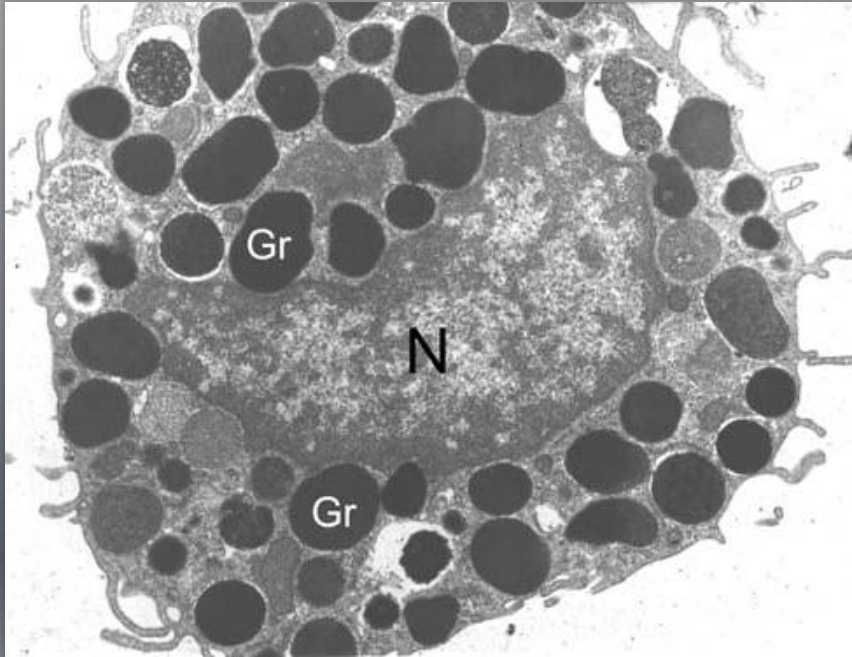
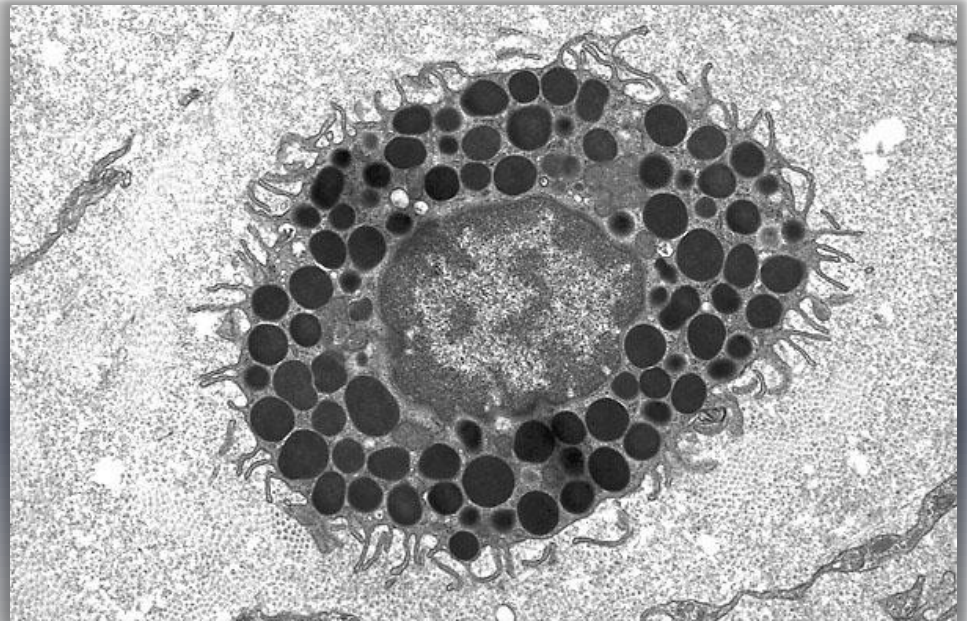
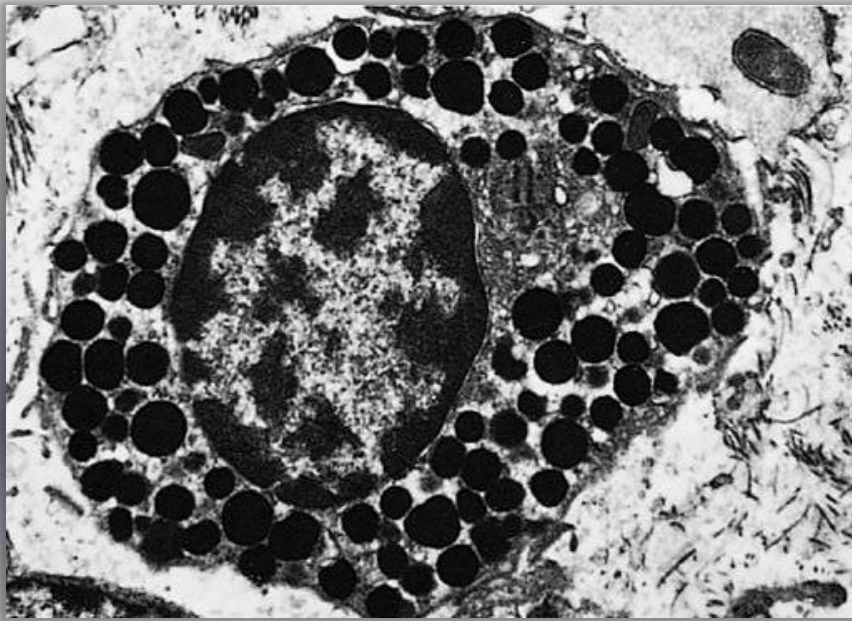
*Dokuda Bazofil (TEM)*



# Mast Hücreleri





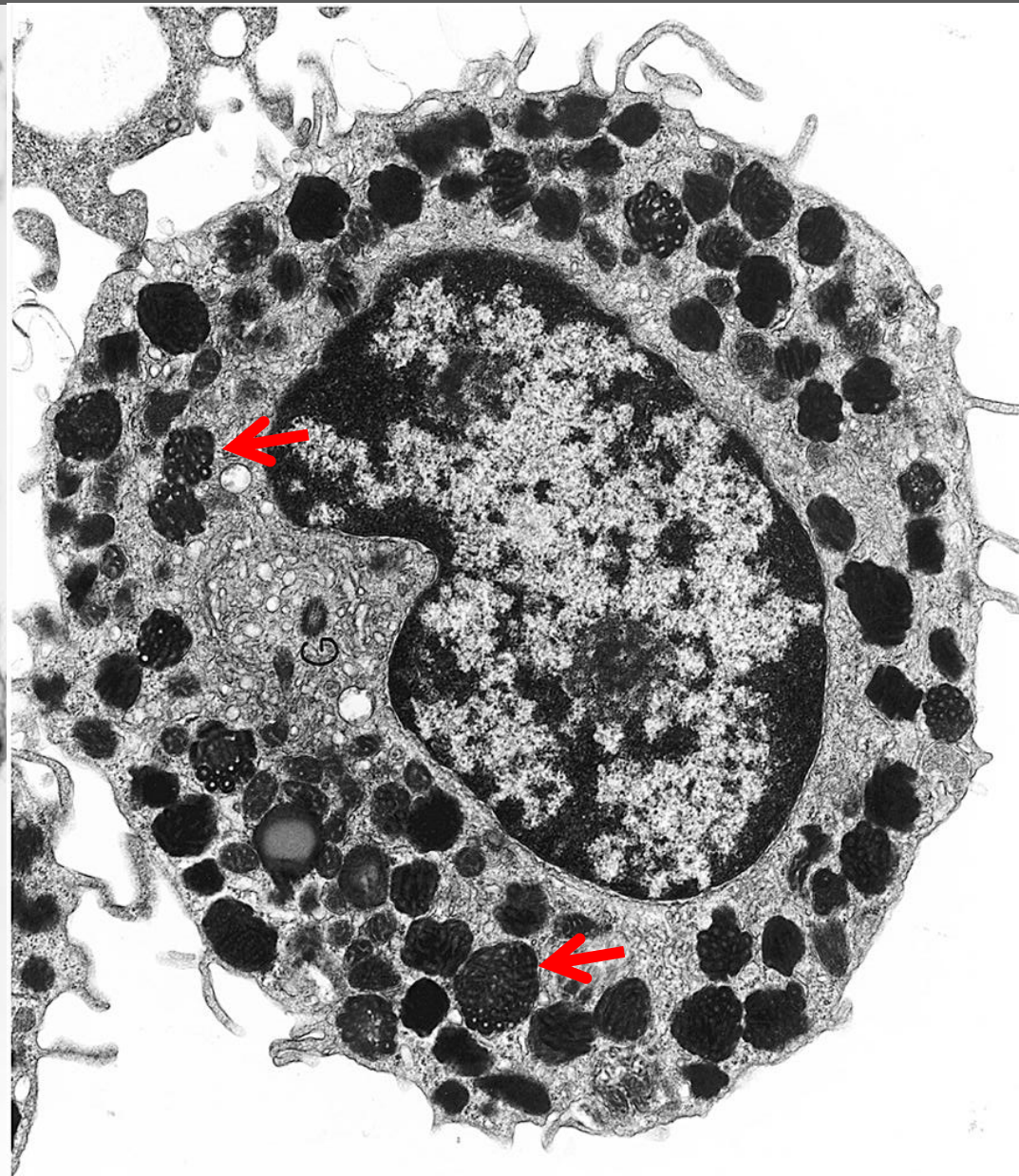
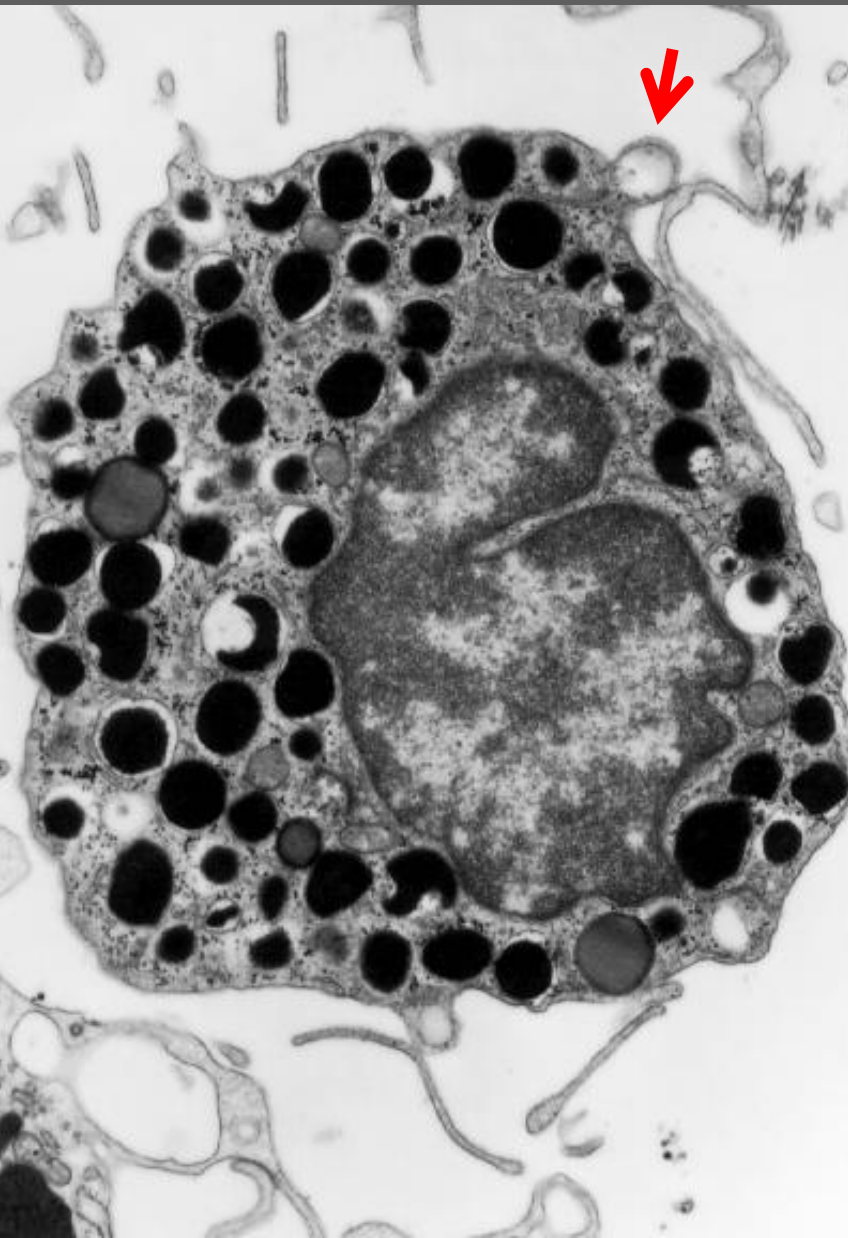


SCIENCEPHOTOLIBRARY

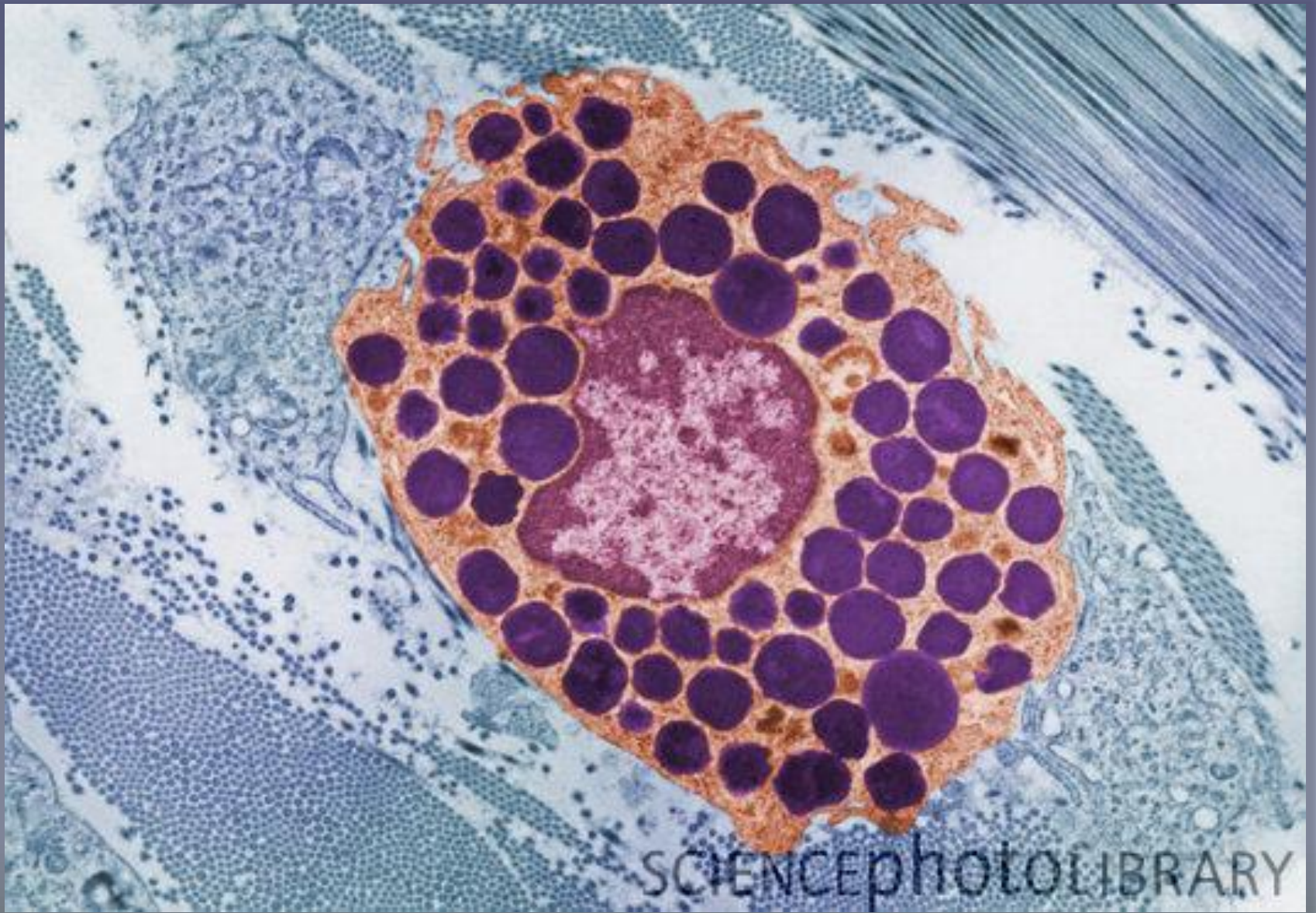Mast Hücresi (TEM)



# Mast Hücresi (TEM)

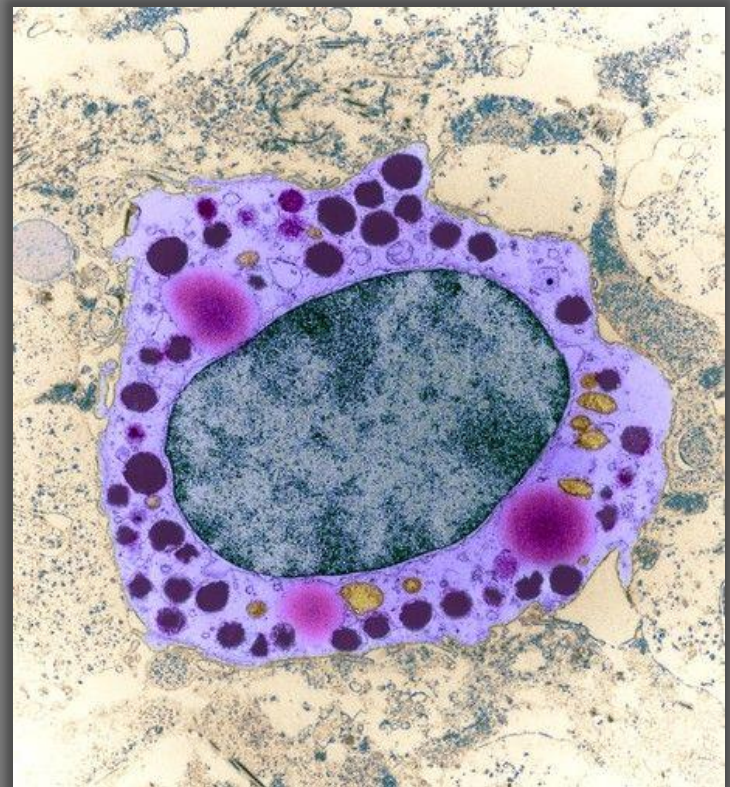
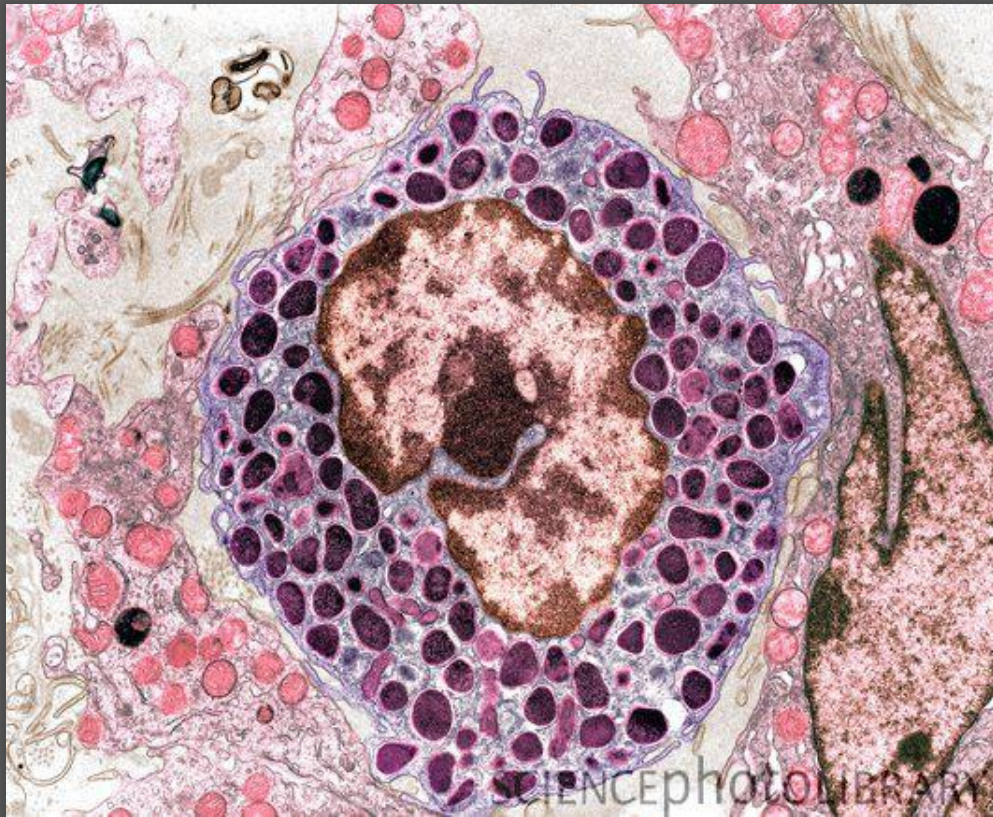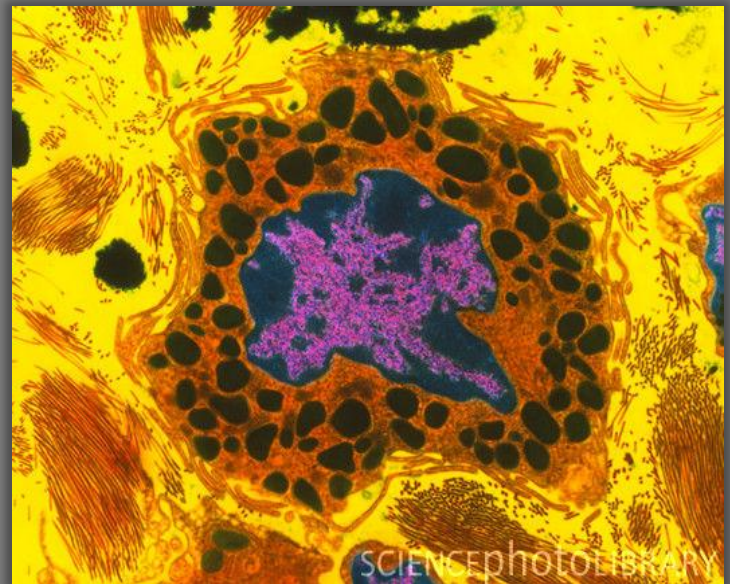
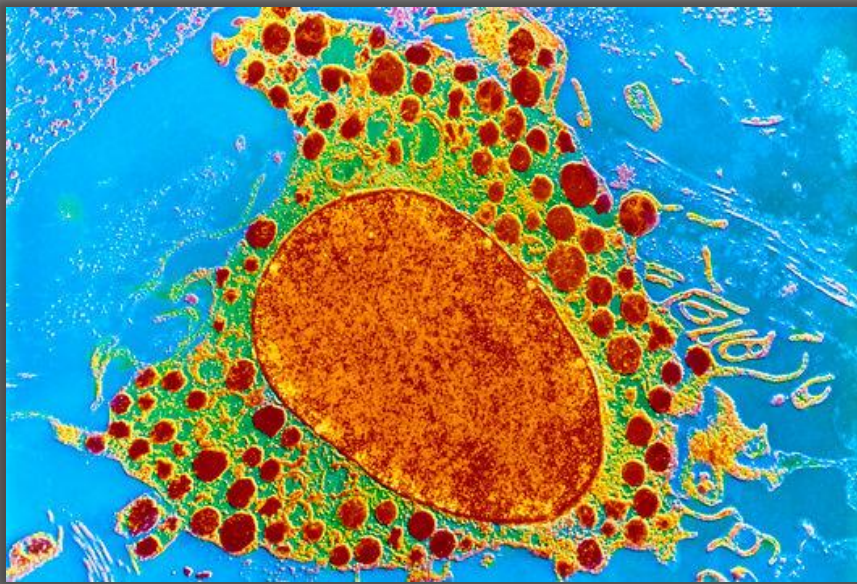




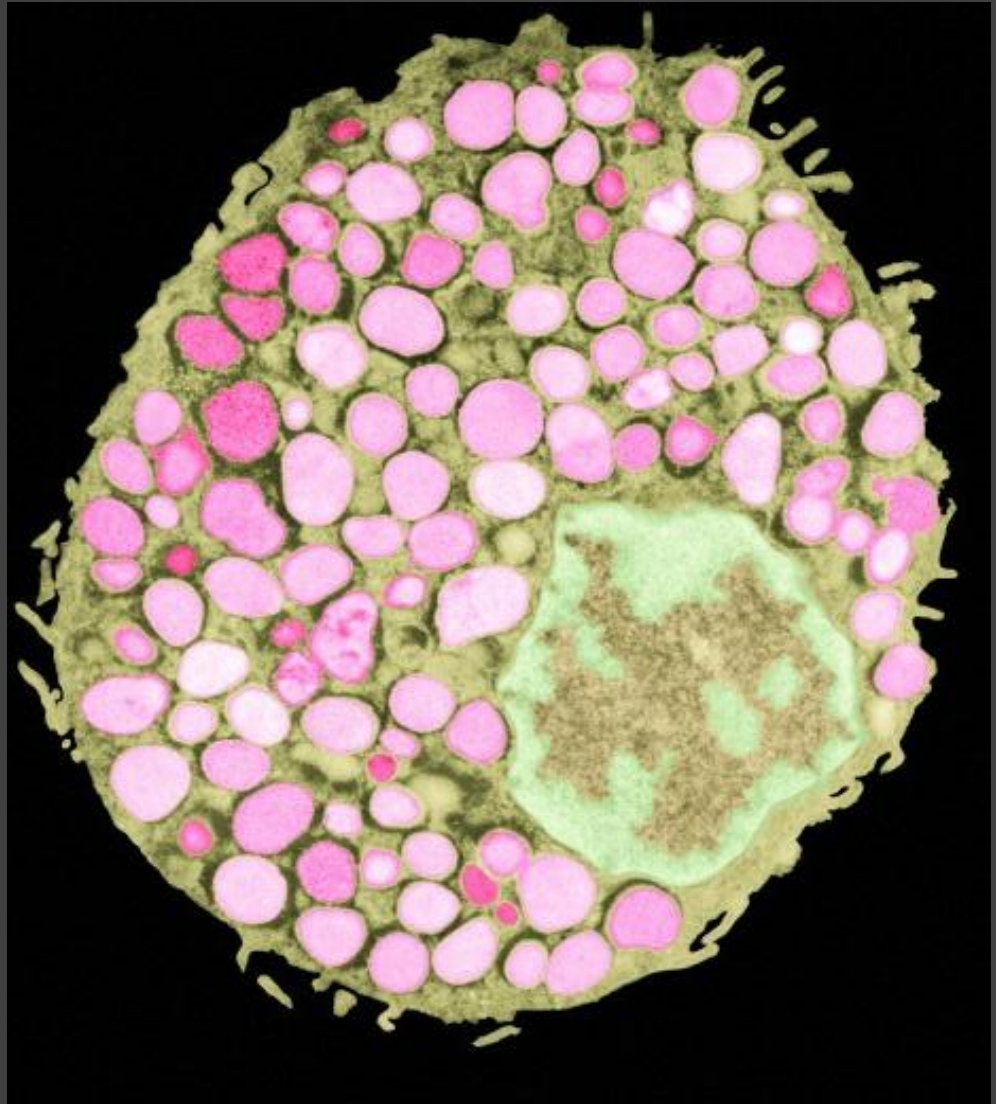
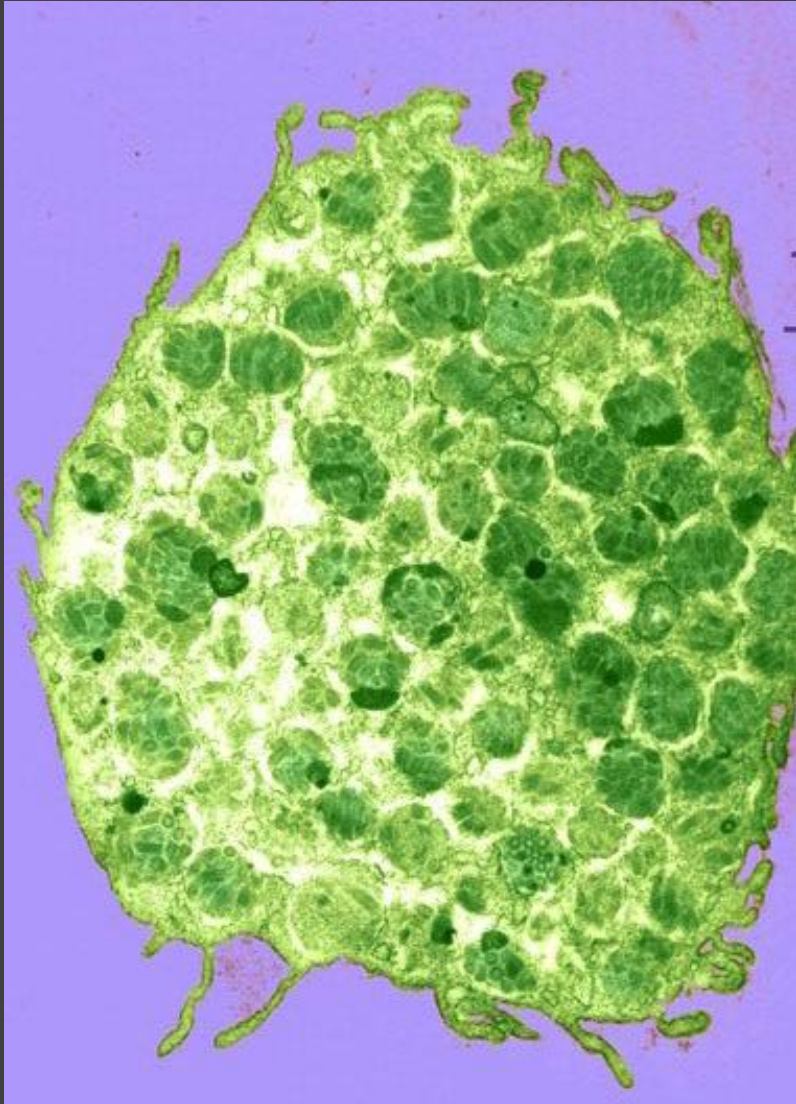


Doku içinde Mast Hücresi (TEM)





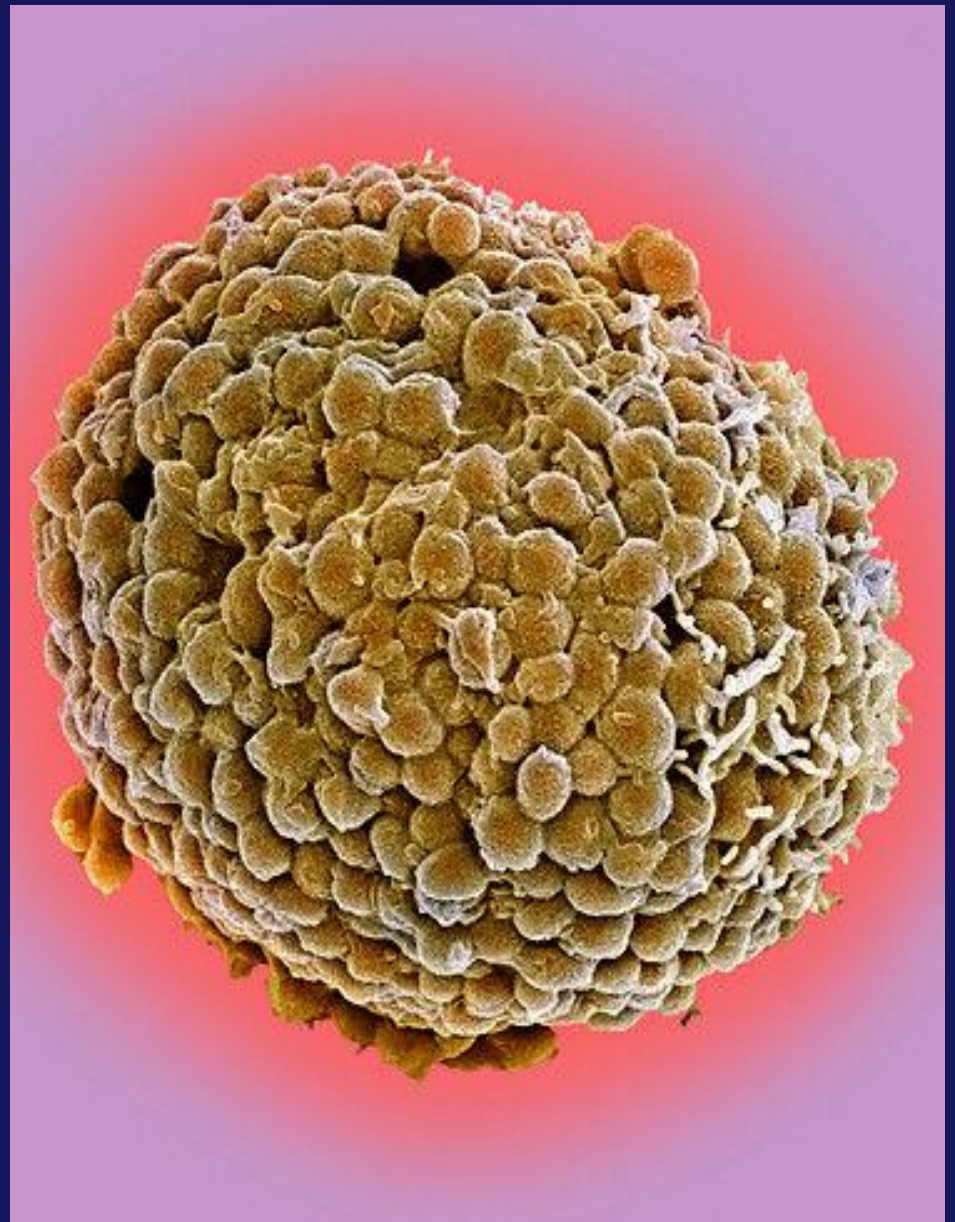
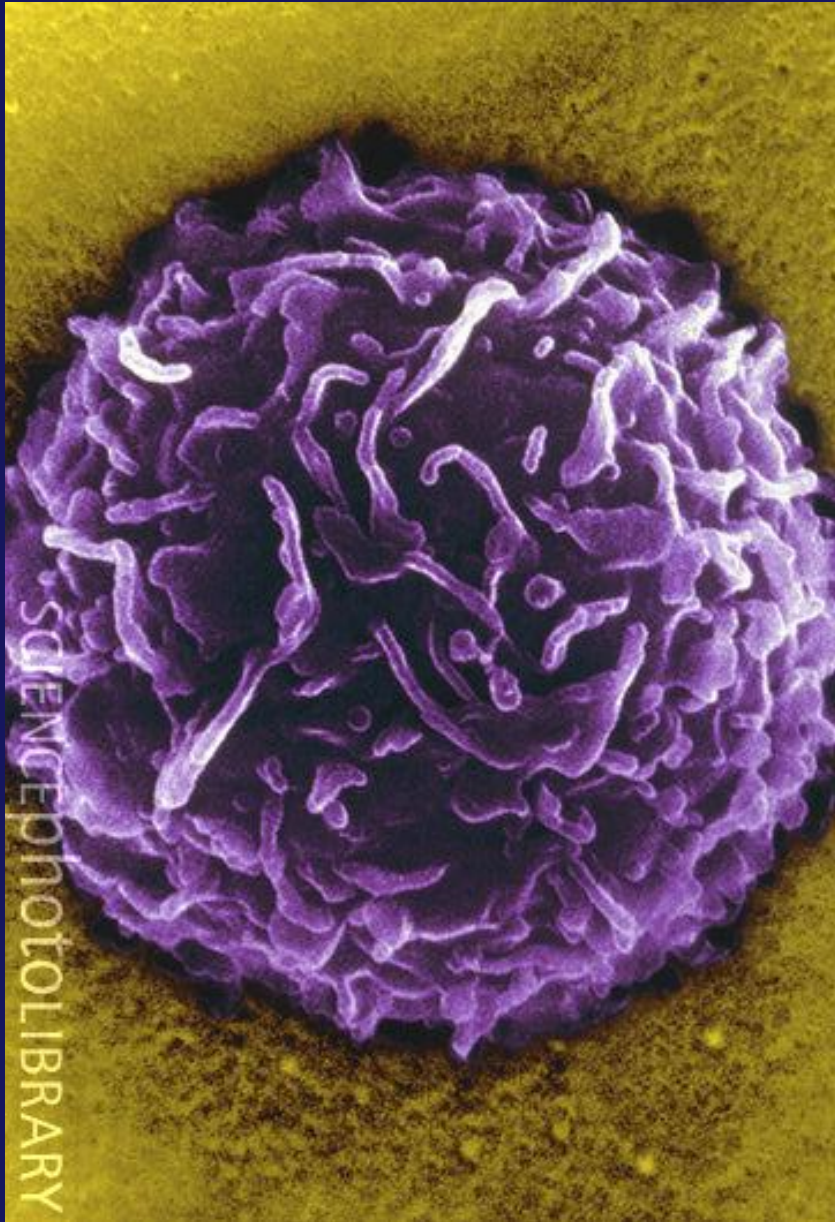



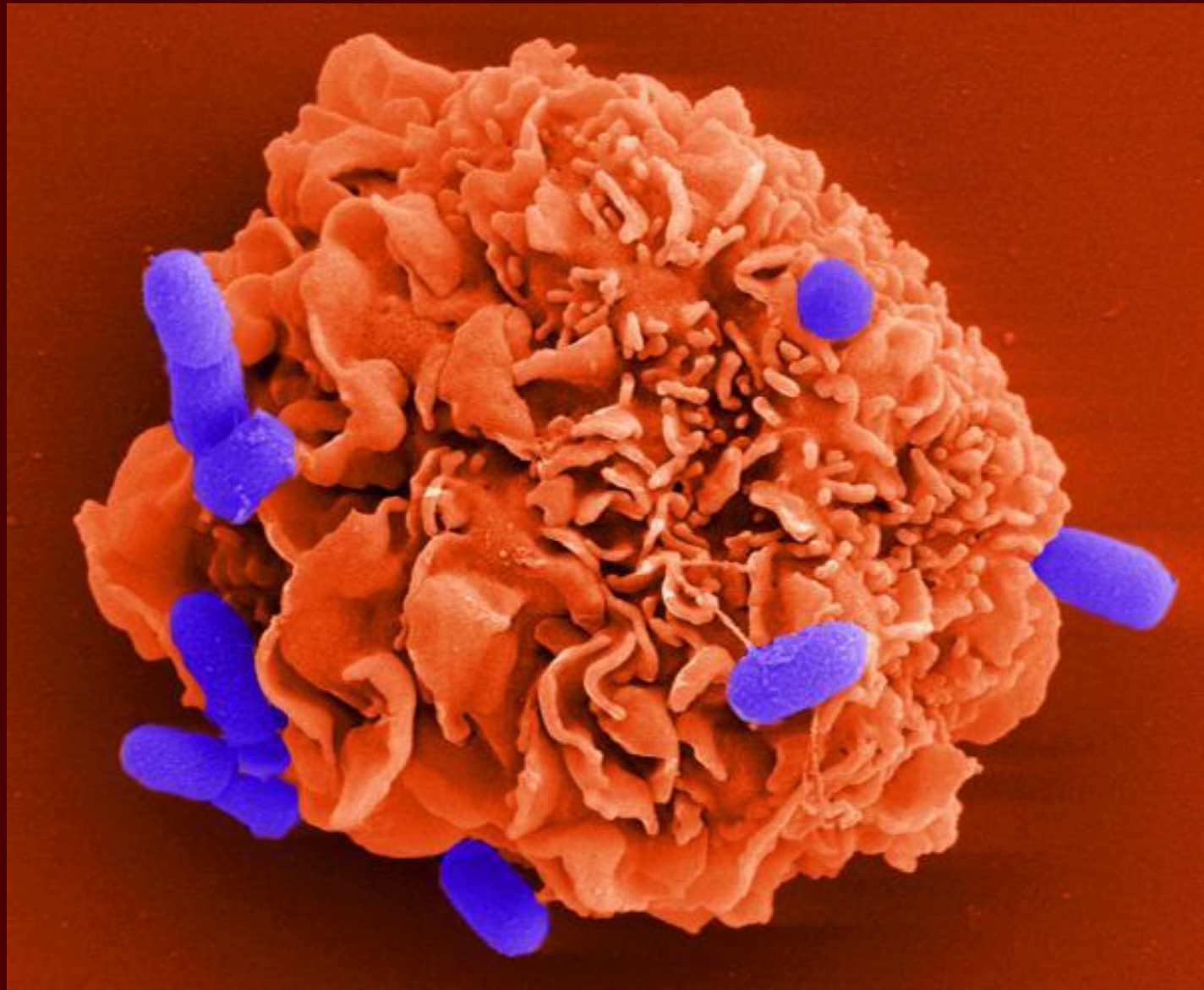
Mast Hücresi (TEM)



# Mast Hücresi (SEM)



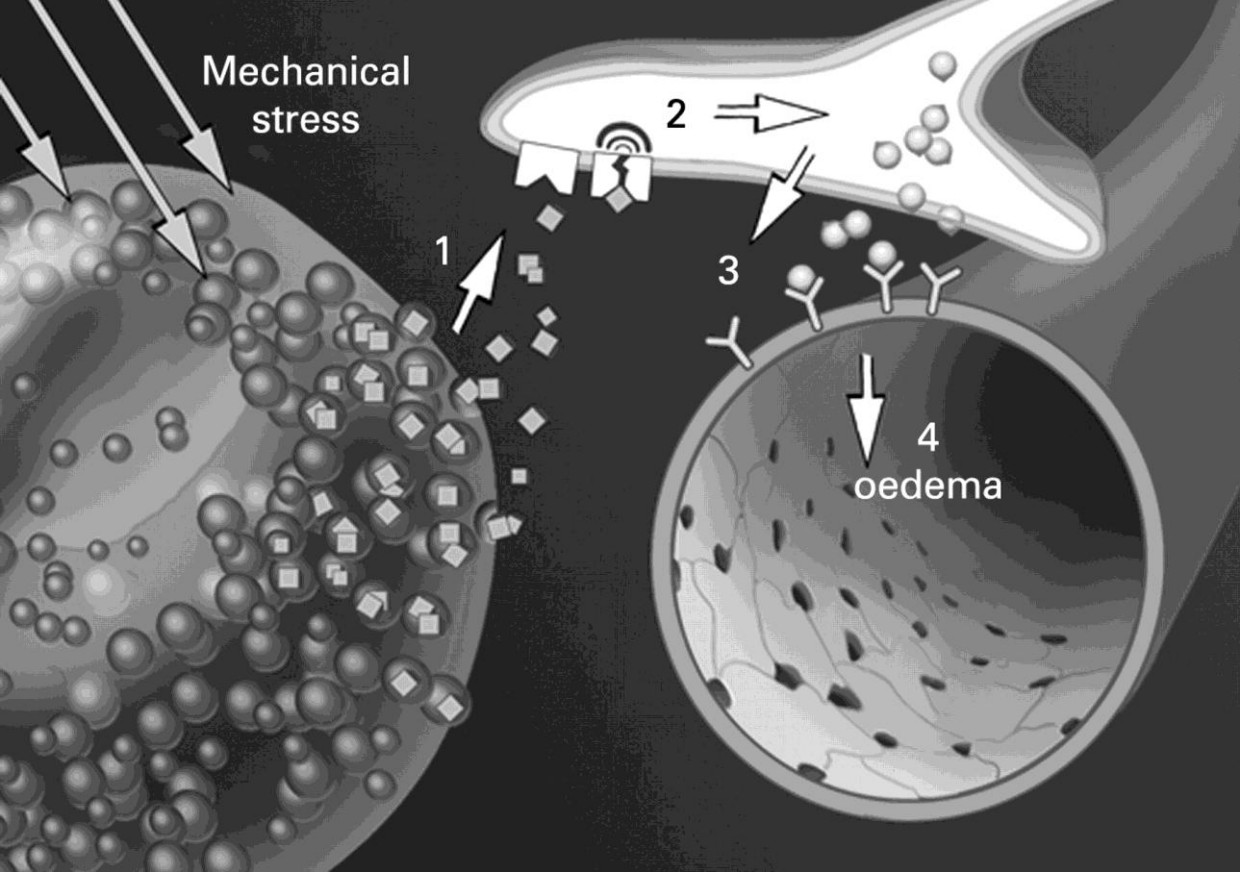
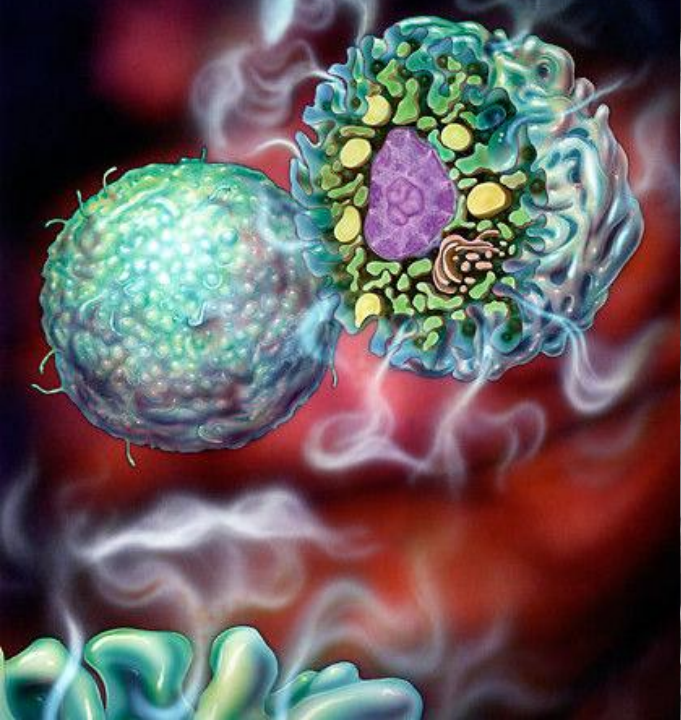
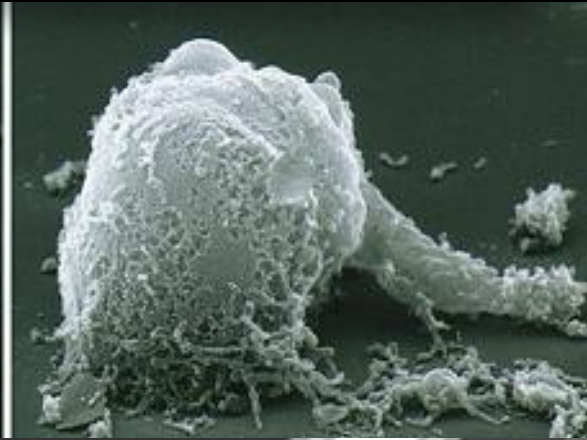
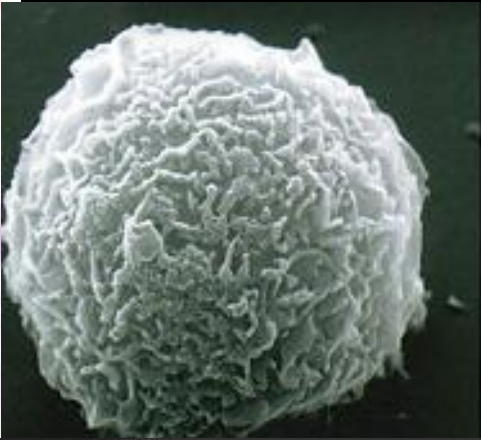
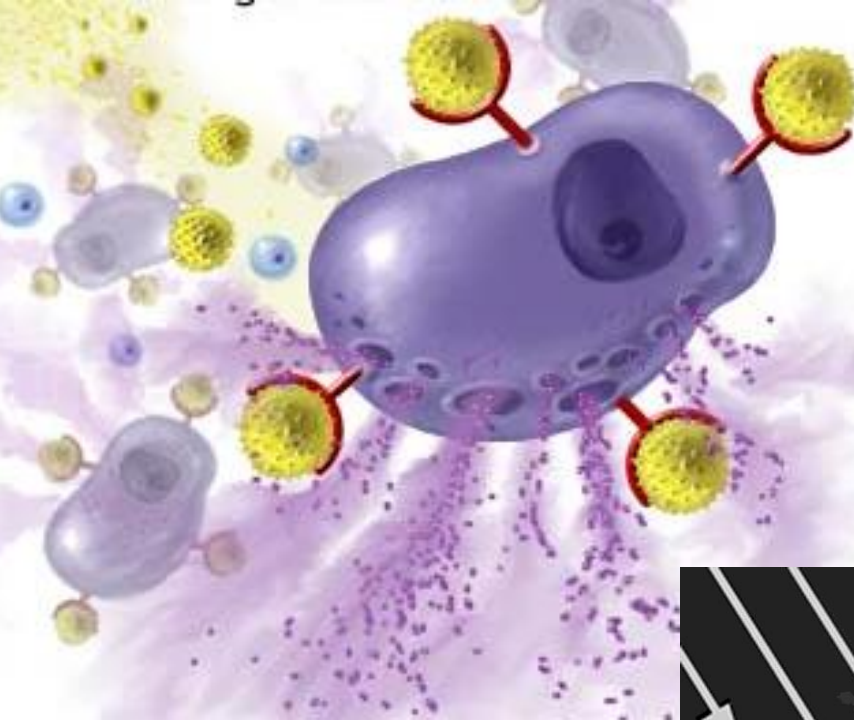



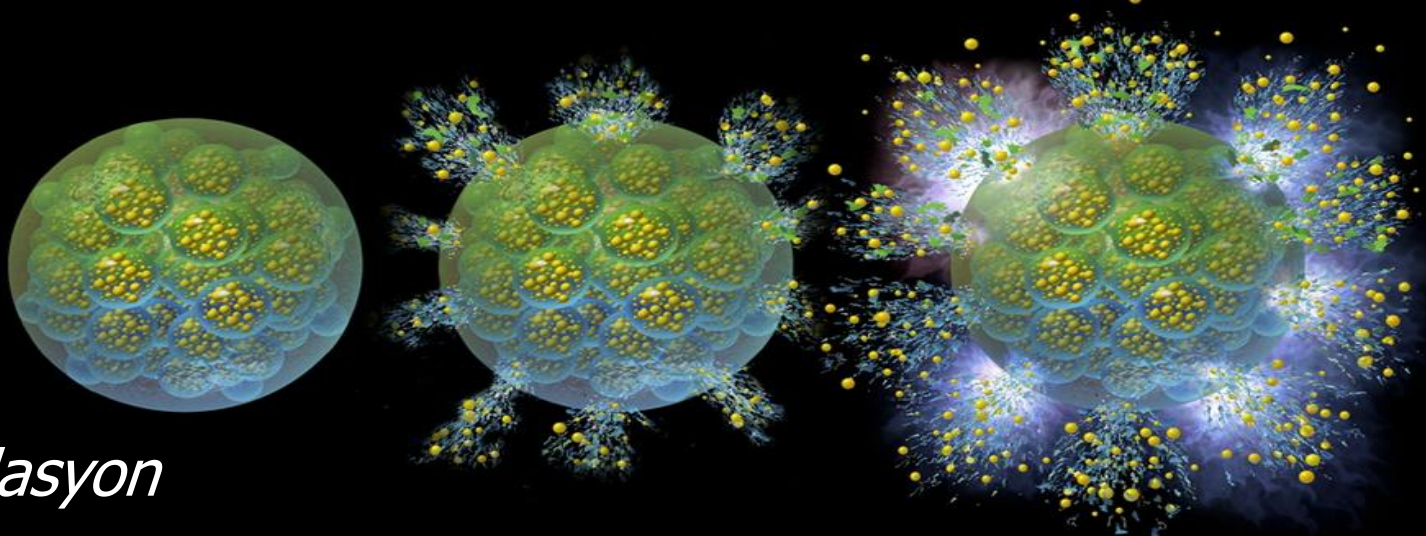
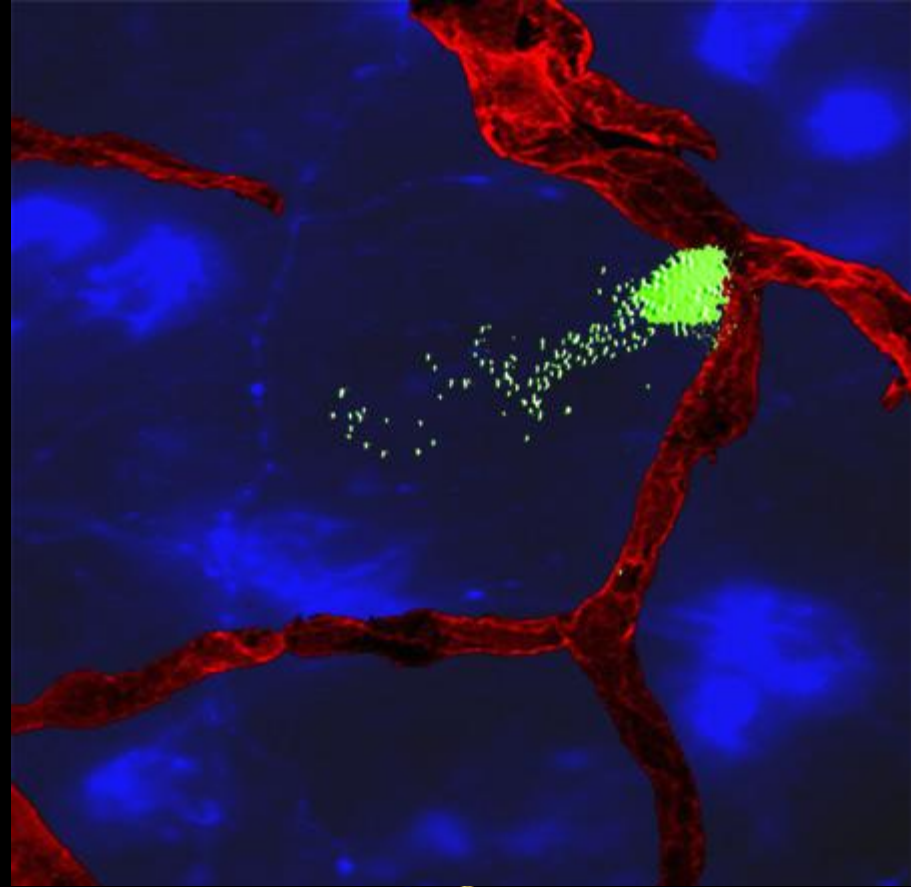
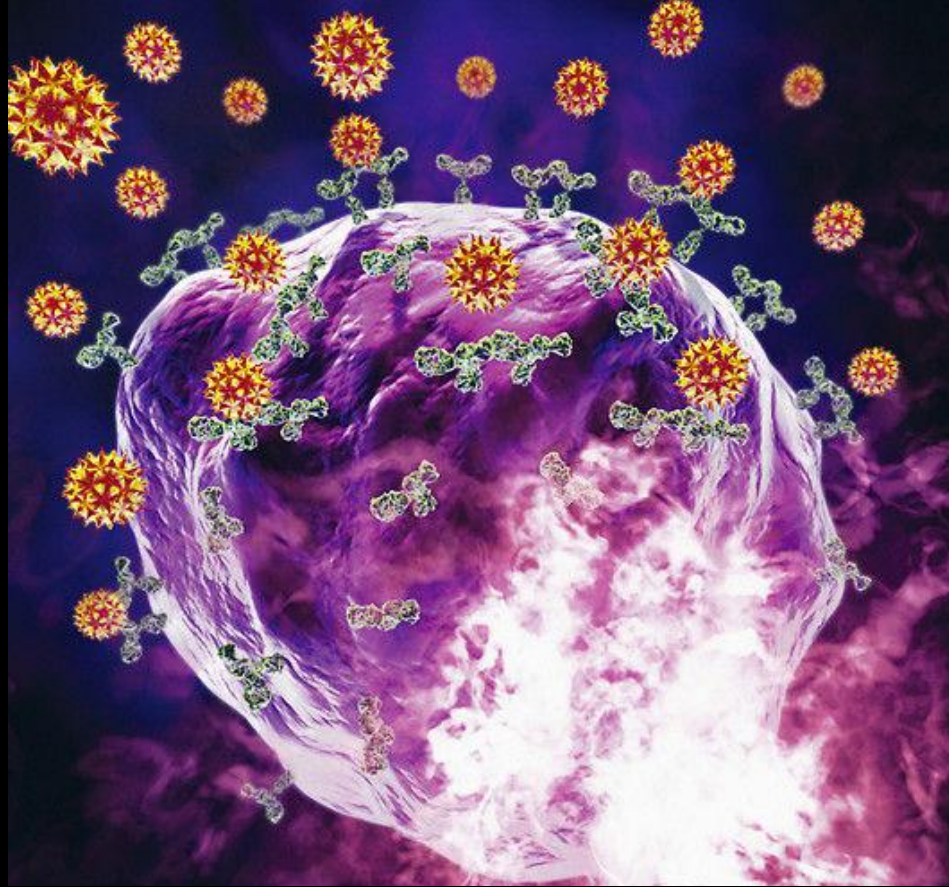
Mast Hücresi ve bakteriler (SEM)



# Mast Hücresi ve Bazofil: Yangı



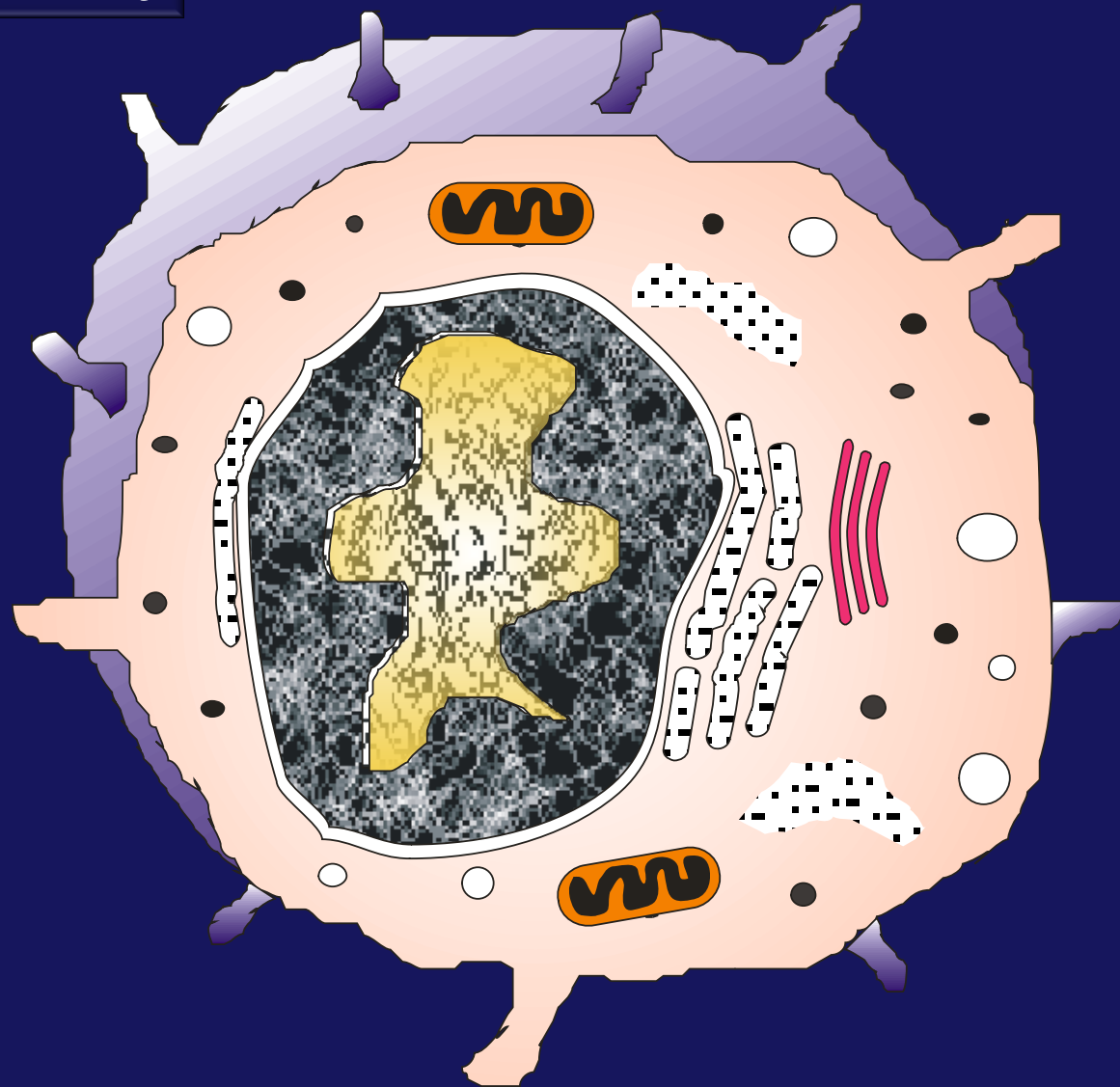




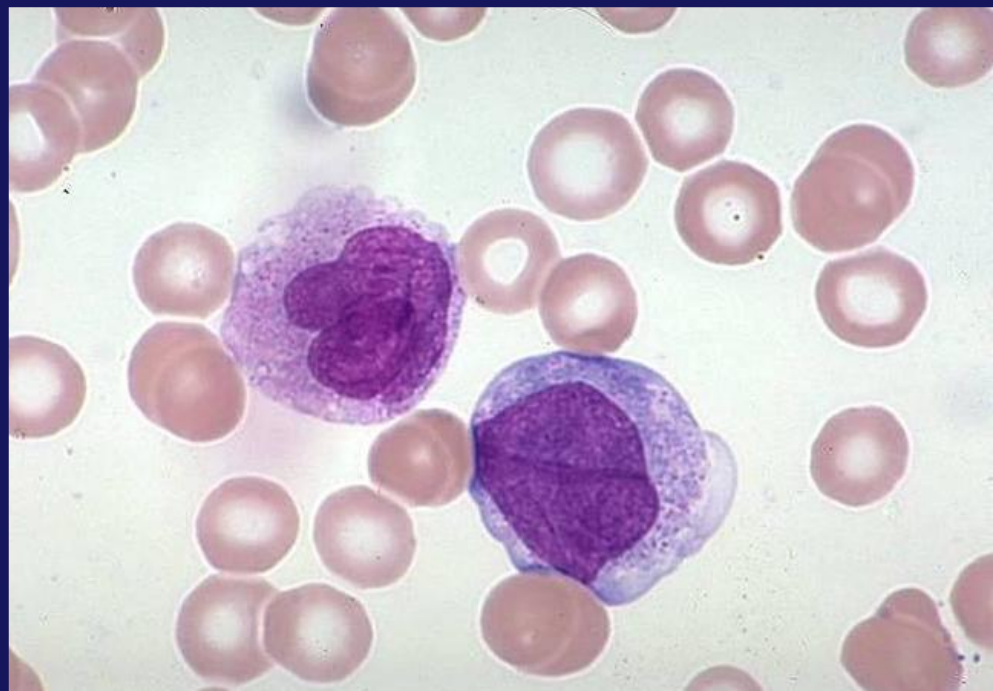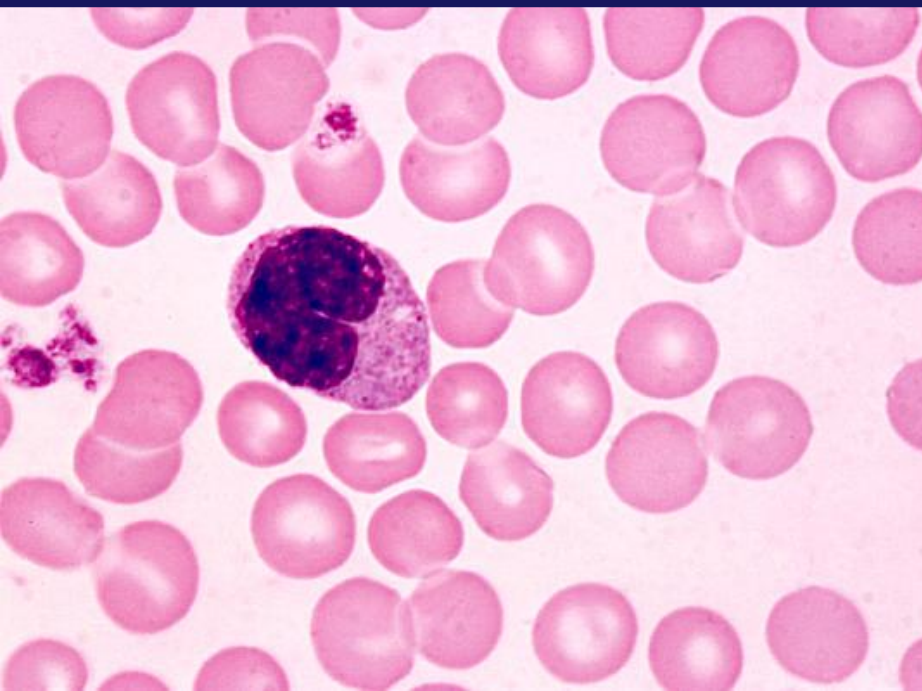
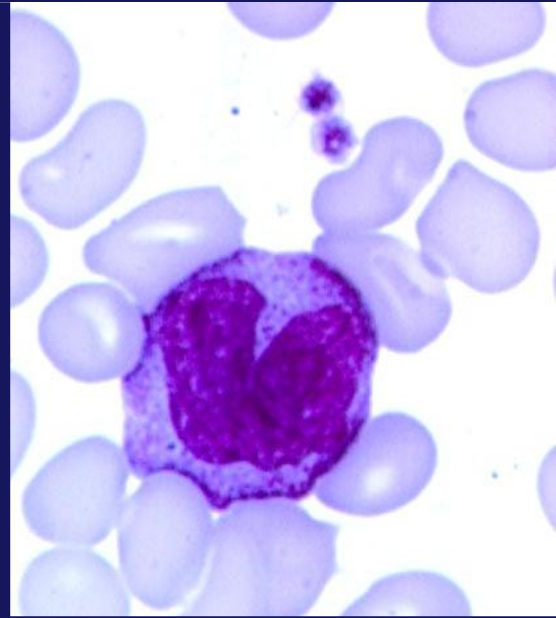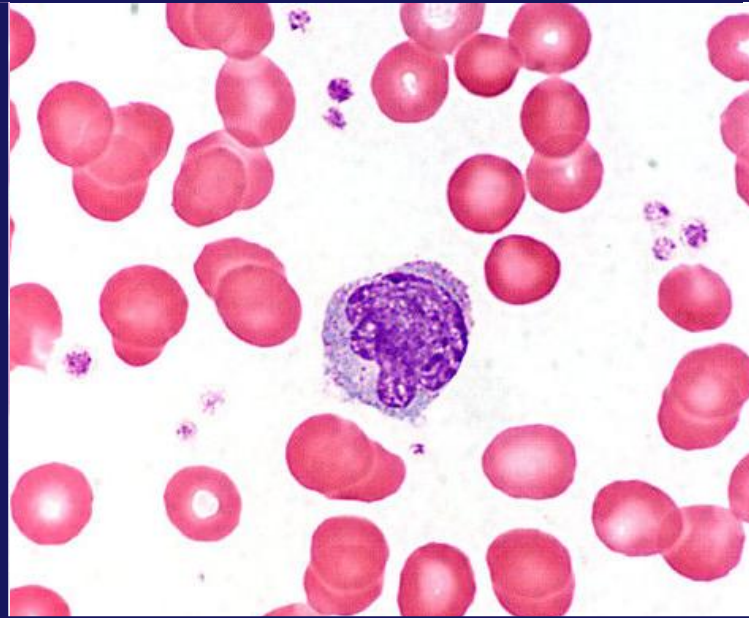
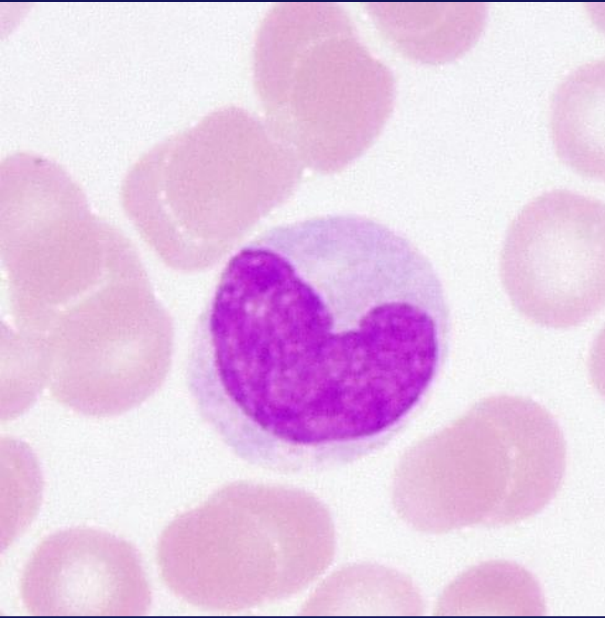*Degranülasyon*



# Monosit/Makrofaj

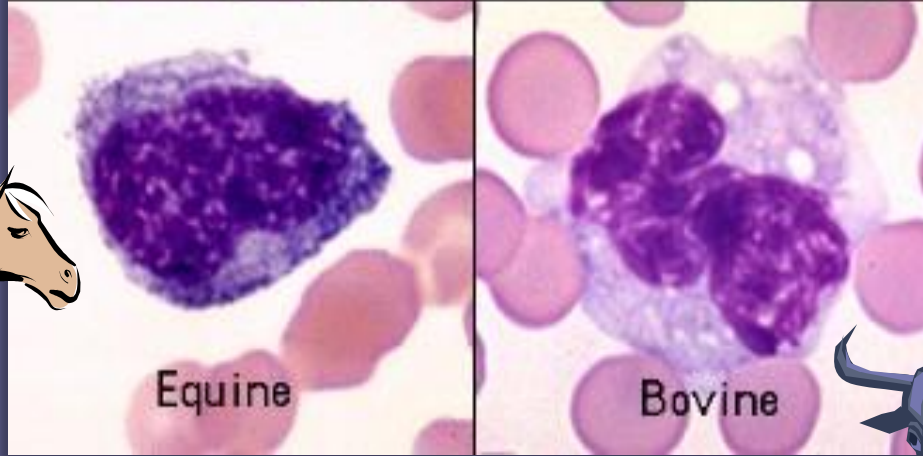
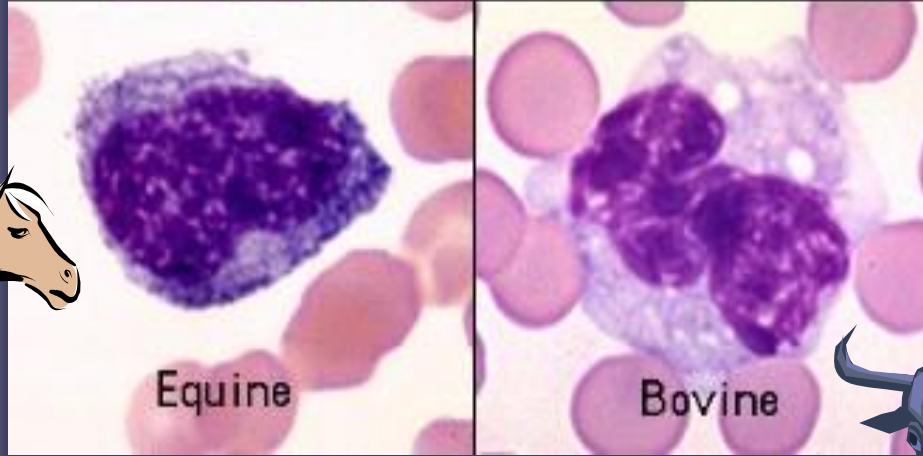

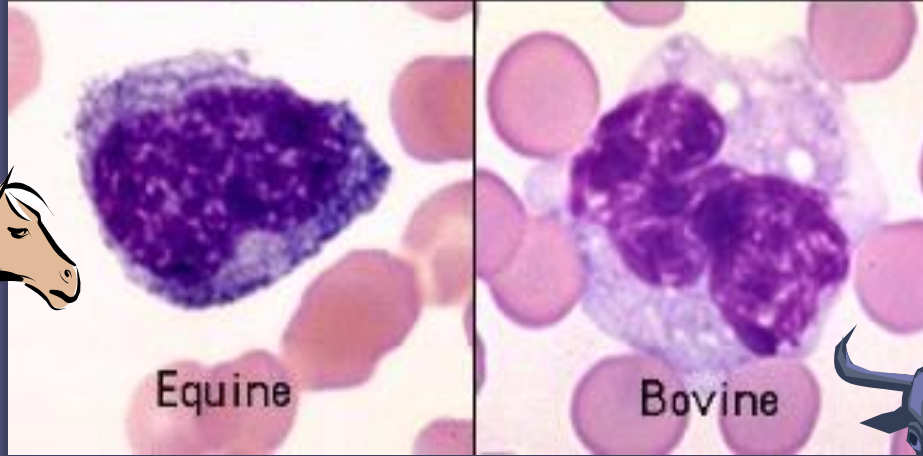
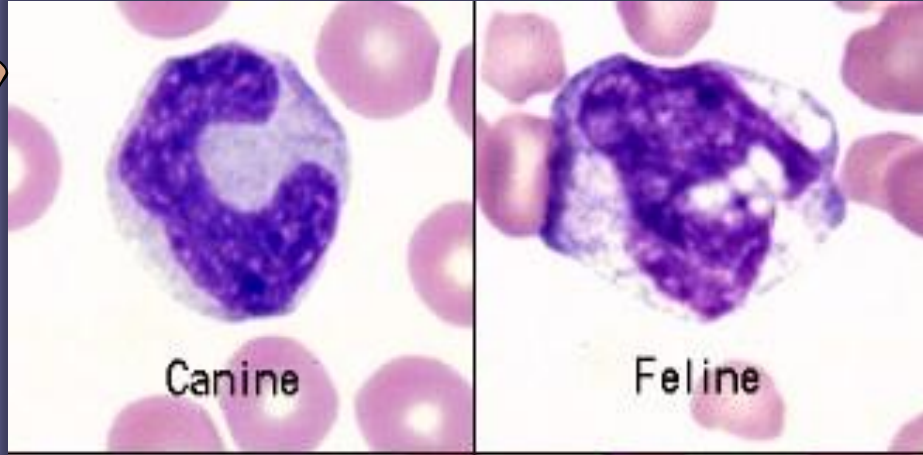


# Monosit

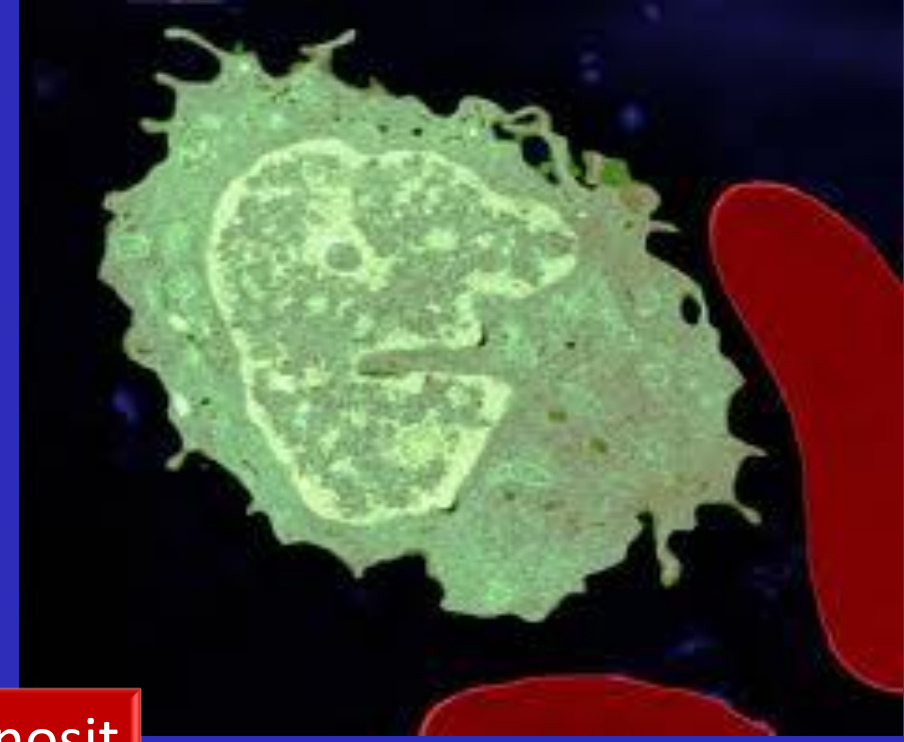
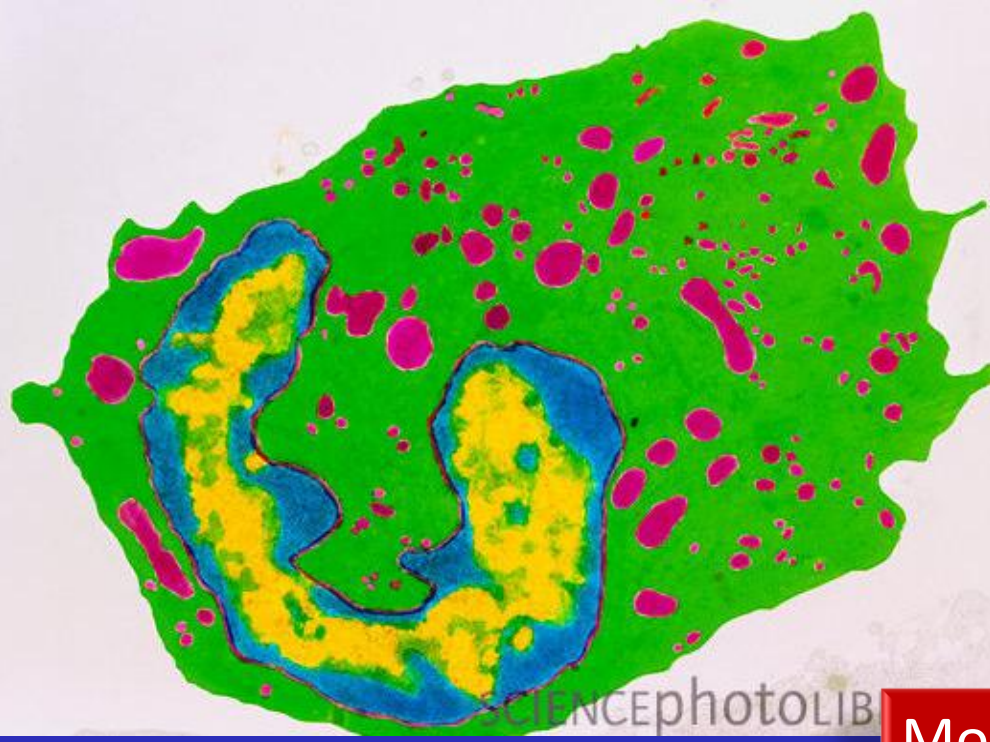




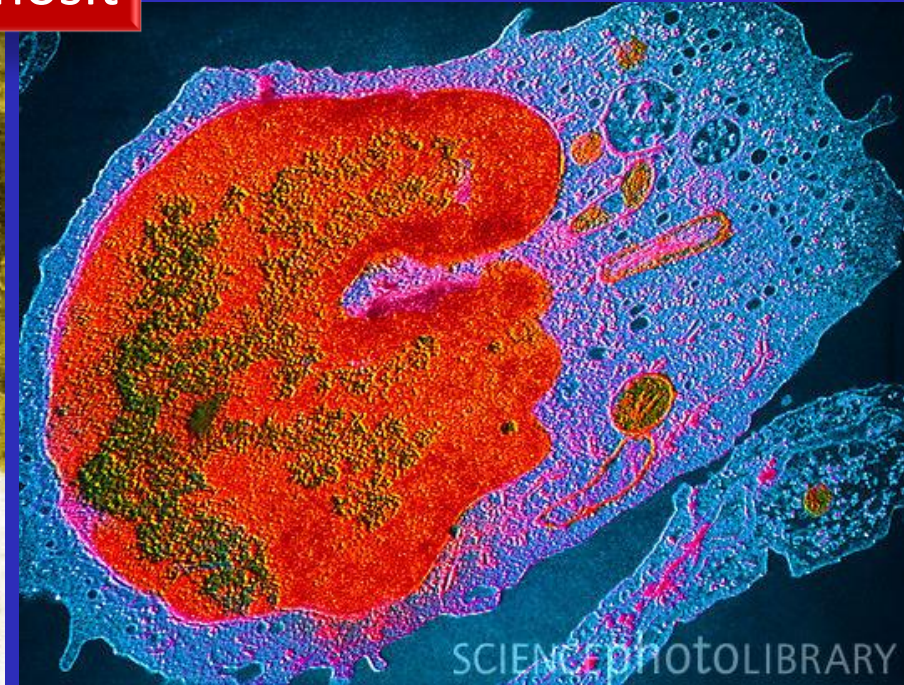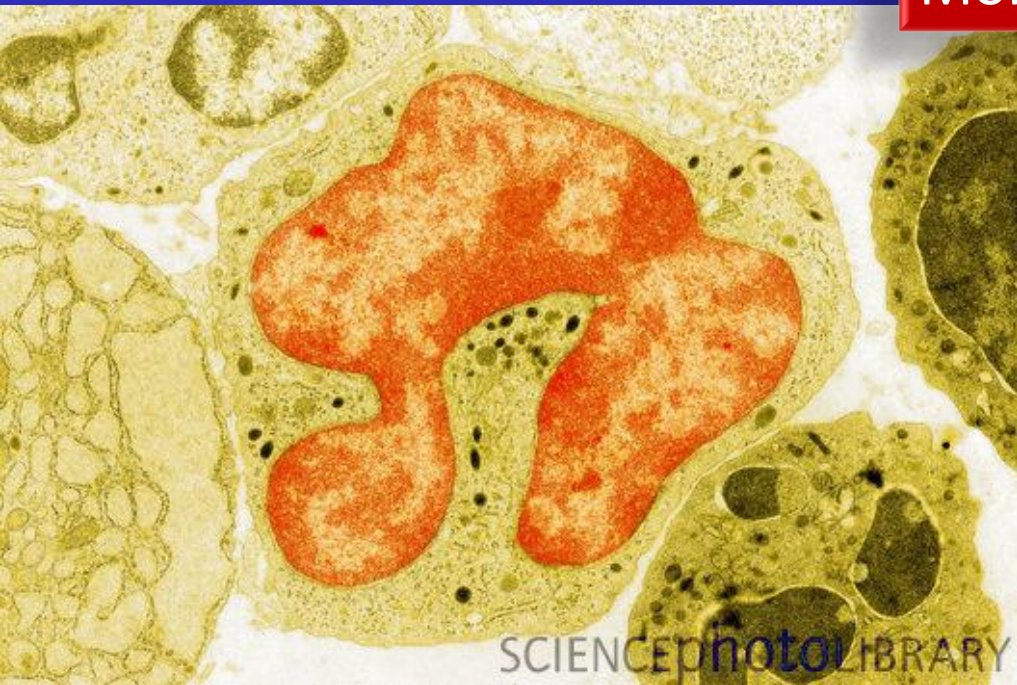
# Hayvan Türlerinde Monositler



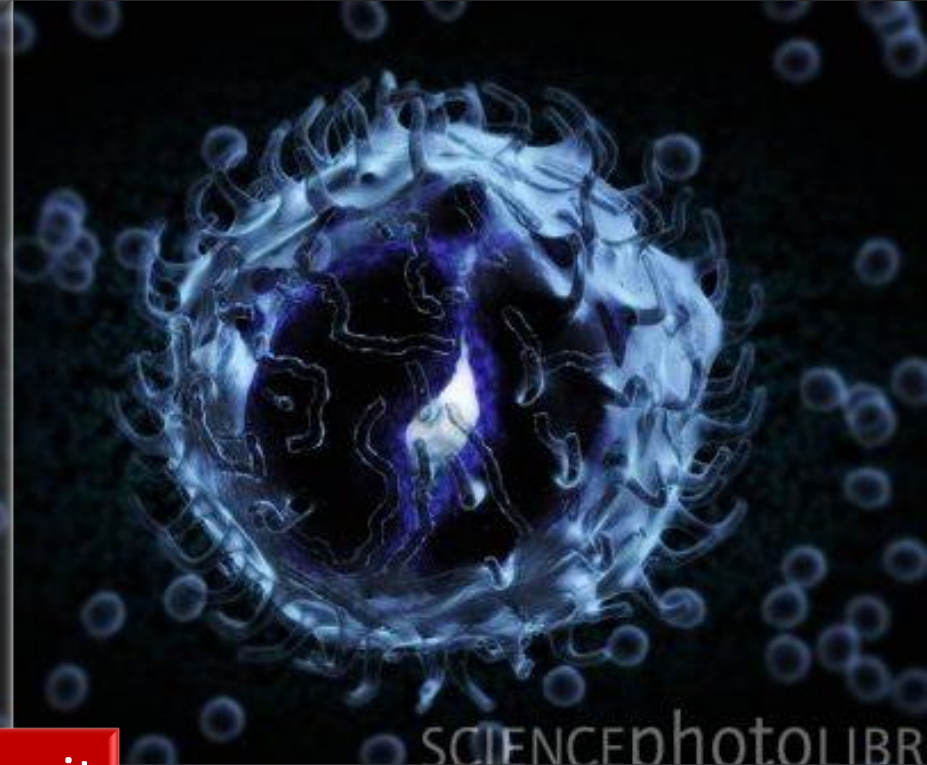
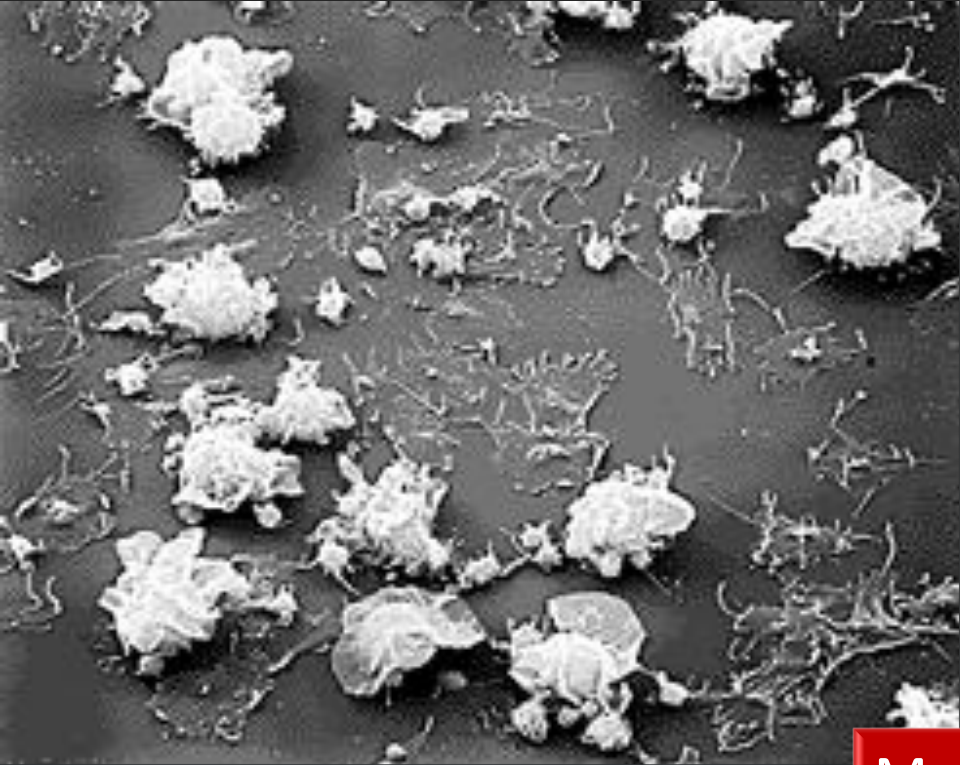




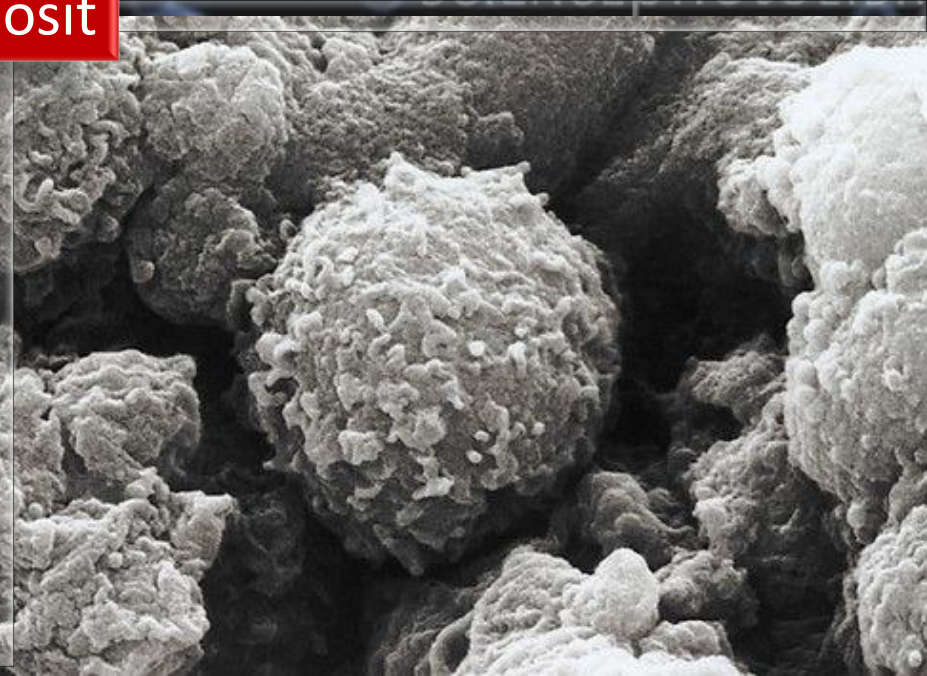
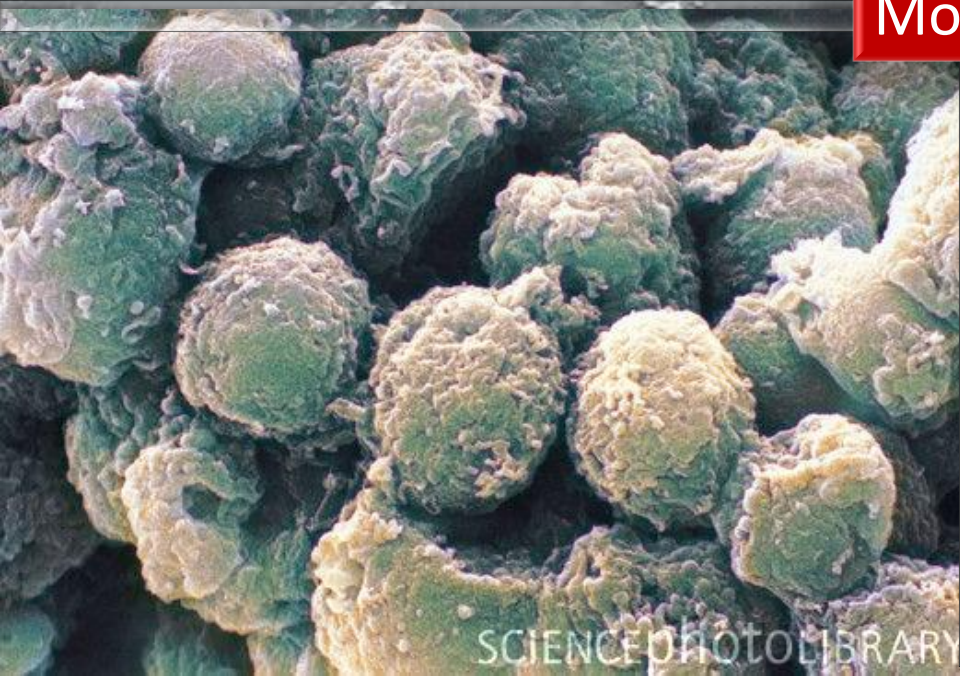
Monosit



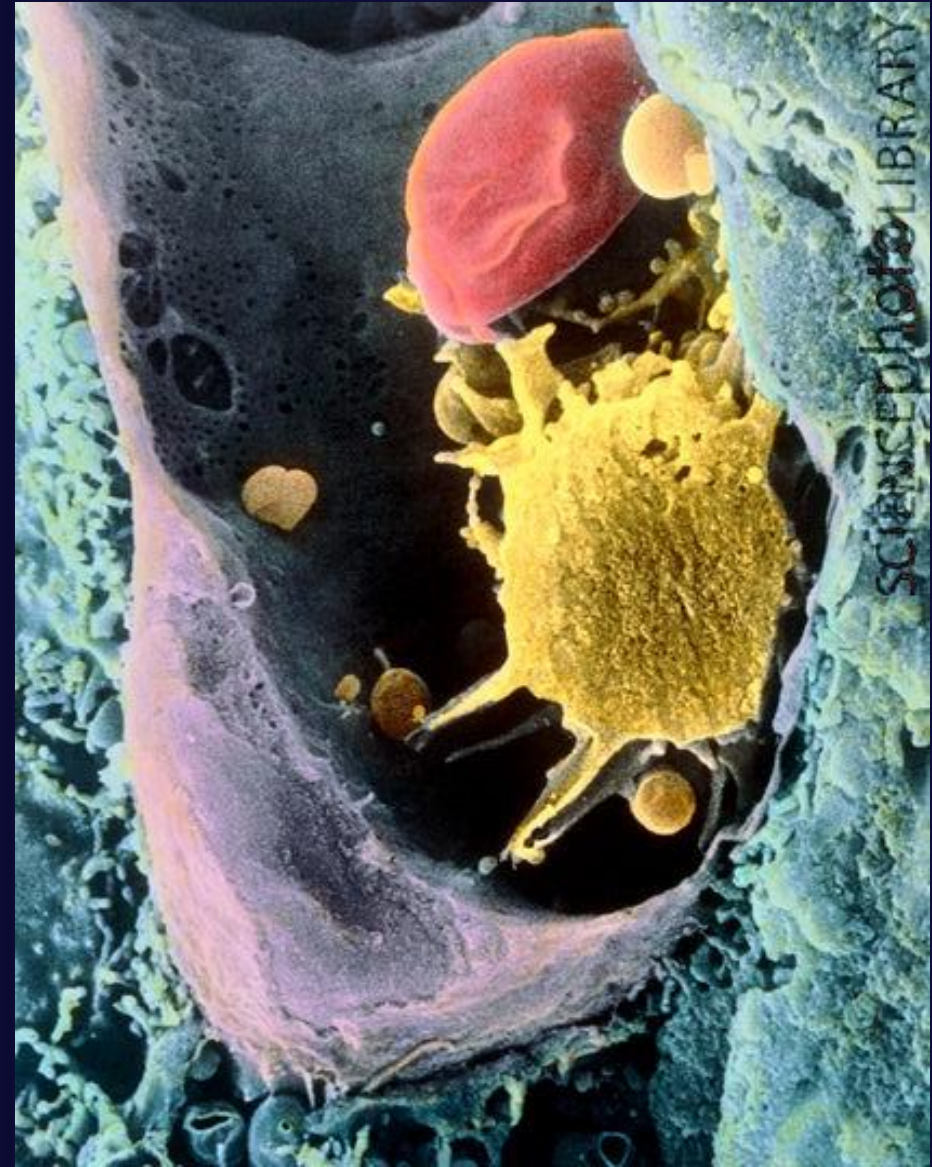
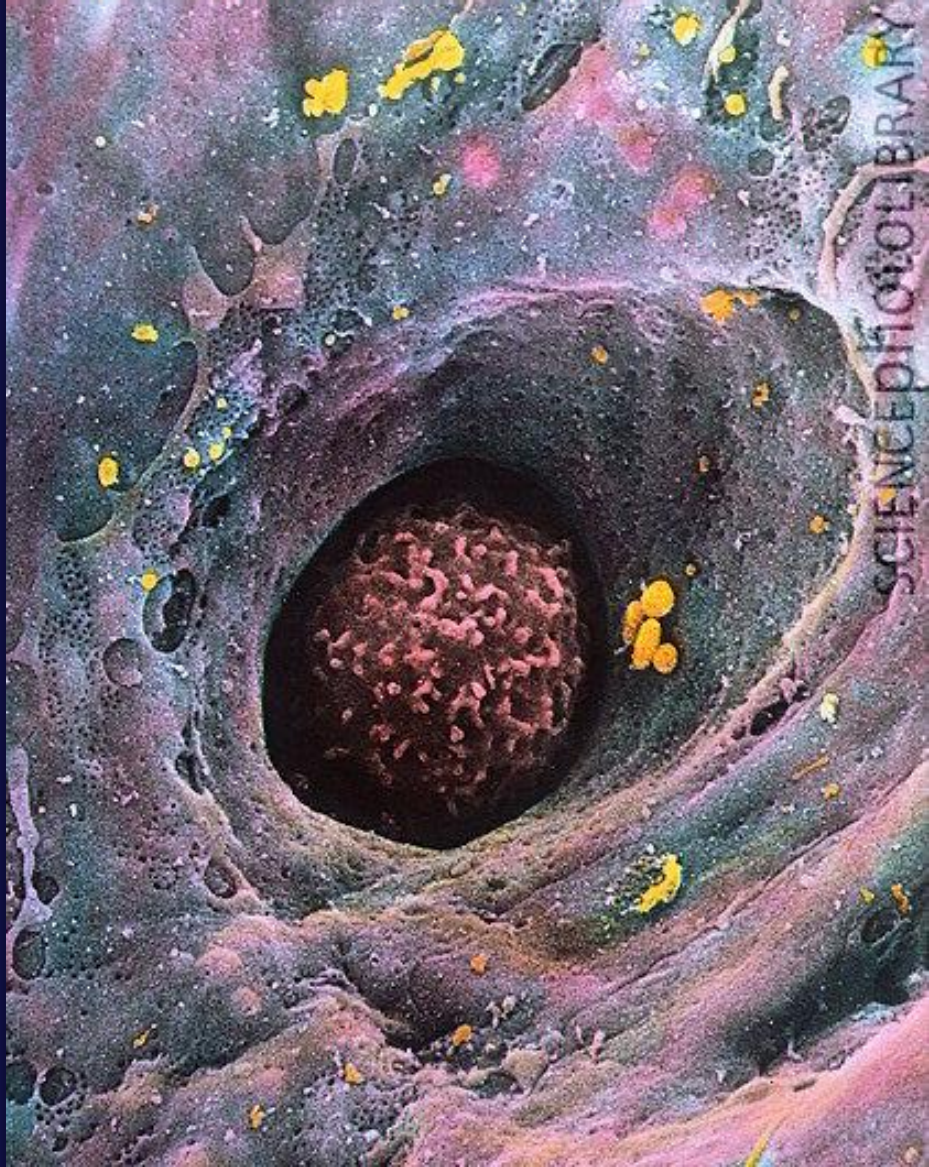


Monosit





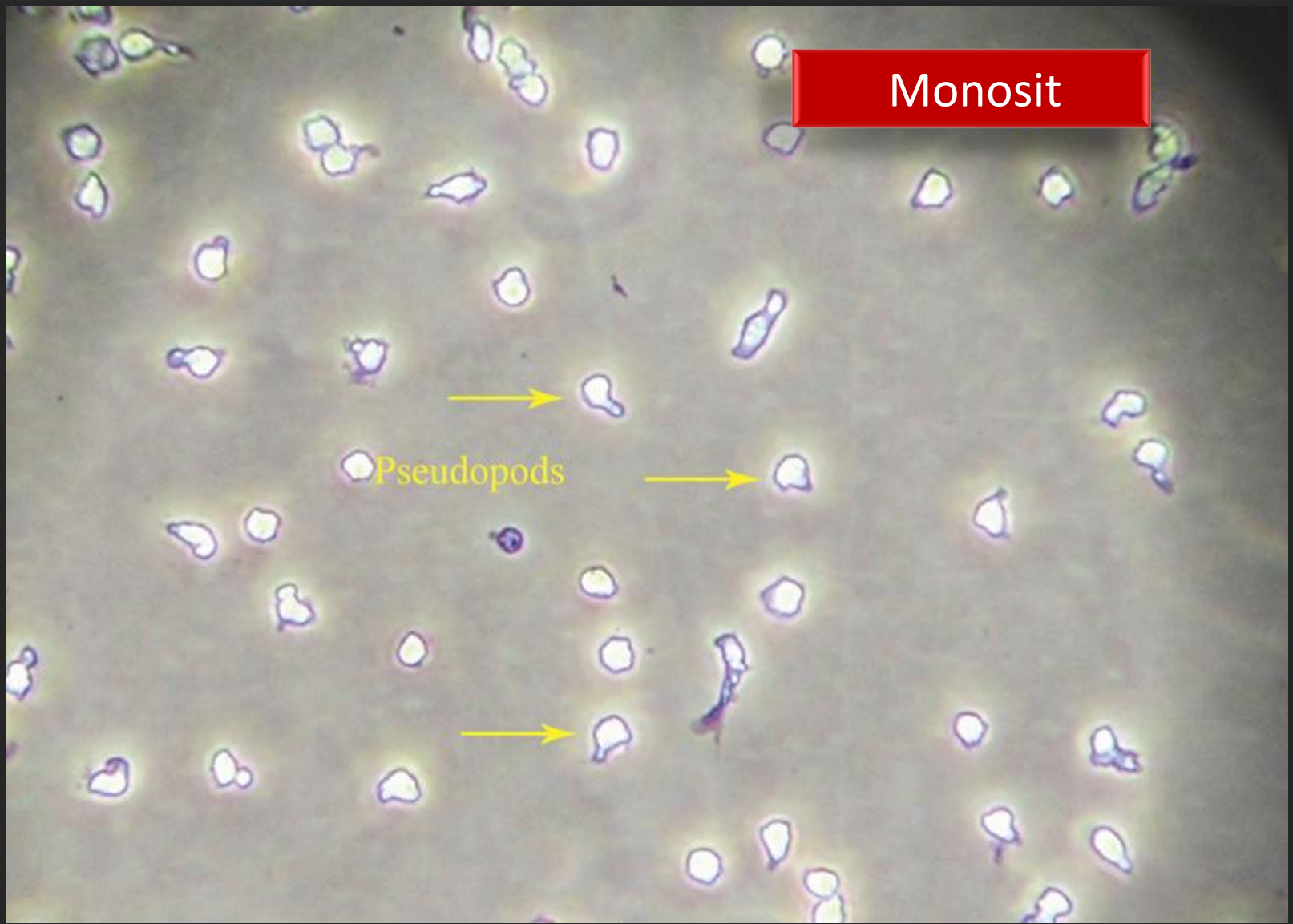


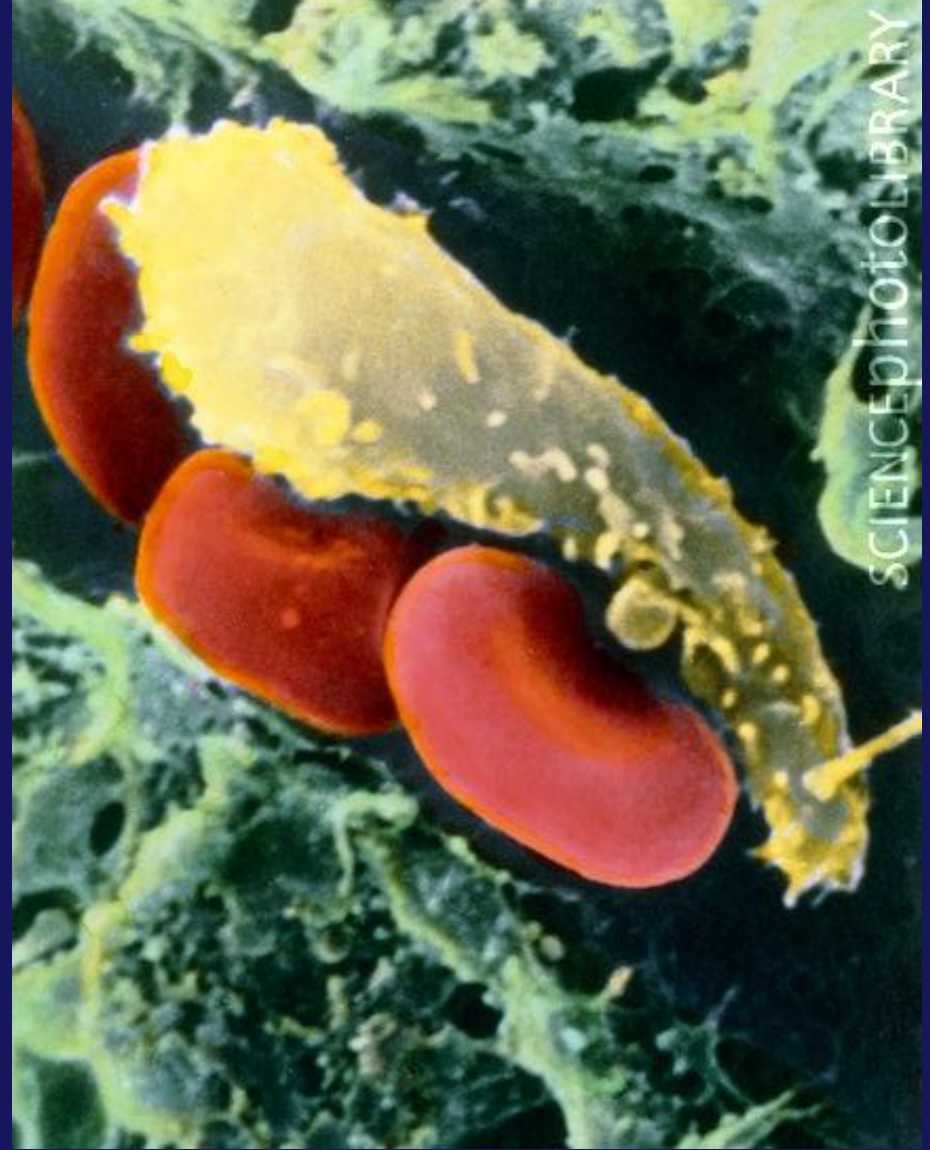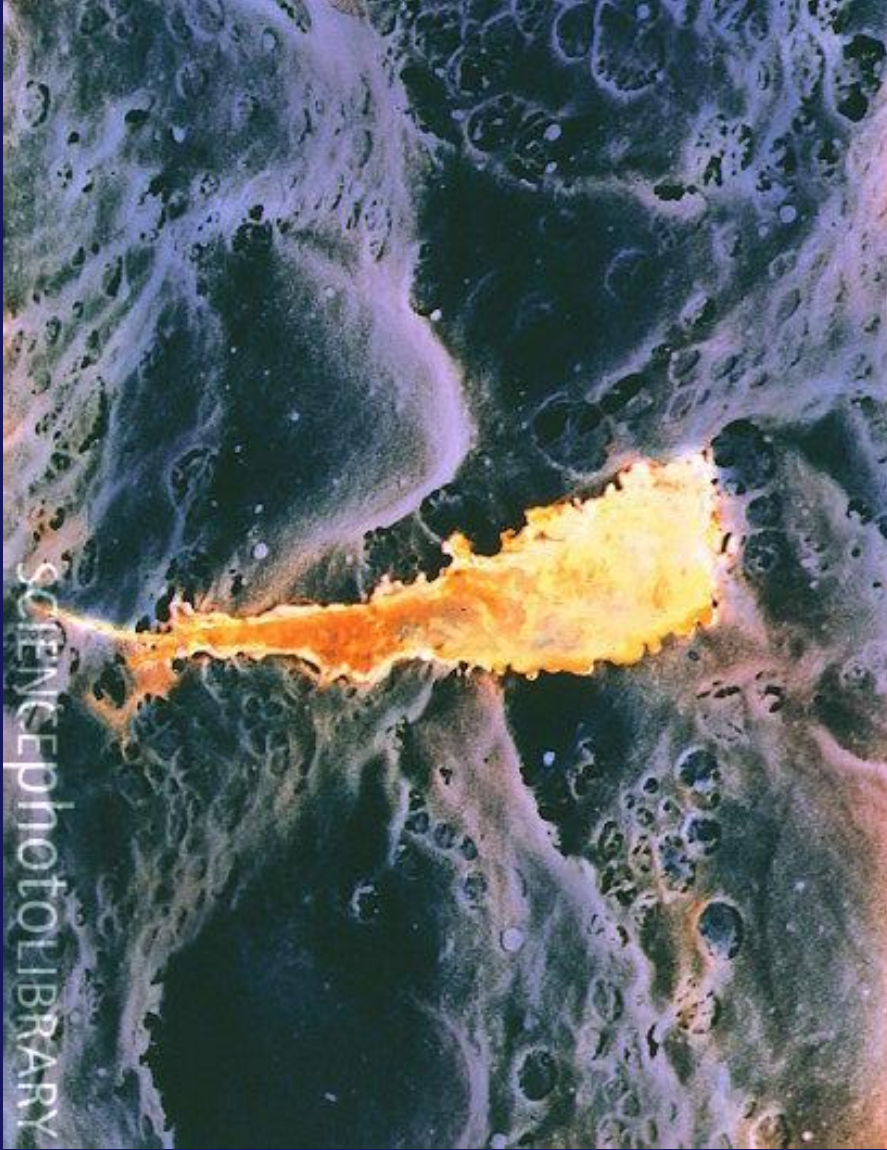Damar içinde Monosit (SEM)



Monosit


Pseudopods





Dokuya göç eden Monosit (SEM)

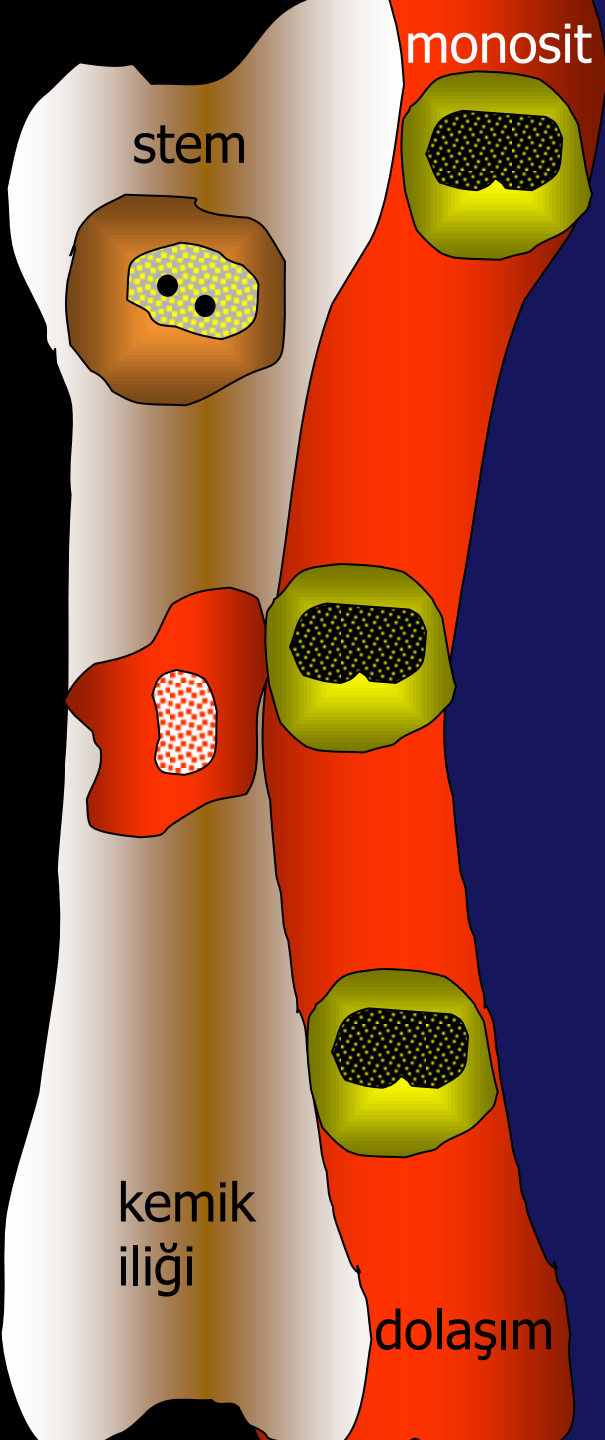




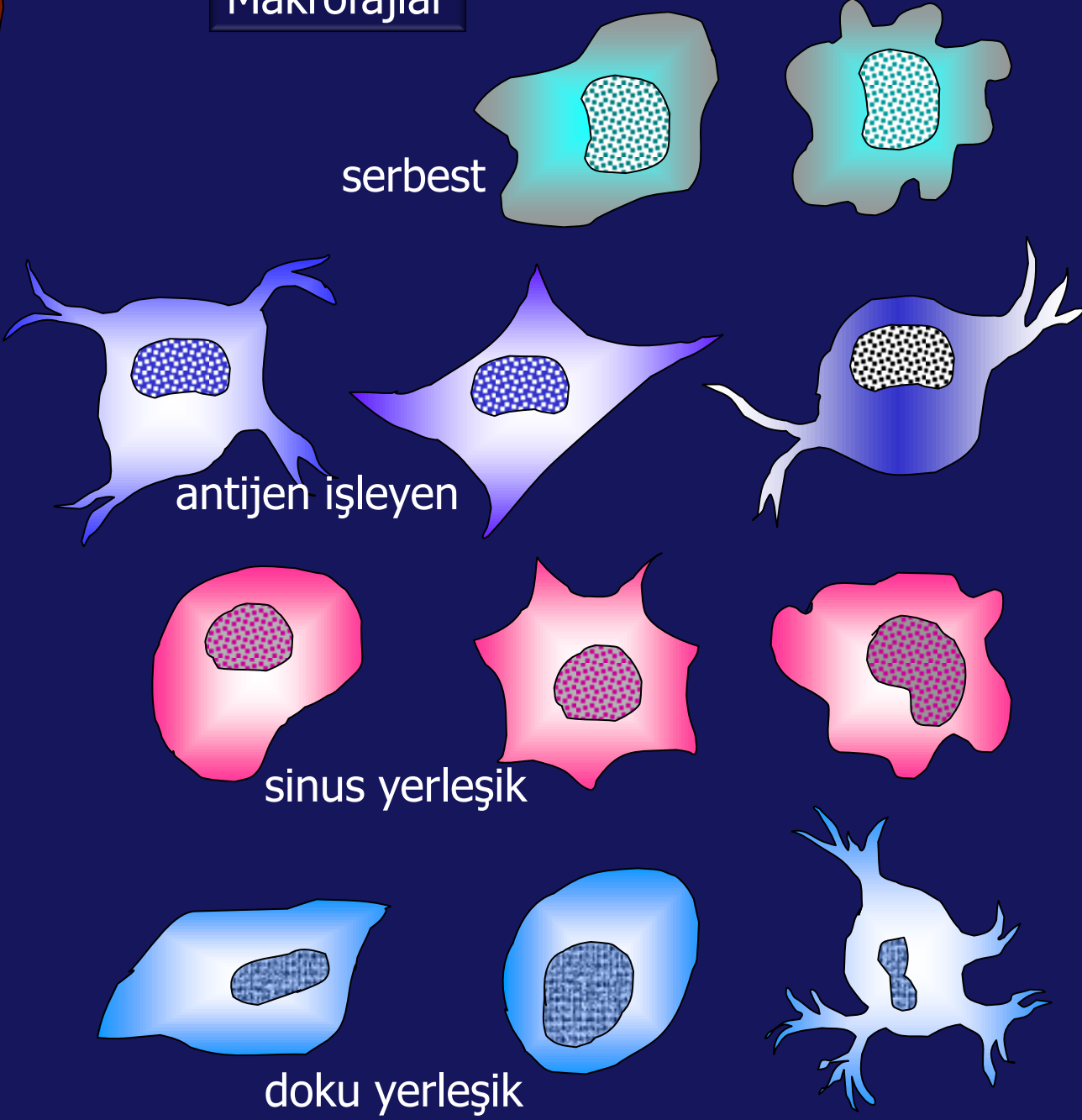
**IDW**<sup>TM</sup>

ONE OF FOUR • \$3.99

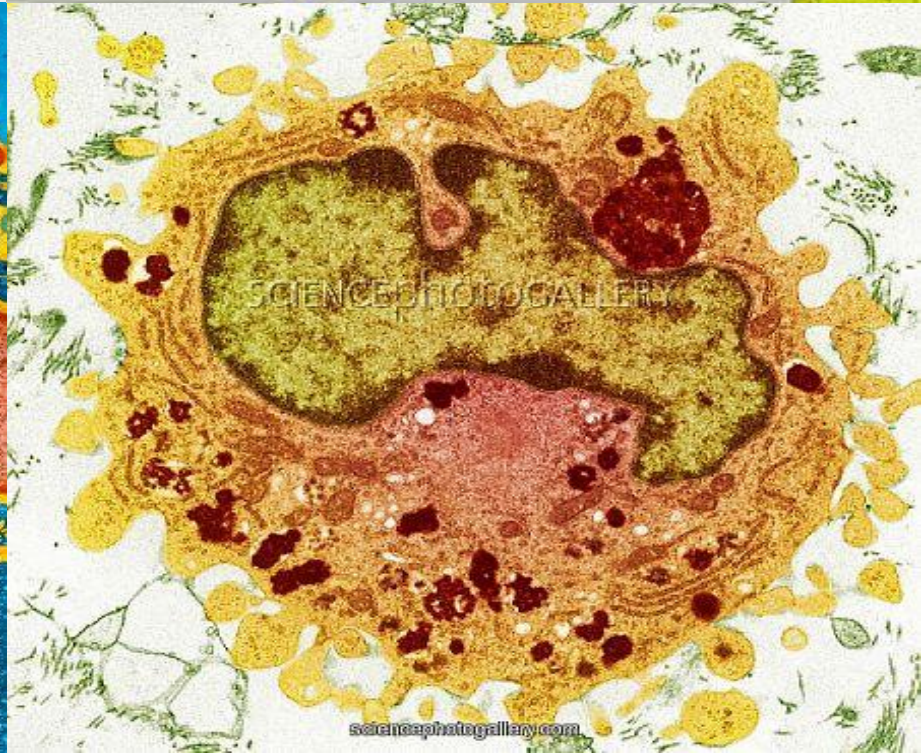
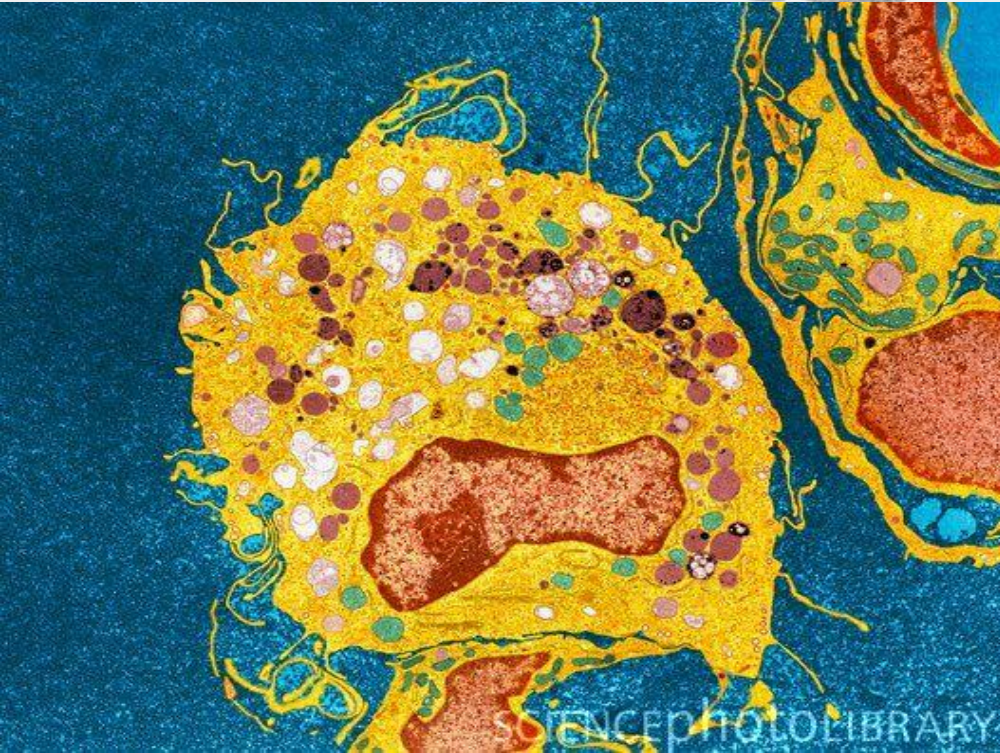
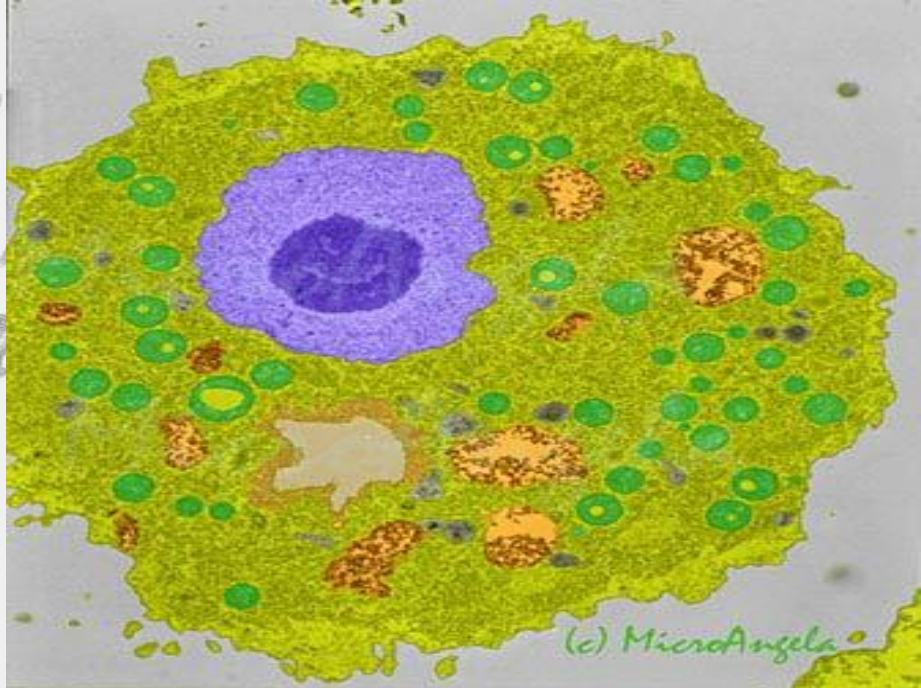
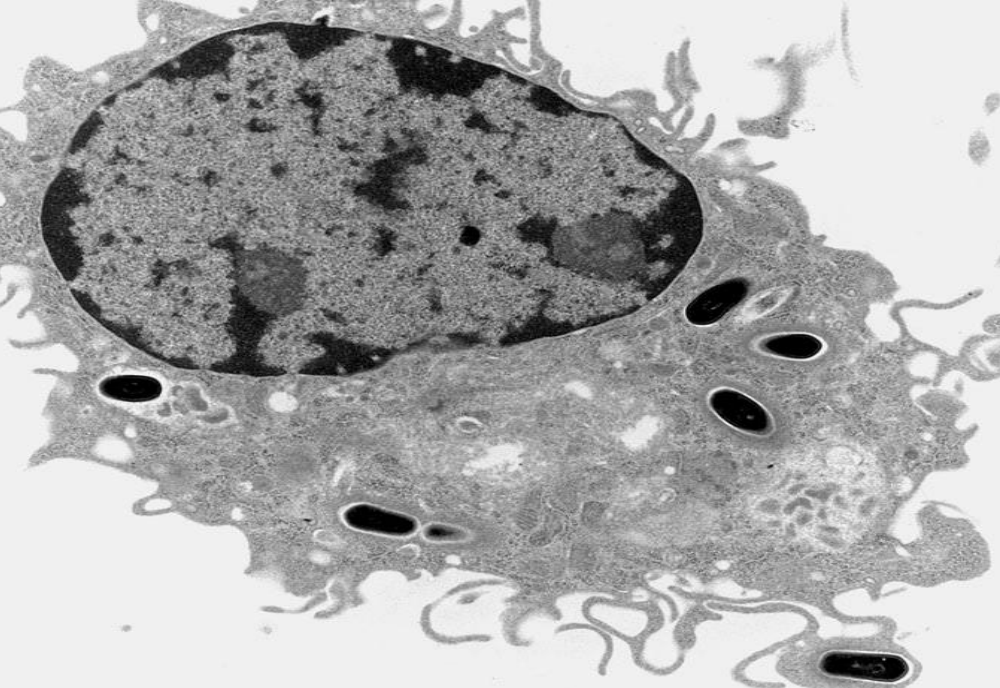
01 **MOONOCYTE**  
IN THE LAND OF THE BLIND THE ONE EYED IS KING



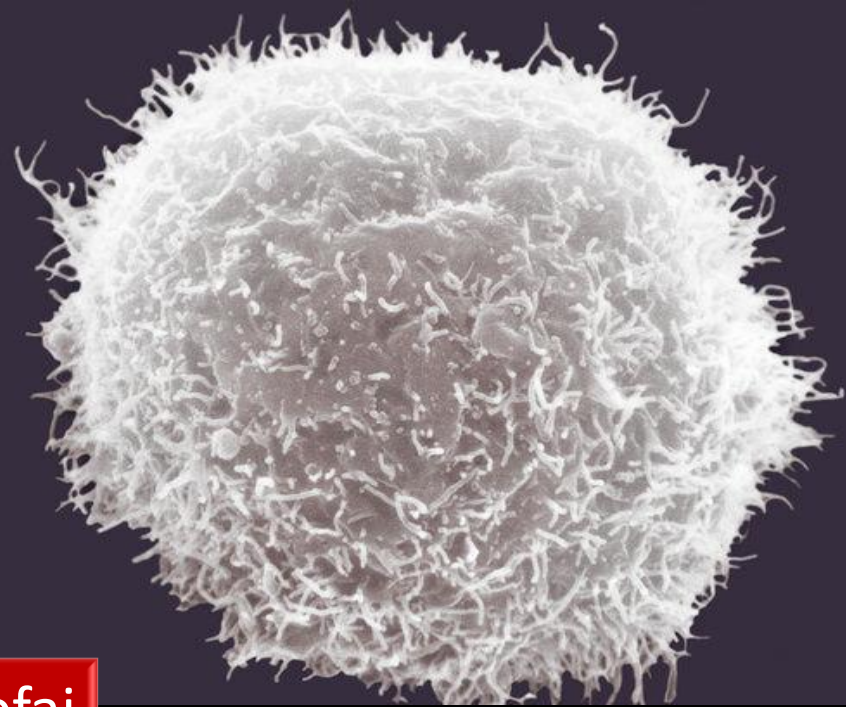

Makrofajlar



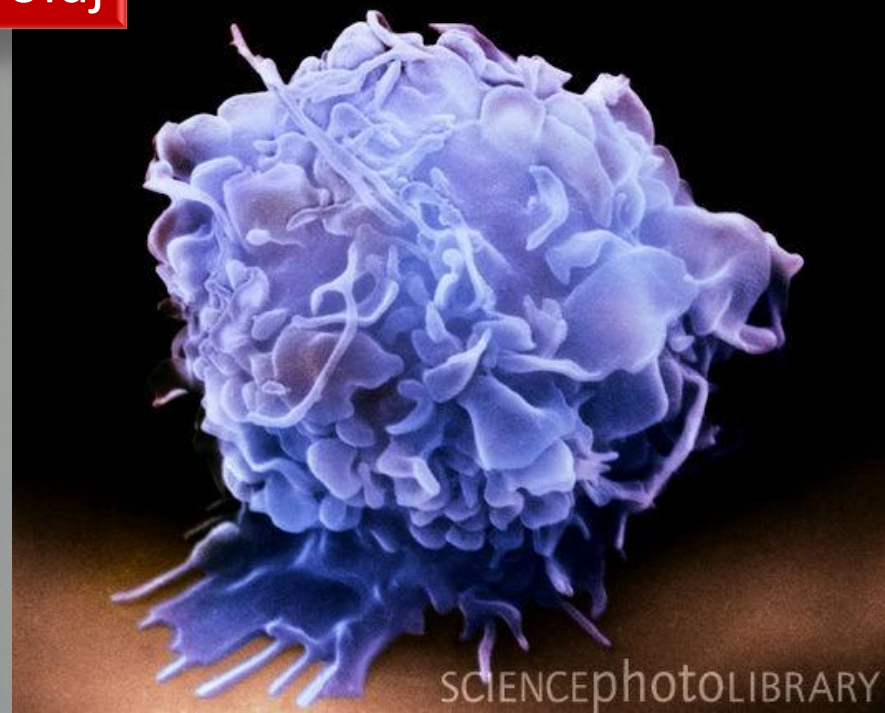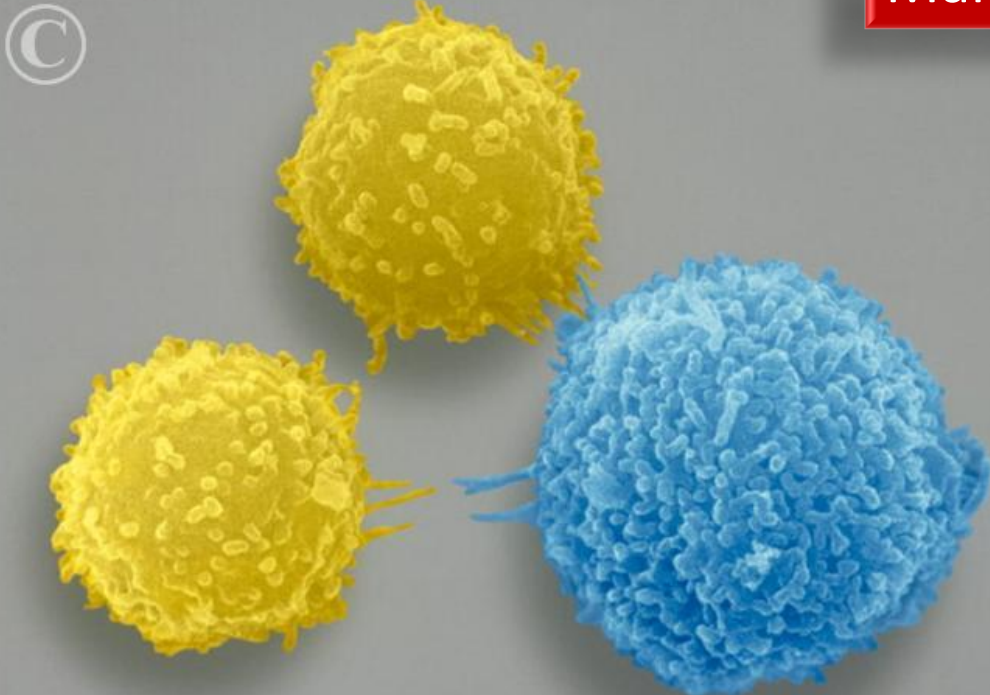




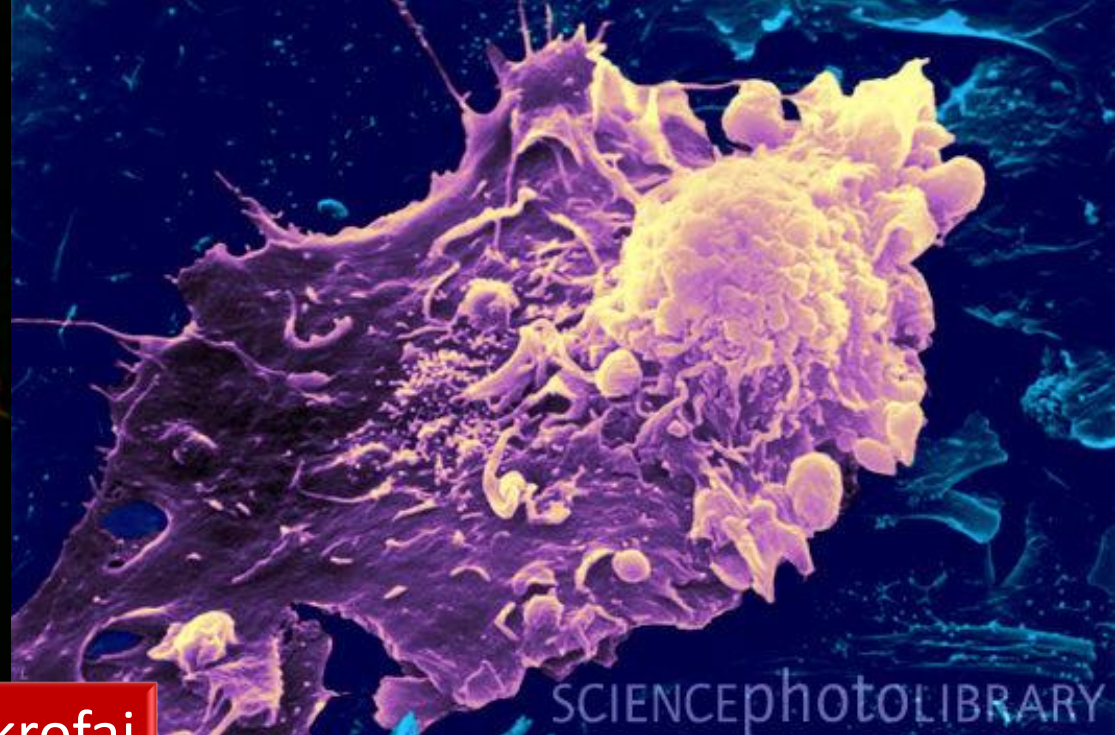

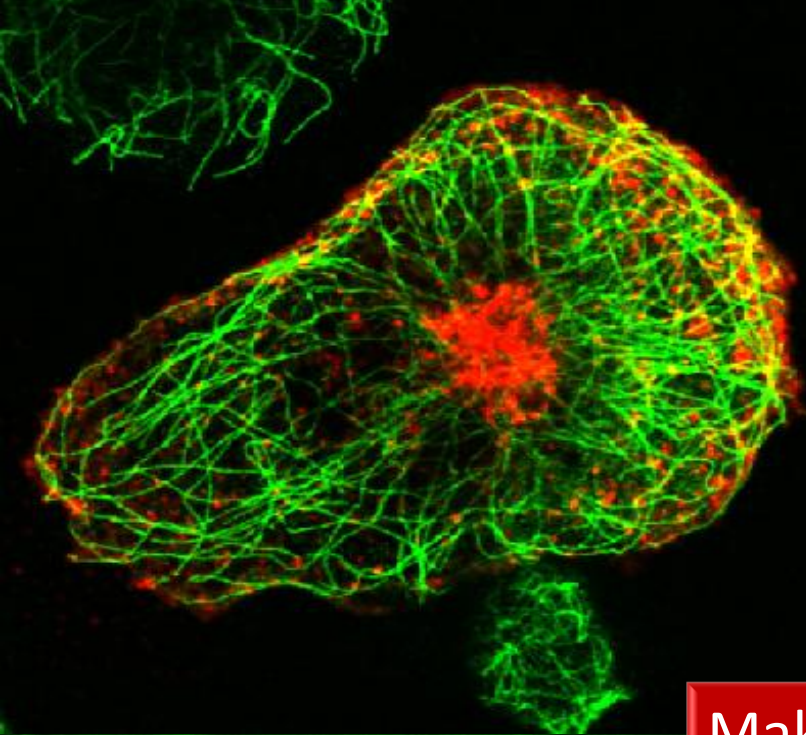


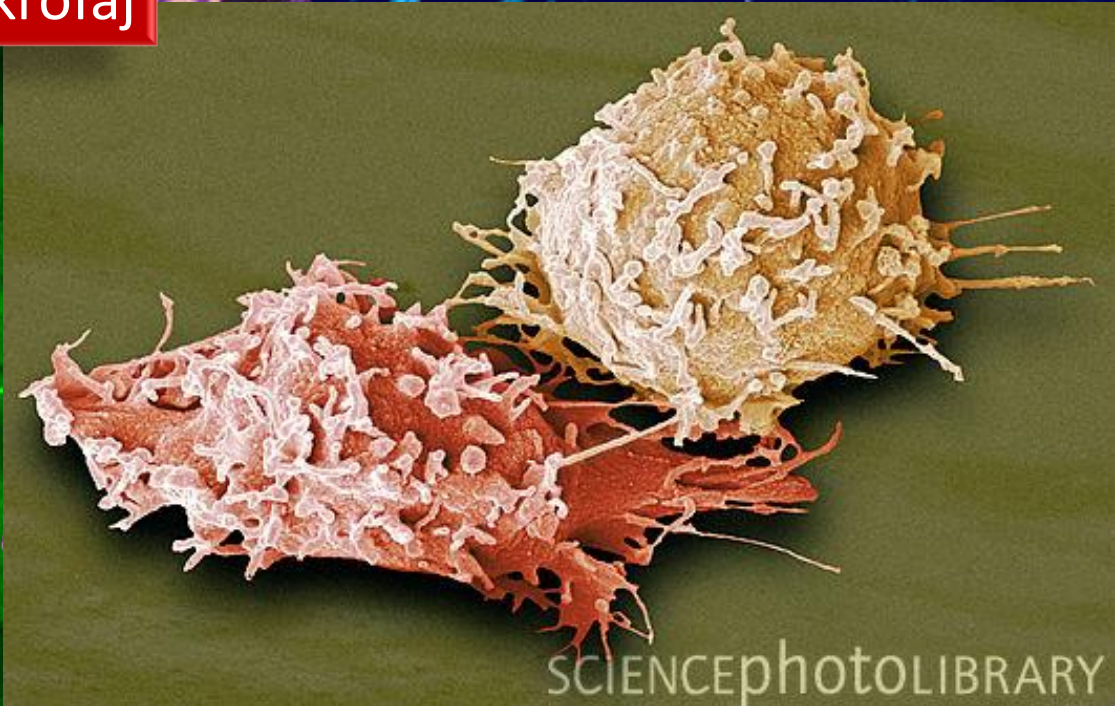
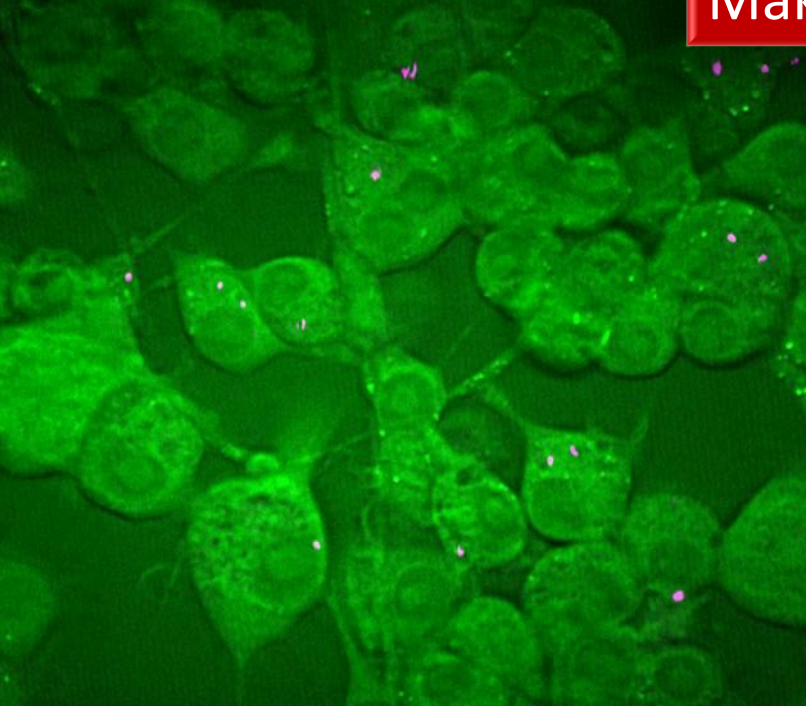Makrofaj





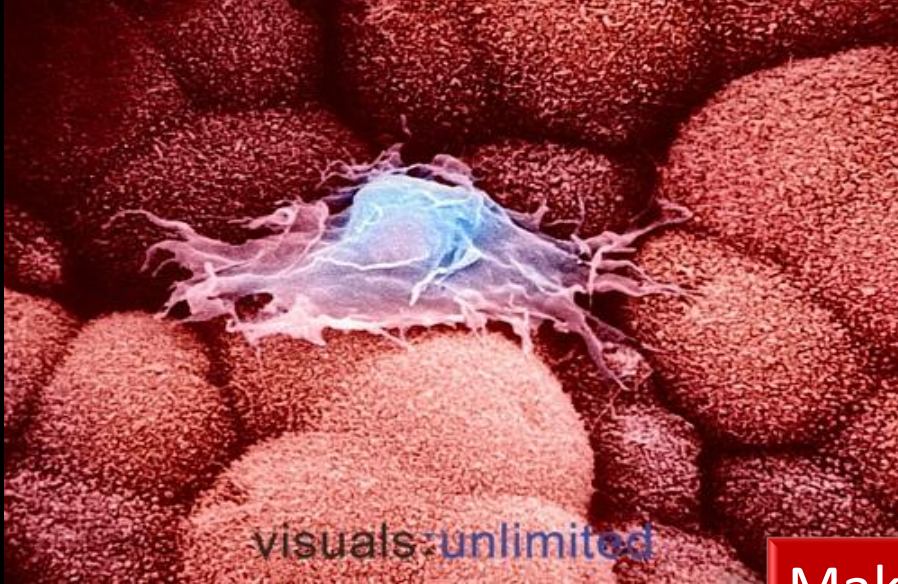

Makrofaj

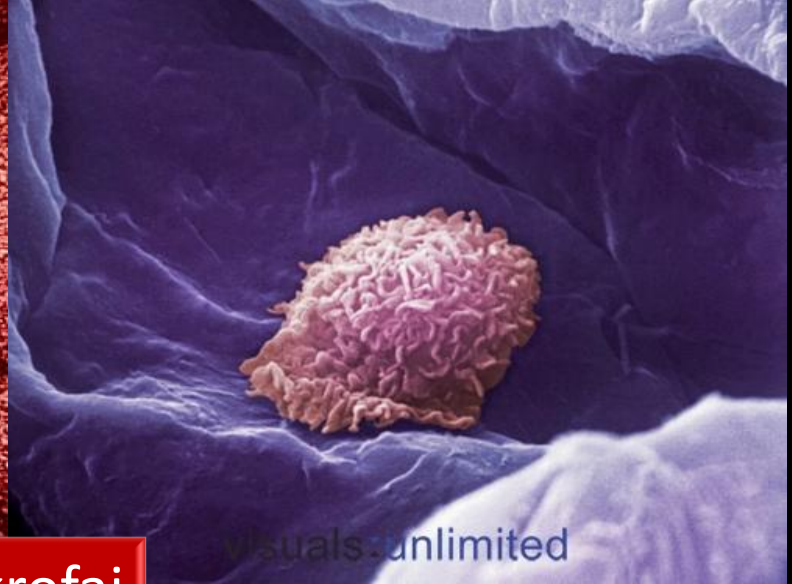


SCIENCEPHOTOLIBRARY



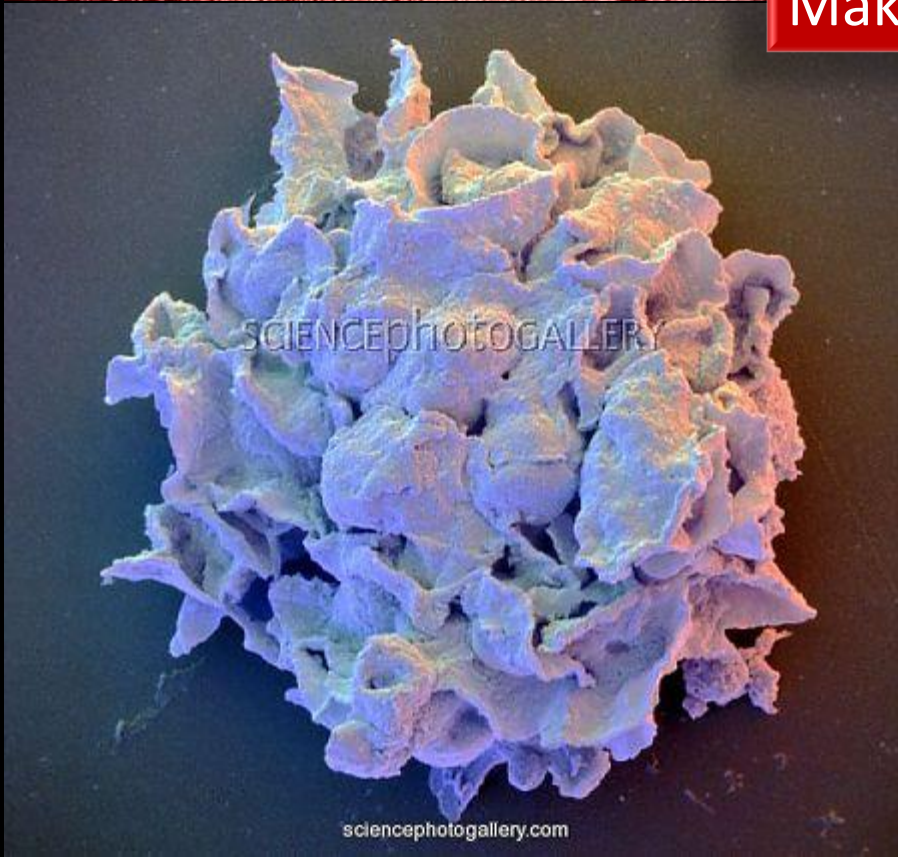

visuals-unlimited



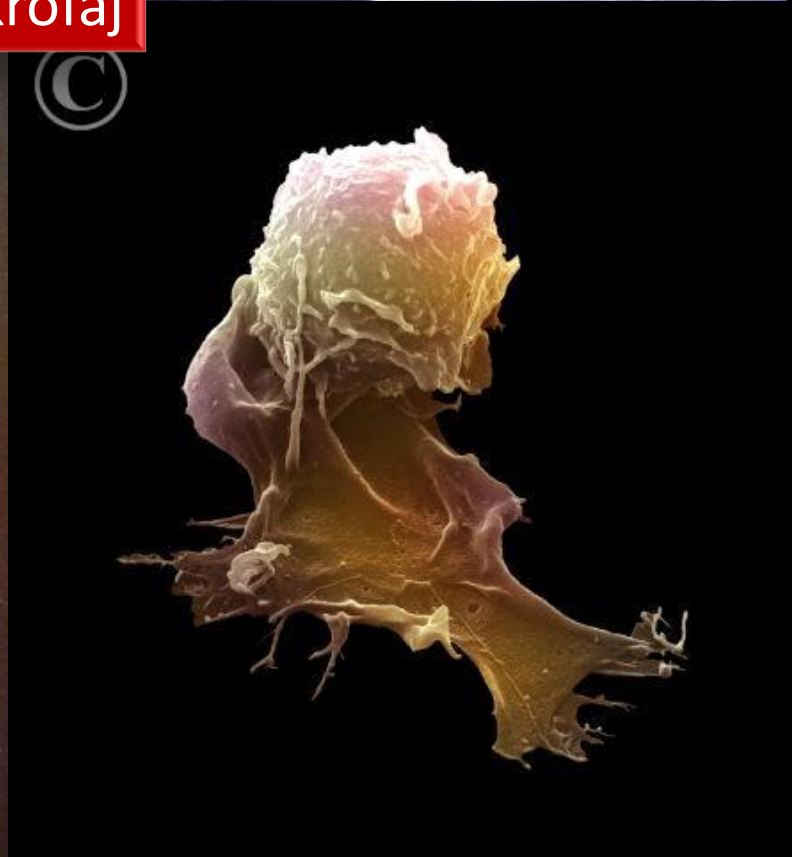
visuals-unlimited

# Makrofaj

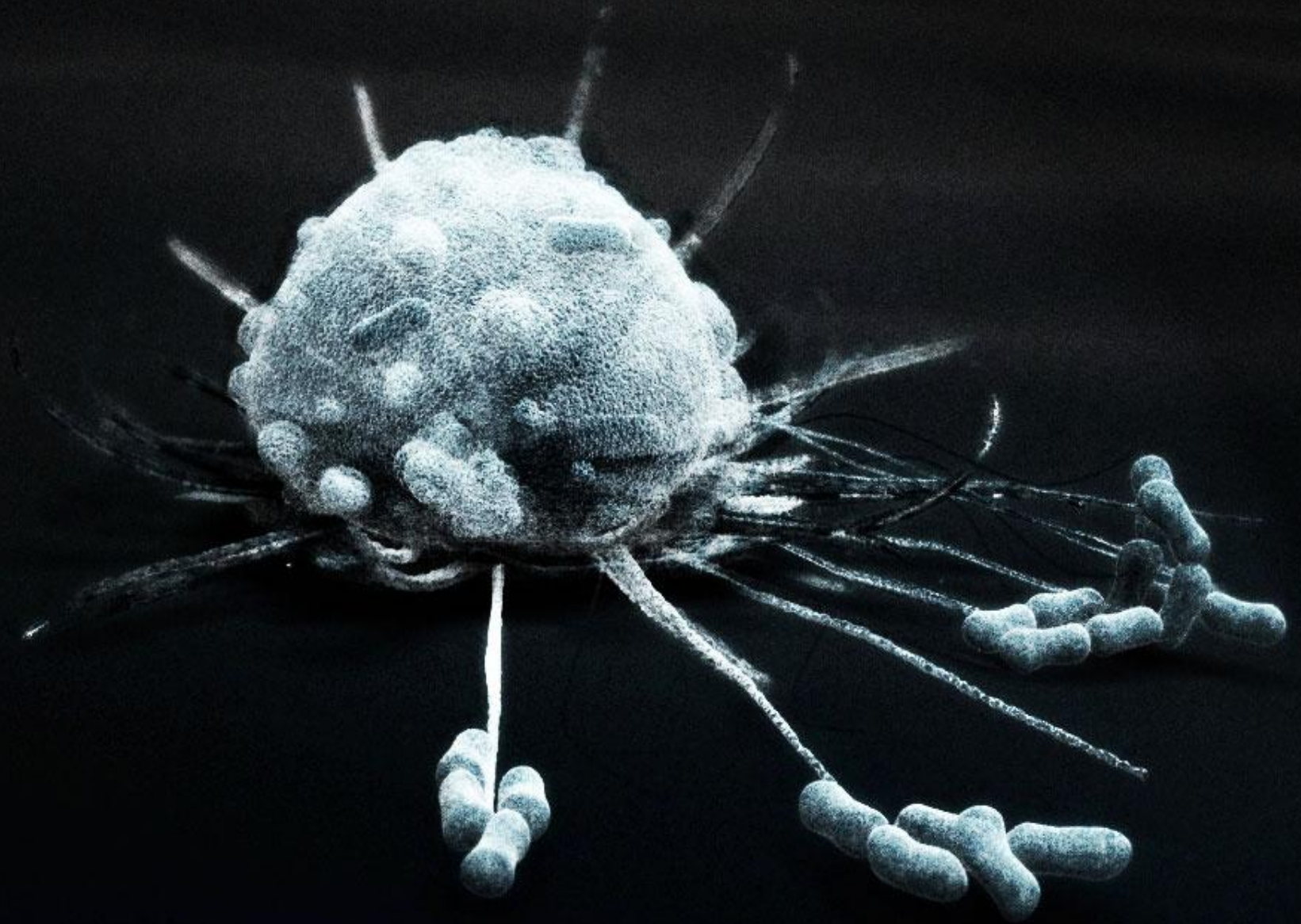


SCIENCEPHOTOGALLERY

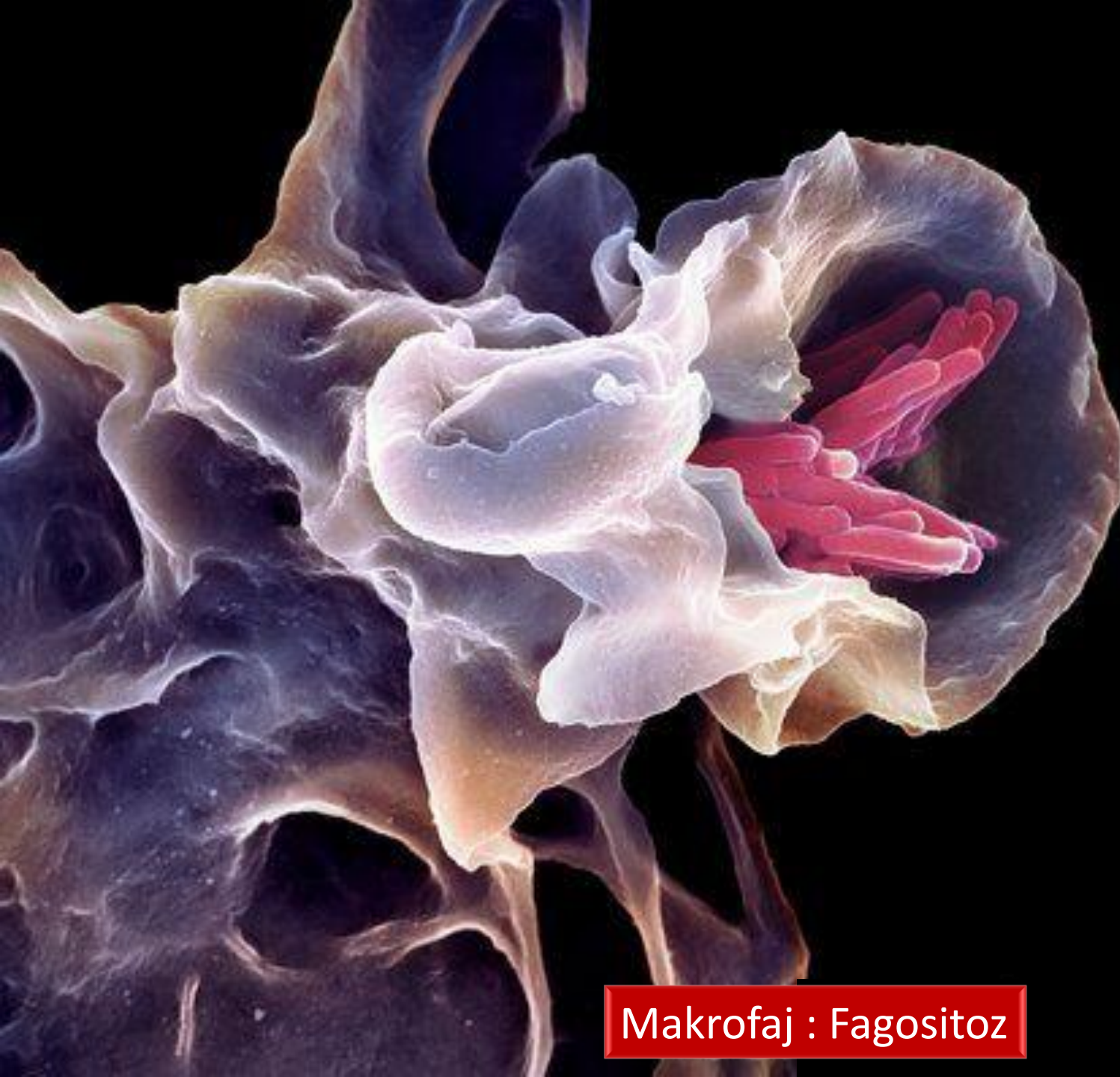sciencephotogallery.com





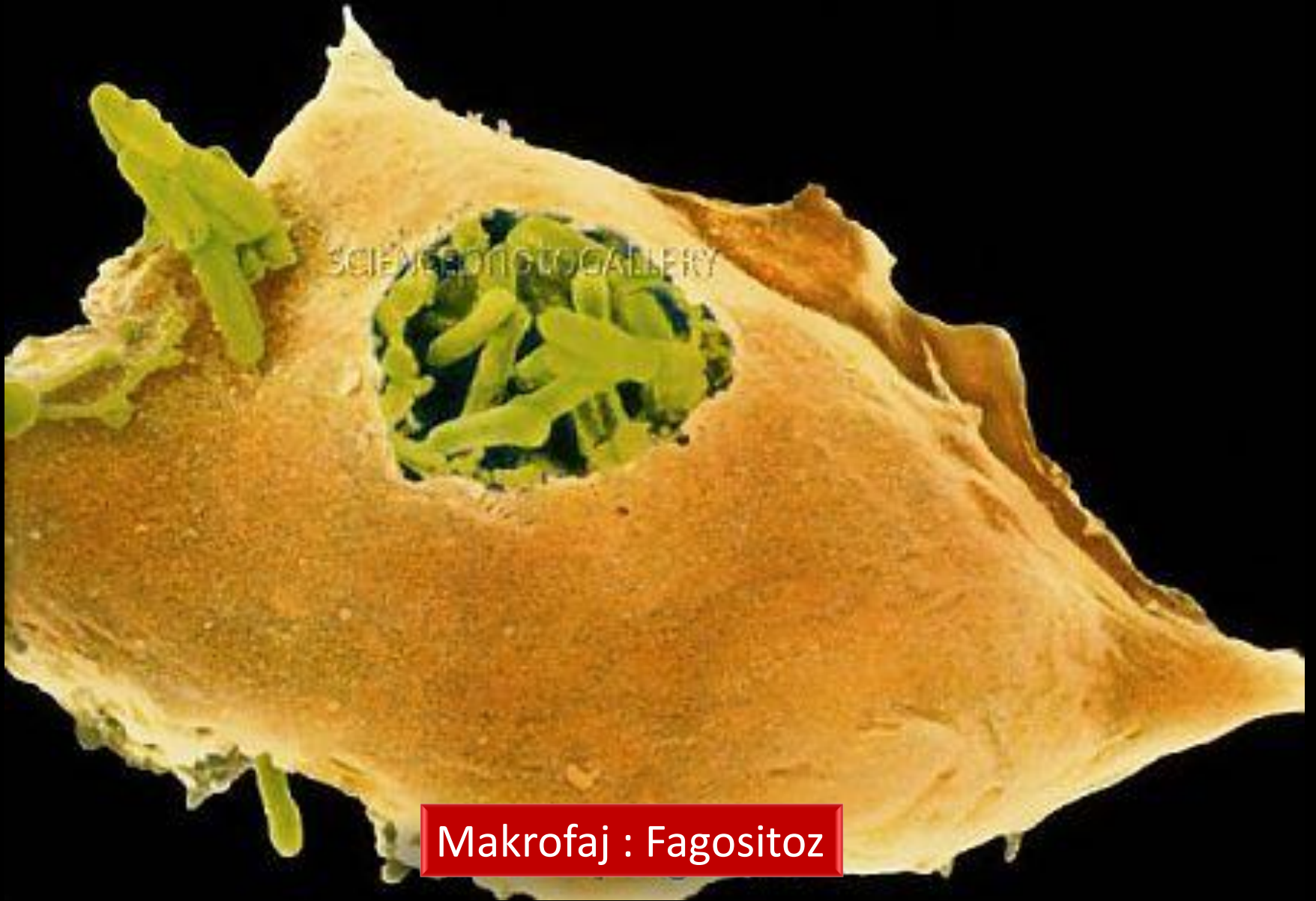

Makrofaj : Fagositoz

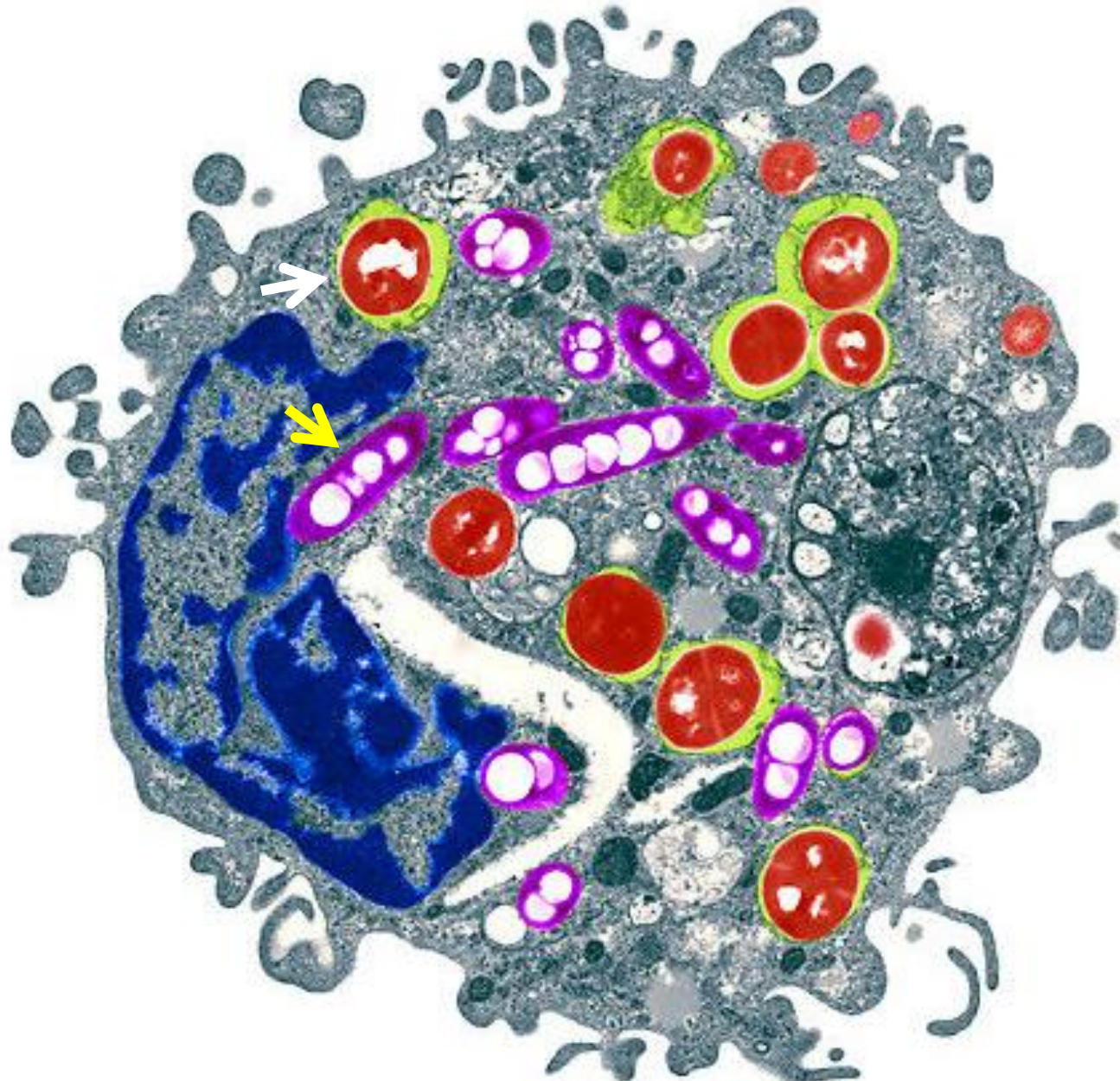


Makrofaj : Fagositoz



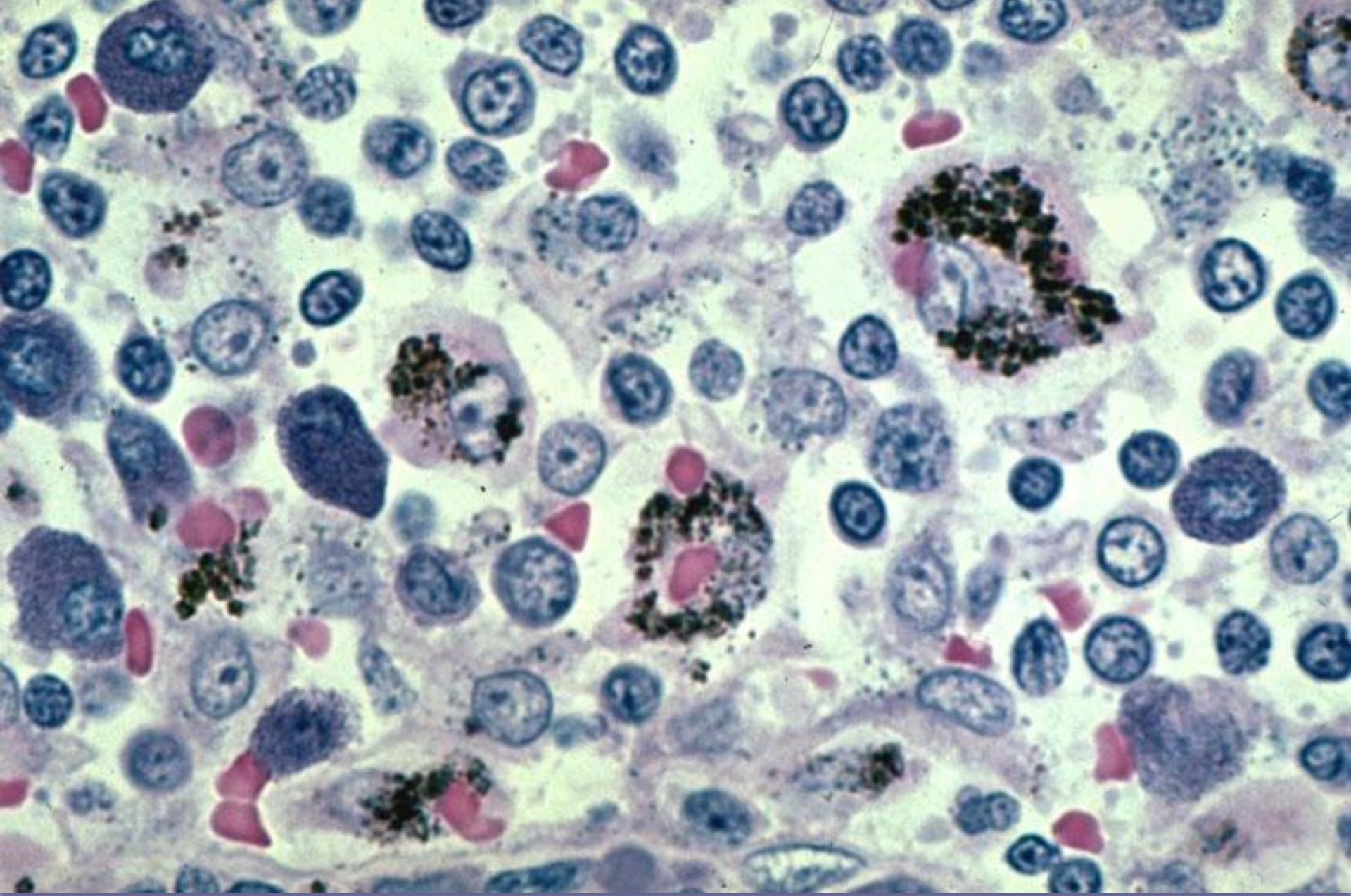


**Makrofaj : Fagositoz**



Makrofaj : Fagositoz : bakteri + mantar



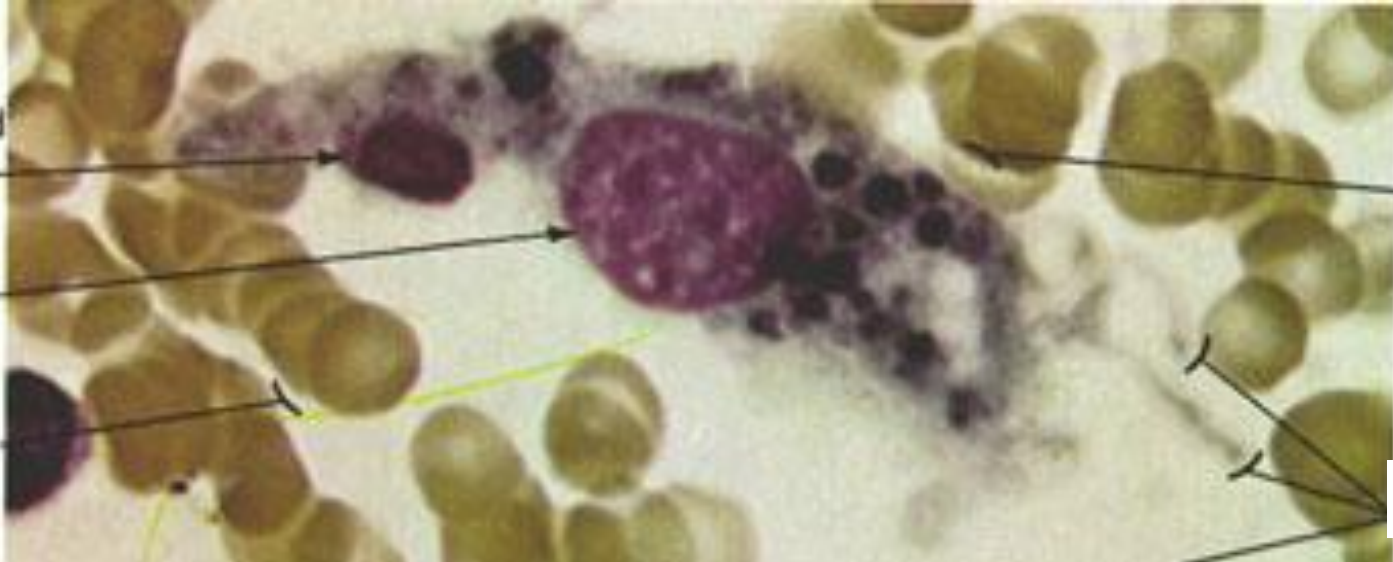


Makrofaj : Fagositoz-karbon partikülleri

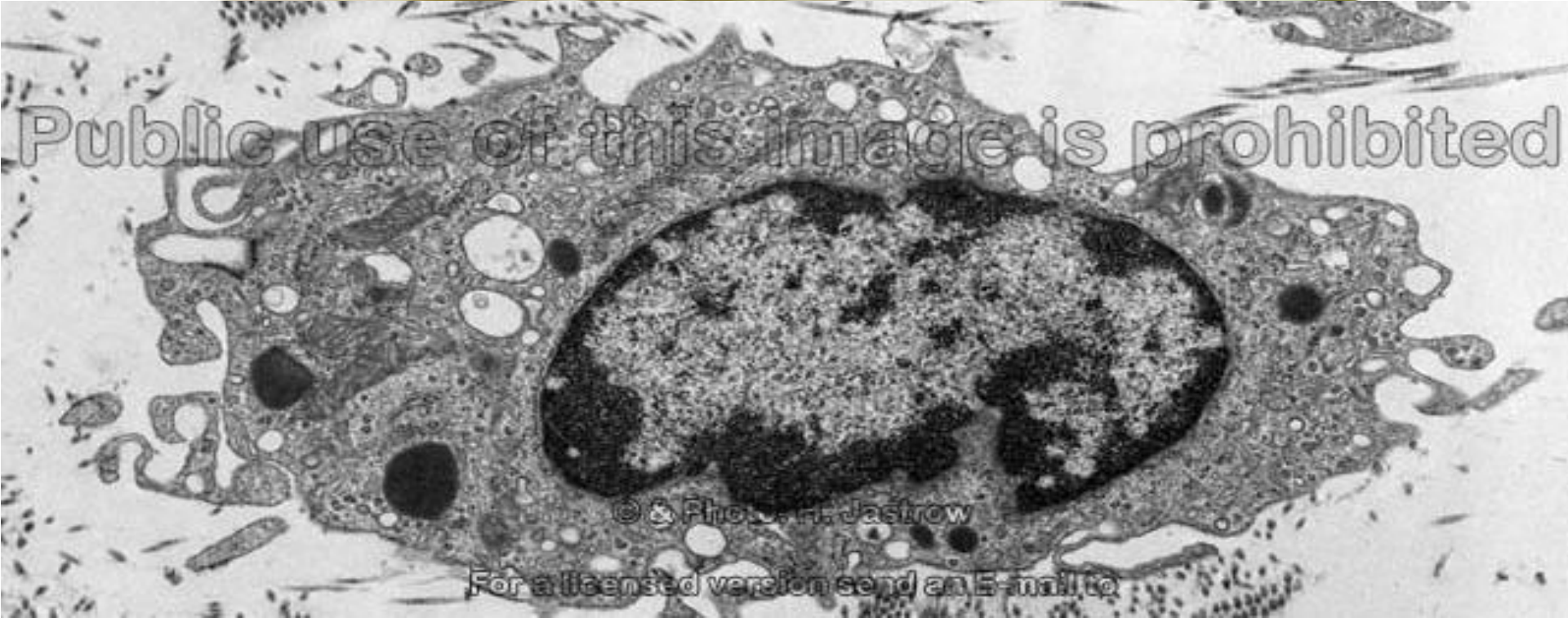

# Doku Yerleşik Makrofaj : Histiosit

Fagosite Materyal  
çekirdek  
eritrositler



Histiosit  
pseudopod



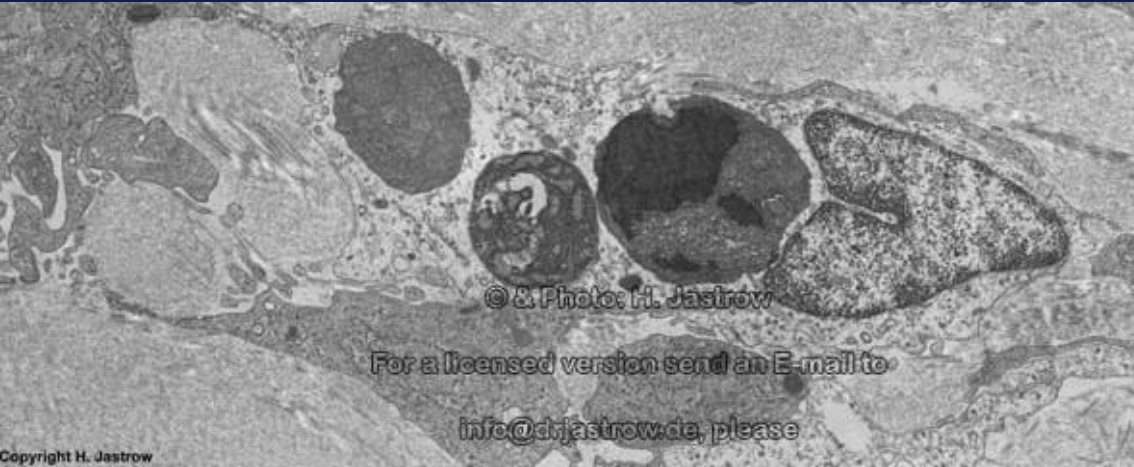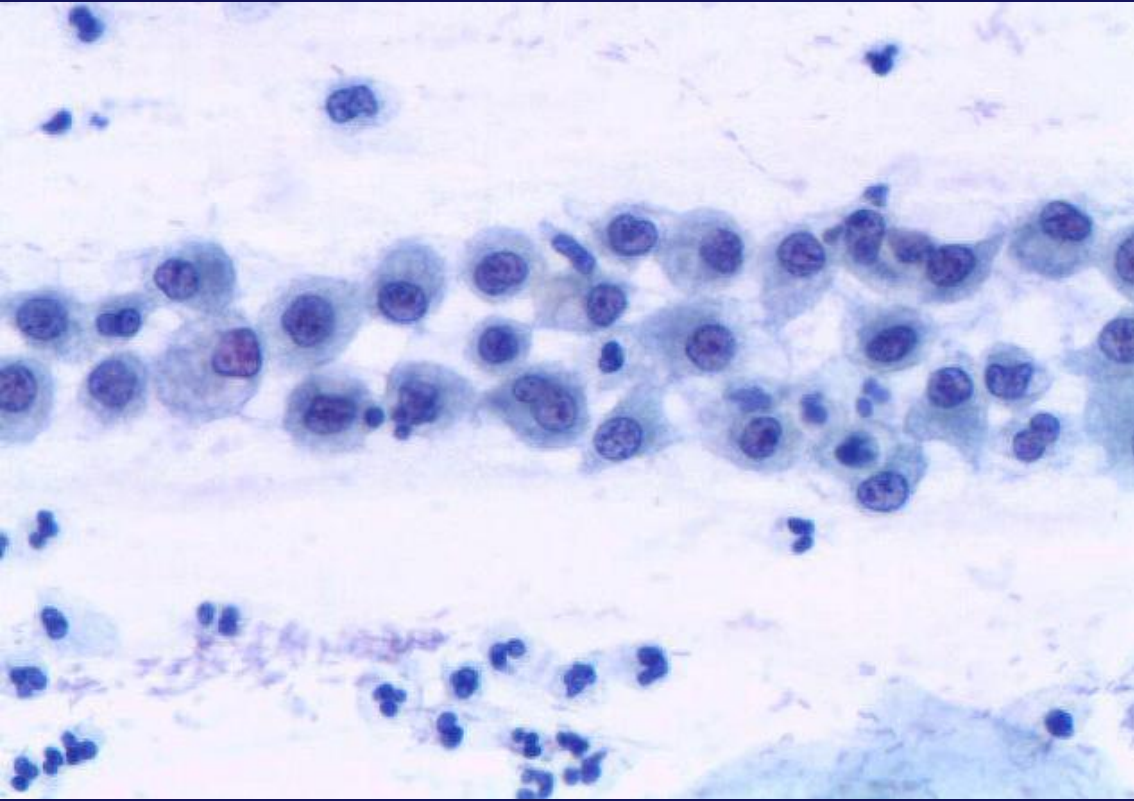
Public use of this image is prohibited

© & Photo: H. Jastrow

For a licensed version send an E-mail to



# Doku Yerleşik Makrofaj : Histiosit

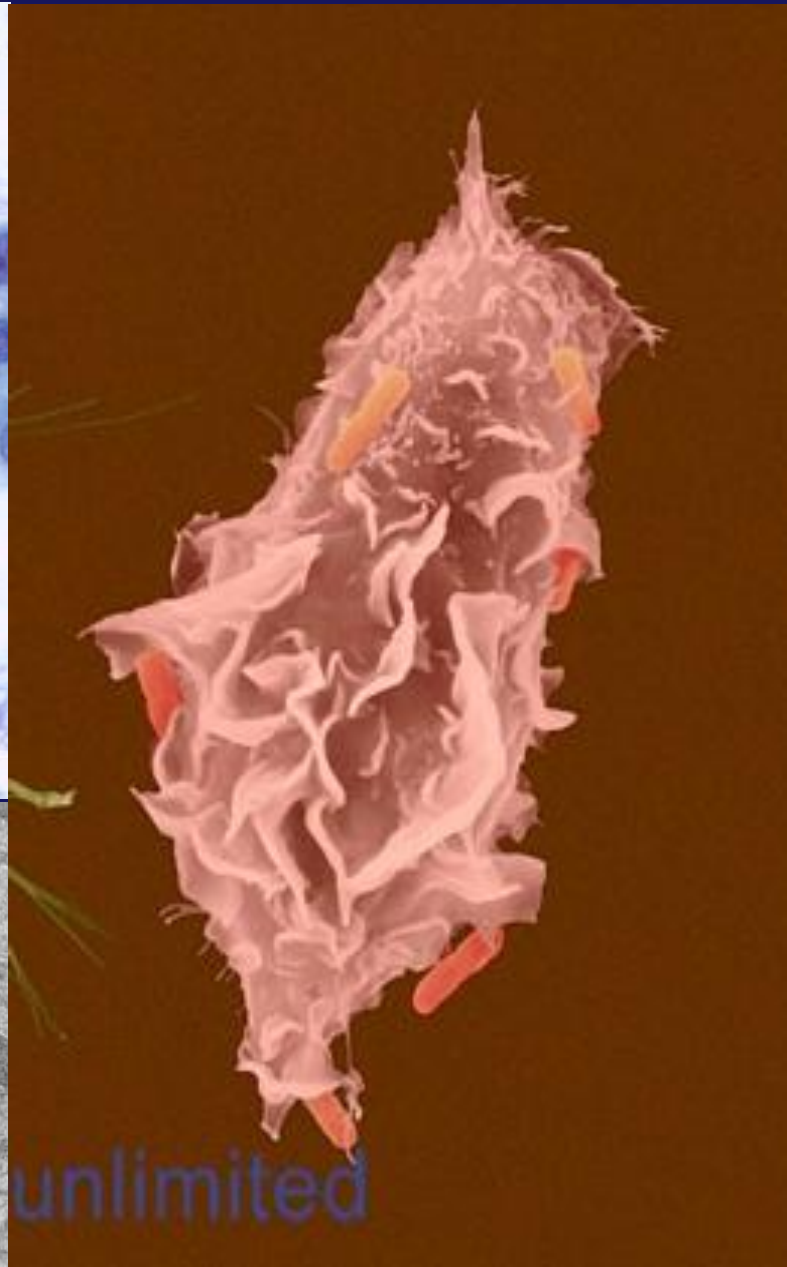


© & Photo: H. Jastrow

For a licensed version send an E-mail to

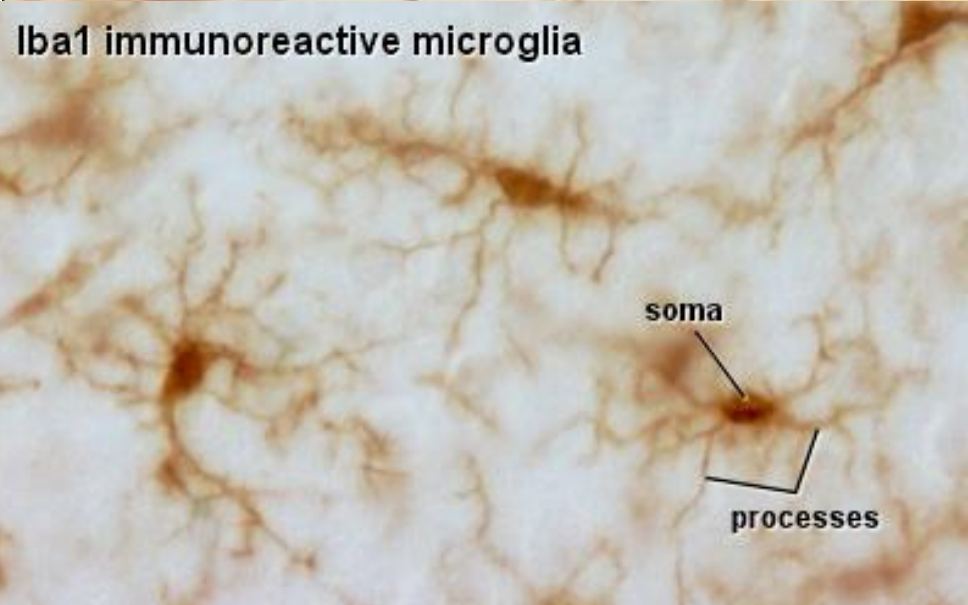
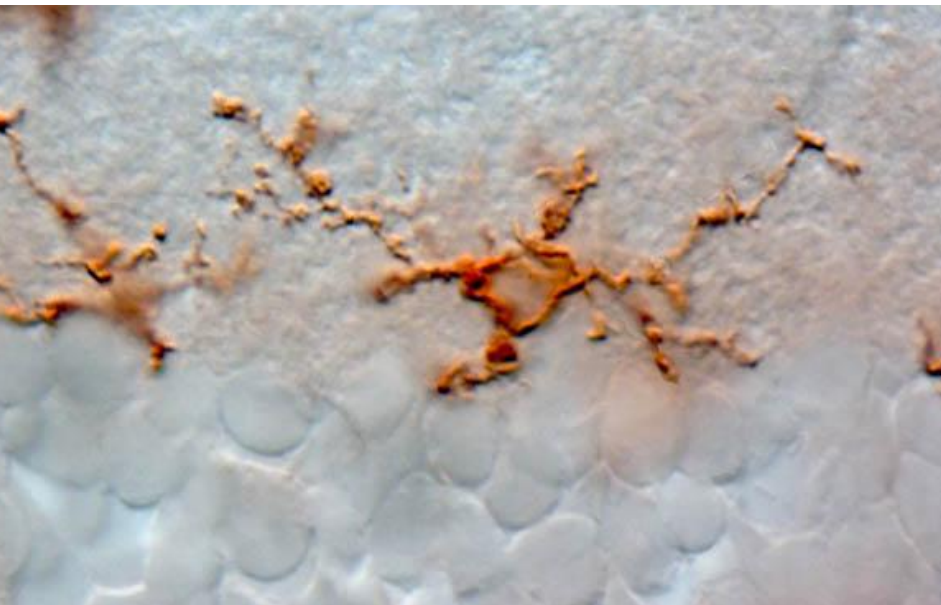
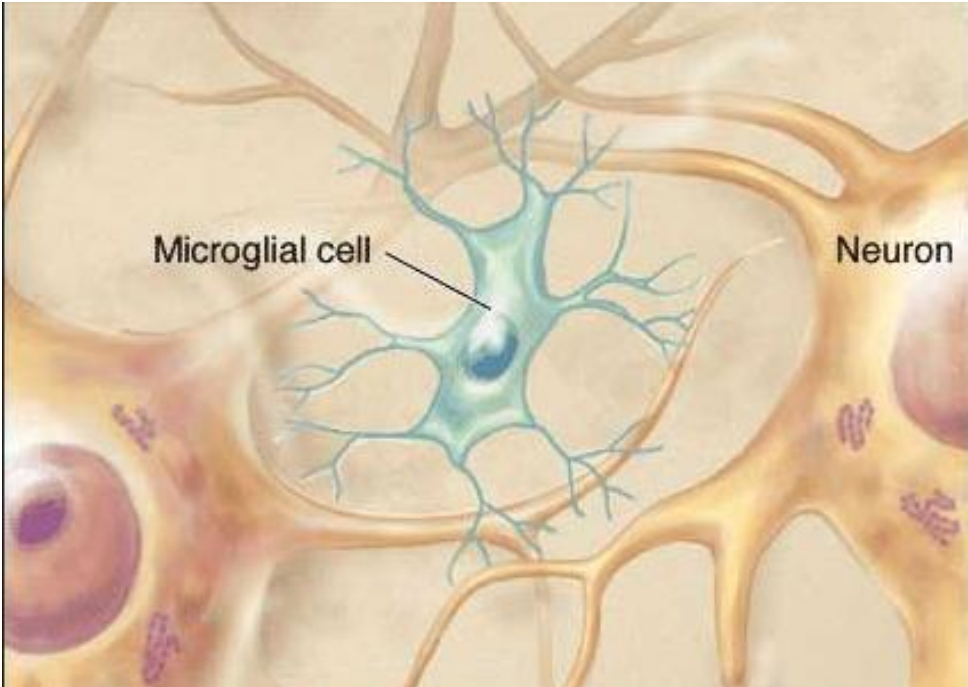
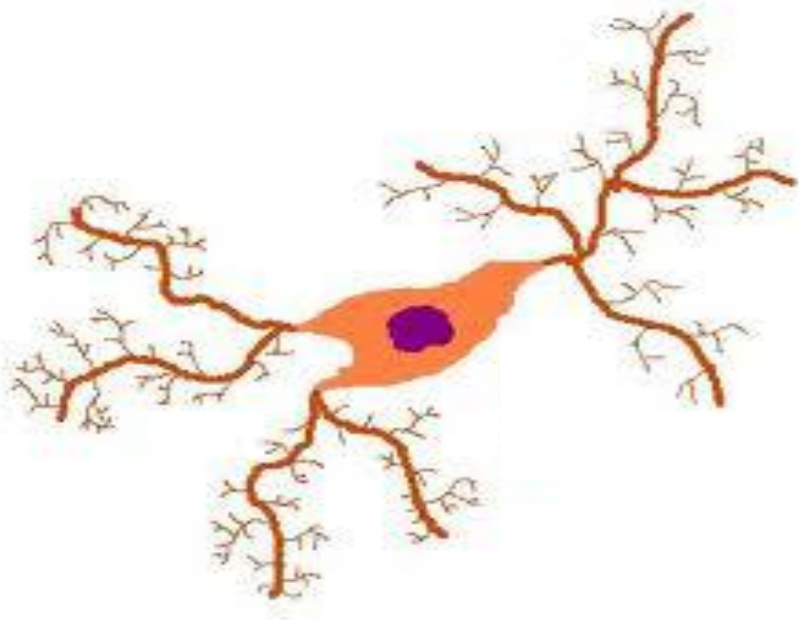
[info@drjastrow.de](mailto:info@drjastrow.de), please

Copyright H. Jastrow

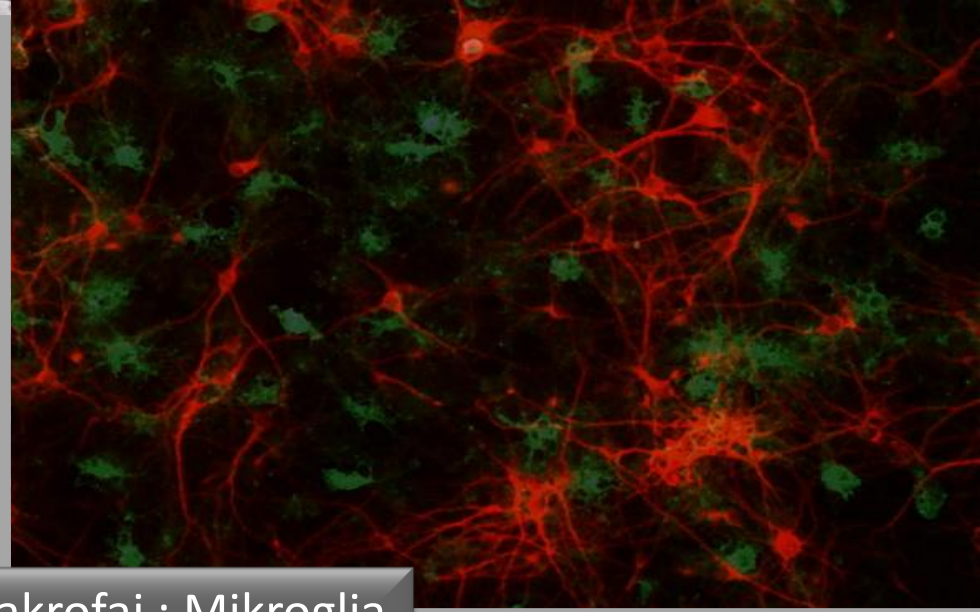
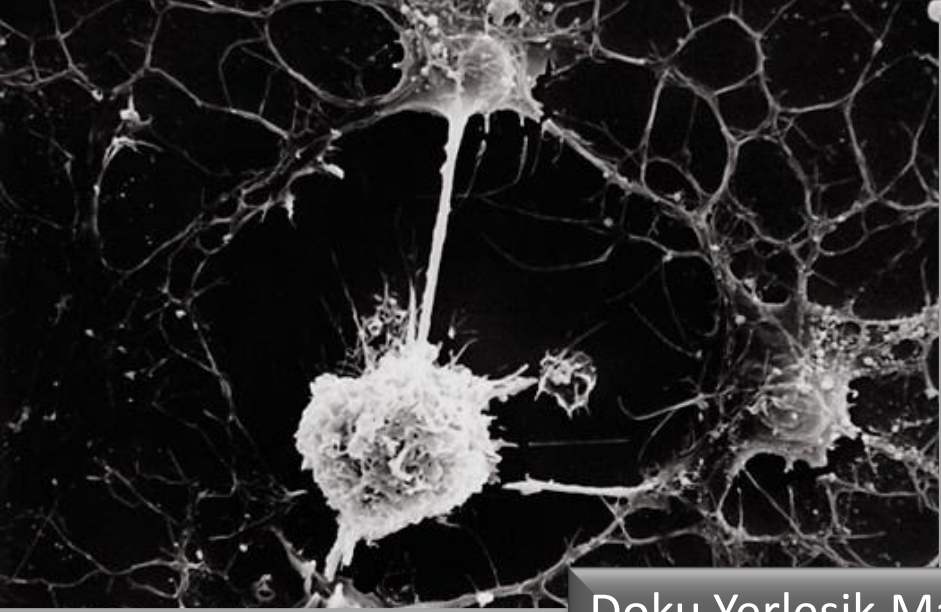


unlimited

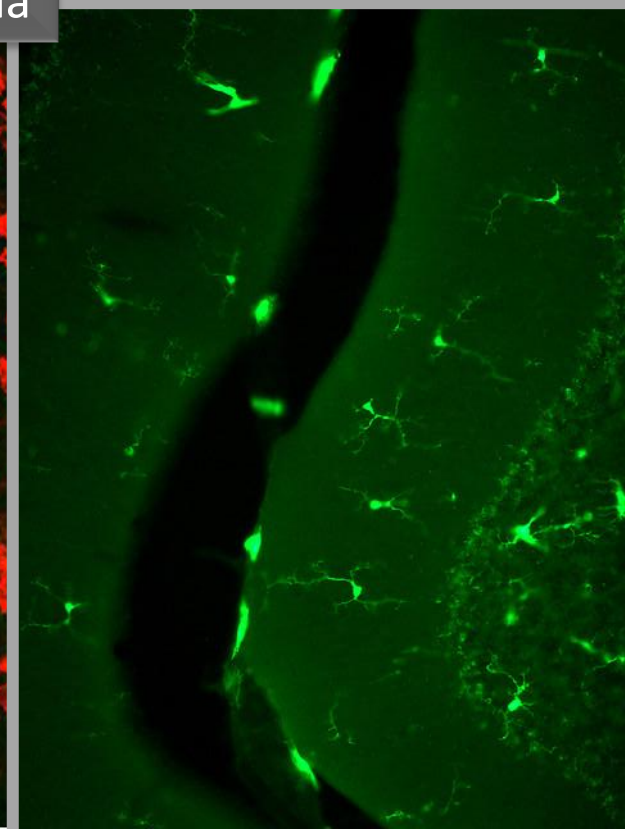
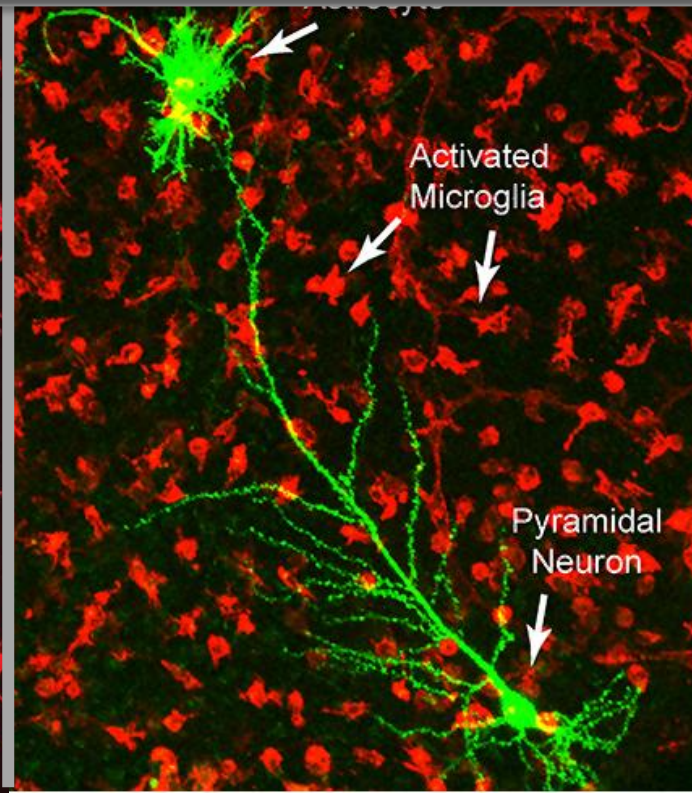
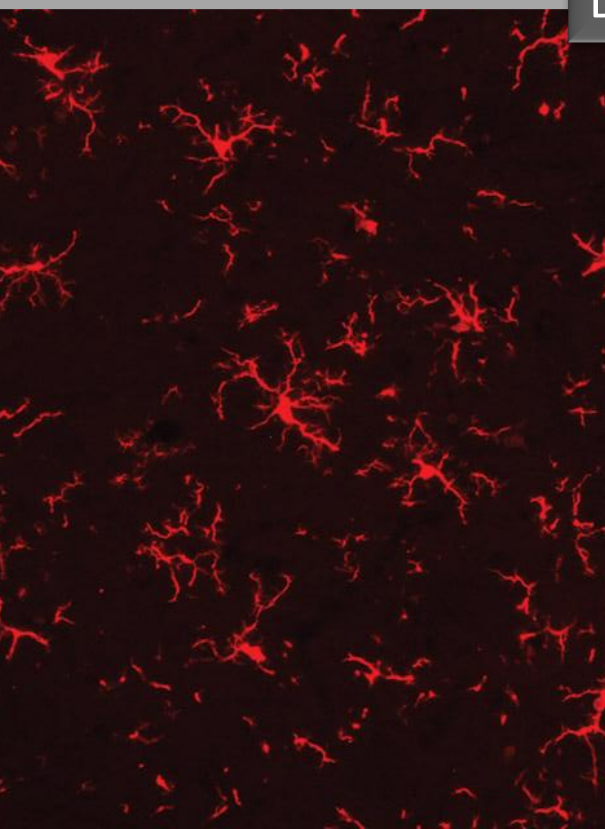
# Doku Yerleşik Makrofaj : Mikroglia





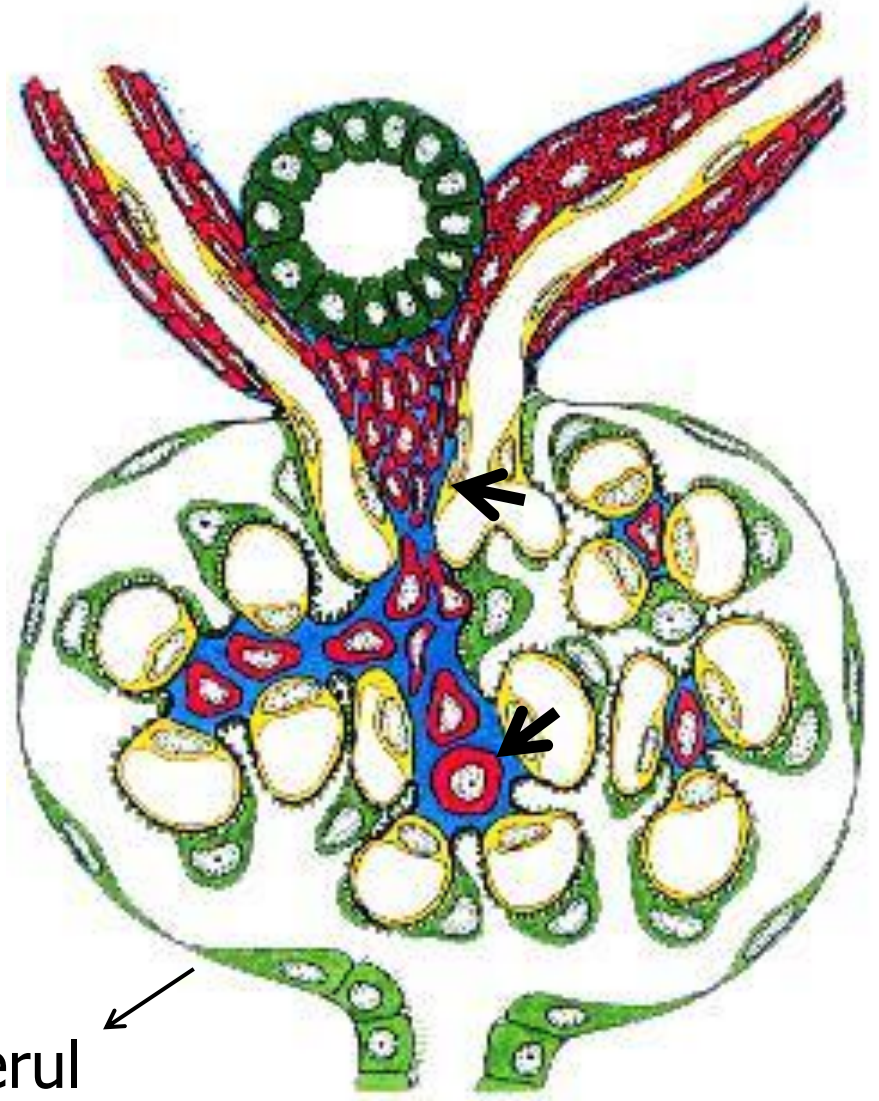
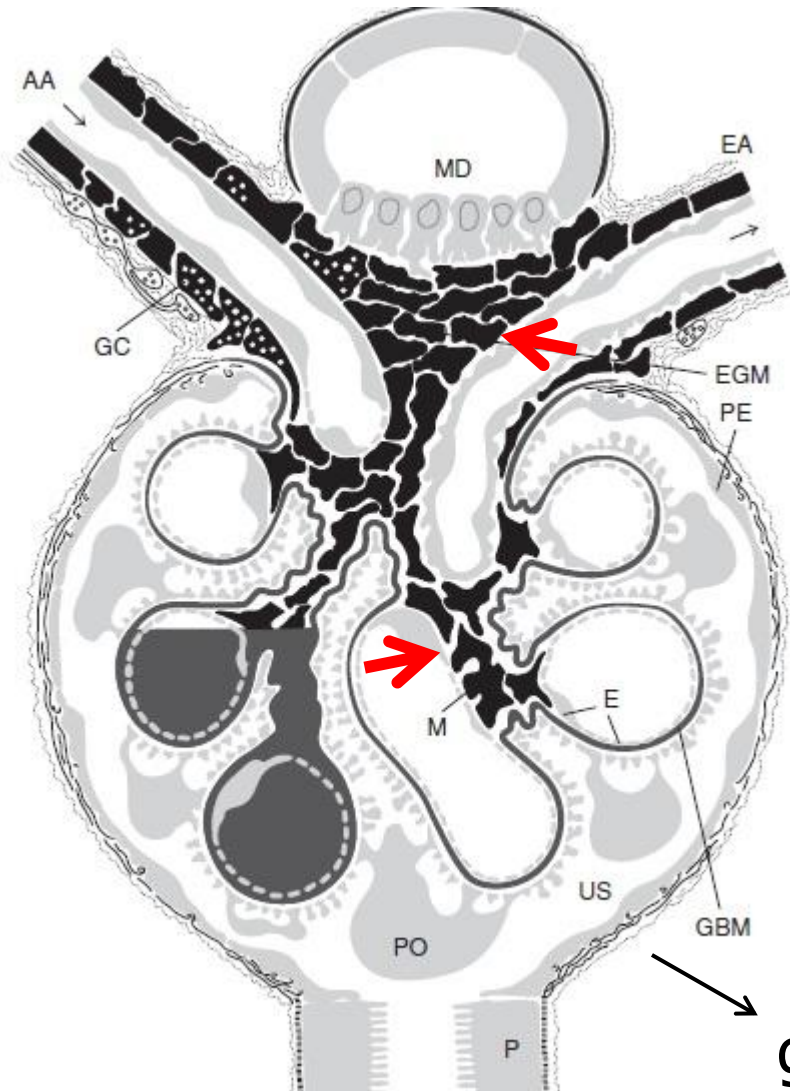


Doku Yerleşik Makrofaj : Mikroglia

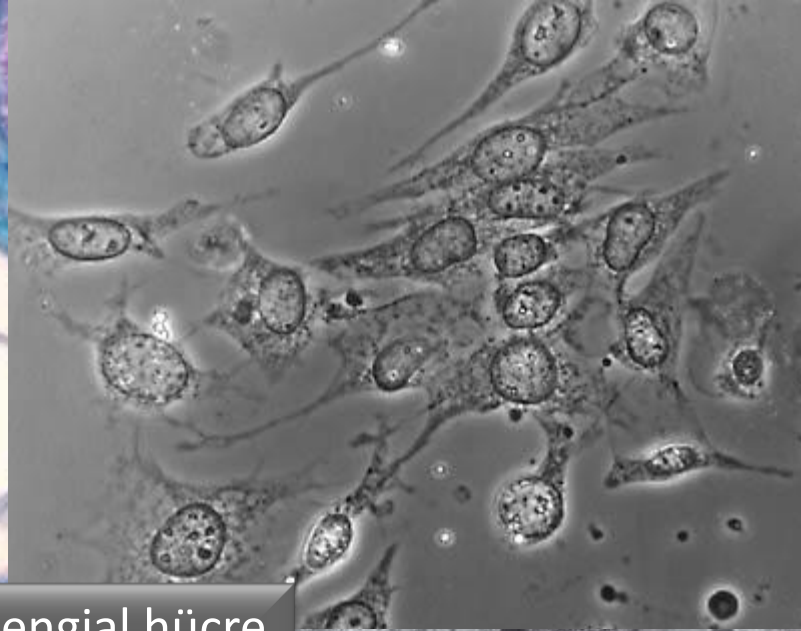
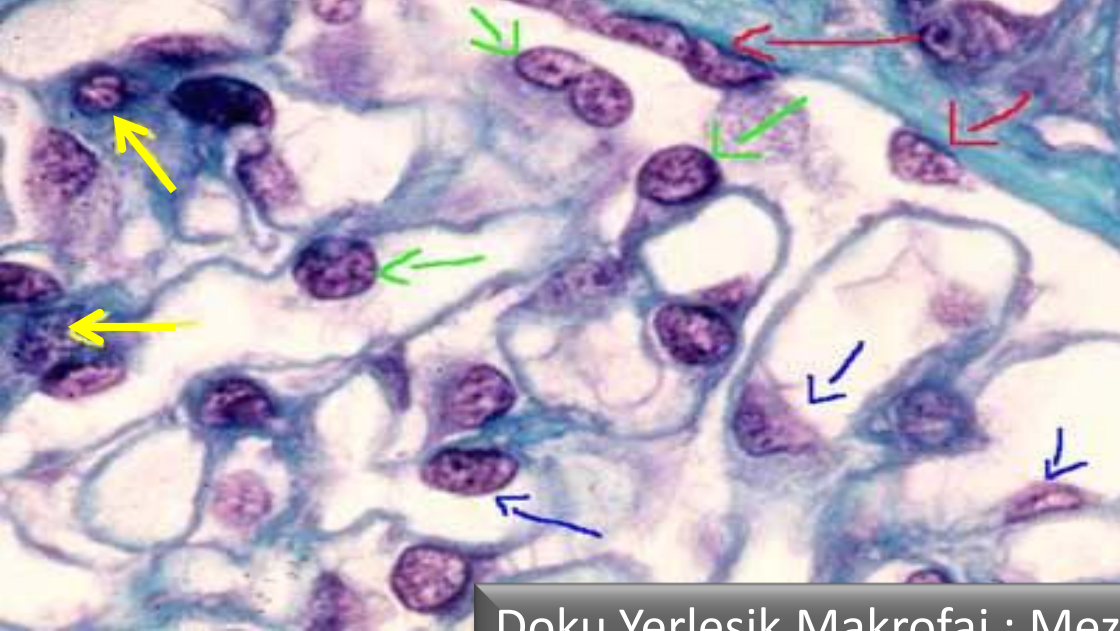


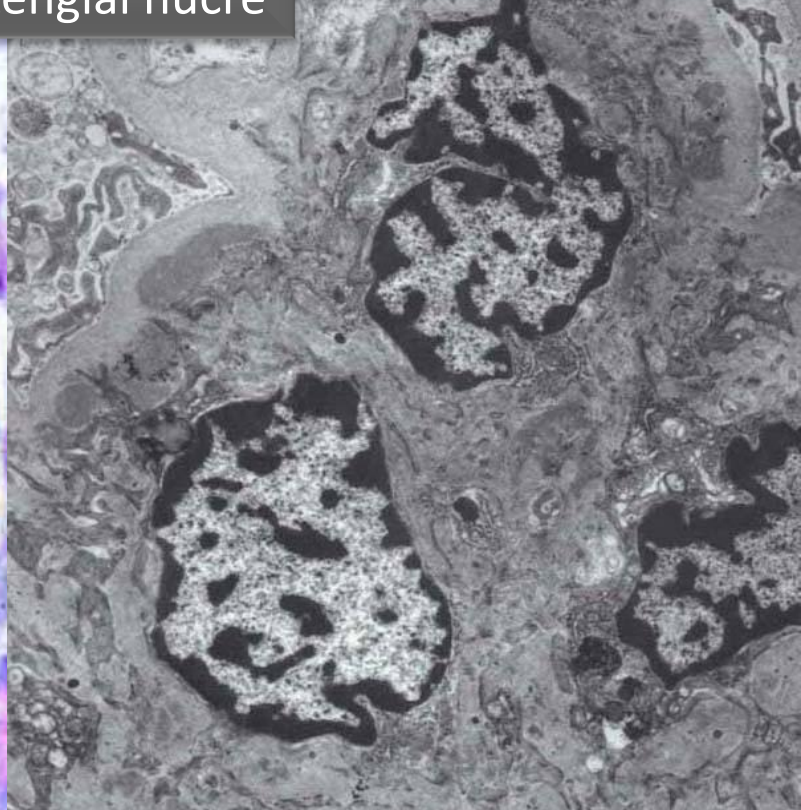
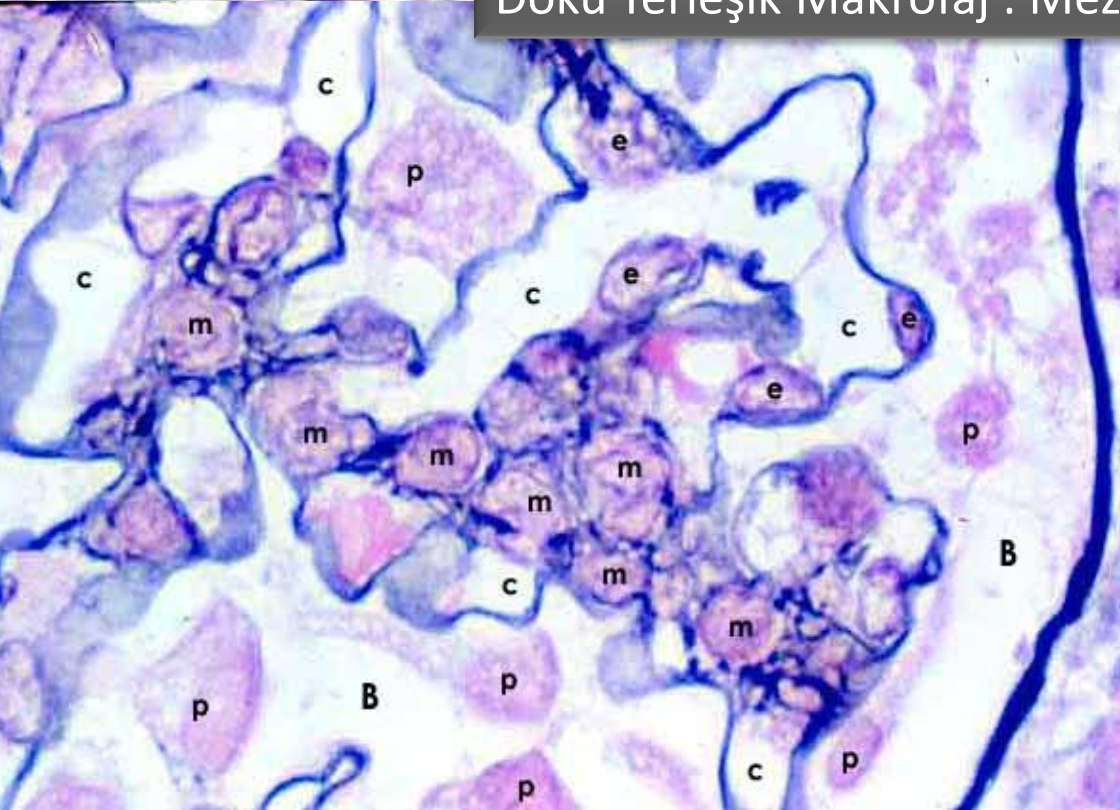
# Doku Yerleşik Makrofaj : Mezengial hücre



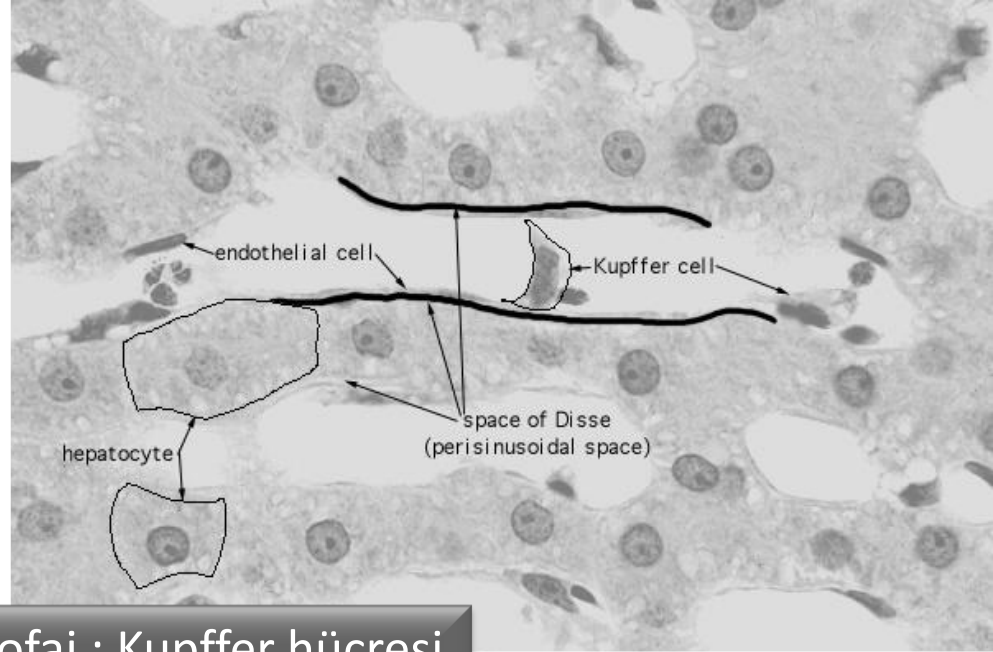
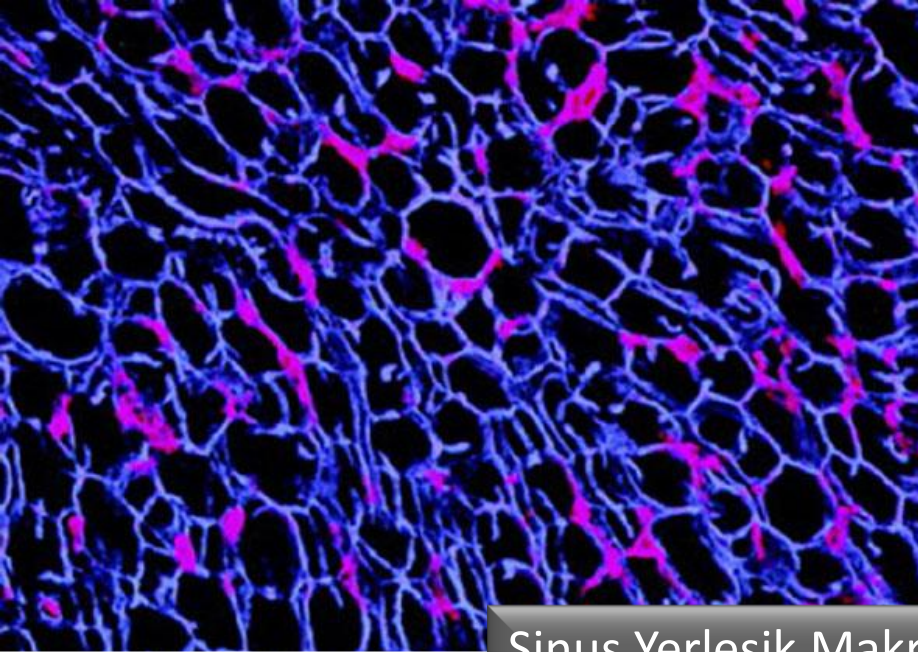




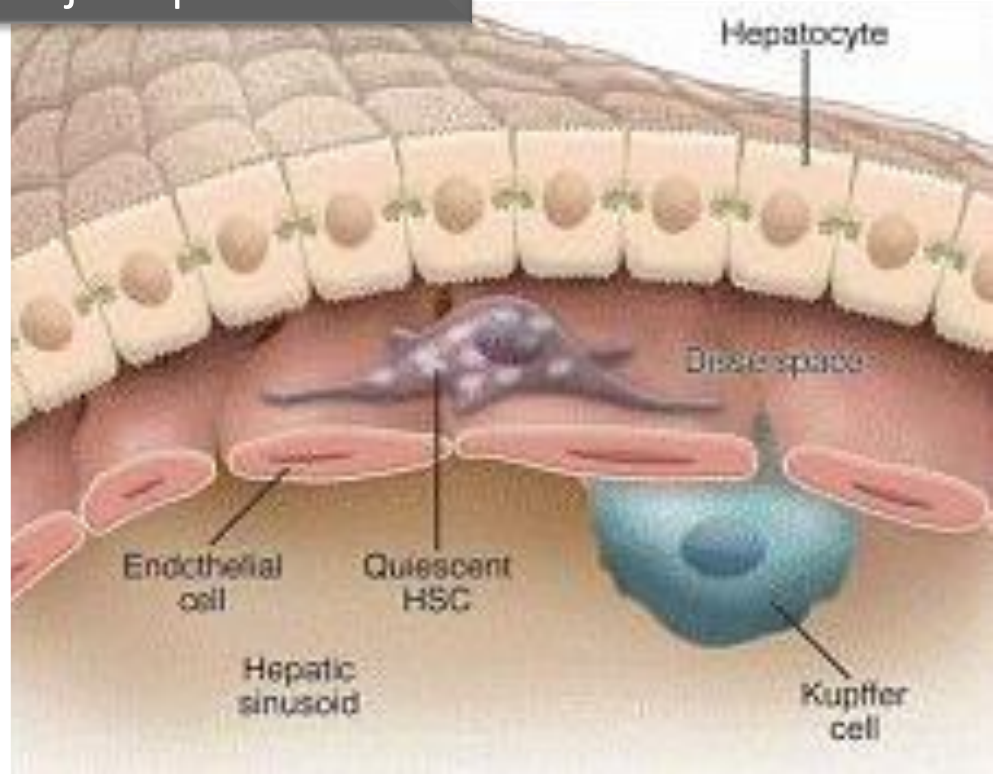
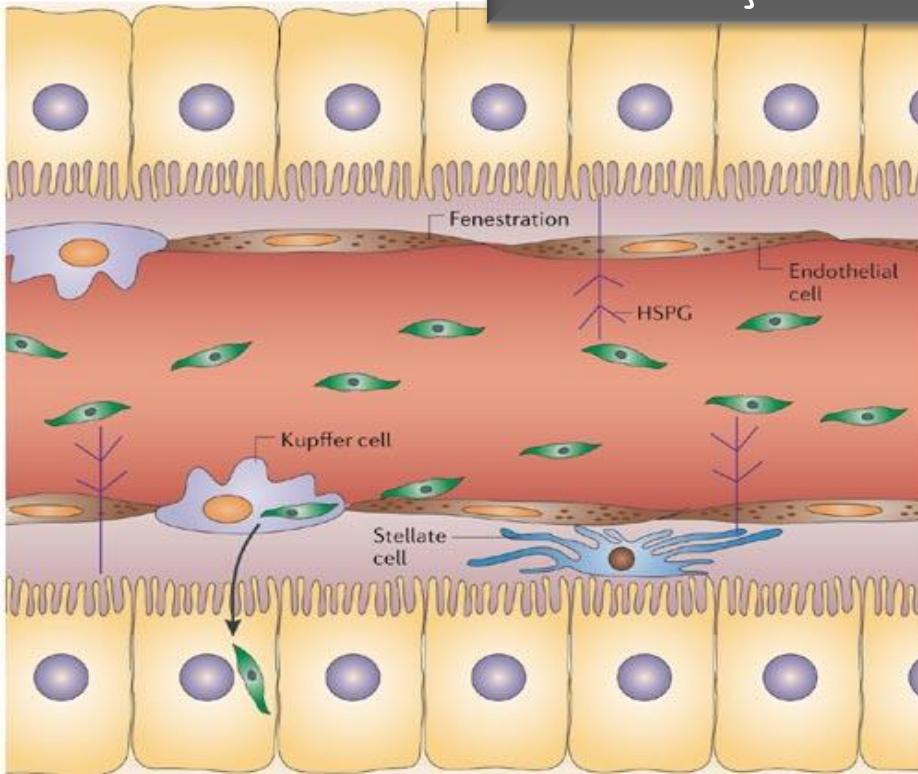
Doku Yerleşik Makrofaj : Mezengial hücre



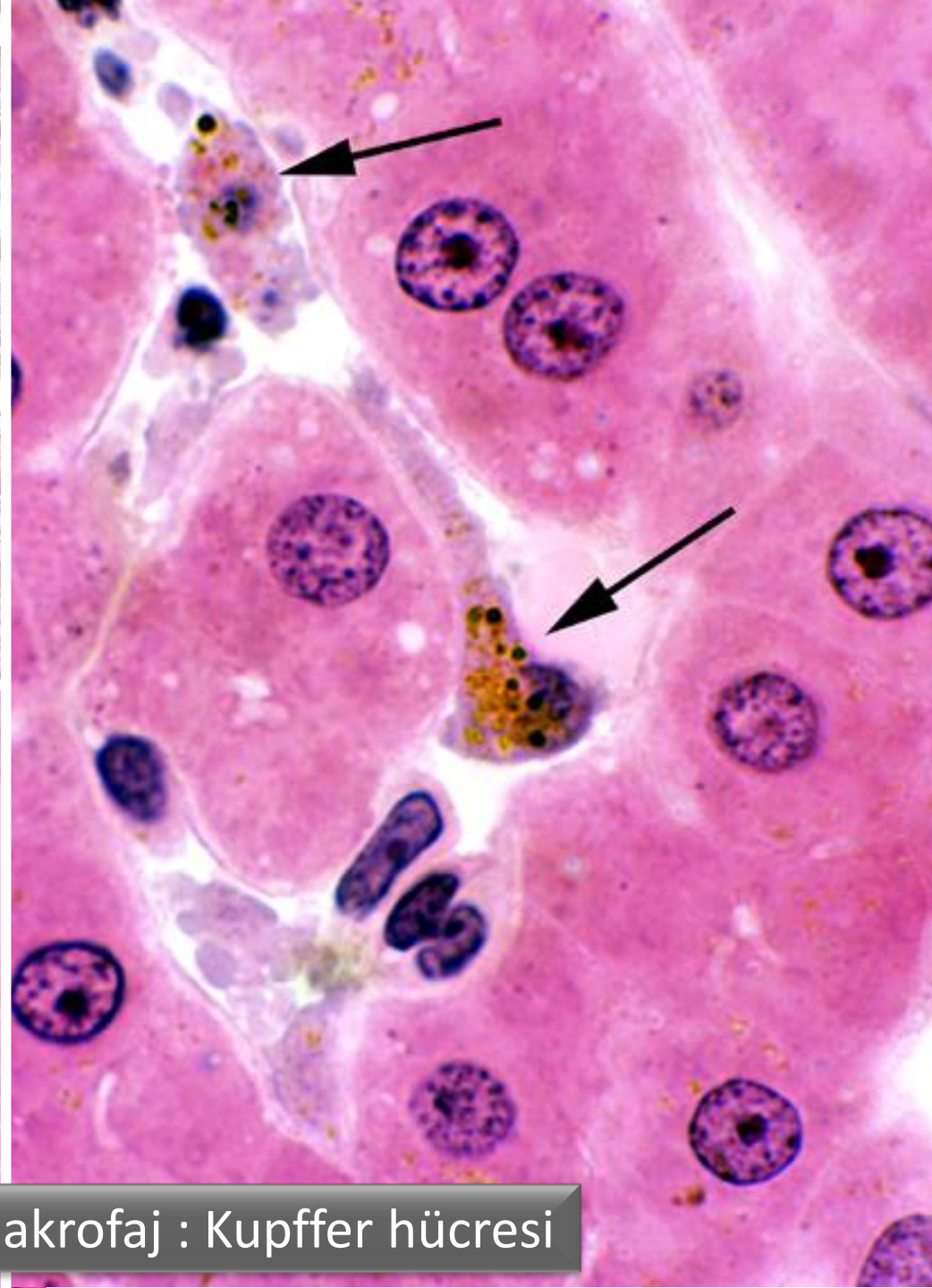
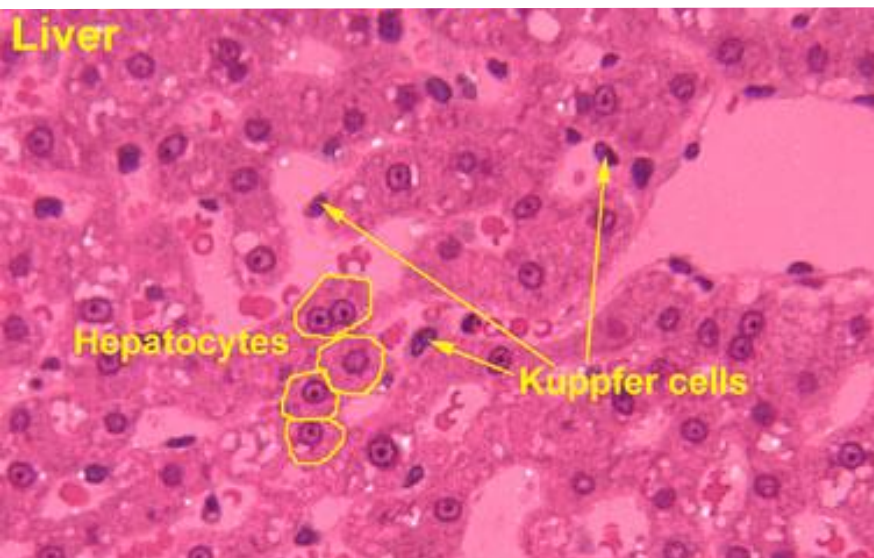
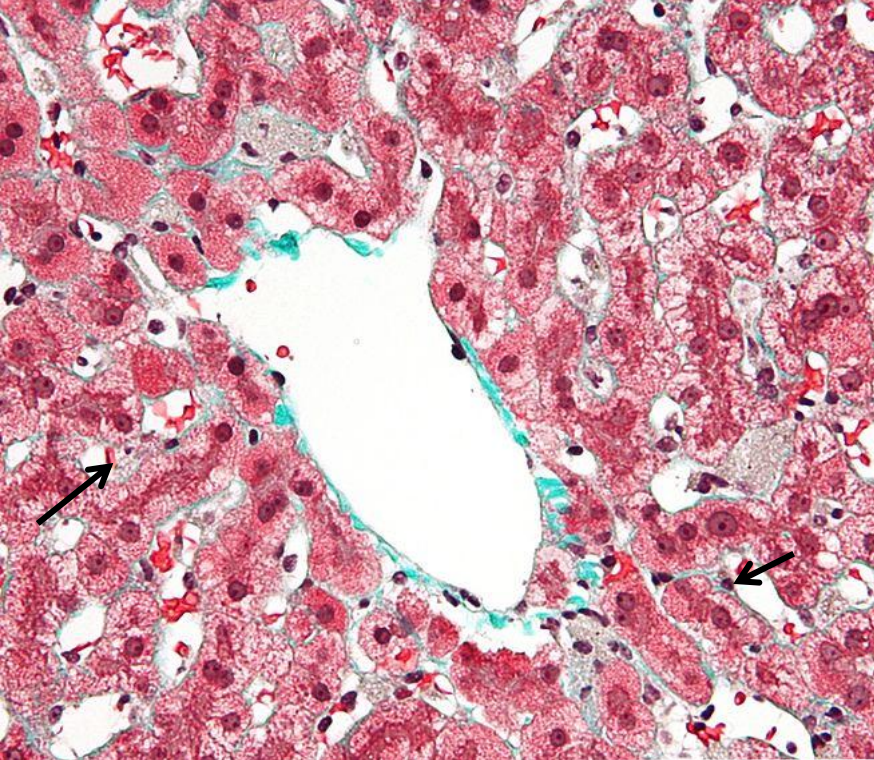




Sinus Yerleşik Makrofaj : Kupffer hücresi







Sinus Yerleşik Makrofaj : Kupffer hücresi

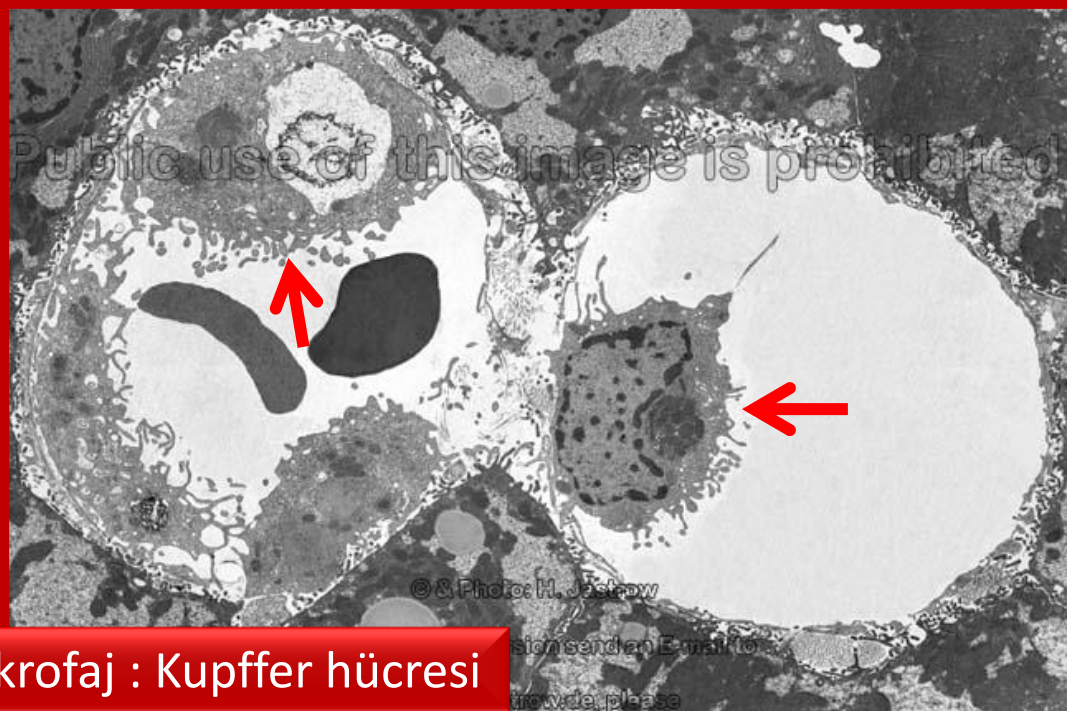
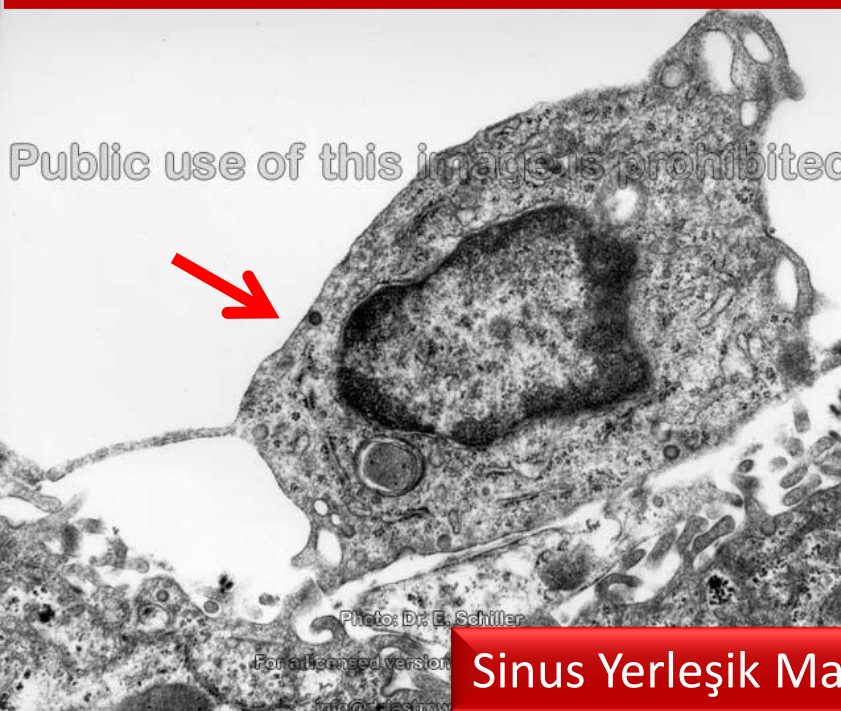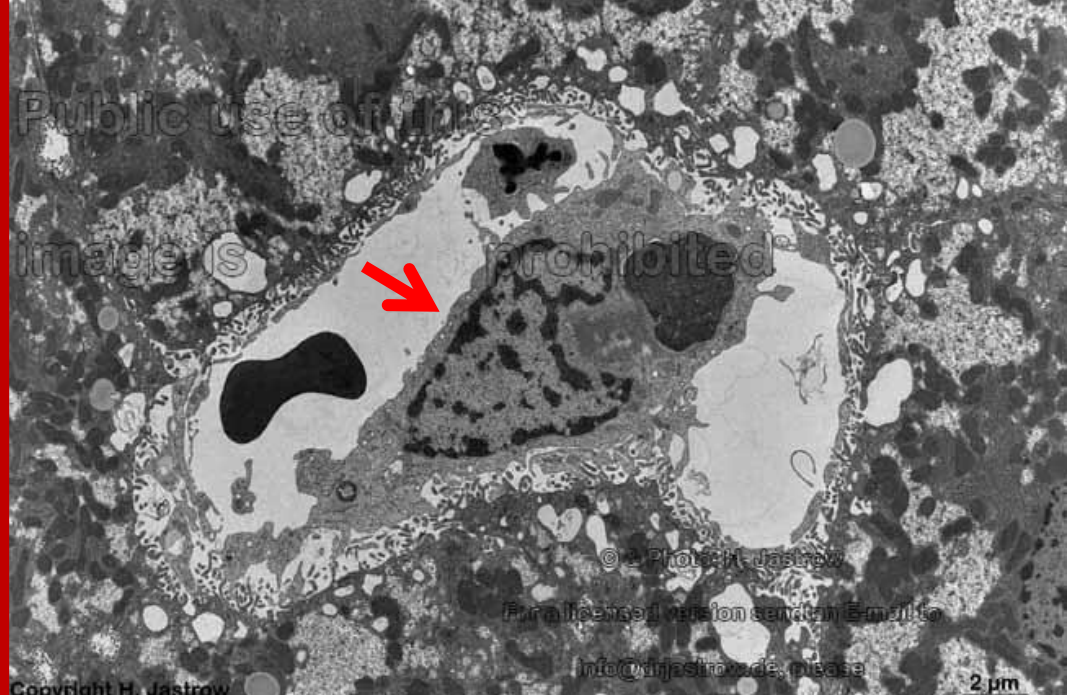
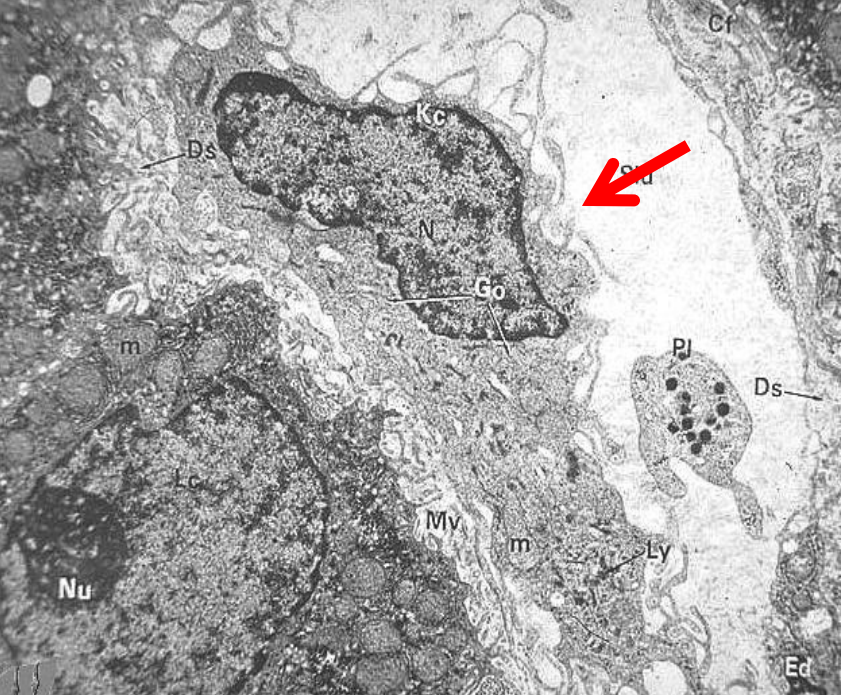




Sinus Yerleşik Makrofaj : Kupffer hücresi

This electron micrograph shows a cross-section of a liver sinusoid. The upper portion of the image displays the sinusoidal space, characterized by large, dark, electron-dense areas representing red blood cells. Below this, a layer of sinusoidal endothelium is visible, showing a distinct fenestrated (pore) structure. The lower portion of the image shows a large, electron-dense cell, identified as a sinusoidal macrophage or Kupffer cell, which is situated within the sinusoid. The cell's cytoplasm is filled with various organelles, including mitochondria and lysosomes, and it exhibits a characteristic ruffled border (microvilli) facing the sinusoidal space. A small circular logo is present in the bottom left corner of the image.





**Sinus Yerleşik Makrofaj : Kupffer hücresi**

1 µm

2 µm

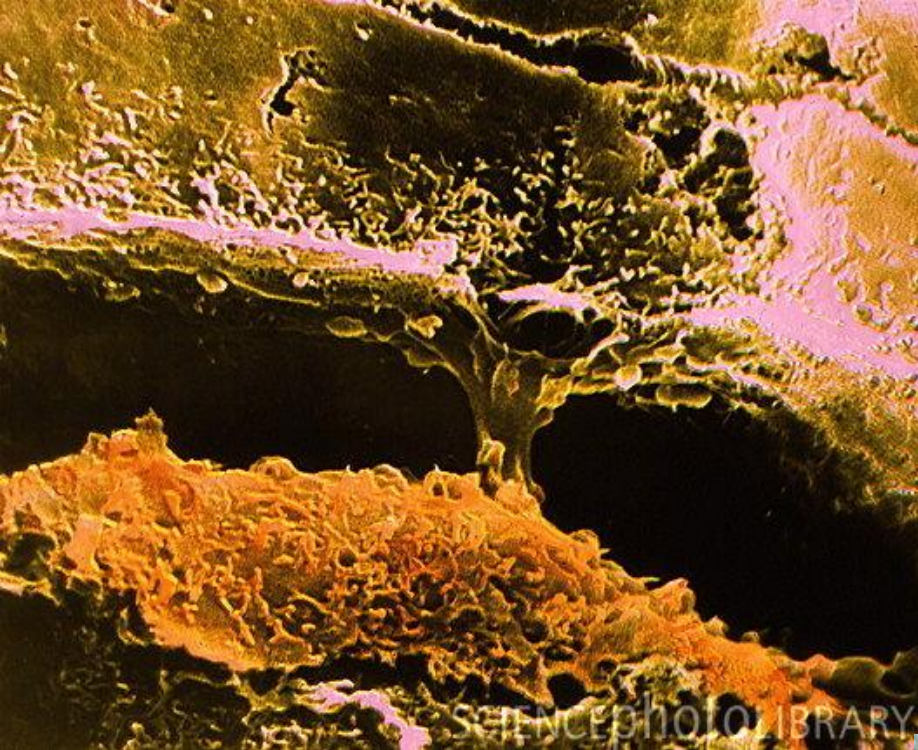
Copyright H. Jastrow

info@hastrow.de, please

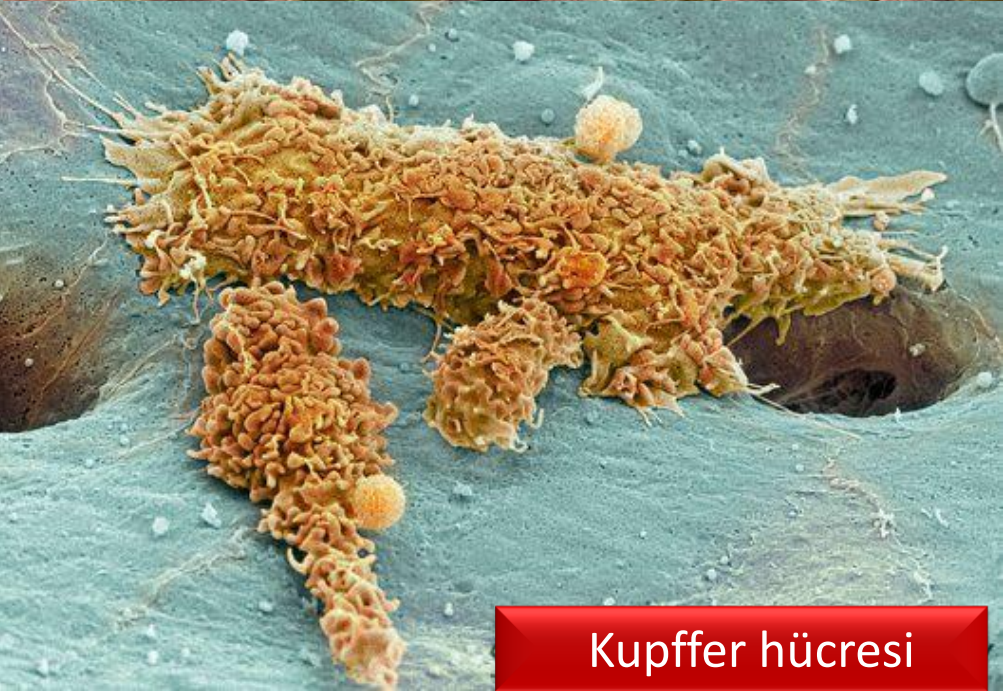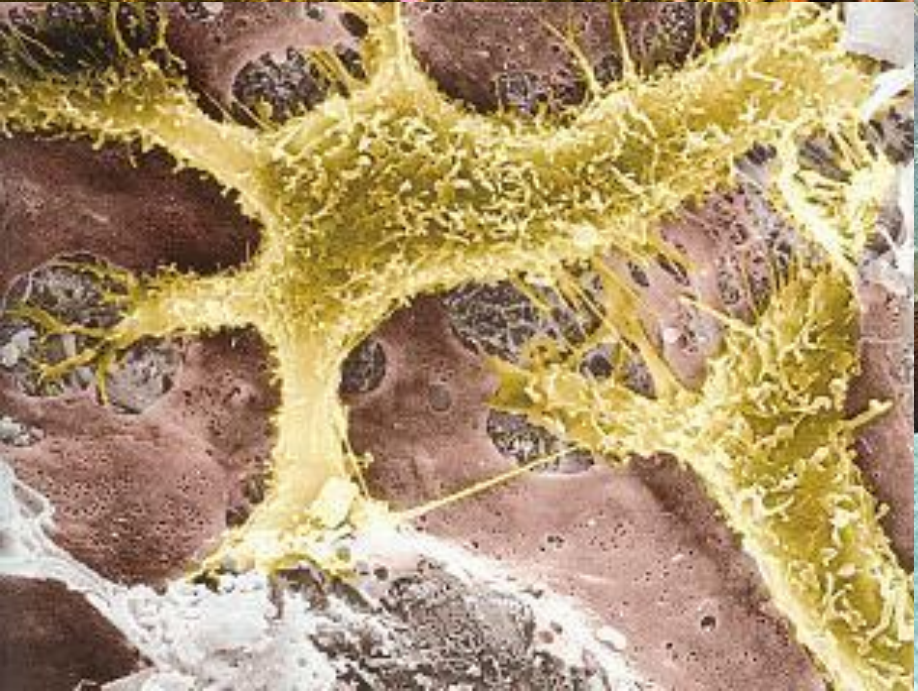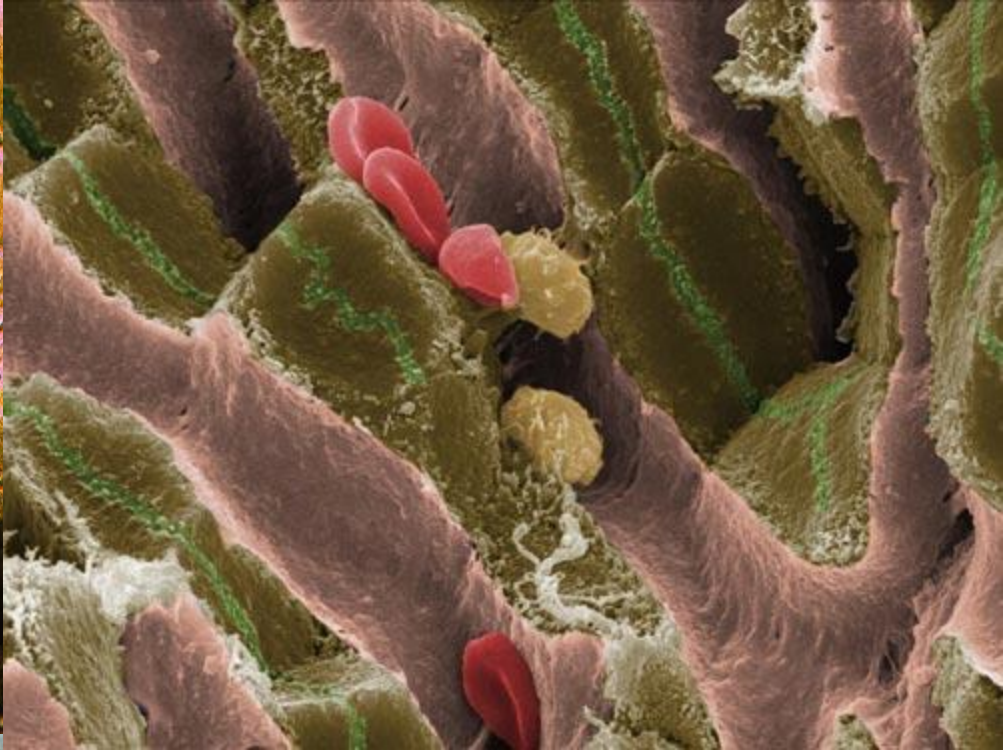
© & Photo: H. Jastrow

Copyright H. Jastrow



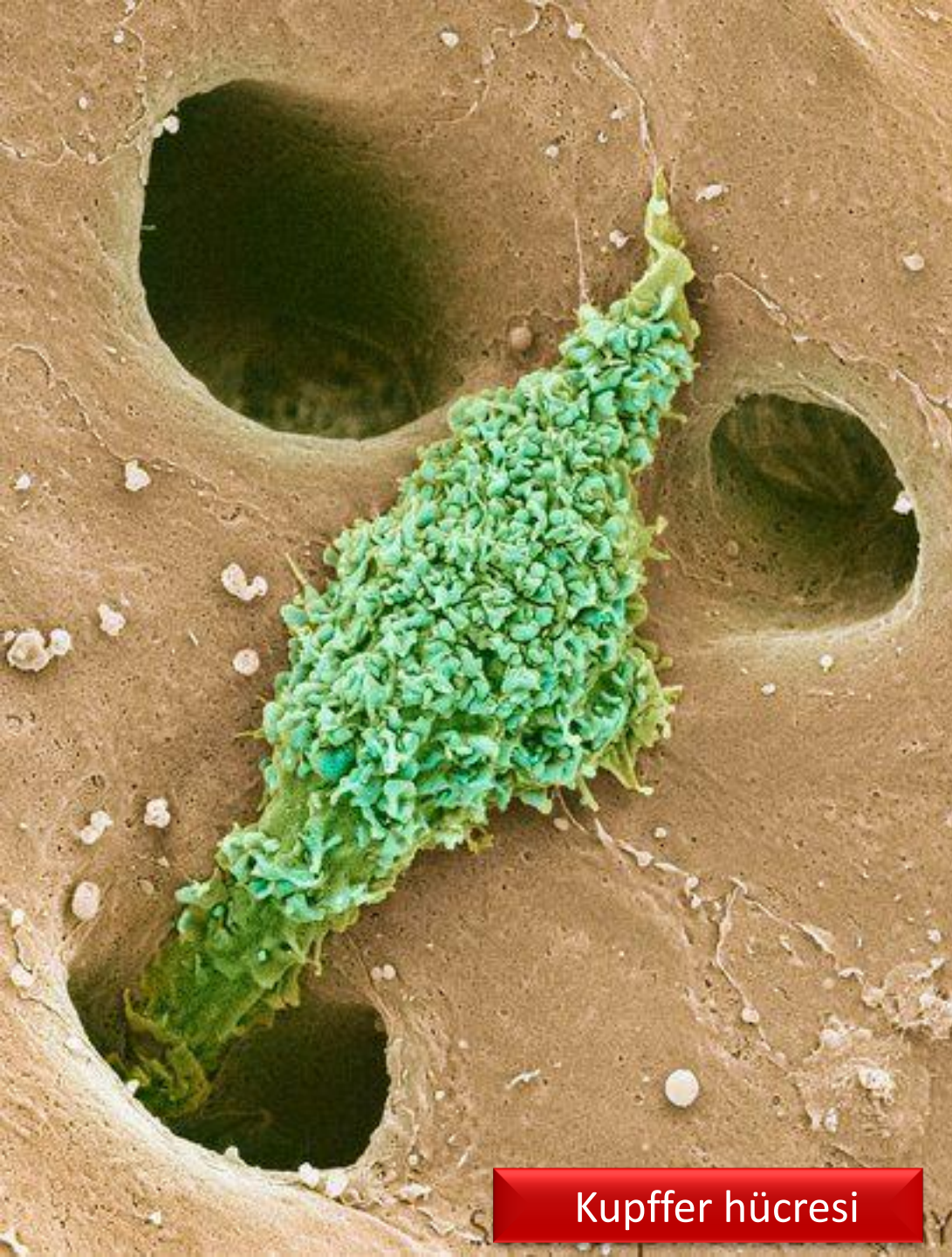


SCIENCEPHOTO LIBRARY

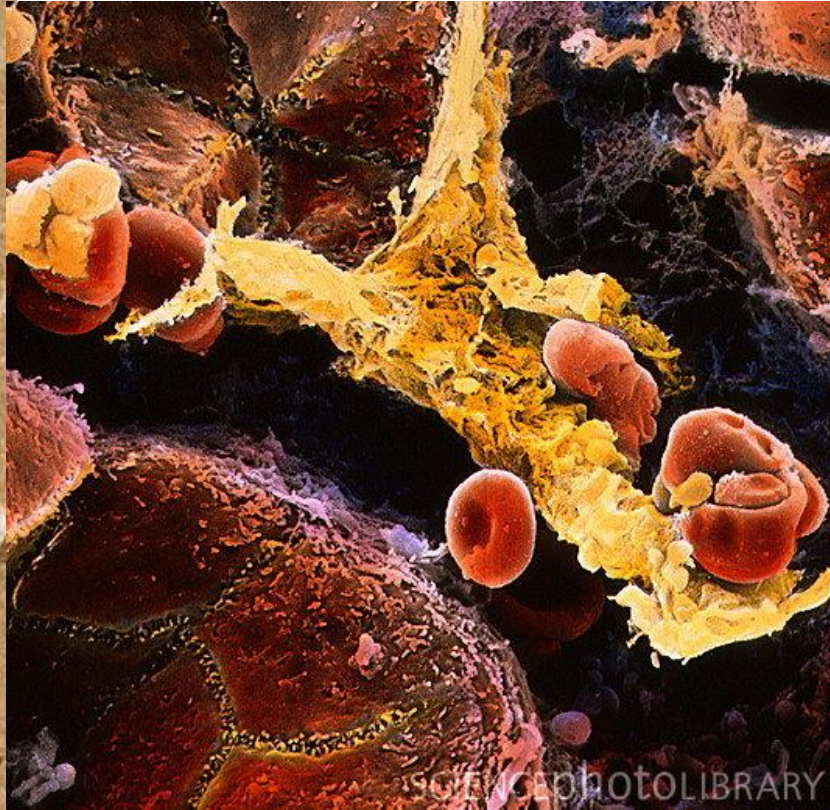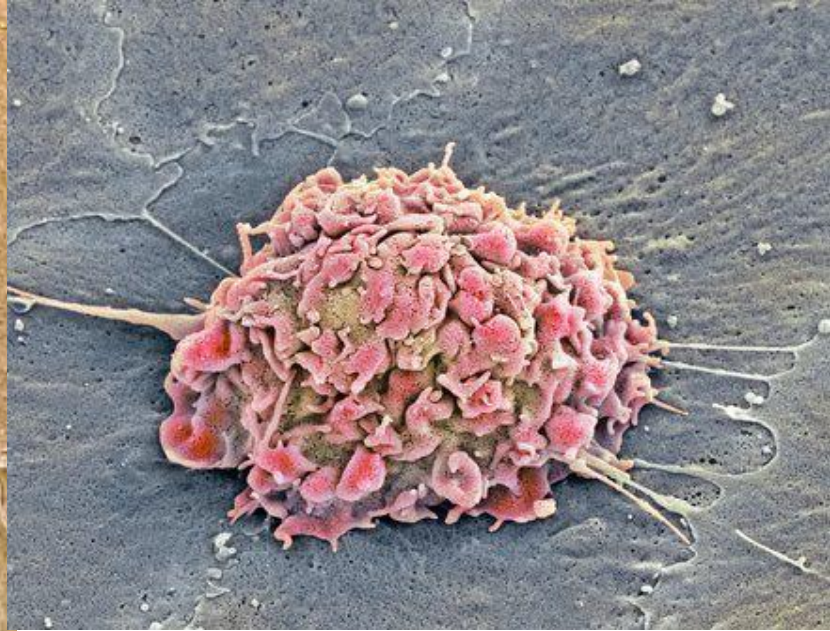


Kupffer hücresi

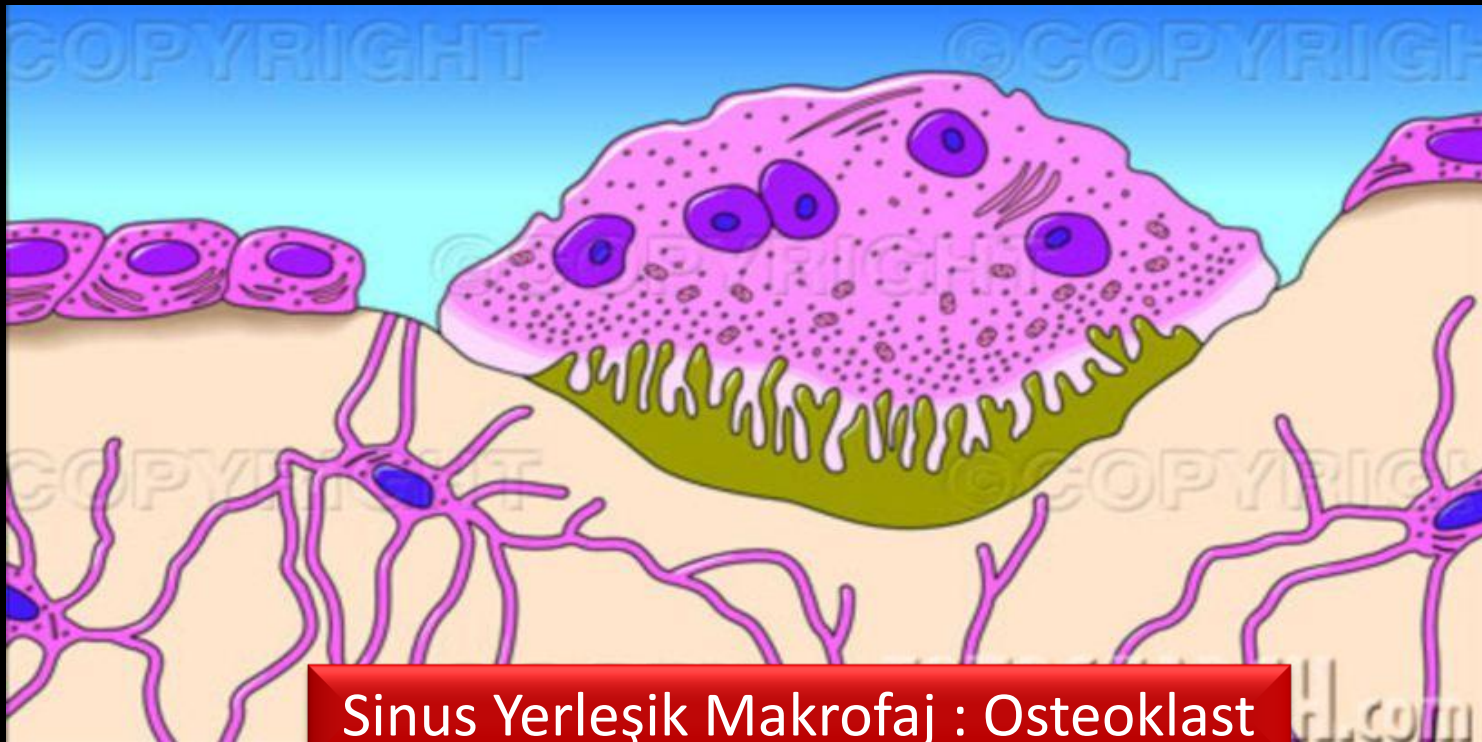



Kupffer hücresi





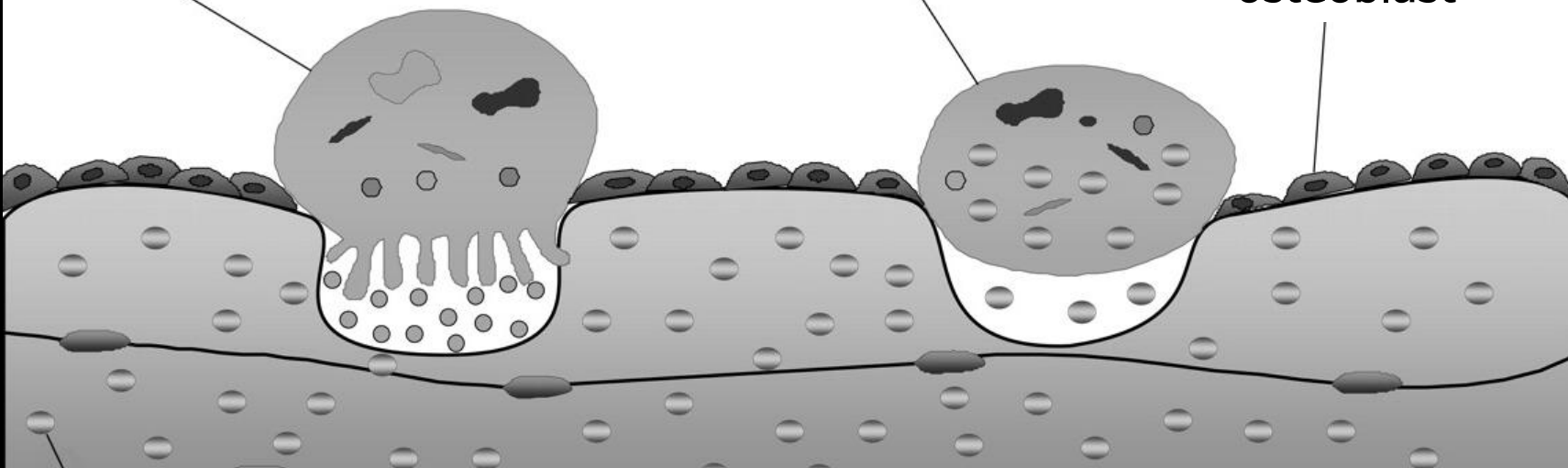


Sinus Yerleşik Makrofaj : Osteoklast

osteoklast

inaktif osteoklast

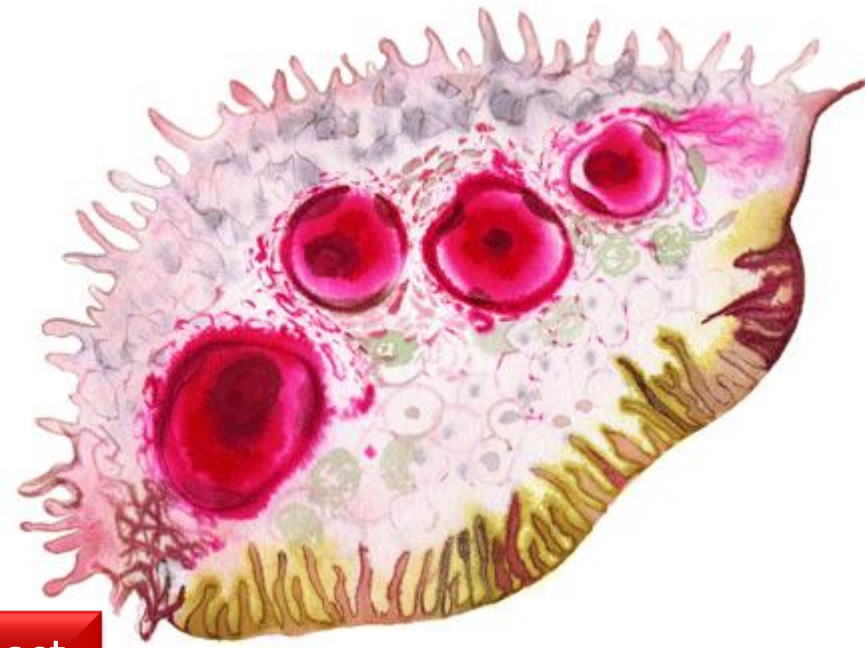
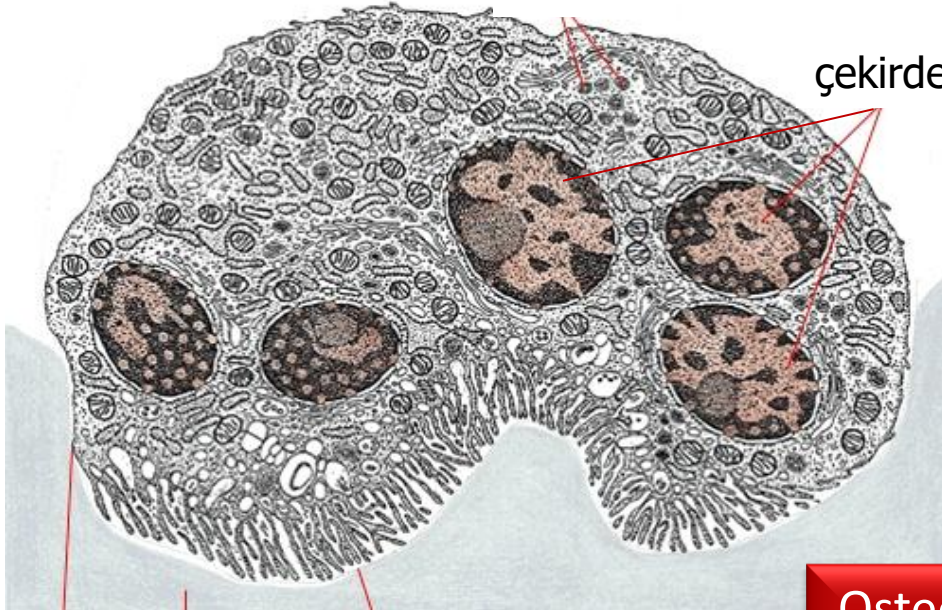
osteoblast





lizozom

çekirdek




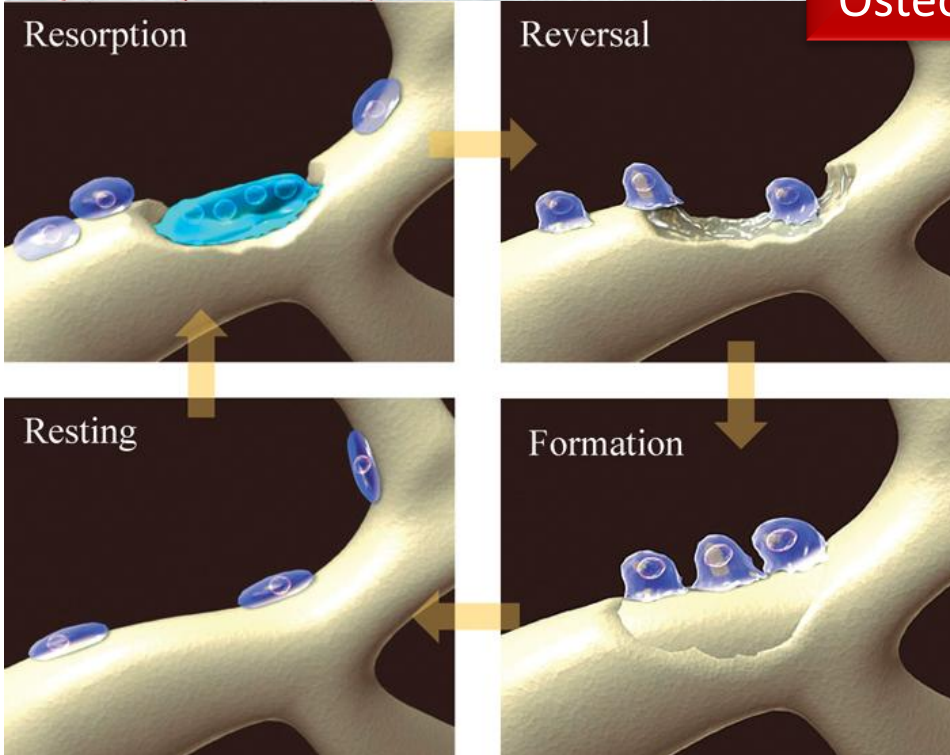
**Osteoklast**

Resorption

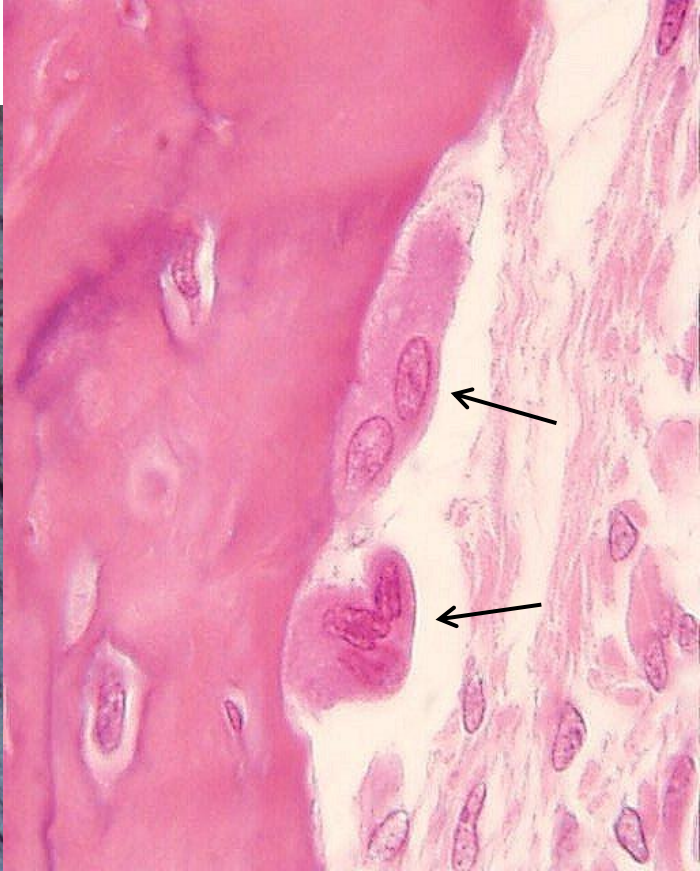
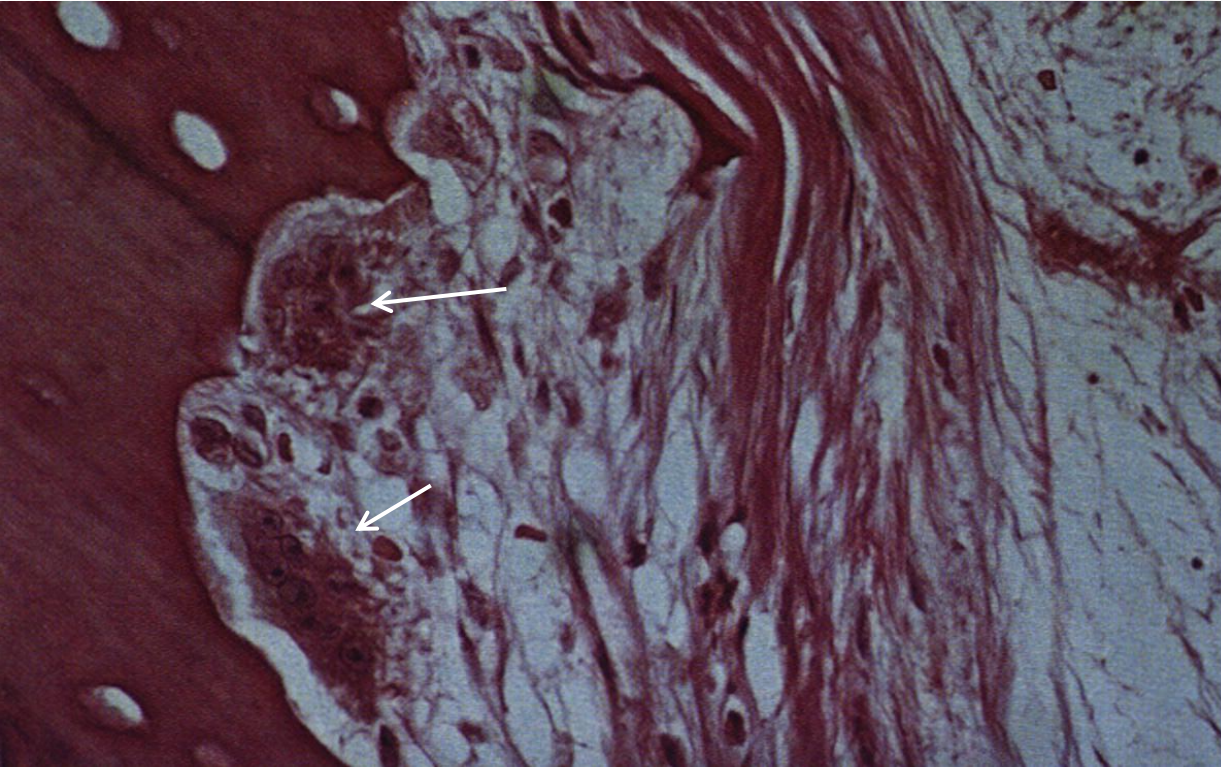
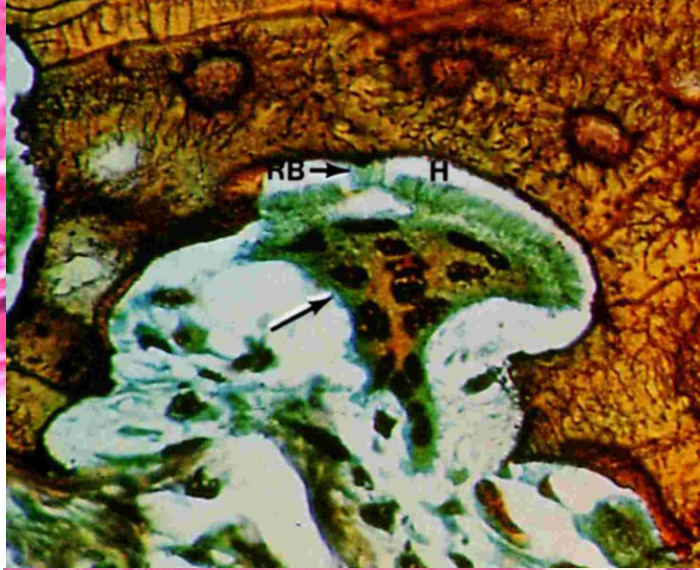
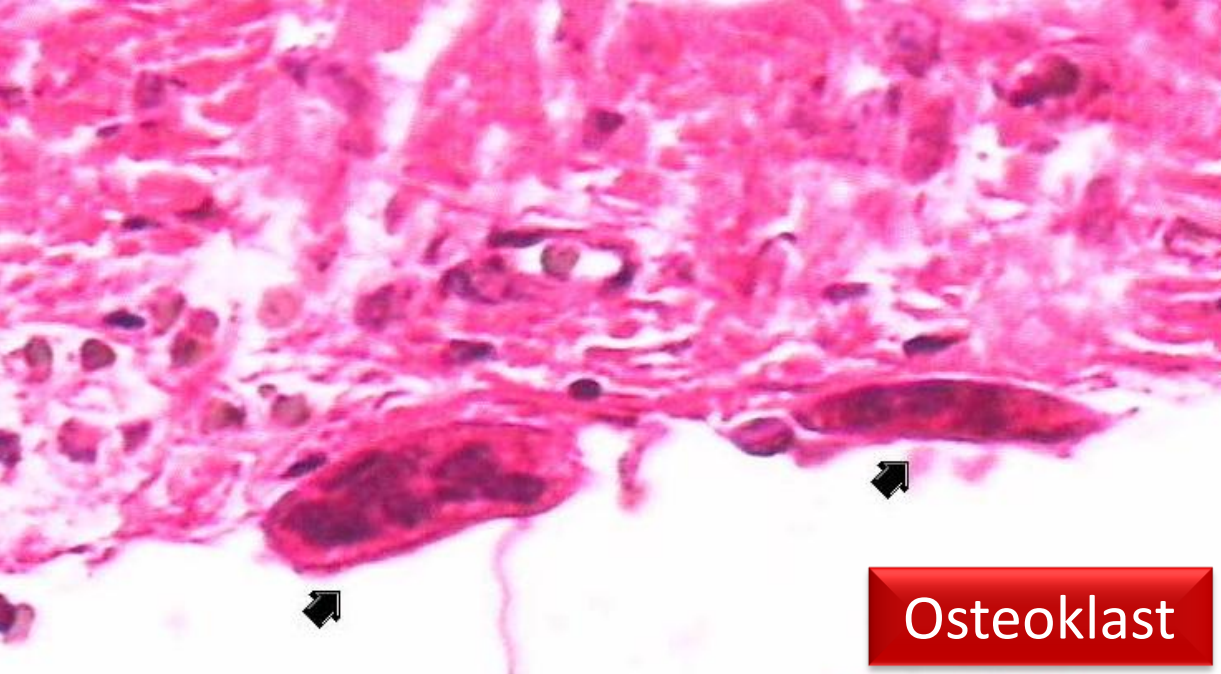
Reversal

Resting

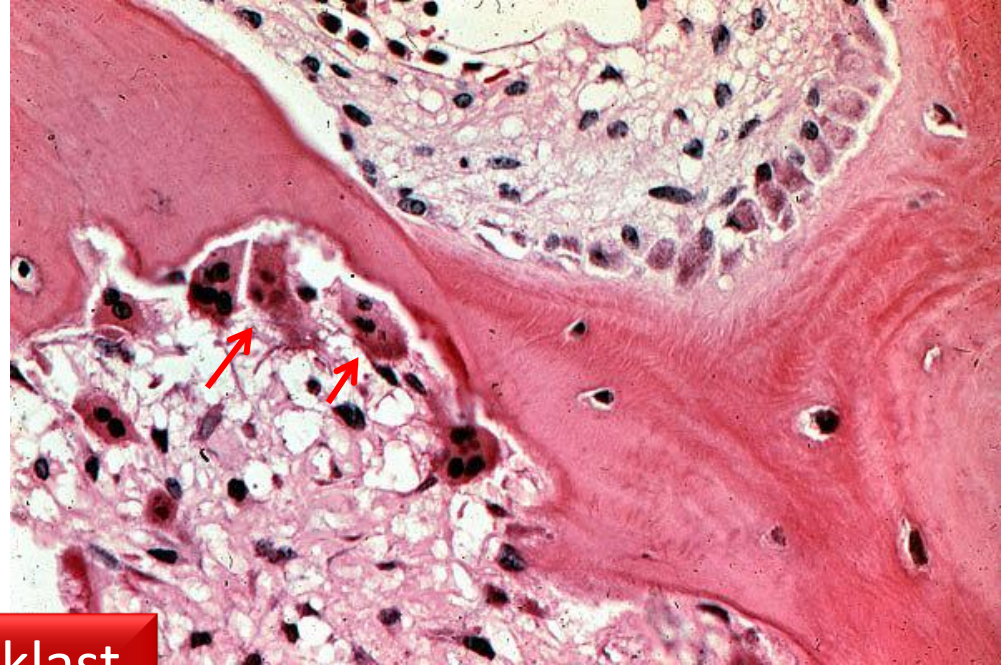
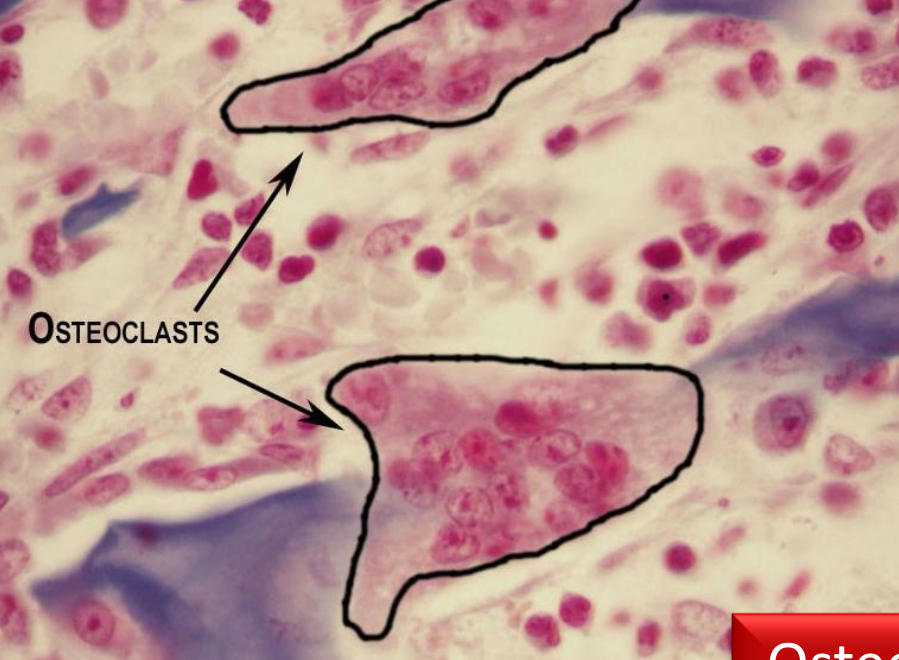Formation



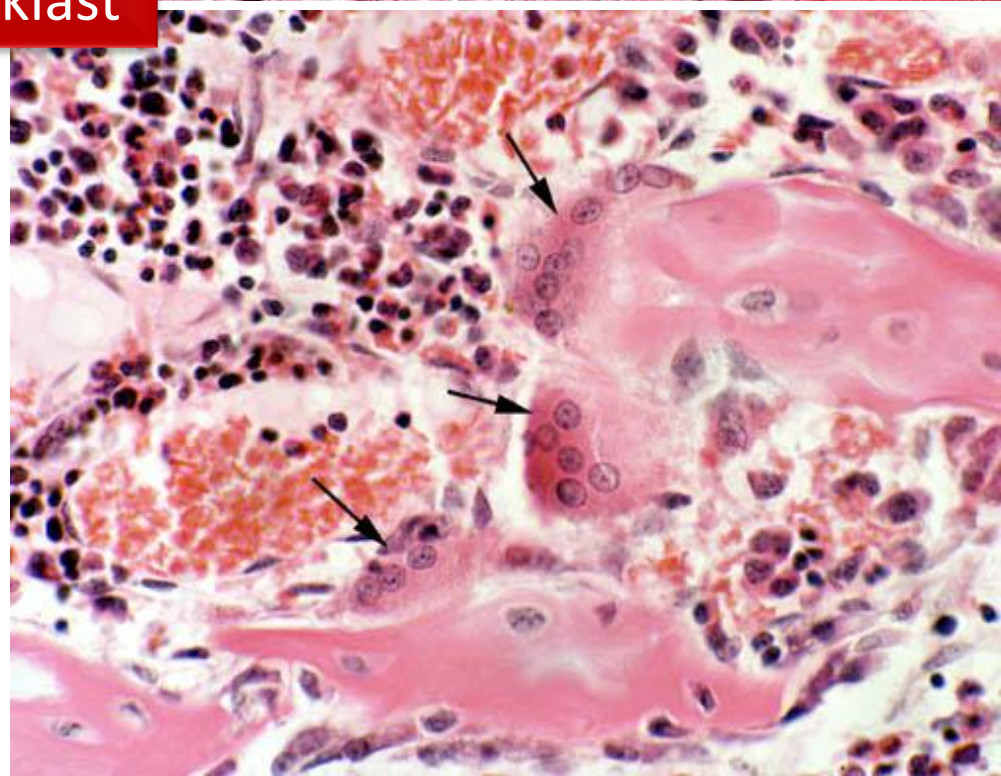
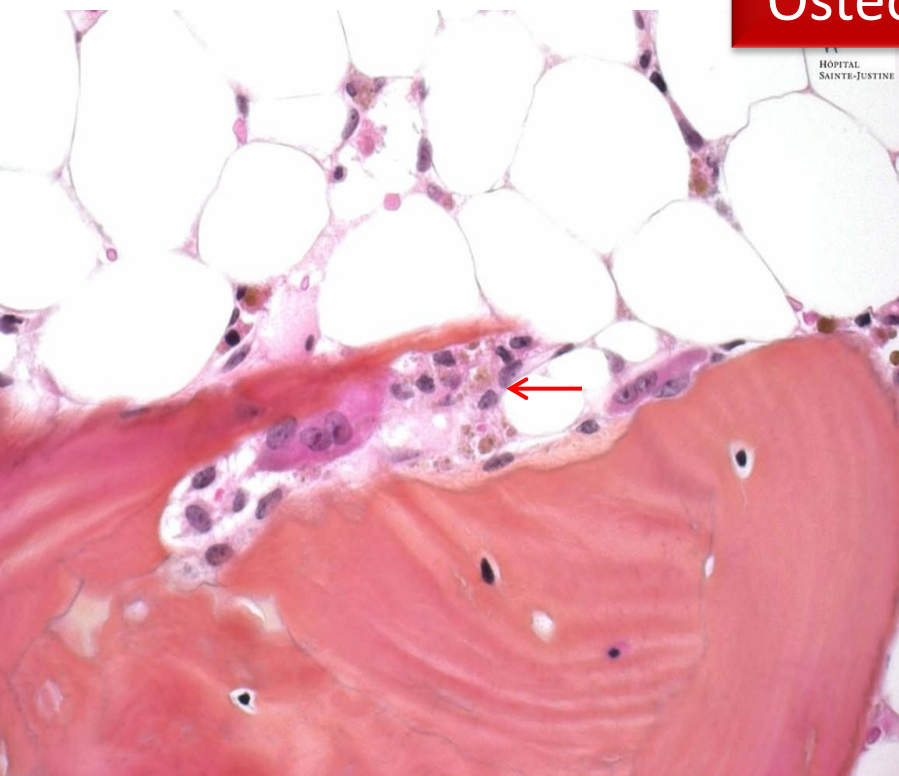




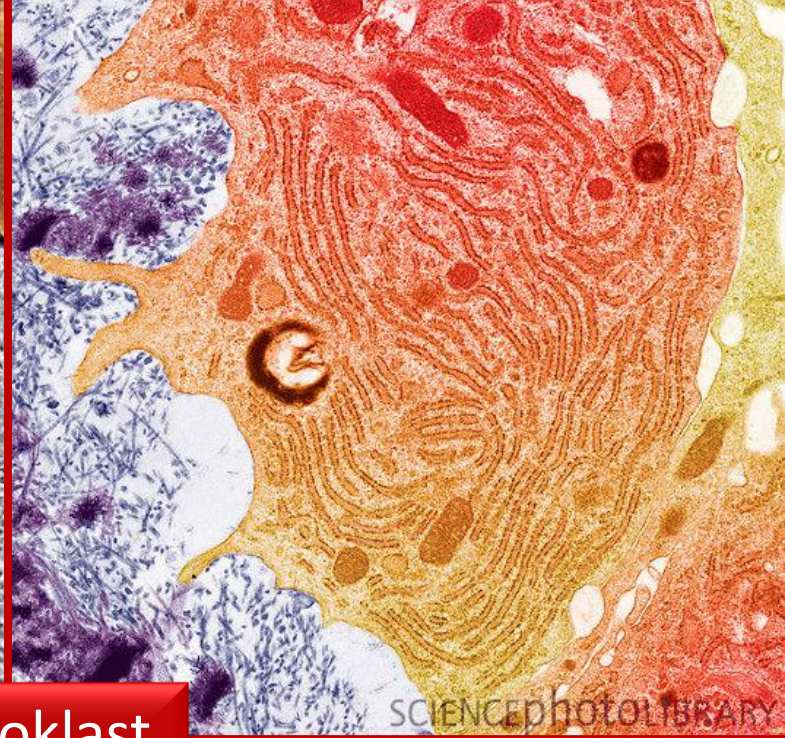
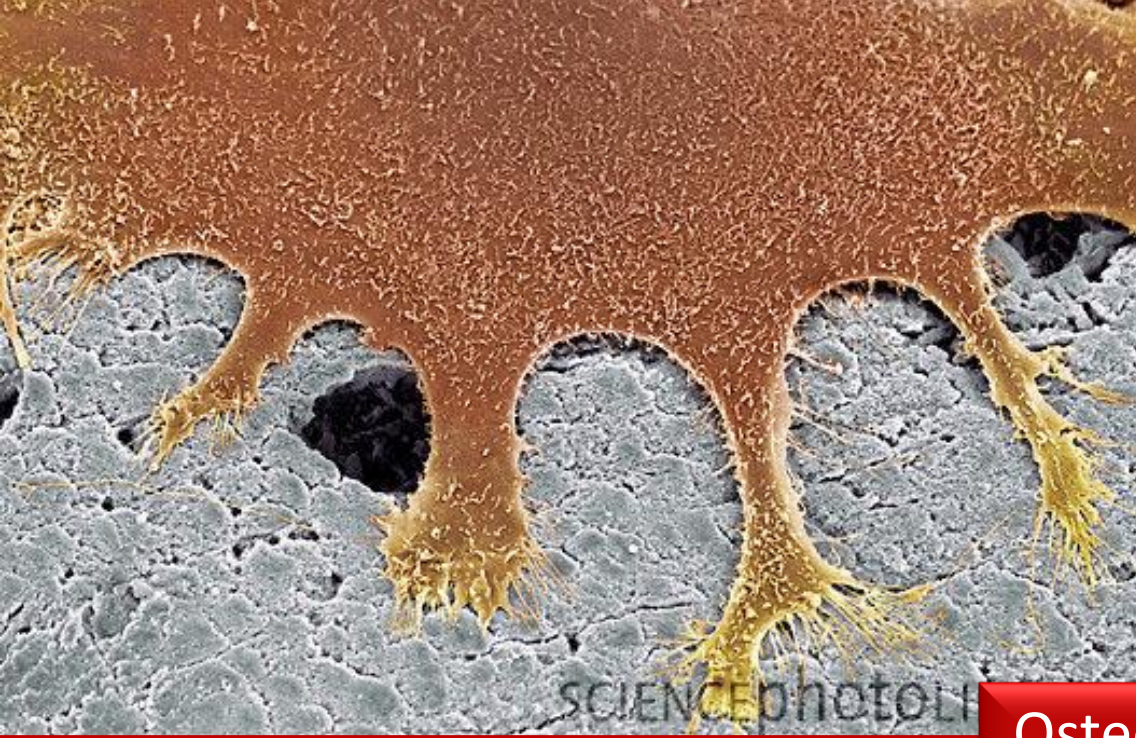



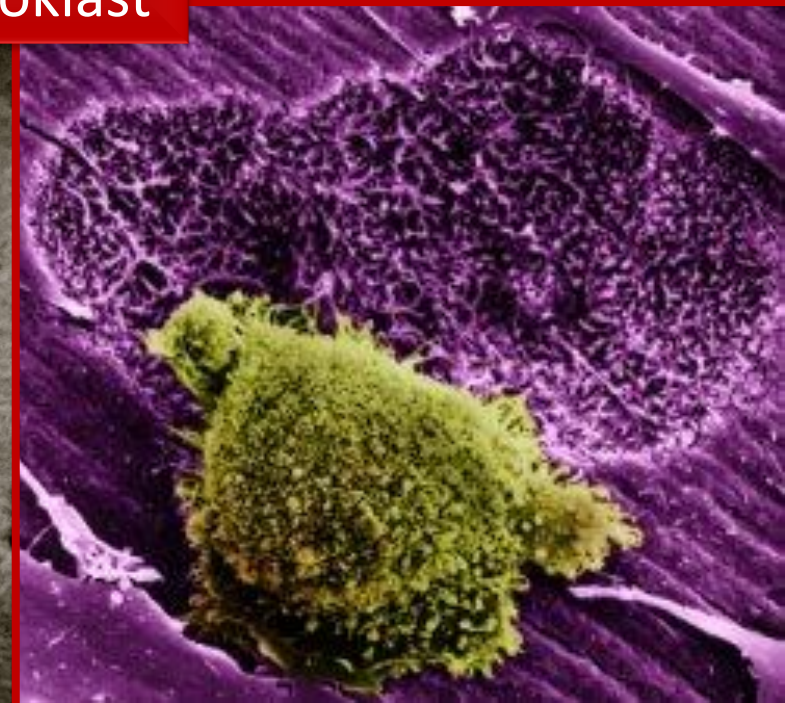
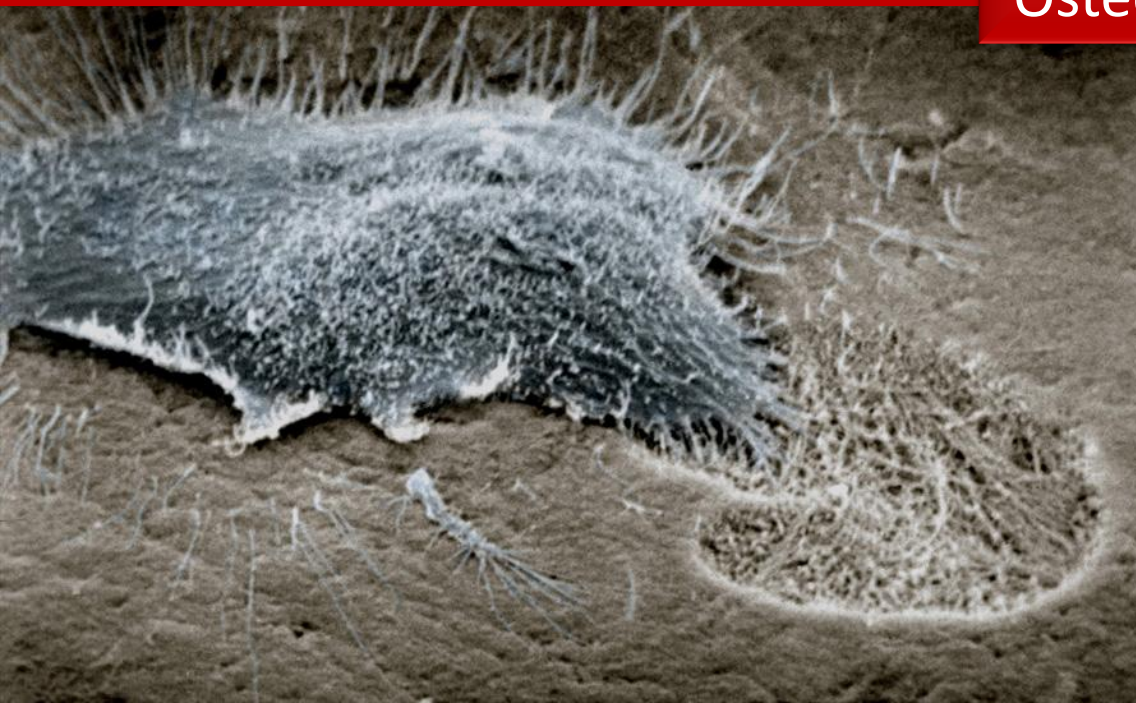
Osteoklast



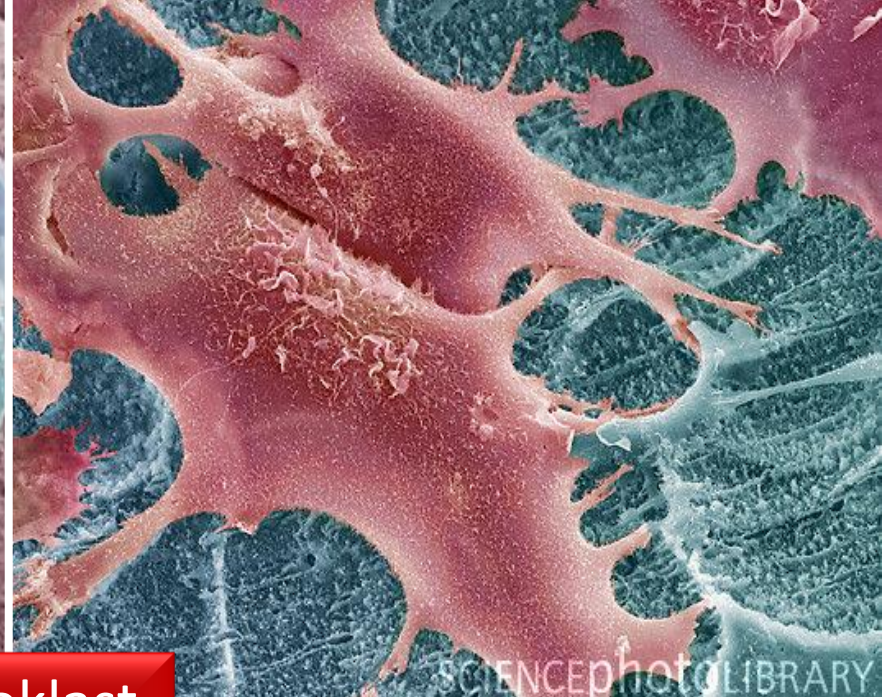
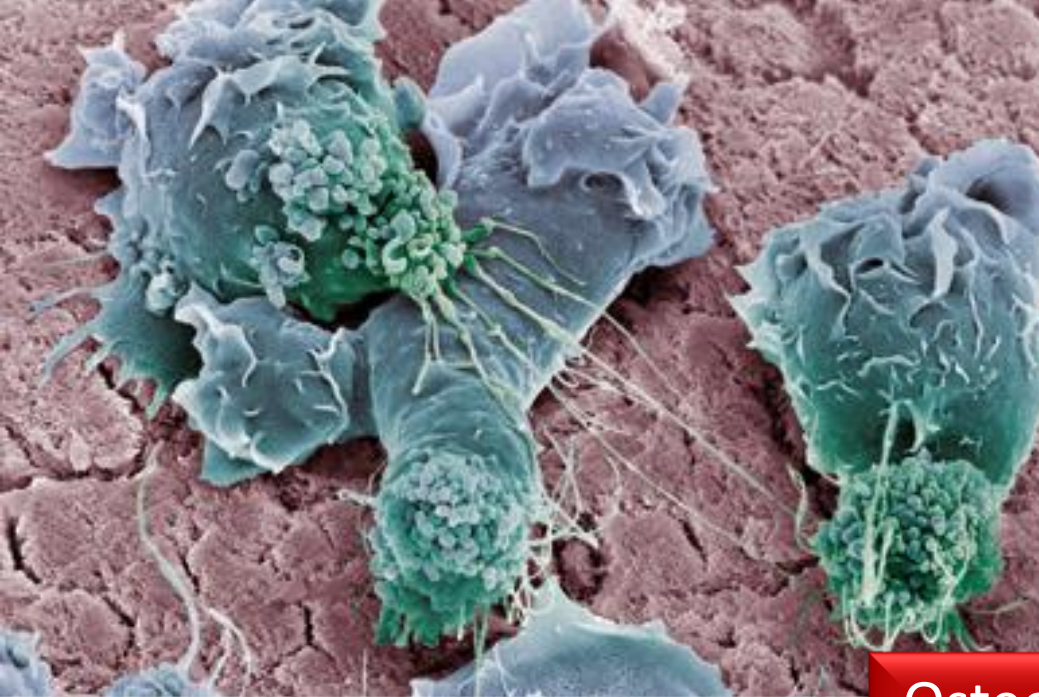




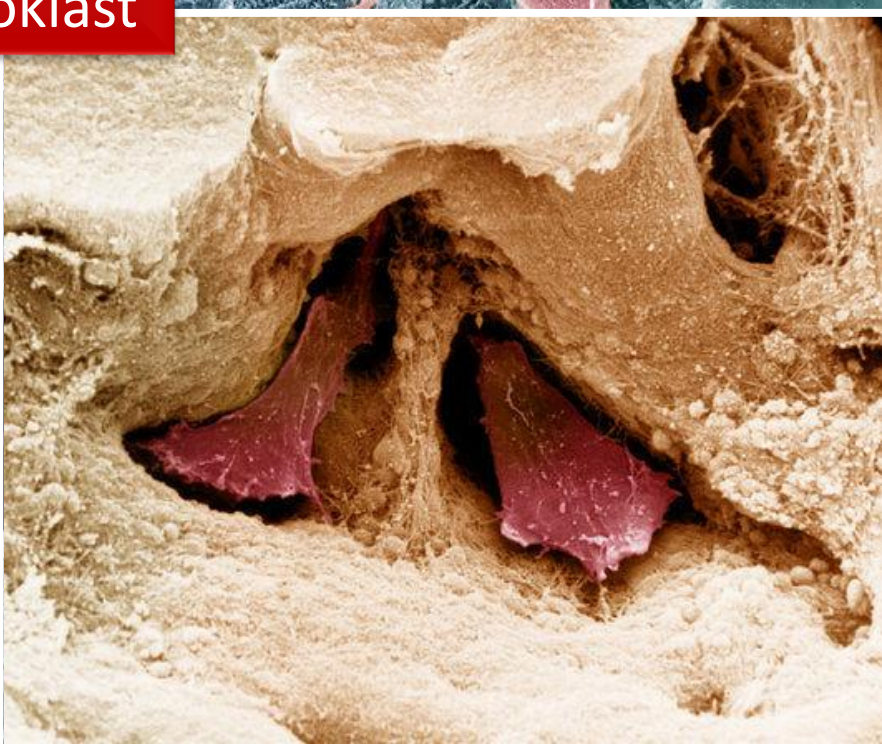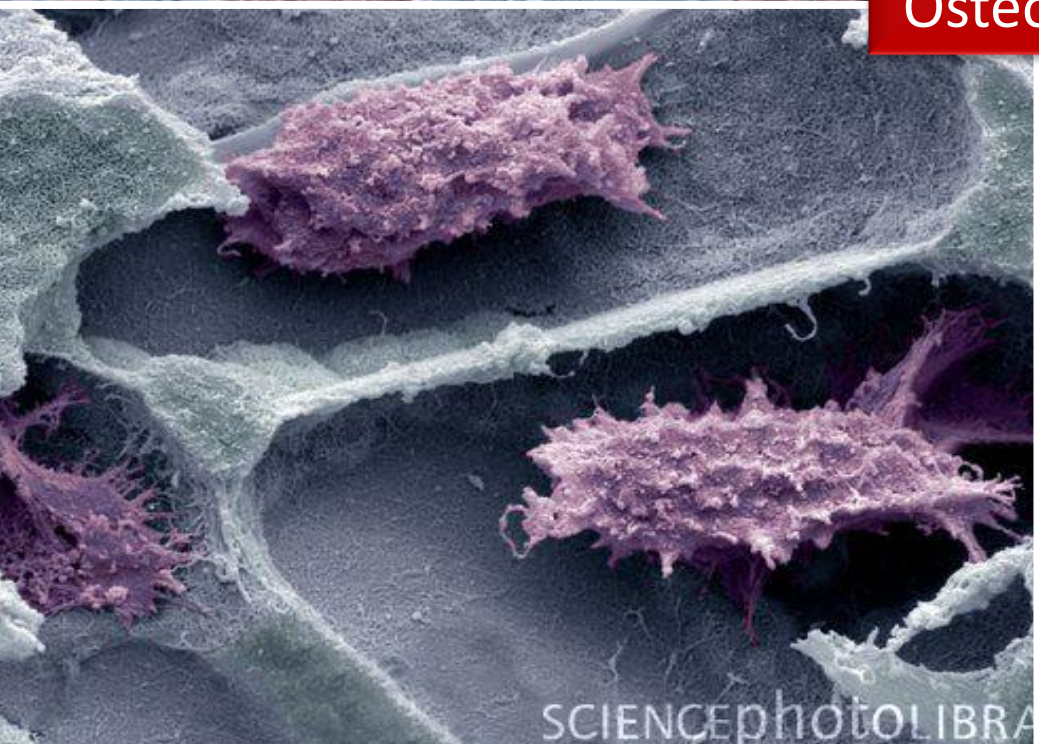
Osteoklast



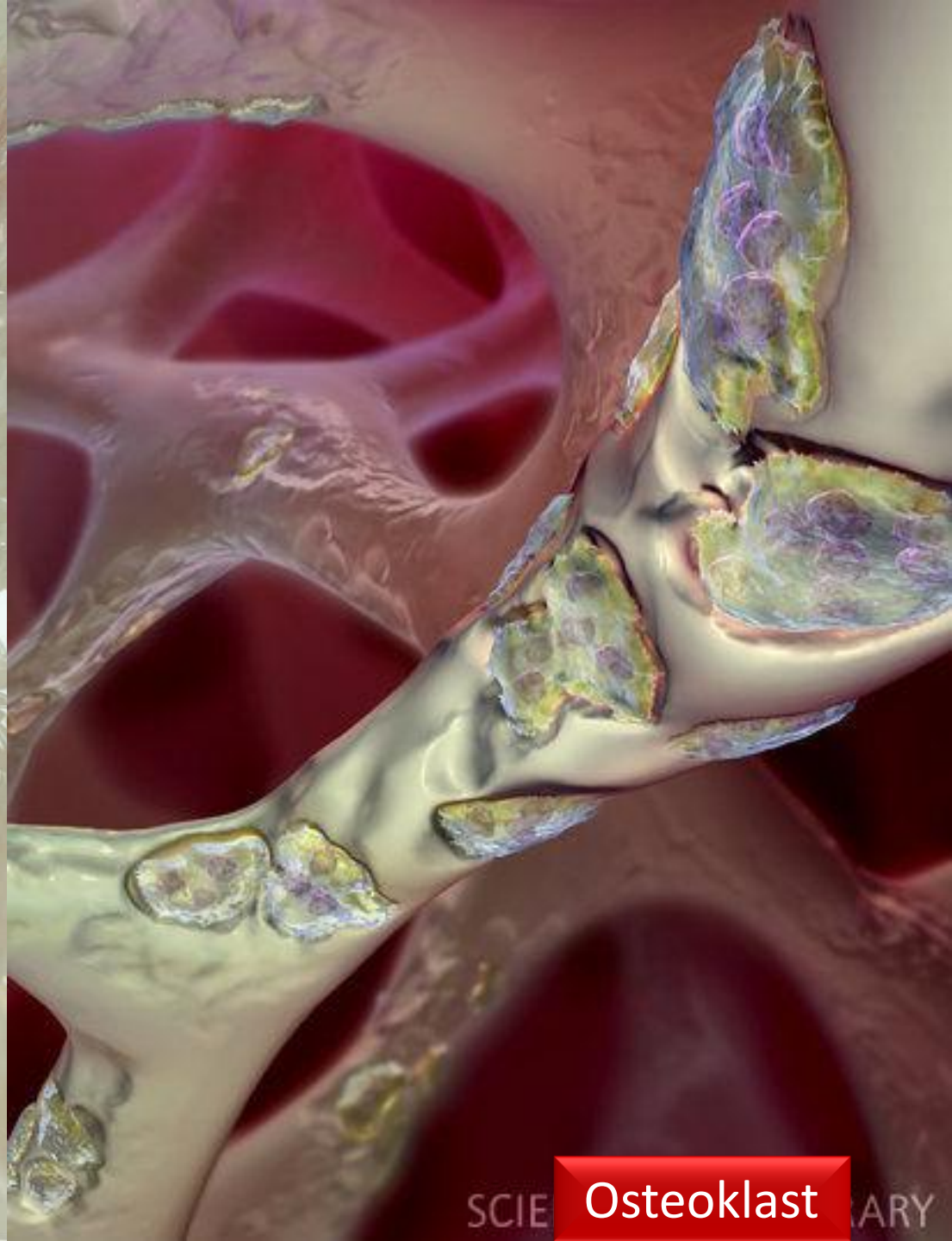
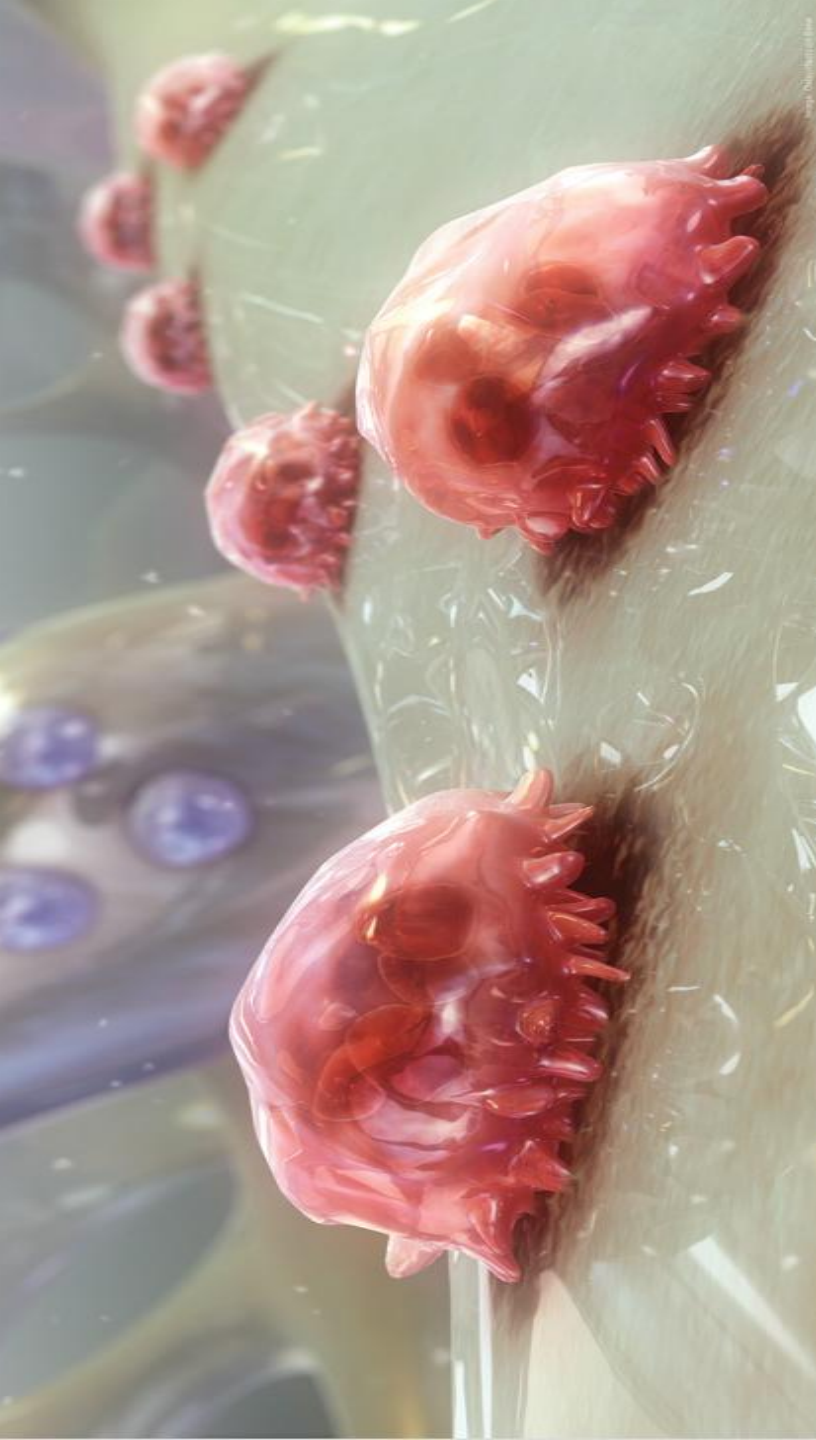




Osteoklast





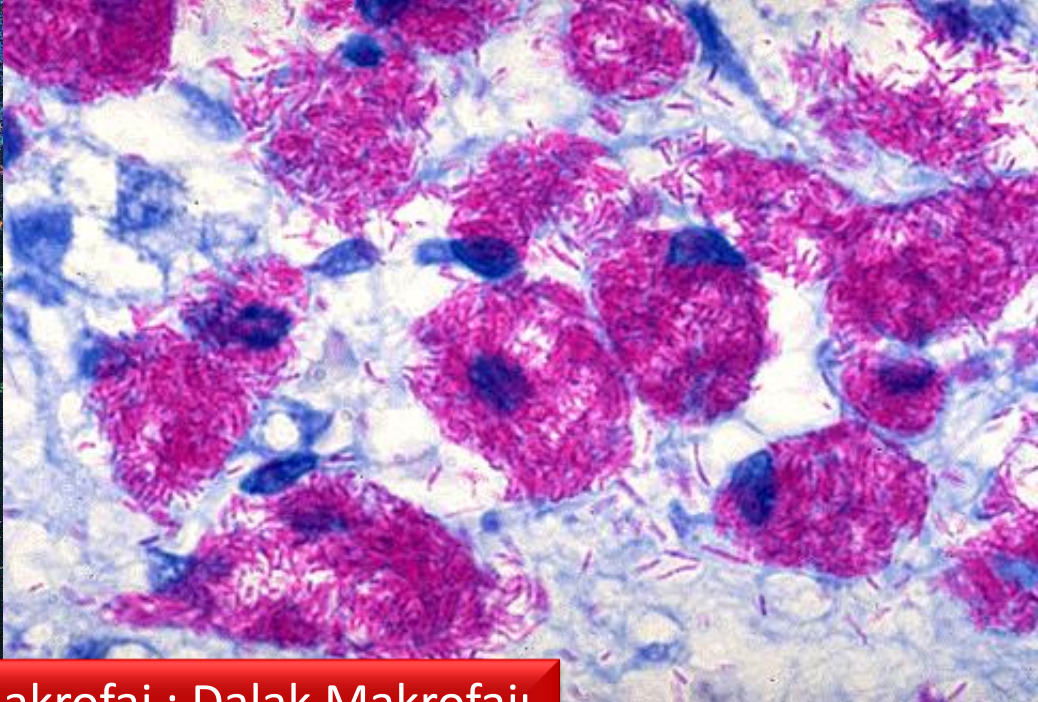
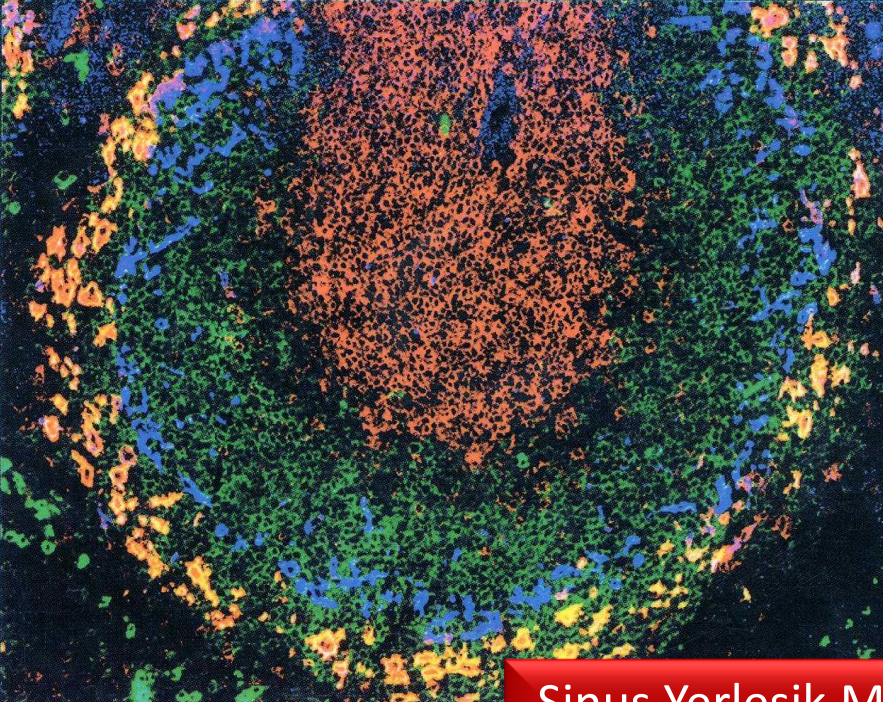


SCIE

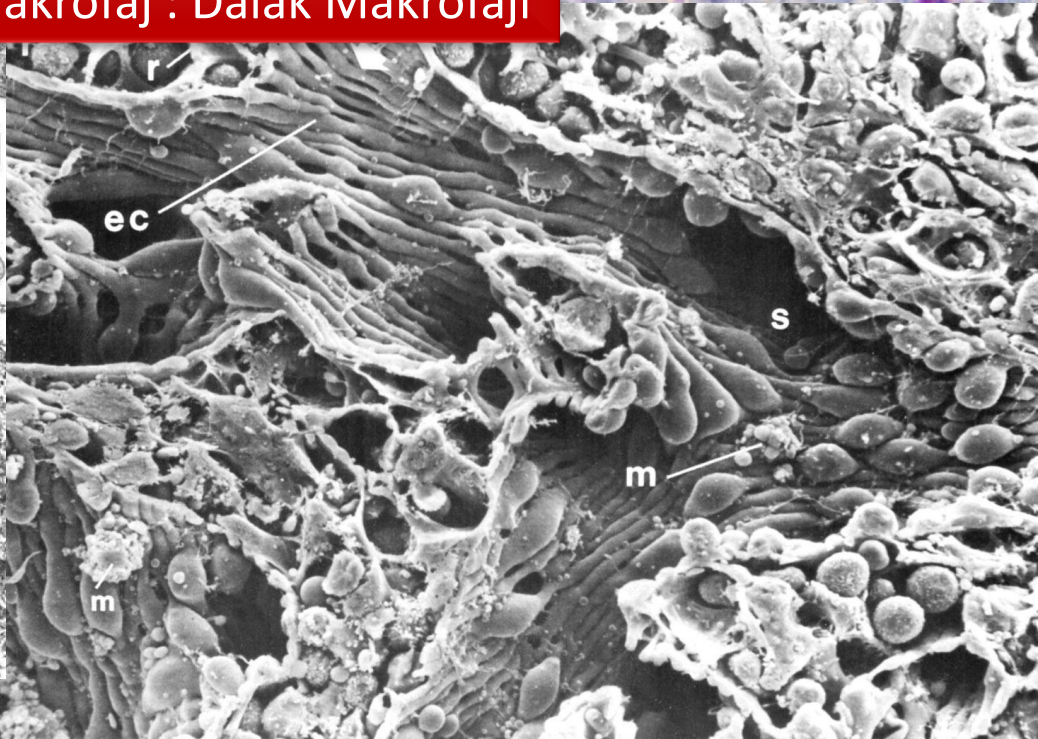
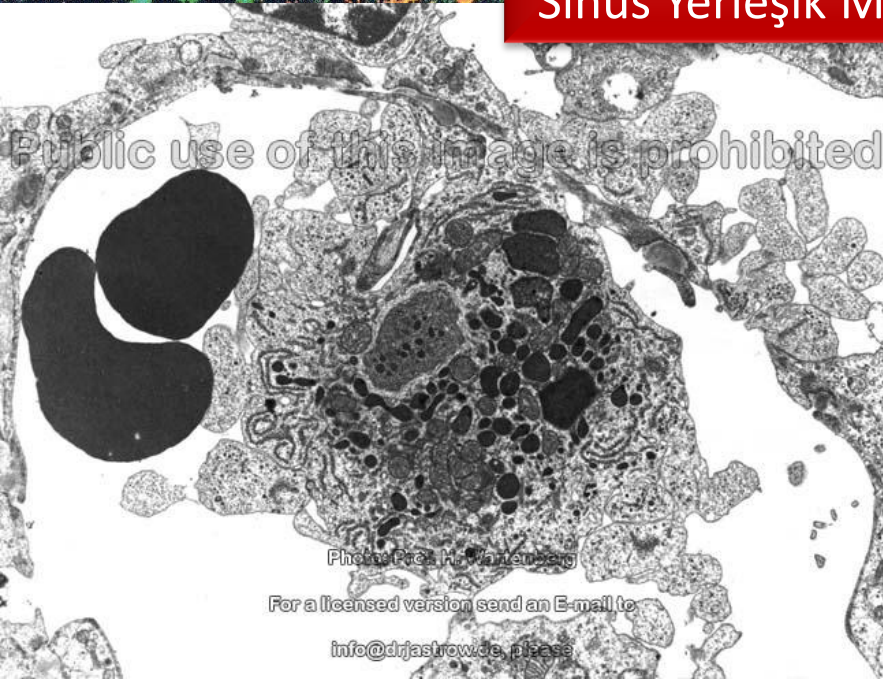
Osteoklast

ARY





Sinus Yerleşik Makrofaj : Dalak Makrofajı

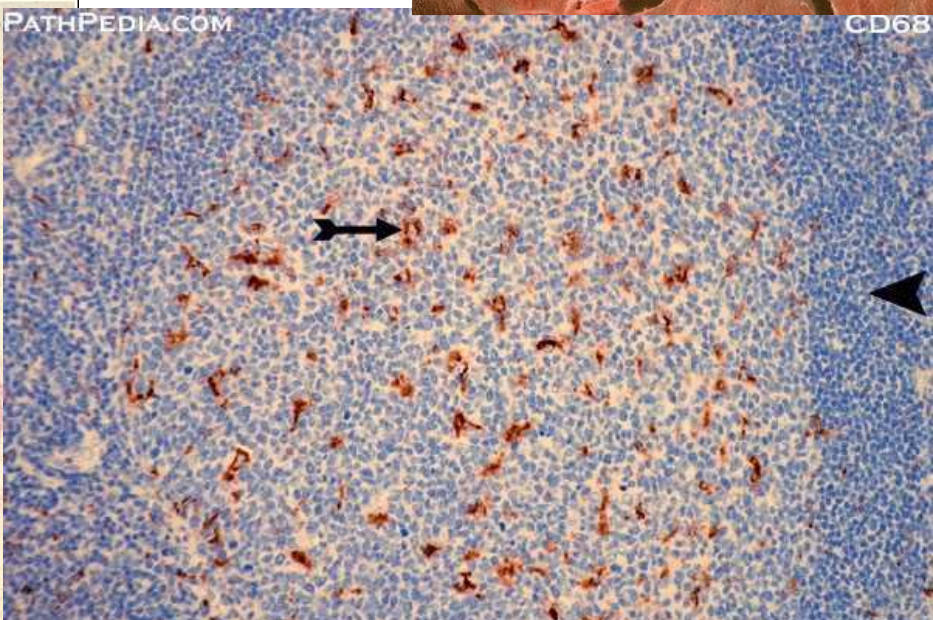
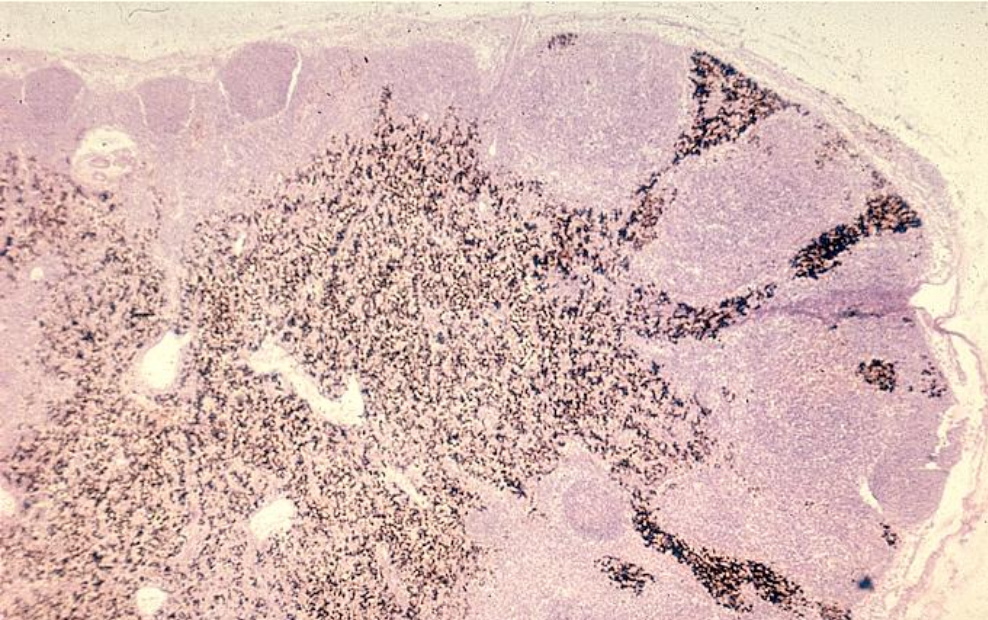
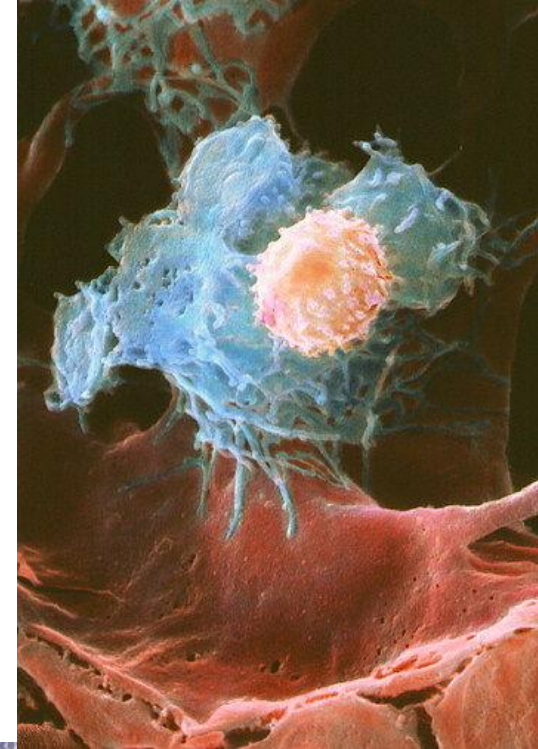
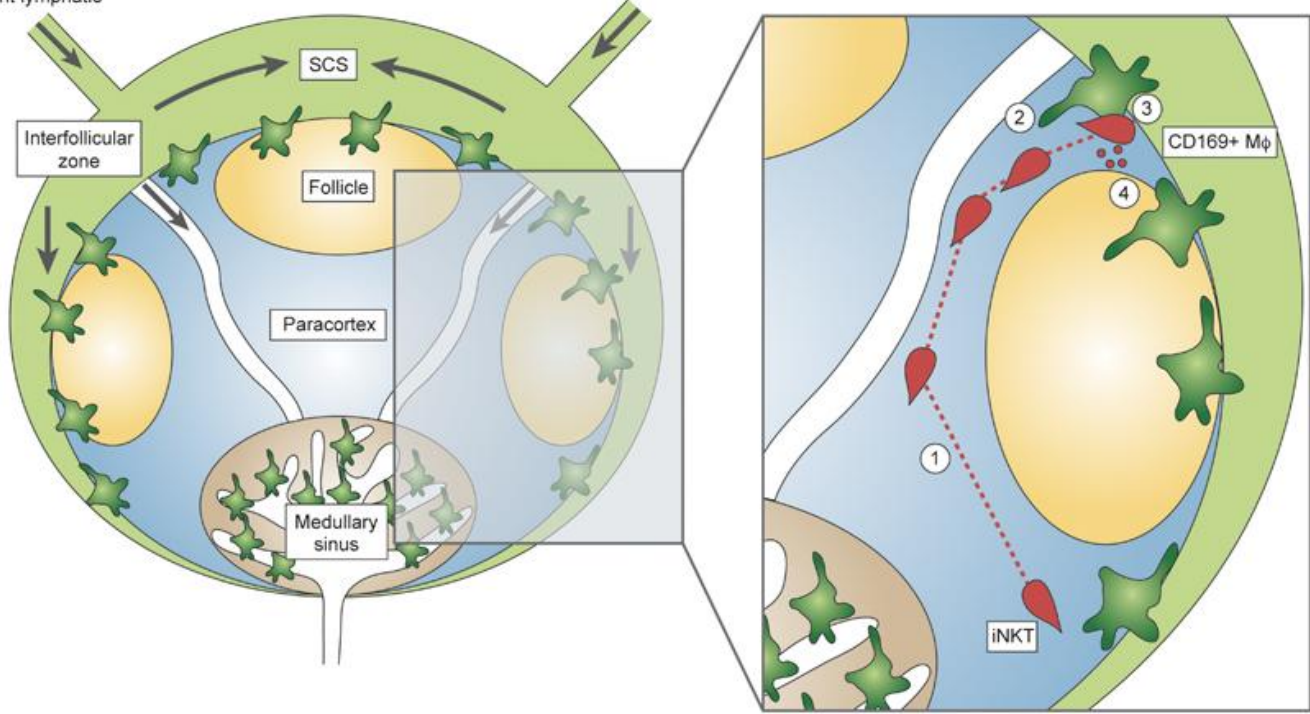


Public use of this image is prohibited

Photo: Prof. Dr. Wartenberg  
For a licensed version send an E-mail to  
info@drjastrow.de, please

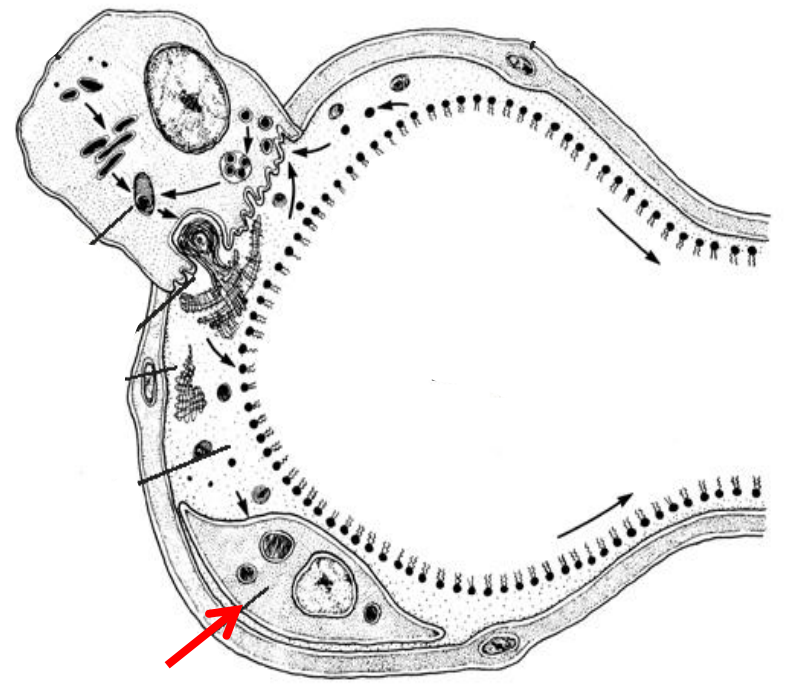
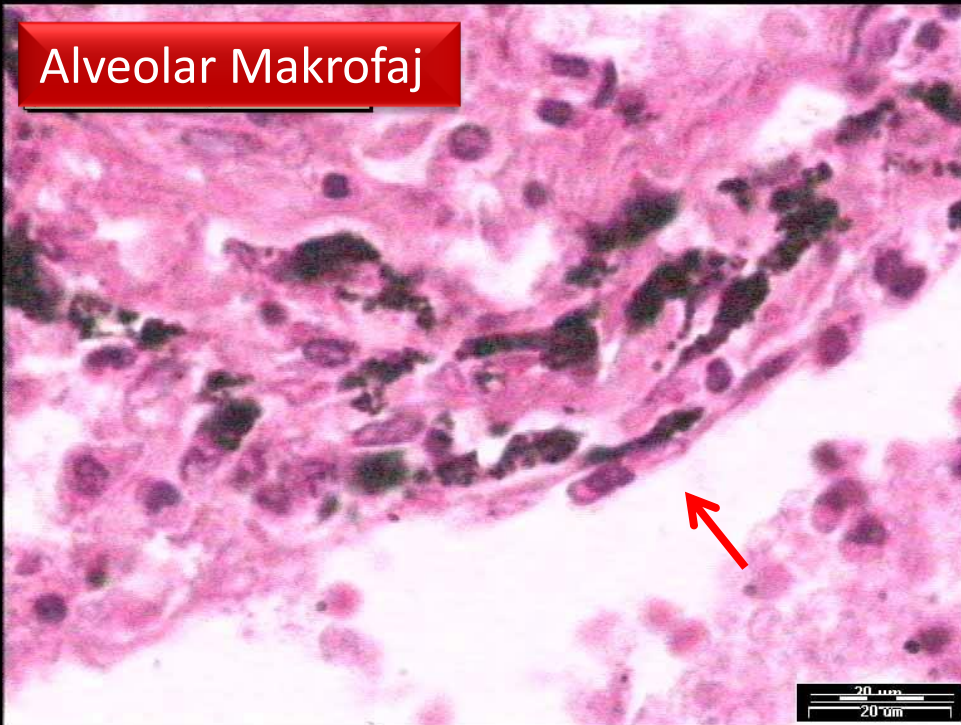
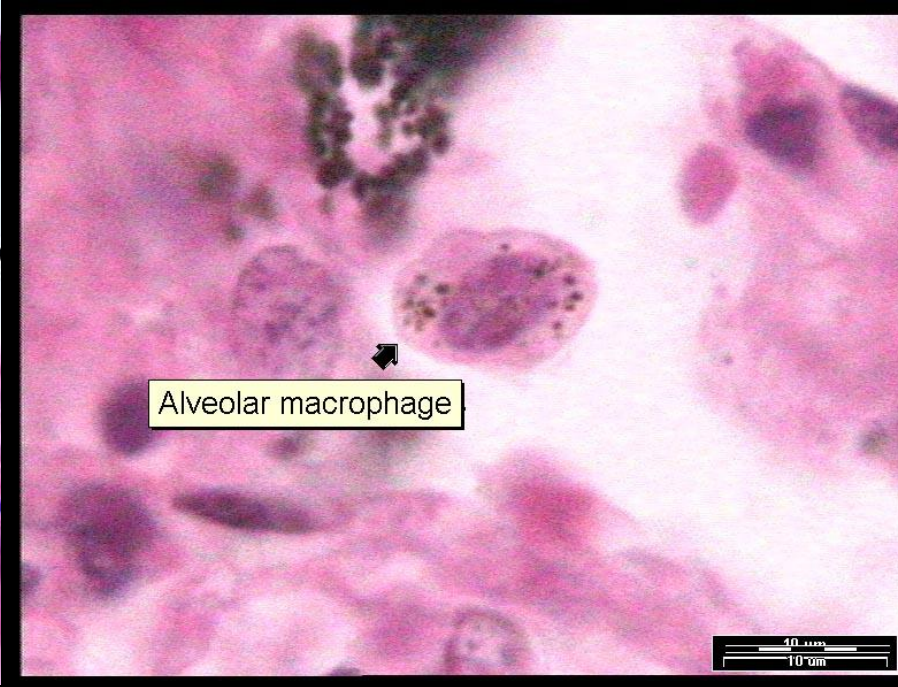
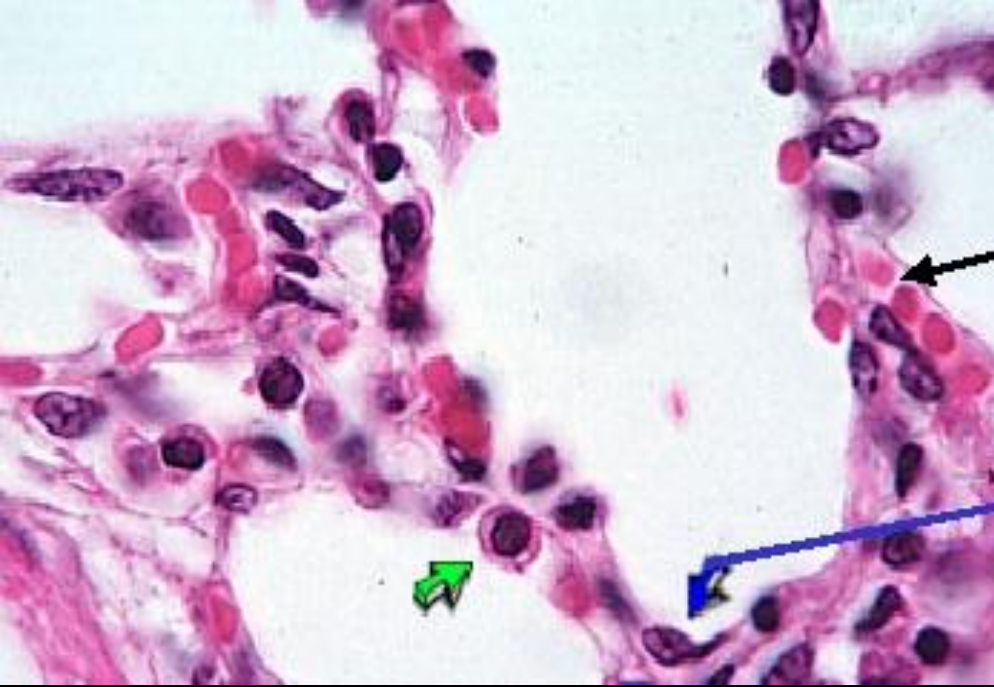


Different lymphatic

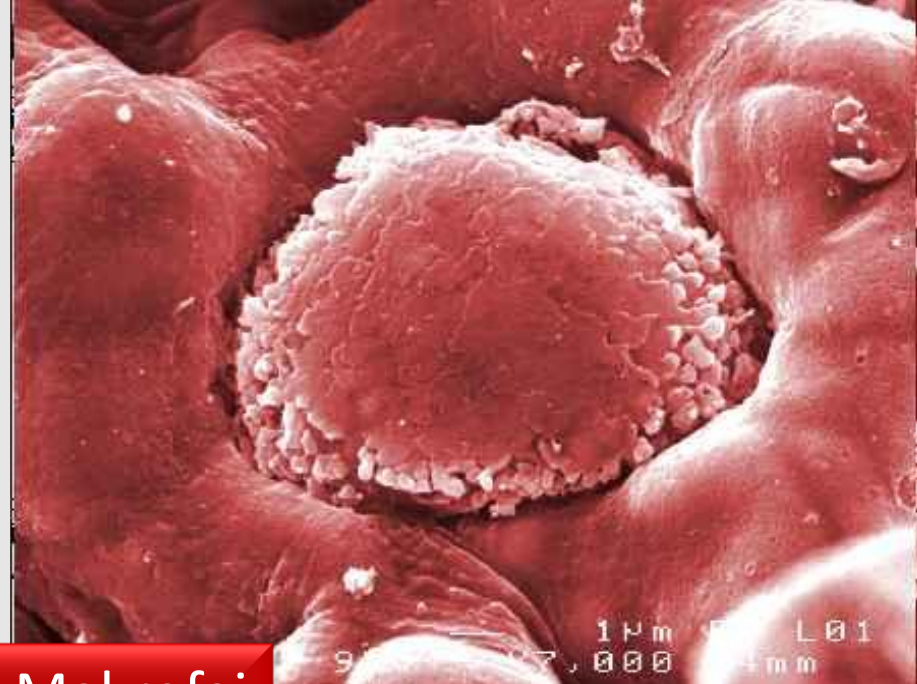
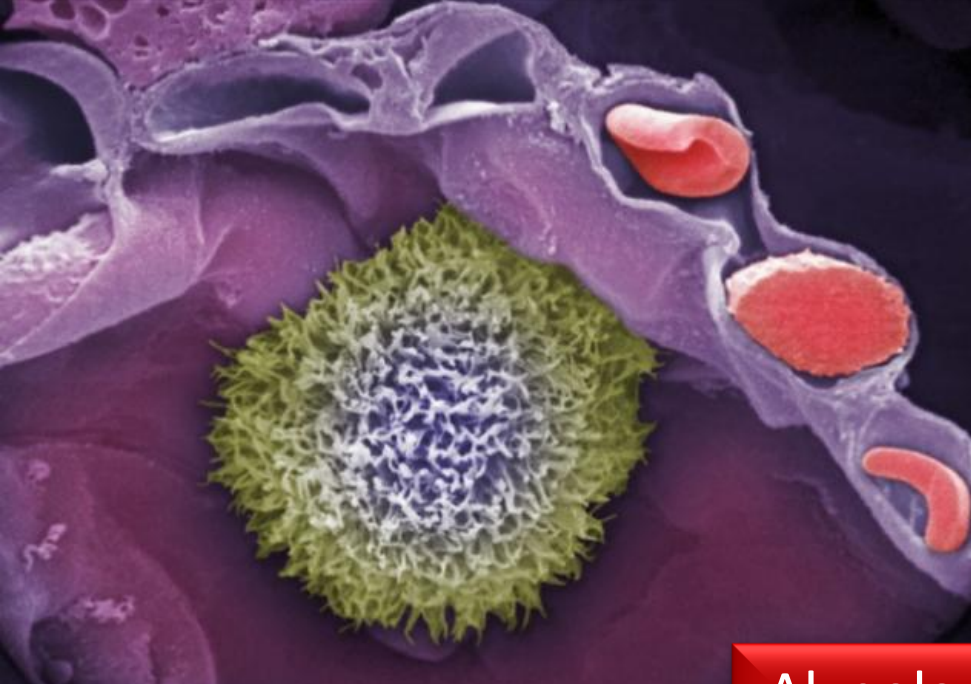
Sinus Yerleşik Makrofaj : Lenf Nodülü Makrofajı

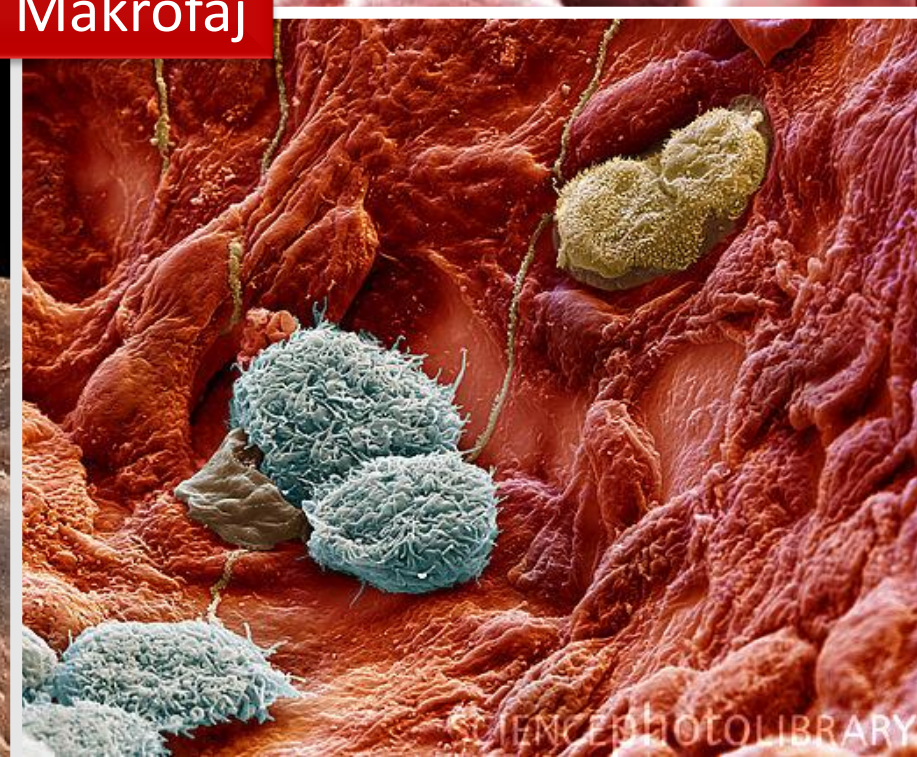
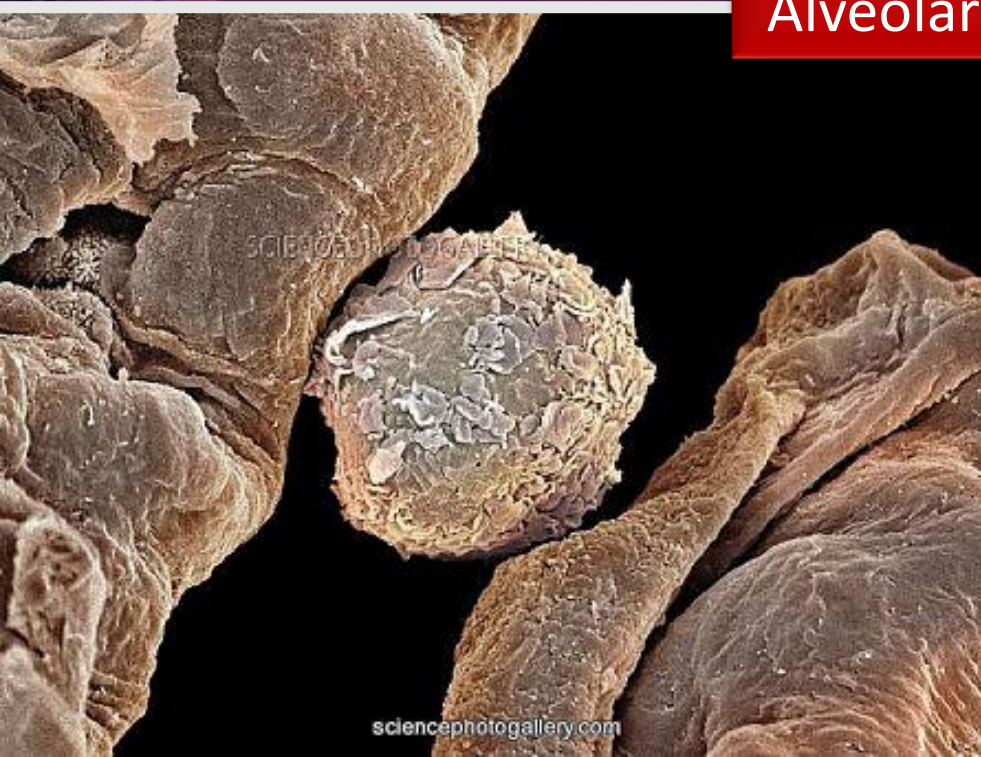




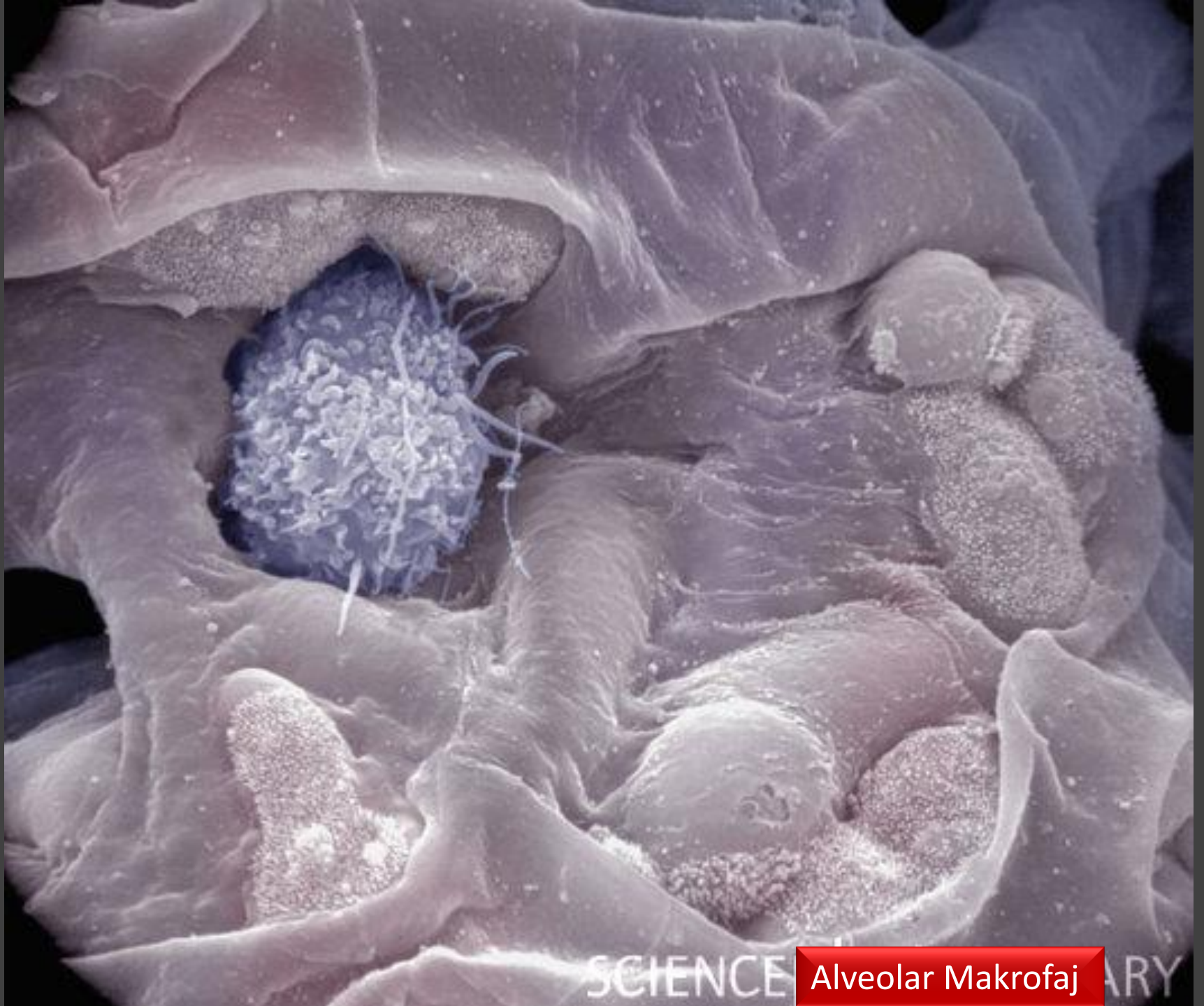

Alveolar Makrofaj

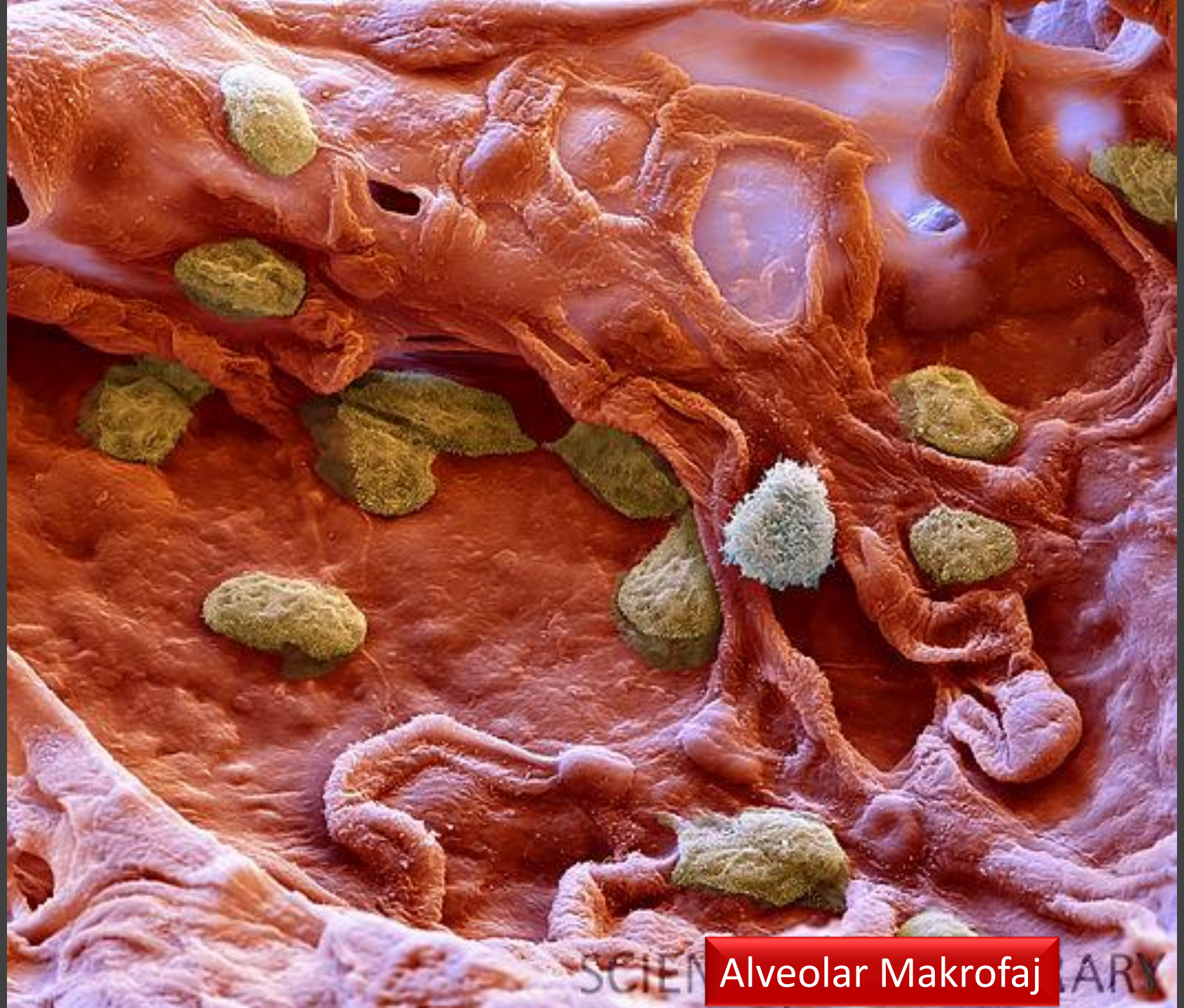





SCIENCE **Alveolar Makrofaj** ARY



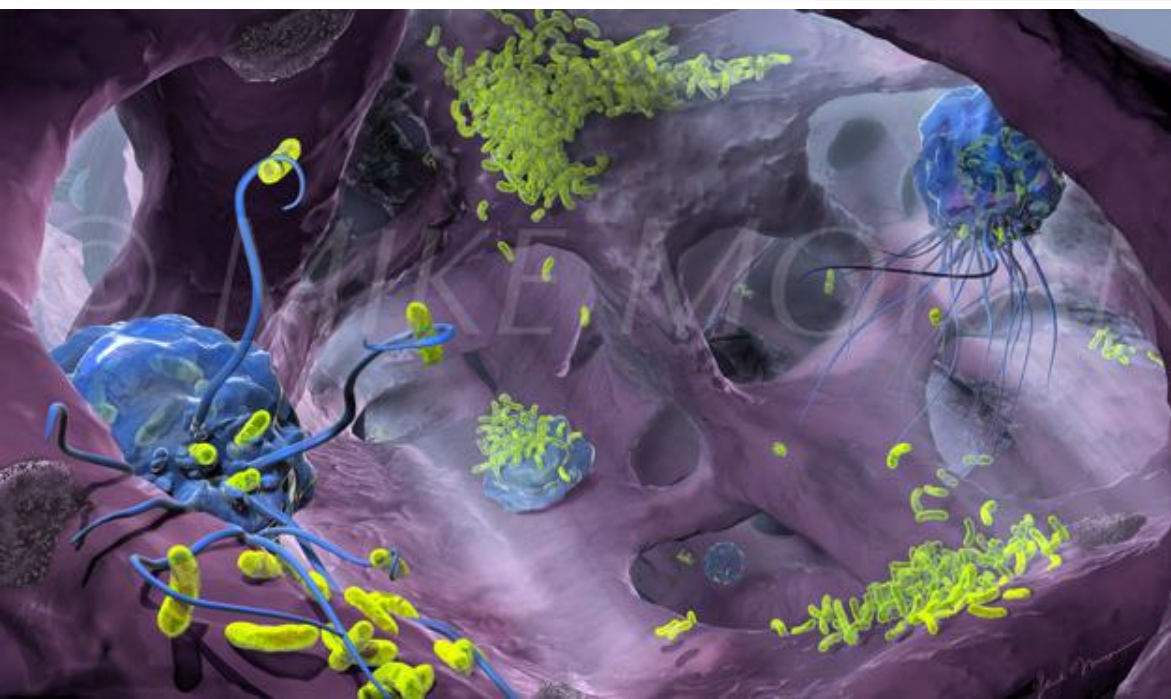
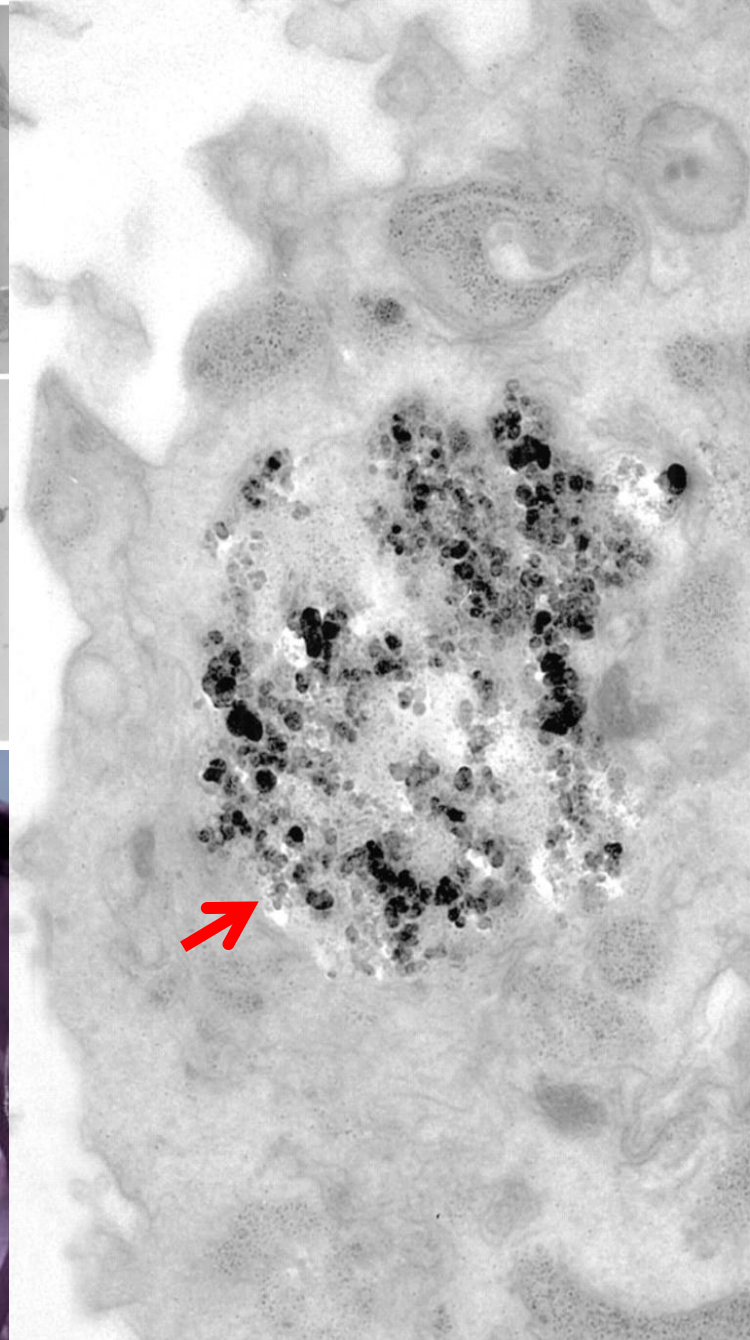
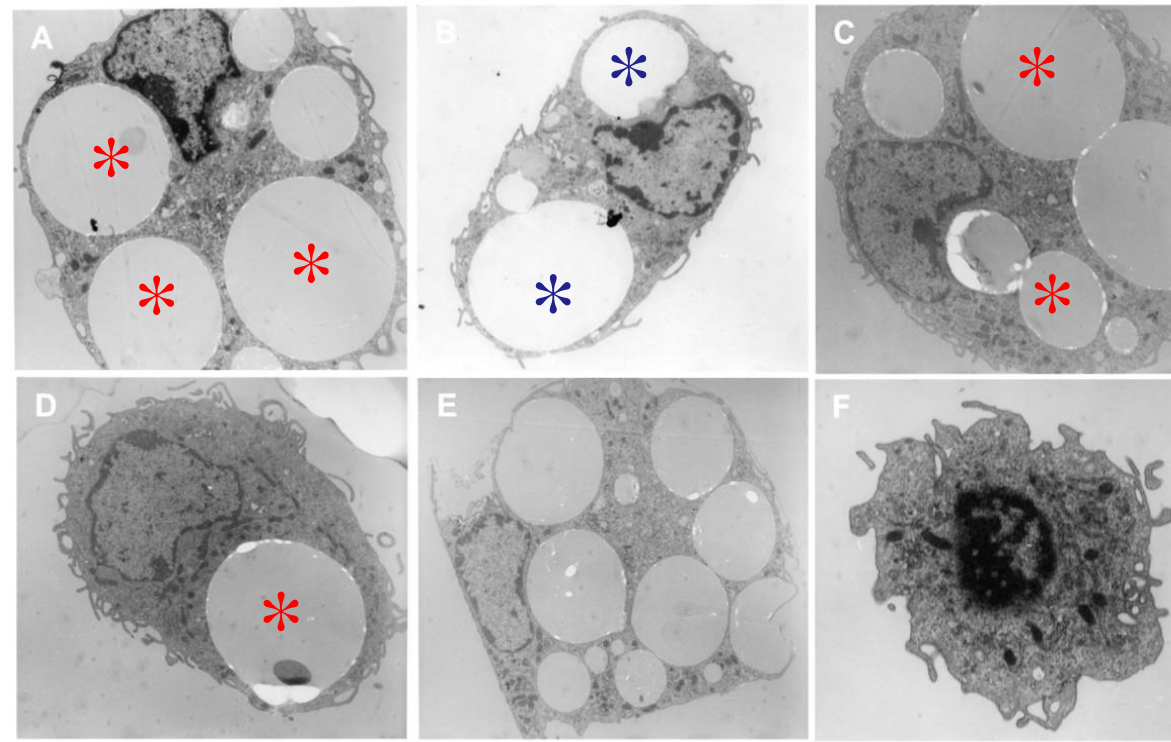


SCIEN

Alveolar Makrofaj

LARY





Alveolar Makrofaj-Fagositoz

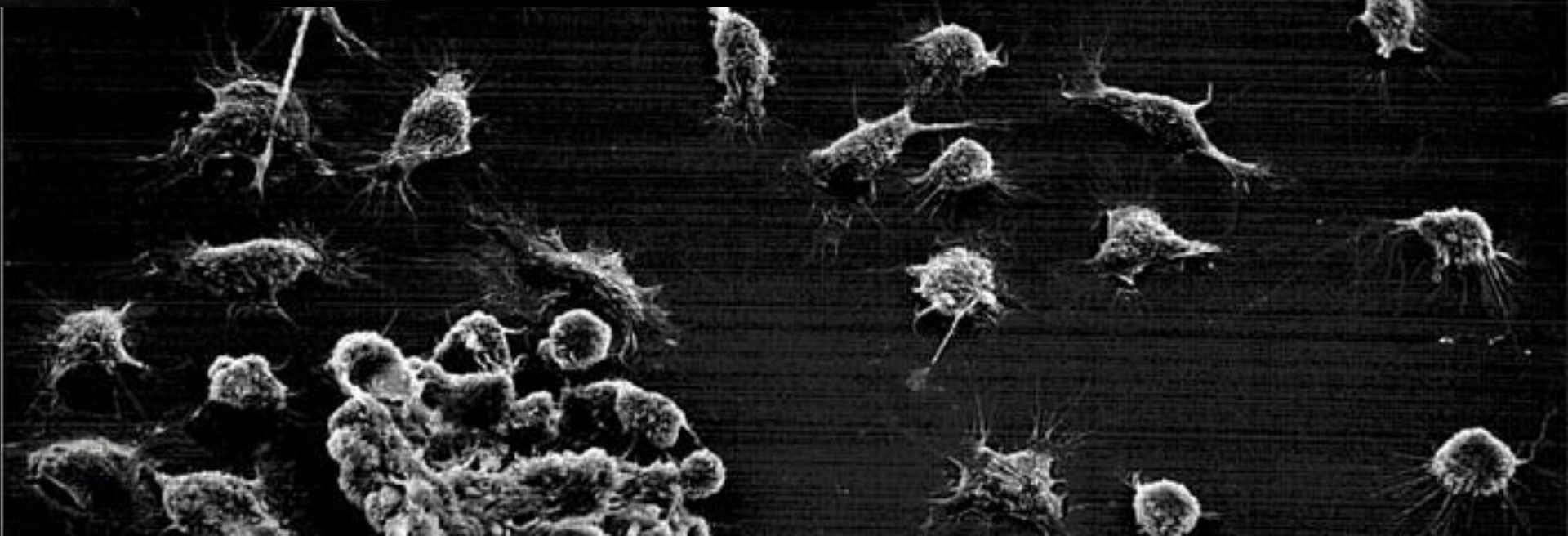
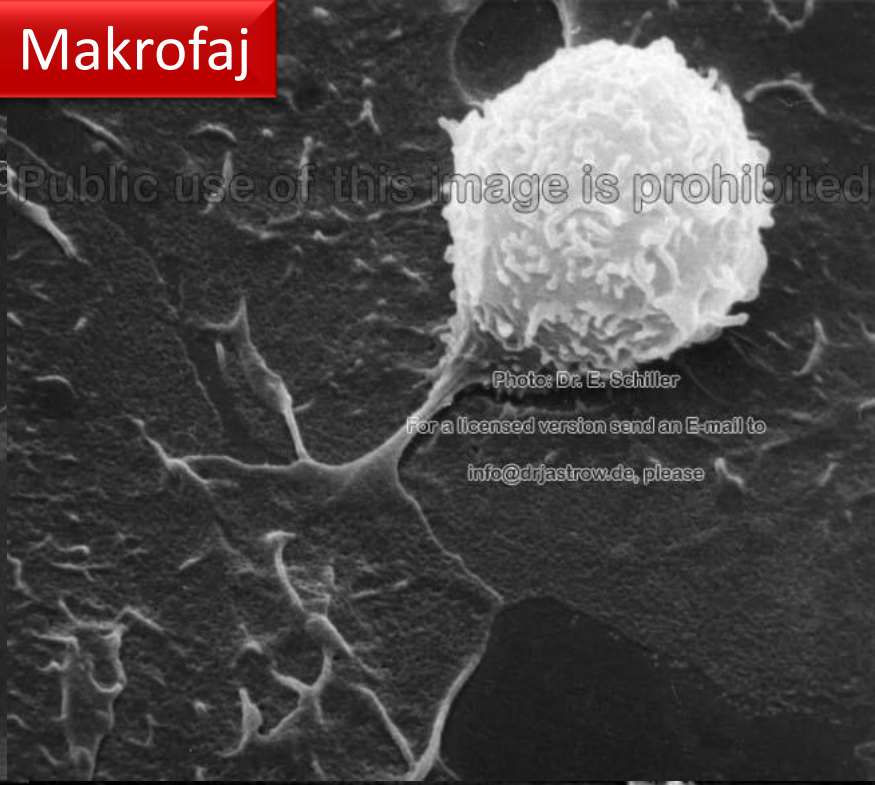

# Peritoneal Makrofaj

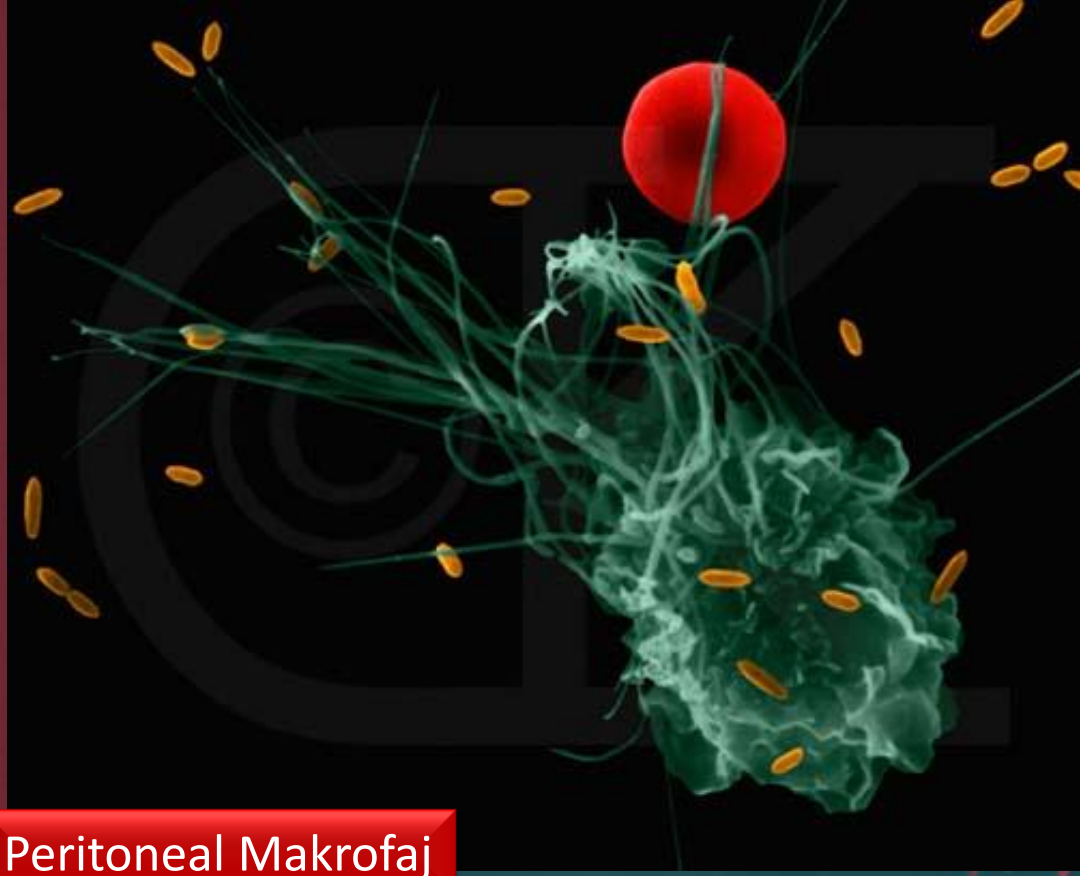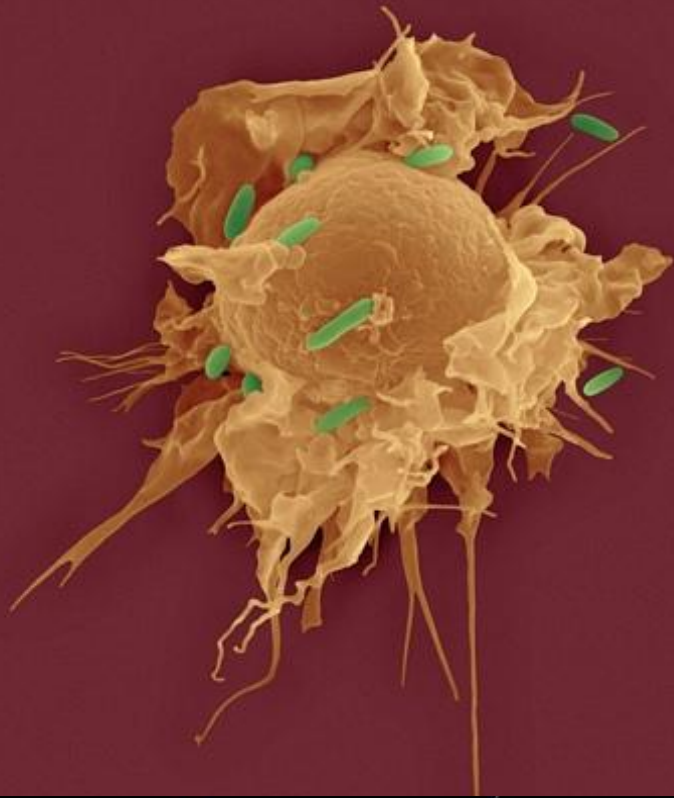
Public use of this image is prohibited



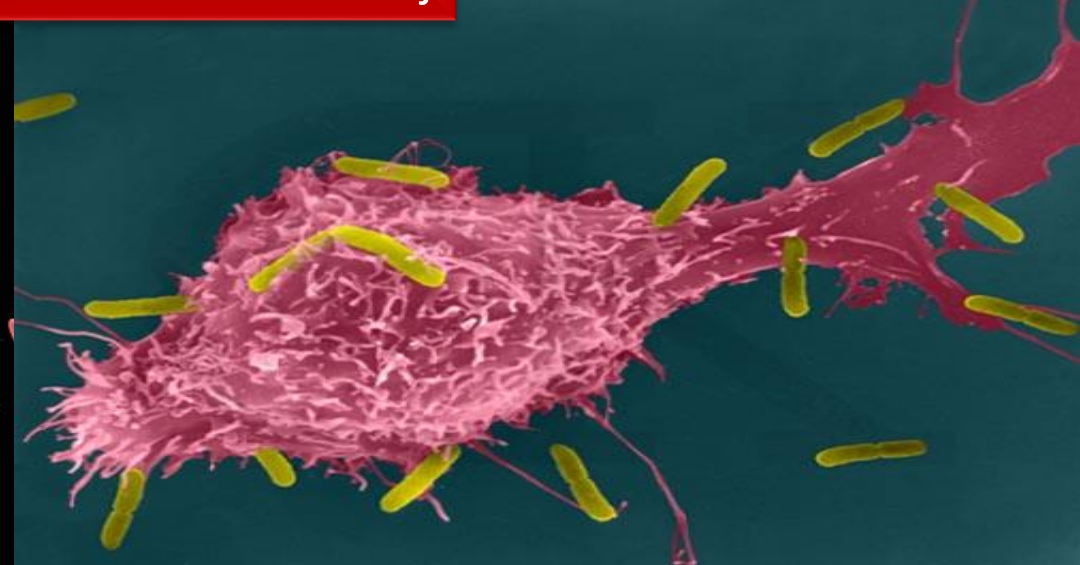
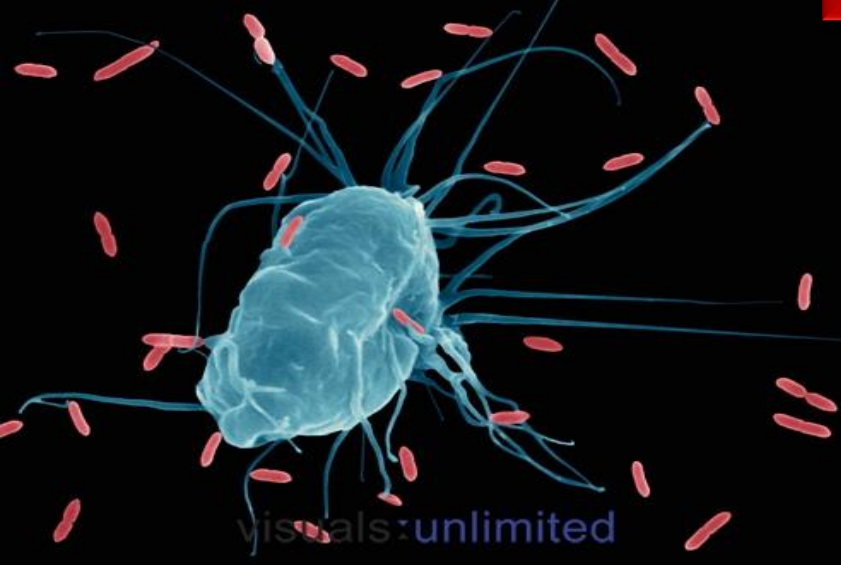Public use of this image is prohibited



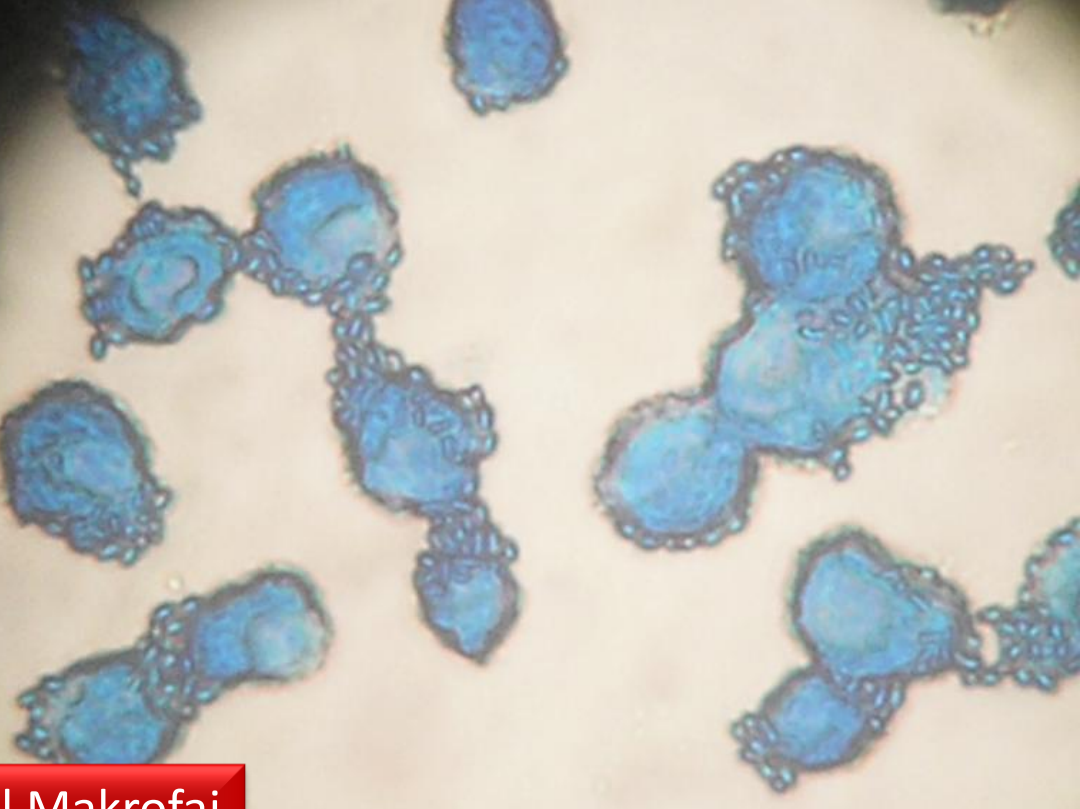
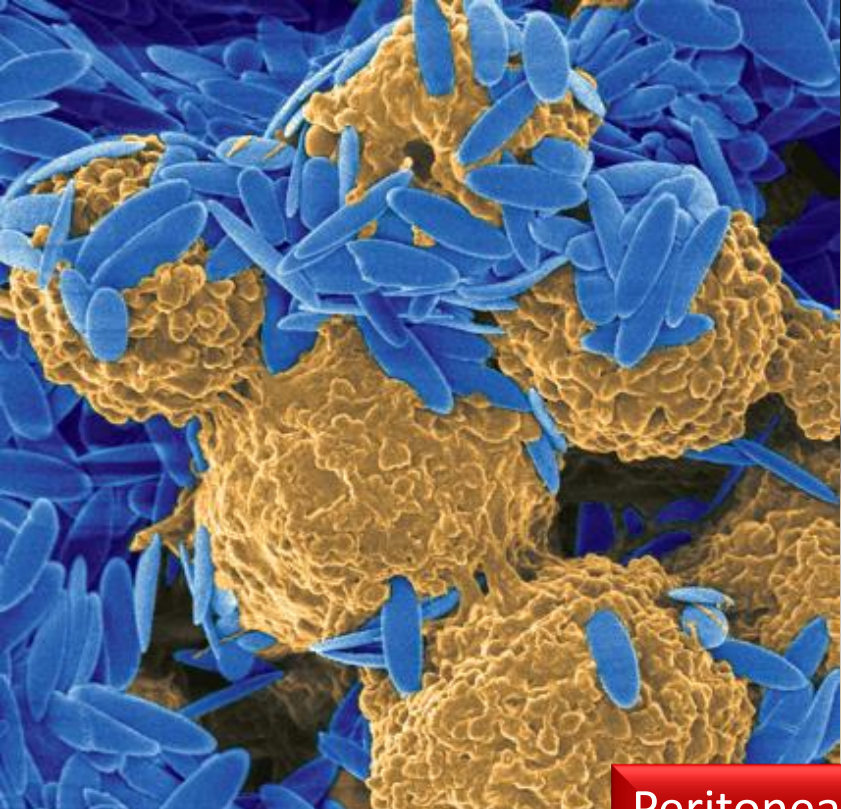




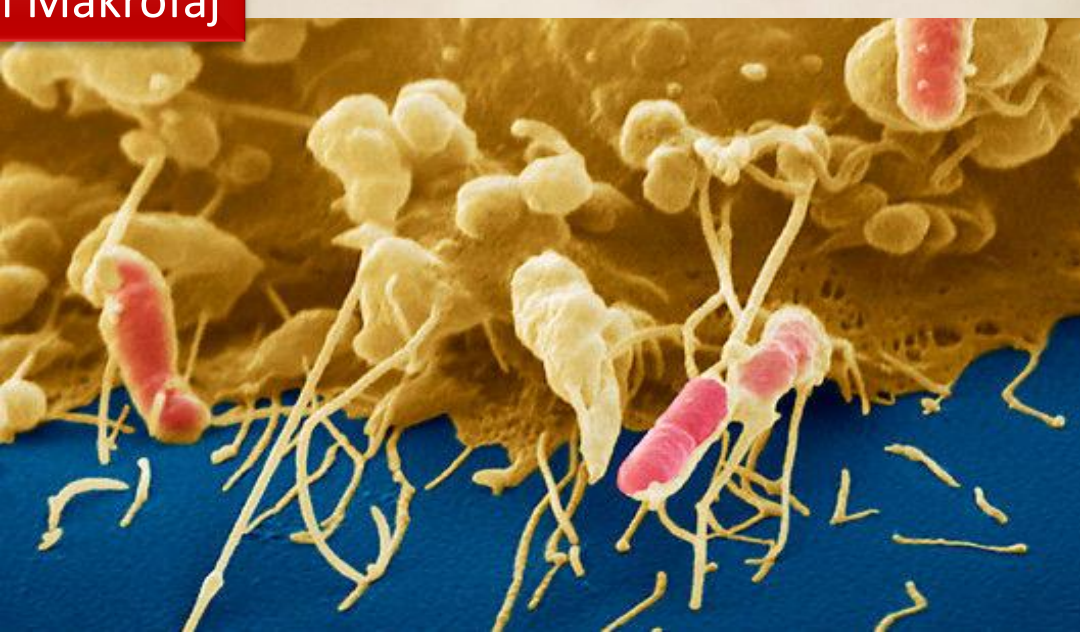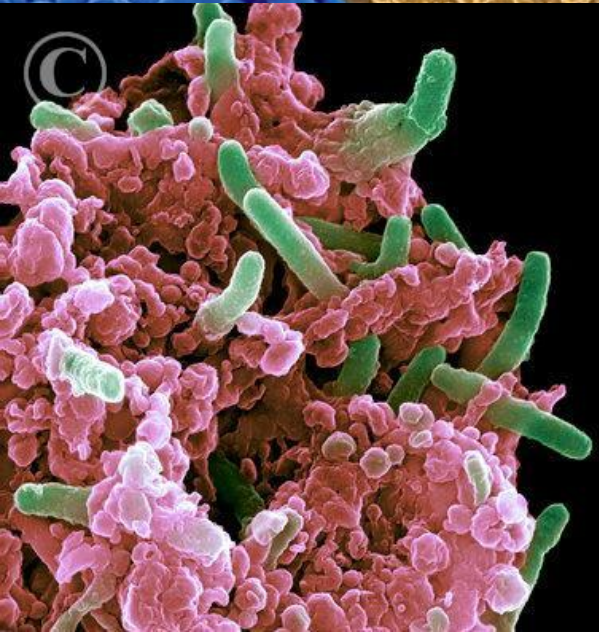
Peritoneal Makrofaj



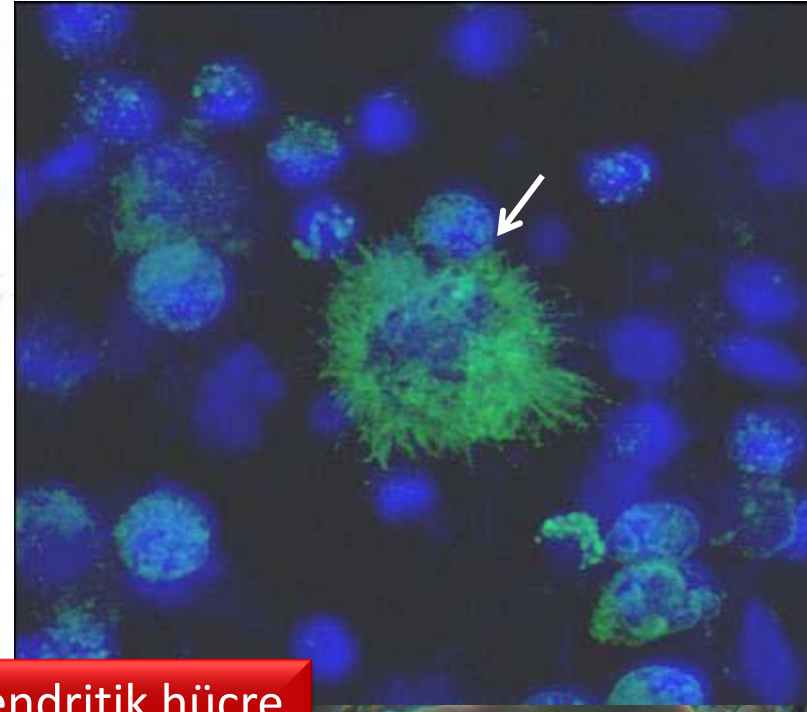
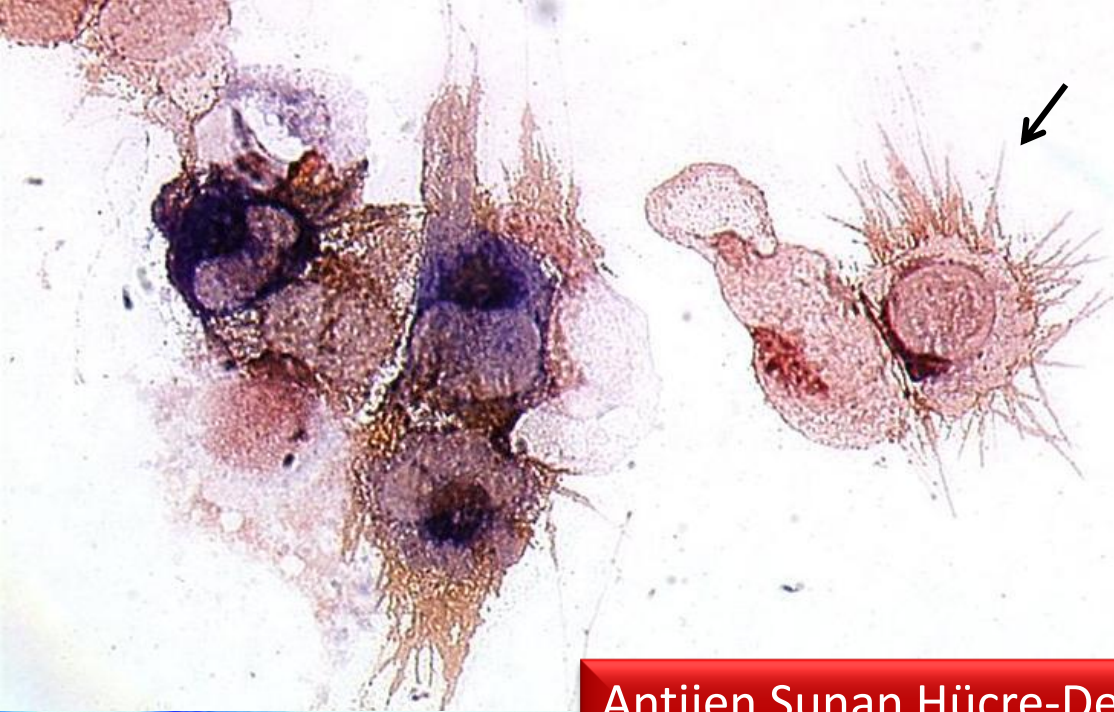



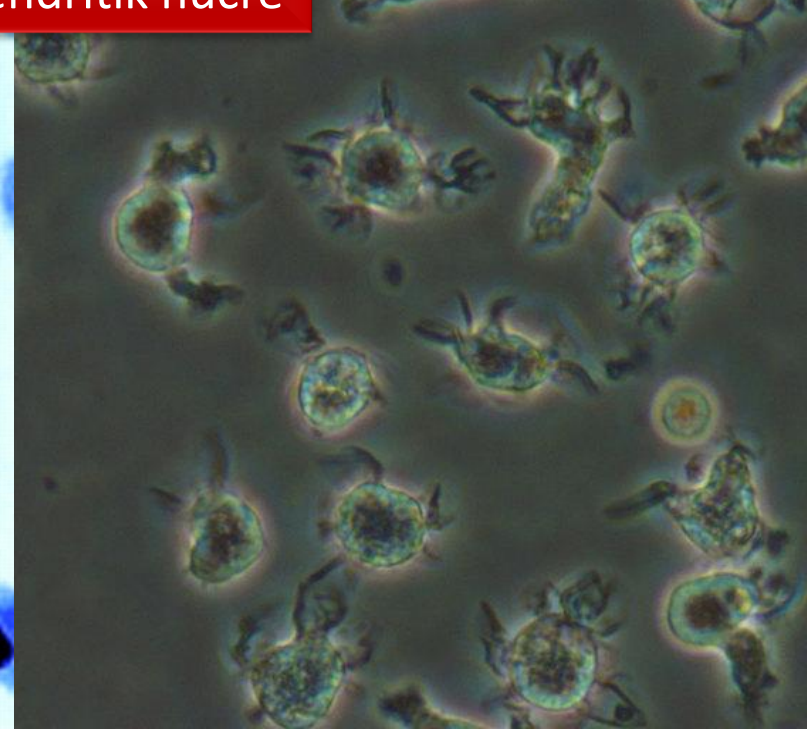
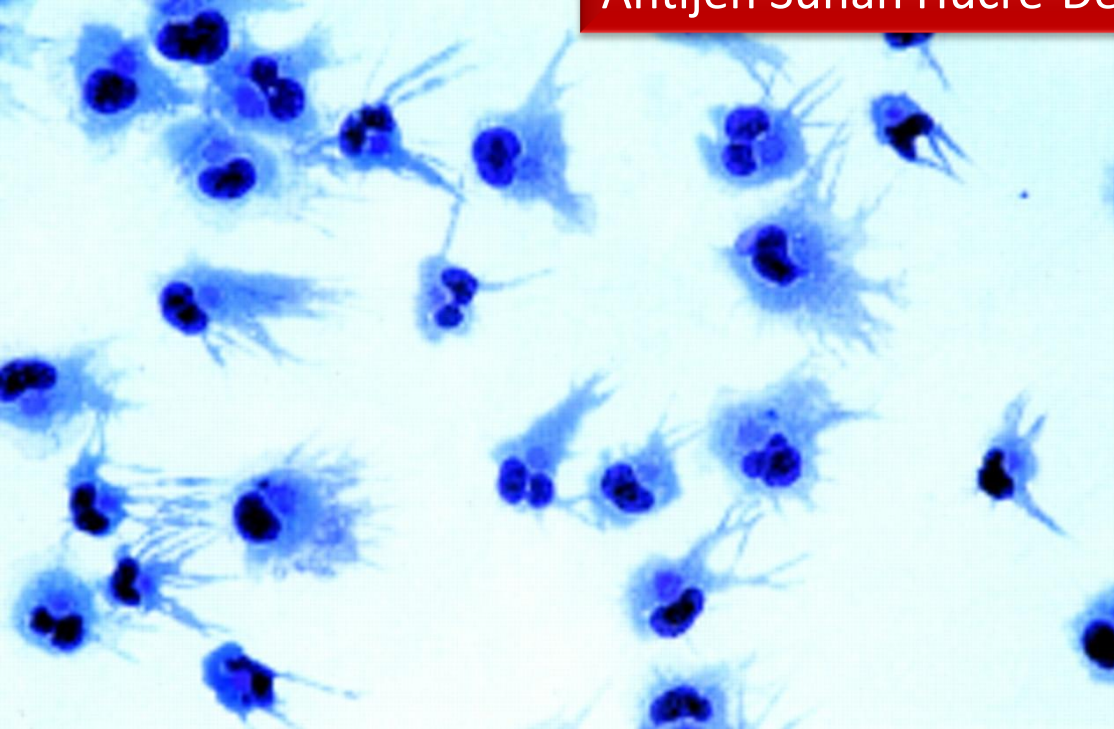
Peritoneal Makrofaj





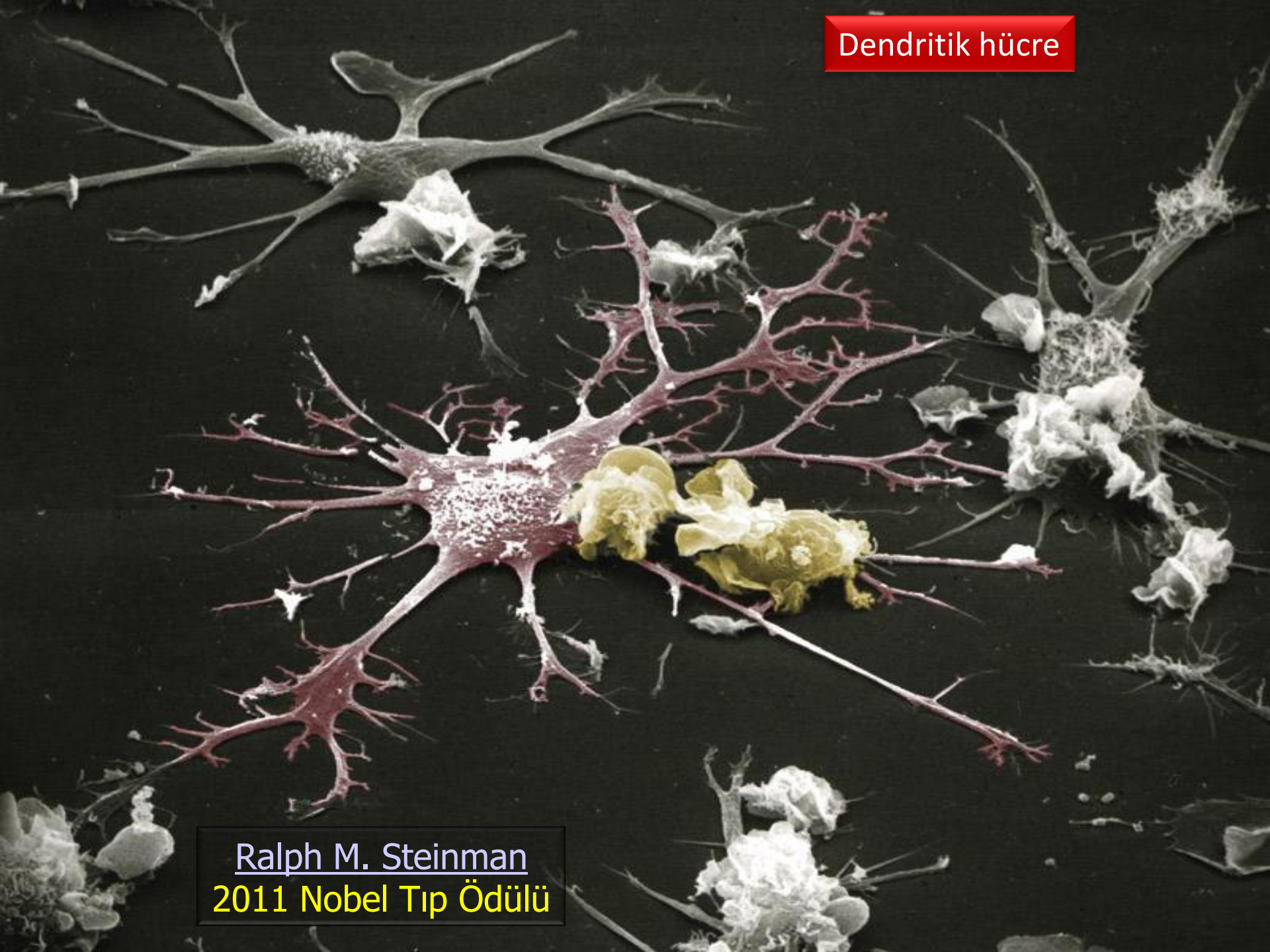


Antijen Sunan Hücre-Dendritik hücre





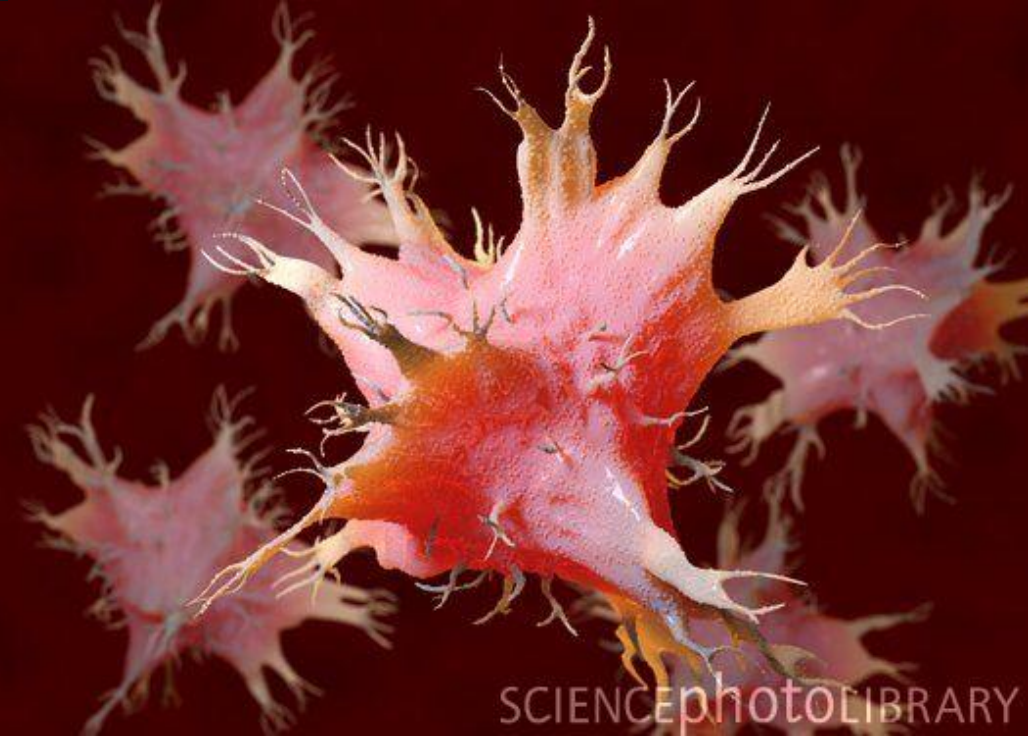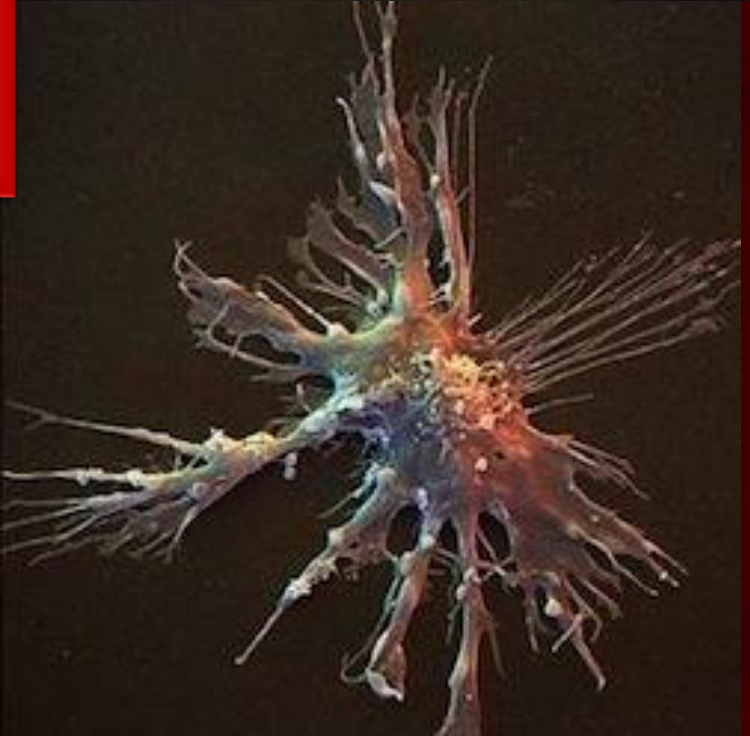
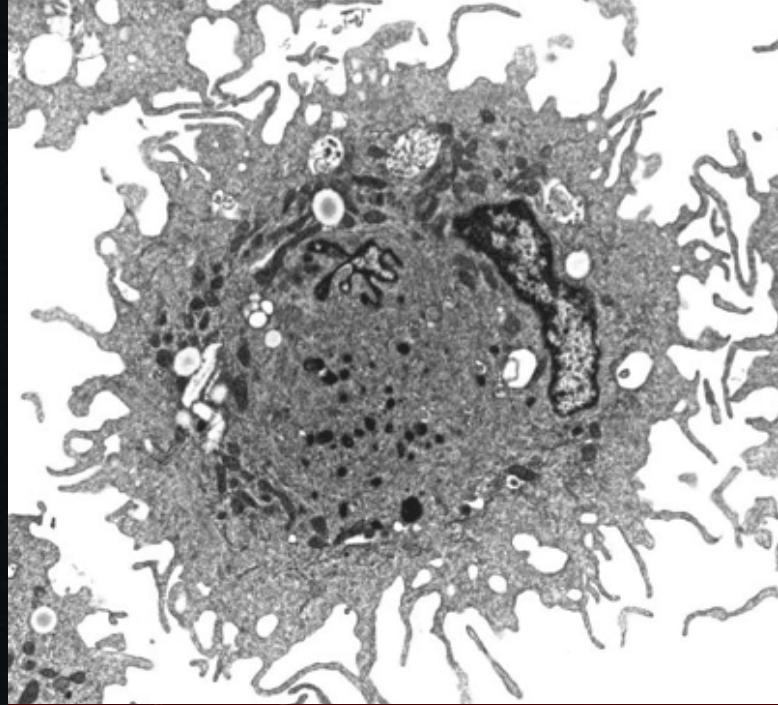
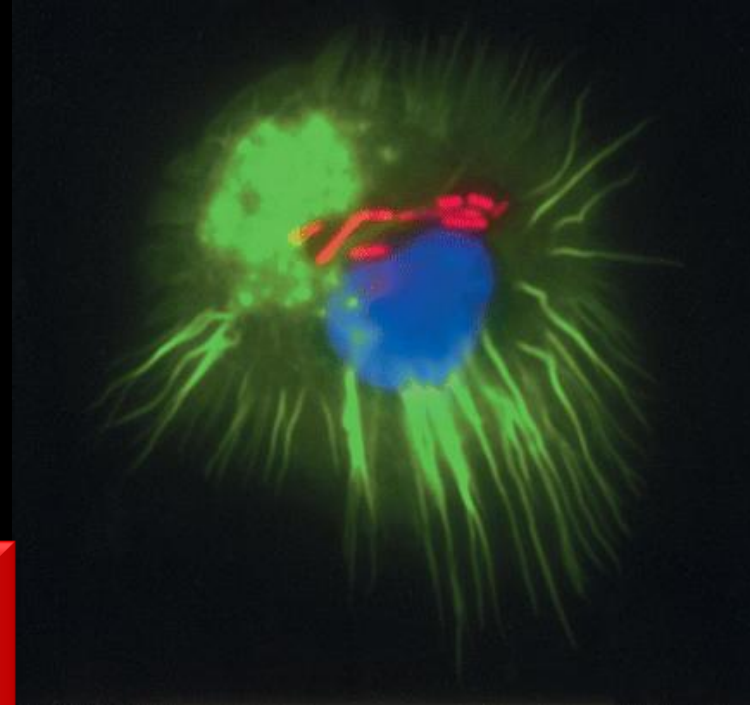
Dendritik hücre



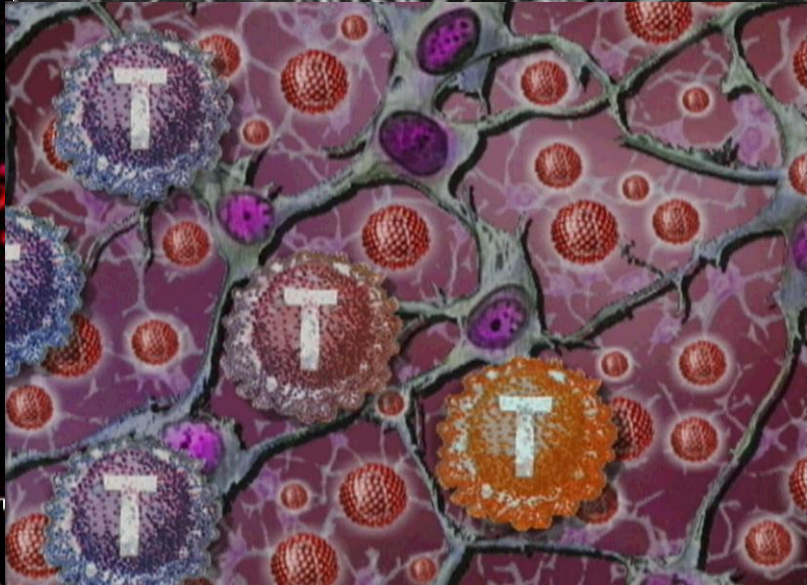
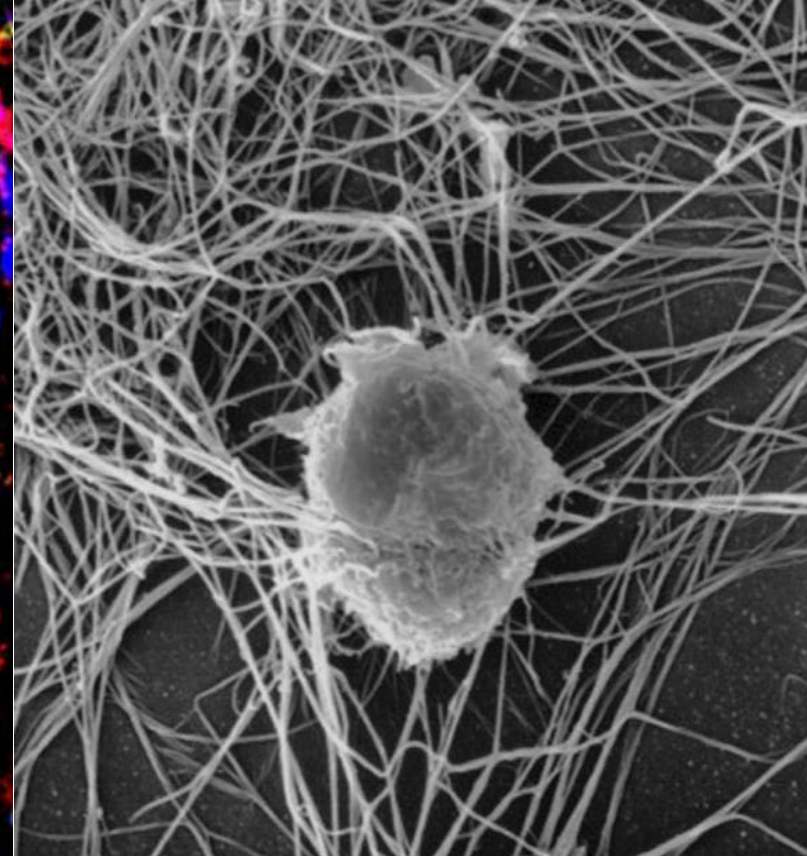
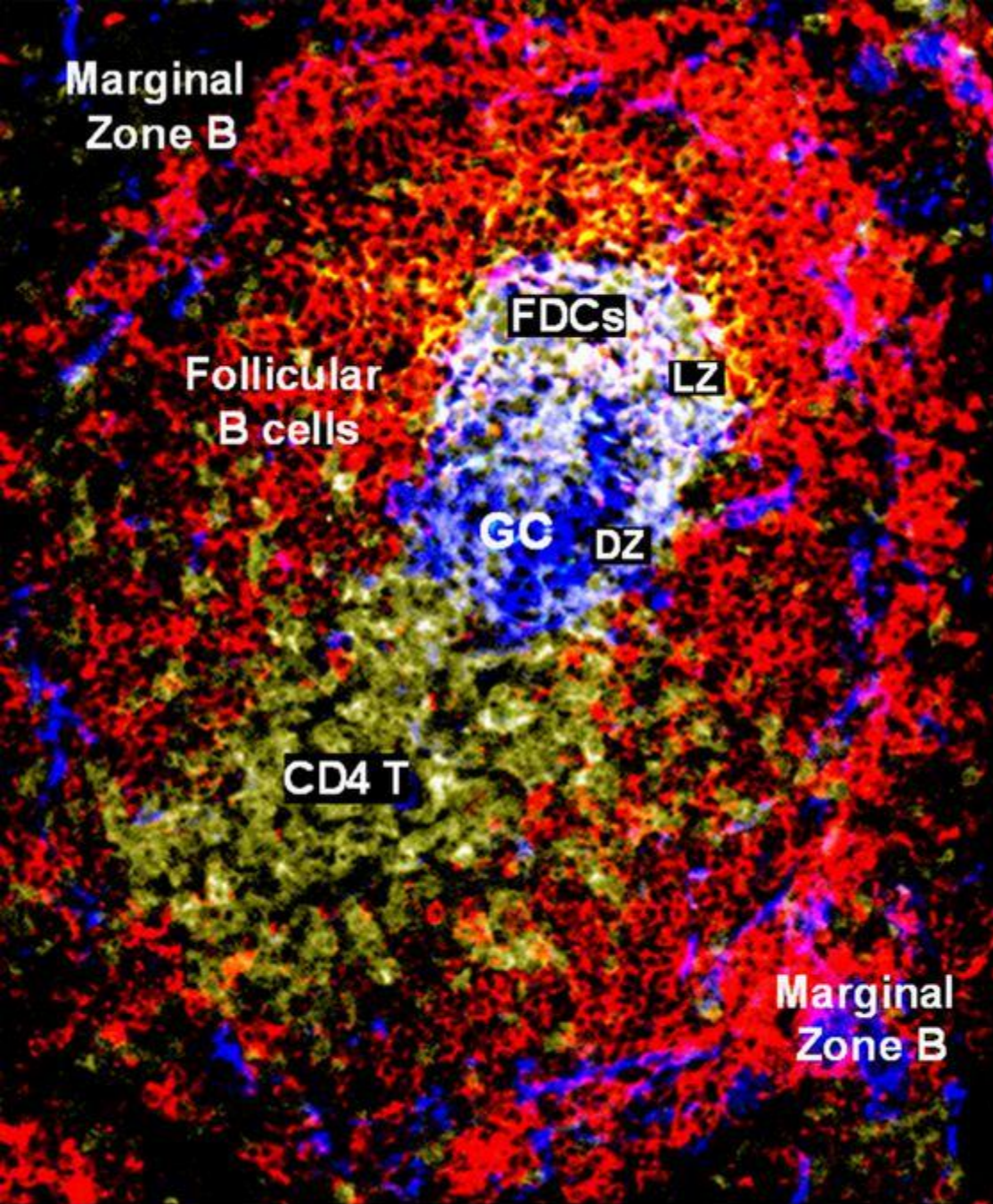
Ralph M. Steinman  
2011 Nobel Tıp Ödülü



Dendritik hücre



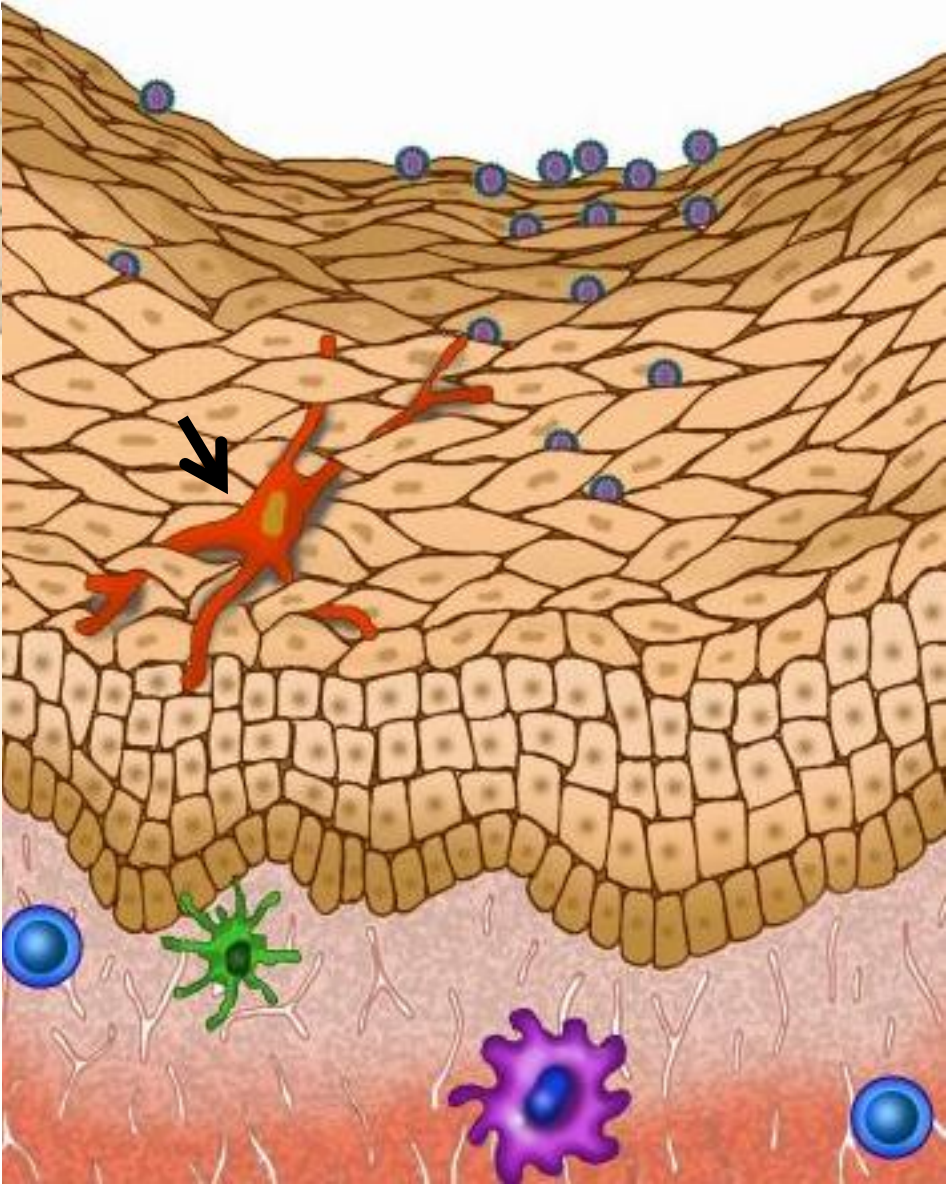
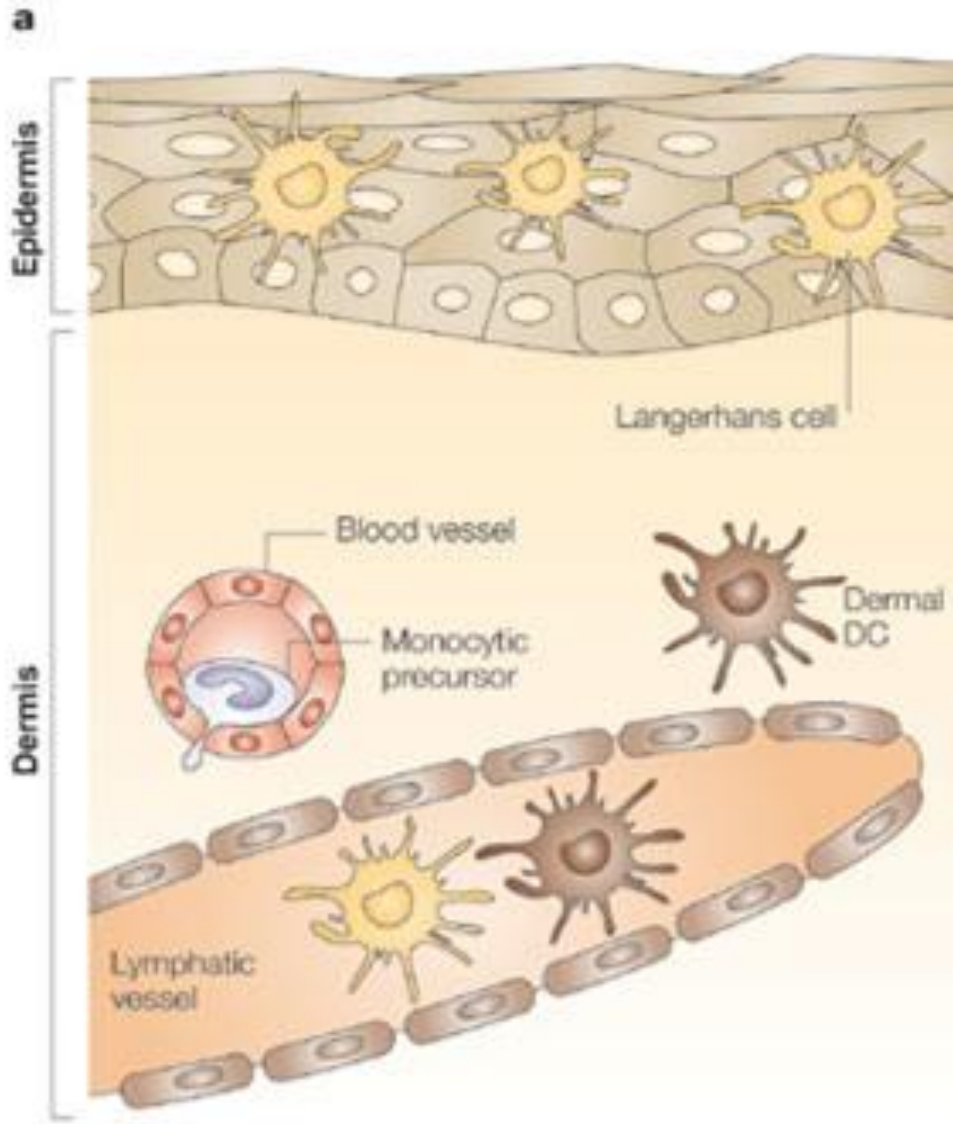





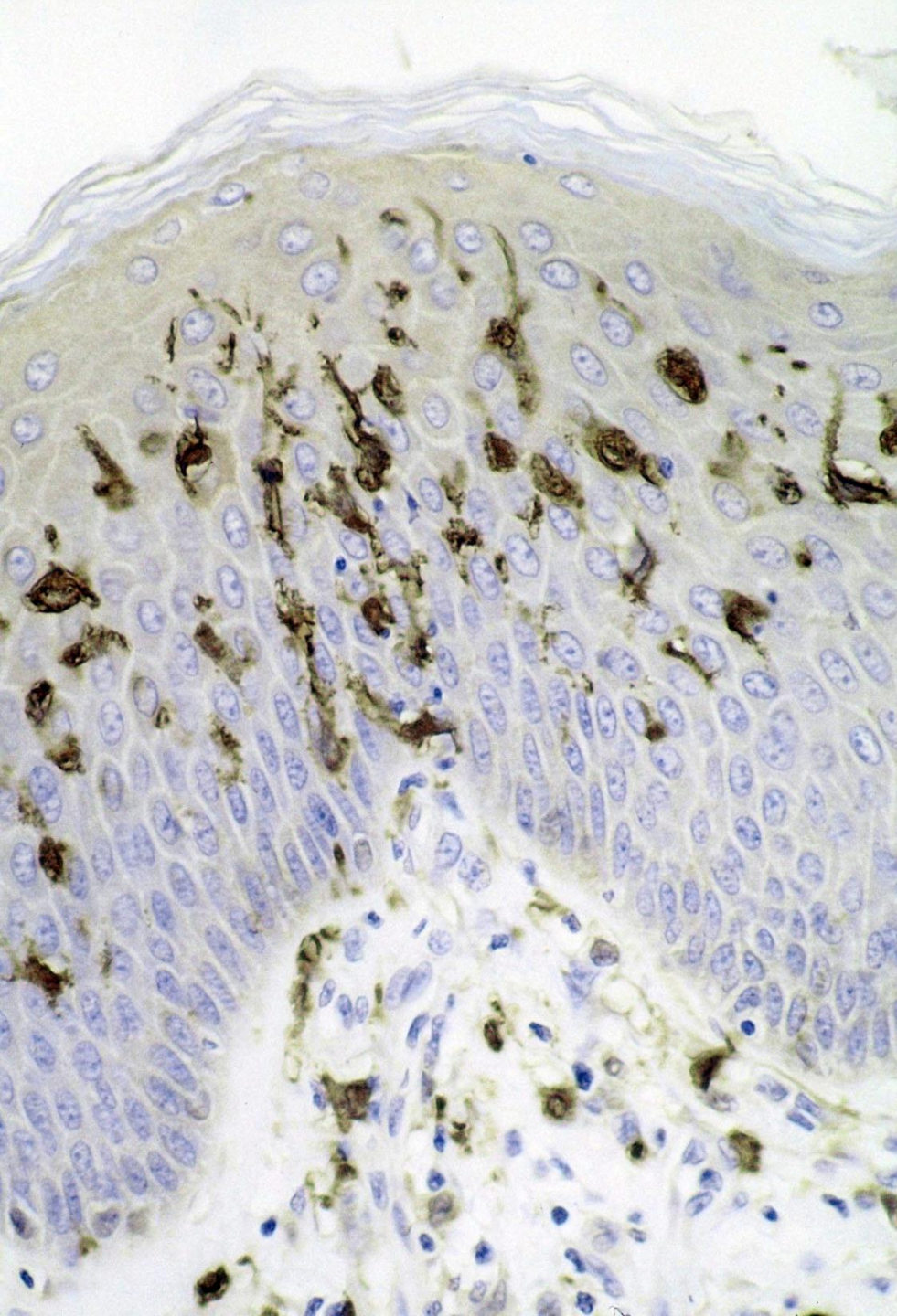
Antijen Sunan Hücre-Foliküler Dendritik hücre



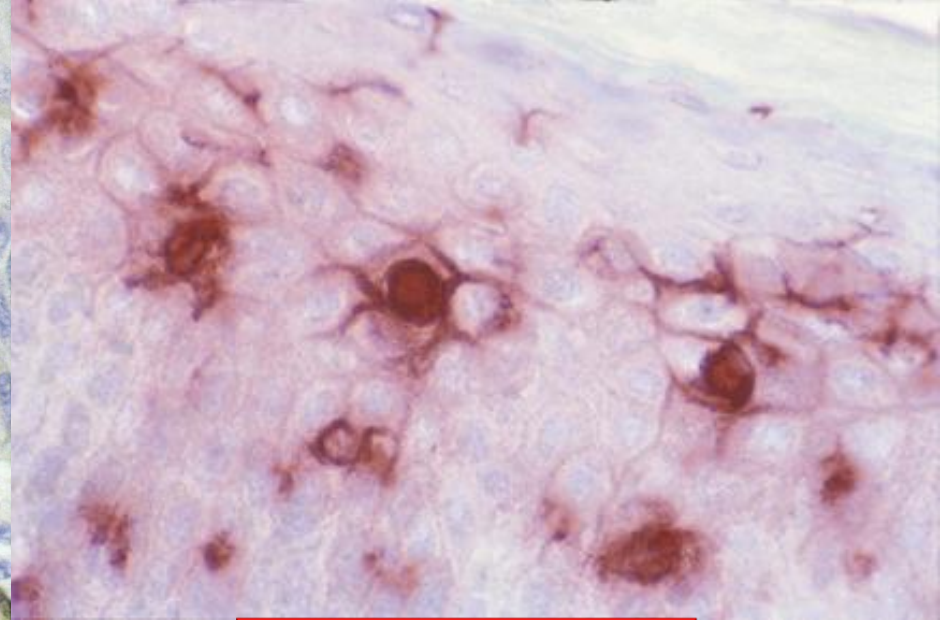
# Antijen Sunan Hücre – Langerhans Hücresi





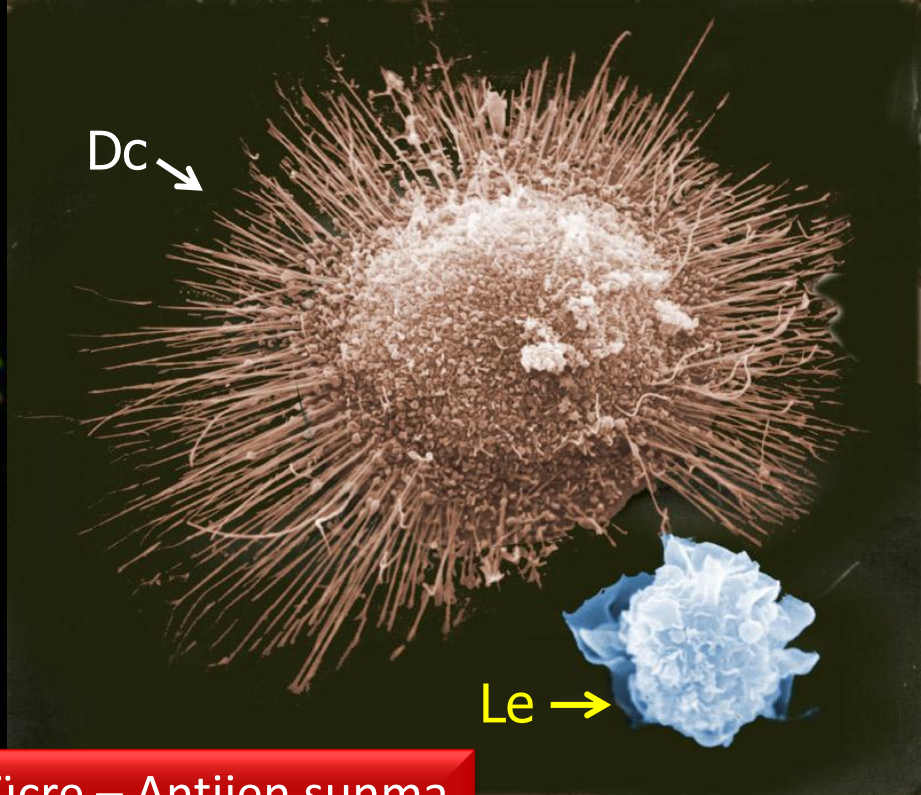
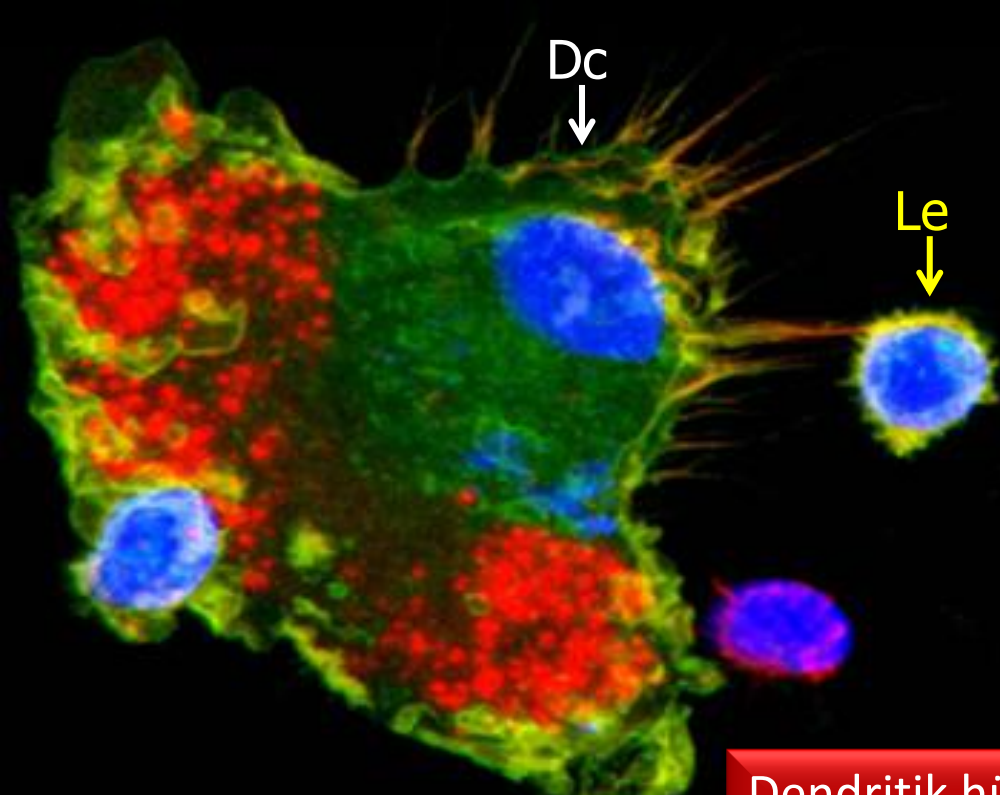


Langerhans adacıkları  
(Pankreas)

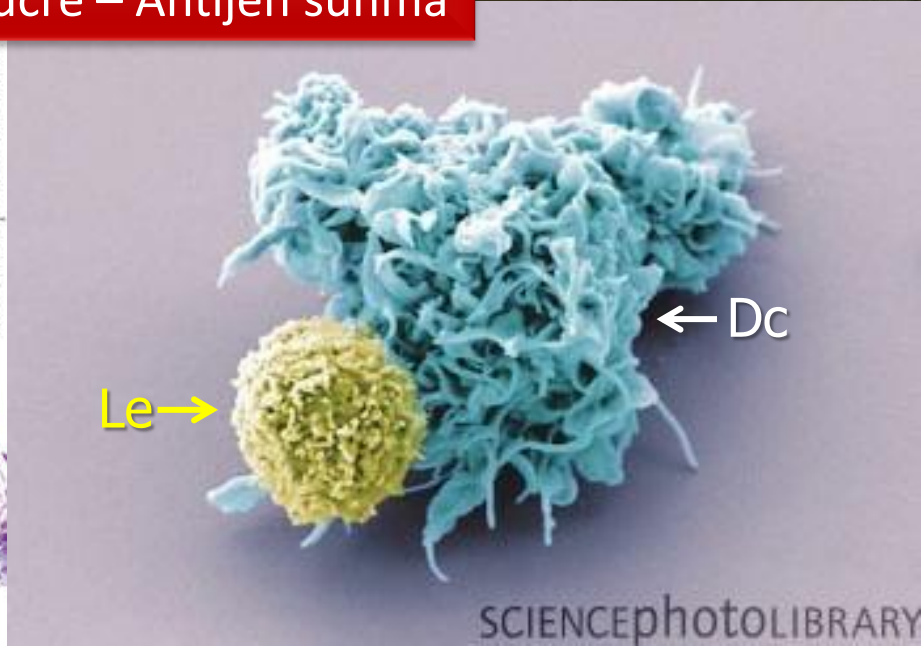
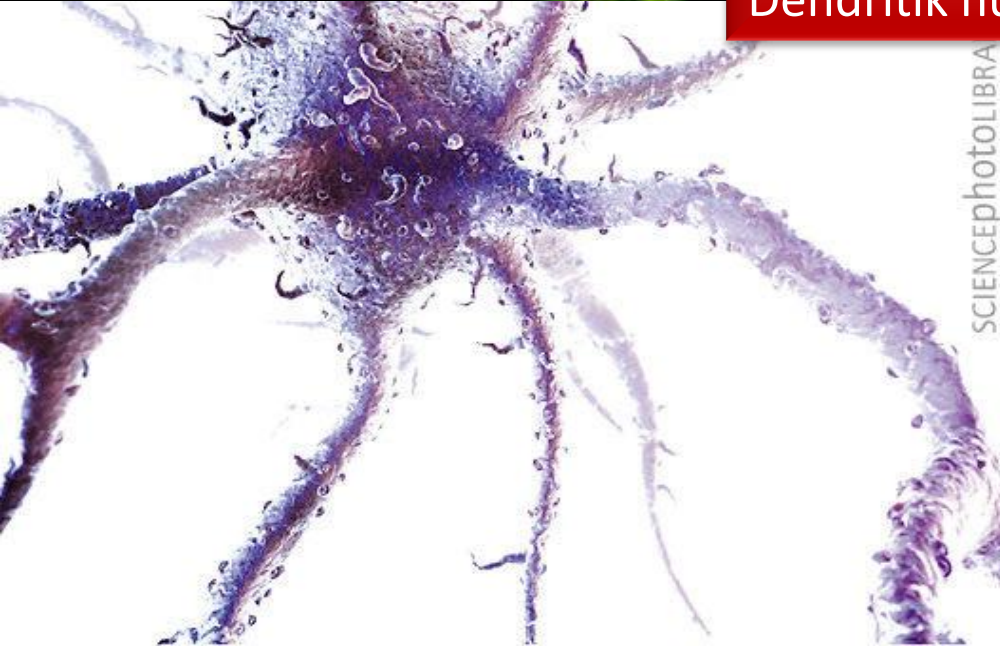


Langerhans hücresi

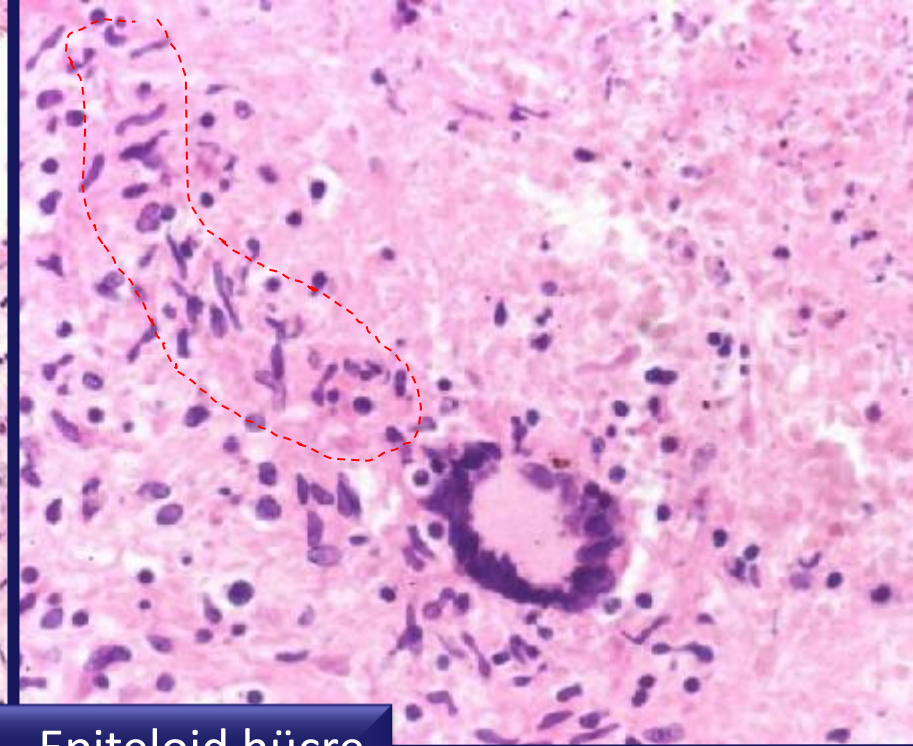
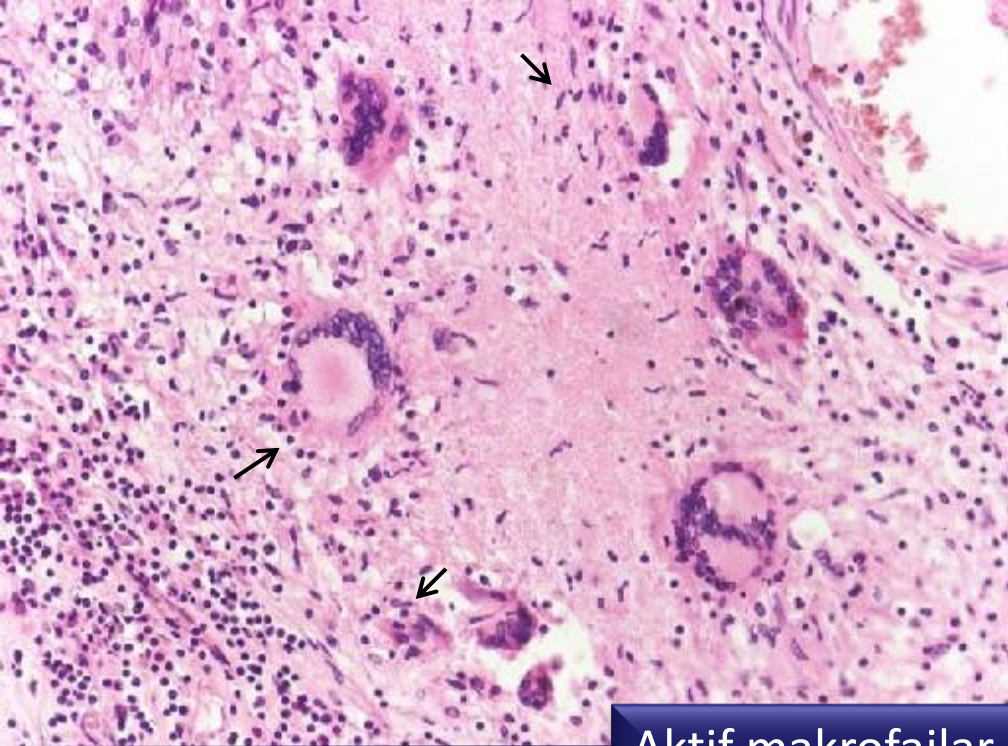




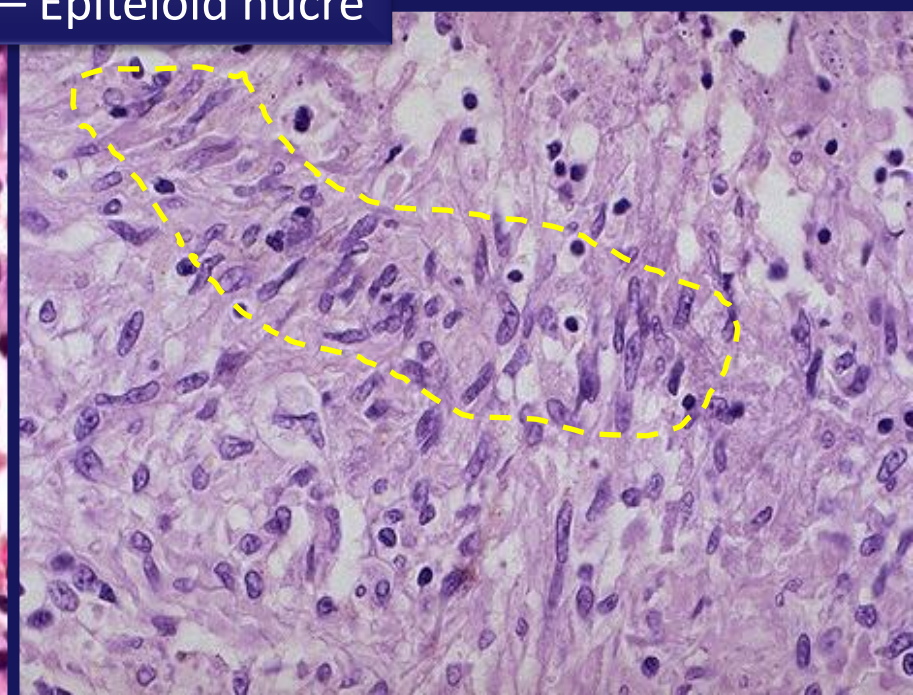
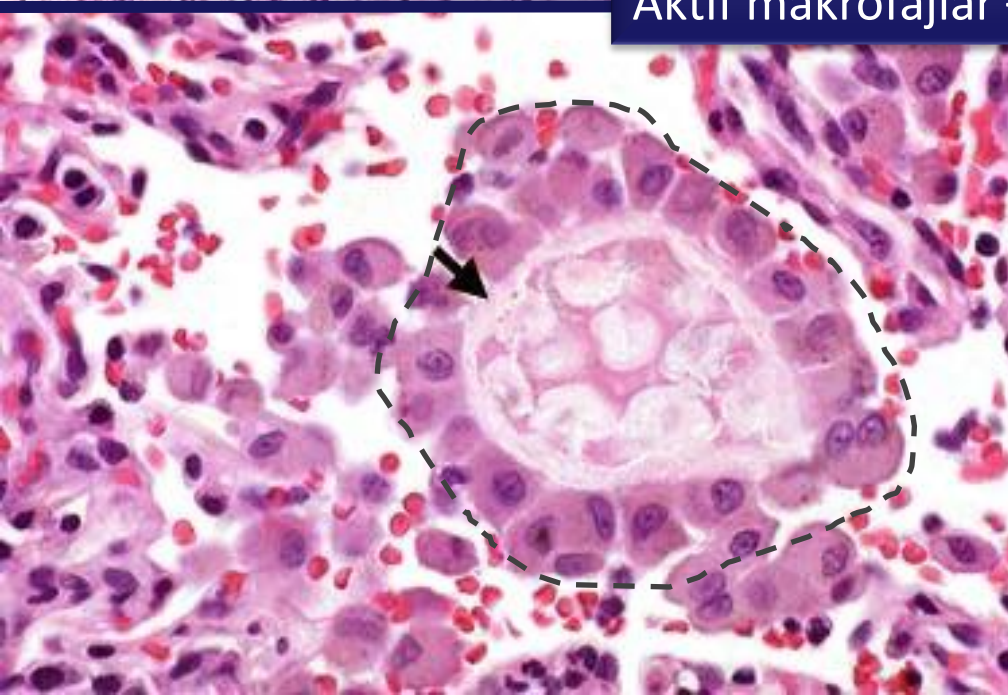
Dendritik hücre – Antijen sunma



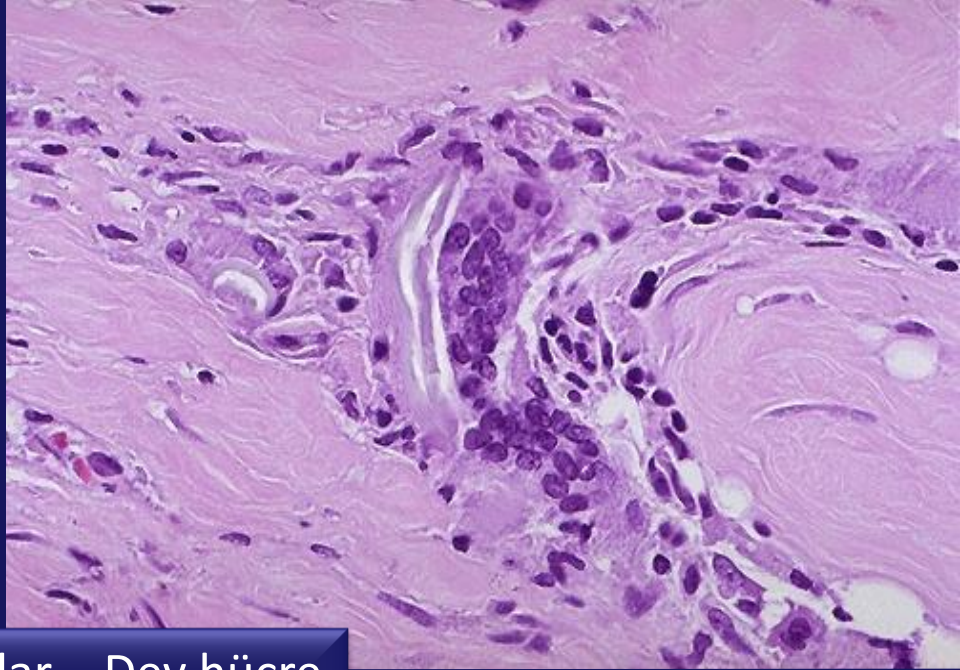
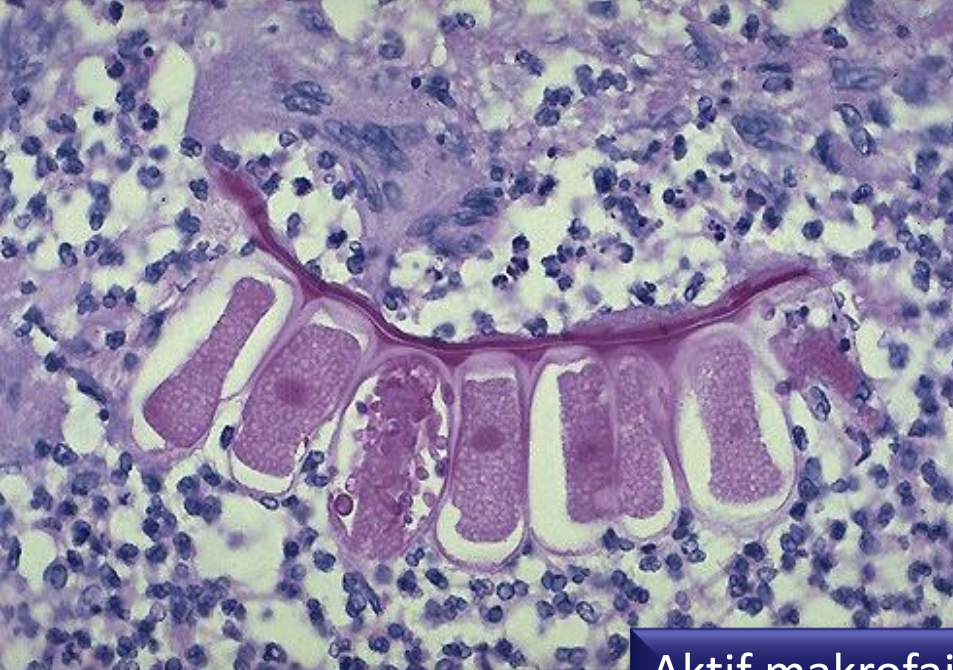



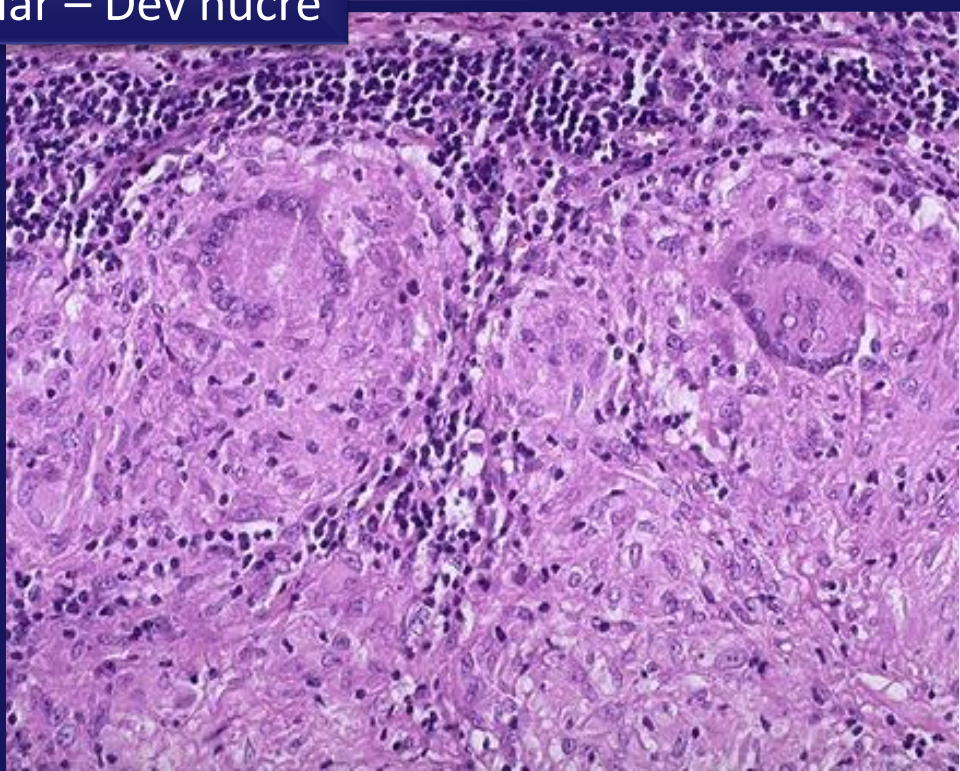
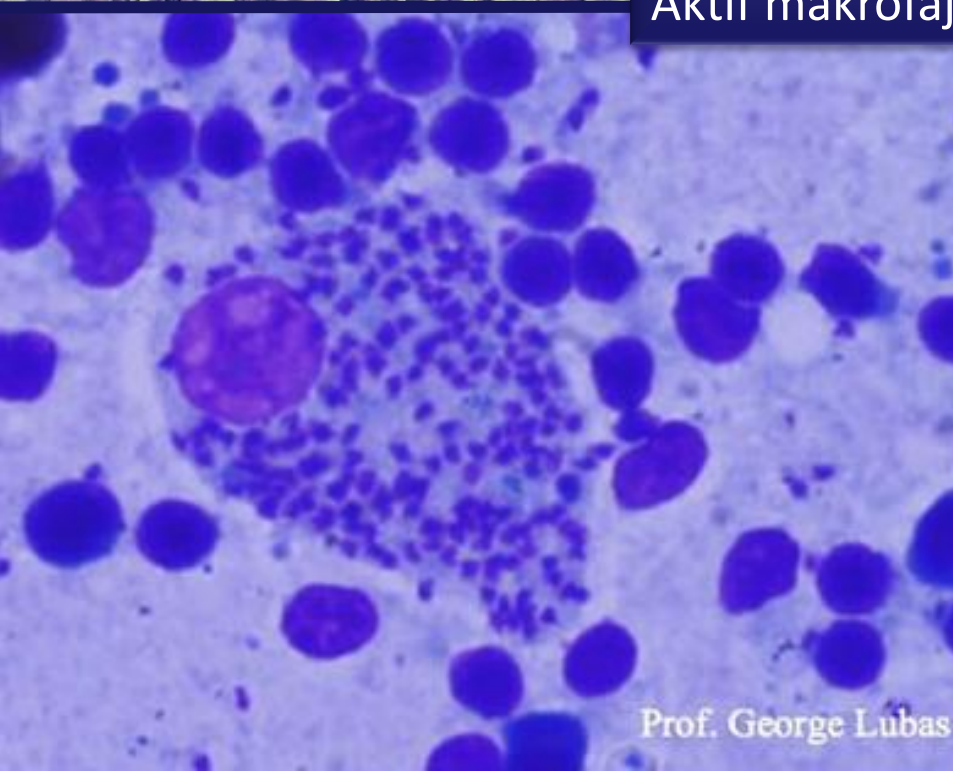
Aktif makrofajlar – Epiteloid hücre



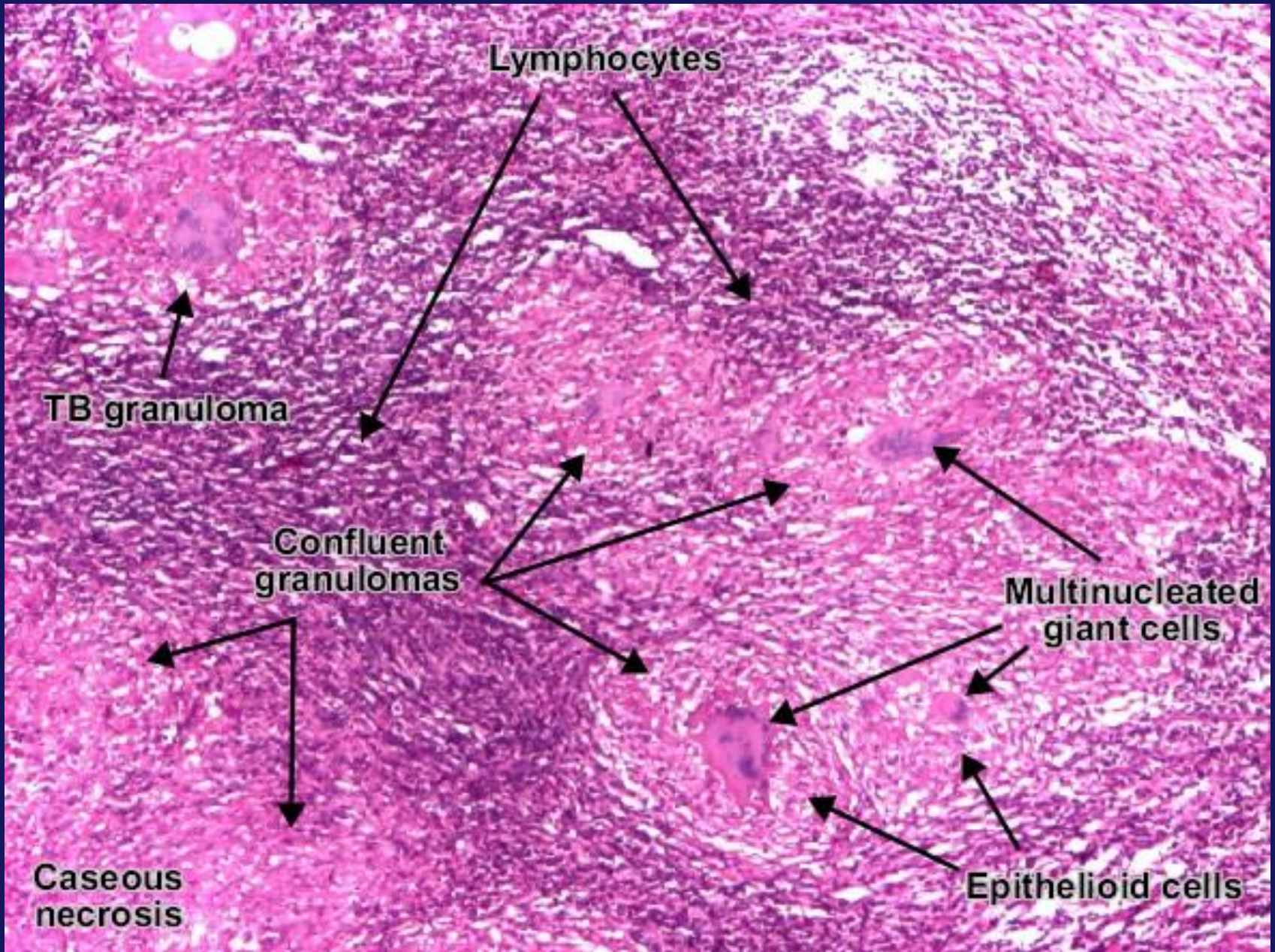




Aktif makrofajlar – Dev hücre

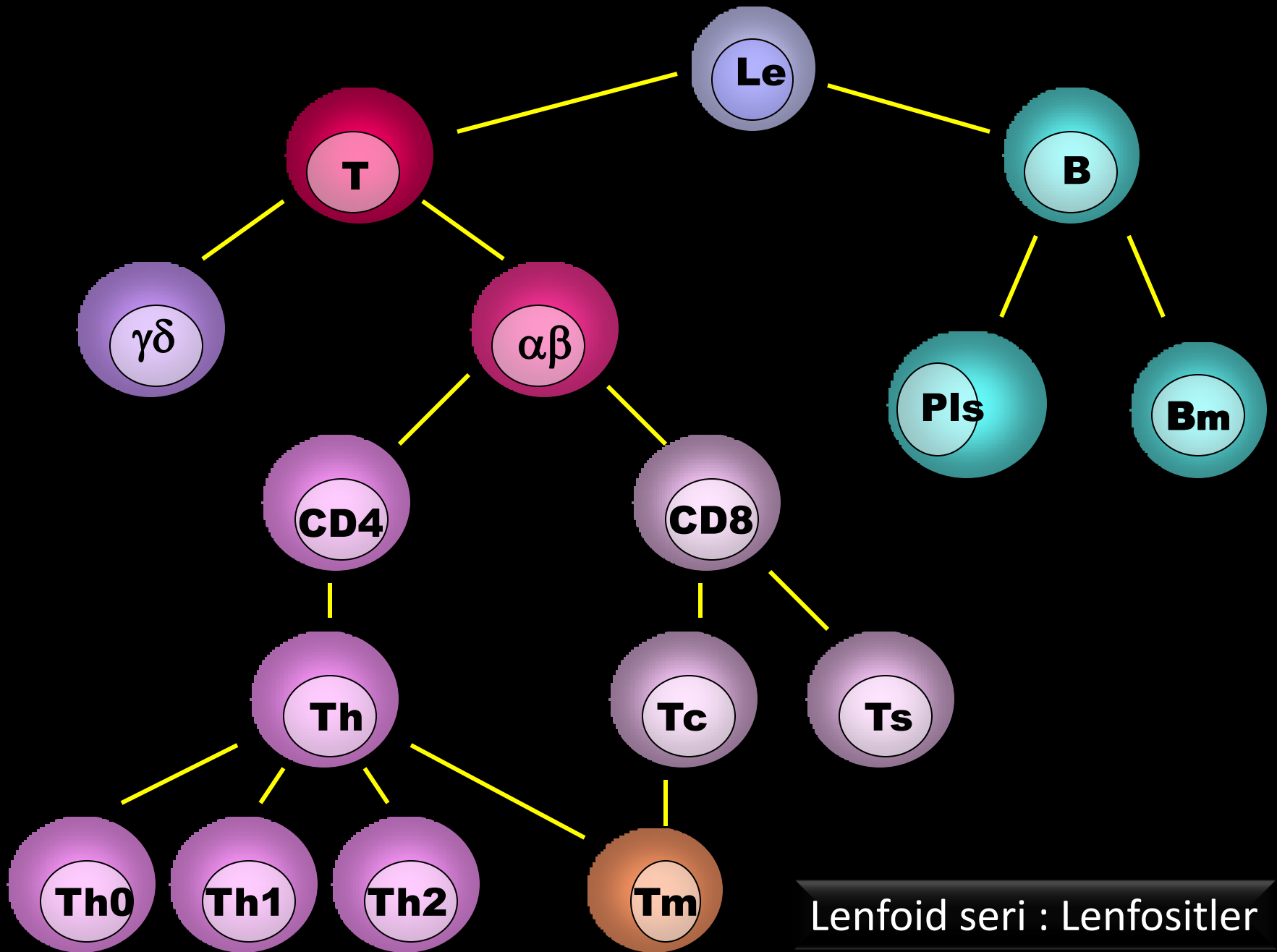






Aktif makrofajlar : Epiteloid hücre – Dev hücre

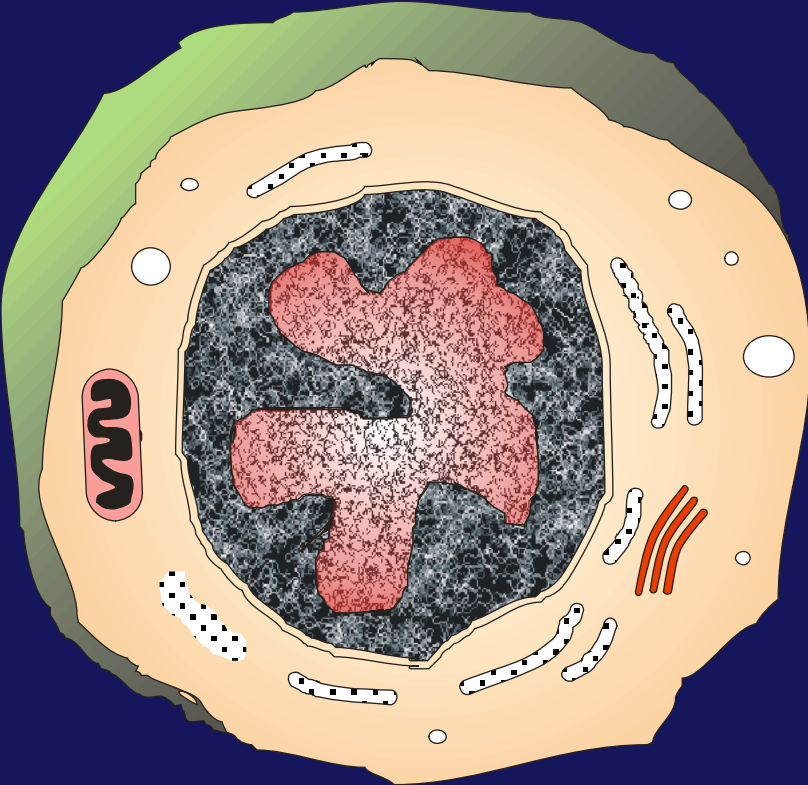




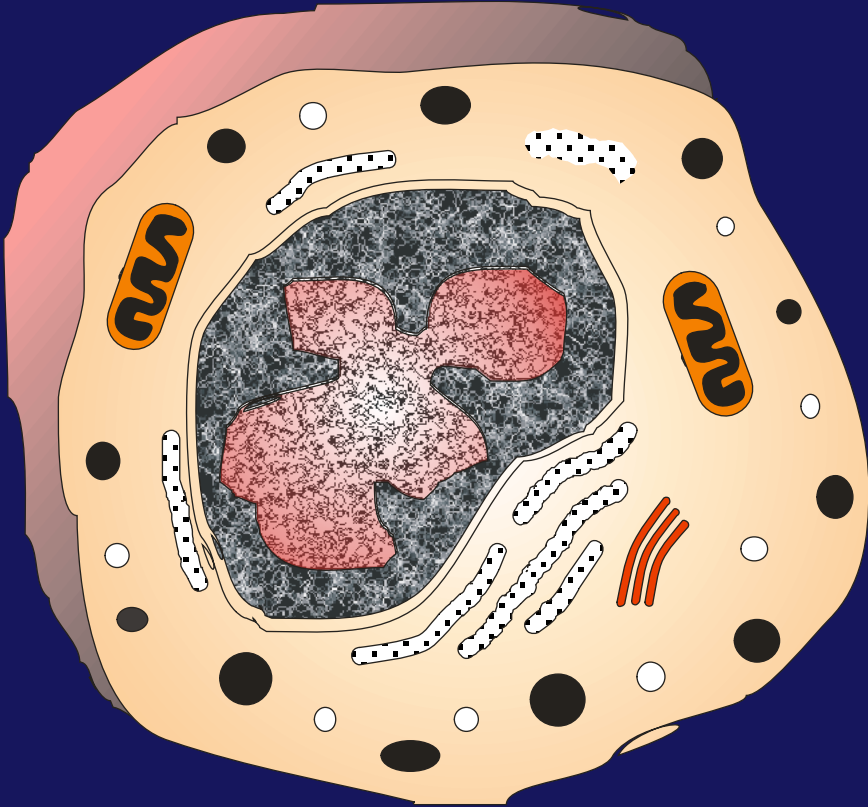
Lenfoid seri : Lenfositler



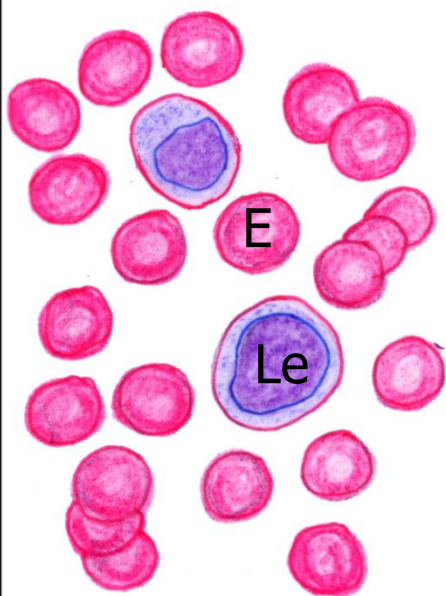
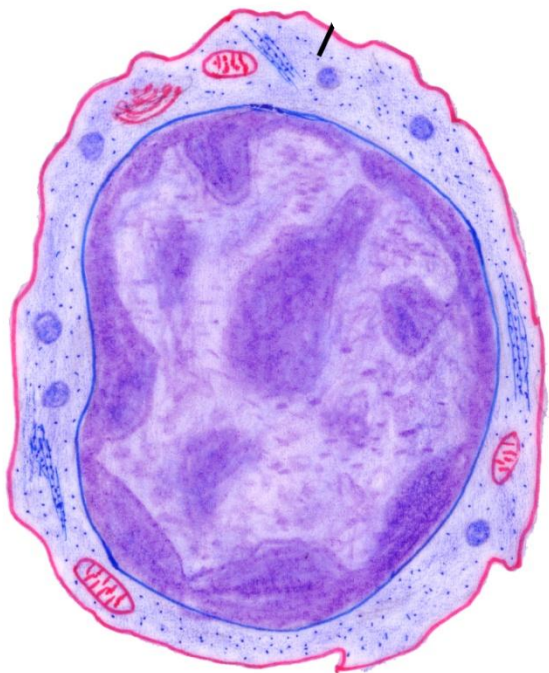
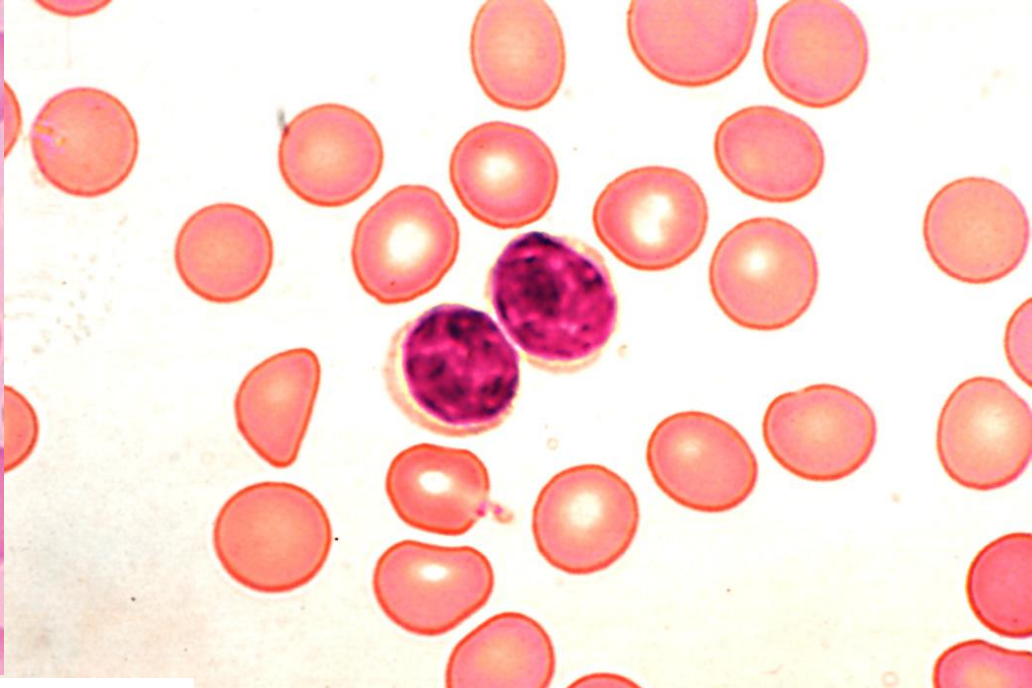
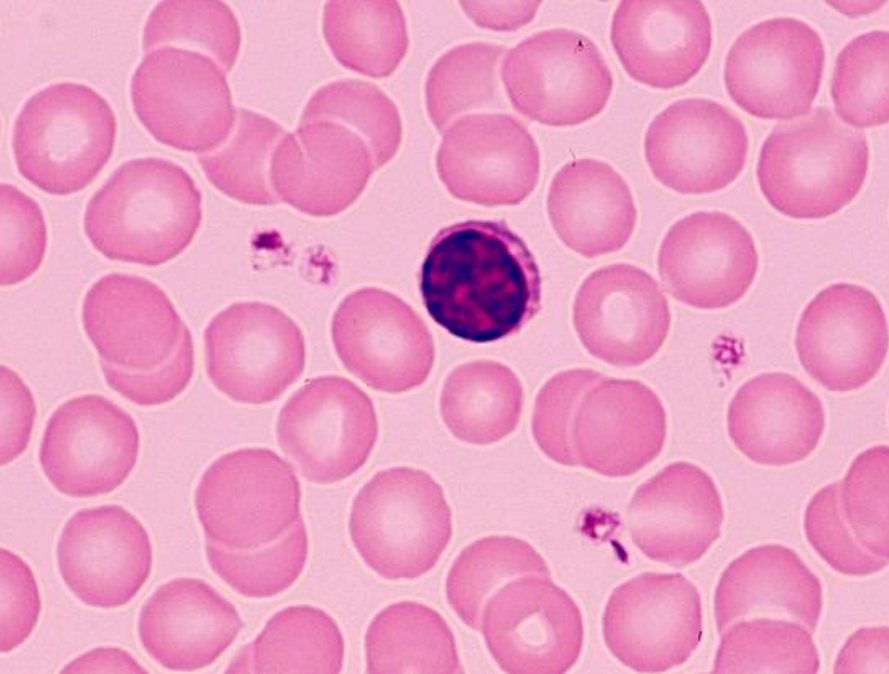
B-lenfosit



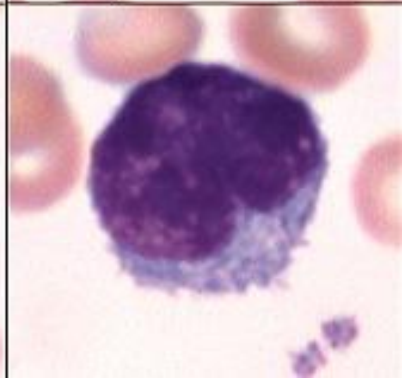
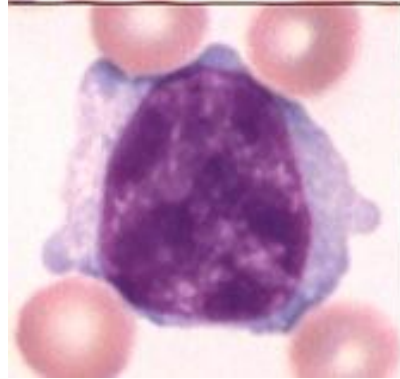
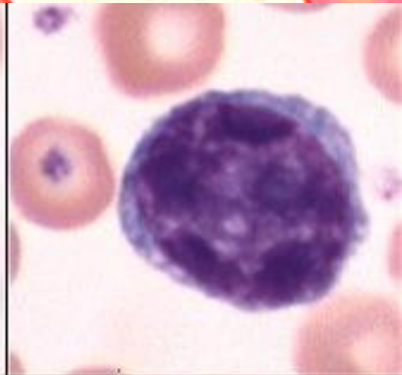
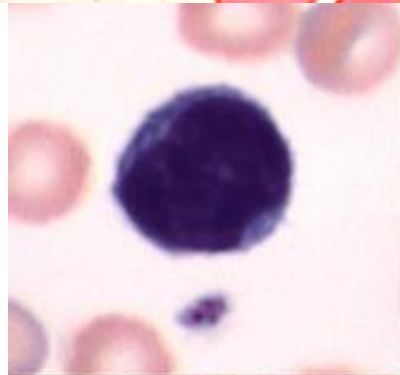
T-lenfosit



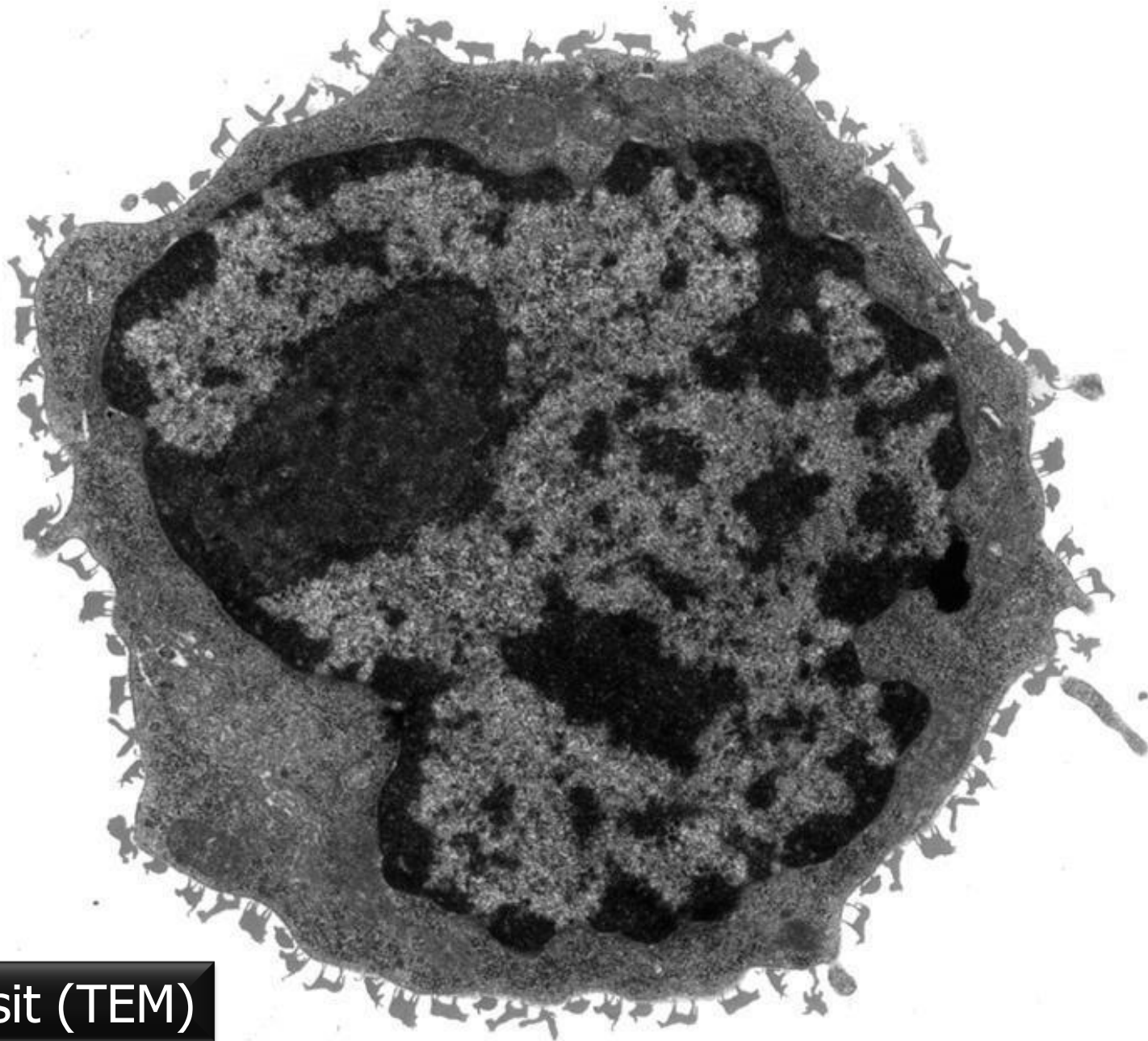




Lenfositler



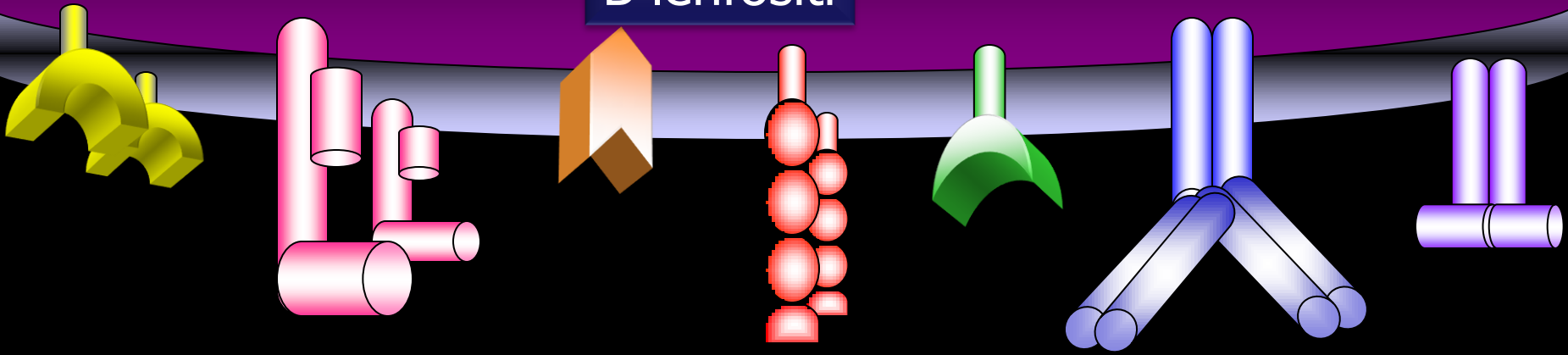




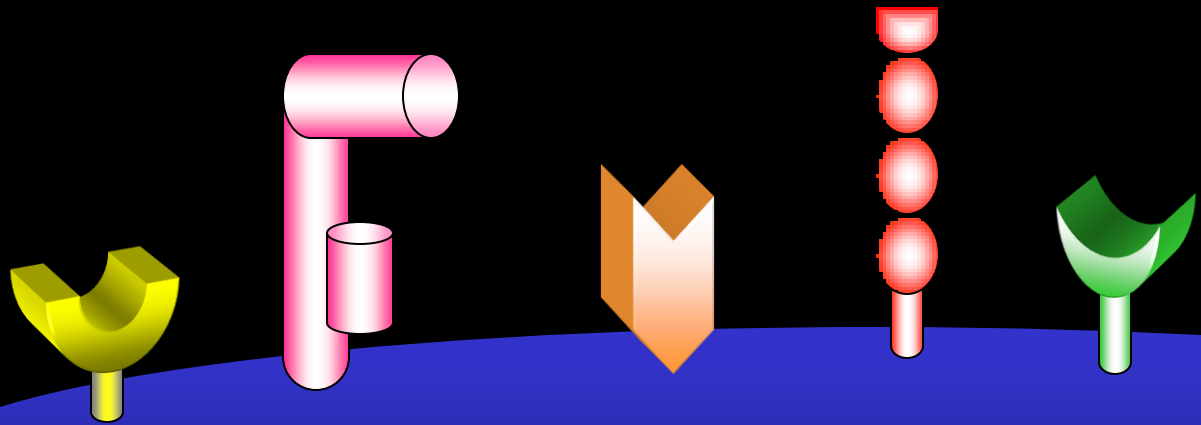
Lenfosit (TEM)



B lenfositü

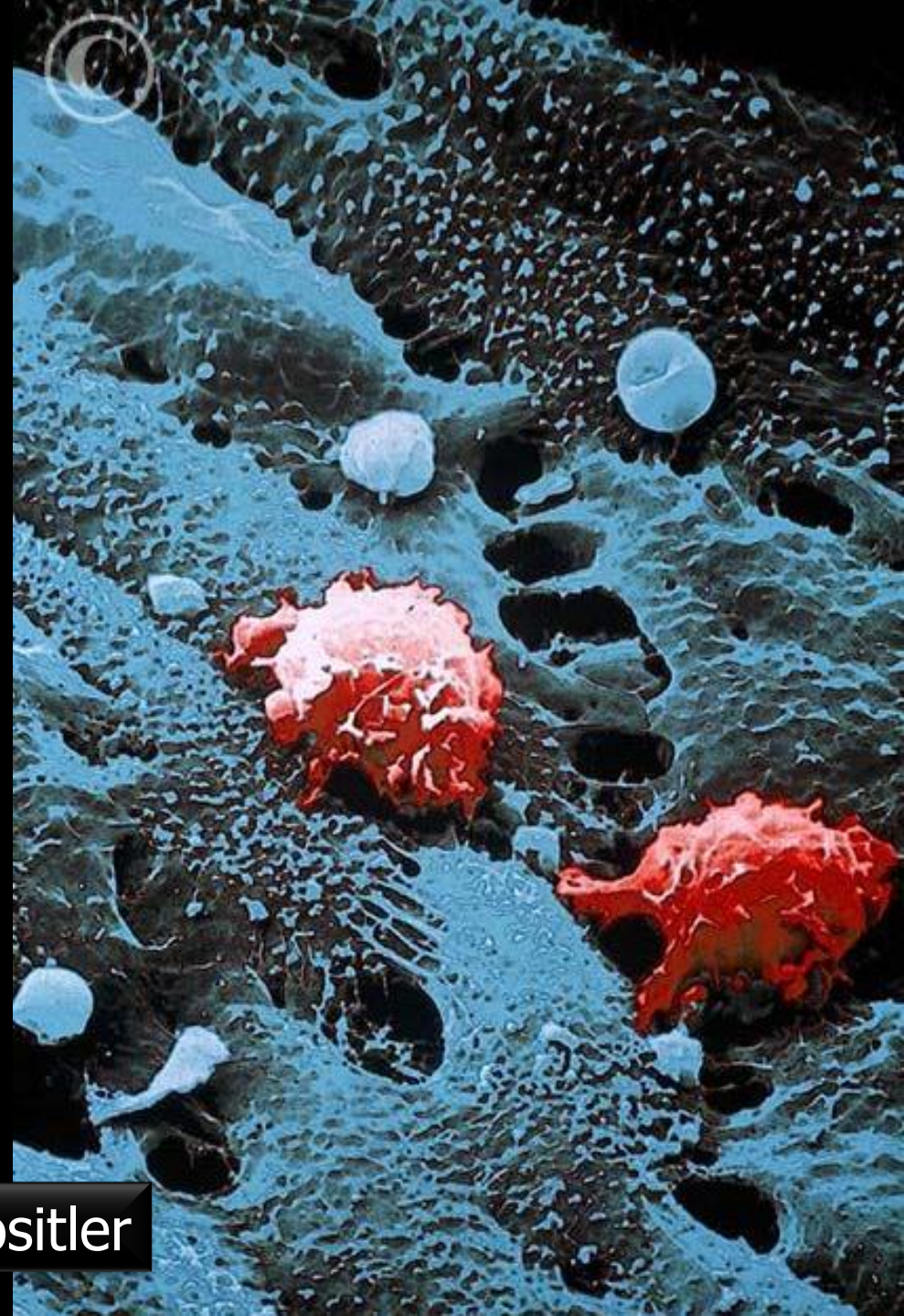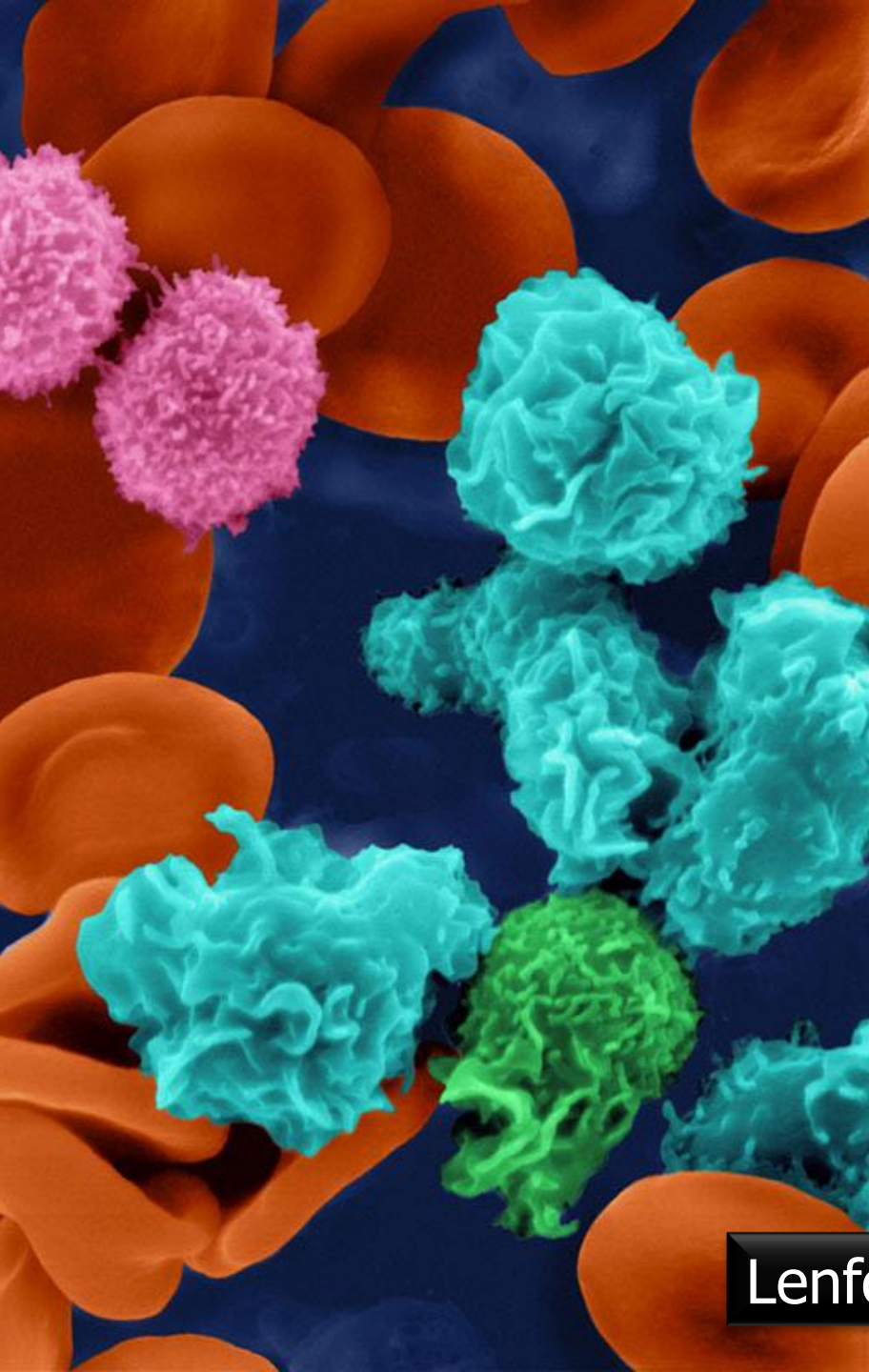


Lenfositlerin yüzey molekülleri



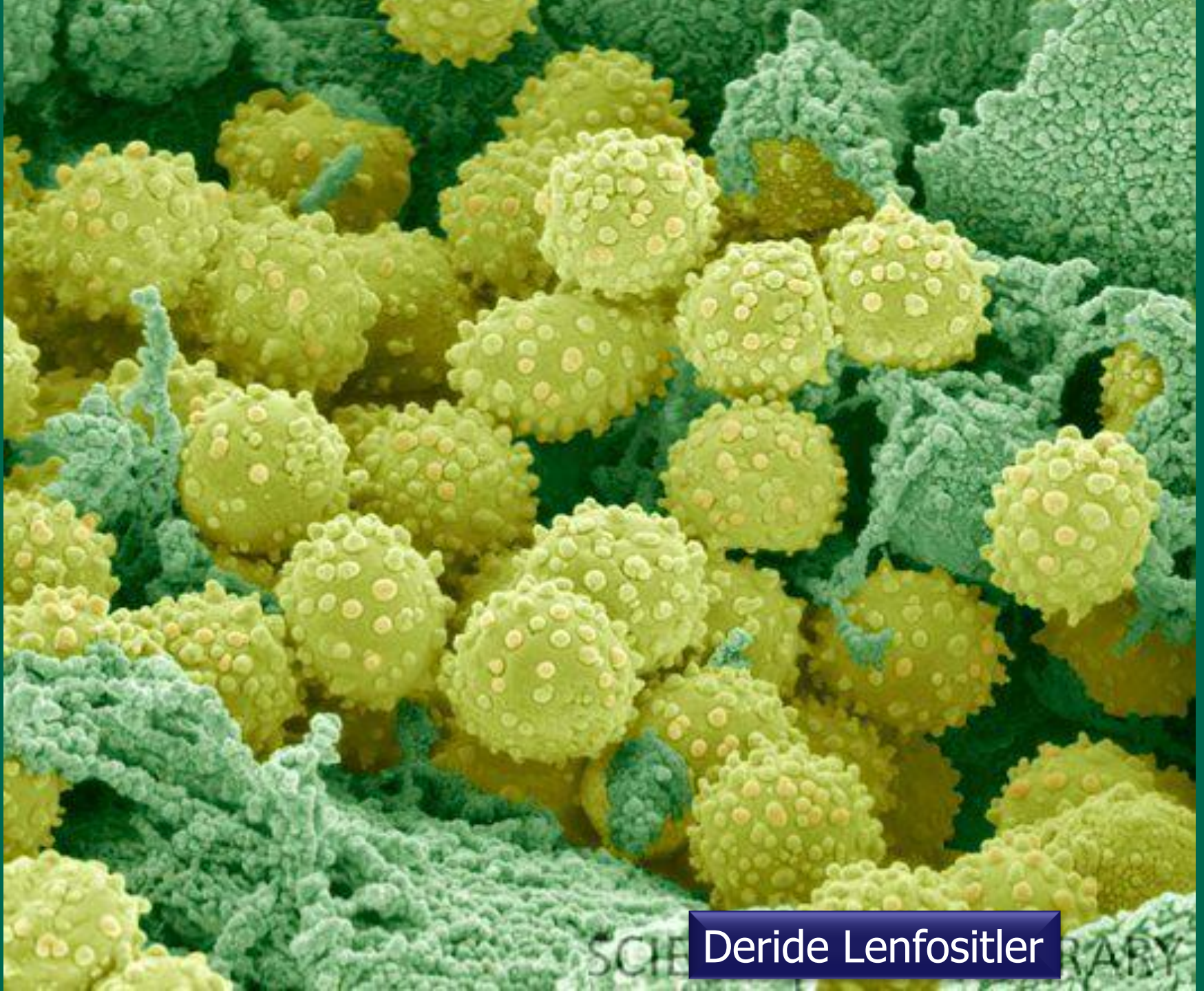
T lenfositü





Lenfositler





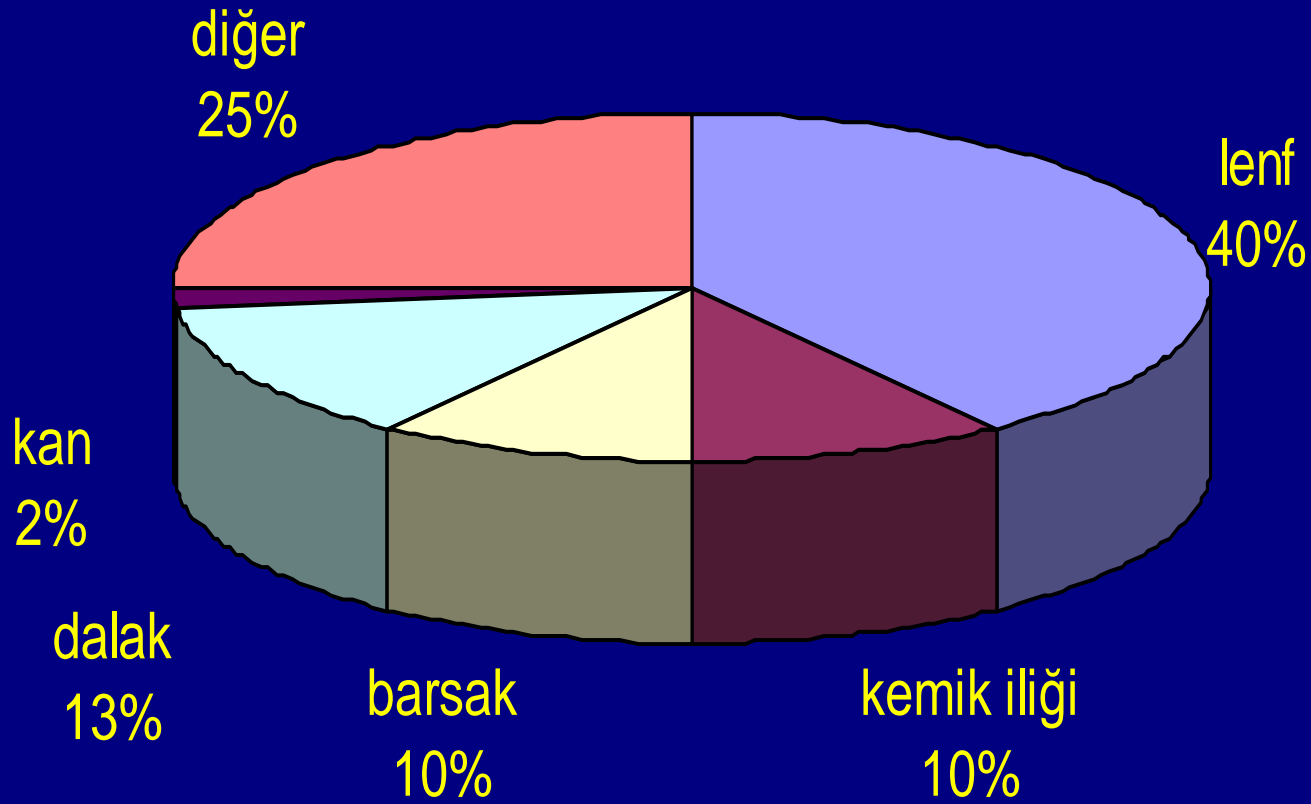
Deride Lenfositler

SCIENCE

LIBRARY

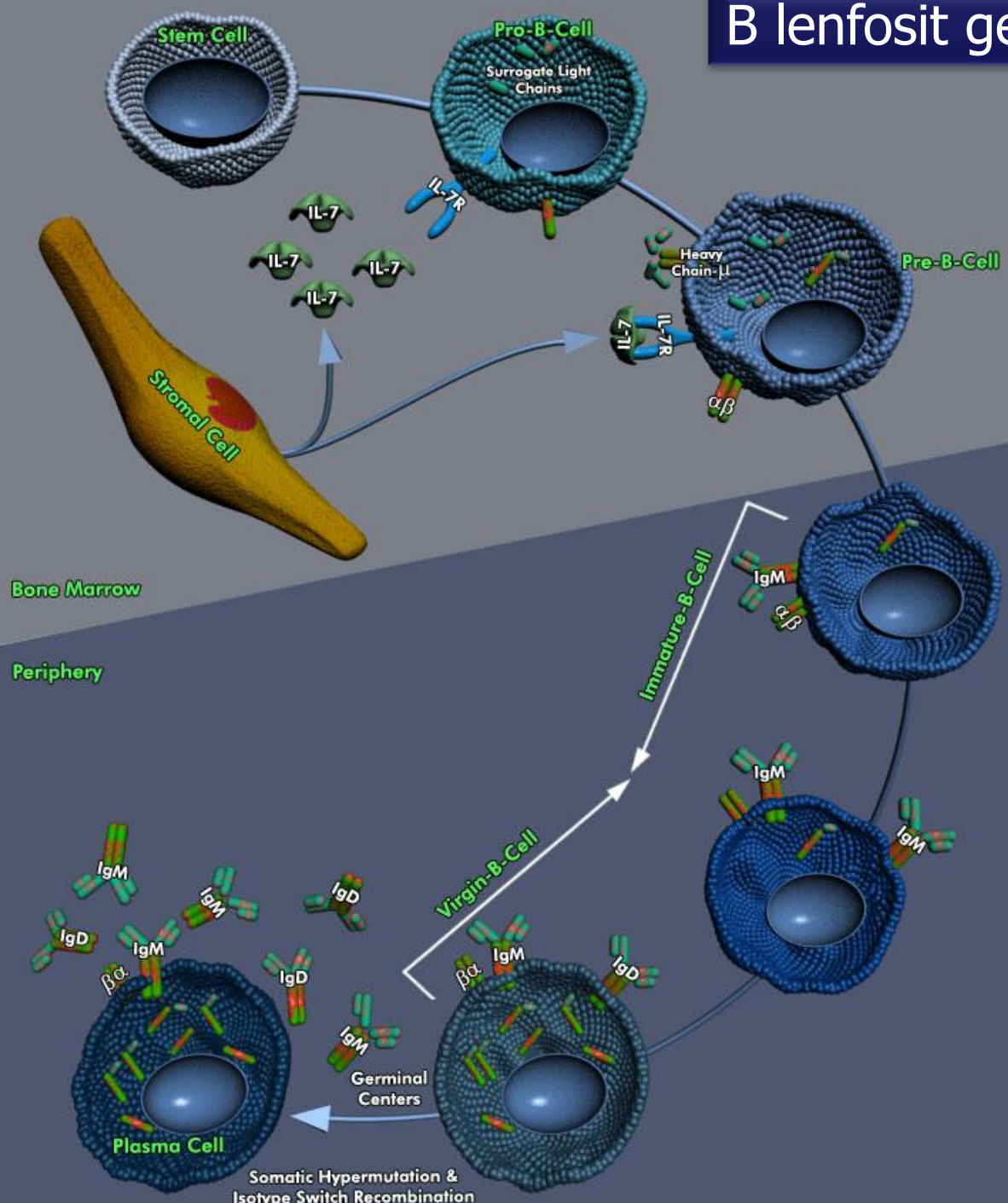


## Lenfositlerin Organlardaki Dağılımı

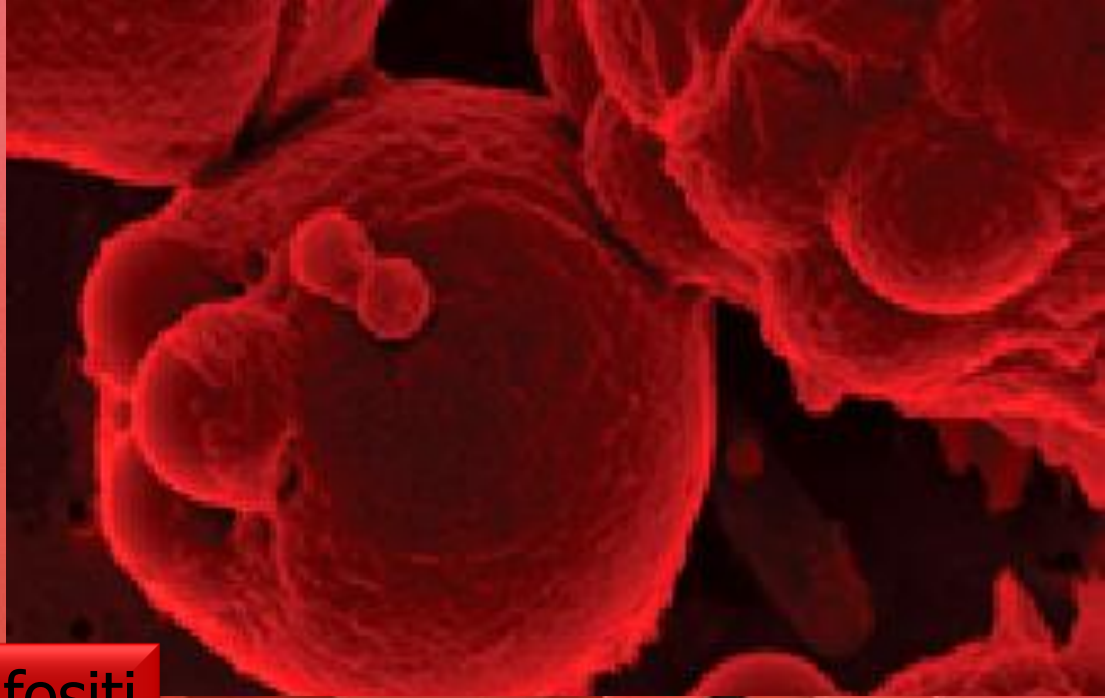
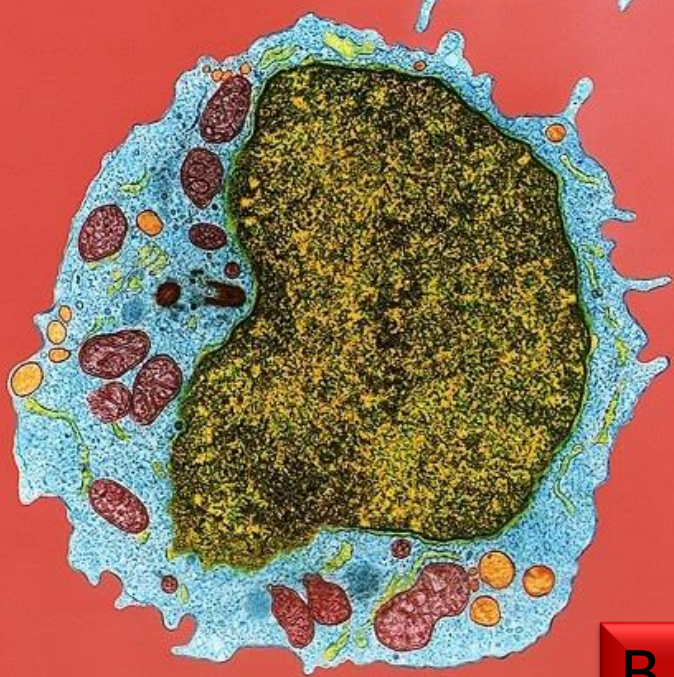



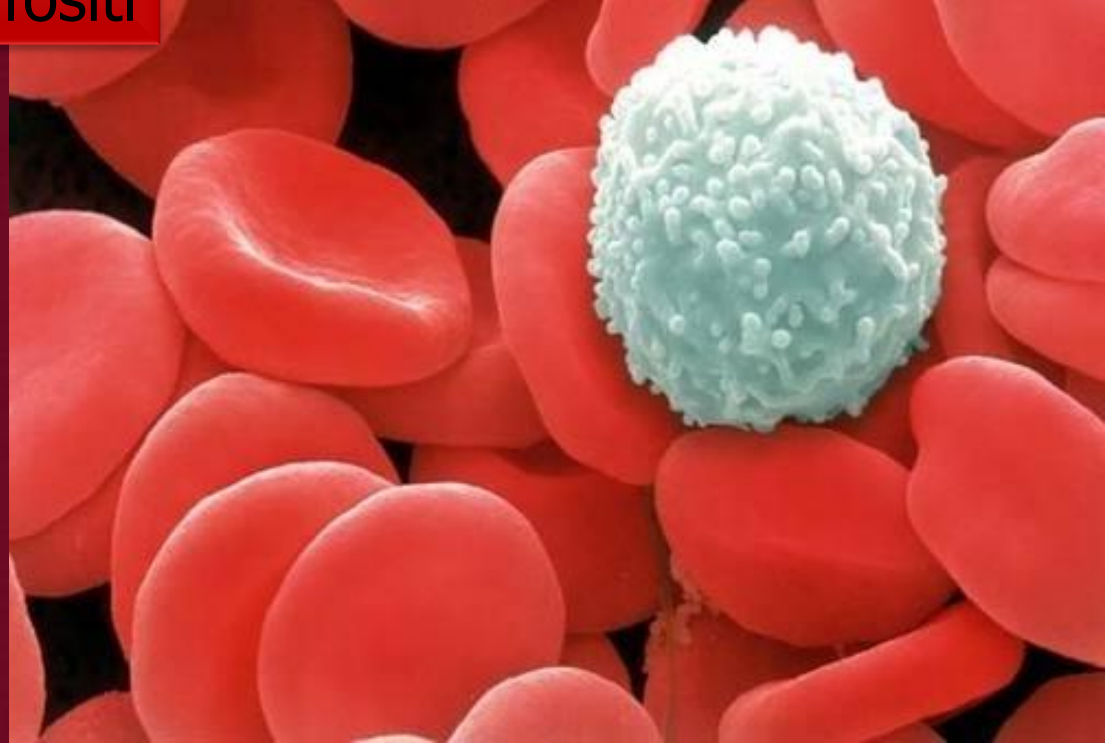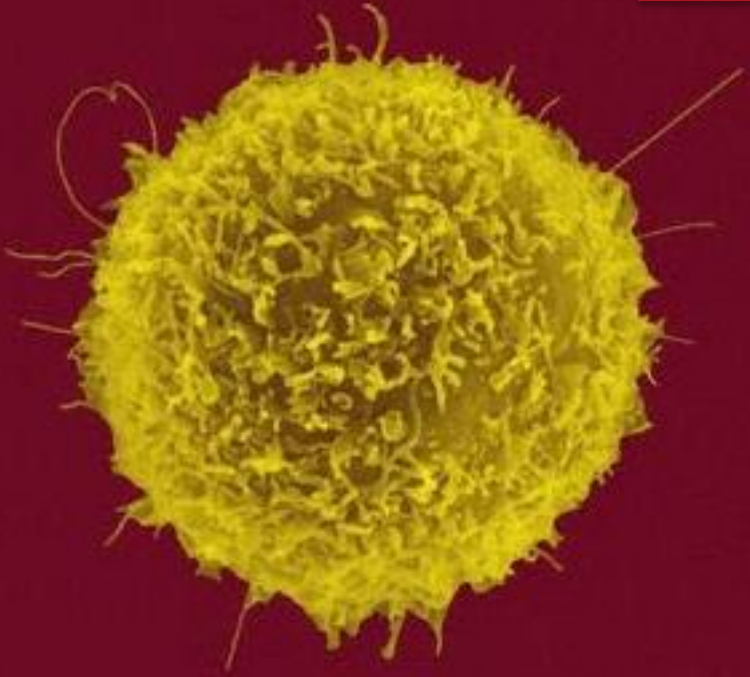
# B lenfosit gelişimi



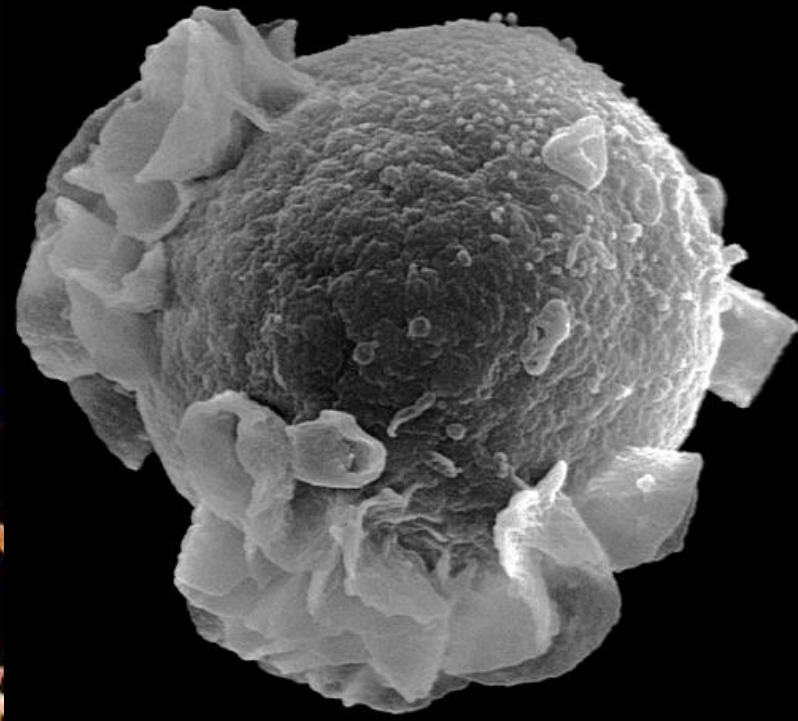
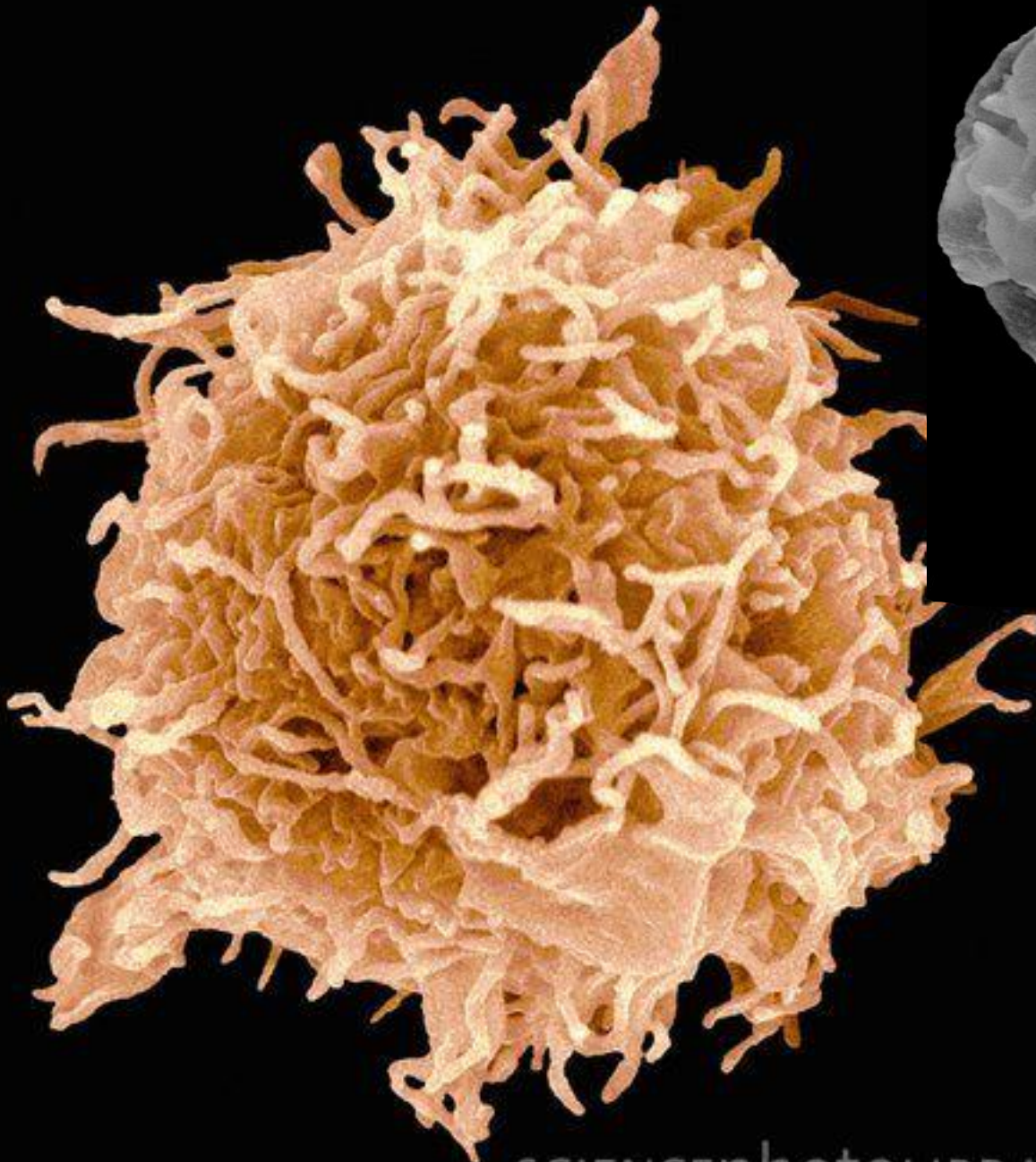




B lenfosit



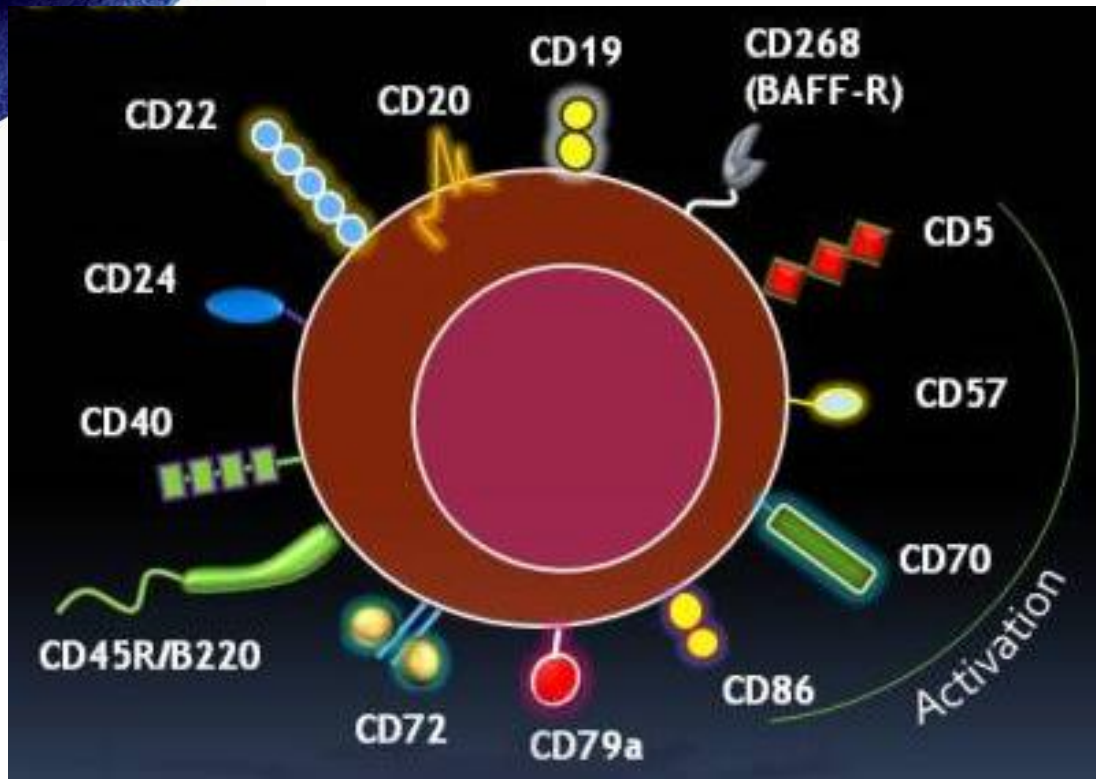
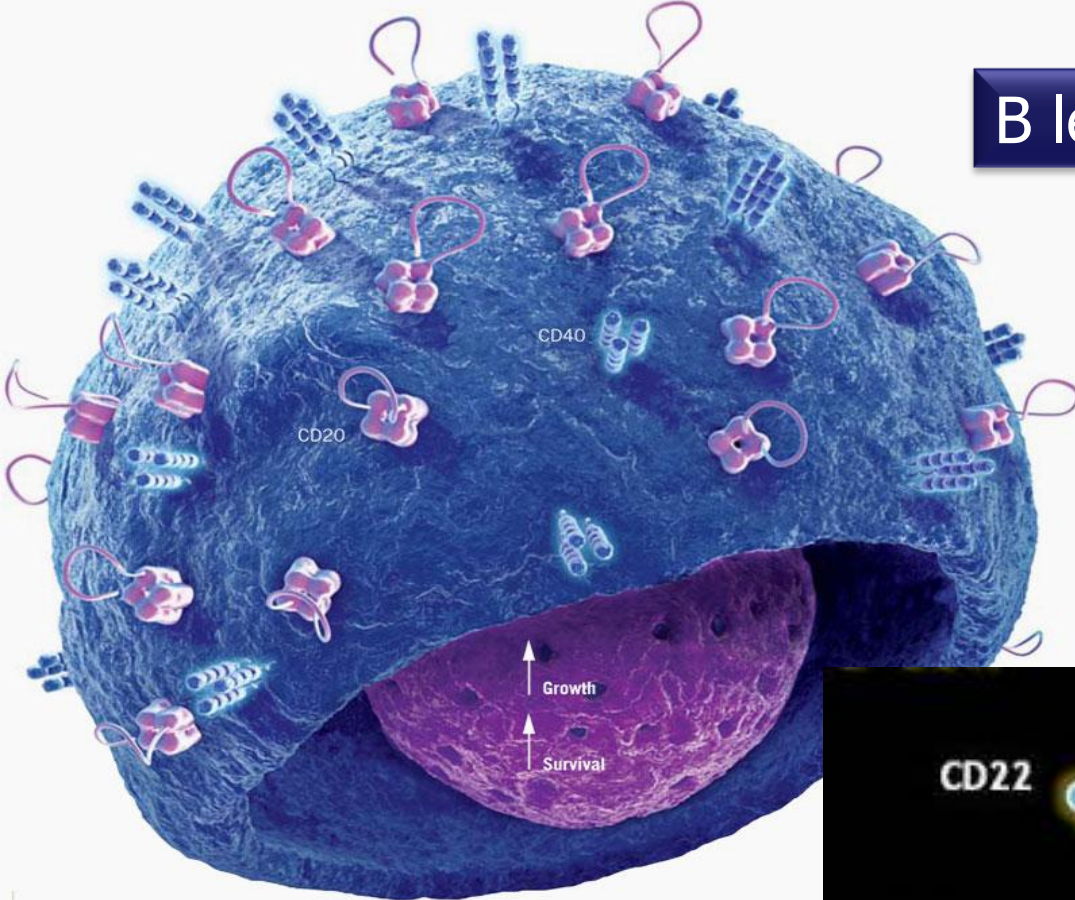




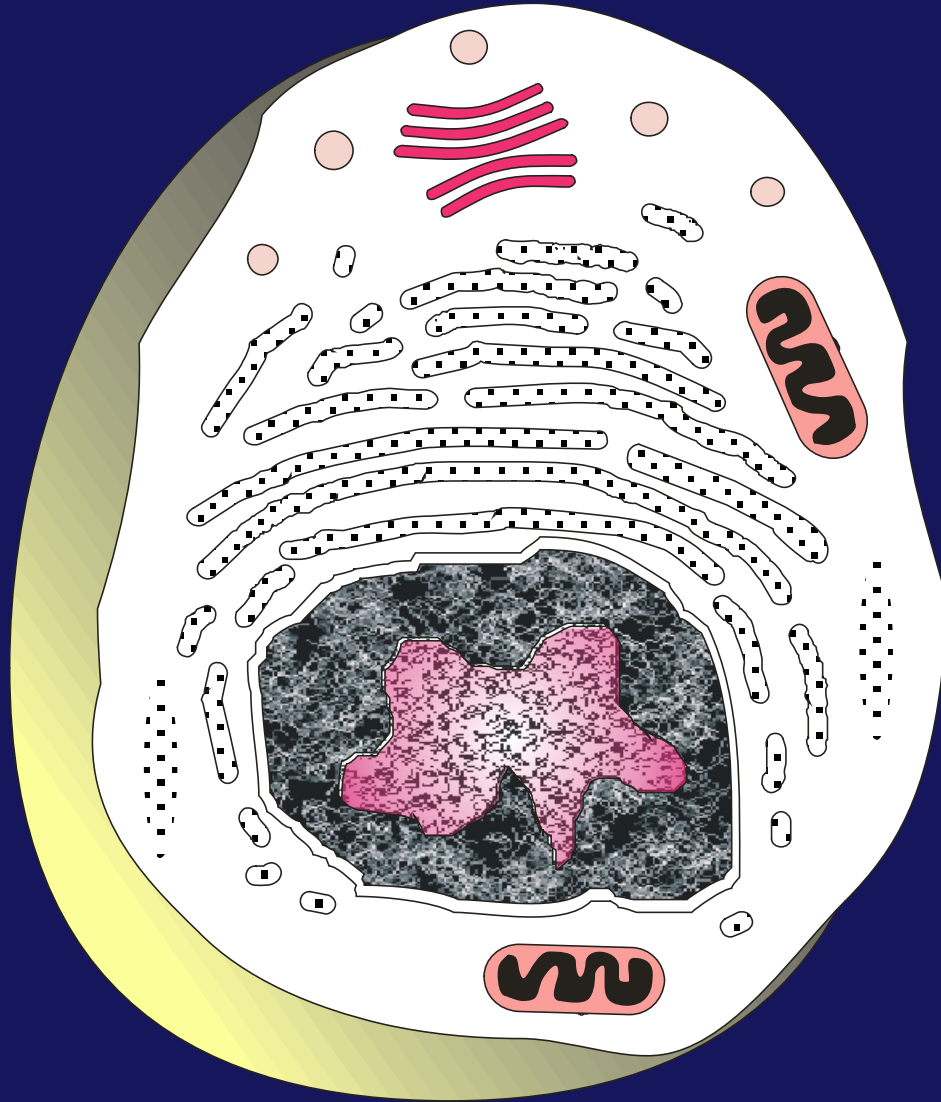
B lenfosit



# B lenfosit yüzey molekülleri

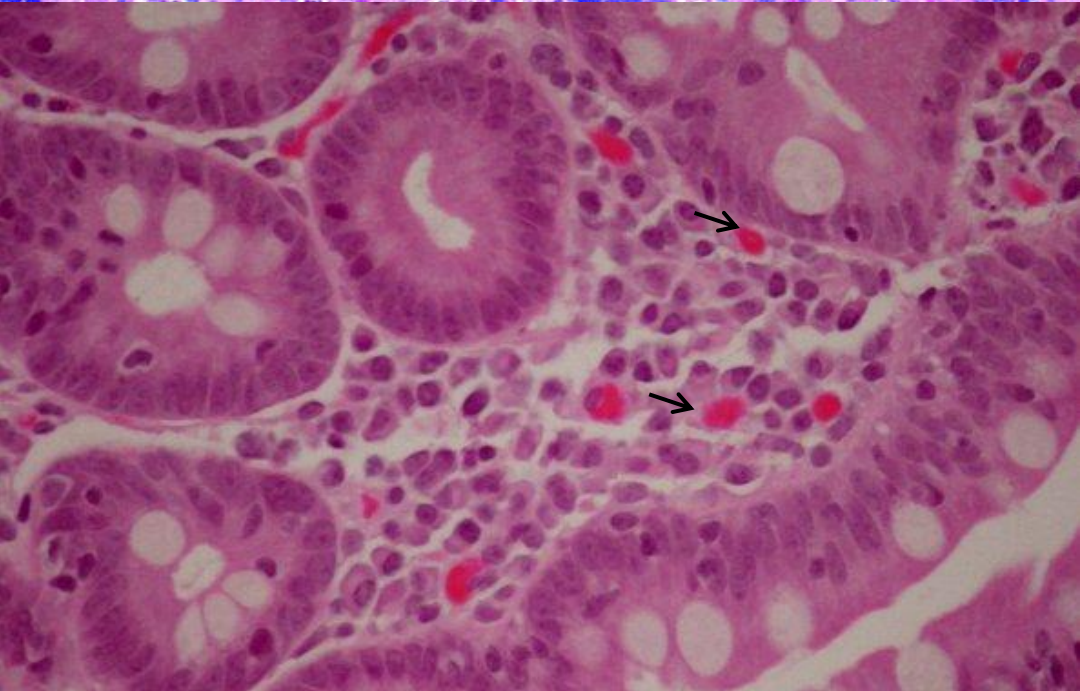
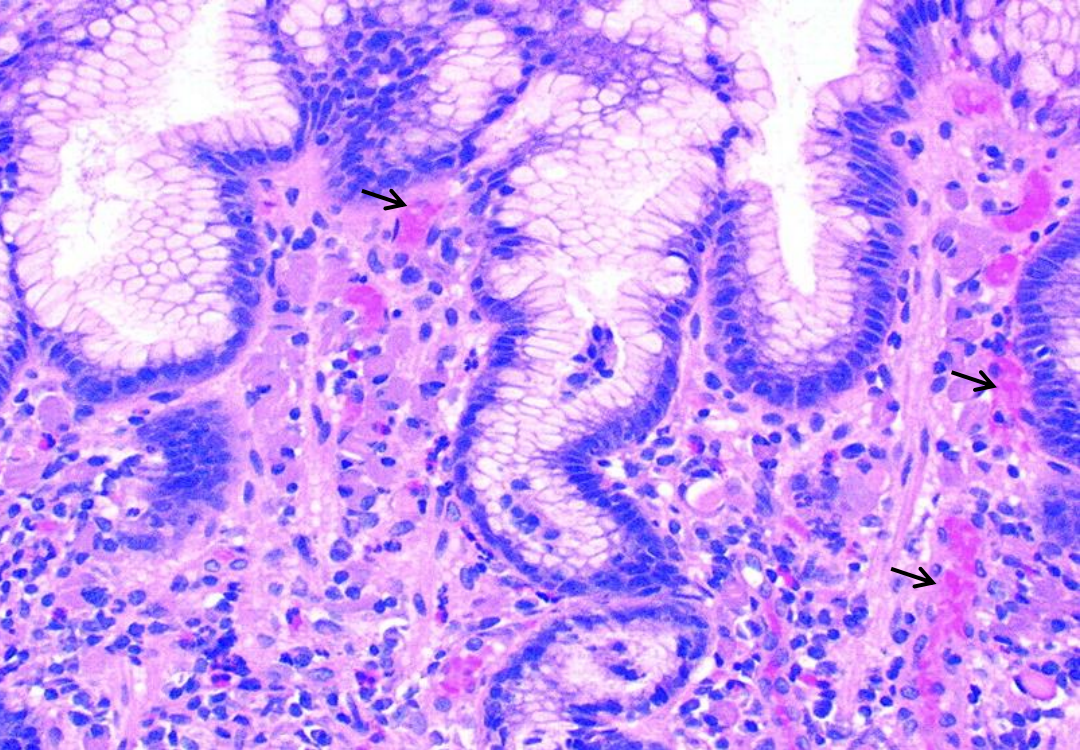
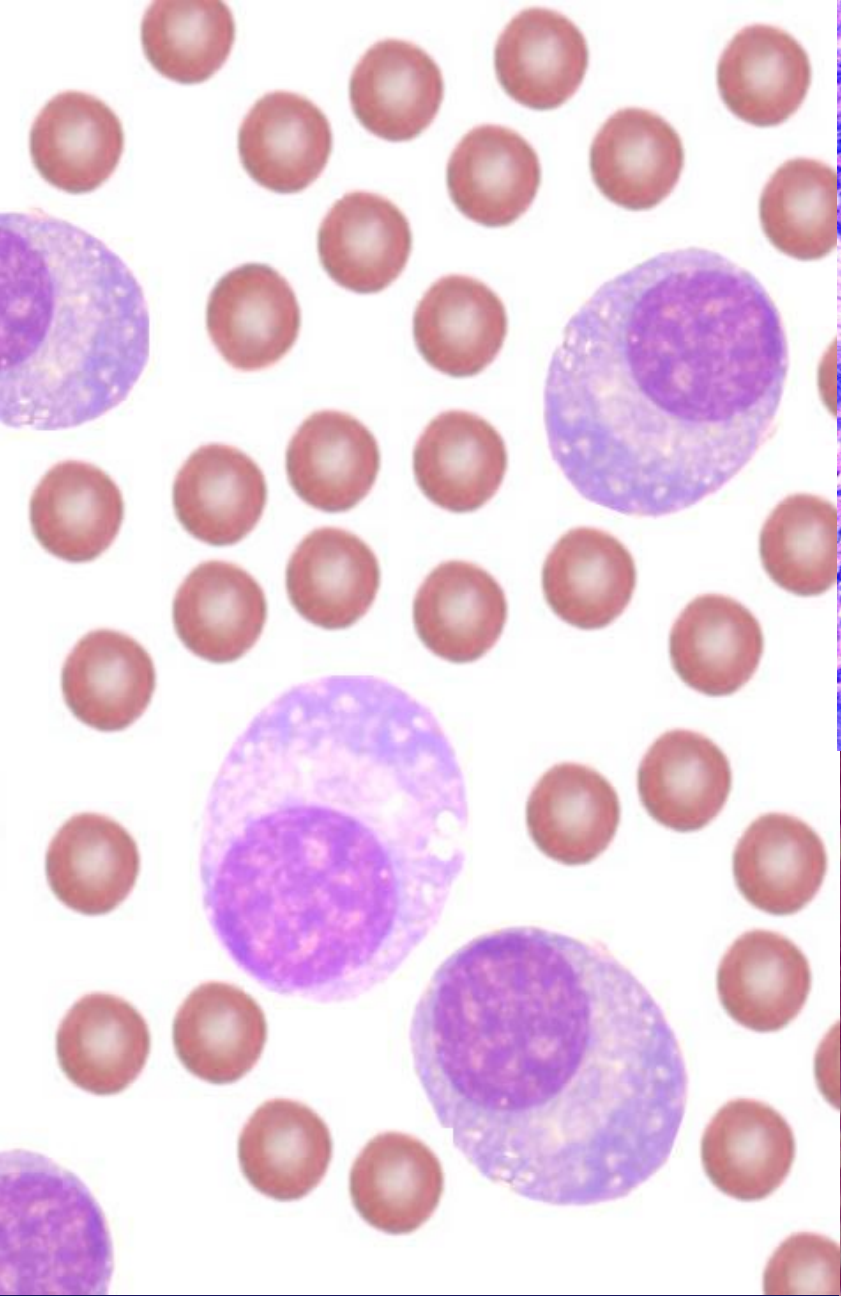






Plazma hücresi



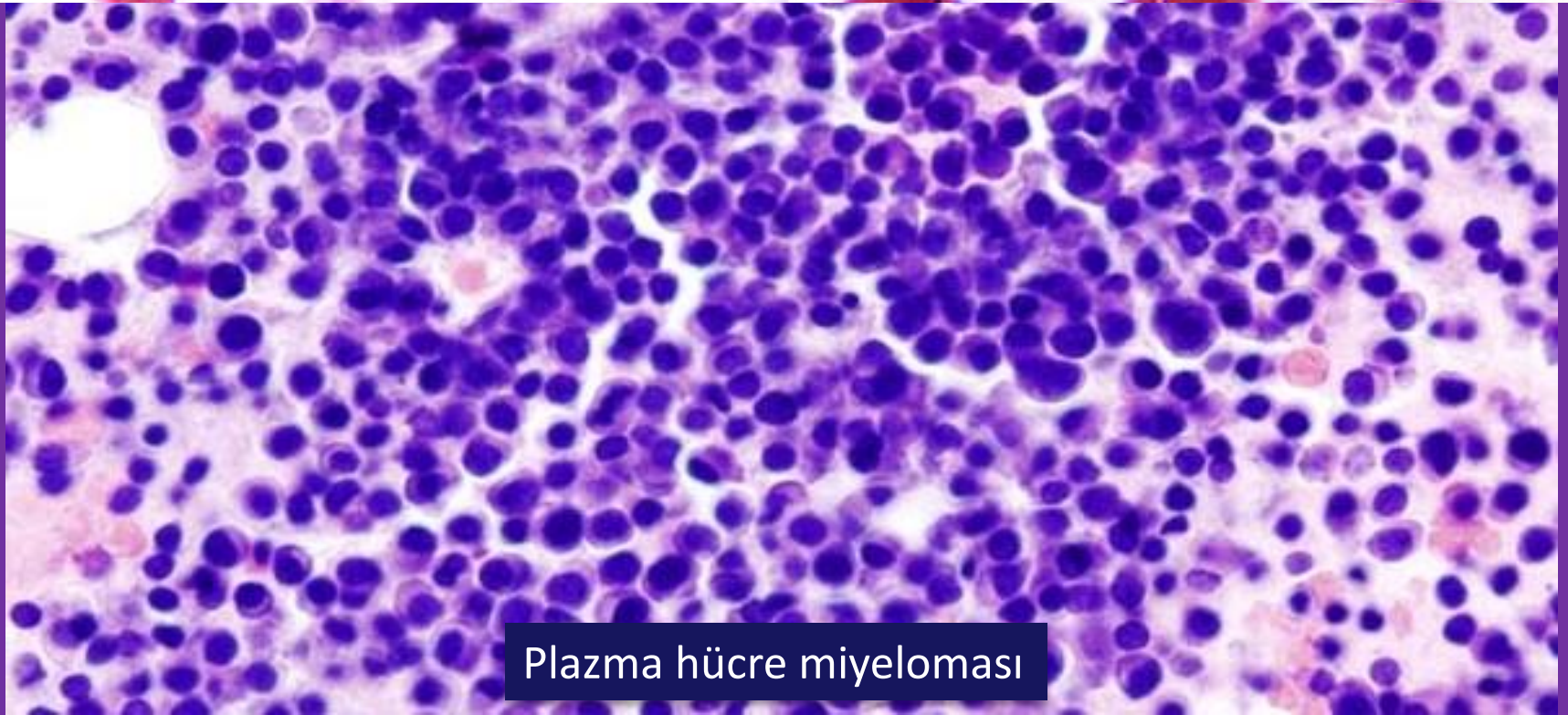
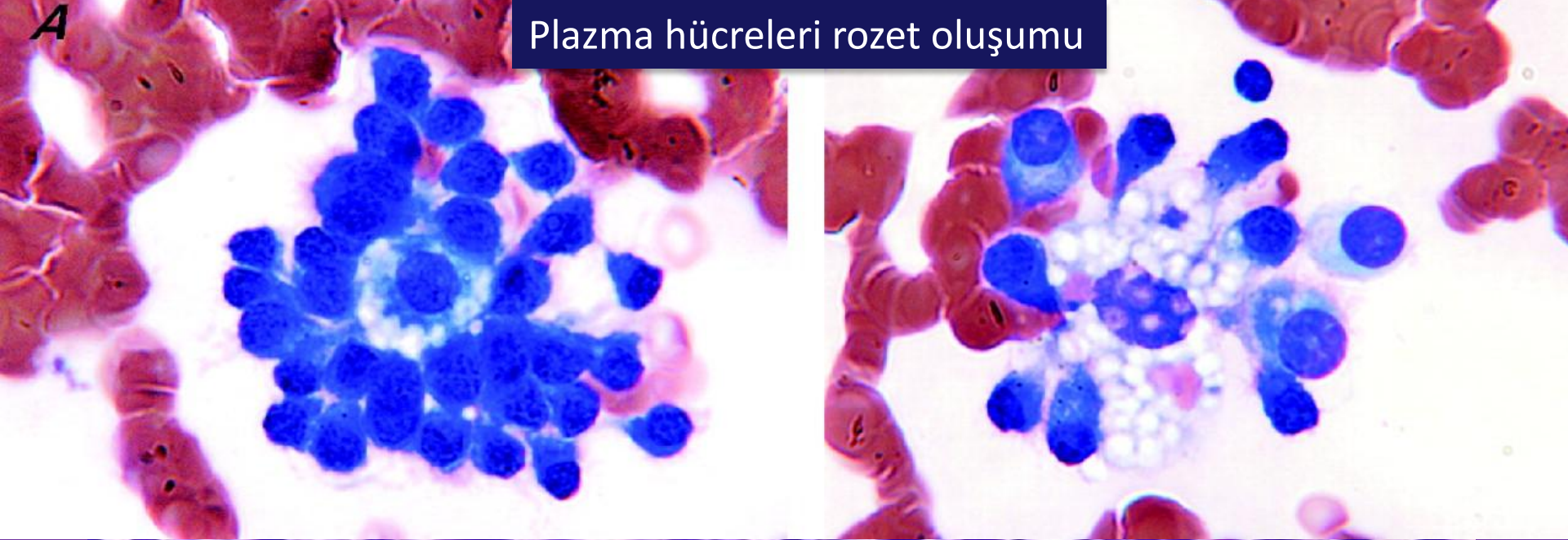
Plazma hücresi



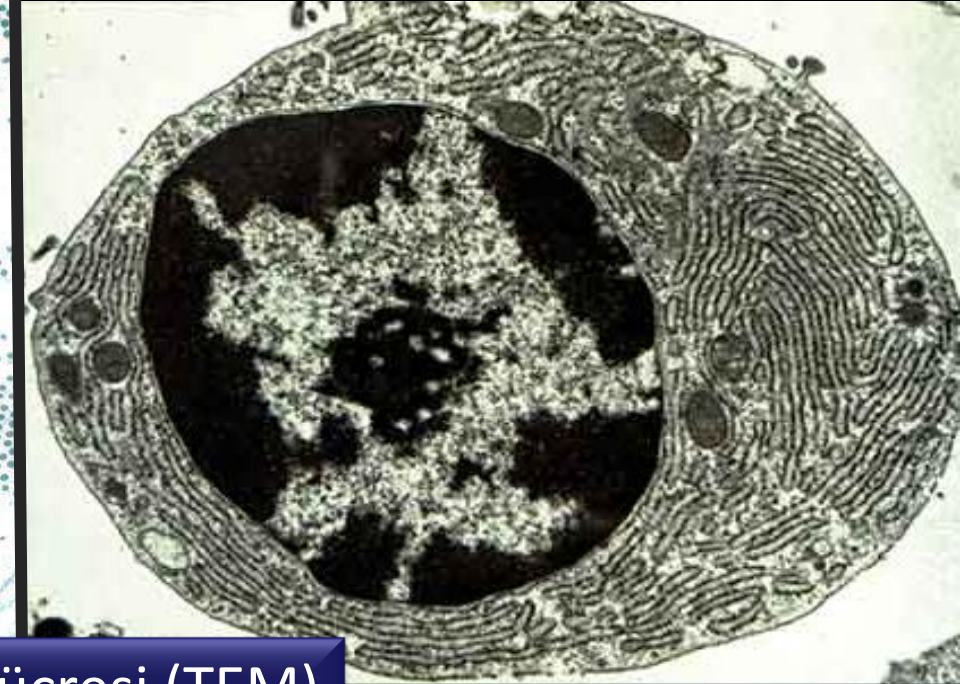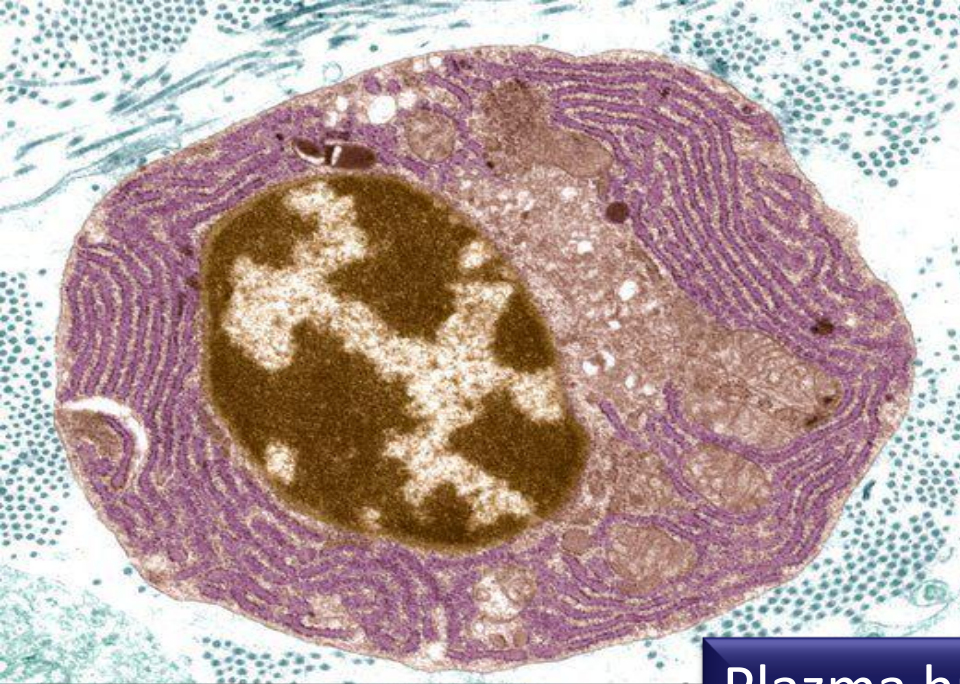
A

Plazma hücreleri rozet oluşumu

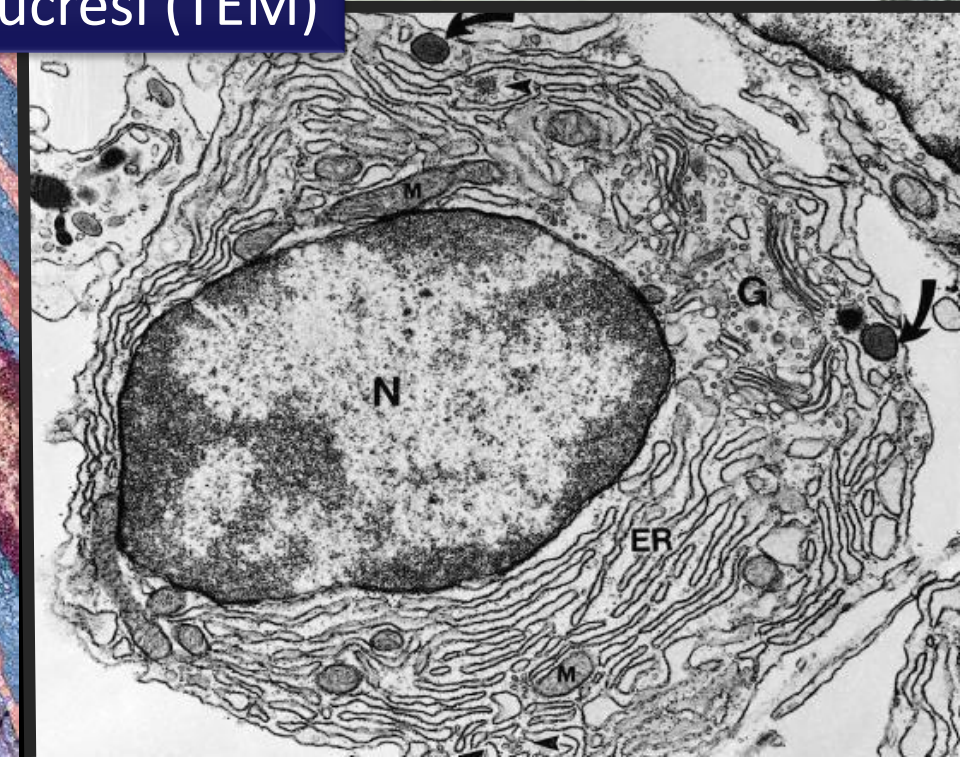
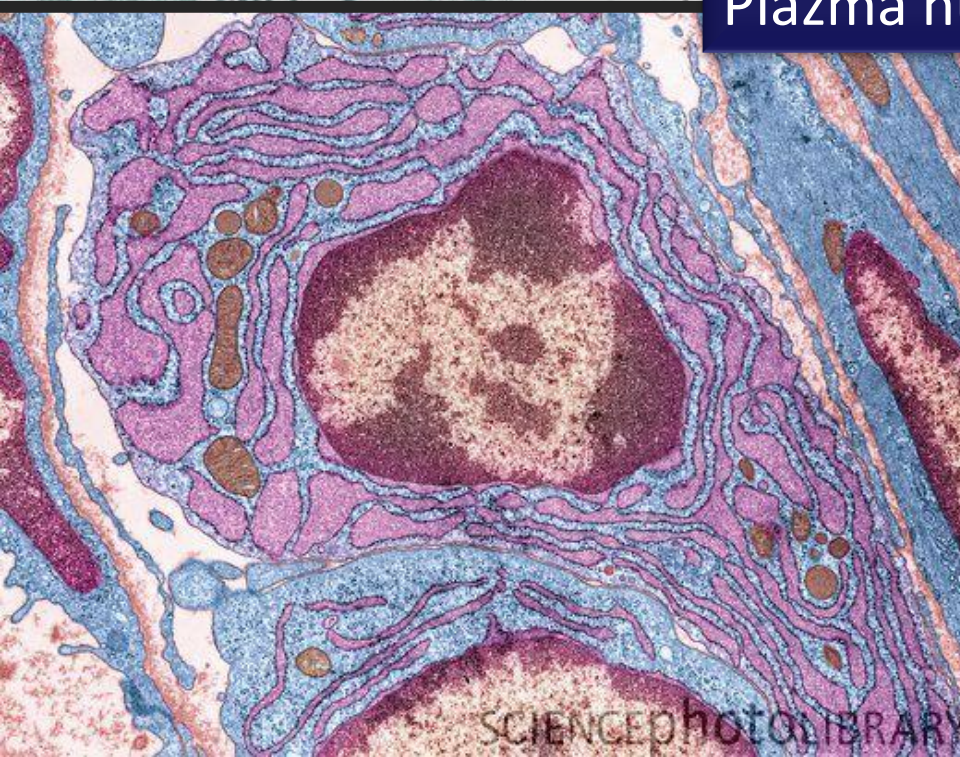

Plazma hücre miyeloması






Plazma hücresi (TEM)

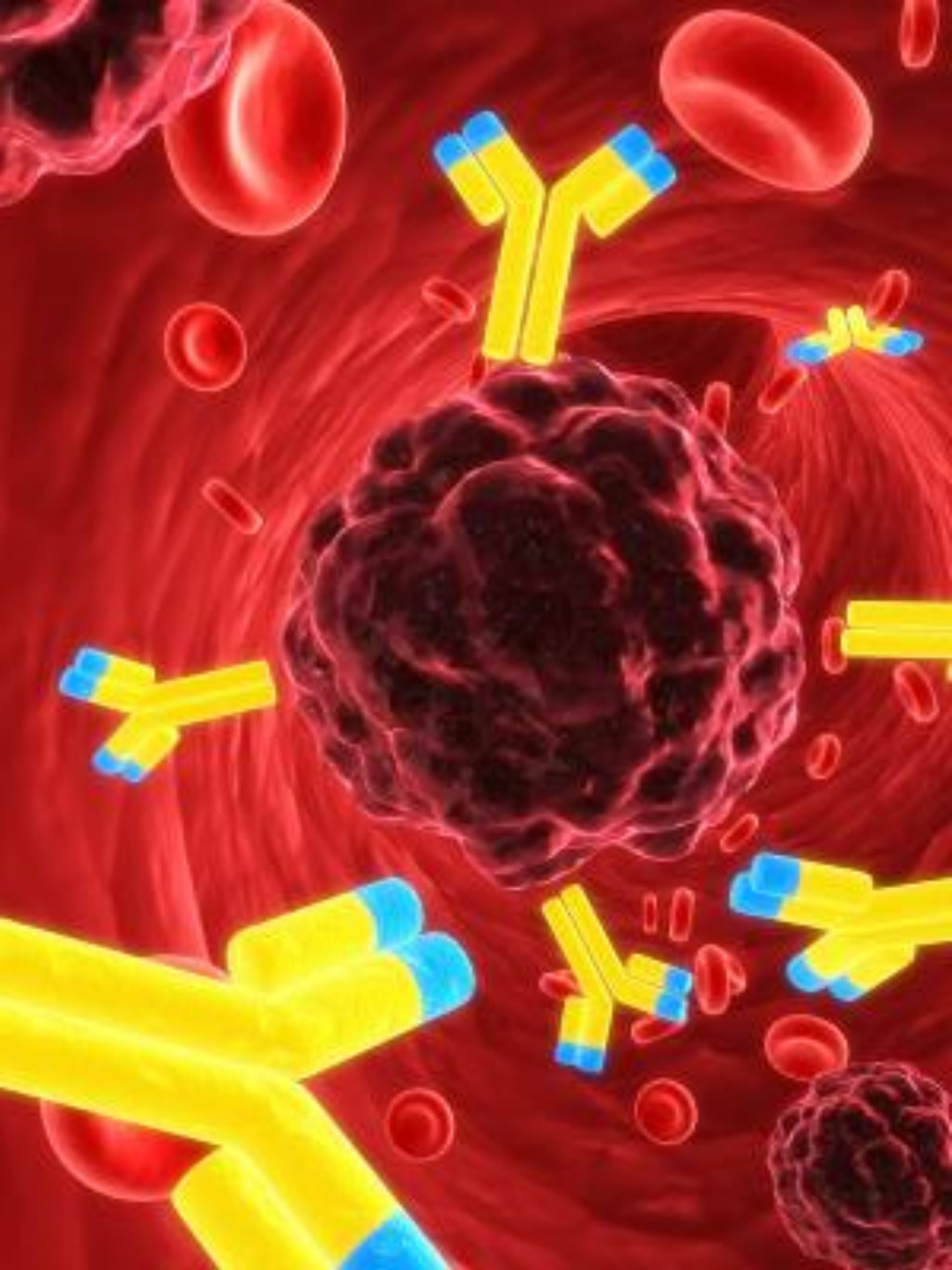


SCIENCEPHOTOLIBRARY

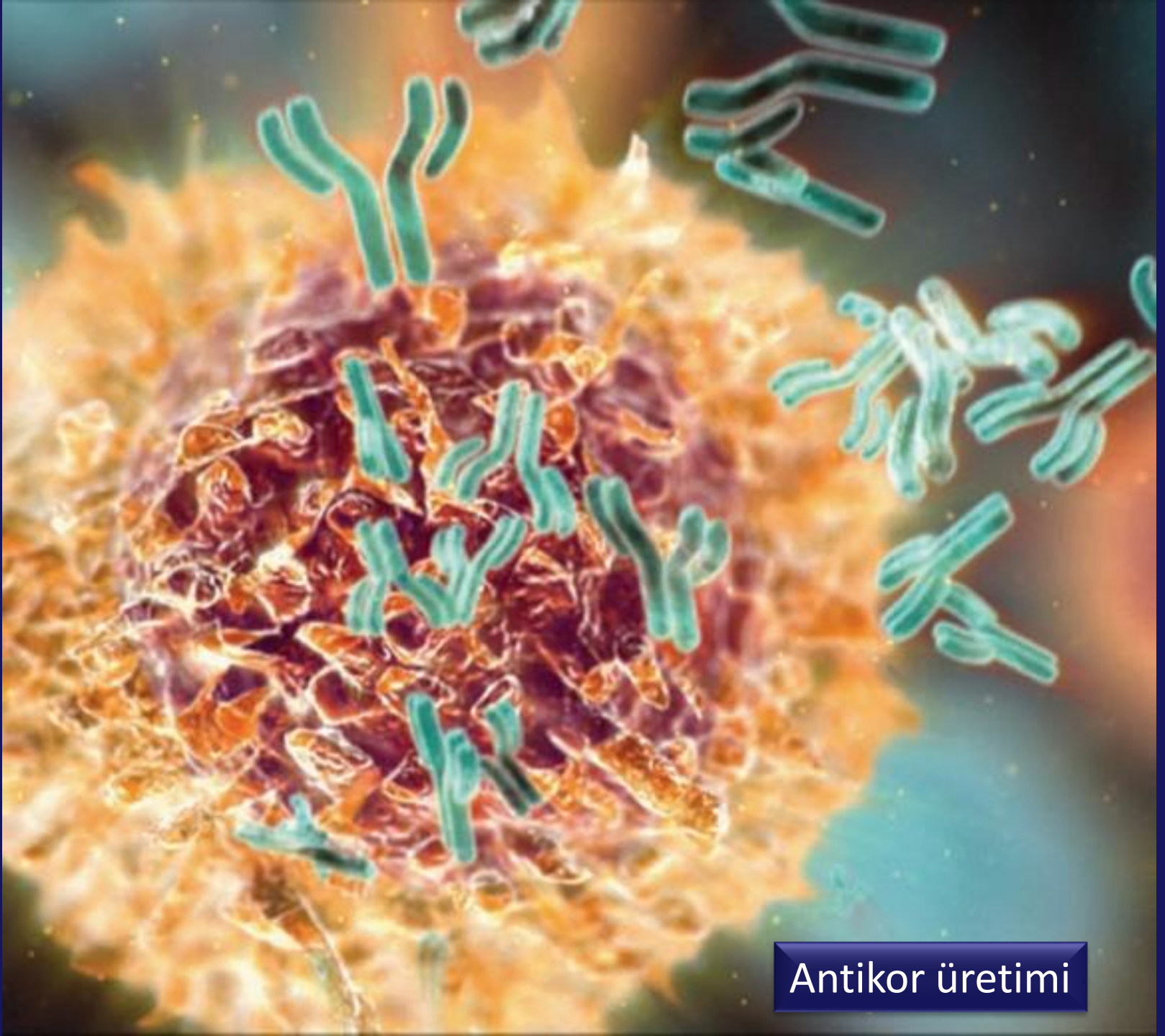




B hücresi  
Plazma hücresi  
Antikor üretimi

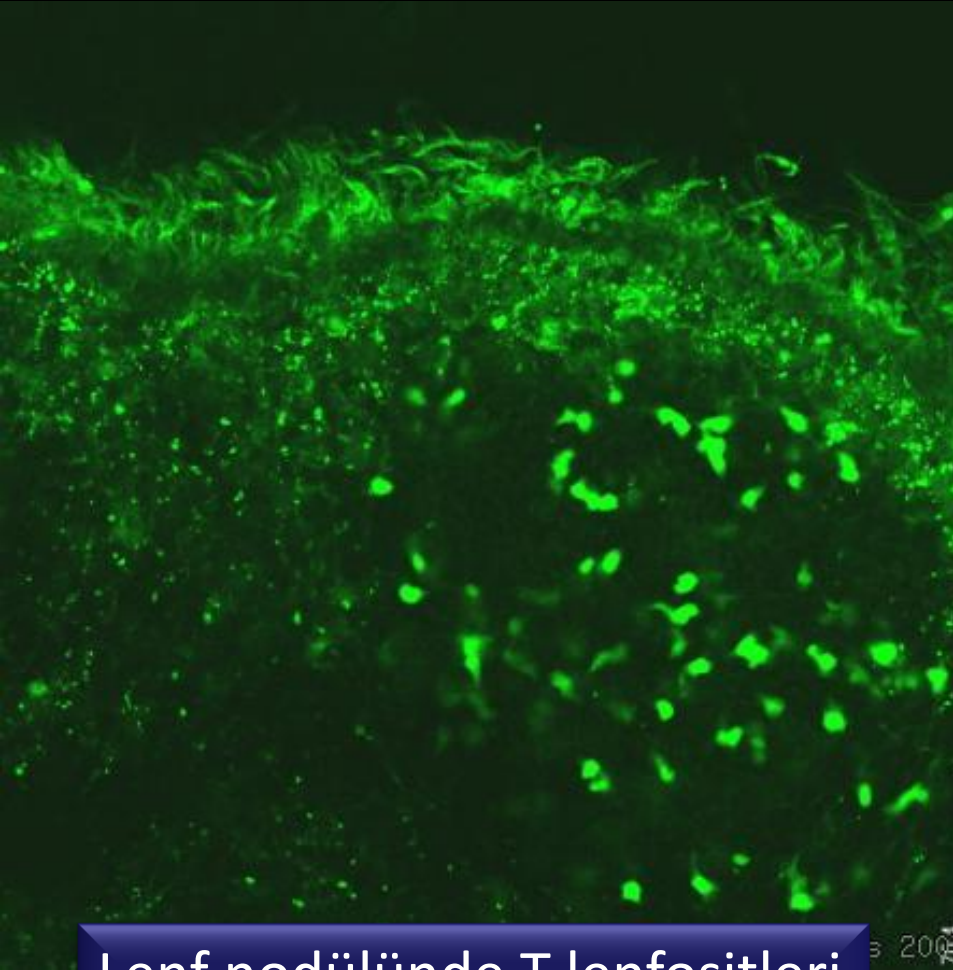




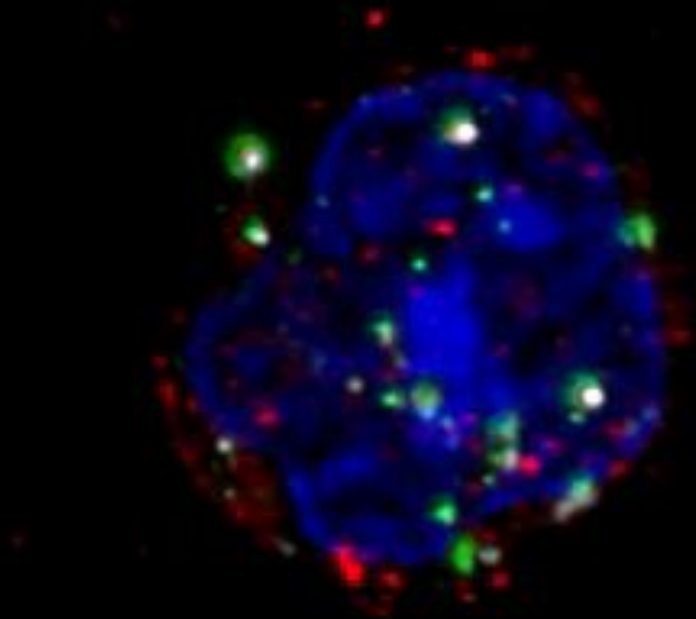


Antikor üretimi



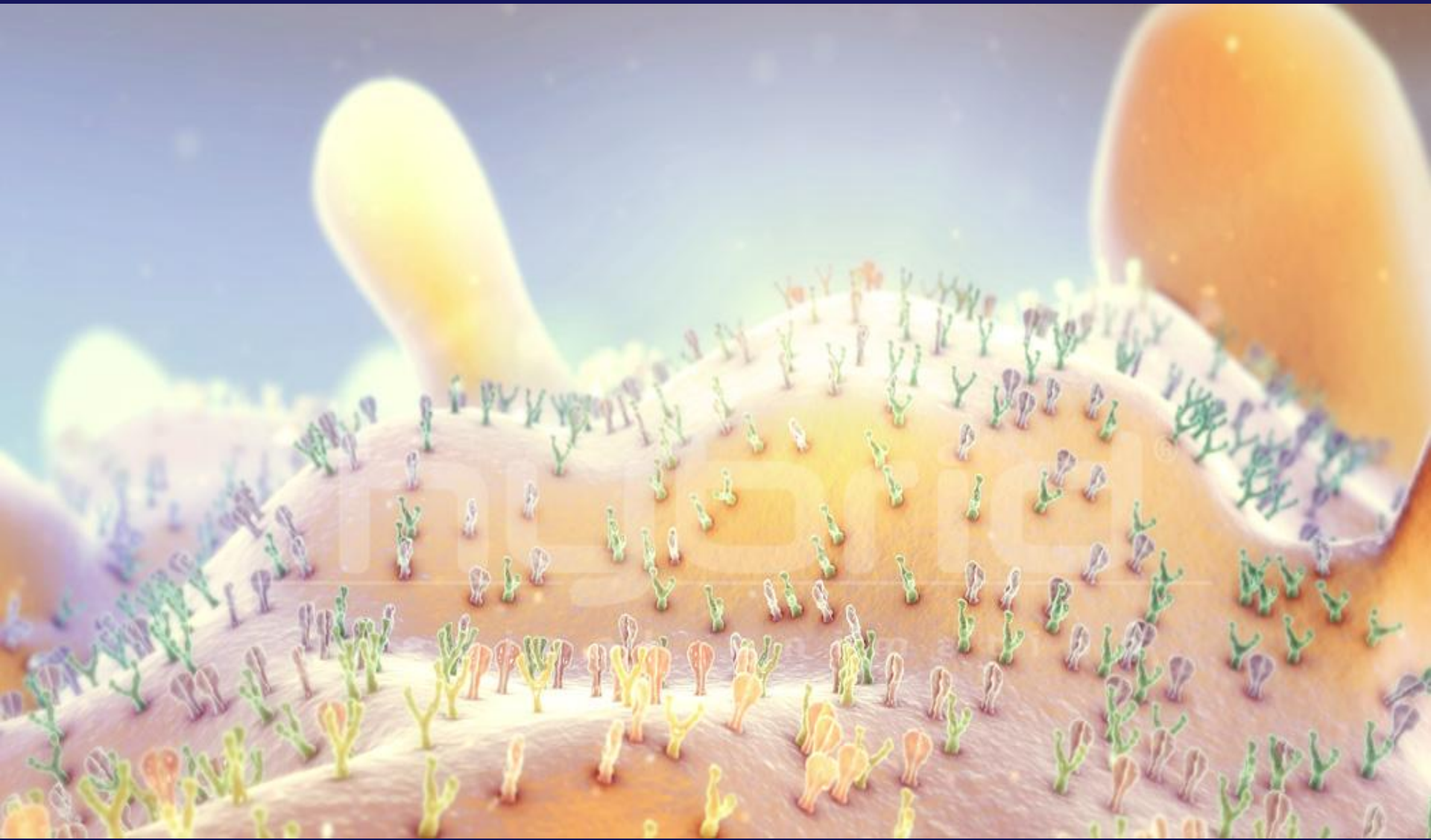


Lenf nodülünde T lenfositleri



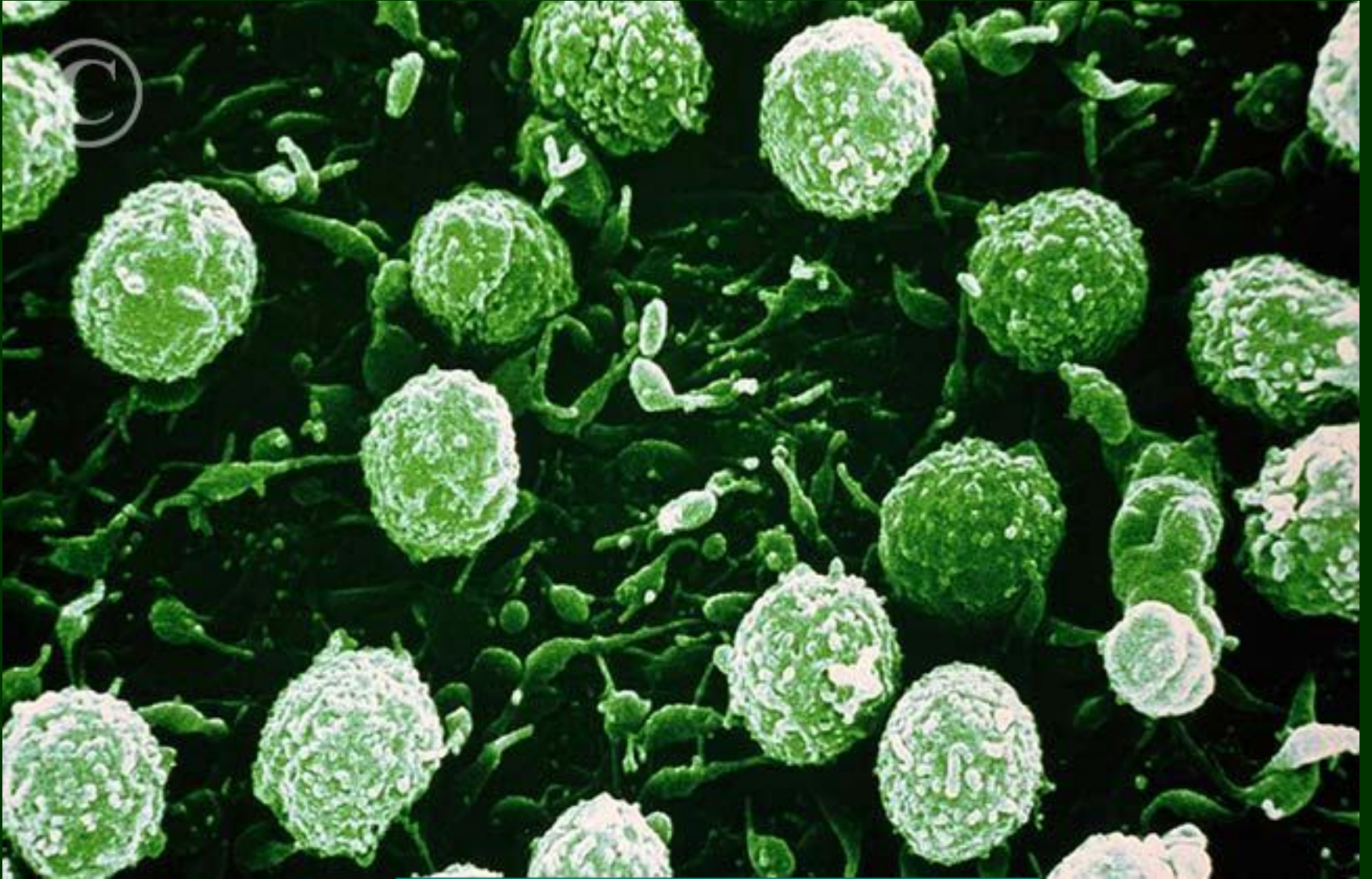
T lenfosit yüzey molekülleri





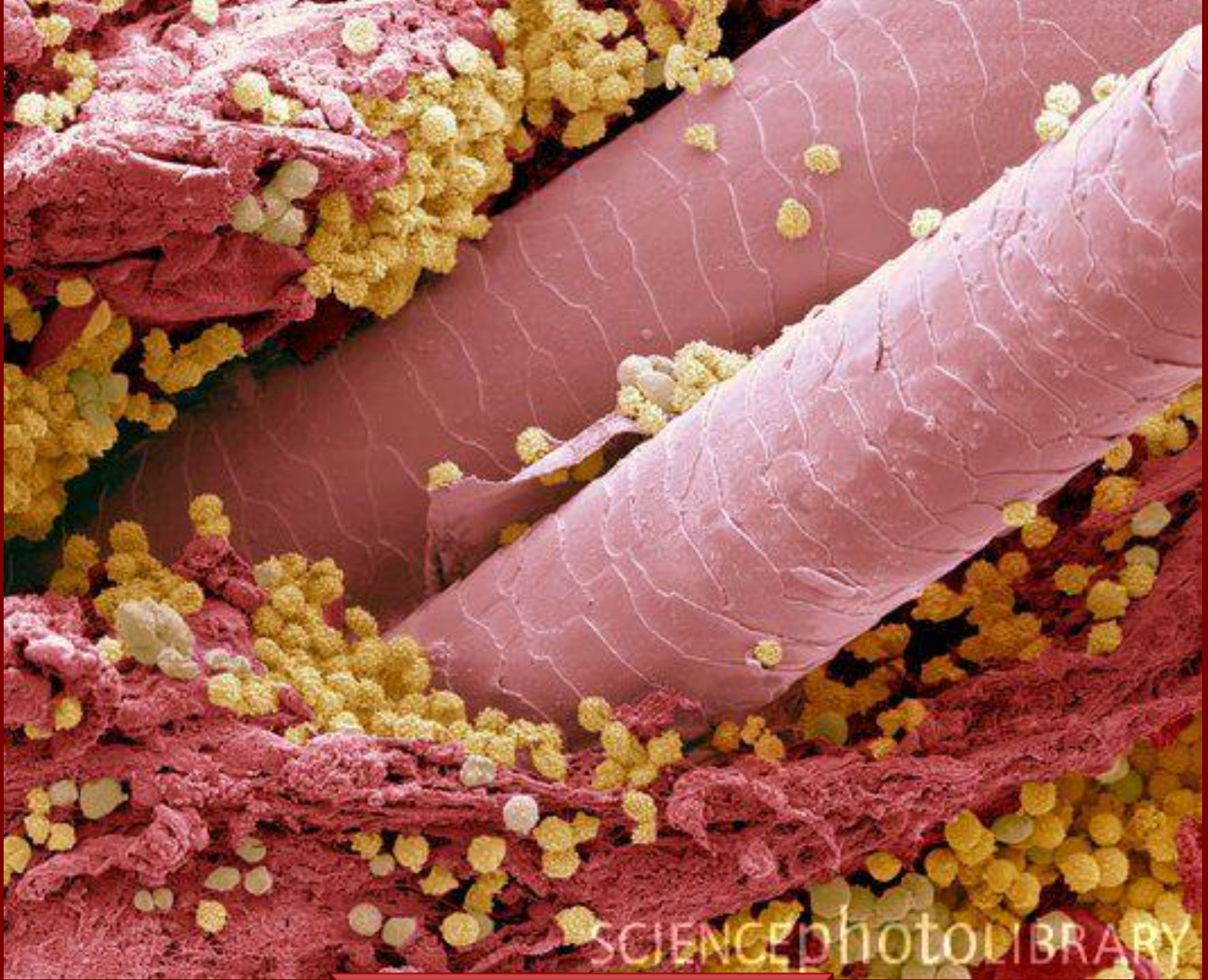
T lenfosit yüzey molekülleri





Endotel üzerinde T lenfositleri

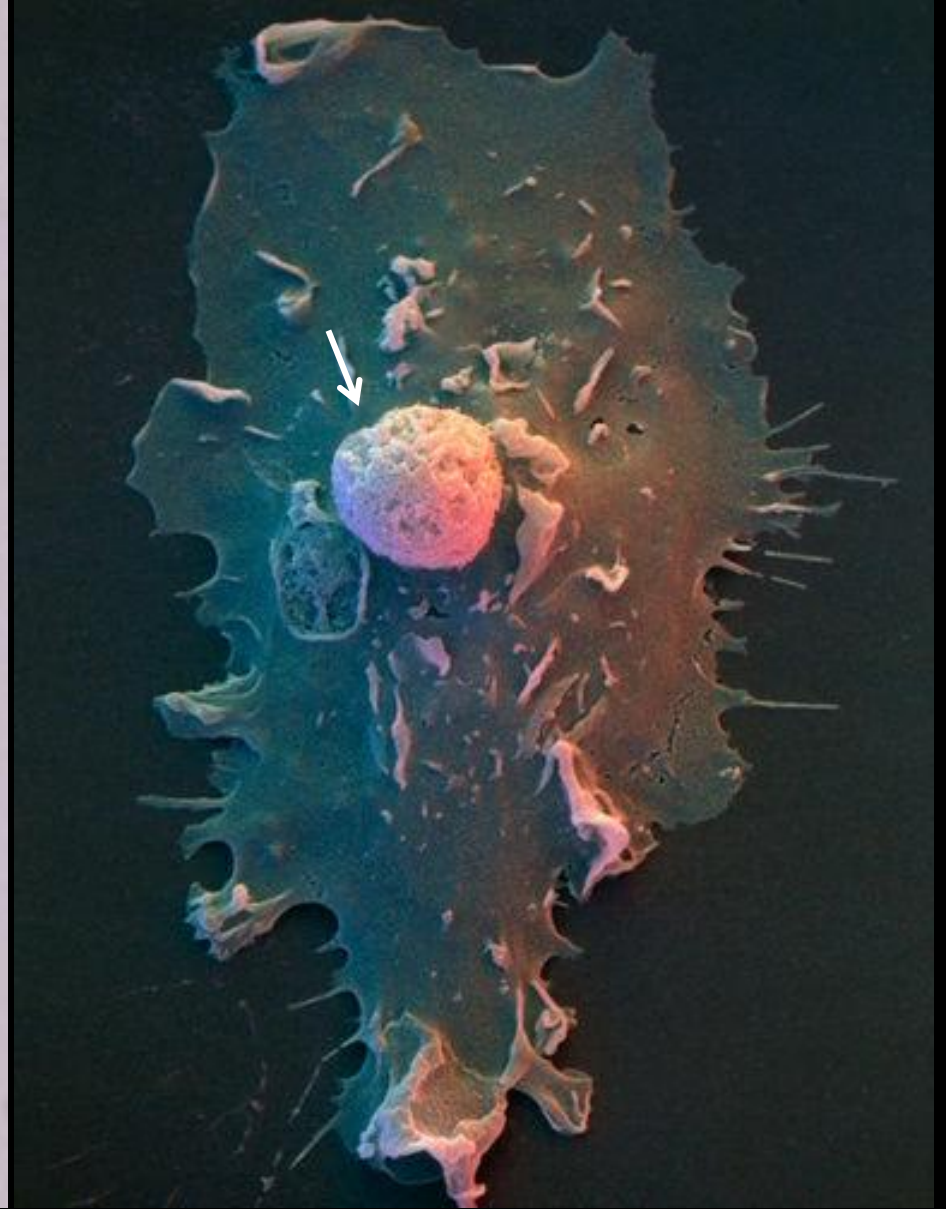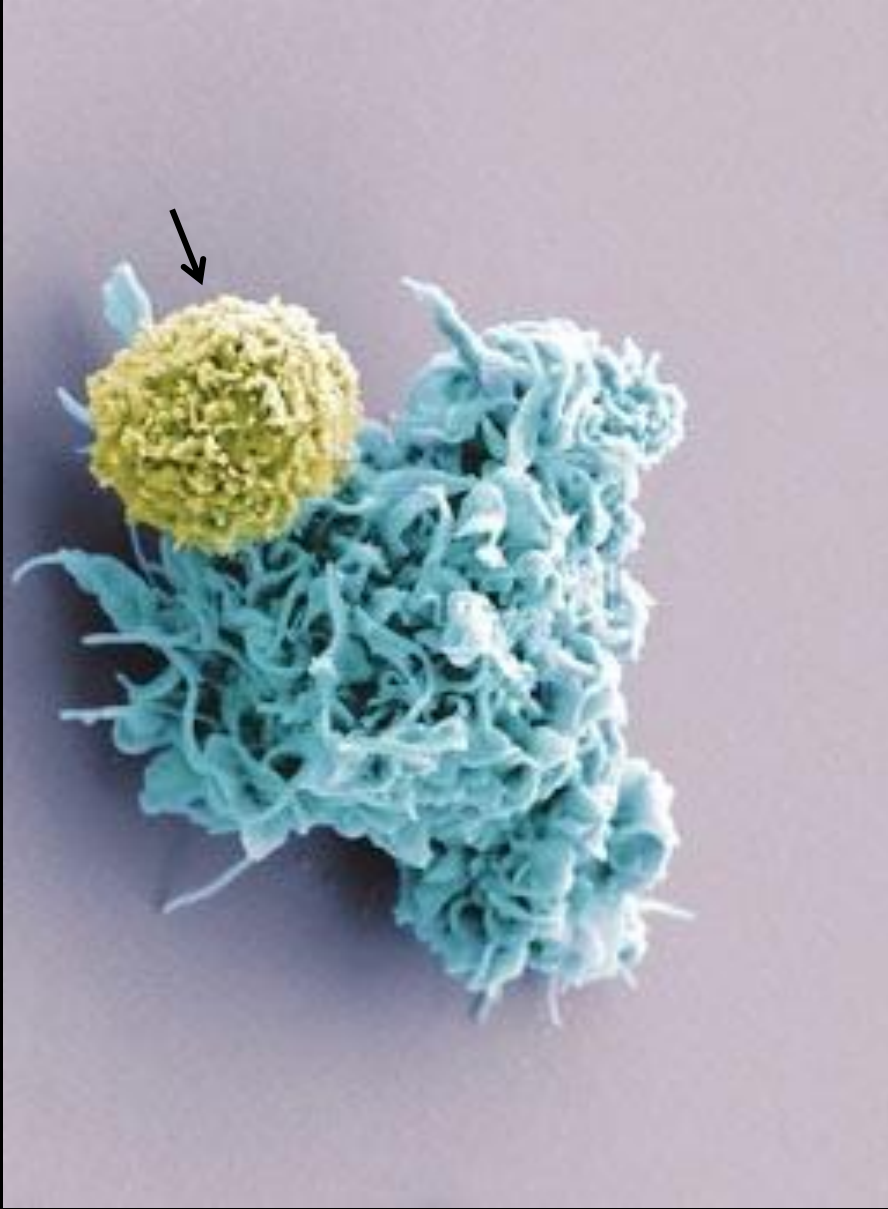




SCIENCEPHOTOLIBRARY

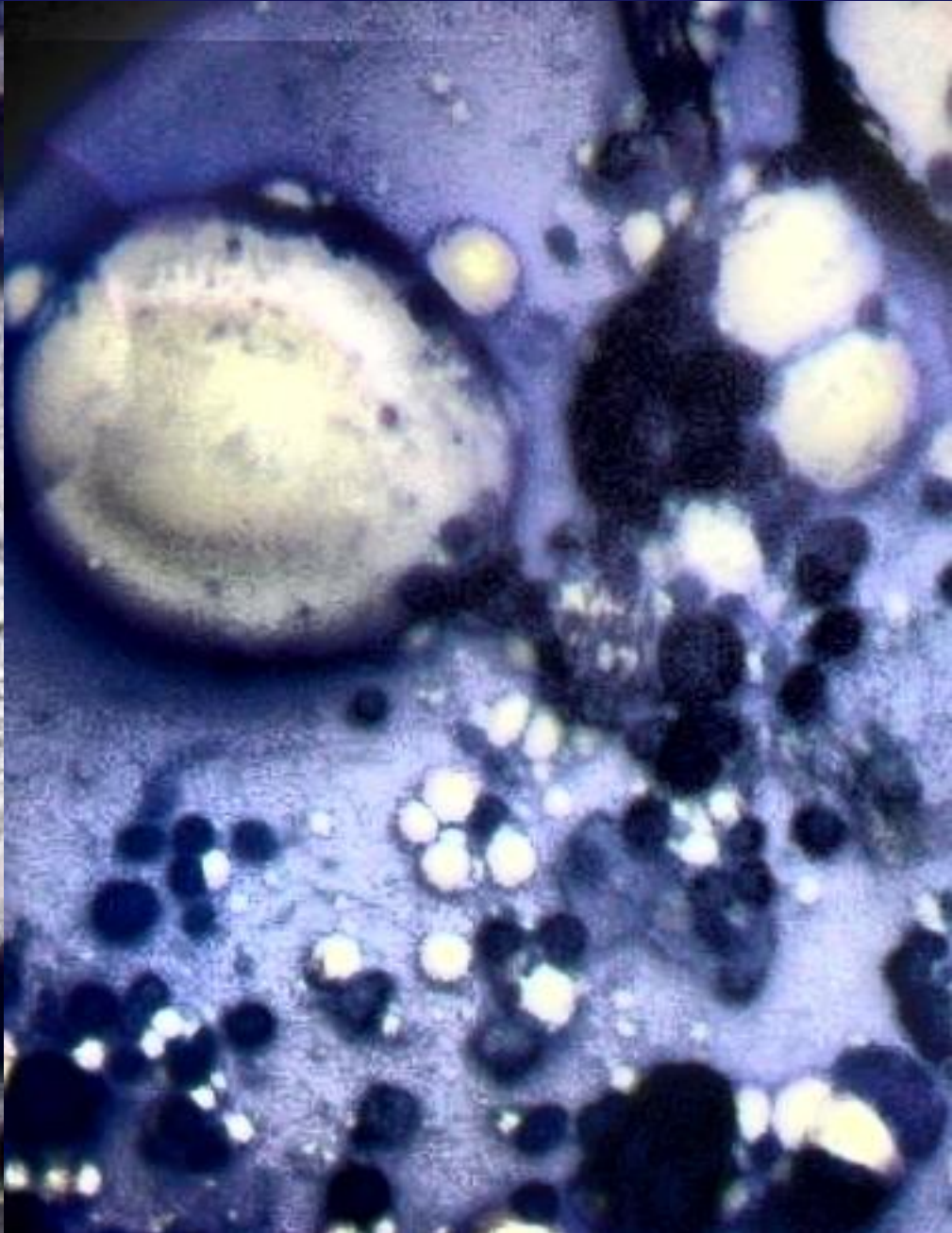
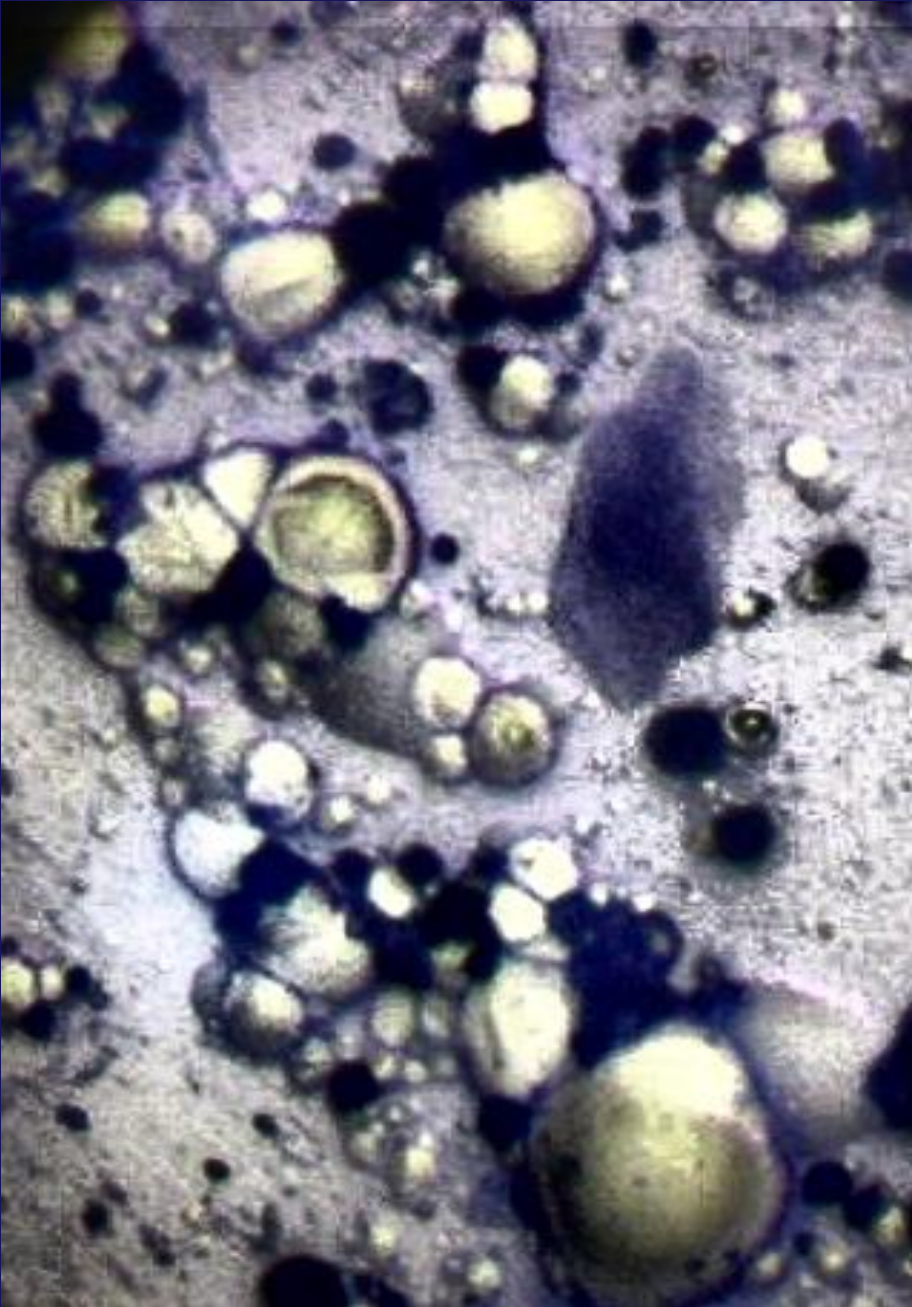
kıl kökünde T lenfositleri





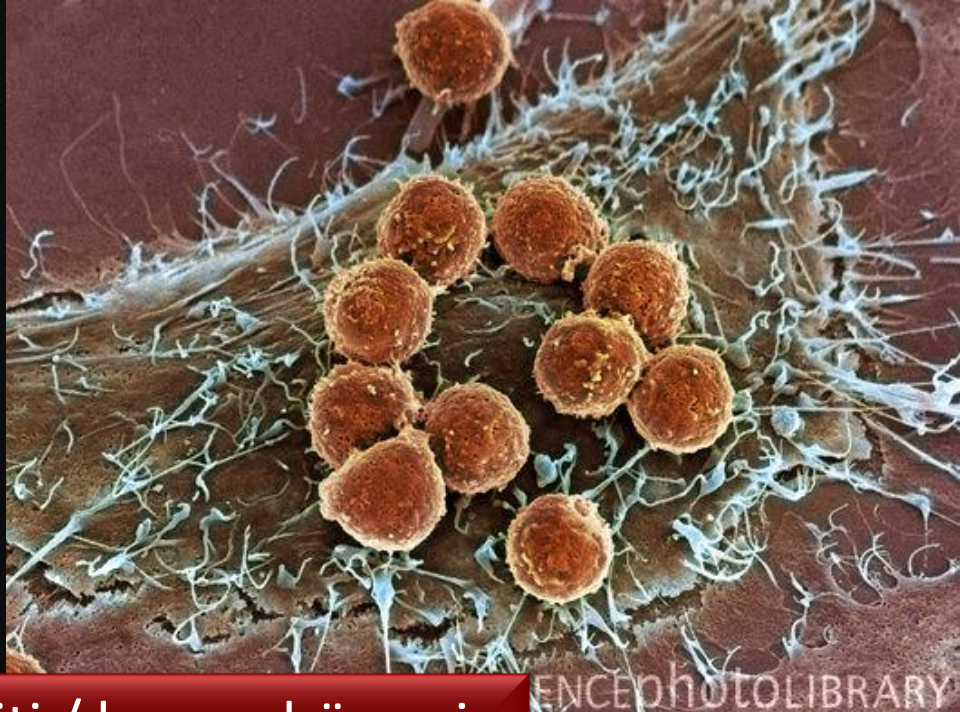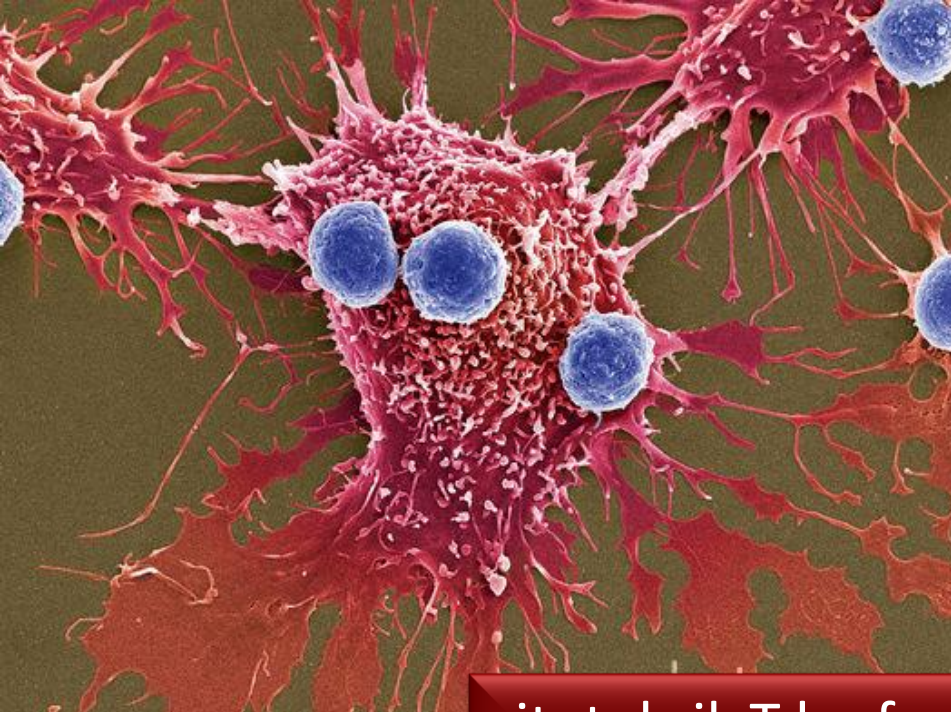
yardımcı T lenfositleri / dendritik hücre : antijen sunma



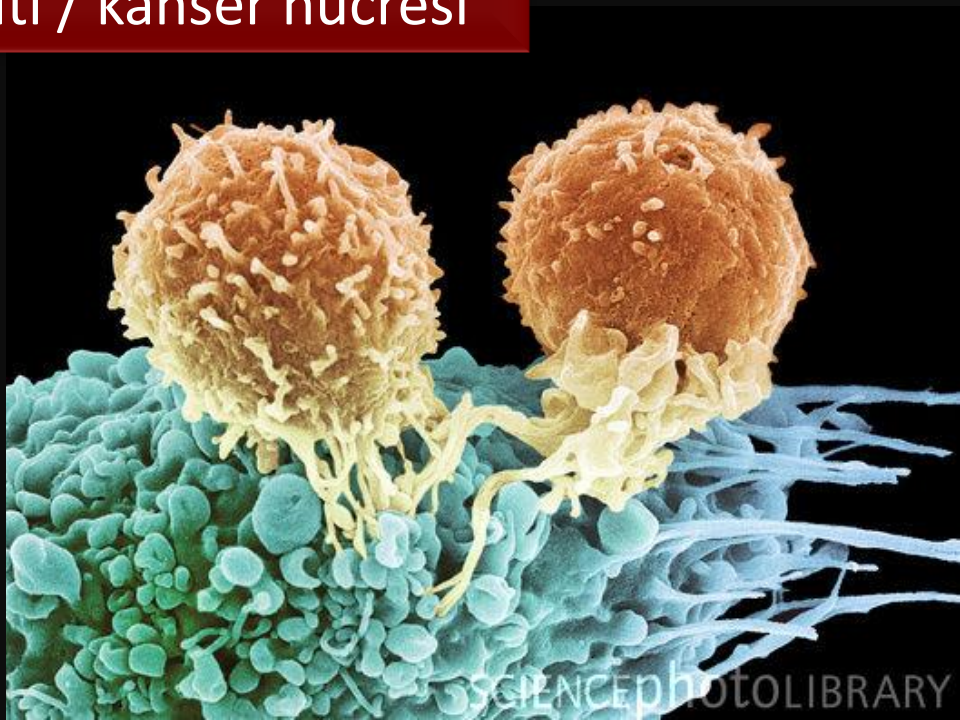
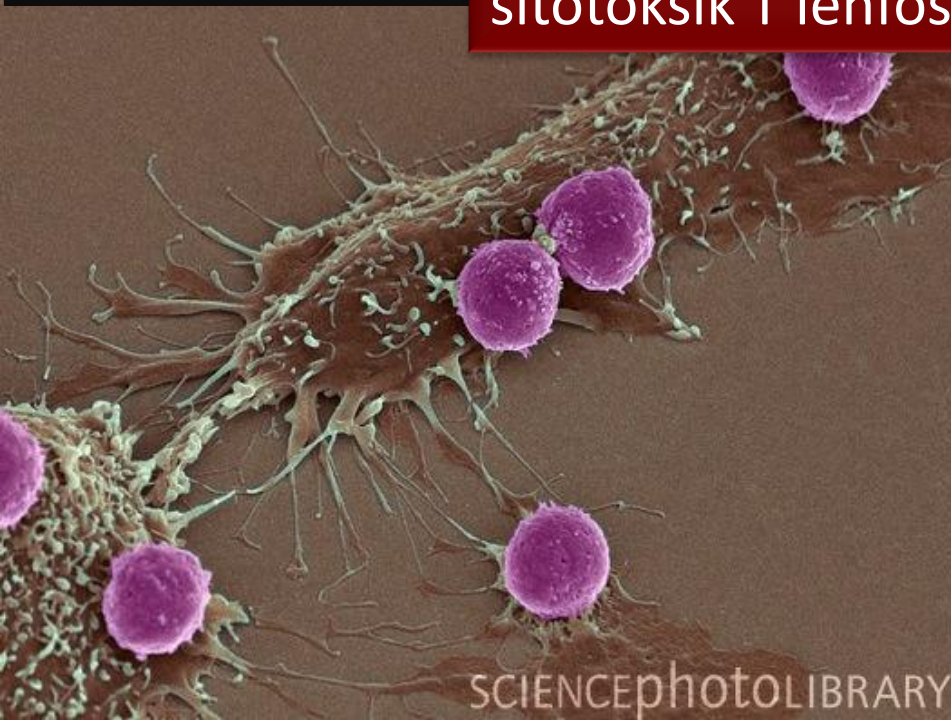
sitotoksik T lenfosit / patojenik mantar

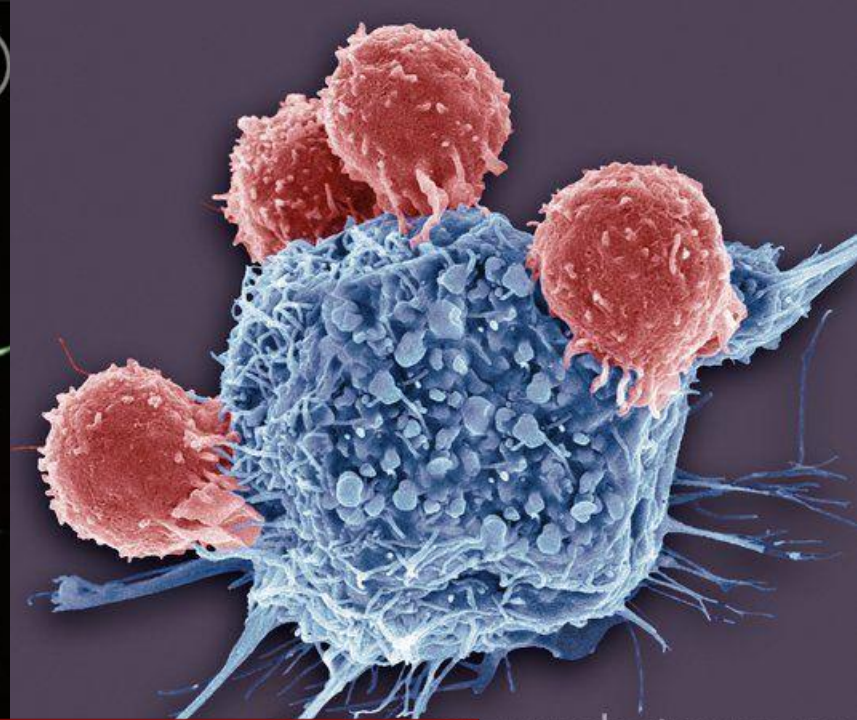
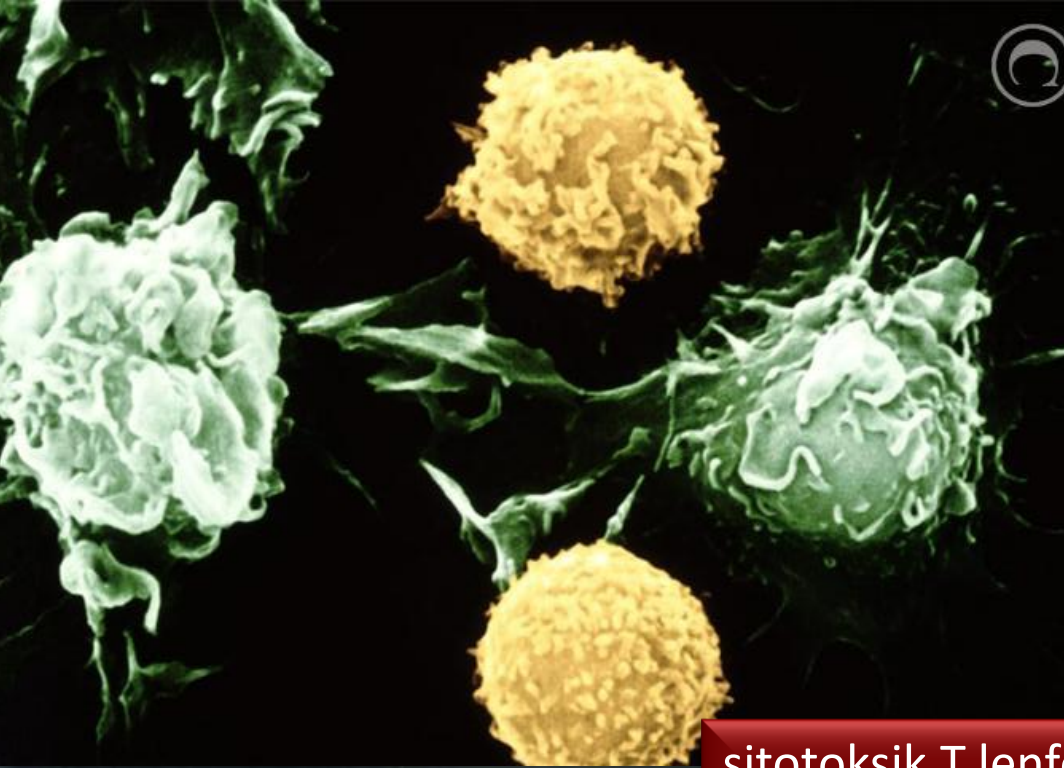




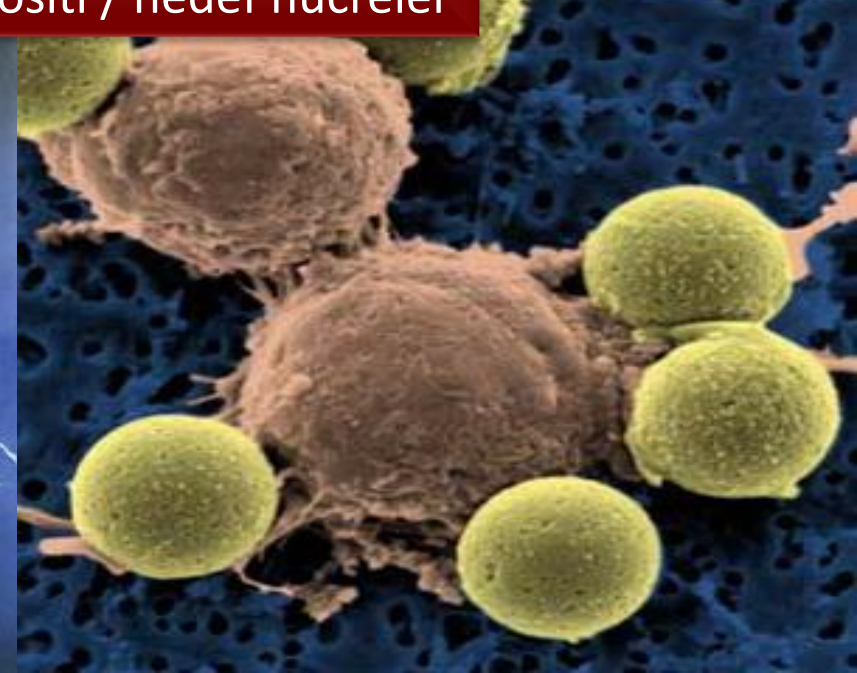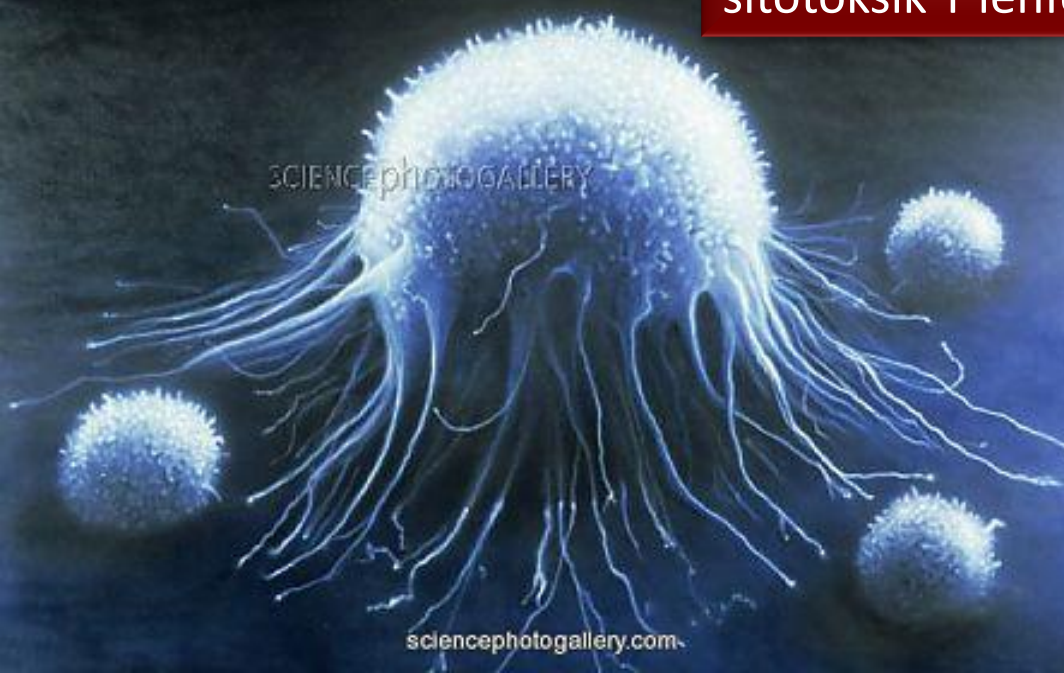sitotoksik T lenfosit / kanser hücresi



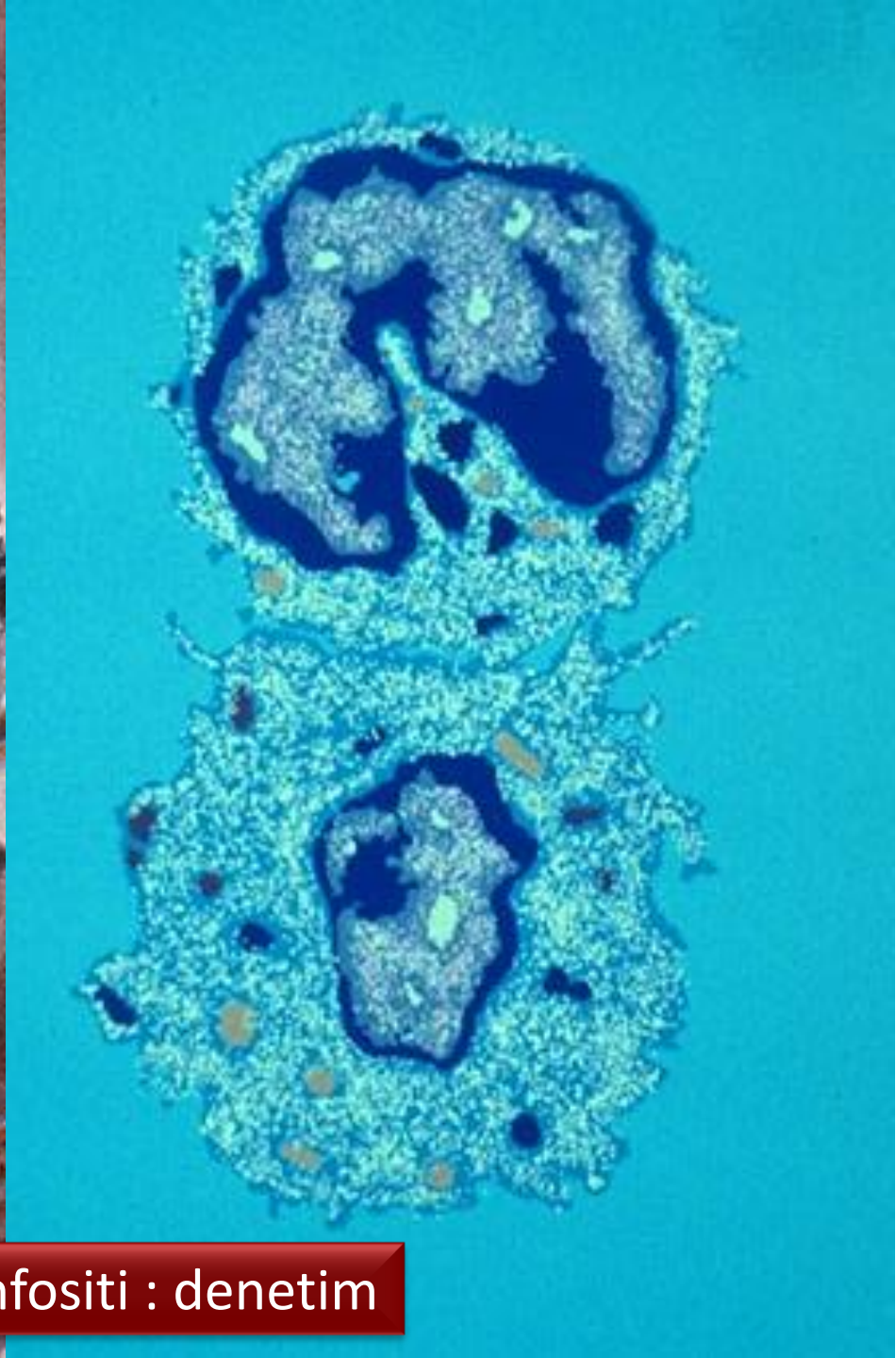
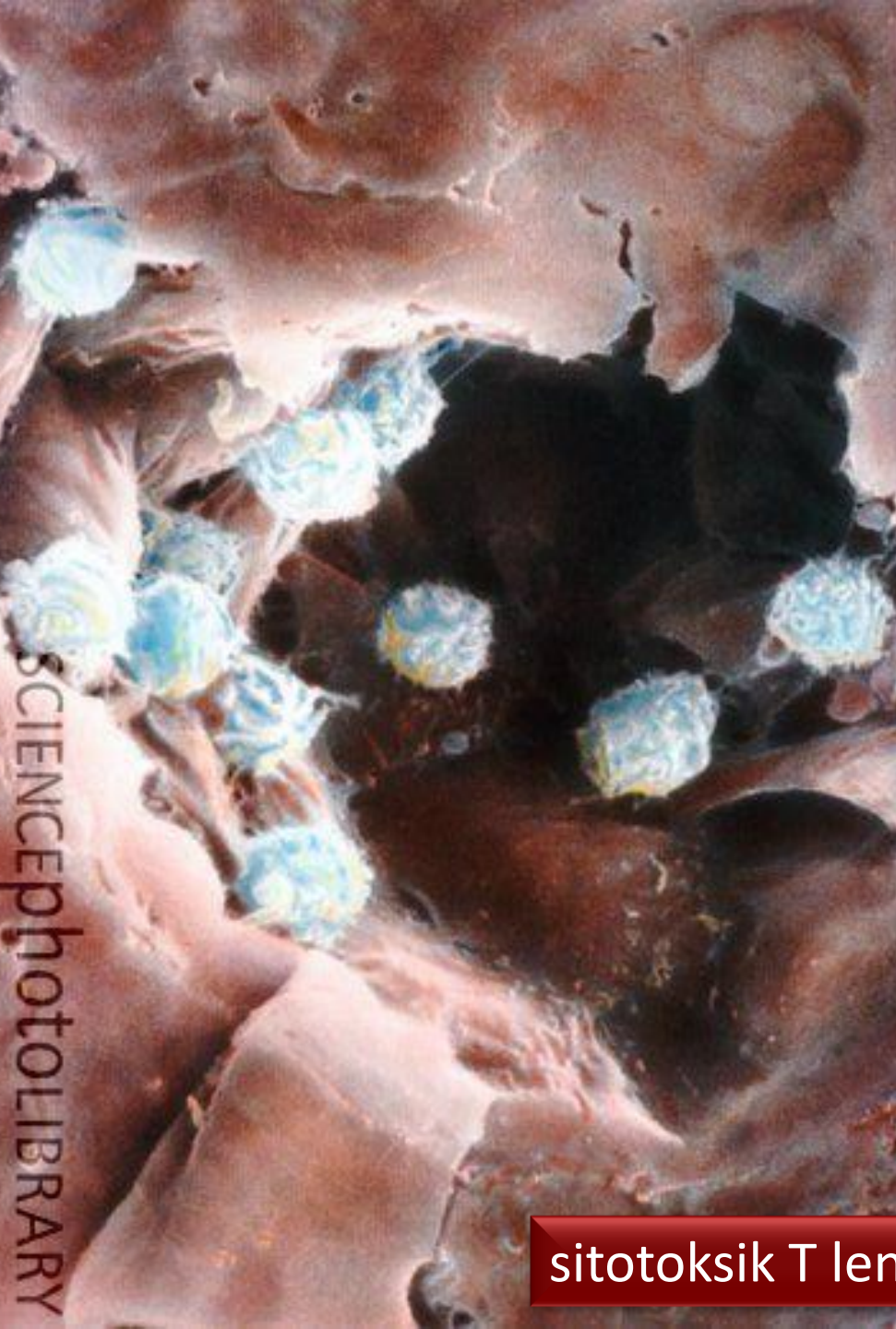



sitotoksik T lenfositleri / hedef hücreler

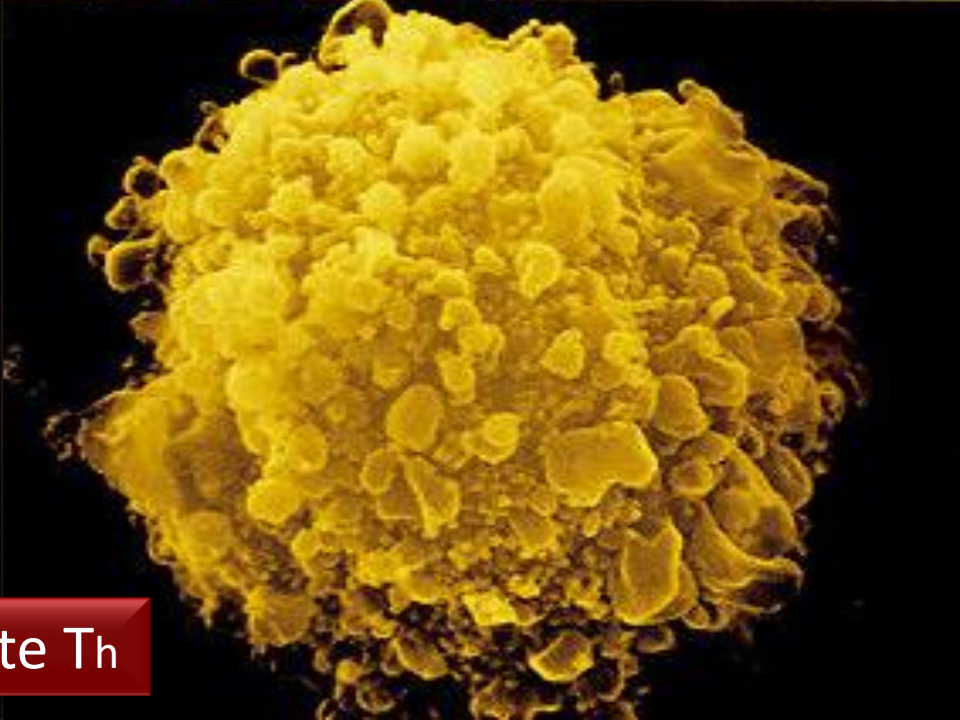
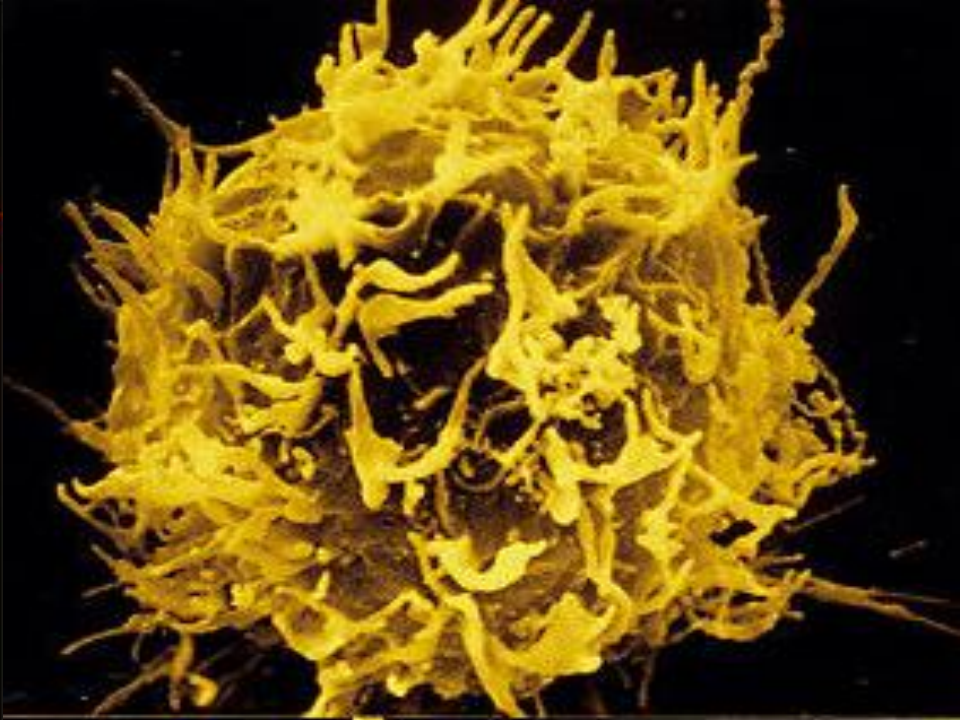
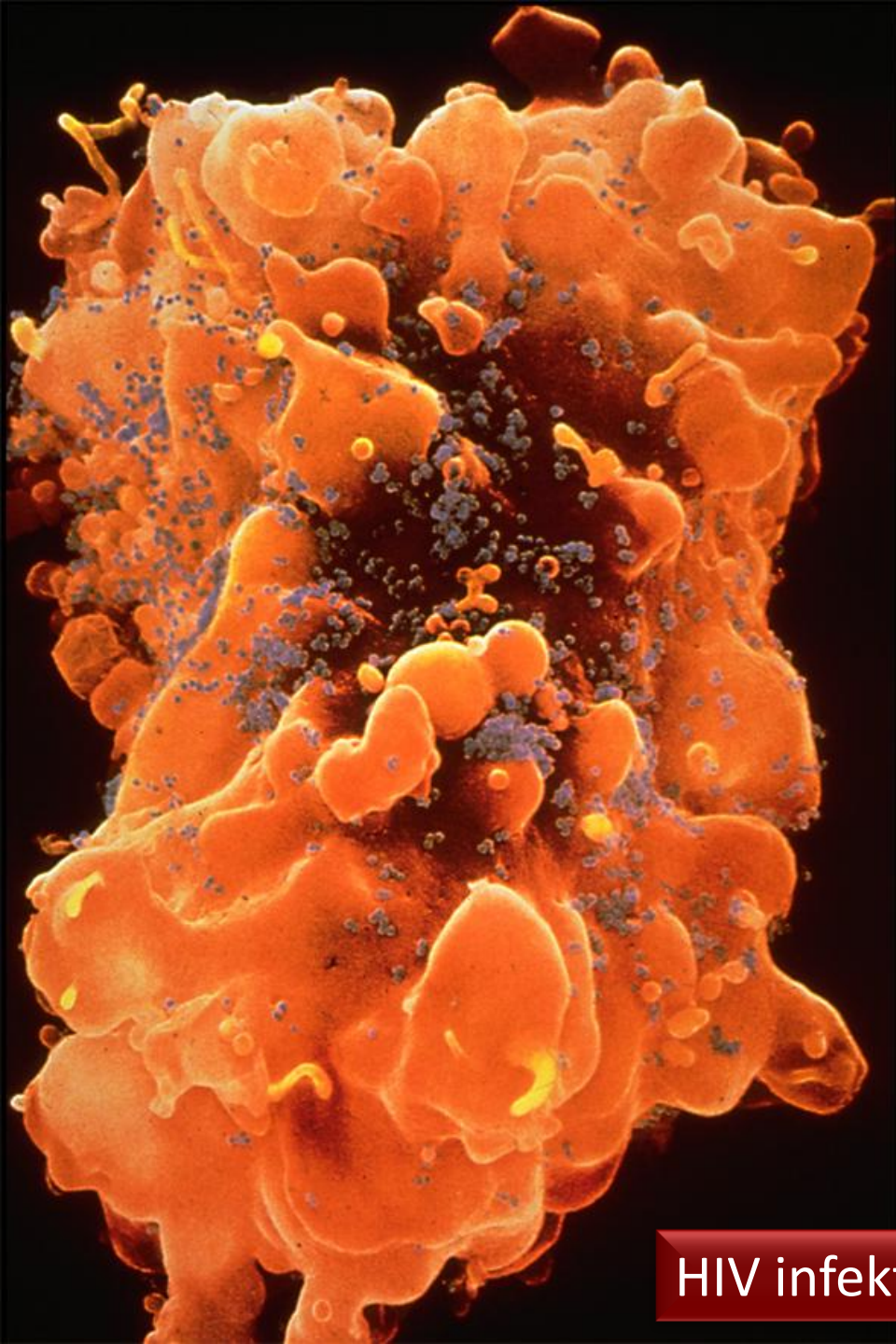





sitotoksik T lenfosit : denetim

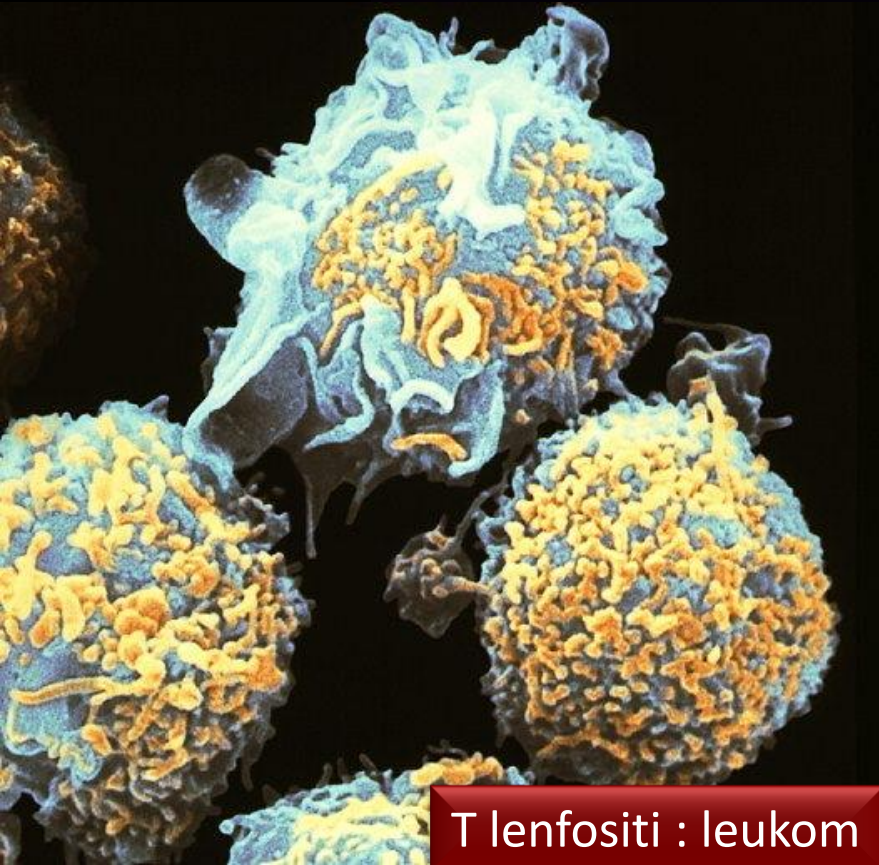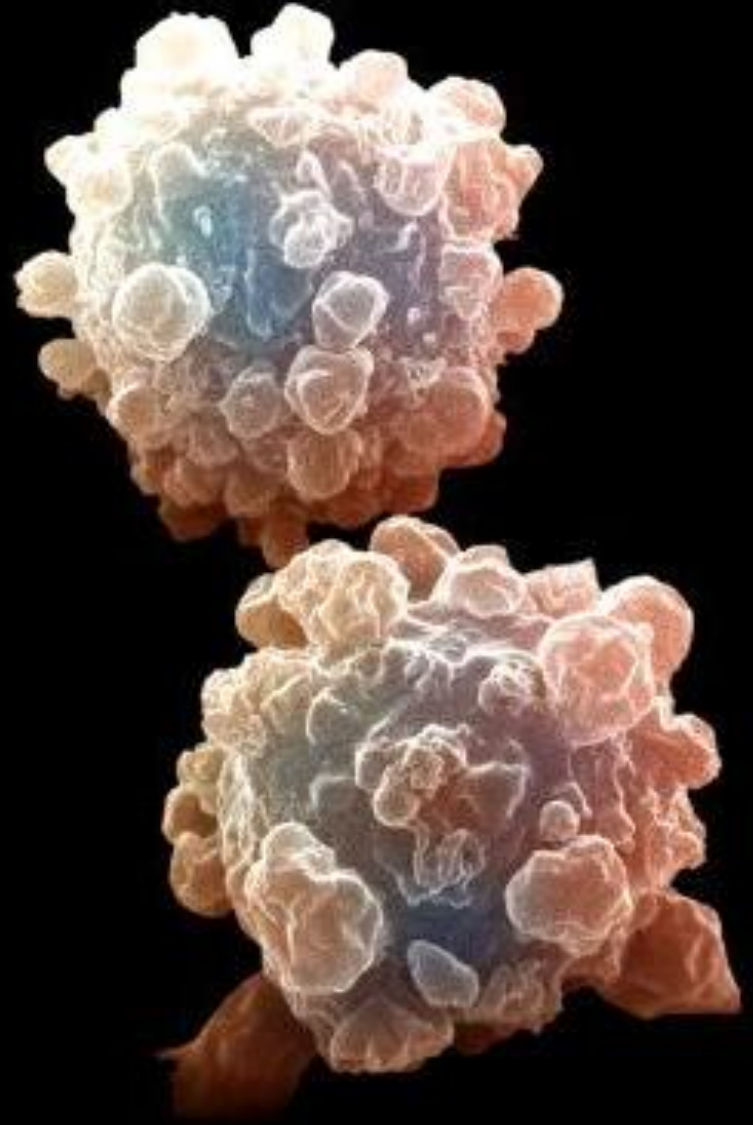
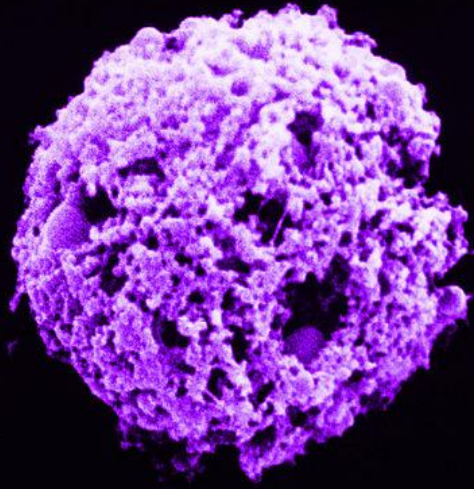




HIV infekte Th

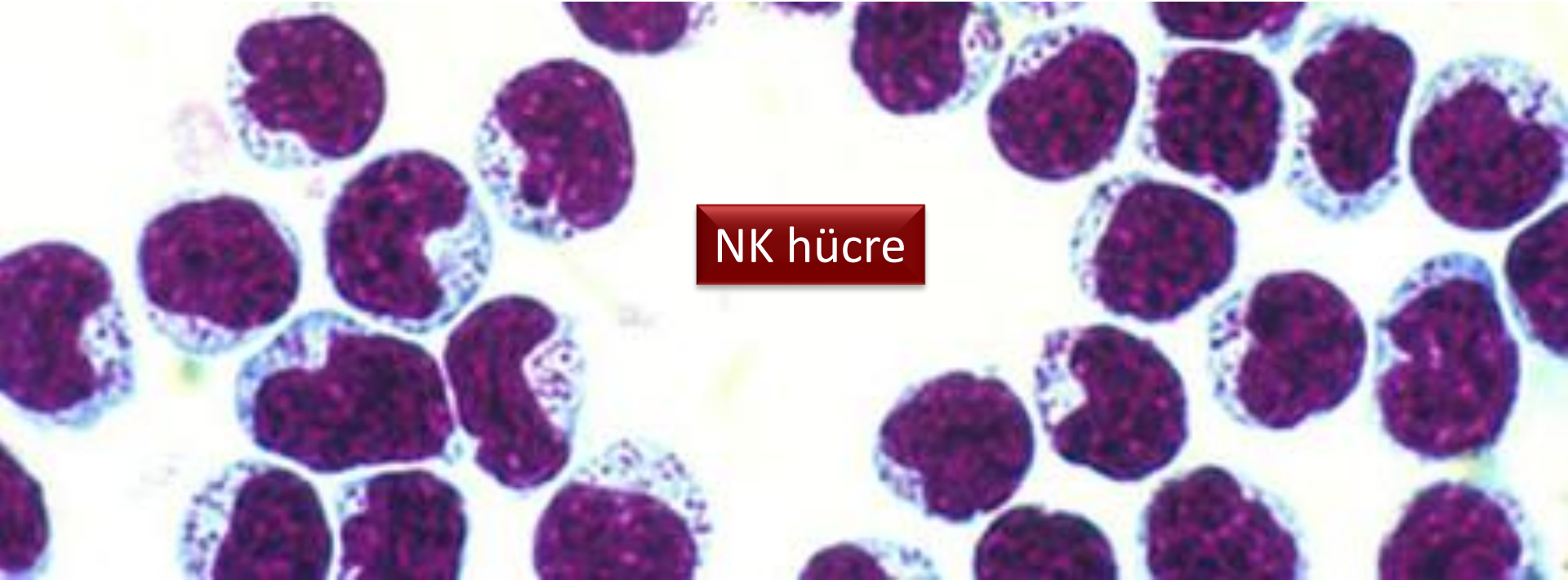


T lenfosi : apoptozis

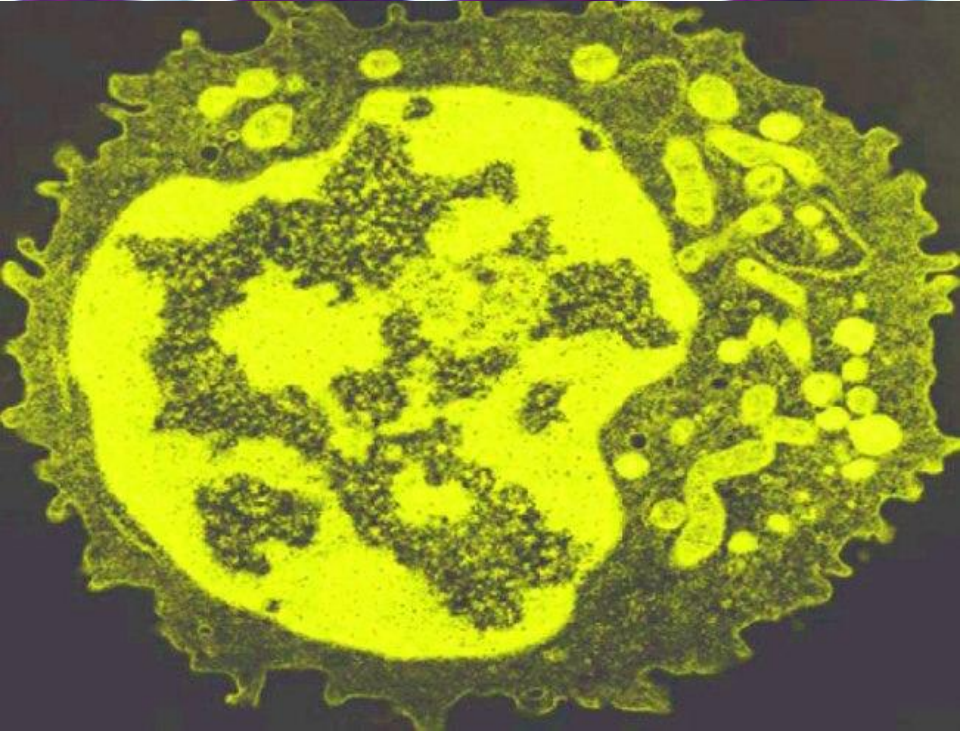
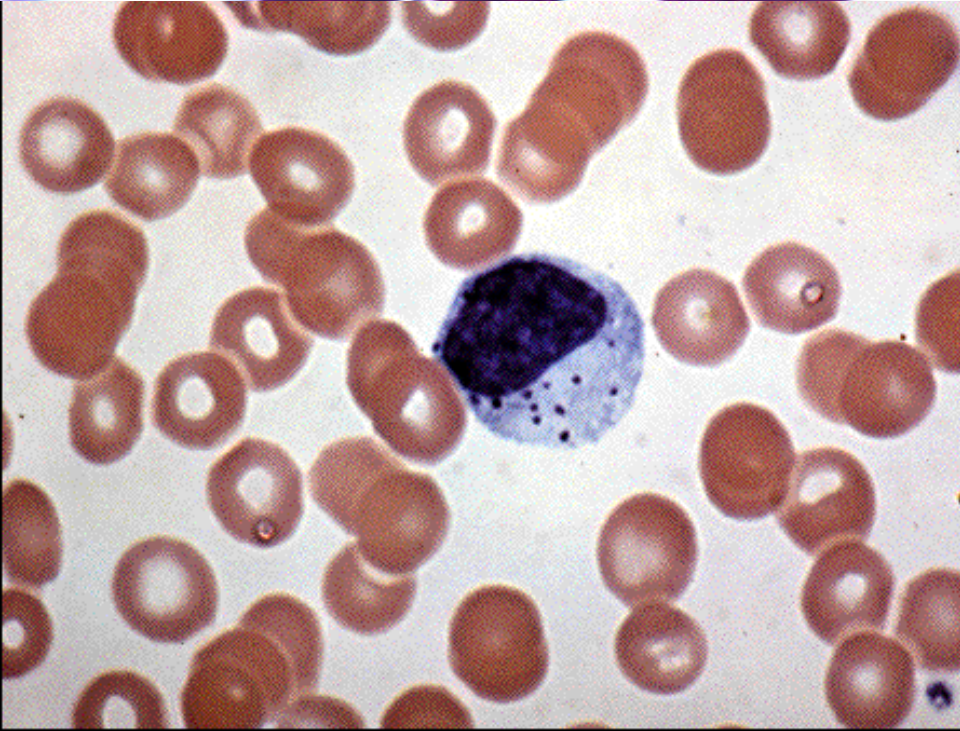


T lenfosi : leukom

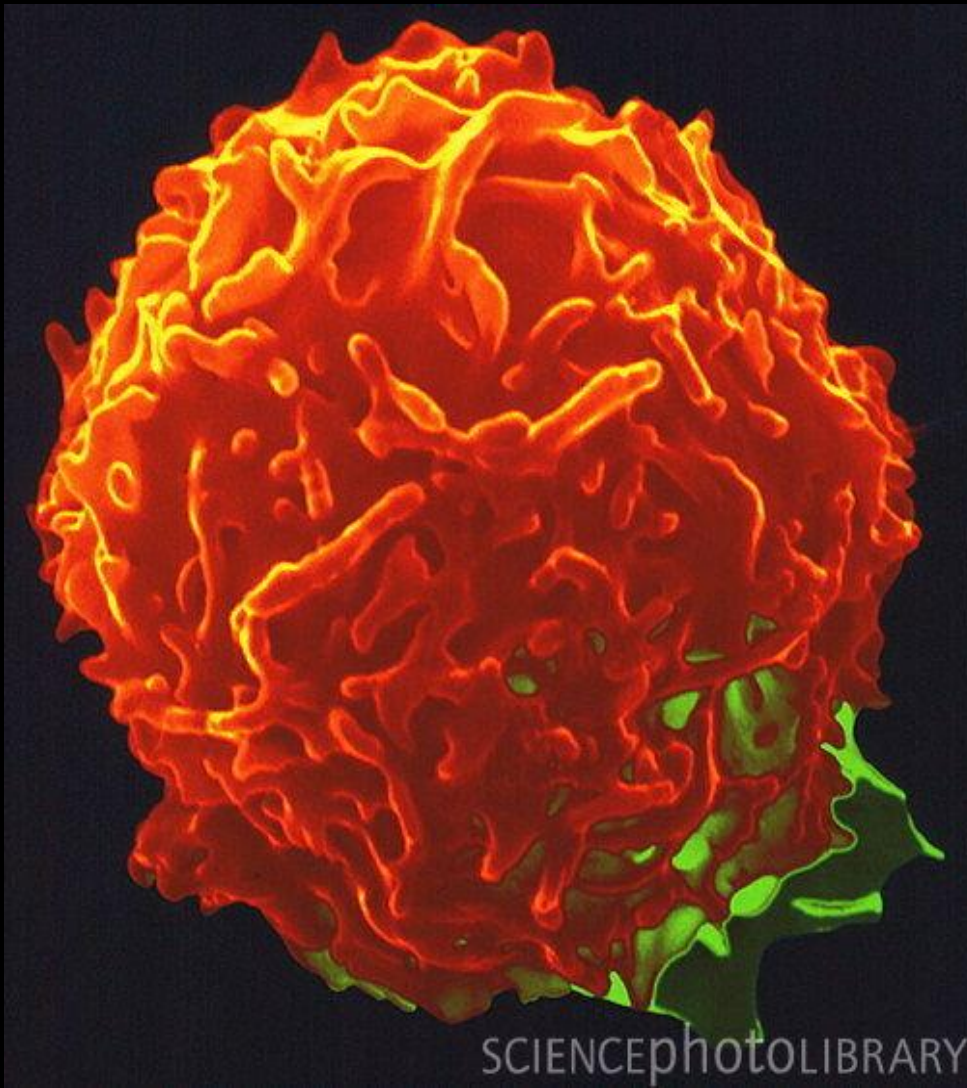



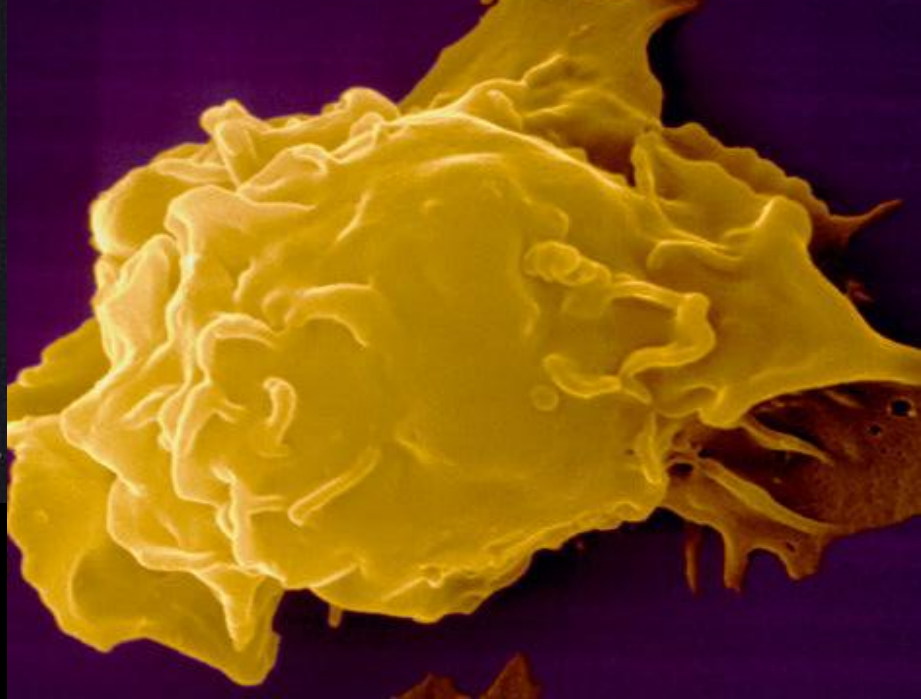
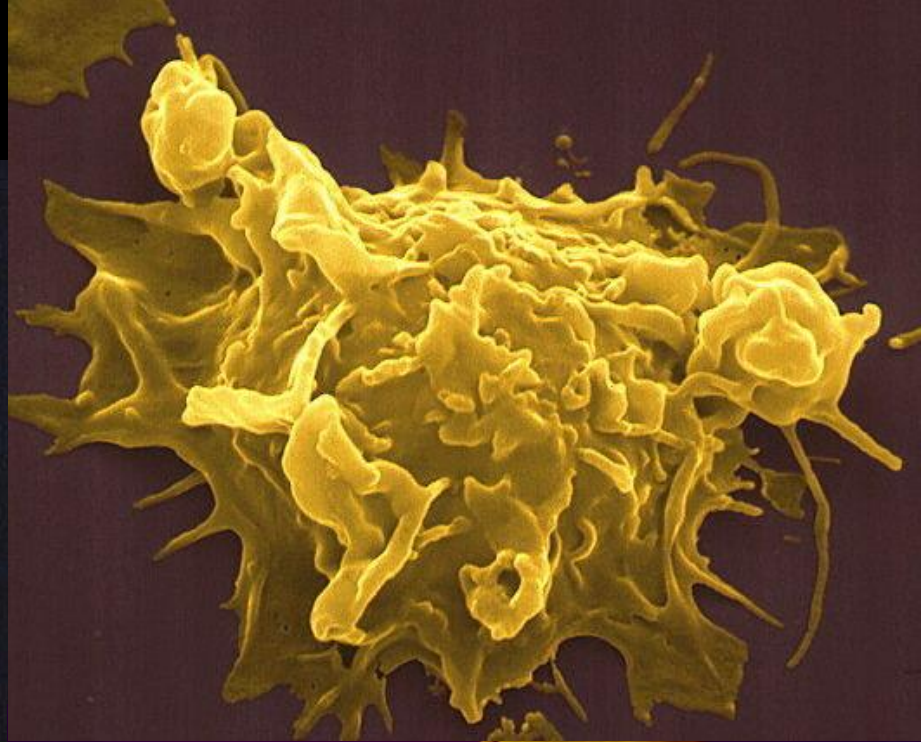
NK hücre



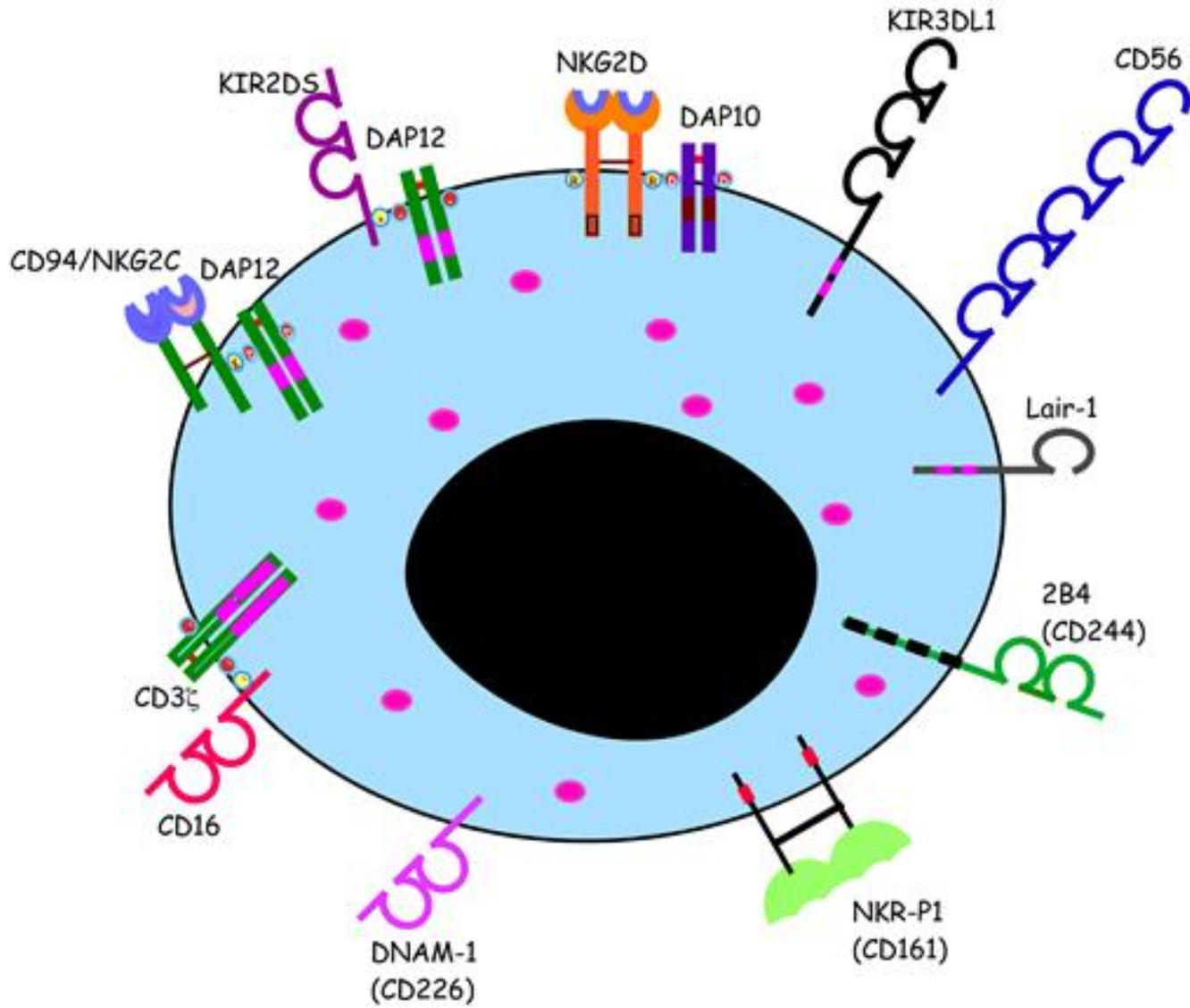




NK hücre

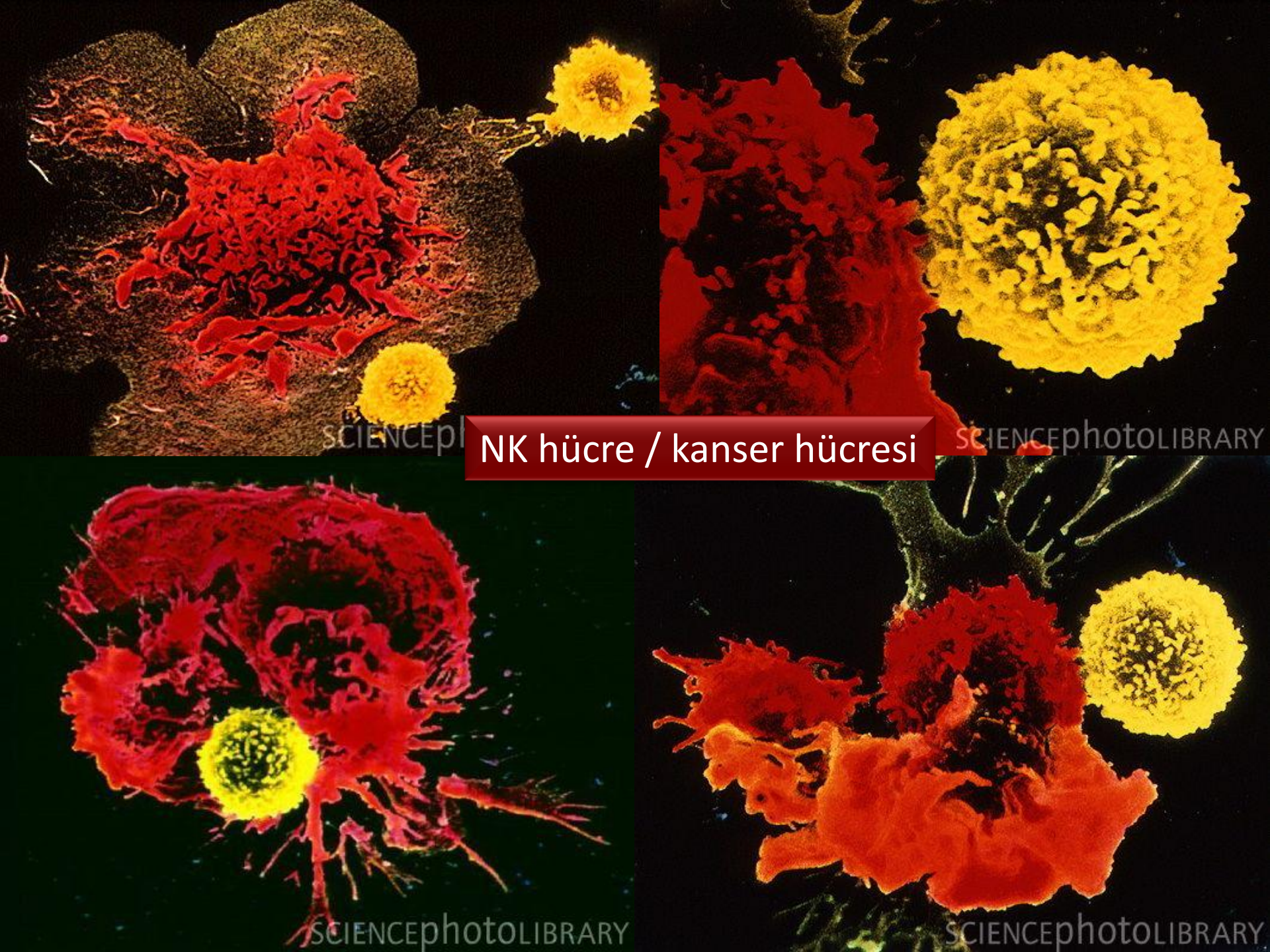






NK hücre yüzey molekülleri





NK hücre / kanser hücresi

SCIENCEPHOTO

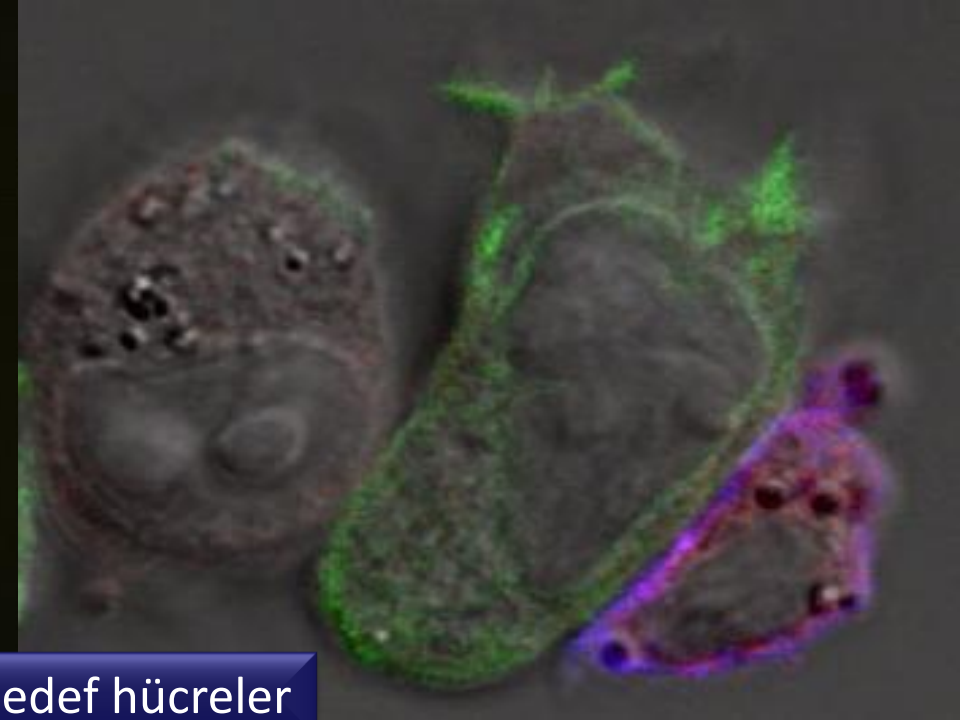
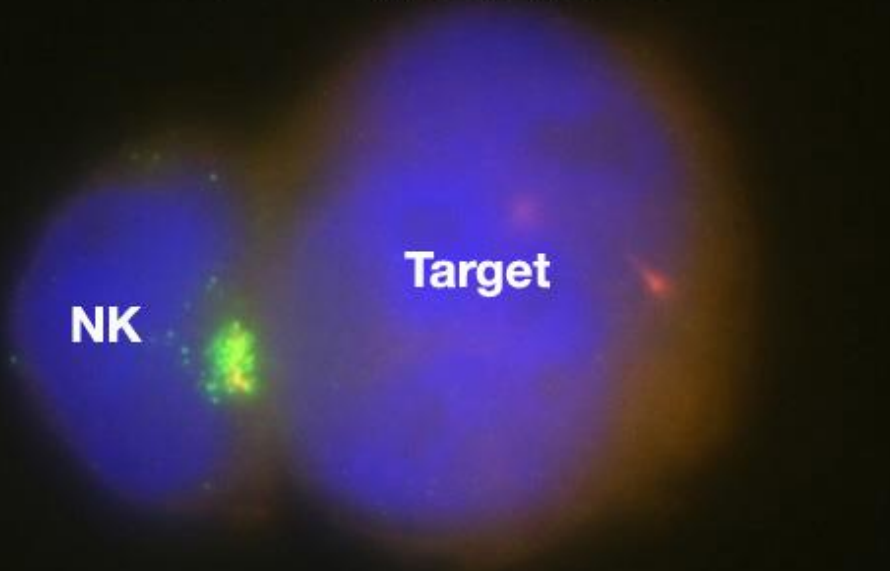
LIBRARY

SCIENCEPHOTO

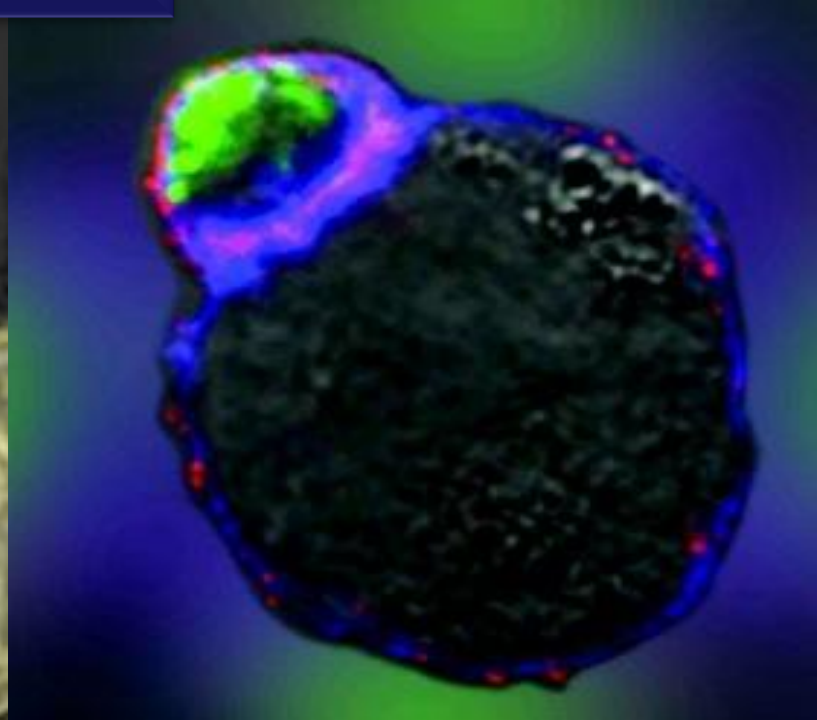
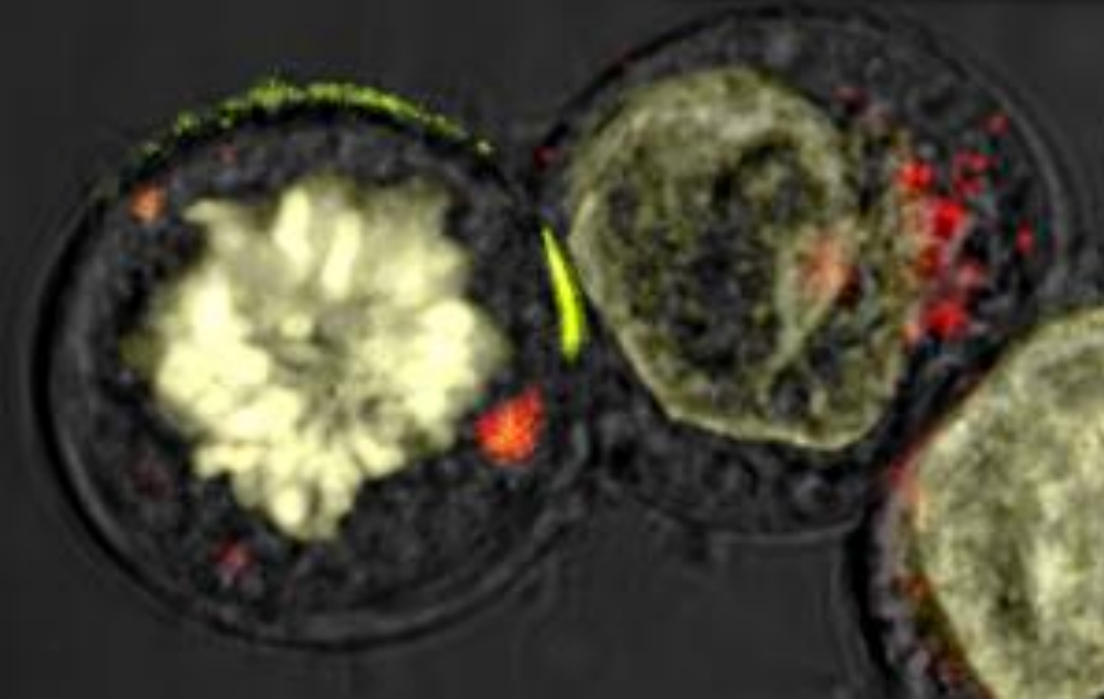
LIBRARY



# A NK cell killing a target cell

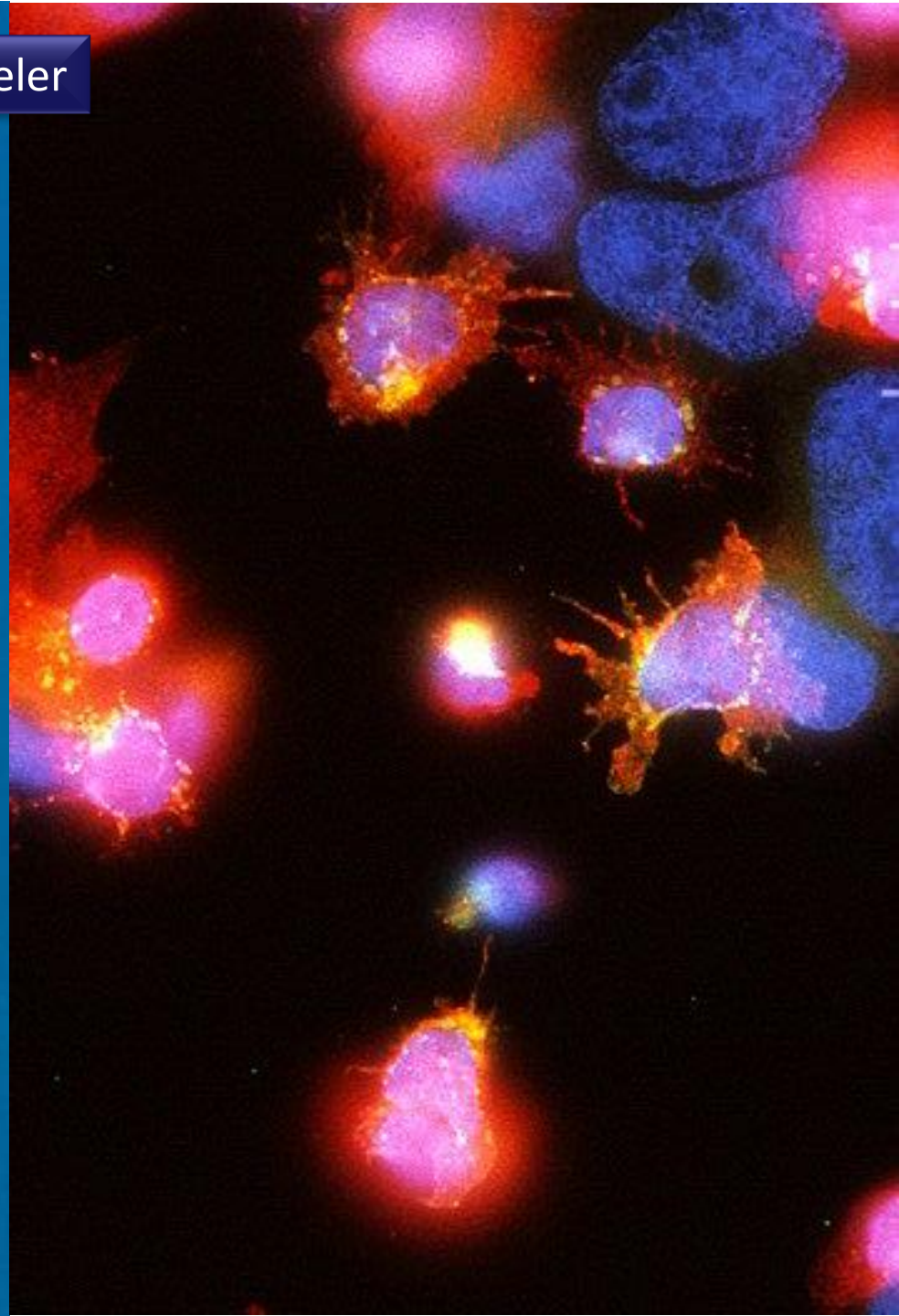
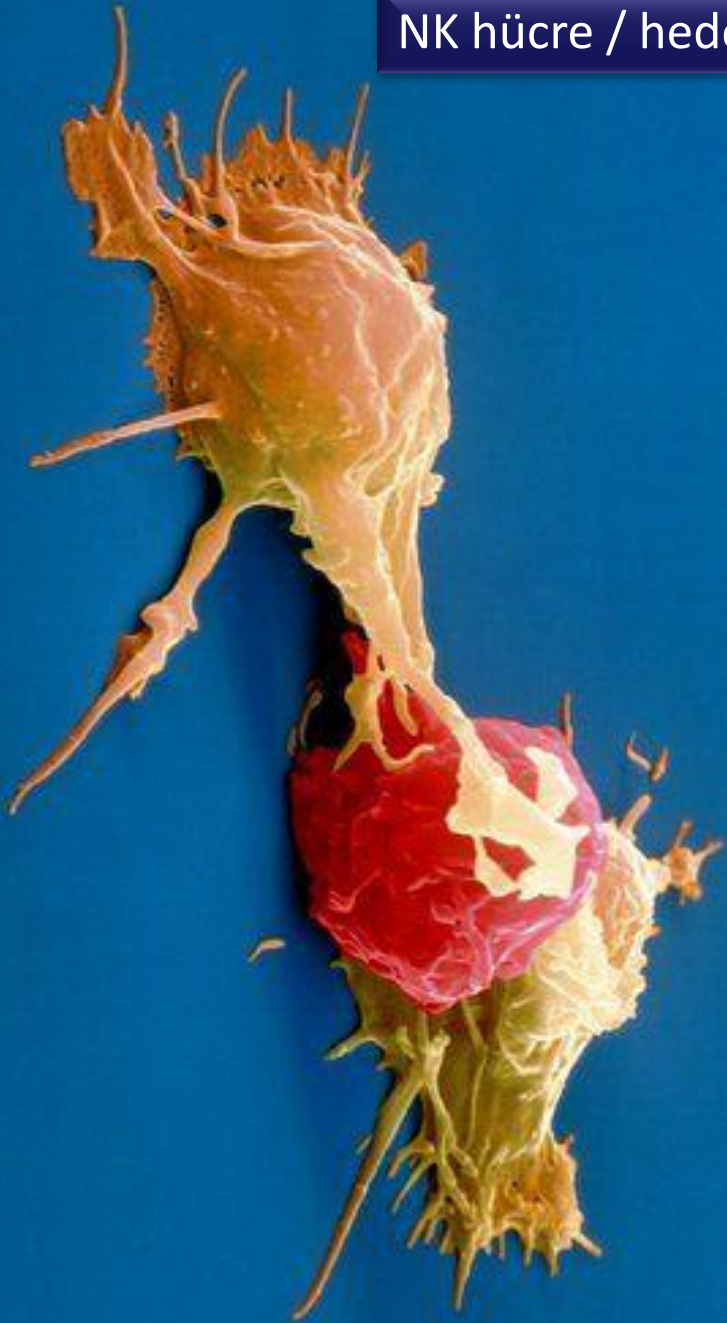

NK hücre / hedef hücreler

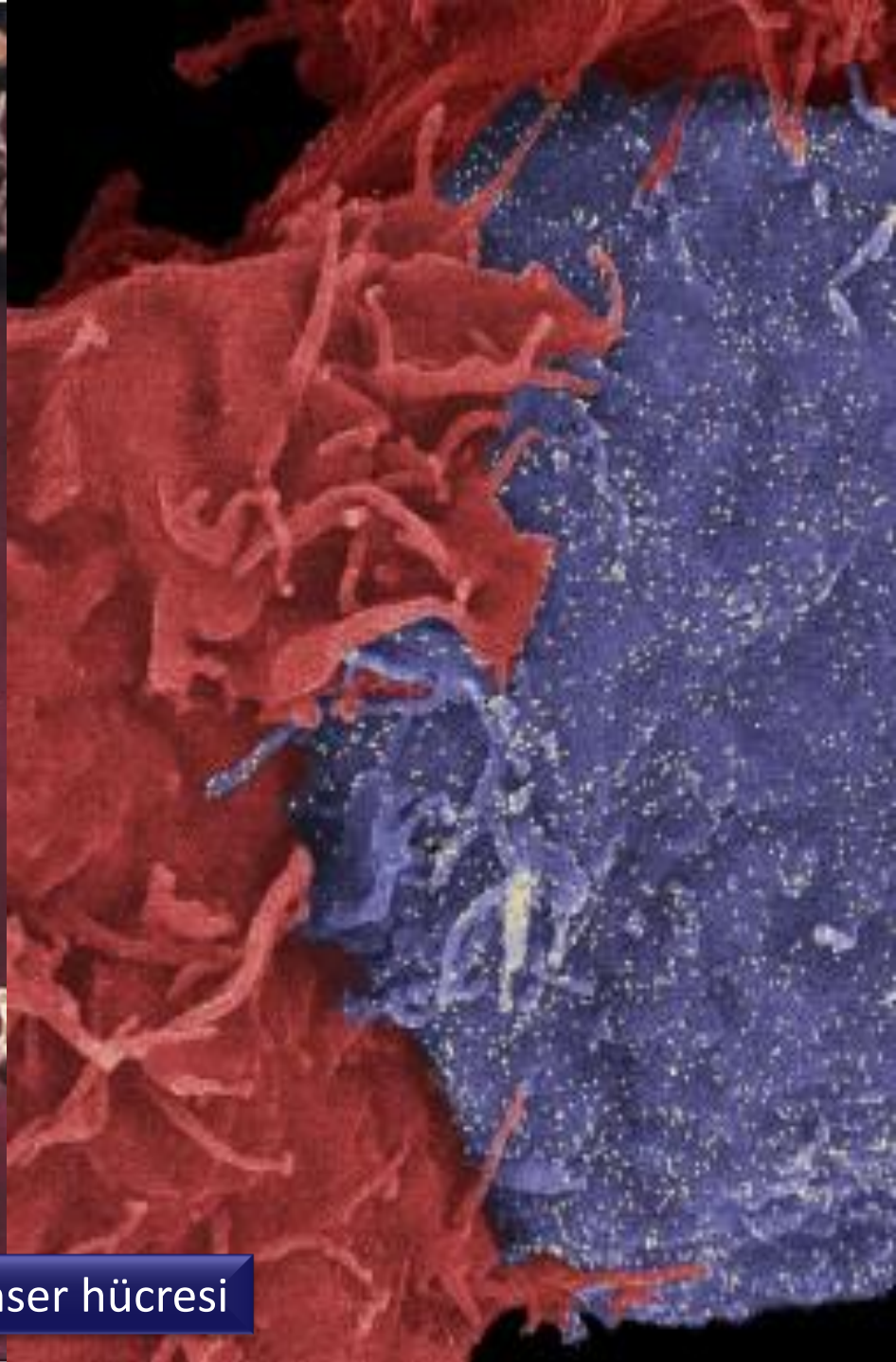
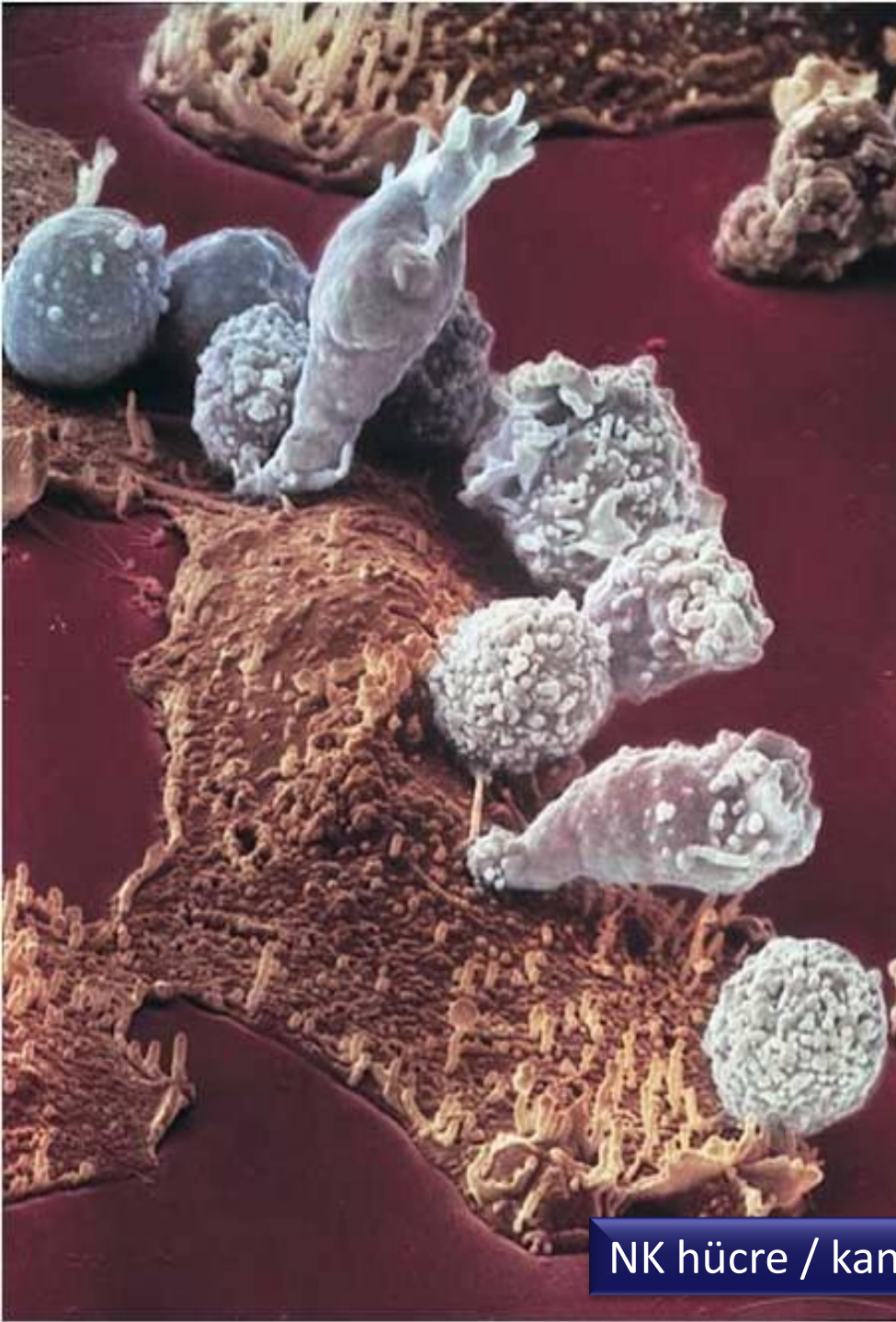



NK hücre / hedef hücreler







NK hücre / kanser hücresi