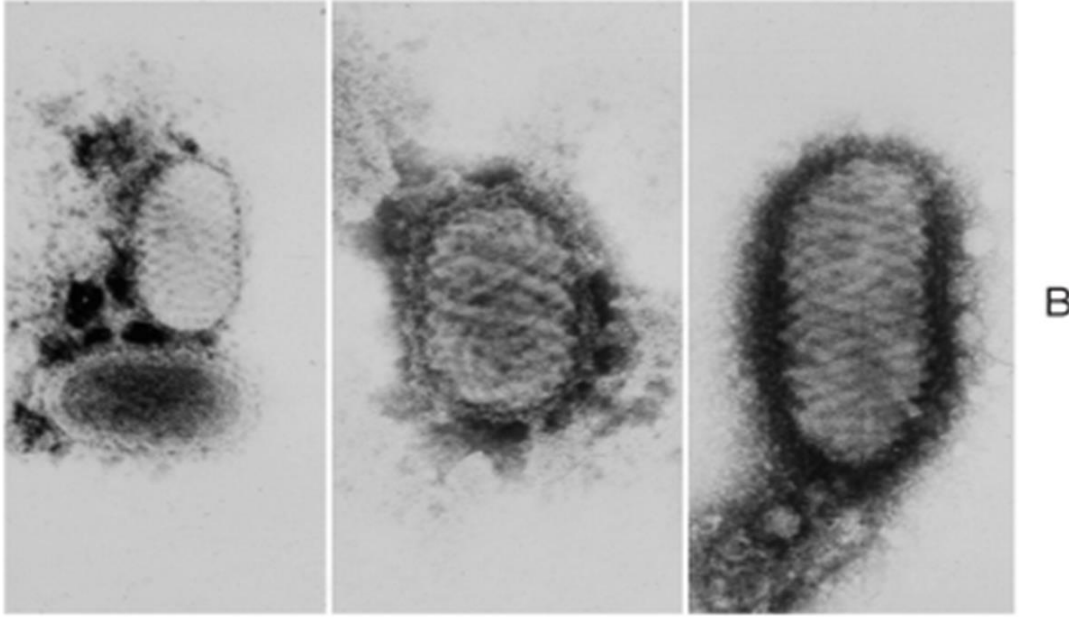


# POXVIRIDAE

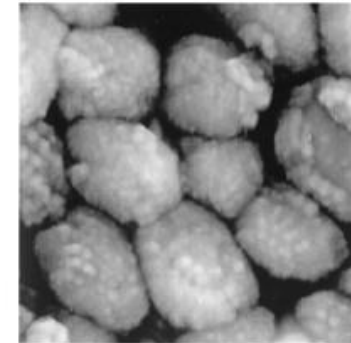
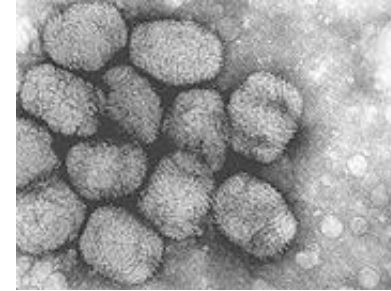
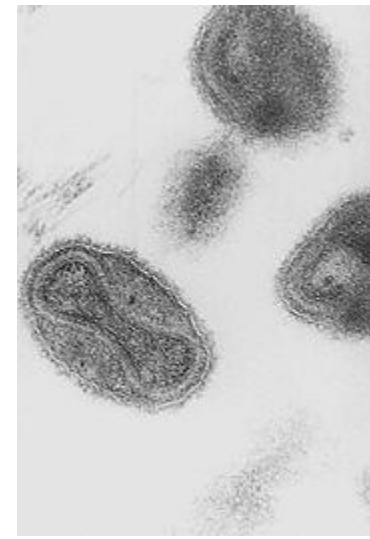


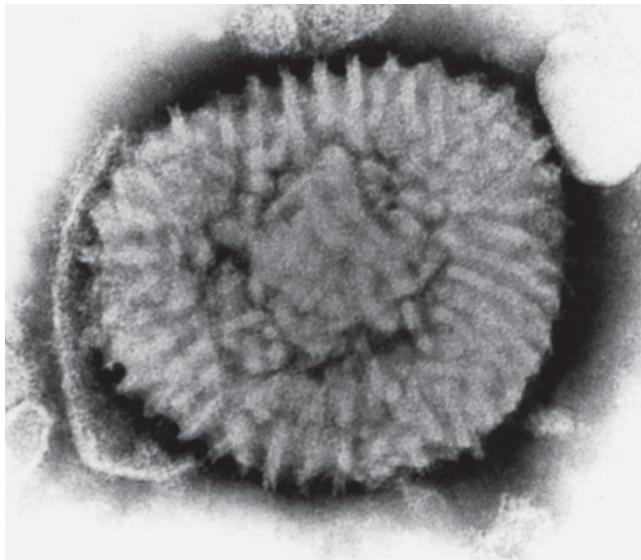© Elsevier. Murray: Medical Microbiology 5e - [www.studentconsult.com](http://www.studentconsult.com)

Viral Zoonozlar – IV.Ders Prof.Dr. T.Çiğdem Oğuzoğlu

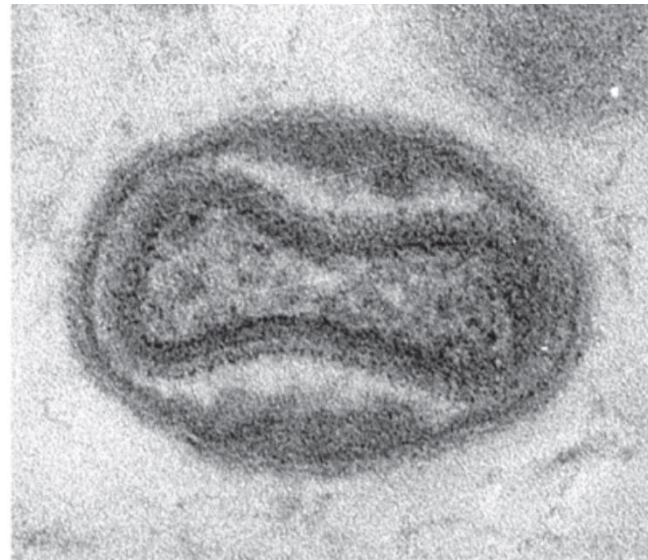# Etiyoloji

- İnsanlarda ölümcül enfeksiyon meydana getiren Poxvirusların önemli bir kısmı, Orthopoxvirus ve Parapoxvirus genuslarında yer alan etkenlerdir.
- Çift iplikli DNA'ya sahip, 200-400nm boyutunda, kompleks yapıda, zarlı etkenlerdir. Çevre şartlarına dayanıklıdırlar.
- Poxviruslar DNA kapsayan viruslar olmasına karşın, intrasitoplazmik olarak çoğalırlar.
- Oval veya tuğla formu görünümünde viruslardır.
- Gerçek Poxviruslar- Variola major, Variola vera isimleri ile anılırlar. Suşa göre %10-90 ölüm meydana getirirler. Smallpox virusları bu grupta yer alır.
- Beyaz Poxviruslar- Variola minör, Alastrim isimleri ile anılırlar. Ölüm oranı (%1-5) sınırlıdır. Monkeypox virusları bu grupta yer alırlar, smallpox viruslardan ayırt edilemezler. Zoonozdurlar.
- Doğu Afrika Poxvirusları- Variola haemorrogica adı ile anılır. Ölüm oranı %5 civarında olmakla beraber bazı ender durumlarda %90'a kadar değişmektedir.





A



B

Source: Karen C. Carroll, Stephen A. Morse, Timothy Mietzner, Steve Miller: *Jawetz, Melnick, & Adelberg's Medical Microbiology, 27<sup>th</sup> Edition*.  
[www.accessmedicine.com](http://www.accessmedicine.com)  
Copyright © McGraw-Hill Education. All rights reserved.

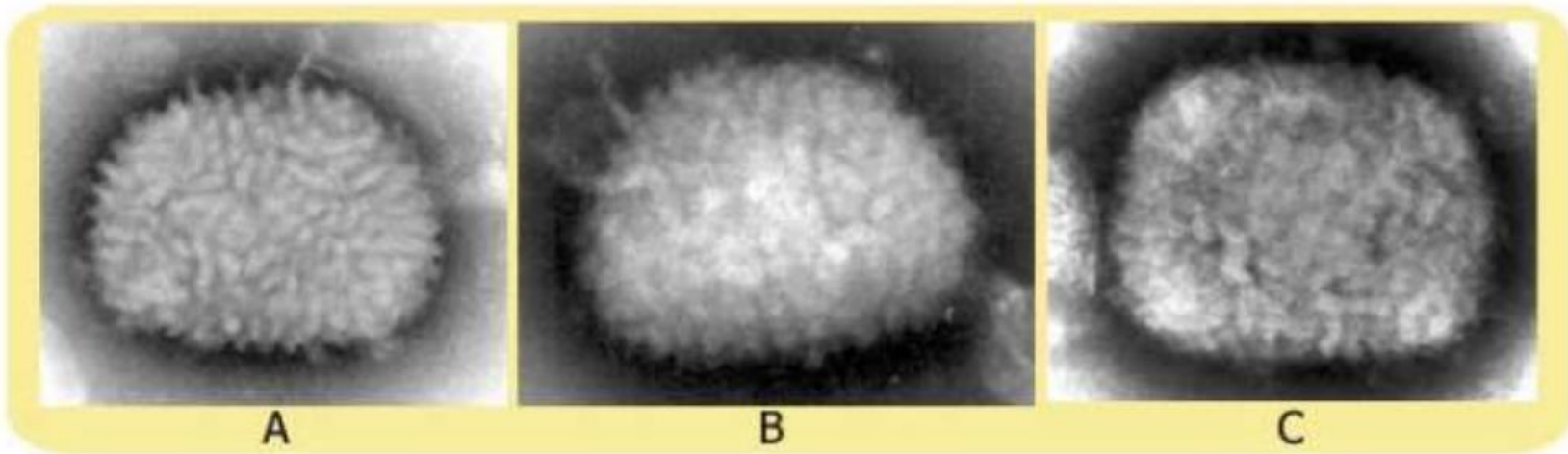
Electron micrographs of vaccinia (Orthopoxvirus) virions. A: Negatively stained particle showing ridges or tubular elements covering the surface (228,000 $\times$ ). (Reproduced with permission from Dales S: The uptake and development of vaccinia virus in strain L cells followed with labeled viral deoxyribonucleic acid. *J Cell Biol* 1963;18:51.) B: Thin section of vaccinia virion showing a central biconcave core, two lateral bodies, and an outer membrane (220,000 $\times$ ). (Reproduced with permission from Pogo BGT, Dales S: Two deoxyribonuclease activities within purified vaccinia virus. *Proc Natl Acad Sci USA* 1969;63:820.)

Source: Poxviruses, *Jawetz, Melnick, & Adelberg's Medical Microbiology, 27e*

Citation: Carroll KC, Hobden JA, Miller S, Morse SA, Mietzner TA, Detrick B, Mitchell TG, McKerrow JH, Sakanari JA. *Jawetz, Melnick, & Adelberg's Medical Microbiology, 27e*; 2015 Available at:

<http://accessmedicine.mhmedical.com/ViewLarge.aspx?figid=94109762&gbosContainerID=0&gbosid=0> Accessed: February 14, 2018

Copyright © 2018 McGraw-Hill Education. All rights reserved



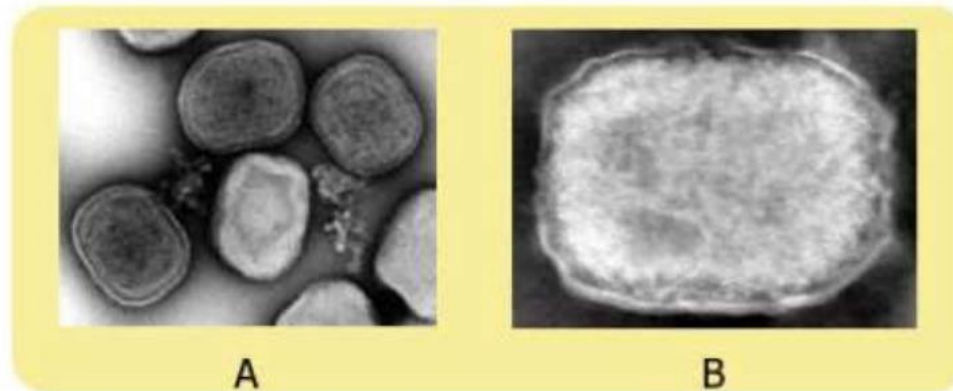
**Figure 3**

3-A: EM of vaccinia virus from tissue culture.

3-B: EM of vaccinia virus from clinical specimen.

3-C: EM of monkeypox virus from clinical specimen.

Note that in clinical specimens the morphology may be less distinct than in tissue culture specimens.



**Figure 4**

4-A: EM of fowlpox virus, tissue culture specimen, showing 3 virions with "C" form.

4-B: EM of tanapox virus, clinical specimen (enveloped virion).

Mikroskopik olarak ilk  
görüntülenen viruslardır.

Embriyolu tavuk  
yumurtasında ve hücre  
kültürlerinde kolaylıkla  
üretilebilirler.

Gen ekspresyonu  
çalışmalarında kullanılırlar.

## Aile: POXVIRIDAE

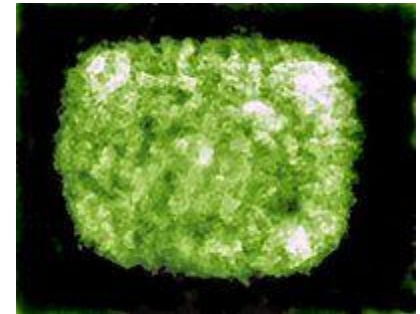
### Alt Aile: Chordopox virinae

Orthopoxvirus	Variola, <u>Vaccinia</u> , <u>Monkeypox</u> , <u>Cowpox</u> , Kamelpox
Avipoxvirus	Kanatlı pox, Kanarya pox
Capripoxvirus	Keçi Çiçeği, Koyun Çiçeği, Lumpy Skin Disease
Leporipoxvirus	Myxomatose
Parapoxvirus	<u>Orf</u> , <u>Bovine papuler stomatitis</u> , <u>Pseudocowpox</u>
Suipoxvirus	Schweinepox
Molluscipoxvirus	Molluscum contagiosum
Yatapoxvirus	<u>Tanapox</u> , Yabapox

*Vacca-* latince *inek* Vaccinia virus

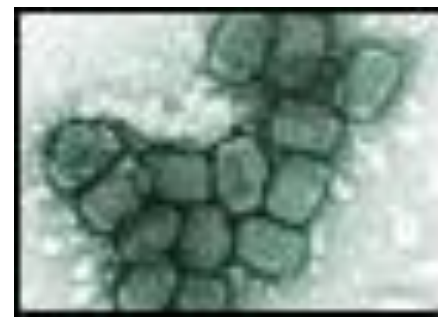
Poxviridae	Cowpox virus	Sığır, kedi, kemirgen	Kontakt, deri çizikleri	Deride püstül
	Milkers' nodes virus	Sığır	Kontakt, deri çizikleri	Deride nodül
	Orf virus	Koyun, keçi	Kontakt, deri çizikleri	Deride ülser
	Monkeypox virus	İnsan, sincap	Kontakt, oral	Generalize döküntü
	Tanapox virus	Kemirgen?, maymun	İnsekt ısırması (mekanik)	Deride nodül

Genus	Disease	Common names and characteristics of diseases
<i>Orthopoxvirus</i>	Variola	Smallpox; systemic; general rash; extinct
	Monkeypox	Systemic; general rash; rare zoonosis
	Vaccinia	Smallpox vaccine; local skin lesion
	Cowpox	Local skin lesion; rare zoonosis
<i>Parapoxvirus</i>	Orf	Local skin lesion; rare zoonosis
	Paravaccinia	Milker's nodules; rare zoonosis
<i>Yatapoxvirus</i>	Tanapox	Local skin lesion; rare zoonosis
	Yabapox	Local skin lesion; rare accidental infection
<i>Molluscipoxvirus</i>	Molluscum contagiosum	Multiple skin lesions; human transmission





## Smallpox (Variola) Virus Efeksiyonu



Smallpox- latince *spotted* (lekeli, benekli) sözcüğünden türetilmiştir.

25 yıldan bu yana tüm dünyada eradike edilmiştir. (1977'de Somali)

1980'den bu yana insanlarda aşılama yapılmamaktadır. (WHO kararı)

Şu an 25 yaşında olan genç insanlar artık Orthopoxvirus enfeksiyonu yönünden korunmamaktadır.

Zoonoz bir enfeksiyon değildir (Anthroponoses). Sadece insanda enfeksiyon meydana getirir.

Bioterörizm! (Fransız-Kızıldereli, İspanya-Aztekler)

Bilinen en eski virus enfeksiyonudur.

Firavun 5.Ramses (M.Ö.1157)

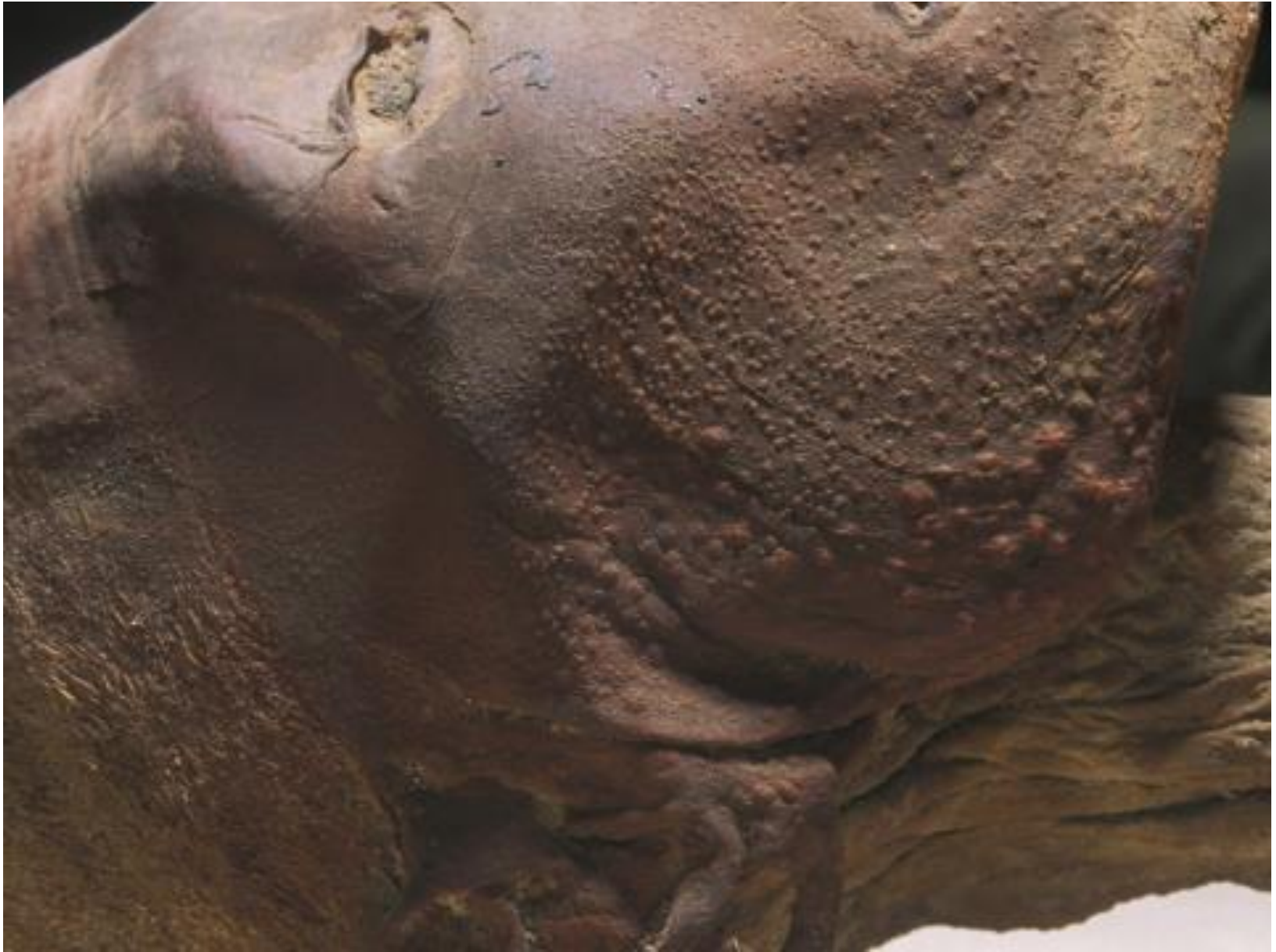1520'de 3.5 milyon Aztekli'nin ölümü.

1798'de Edward Jenner Vaccinia Virus'un Smallpox'a karşı koruyuculuğunun tespiti.

Cowpox virusun izolasyonu.

Bulaşma- Direkt temas, vücut sıvıları ve kabuk





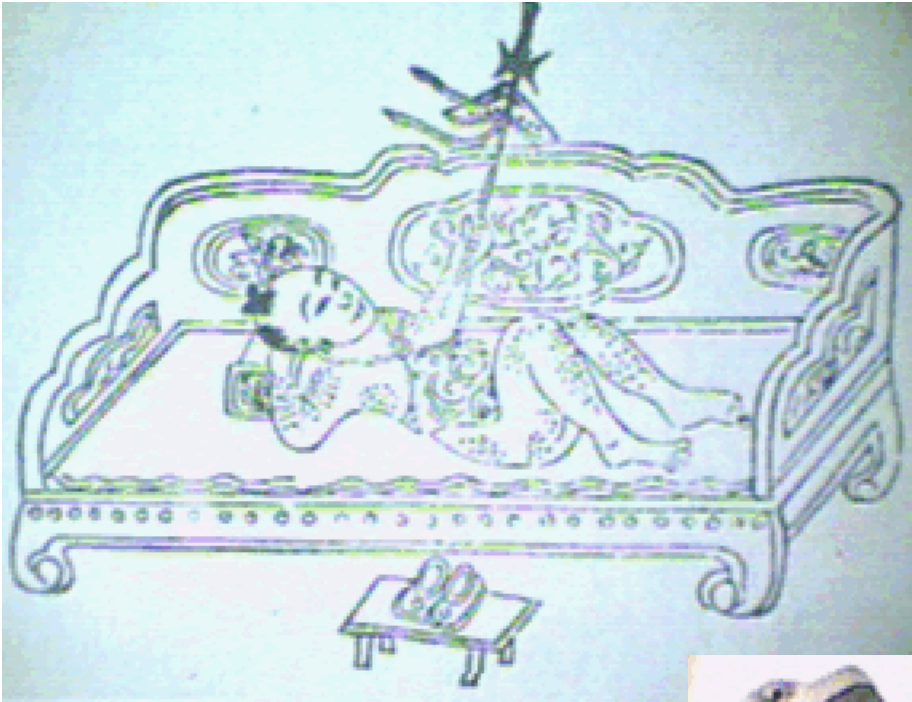
Ramses V, a pharaoh who had smallpox. Getty Images

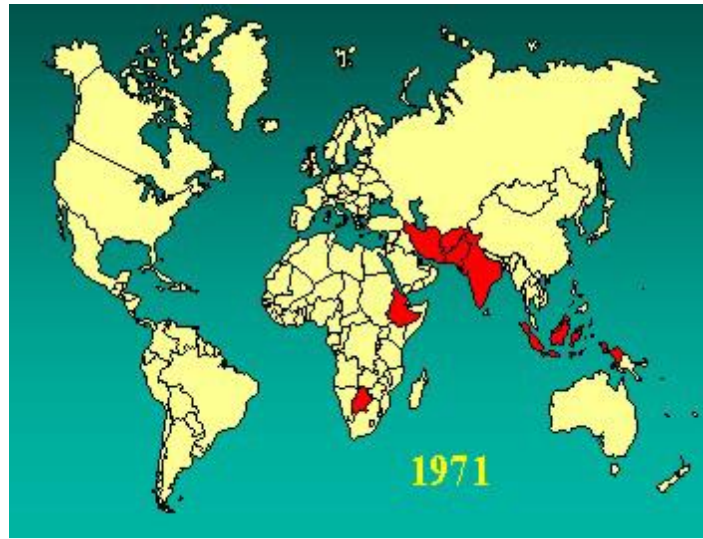
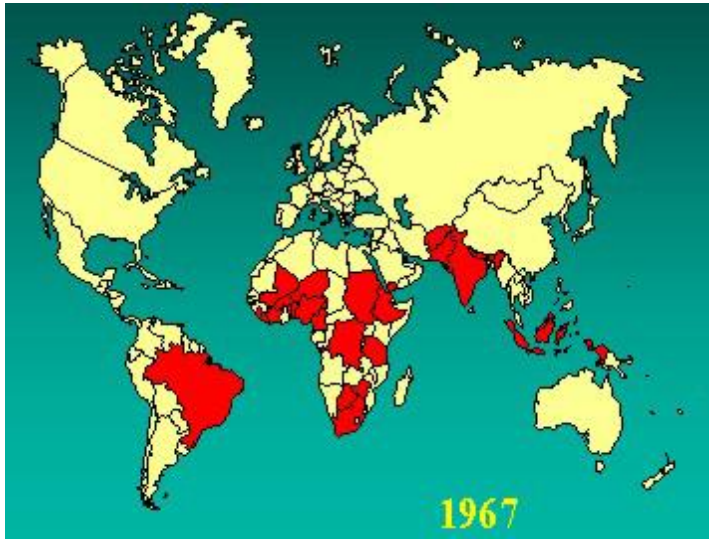
# Jenner, 1798



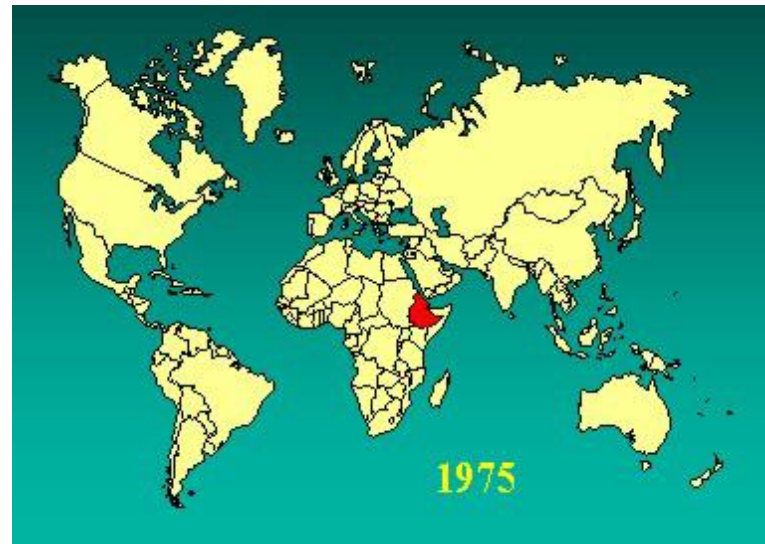
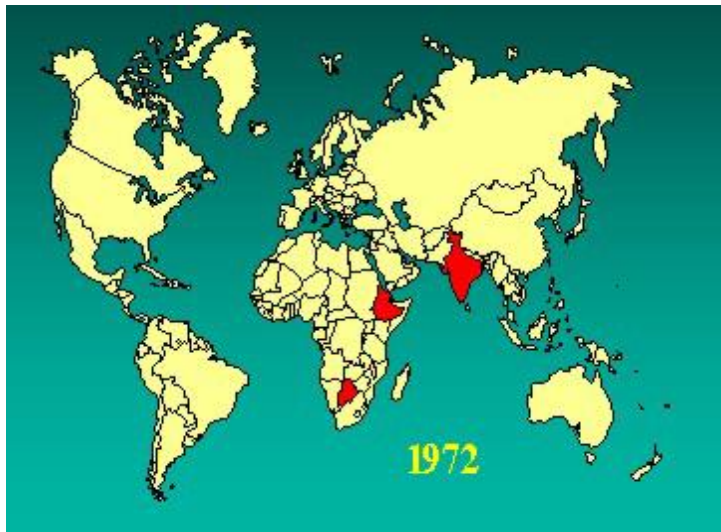Cowpox virusu ile 8 yaşındaki James Phipps Variola'ya karşı aşılandı.







1977 Somali

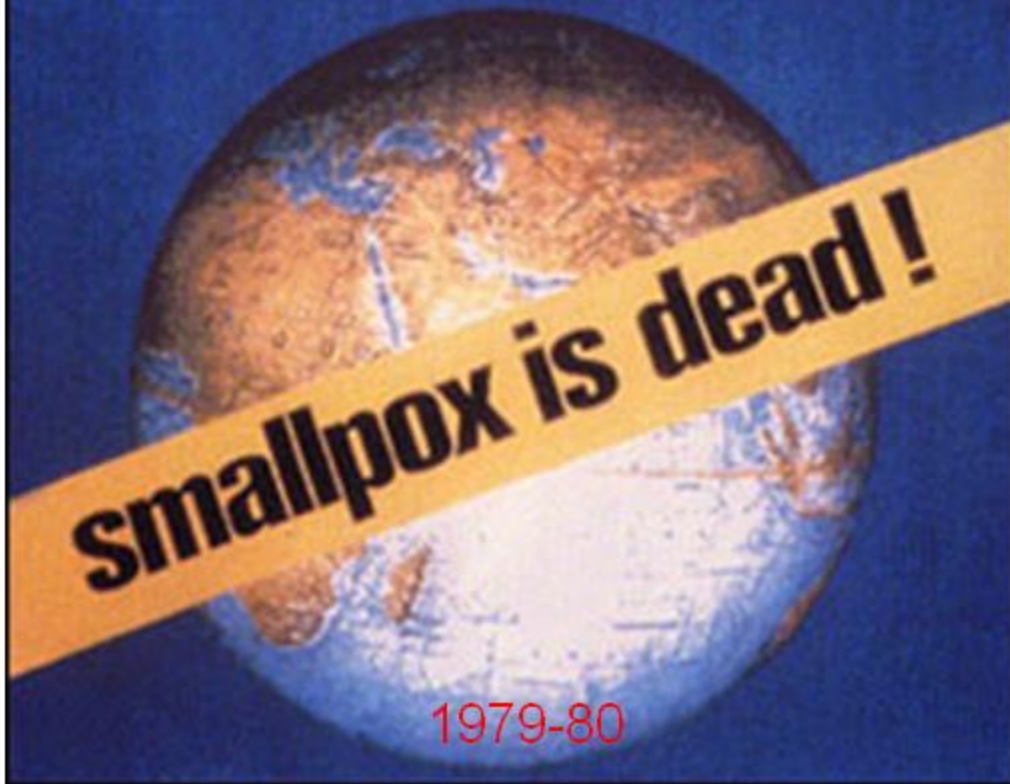


Monkeypox 1975 Zaire



# WORLD HEALTH

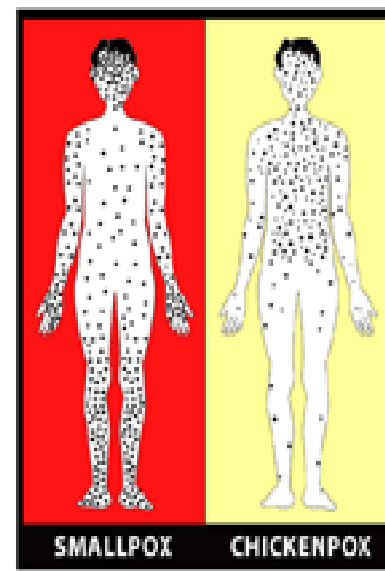
THE MAGAZINE OF THE WORLD HEALTH ORGANIZATION - MAY 1980



1979-80

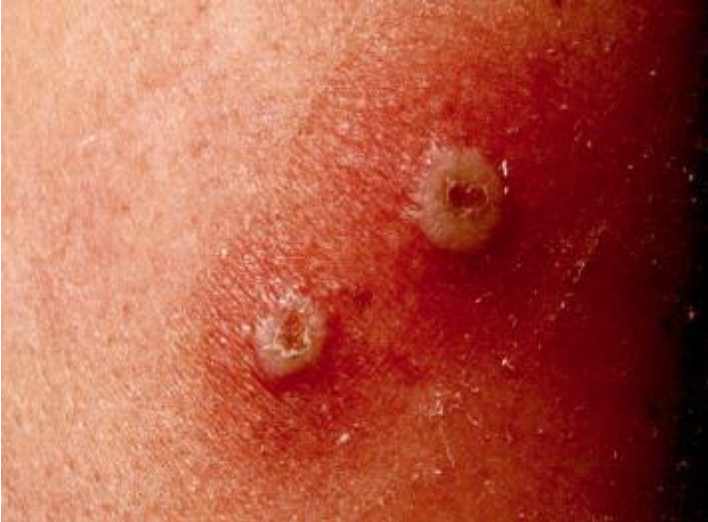# Klinik

- 7-17 gün inkubasyon (ortalama 12 gün)
- 1.viremi karaciğer, dalak, lenf yumruları
- 2.viremi deri
- Prodromal dönem (2-4 gün) - Ateş, durgunluk, halsizlik, vücut ağrısı, kusma.
- Erken döküntülü dönem (4 gün) – dilde ve ağız boşluğunda kızarıklık, sekrette virus bulunur. Yüz, eller, kollar ve bacak dersinde ağrılı yaralar, dördüncü gün içi sıvı dolu veziküller.
- Pustular dönem (5 gün)
- Kabuklanma dönemi (6 gün)
- Ayrılma dönemi
- Kabukların toplam iyileşme süresi 3 haftadan itibaren

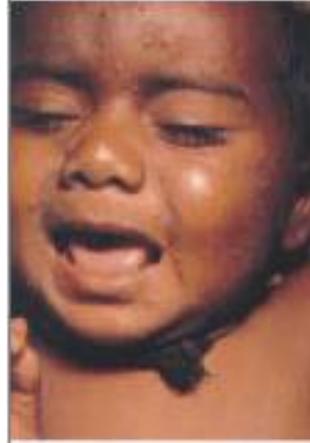

# Klinik Lezyon Evreleri

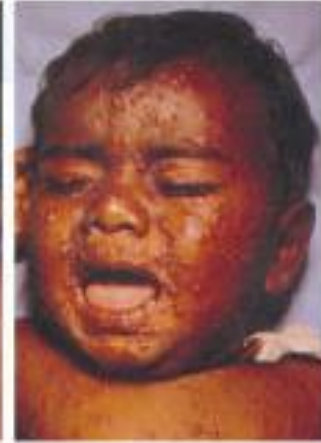- Makula (Kızarıklık),
- Papul (Kabarcık),
- Vezikül (İçi sıvı dolu kesecik),
- Pustul (Sıvının koyulaşıp irinleşmesi),
- Kruste (Kabuk).



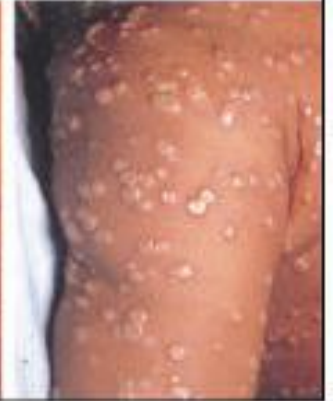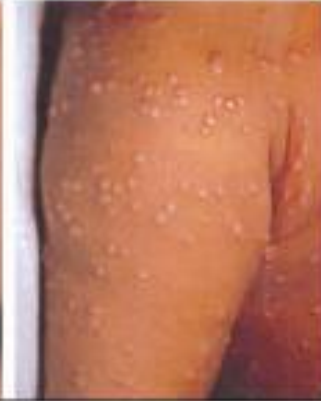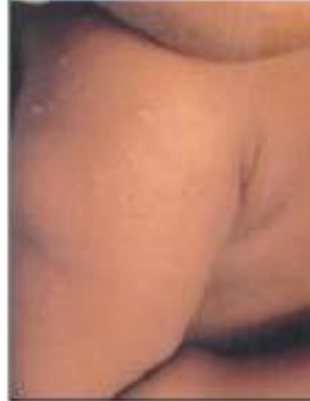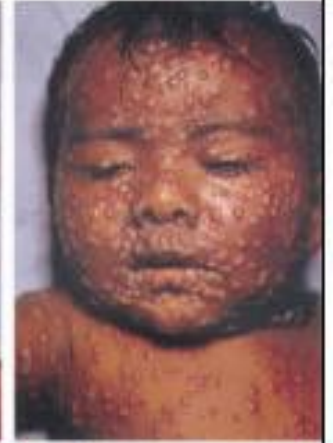3. Gün



5.Gün



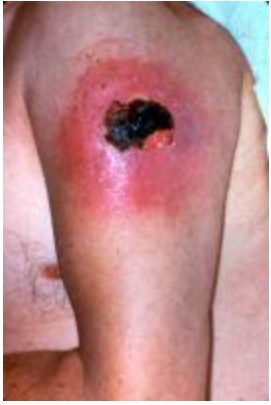7.Gün



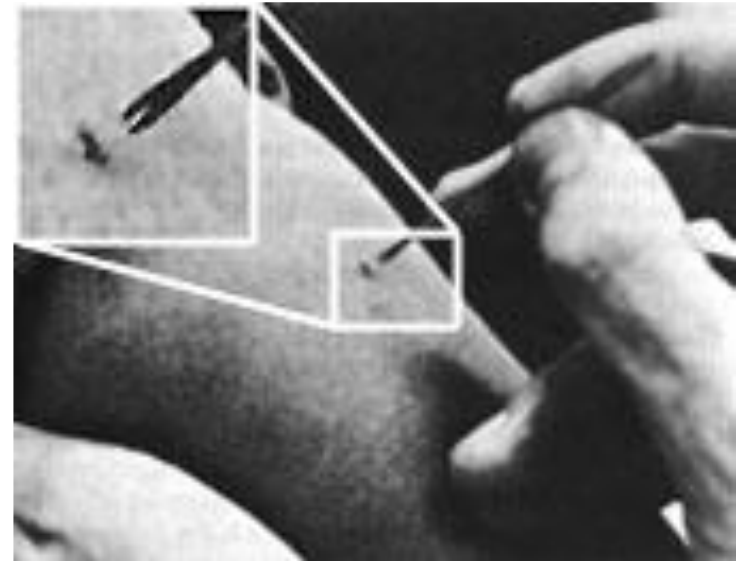








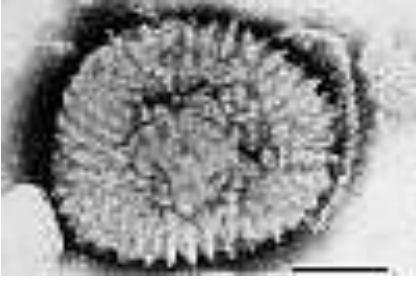
Aşılama sonrası gelişen  
vaccinia gangrenosum



Aşılama

**Table 1.** Select zoonotic poxviruses and their associated distribution and clinical features.

<b>Genus</b>	<b>Virus</b>	<b>Geographic location</b>	<b>Reservoir</b>	<b>Primary zoonotic source</b>	<b>Clinical features in animals</b>	<b>Clinical features in humans</b>
Orthopoxvirus	Cowpox	Europe & Western Asia	small rodents (voles & wood mice)	domestic cats	single bite like lesion on head or extremity that develops into a generalized papular rash; upper respiratory signs	painful, large, ulcerative lesion on hand or face with inflammation and edema; thick, hard, black crust; flu-like symptoms
	Monkeypox	Western & Central African rainforests	UNK; suspect rodents	rodent species	sudden death; upper respiratory signs, anorexia, lymphadenopathy, blepharitis; +/- generalized papular rash	2-4 day prodrome of headache and fever; generalized rash and lymphadenopathy; single nodule with focal hemorrhagic necrosis at inoculation site (hand)
Parapoxvirus	Orf	World-wide	sheep & goats	sheep & goats	large proliferative lesions with raised crust primarily around comissures and muzzle	Single or multiple lesions on upper extremities (especially hands) or face; vesicle has "target" appearance (red center, white ring, red halo), papillomas over surface prior to crusting
	Bovine Papular Stomatitis	World-wide	cattle	cattle	primarily young feedlot cattle ; lesions usually on muzzle, nose & hard palate; erosions & ulcers common	see Orf
	Pseudocowpox (Paravaccinia)	World-wide	cattle	cattle	primarily dairy cows; lesions usually on teats, udder & perineum	see Orf



# Cowpox

İnsanda kendini sınırlayan bir viral zoonoz enfeksiyondur.

Sığır, kedi ve kemirgenler rezervuar konakçdırlar.

İnsan ve memeli birçok hayvanda enfeksiyon görölmüştür.

Dermatitis, mastitis, ülseratif stomatitis ile komplike olabilir.

Klinik

Sirkte yařayan fillerde tespit edilmiř, bakıcılarına bulařtıęı bildirilmiřtir.

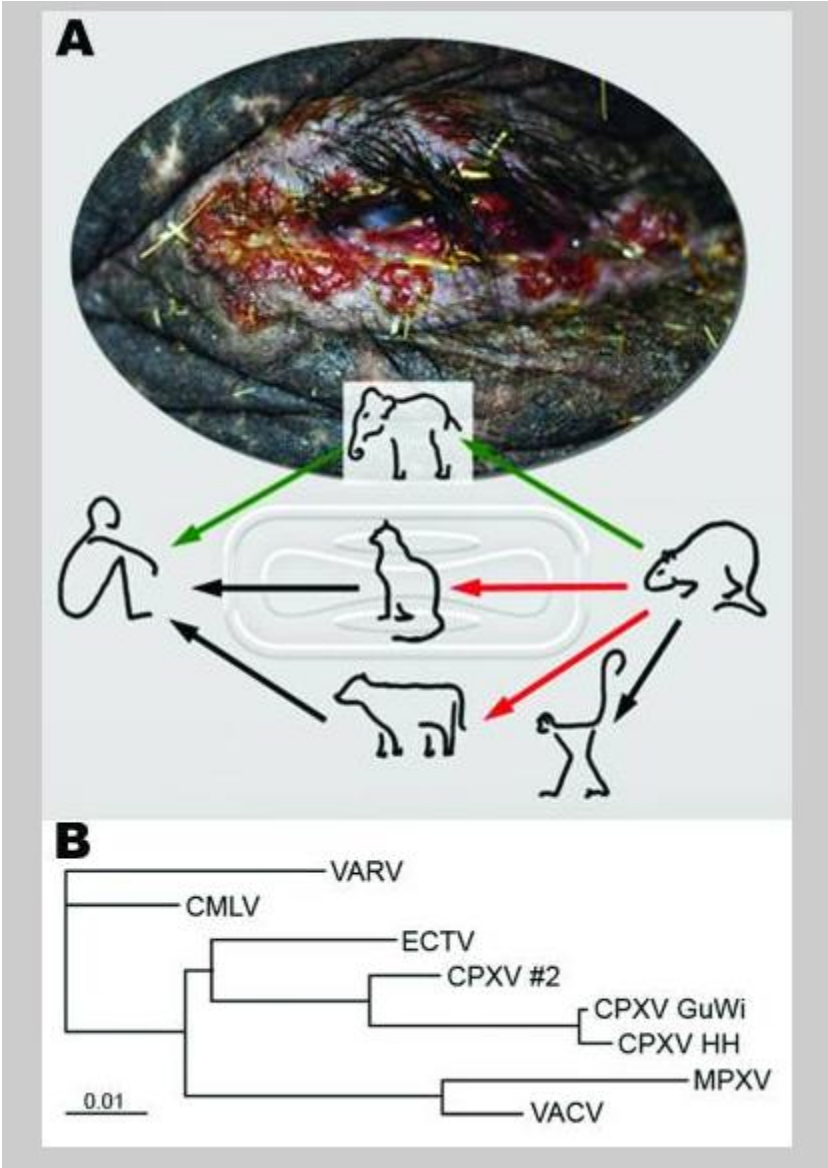


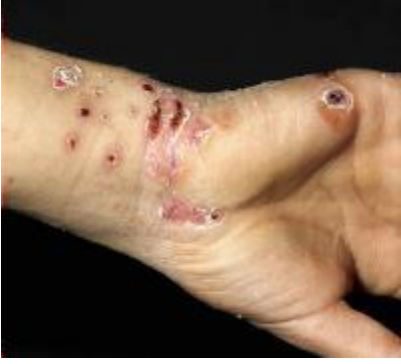Kurth A, Wibbelt G, Gerber HP, Petschaelis A, Pauli G, Nitsche A. Rat-to-elephant-to-human transmission of cowpox virus. *Emerg Infect Dis.* Apr 2008;14(4):670-1.

Gambian giant-pouched rat (*C. gambianus*)



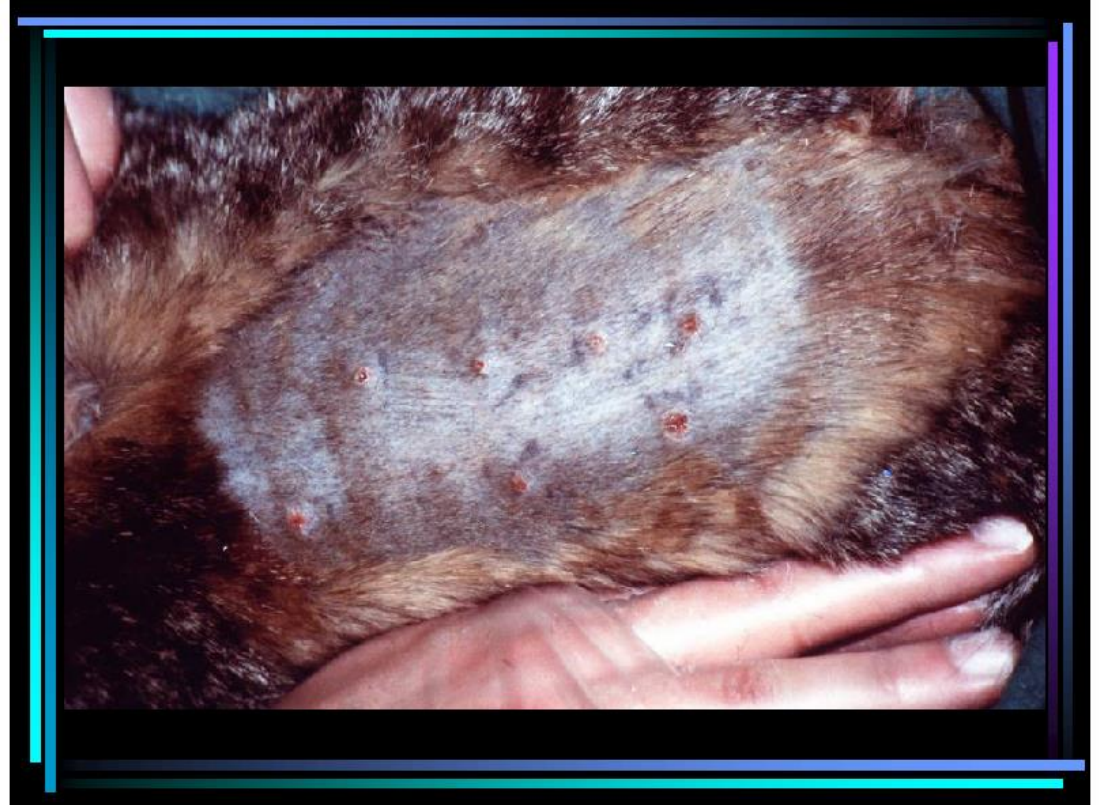courtesy Lincoln Park Zoo





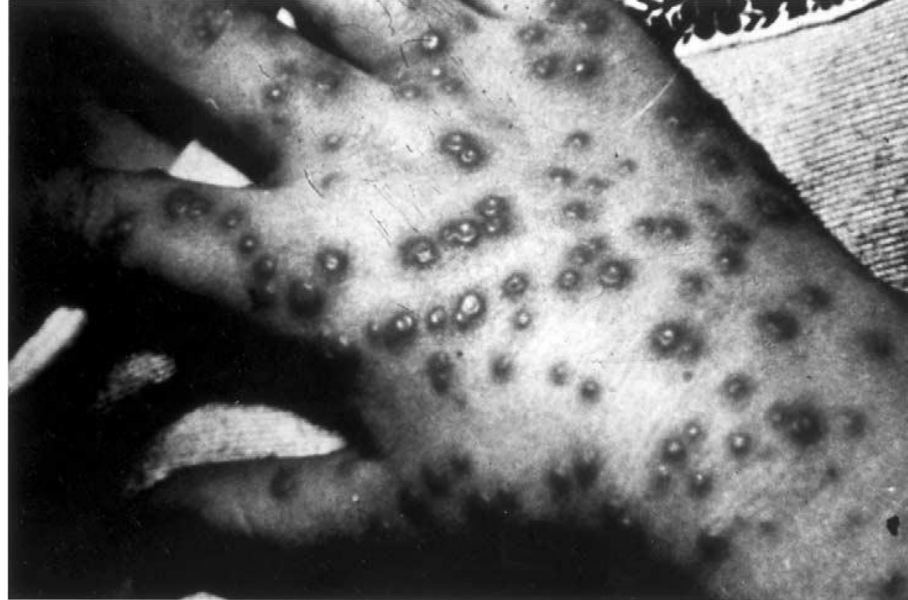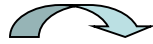İnsanlarda 9-10 günlük inkubasyondan sonra lenf yumrularında şişkinlik, ateş, iştah kaybı ve deride vezikülo exantemler gözlenir.

A 16-year-old boy with generalized cowpox. Courtesy of Dr. Reinhard Hoepfl, Innsbruck, Austria.



# Monkeypox virus enfeksiyonu

- 1958'de Kopenhag hayvanat bahçesindeki maymunlarda tespit edilmiştir.
- Maymun ve kemirgenler tarafından bulaştırılır. Zoonozdur.
- 1970'lerde Zaire'de çocuklarda %90 ölümcül seyreden bu enfeksiyon Smallpox'tan ayırt edilemez.



# Parapox virus enfeksiyonu

- Koyun ve Keçilerin Püstüler Dermatitisi

Ecthyma contagiosum veya ORF

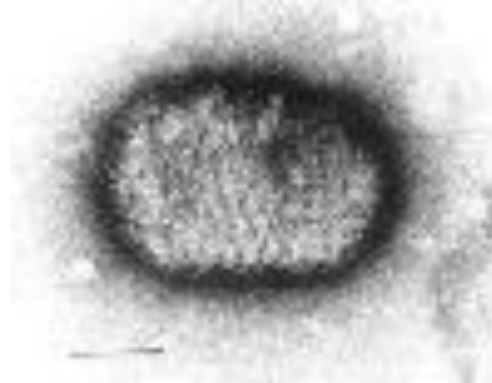Etken: *Parapoxvirus ovis*

Mortalite %20-50

(gençlerde)

Morbidite yüksek

İnkubasyon 3-8 gün



Klinik formlar:

Labial

Podal

Genital

Malignant

Endemik olduğu ülkeler: Kuzey Amerika, Yeni Zelanda

Klinik

# Klinik

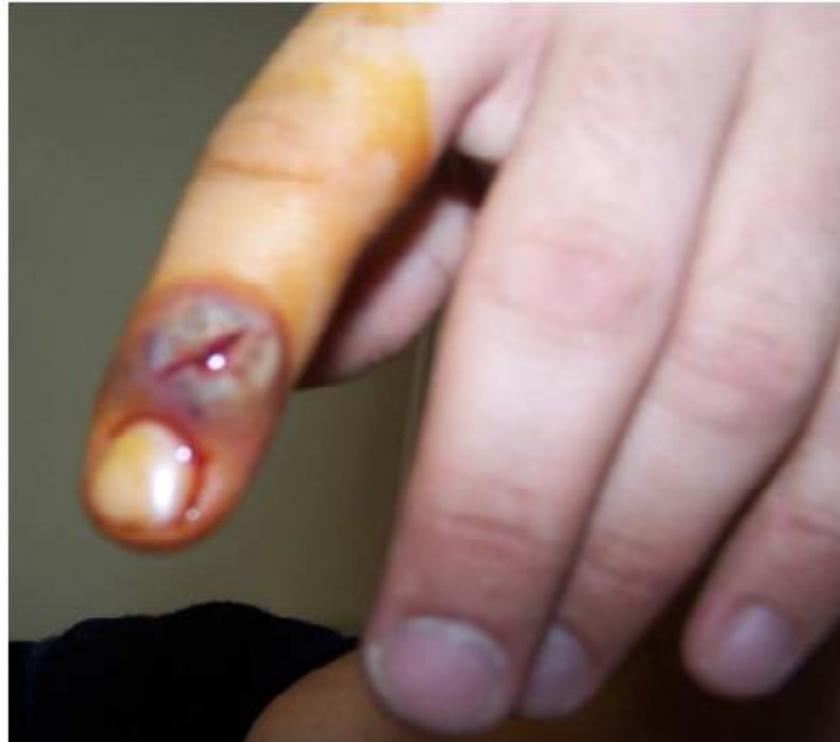- Podal
- Genital

# Korunma ve Mücadele

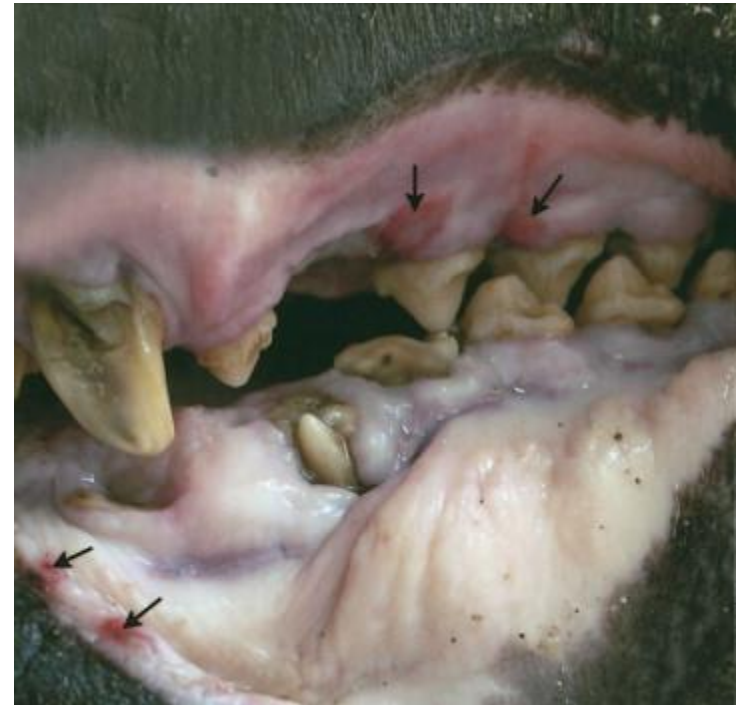- Canlı aşı – subkutan
- 1-2 günlük yavrulara aşılama yapılır.
- Enfeksiyon görülen yerlerde mihrak dışında bulunan 3 aydan büyük tüm küçük ruminantlar aşılanmalıdır.
- Enfekte hayvanların sütleri tüketilmemelidir.
- İnsanlardaki yaralara antiseptik pudralar kullanılabilir.



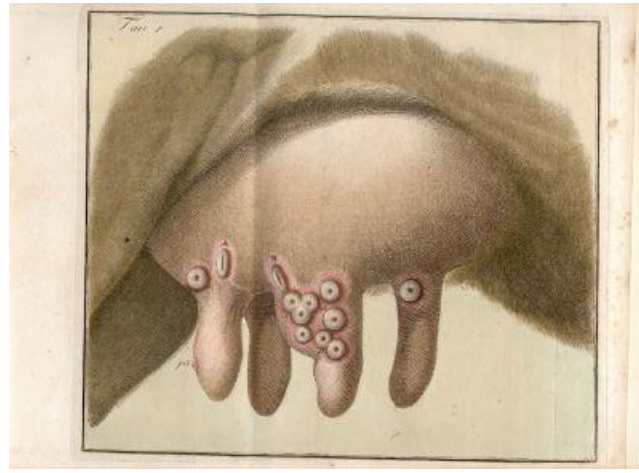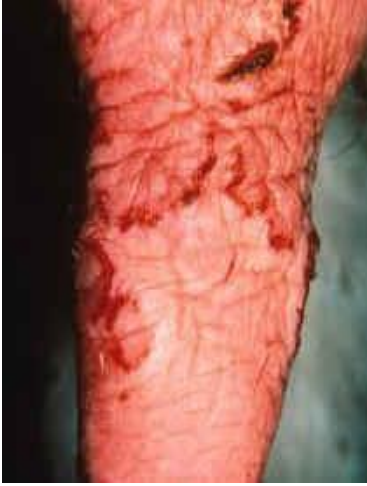First molecular characterization of a Turkish orf virus strain from a human based on a partial B2L sequence. Karakaş ve ark. (2013)







**Visceral Leishmaniosis and Parapoxvirus Infection in a Mediterranean Monk Seal (*Monachus monachus*) Toplu ve ark. 2007**

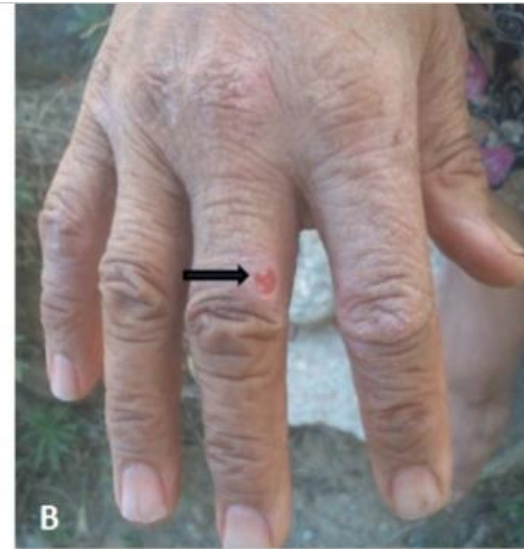
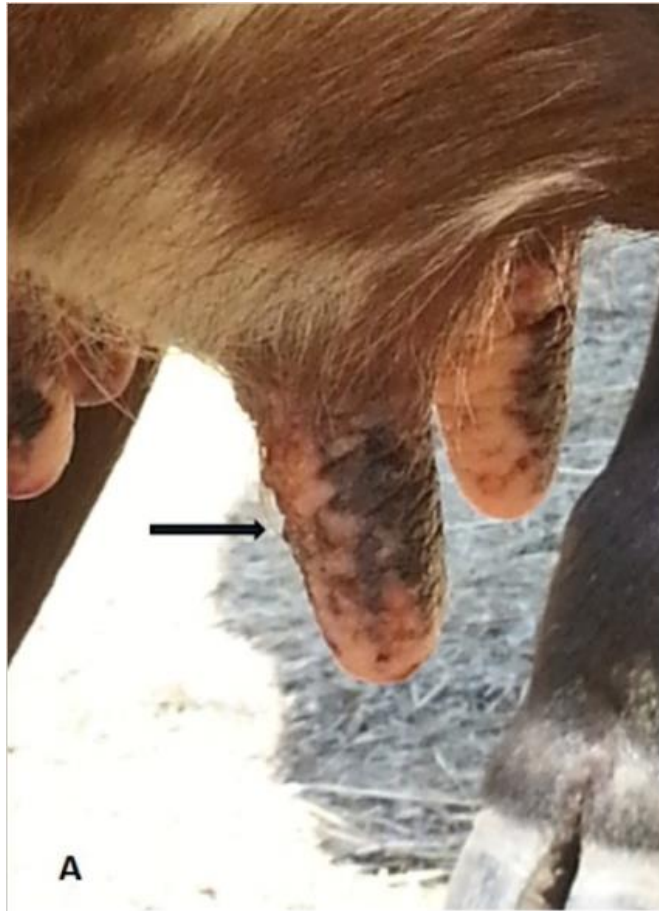
1799 - ilk bildirim

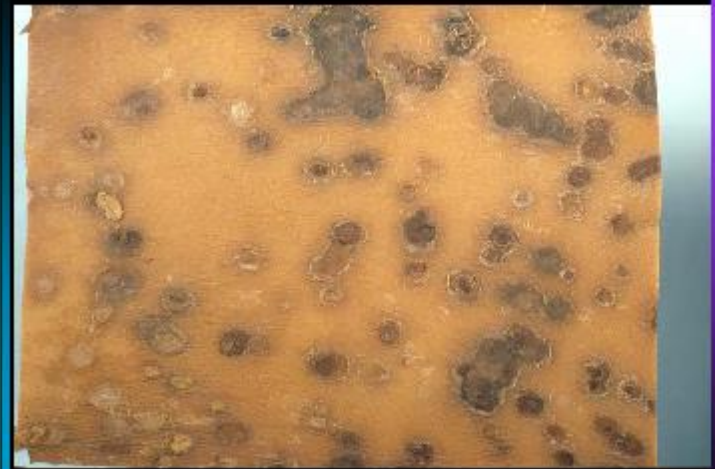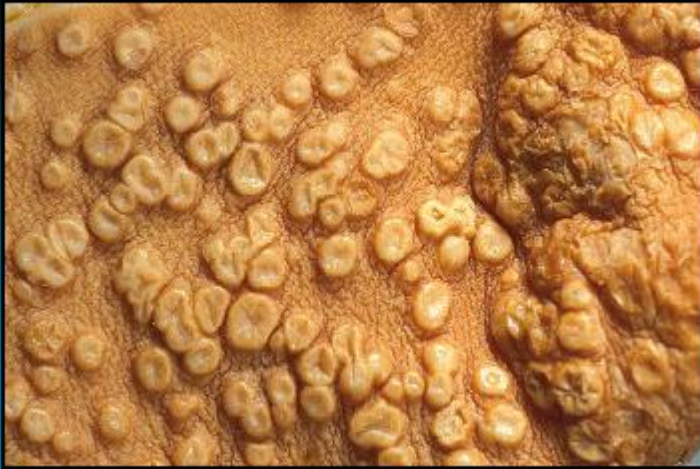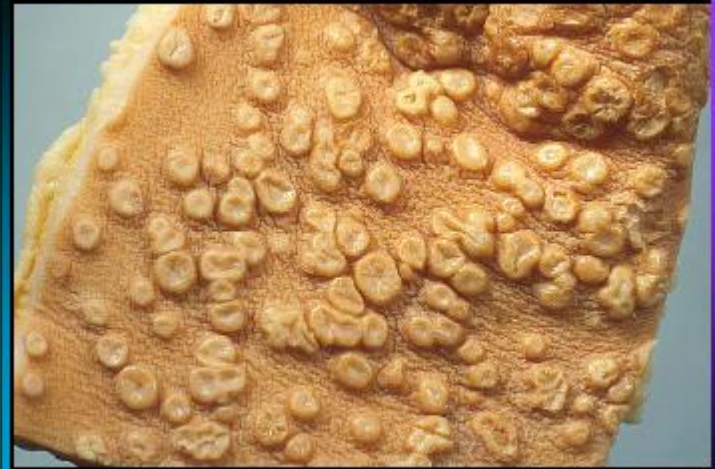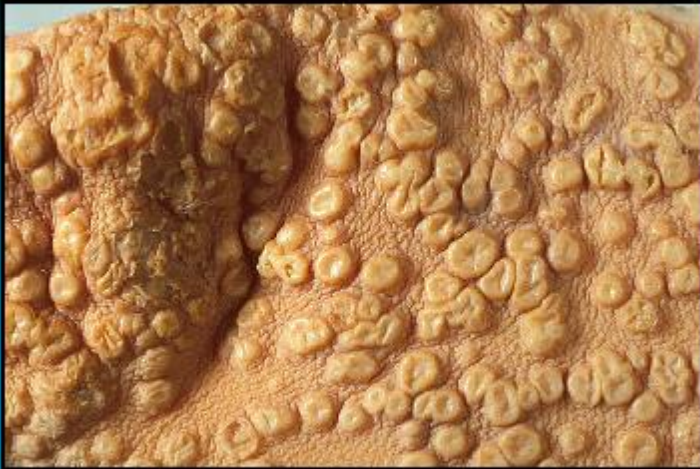Eritematöz makulopapular lezyonlar

Parapox bovis 2 (pseudocowpox) (bovine papular stomatitis) Milker's Nodes/Nodules

Evidence of zoonotic pseudocowpox virus infection from a cattle in Turkey.  
Oguzoglu ve ark. 2014







parapox

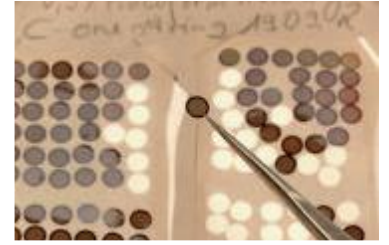
?

monkeypox

cowpox

# Teşhis

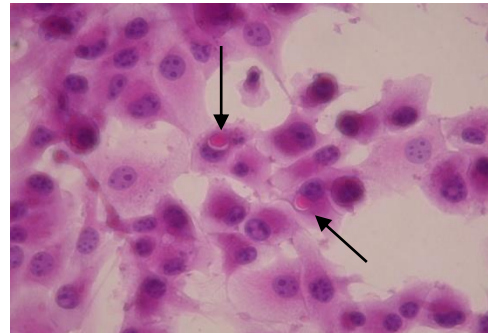
- Elektron mikroskopi
- Nükleik asit tespiti  
(PCR ve Sekans Analizi)
- Virus izolasyonu  
(CAM ve Hücre kültürü)



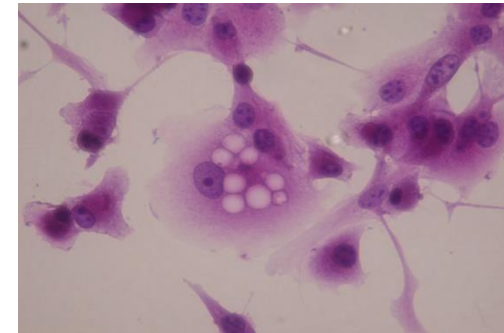
Orthopox virus

Parapoxvirus

A



B





# Kontrol ve Korunma

## Genel Kurallar

İthalatın kontrolü ve hızlı reaksiyon

Uygulamalı arařtırmalar

Salgınların kontrolü ve önlenmesi

Alt yapı

Günümüzde Poxviruslar-Rekombinant  
aşı vektörü

## Introduction

Viruses of the genus parapoxvirus from the family Poxviridae are comprised traditionally of orf virus (ORFV, ecthyma contagiosum), pseudocowpox virus (PCPV) and bovine papular stomatitis virus (BPSV), which infect ruminants, and zoonotic transmission is capable of causing cutaneous infections in humans worldwide. At the same time these infections may be classified as emerging diseases. The purpose of this study is to present information about the existence of parapoxvirus infections in Turkey in ruminants and in human. This study is originated from two studies that have already been published (Karakas et al., 2013, ArchVirol May;158(5):1105-8; Oguzoglu et al., 2014, VirusDisease, DOI:10.1007/s13337-014-0214-z) on presence of emerging zoonotic parapoxviruses in Turkey, and additionally contributed with molecular characterization based on sequence analysis of newly achieved parapoxvirus from a goat at seasonal outbreaks in 2014, Turkey.

## Materials and methods

Two previous reports, which have been reported in 2013 (Figure 1) and in 2014 (Figure 2), and the additional scap sample from one two months old Saanen goat kid, have created the materials of this study. In the goat herd, some Orfvirus-associated clinical signs have been described on the muzzle, lips, mouth and in the oral cavity of infected animals (Figure 3).

Molecular characterization methods in the cited studies have been used. Briefly, for the molecular characterization of Turkish parapoxviruses from a man, from a cattle and from a goat B2L gene region PCR products which have been purified using PCR cleanup kit from Sigma were used. They were sequenced by CEQ8000 sequencer (Beckman Coulter) and data were aligned by using BioEdit Program version 7.0.5.3 with ClustalW algorithm (Hall, 1999). The phylogenetic tree was established by using Mega 5.0. software program (Tamura et al., 2007).

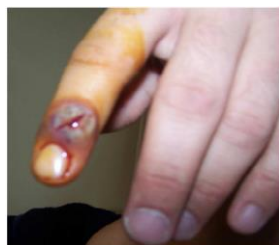

Figure 1. The specific lesion as scab material on the finger of infected man with parapoxvirus. Karakas et al. (2013) had been applied molecular characterization from this infected lesion sample.

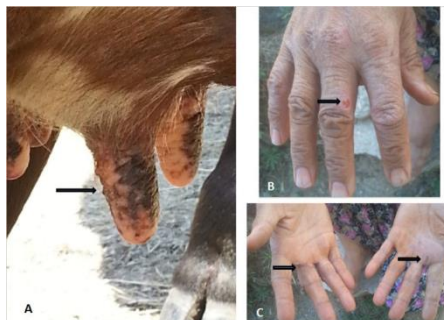

Figure 2. A. The nodular lesions on the udders and teats induced by PCPV. B and C. The similar lesions on the milkers' hands. (Oguzoglu et al., 2014.)

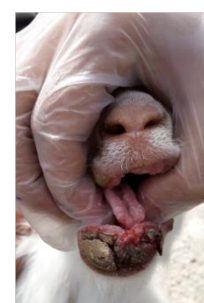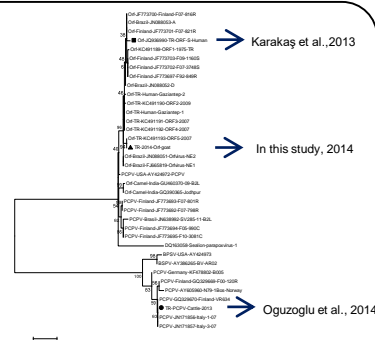


Figure 3. 2014 Ecthyma (Orf) outbreak in goat herd.

## Results

We have two studies about parapoxvirus infections in Turkey that were titled "First molecular characterization of a Turkish orf virus strain from a human based on a partial B2L sequence" and "Evidence of zoonotic pseudocowpox virus infection from a cattle in turkey". Molecular characterization results of two previous studies and newly achieved scab sample from an infected goat kid are evidences of the presence of parapoxvirus infections in Turkey in ruminants and human. Our results showed that zoonotic parapoxvirus infections are endemic among the different animal species (cattle and goat) in Turkey.

Phylogenetic tree is shown that all parapoxvirus sequences from Turkey have closed antigenic relationship with each other. Additionally, these results have been revealed that obtained viruses from last outbreak among small ruminant herds in Turkey in 2014 may be related to using vaccines.



## Discussion points

- Domestic ruminants infected with parapoxviruses provide the most likely source of human infections. Additionally, the current live vaccines also may be efficient on spreading of parapoxviruses which contaminates the environment in a manner similar to natural infection.
- The detection and characterization of the different parapoxviruses from different species are important for the control/eradication program (with vaccine) which will be evaluated in the future.
- Clinicians in hospitals with questions regarding the diagnosis of humans with a suspected parapoxvirus infection in Turkey should consider that it may be originated occupational or other contact with infected ruminants.
- Our opinion is that the eradication of parapoxvirus infections through to the vaccination of animals in order to avoid zoonotic transmission from infected animals to humans is necessary in Turkey.

## References

Hall TA (1999) BioEdit: Nucl. Acids. Symp. 41: 95-98; Karakas et al., 2013, ArchVirol May;158(5):1105-8; Oguzoglu et al., 2014, VirusDisease DOI:10.1007/s13337-014-0214-z; Tamura K, Dudley J, Nei M & Kumar S (2007) MEGA4: v.5.0. Molecular Biology and Evolution 24:1596-1599

\*T.Çiğdem Oğuzoğlu have a position in Turkish Academy of Science in the framework of young scientist award program (TUBA-GEBİP-2010).

•Information: coguzoglu@gmail.com; coguzoglu@ankara.edu.tr

## Kaynaklar

- Abei U and Pollard TD. A glow discharge unit to render electron microscopic grids and other surfaces hydrophilic. *Journal of Electron Microscopy Techniques*. 1987;7:29-33.
- Centers for Disease Control and Prevention. Smallpox.
- Gelderblom HR and Hazelton PR. Specimen collection for electron microscopy. *Emerging Infectious Diseases*.2000;6(4):433-434.
- Long GW, Nobel J, Murphy FA, Herrmann KL, and Lourie B. Experience with electron microscopy in the differential diagnosis of smallpox. *Applied Microbiology*. 1970;20(3):497-504.
- Miller SE. Bioterrorism and electron microscopic differentiation of poxviruses from herpesviruses: Dos and Don'ts. *Ultrastructural Pathology*. 2003;27:133-140.
- Nakano JH. Poxviruses. In Lennette EH and Schmidt NJ, editors. *Diagnostic Procedures for Viral, Rickettsial and Chlamydial Infections*, 5th ed. Washington, DC: American Public Health Association, 1979; 257-308.
- Essbauer et al. 2010, Zoonotic Poxviruses. *Veterinary Microbiology* 140 (2010) 229–236
- Joklik W (1966). BACTERIOLOGICAL REVIEWS, Mar., 1966 Vol. 30, No. 1
- Oguzoglu et al. 2006. A Sheep Poxvirus Outbreak in Central Turkey in 2003: Isolation and Identification of Capripoxvirus ovis. *Vet Res Com*. 30, 965-971.
- Oguzoglu et al.(2014). Evidence of zoonotic pseudocowpox virus infection from a cattle in turkey. *VirusDisease*, DOI: 10.1007/s13337-014-0214-z, Volume 25, Issue 3 (2014), Page 381-384
- Oguzoglu TC ve ark. 2014. Parapoxvirus infections in Turkey. International Meeting on Emerging Diseases and Surveillance. 31.10-3.11.2014, Vienna-Austria
- Toplu et al. (2007). Visceral Leishmaniosis and Parapoxvirus Infection in a Mediterranean Monk Seal. *J Comp Pathol* 136, 283-287.
- Karakaş ve ark. 2013. First Molecular Characterization of the Turkish Orf Virus Strain from a Human based on a Partial B2L Sequence. *Archives of Virology* DOI: 10.1007/s00705-012-1575-5, 158:1105–1108