

Postmortal

Coagulatio

Sanguis

Postmortem autolysis result from the degradation of tissues associated with the release of proteolytic lysosomal enzymes from tissue cells when they die, as well as from the action of postmortem bacterial enzymes (**putrefaction**). Bacteria that form part of the normal microbial flora in the intestine proliferate soon after death. Invasion of organs and tissue occurs primarily through the vessels and lymphatics.

Postmortem autolysis can be slowed by decreasing the animal's temperature via refrigeration soon after death. Since most lysosomal enzymes and bacterial enzymes are temperature dependent, lower temperatures slow (but does 'not completely stop) the degradation of the tissues. Lower temperature also inhibits bacterial growth. Freezing is not, however, recommended because the ice crystals which form damage cells and can make this histopath difficult to interpret.' Still, if the necropsy must be delayed a week or more, freezing is recommended since the continued degradation of tissue refrigerated longer than would have even more harmful consequences.

Clotting enzyme is not enough to clot blood in all vessels after death.

Blood coagulates more often in medium diameter vessels; in capillary vessels, it remains uncoagulated.

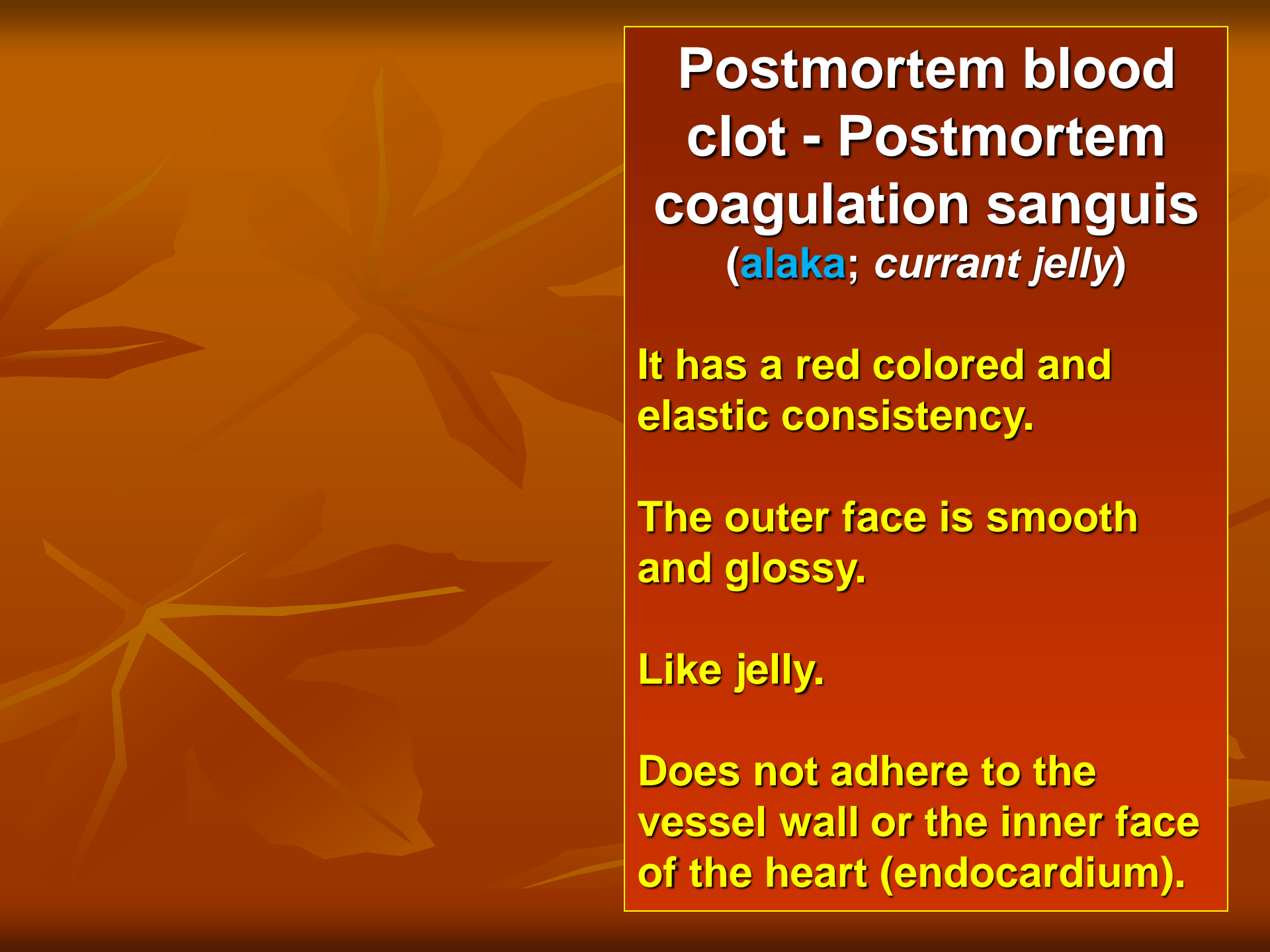
In the long-lasting agony, the stasis of blood begins before death.

Postmortem clots (occur in cardiac chambers after death)

There are two types:

1- Chicken Fat Clot

2-Red or Currant Jelly Clot



**Postmortem blood
clot - Postmortem
coagulation sanguis
(*alaka*; *currant jelly*)**

**It has a red colored and
elastic consistency.**

**The outer face is smooth
and glossy.**

Like jelly.

**Does not adhere to the
vessel wall or the inner face
of the heart (endocardium).**

Red or Currant Jelly Clot

- ❖ Occur when the components of the blood are evenly distributed through out the clot.
- ❖ This type develops when there is rapid clotting of blood.
- ❖ Formed of fibrin, red and white blood cells.

Chicken Fat Clot

- result from a settling and separation of erythrocytes from the fluid phase of the blood.
- Such clots occur when postmortem clotting is delayed
- which allow sedimentation of red cells with plasma, fibrin and white cells above.

In some cases it collapses by showing blood stratification. the clot becomes stratified.

Erythrocytes are collected at the bottom.

Leukocytes, fibrin and liquid part of the blood are collected in the upper part.

It forms a layer in yellowish, transparent appearance, elastic consistency.

Chicken fat clot:

Formed due to settling and separation of RBC from the plasma and seen in heart chambers of the horse.

Gross :- 1- smooth and shiny surface

2- yellow color of plasma

3- not attached to the endocardium.

Causes:- coagulation process that is initiated by release of tissue thromboplastin from degeneration of capillary endothelium that occur after death .

It is normal because the sedimentation rate in **horses** is **high**.

But;

Other animals;

- In prolonged agony,
- Some anemia and
- some infections that increase the sedimentation rate.

Postmortem blood clot sometimes occurs more quickly than usual. Their consistency is harder.

Reason;

is increased neutrophil leukocytes in the circulation.

Purulent inflammations, especially pyemi are found on the basis of such events

In some diseases, the blood does not coagulate well.

1- Septicemic Diseases/Septicemia

Notedly; anthrax

2- Acute or chronic liver diseases

3- Vitamin K deficiency

4- Icterus → Because calcium ions is bound with bile in icterus, so the blood does not clot.

**5-Poisonings with Hedysarum
cappadocicum (tatlı tırfıl) and
Mellilotus albus (tatlı yonca, ak taş
veya Buhara yoncası,)**

**Coagulation is
prevented due to
dicumarol (coumarin)
found in the structure of
the plant.**

▪

**6- 'Dicumarol'
and "Warfarin"
Poisoning in
dogs**

7-The addition of oxalate, sodium citrate and heparin into the blood disrupts coagulation.

8-Some neoplastic diseases → especially in mastocytomas.

9- Disease of hemophilia →

Hemophilia is an inherited disorder involving a deficiency of the clotting activity in the blood and is more commonly seen in **dogs (puppies)** and occurs more often in the males.

**What is the difference
between antemortem and
post mortem clot?**

thrombus

- adherent to wall, propagates centrally from this point
- laminated



post-mortem clot

- not adherent to vessel wall
- often separates into red cells and plasma ("currant jelly" / "chicken fat")



	THROMBUS	POSTMORTEM CLOT
CONSISTENCY	Dry and Friable	Moist and Jelly-like
SURFACE	Granular and rough	Smooth and glistening
COLOR	White or Buff	Intense red or yellow
ATTACHMENT	Attached to vessel wall	Not attached to vessel wall
ENDOTHELIUM	Damaged/injured	Undamaged
COMPOSITION	Platelets primarily	Fibrin Primarily
RAPIDITY OF BLOOD FLOW	Formed in flowing stream of blood	Formed in stagnant column of blood
ANIMAL	Formed in living animal	Formed in dead animal
ORGANIZATION	May be partially organized	No organization