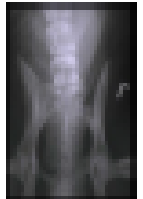


LSS

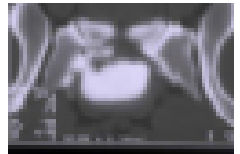- Lumbosacral transitional vertebral segment

(Flückiger et al. VSRU 2006; Steffen et al. JAAHA, 2004)




- Osteochondrosis of sacral endplate (GSD)

Lang et al. VRSU 1992; Ondreka et al. Vet J, 2013)

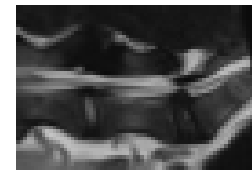


- Lumbosacral step (GSD)

- Ondreka et al. Vet J, 2013

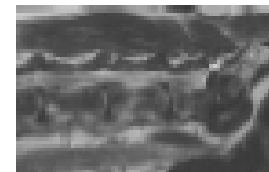


- Primary stenosis (GSD) Ondreka et al. Vet J, 2013



- Disseminated skeletal/spinal hyperostosis Togni et al,

JSAP 2014, De Decker et al. Vet Rec, 2014



Klinik Görünüm:

Bilinç duyu iletimi kaybı

Paraparezis

Kuyruk felci

Üriner ve fekal inkontinens

(AMN)

Tanı :

Klinik muayene

Radyolojik Muayene

Sağaltım : Operasyon