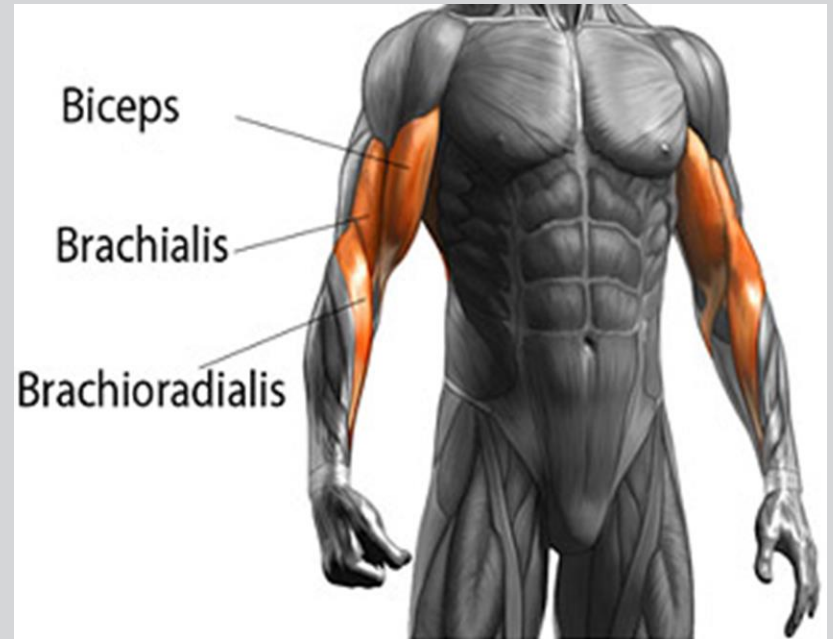
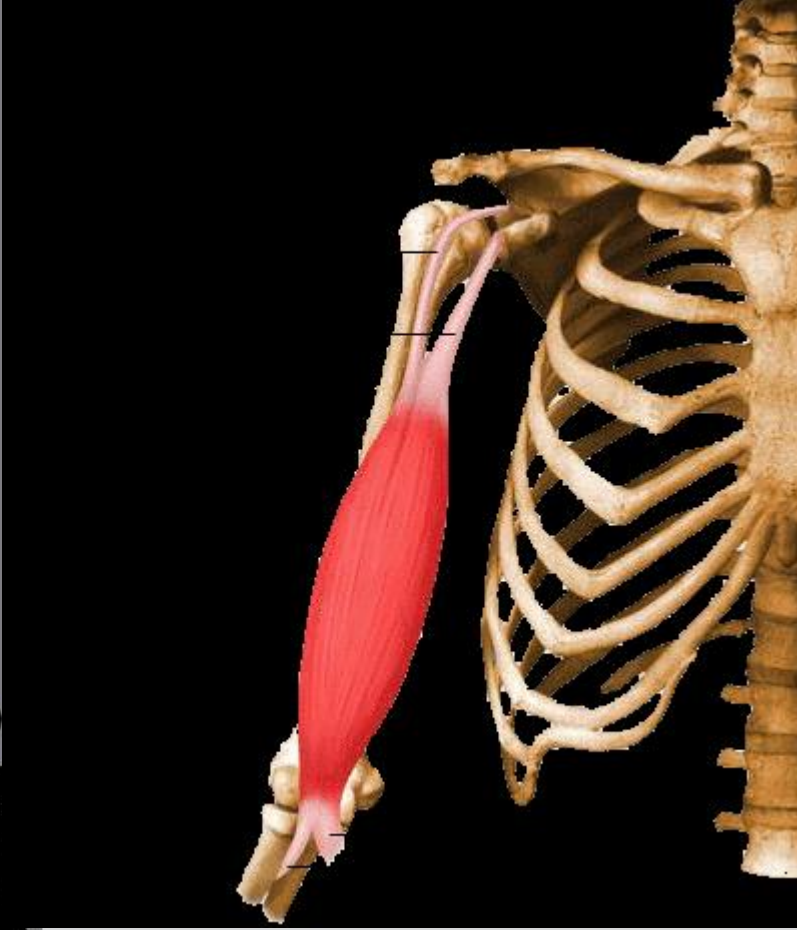

# AKTİF HAREKET SİSTEMİ

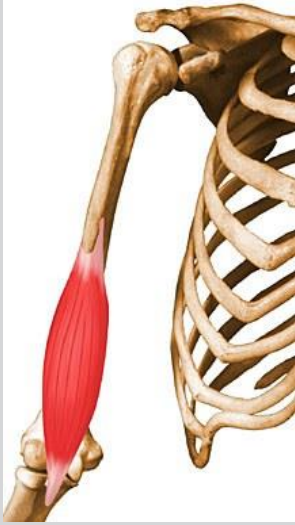

# Biceps Bracii



- O: Uzun Baş.scapula supraglenoid tuberculum
- Kısa baş: scapula coracoid process
- I: radial tuberosity ve on kolun fasiasına
- F: subinasyon ve subinasyondayken fleksiyon

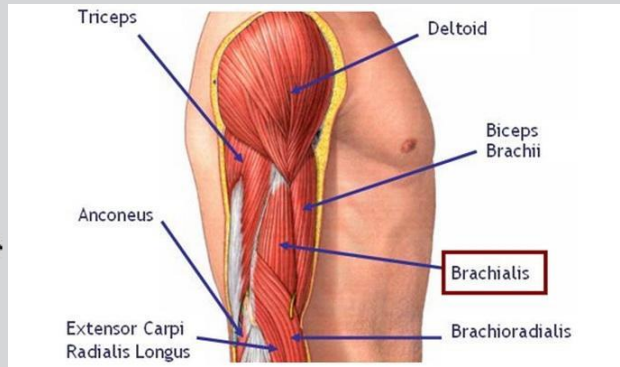
# Bracialis



O: humerusun distal yarısı  
ve ön yuzu

I: ulnanın coronoid processsi  
ve tuberesitiy.

F: ön kolun major fleksoru



# Brachioradialis

- O: Humerus
- I: Radius
- F: Bileğin flexsiyonu

## Muscles of the Elbow and Forearm

### *Brachioradialis*

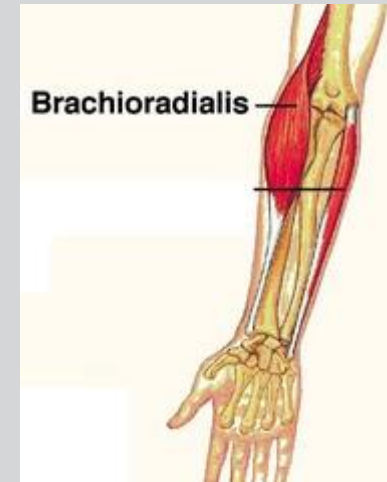
*Origin:* Lateral supracondylar ridge on the humerus

*Insertion:* Styloid process of radius

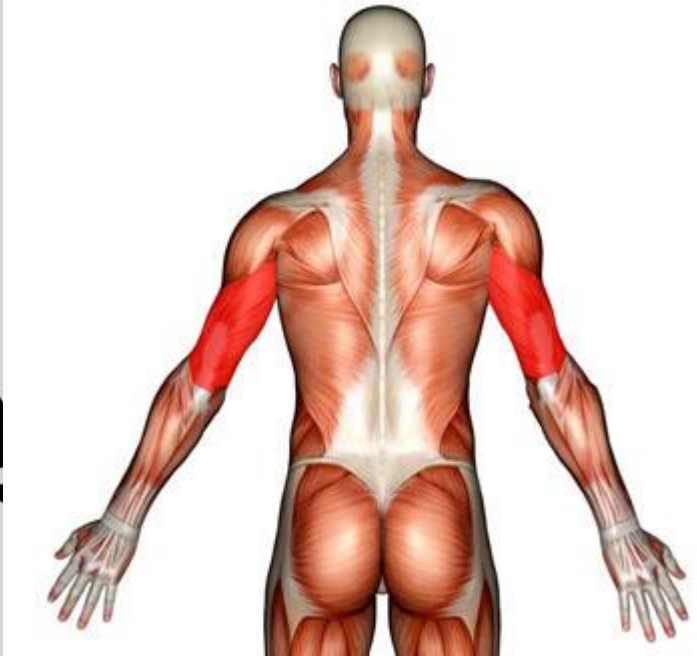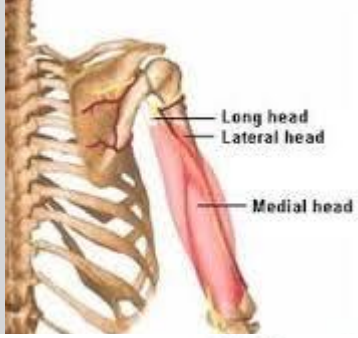
*Action:* Elbow flexion

*Innervation:* Radial nerve

*Vascular supply:* Radial artery



# Ticeps Bracii



O:

uzun baş:scapula (infraglenoid tubercule)

Orta baş: humerusun arka yüzü

Lateral baş. humerusun arka yüzü

I: Ulna olecronan process

F: ön kolun ektansiyonu