

---

# ULTRASONOGRAPHY OF THE UROGENITAL TRACT



Panagiotis Mantis

DVM, DipECVDI, FHEA, MRCVS

---

# URINARY TRACT

- 
- Indications
  - Scanning technique
  - Normal appearance
  - Alterations from normal

## Indications

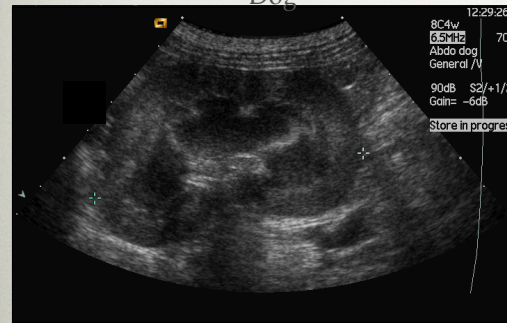
---

- |                       |                        |
|-----------------------|------------------------|
| Serum biochemistry    | • Hypoplasia / aplasia |
| Physical findings     | • Nephritis            |
| Species / age related | • End-stage Kidneys    |
|                       | • Renal cysts          |
| Radiographic findings | • Hydronephrosis       |
|                       | • Trauma               |
|                       | • Neoplasia            |

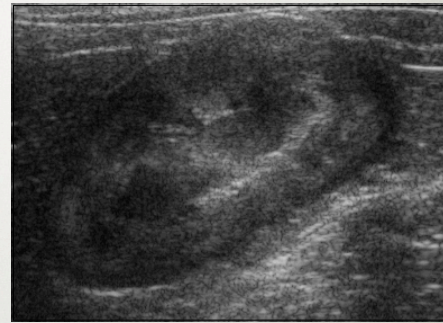

# KIDNEYS

Dog



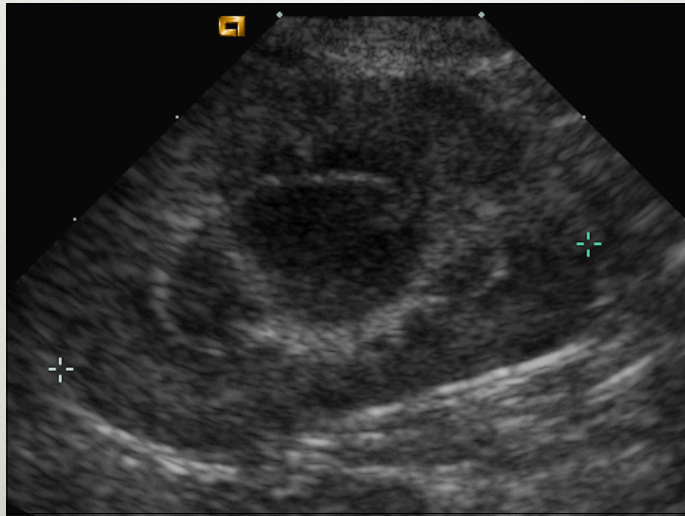
Cat

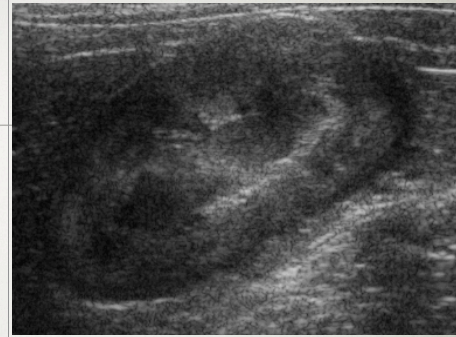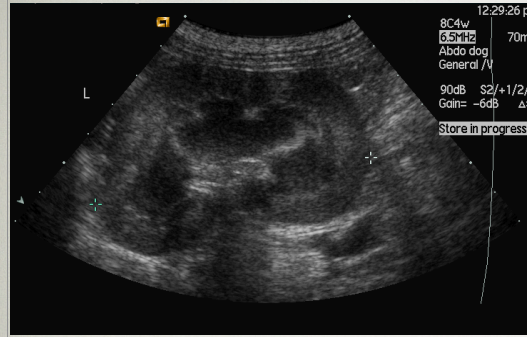


- Hyperechoic cortex and hypoechoic medulla.
- Renal cortex hypoechoic to the spleen.
- Renal cortex usually hyper-, hypo- or iso-echoic to the

## MEDULLARY RIM SIGN

---





Renal size  
Very variable in the dog

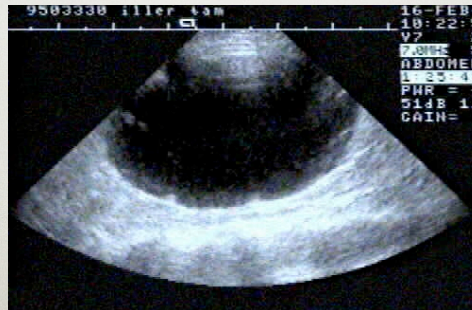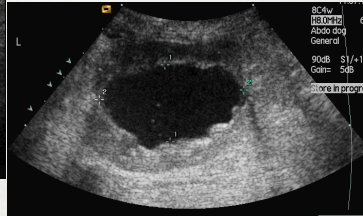
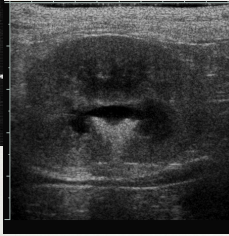
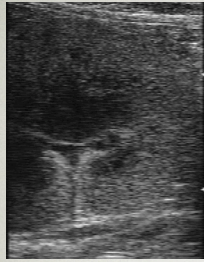5Kg	4.4 cm
10 Kg	5.6 cm
30 Kg	7.2 cm
50 Kg	9.1 cm

From FJ Barr

Cat renal length = 3.8 to 4.4 cm

# Alterations in the renal pelvis

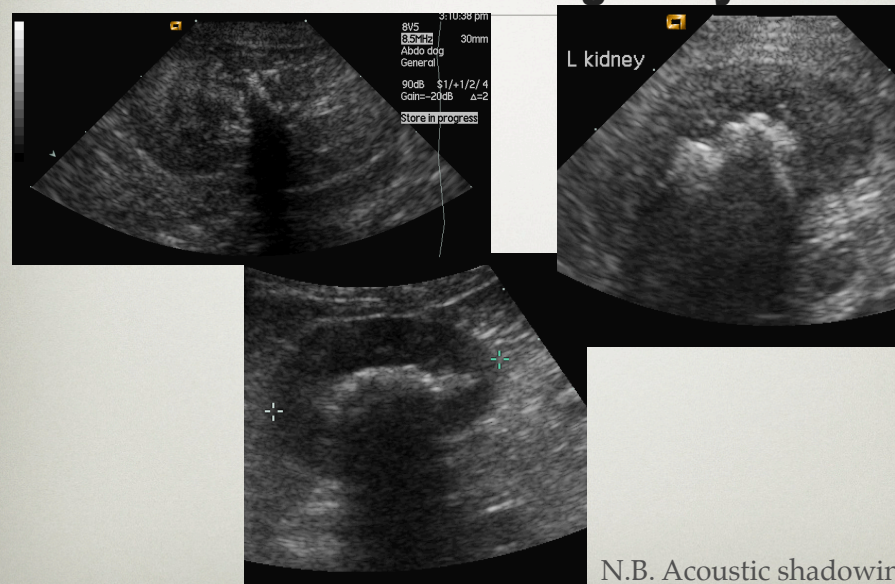
## Dilatation- fluid filling



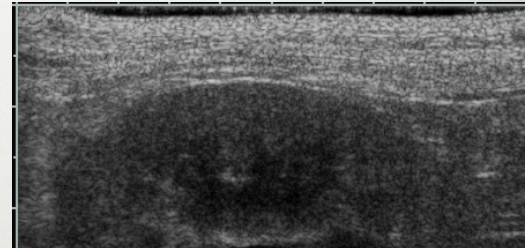
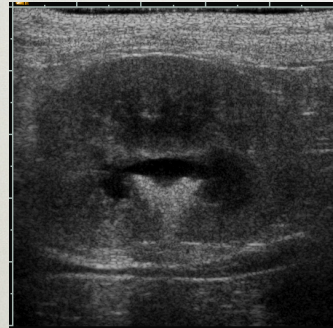
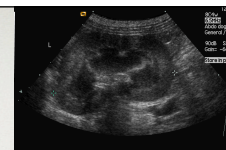


# Alterations in the renal pelvis

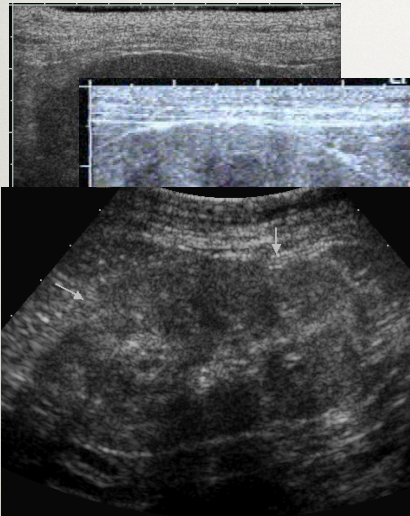
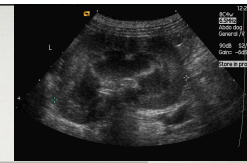
## Increased echogenicity



**Alterations in renal  
parenchyma  
Increased echogenicity**



**Alterations in renal  
parenchyma  
Increased echogenicity**



Chronic inflammatory  
disease processes

Chronic pyelonephritis

End stage renal disease

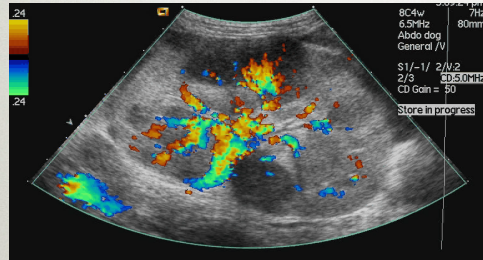
## FOCAL ALTERATIONS IN RENAL PARENCHYMA

---

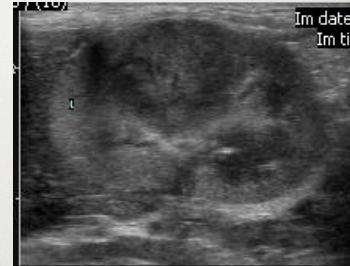- Renal tumours
- Renal infarcts
- Renal abscesses
- Renal cysts
- Renal haematomas



# RENAL TUMOURS

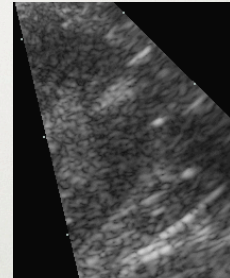
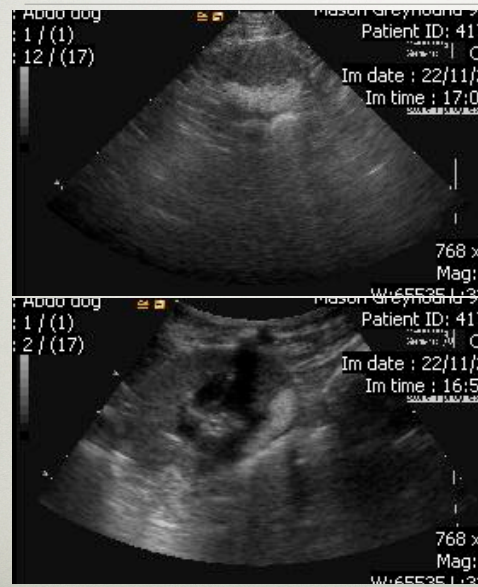


Lymphoma



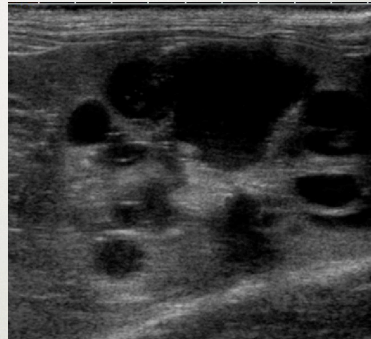
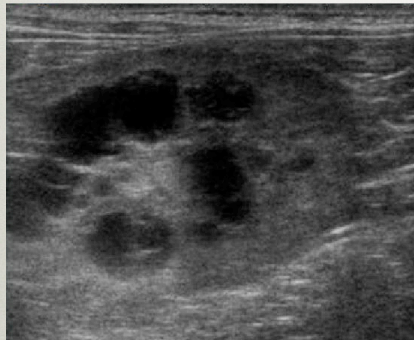Carcinoma

# RENAL INFARCT

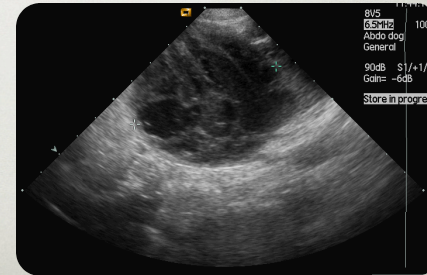
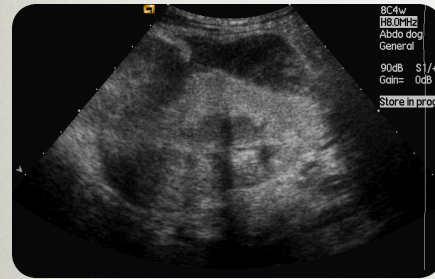


## RENAL CYSTS

---



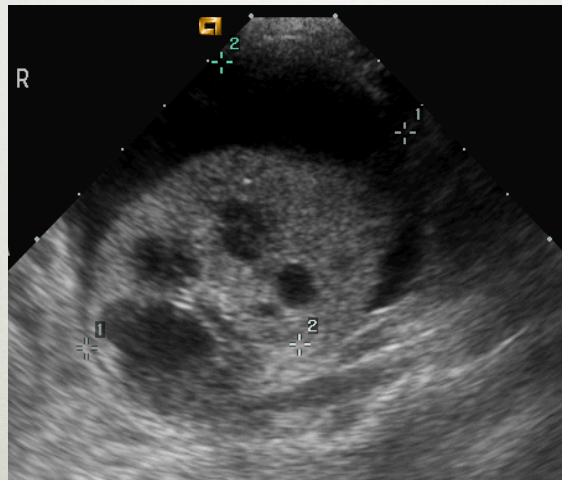
# RENAL HAEMATOMA





# PERINEPHRIC PSUDOCYST

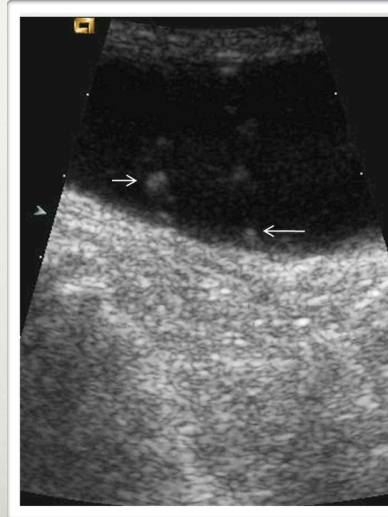
---



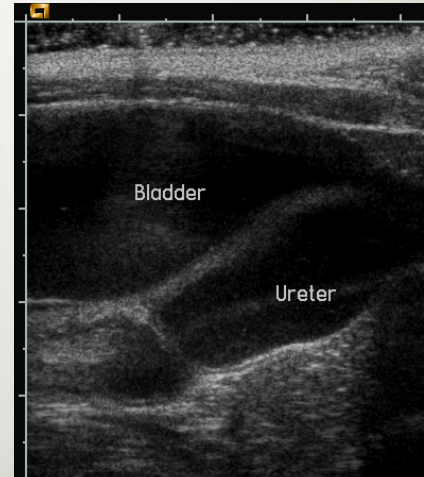
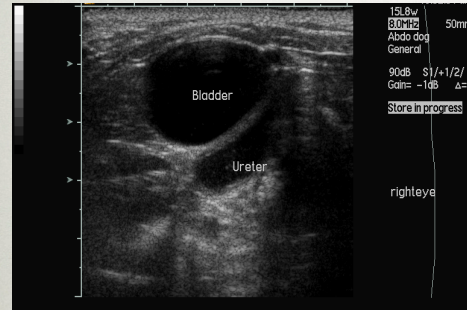
## URETERS

---

- Not normally seen
- Readily identified at least in part if dilated
- Ureteral jets can be seen

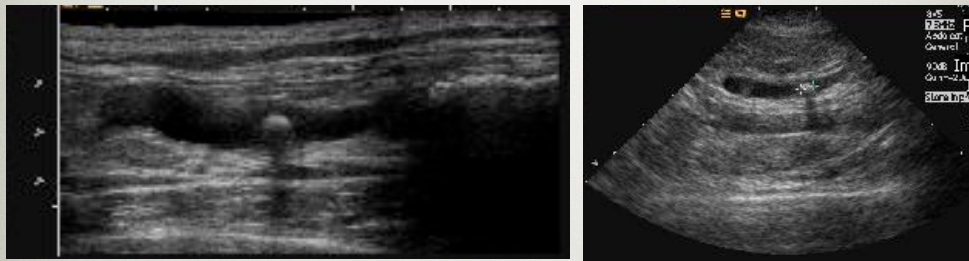


# ECTOPIC URETERS



# URETERAL CALCULI

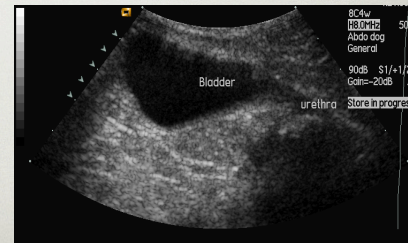
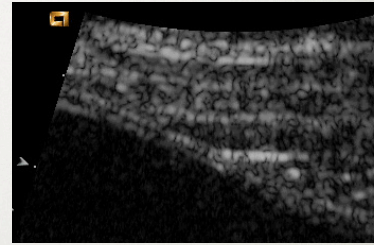
---



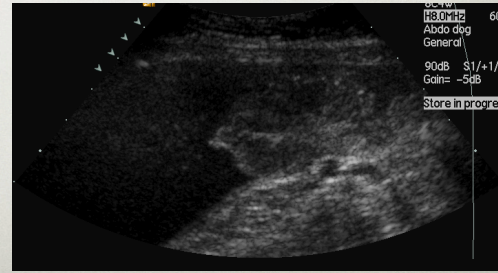
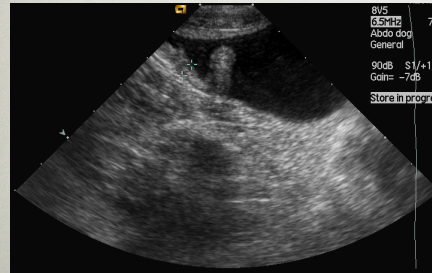
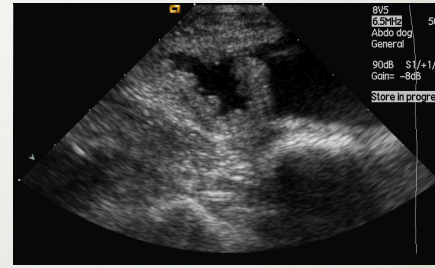
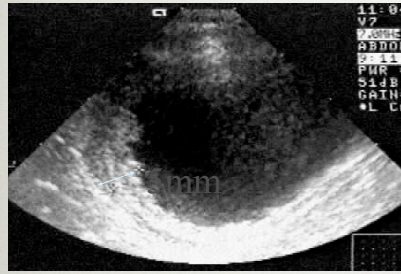


# URINARY BLADDER

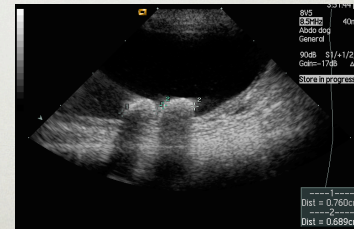
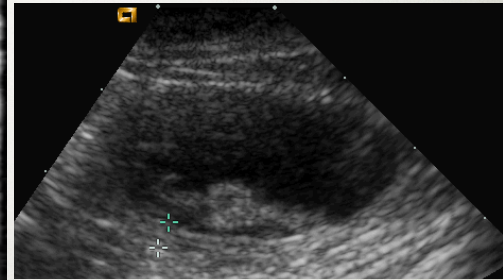
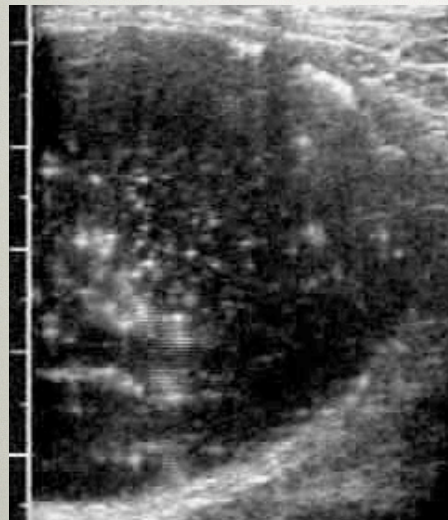
- View part filled
- Wall thickness 2mm
- Hypoechoic mucosa
- Hyperechoic sub mucosa
- Hypoechoic/mixed muscular layer
- Hyperechoic serosal surface



# DIFFUSE/ FOCAL THICKENING



# ALTERATIONS IN URINE



# REPRODUCTIVE TRACT



## INDICATIONS

---

- Pregnancy
- Evaluation of foetus
- Pyometra/ mucometra/haemometra/ hydrometra
- Endocrine abnormality
- Dysuria
- Haematuria
- Bloody discharges
- Painful defecation
- Locomotor problems

## CANINE OVARIES

---

- Found by their relationship to the kidneys
- May touch or be up to 2 cm caudal

# CANINE OVARIES

---

**Anestrus** May be very difficult to find

**Proestrus**

Oval (1.5cm) echogenicity of renal cortex

Follicles appear 2-7 days after onset

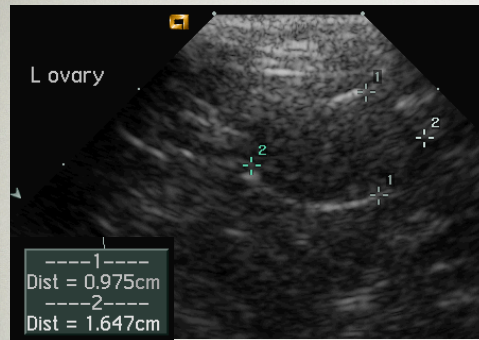
Start small, range from 0.3 to 1.2 cm  
before ovulation

**Oestrus**

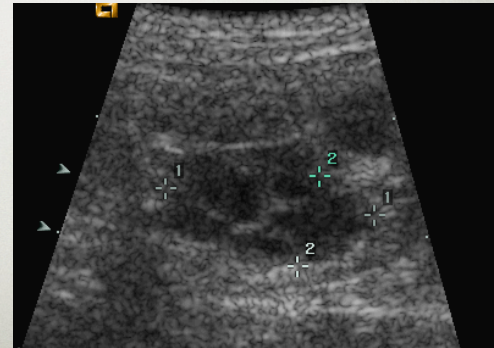
Follicles reduce in number but some may normally develop  
to cysts (2.5 cm)

**Metestrus**

Development of corpora lutea



Proestrus  
Early estrous





# UTERUS

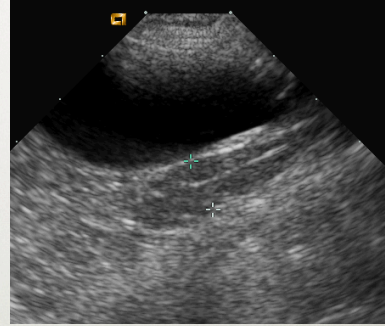
---

- Non-pregnant difficult to see.
- Easier if:
  - Older animal
  - Previous pregnancy
- During oestrus it becomes enlarged and hypoechoic

# UTERUS

---

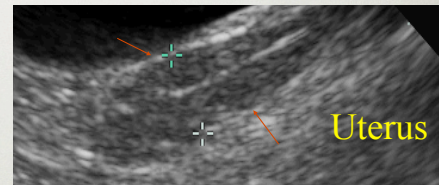
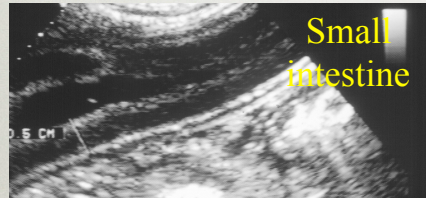
Best seen dorsal to a fluid filled urinary bladder



## UTERUS VS BOWEL

---

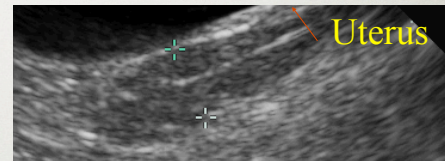
- Different layering
- Peristalsis
- Gas/fluid content



# UTERUS

---

- Uterine wall becomes increasingly hypoechoic during proestrus and estrus

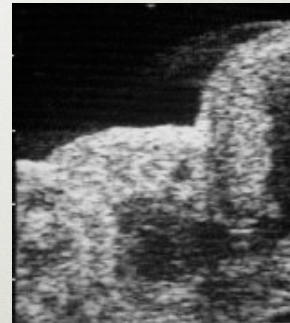
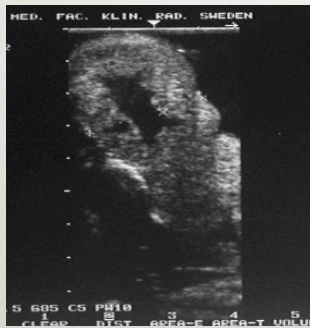
- Small amount of fluid may be seen in the uterus during estrus.

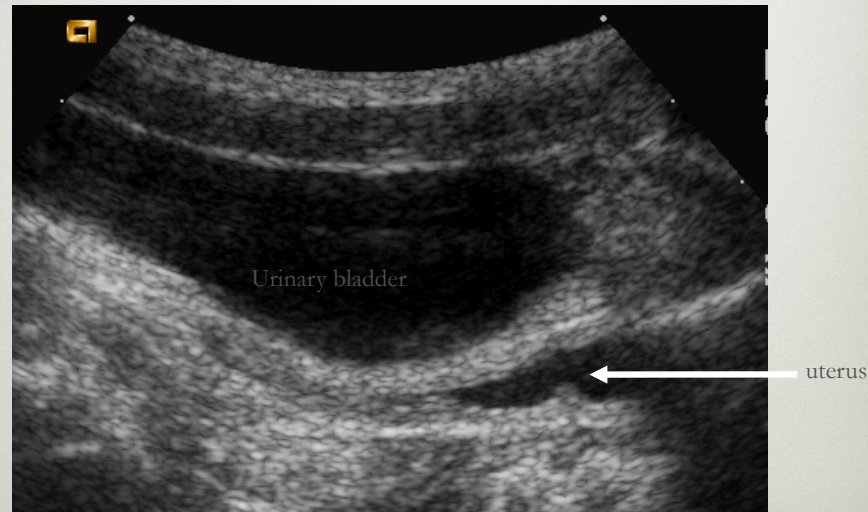


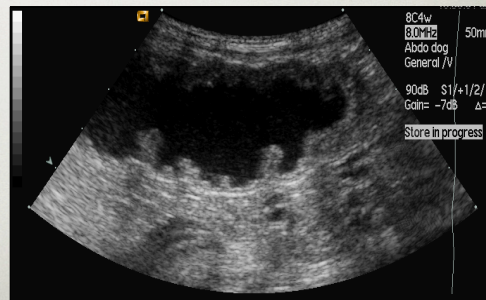
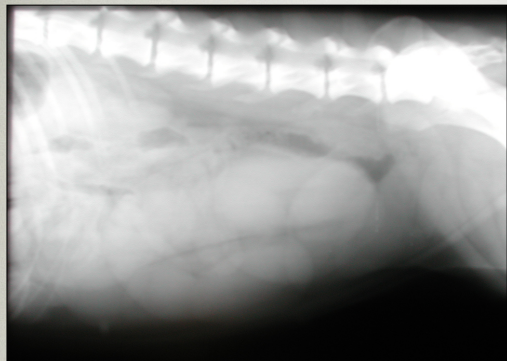
## UTERINE WALL THICKNESS

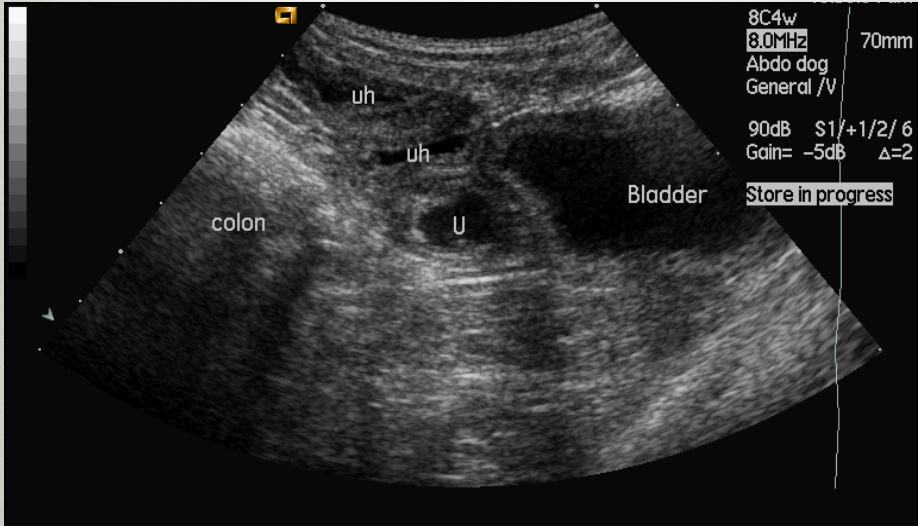
- Increased wall thickness
- Small cystic zones



## FLUID WITHIN THE UTERINE LUMEN









## FLUID IN UTERUS

---

**Endometritis/Pyometra**

anechoic to echoic

uterine wall changes

clinical signs

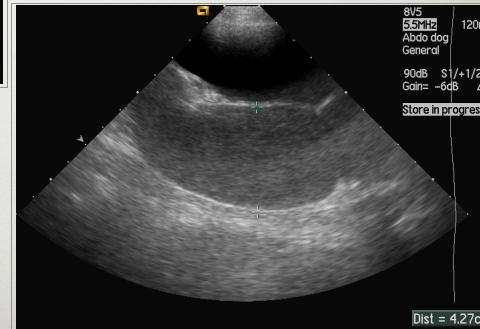
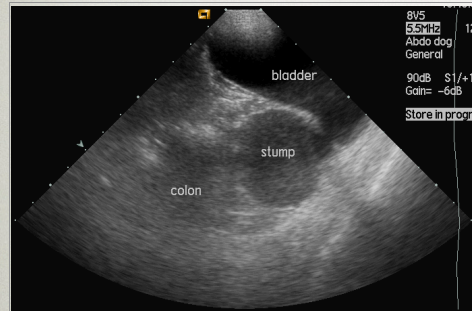
**Hydrometra**

usually anechoic

**Mucometra**

usually echogenic  
material/foci

# STUMP PYOMETRA



## **PREGNANCY**

---

First detectable 15 to 21 days after first breeding

Sensitivity for pregnancy detection is high

Accuracy in predicting litter size is poor

Foetal viability heart rate < twice maternal –  
distress

Gestation

Gestational age

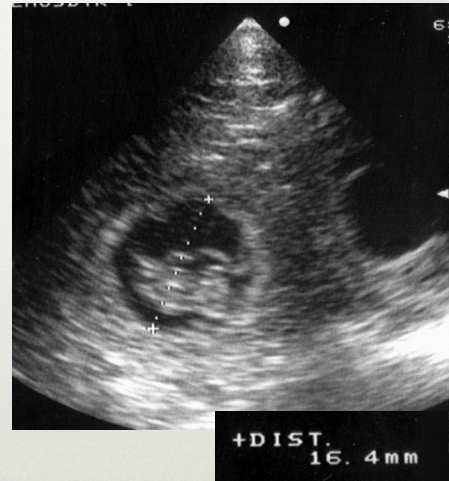
$$= (6 \times 1.6) + 20$$

$$= 9.6 + 20$$

= 30 days approx.

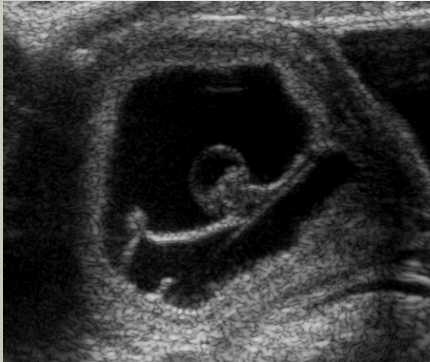Days to parturition

$$65 - 30 = 35$$

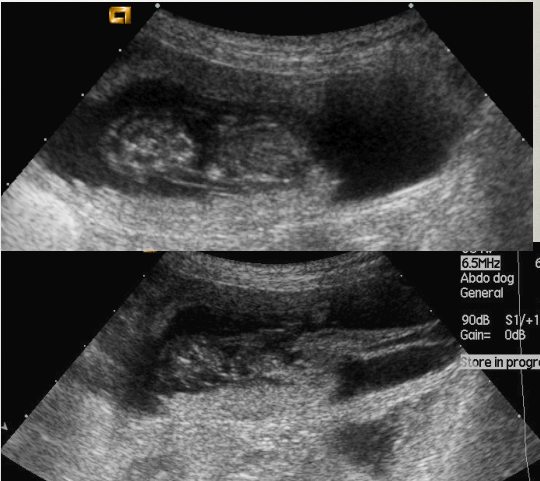



# PREGNANCY



Cat 3 weeks pregnancy

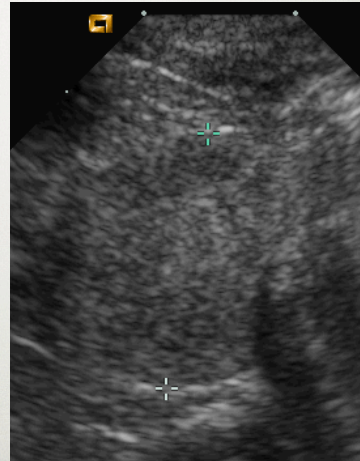


Dog 5 weeks pregnancy

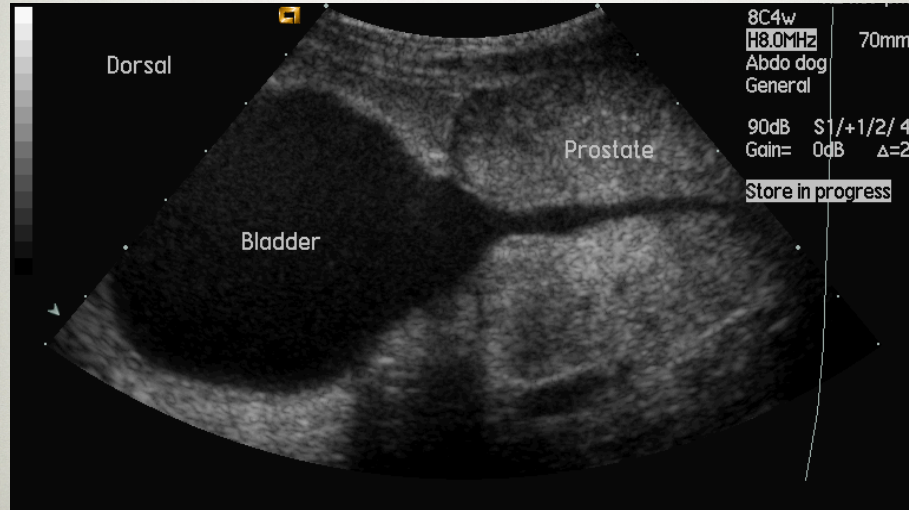
# PROSTATE

---

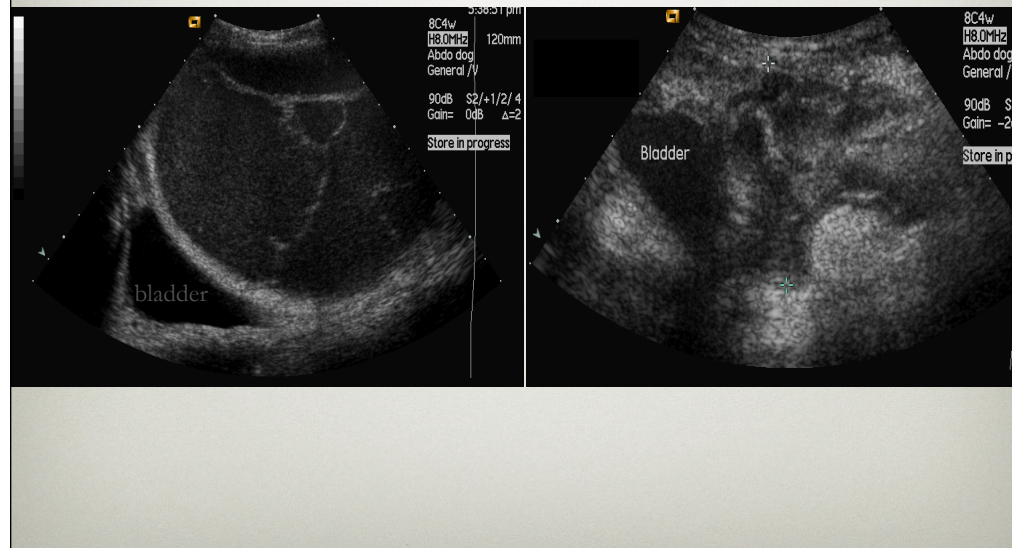
- Ovoid
- Smooth well defined margins
- Uniform, coarse echotexture
- Slightly hyperechoic to surrounding tissue
- Size can be evaluated however more commonly is measured on abdominal radiographs.



# PROSTATOMEGALY

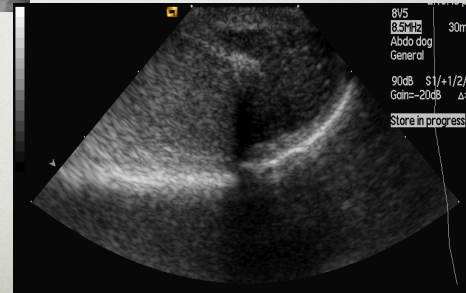
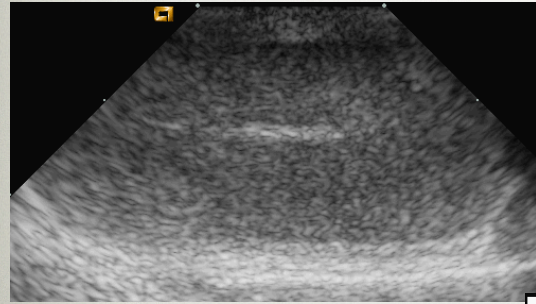


# PARAPROSTATIC CYSTS



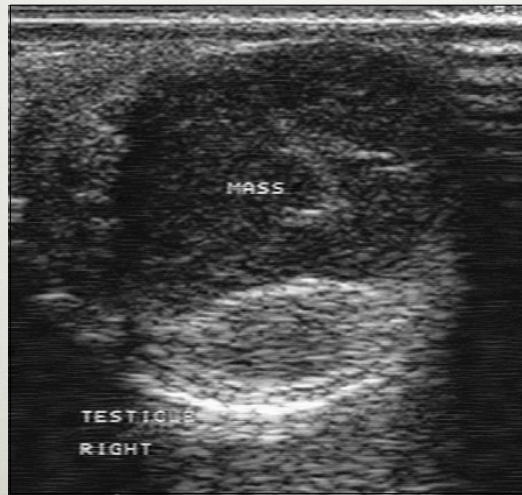


# TESTES

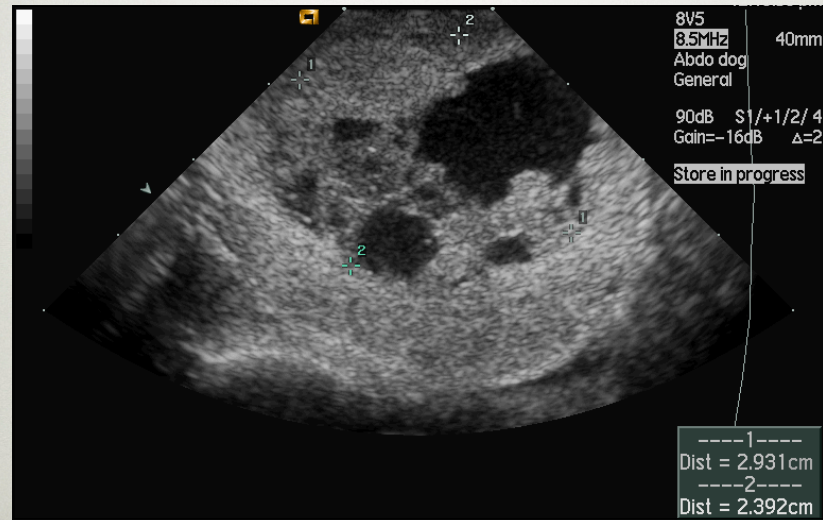


# TESTICULAR MASS

---



# TESTICULAR NEOPLASIA



## RETAINED TESTICLE

