






Surgery of the Cardiovascular System



Dr. Pinar CAN

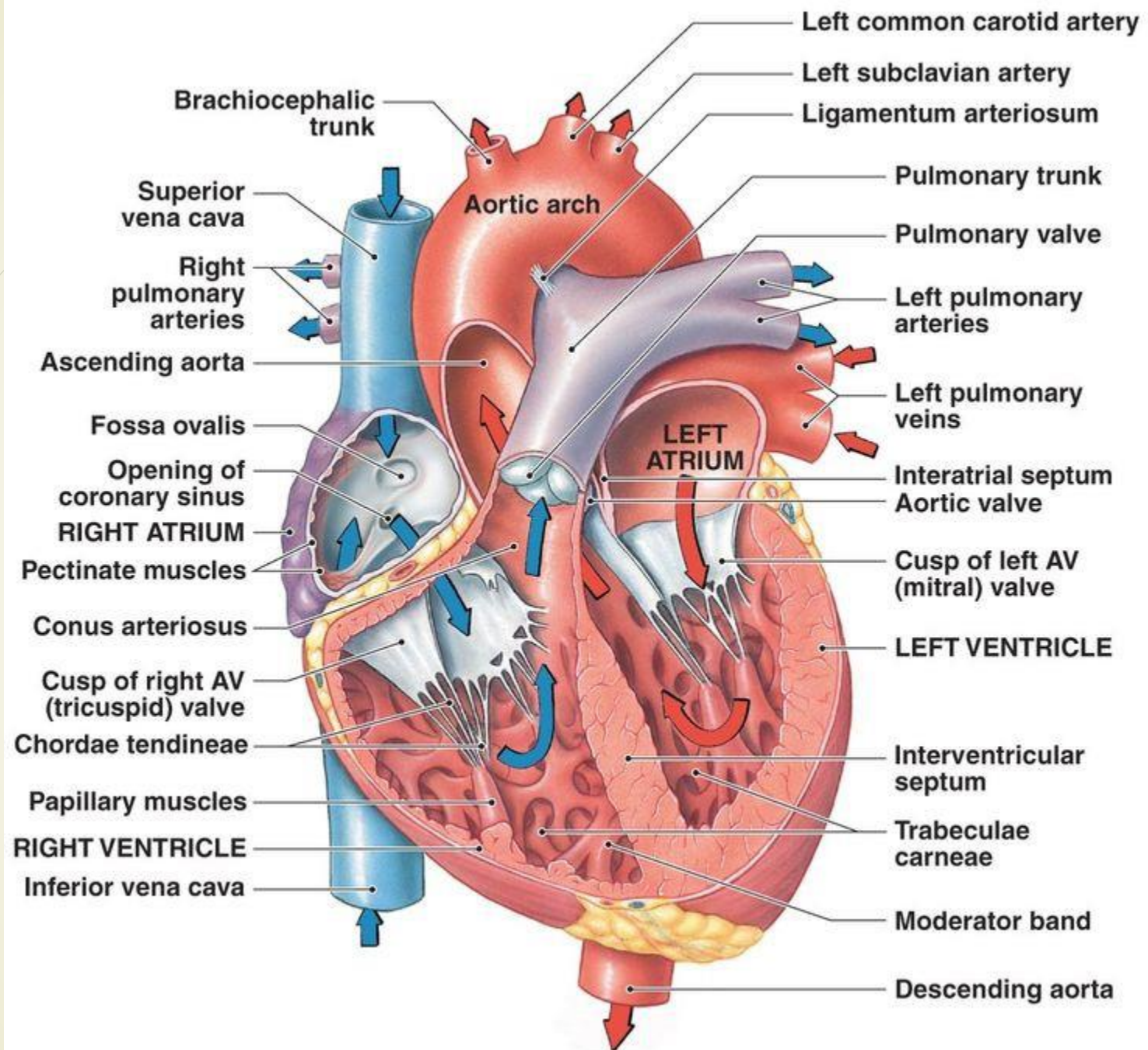


Anatomy

- ▶ The right atrium and left atrium are divided by an atrial septum and receive blood from the systemic and pulmonary venous circulations, respectively.
 - ▶ Blood is carried from the systemic circulation to the right atrium by the cranial and caudal vena cavae.
- 

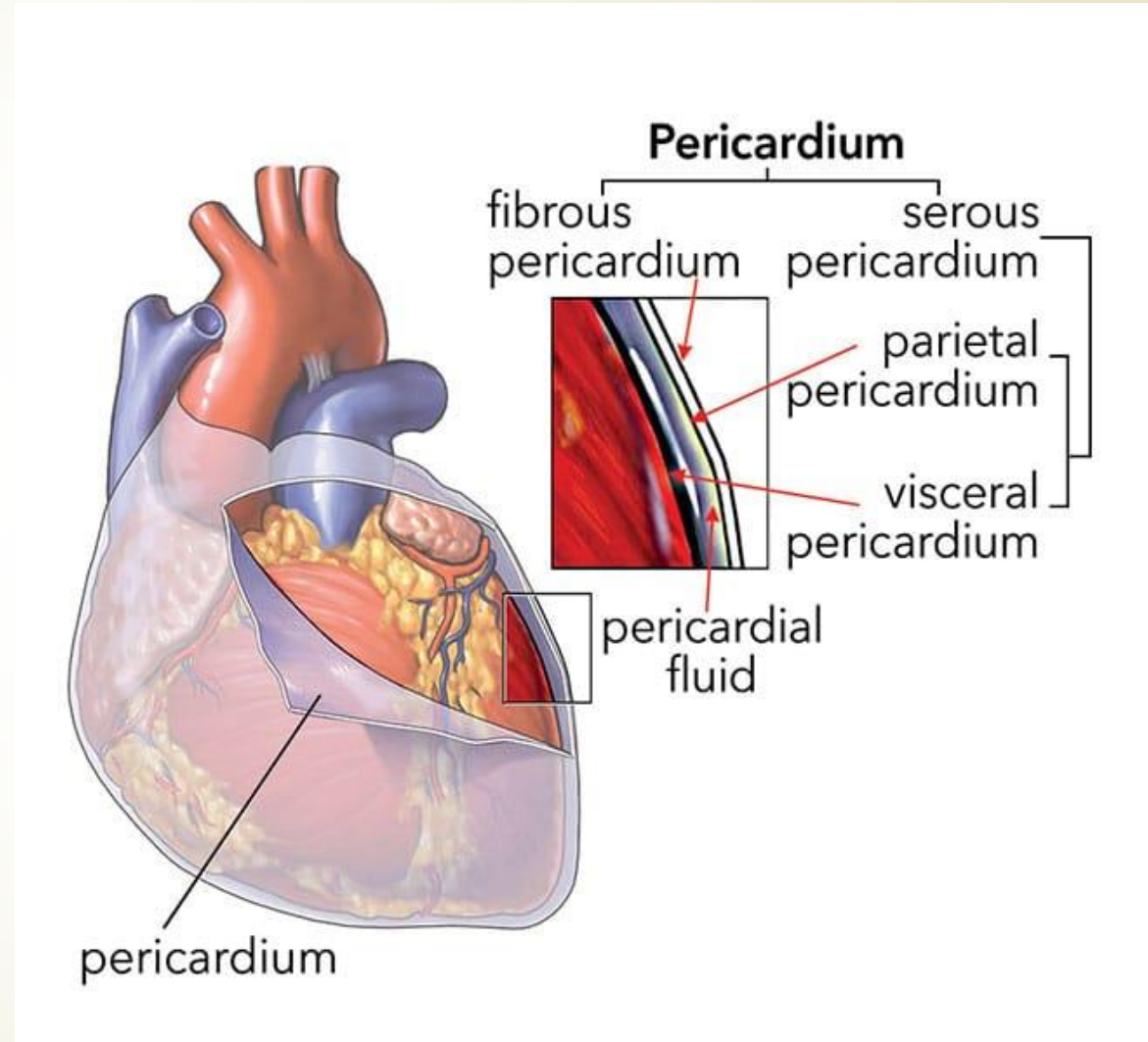
- 
- 
- ▶ Blood is carried to the left atrium by multiple pulmonary veins located on the dorsal aspect of the heart.
 - ▶ Blood flows from the right and left atrium into their respective ventricles through the right atrioventricular (tricuspid) and left atrioventricular (mitral) valves

- 
- 
- The right ventricle pumps blood to the pulmonary arterial circulation via the main pulmonary artery or trunk.
 - The pulmonic (pulmonary) valve is situated between the right ventricle and main pulmonary artery.
 - The left ventricle pumps blood to the systemic arterial circulation via the aorta.
 - The aortic valve is located between the left ventricle and aorta.




(a) Frontal section through the heart


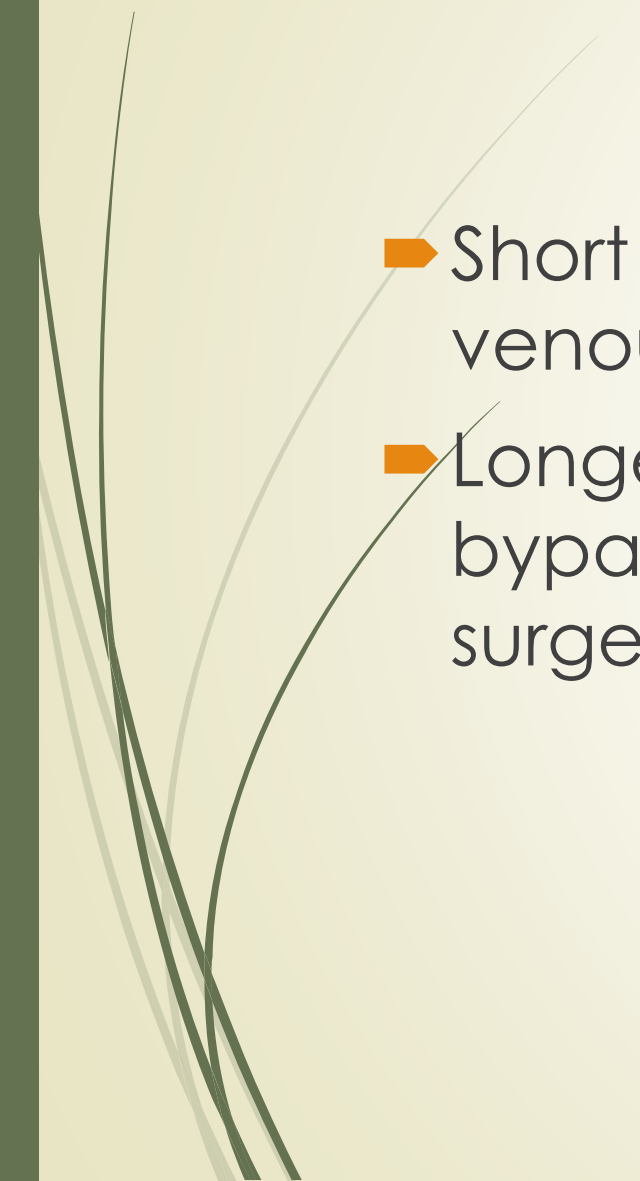
- ▶ The pericardium is a thick, two-layer sac composed of outer fibrous and inner serous layers.
- ▶ The pericardial cavity is located between two layers (visceral and parietal) of serous pericardium and normally contains a small amount of fluid.






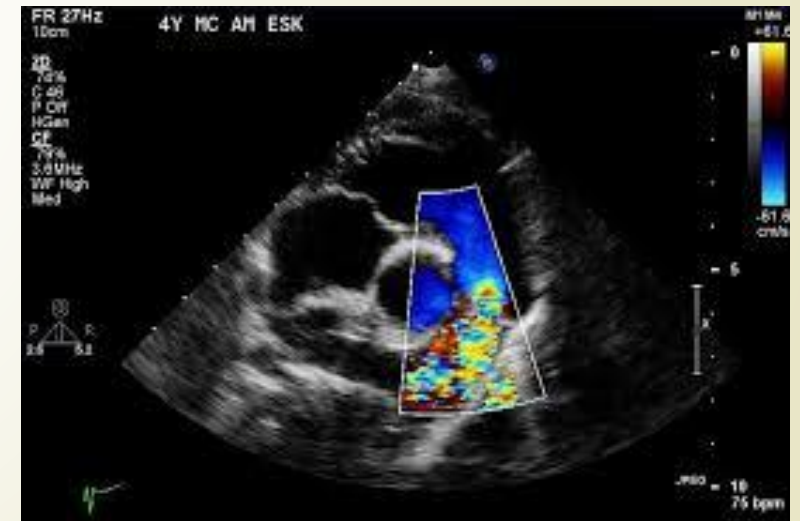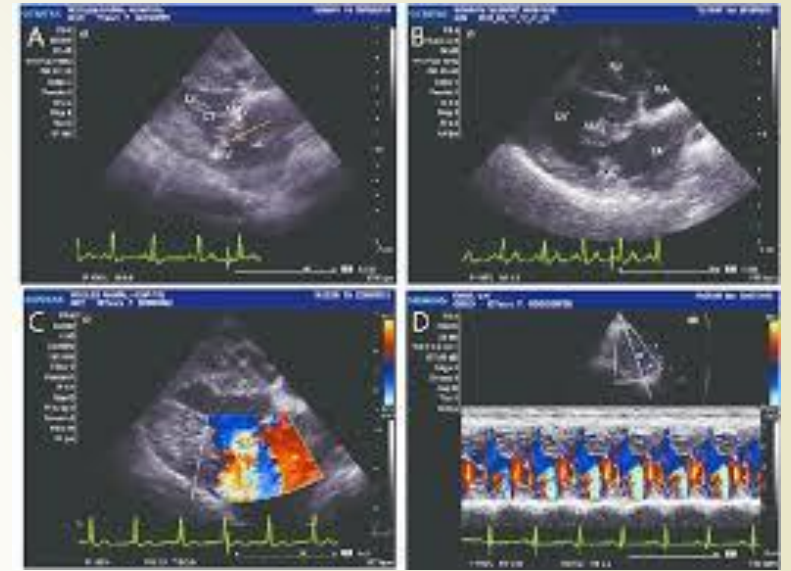PREOPERATIVE CONSIDERATIONS

- ▶ Cardiac surgery includes procedures performed on the ventricles, atria, cardiac valves, or great vessels.
 - ▶ Some cardiac surgeries are performed on a closed beating heart, but others are open procedures in which a major cardiac structure must be opened to accomplish the repair.
 - ▶ The latter require a strategy to arrest or support the circulation during the repair.
- 

- 
- 
- ▶ Short procedures (<4 minutes) can be performed with venous inflow occlusion and brief circulatory arrest.
 - ▶ Longer open cardiac repairs require cardiopulmonary bypass to support cardiopulmonary function during surgery.

- 
- Animals requiring cardiac surgery often have prior cardiovascular compromise that should be corrected or controlled medically when possible before anesthetic induction.
 - Congestive heart failure (CHF), particularly pulmonary edema, should be managed with diuretics (e.g., furosemide) and angiotensin-converting enzyme (ACE) inhibitors (e.g., enalapril, benazepril, lisinopril) and an inodilator (pimobendan) before surgery.
 - Ventricular tachycardia should be suppressed before surgery with class I antiarrhythmic drugs (i.e., lidocaine and procainamide).


- All animals should undergo a complete echocardiographic evaluation before cardiac surgery; an incomplete or inaccurate diagnosis can have devastating consequences.
- With the advent of Doppler echocardiography, cardiac catheterization is no longer routinely necessary before cardiac surgery.








ANESTHESIA

- ▶ Anesthesia of the patient with cardiac compromise has risks that vary depending on the cause of the underlying disease.
- ▶ Preanesthetic medication is appropriate for most animals undergoing cardiac surgery.
- ▶ Parenteral opioids (i.e., hydromorphone, butorphanol, buprenorphine, and fentanyl) induce sedation with minimal cardiovascular effects; however, all opioids can produce respirator depression and/ or bradycardia.


- 
- ▶ α 2-Agonists (e.g., demedetomidine) and acepromazine should be avoided in cardiac patients owing to significant alterations in hemodynamic parameters associated with their administration.
 - ▶ Anticholinergics (i.e., atropine and glycopyrrolate) should be administered only as needed.
 - ▶ Benzodiazepines (e.g., diazepam 0.2 mg/kg, midazolam 0.2 mg/kg) have minimal cardiopulmonary effects and enhance sedation when given alone or combined with opioids.


- 
- 
- ▶ Induction of anesthesia should be undertaken with caution in animals with cardiopulmonary compromise.
 - ▶ Propofol produces rapid induction but causes essentially the same cardiovascular compromise as thiobarbiturates.
 - ▶ The addition of fentanyl decreases propofol requirements in healthy dogs with minimal alteration in cardiovascular parameters.

- 
- ▶ A balanced anesthetic approach using benzodiazepine, opioids, and modest amounts of inhalant is generally much safer.
 - ▶ Thoracic surgery always requires controlled ventilation.
 - ▶ Mechanical ventilation should achieve a tidal volume of 6 to 10 ml/kg of body weight at an inspiratory pressure of less than 20 cm of water.



PATENT DUCTUS ARTERIOSUS

- The ductus arteriosus is a fetal vessel that connects the main pulmonary artery and the descending aorta.
 - During development, it shunts blood away from collapsed fetal lungs.
 - Normally, it closes shortly after birth during the transition from fetal to extrauterine life.
 - Continued patency of the ductus arteriosus for longer than a few days after birth is called patent ductus arteriosus (PDA).
- 



- 
- PDA is one of the most common congenital heart defects of dogs; it occurs infrequently in cats. PDA typically causes a left-to-right shunt that results in volume overload of the left ventricle and produces left ventricular dilation.
 - Progressive left ventricular dilation distends the mitral valve annulus, causing secondary regurgitation and additional ventricular overload.
 - This severe volume overload leads to left-sided CHF and pulmonary edema, usually within the first year of life.

SURGICAL TREATMENT

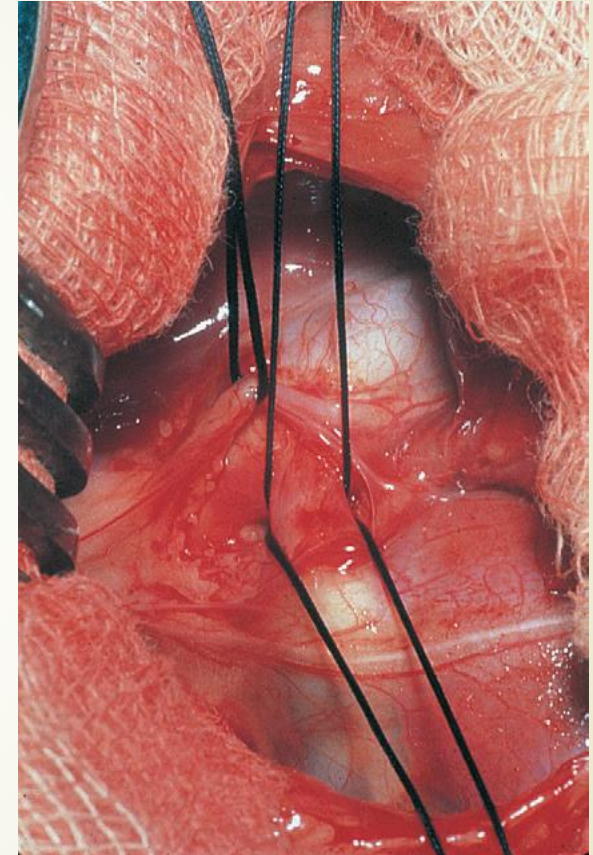
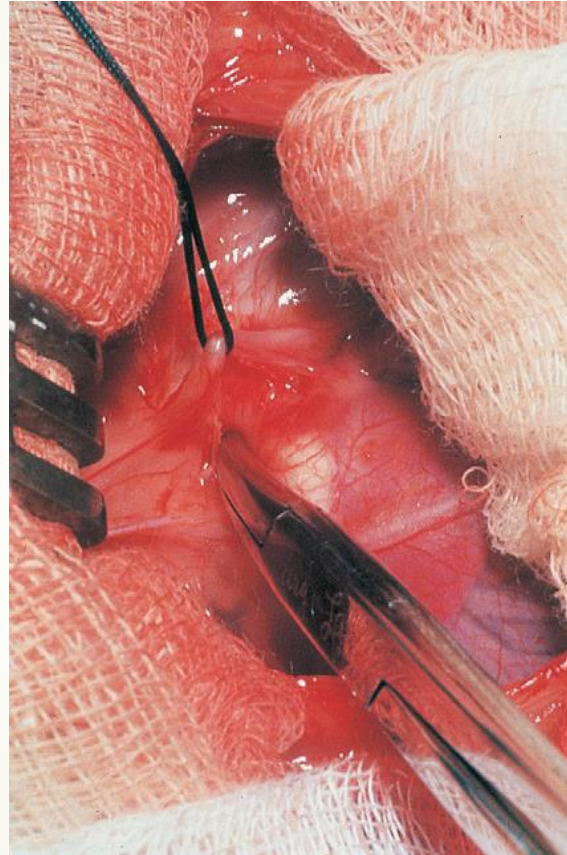
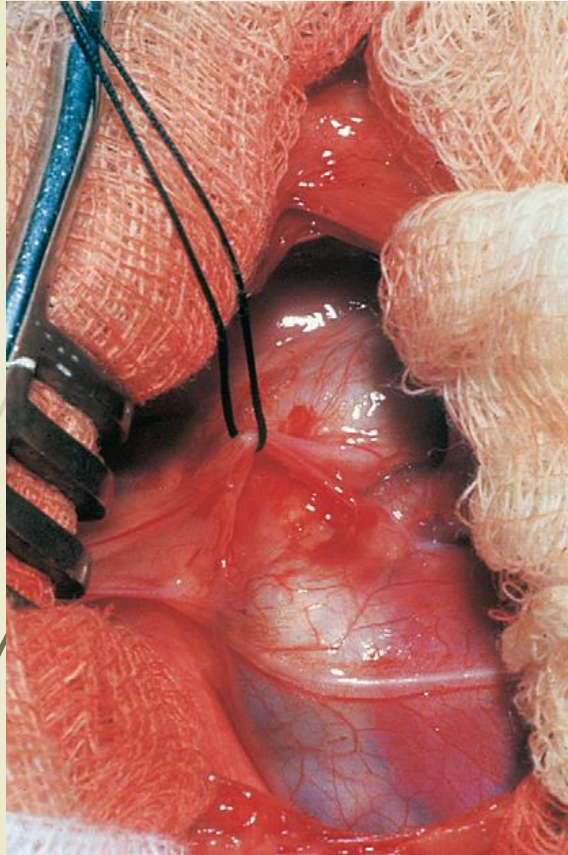
- ▶ Intravascular coils, vascular plugs, and duct occluders are now used routinely for closure of patent ductus arteriosus.
- ▶ Standard surgical correction of left-to-right patent ductus arteriosus is accomplished by ligation of the ductus arteriosus



Intravascular coil


- 
- 
- These techniques have the advantage of not requiring a thoracotomy and have less risk for major complications; however, mortality rates are comparable between transcatheter arterial occlusion and surgical ligation.
 - The coil(s) or occluders are placed in the ductus under fluoroscopic guidance, and complete occlusion is verified by injection of contrast agent into the aorta.



Right lateral recumbency, a *left fourth space intercostal thoracotomy*





PULMONIC STENOSIS

- ▶ Pulmonic stenosis (PS) is a congenital narrowing of the pulmonic valve, pulmonary artery, or right ventricular outflow tract.
 - ▶ Valvular stenosis may be simple, consisting of incomplete separation of valve leaflets, or it be due to valve dysplasia characterized by a hypoplastic valve annulus and thickened immobile valve leaflets.
- 

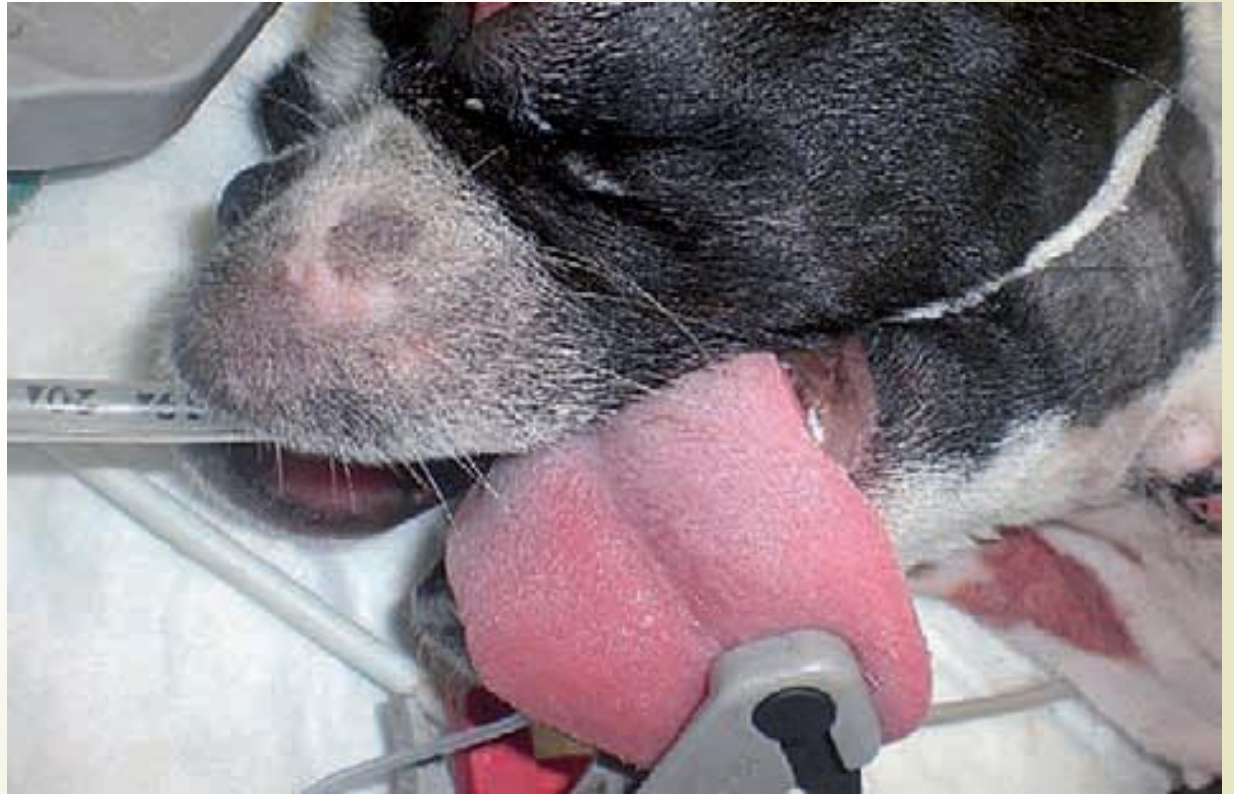- 
- 
- ▶ English Bulldogs, Scottish Terriers, Wirehaired Fox Terriers, Beagles, Miniature Schnauzers, Cocker Spaniels, Samoyeds, and Mastiffs are at increased risk for developing PS.
 - ▶ Young animals with PS are often asymptomatic.
 - ▶ Advanced cases may present with exercise intolerance, syncope, or abdominal distention from ascites.

SURGICAL TREATMENT

- ▶ Therapy for PS is based on its degree of severity and the type of lesion present.
- ▶ Severity is judged by the presence of signs, the extent of right ventricular hypertrophy, and the magnitude of the systolic pressure gradient.
- ▶ Animals with PS that have no signs, mild hypertrophy, and a pressure gradient less than 50 mmHg generally do not require surgical intervention.
- ▶ Surgical options for correction of PS include valve dilation and patch-graft valvuloplasty. With the advent of balloon valvuloplasty, operative valve dilation is seldom indicated.

TETRALOGY OF FALLOT

- ▶ Tetralogy of Fallot is a complex congenital heart defect that consists of PS, VSD, a dextropositioned overriding aorta, and right ventricular hypertrophy.
- ▶ most common congenital heart defect that causes cyanosis in small animals.
- ▶ It occurs in cats and a variety of canine breeds.
- ▶ A shortened life span is expected in these animals because of complications of hyperviscosity-induce thromboembolism or sudden death (caused by polycythemia).


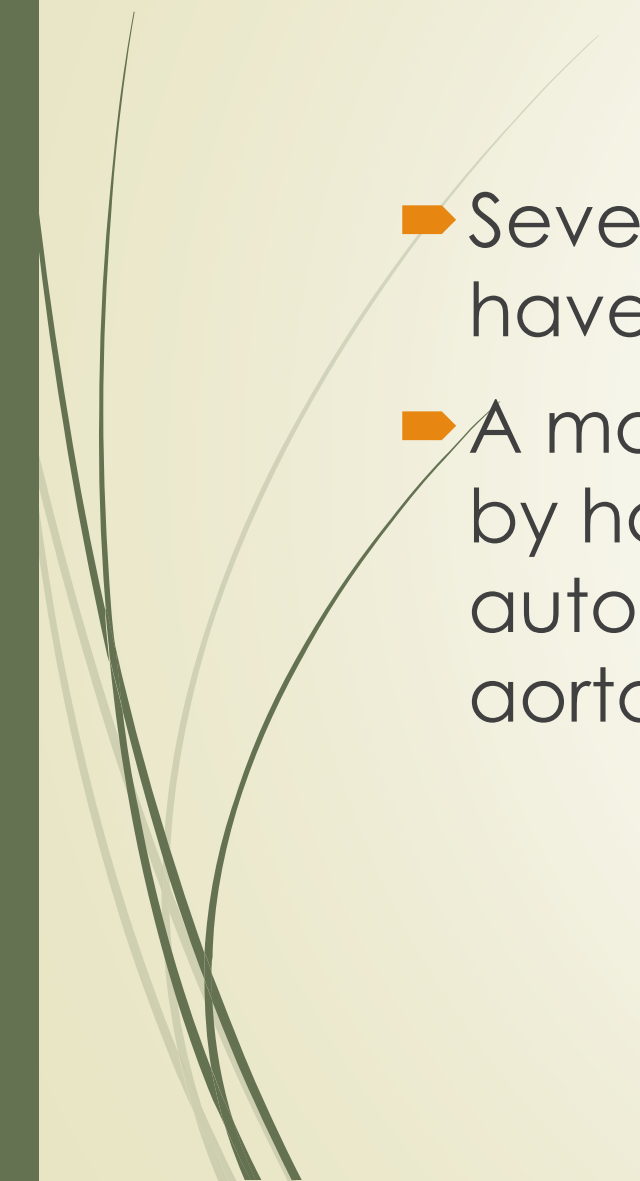


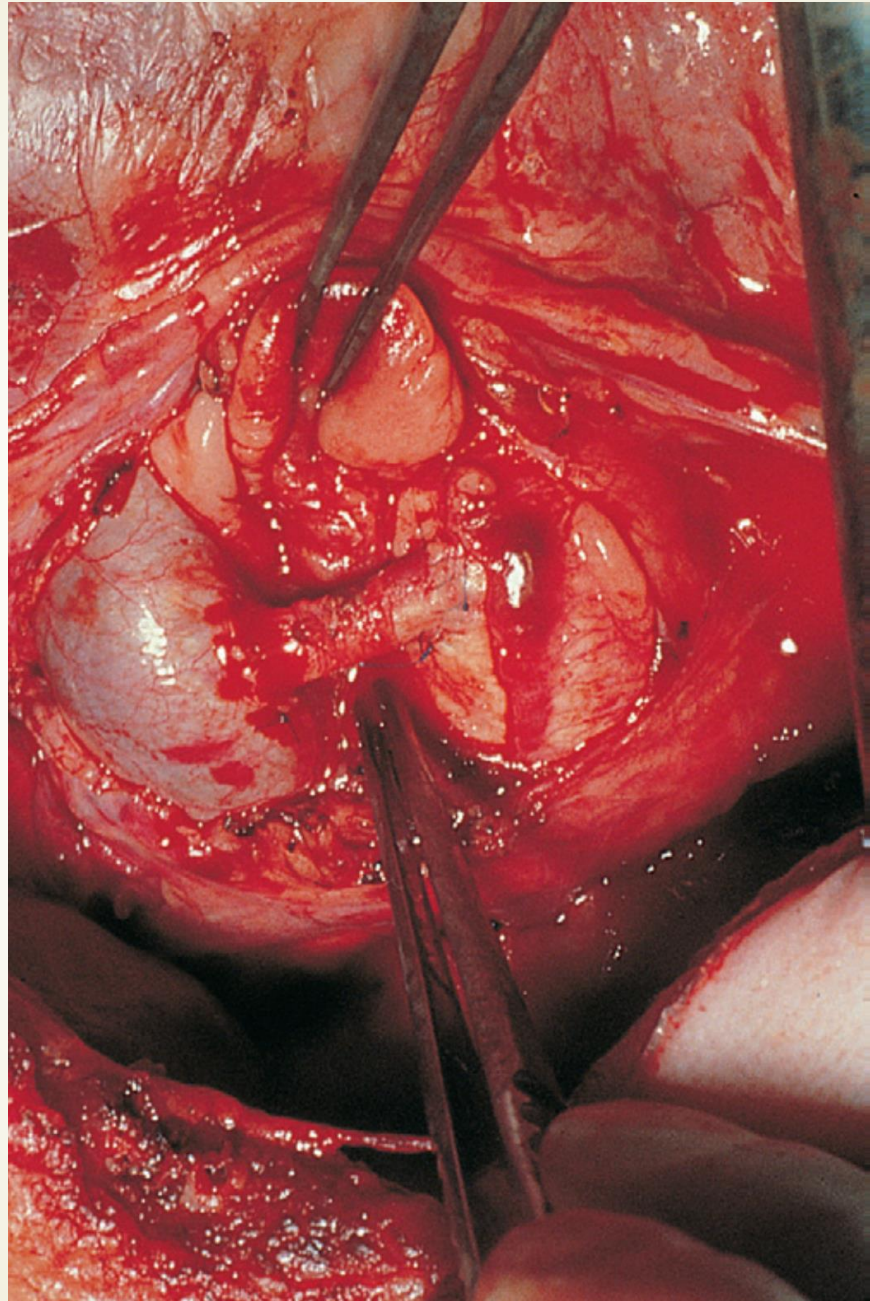
- Breeds most commonly reported to have tetralogy of Fallot include Keeshonden, English Bulldogs, Poodles, Schnauzers, Terriers, Collies, and Shelties.
- Clinical findings at presentation include moderate to severe exercise intolerance, exertional tachypnea, collapse, and syncope.



SURGICAL TREATMENT


- Surgery should be considered for severely cyanotic animals to lessen clinical signs and prolong life.
- Animals with resting arterial oxygen saturation less than 70% should be considered candidates for surgery.
- Palliative surgeries for tetralogy include isolated correction of the PS or creation of a systemic-to-pulmonary shunt (e.g., Blalock-Taussig shunt)


- 
- 
- Several types of systemic-to-pulmonary shunt have been used to palliate tetralogy of Fallot.
 - A modified Blalock-Taussig shunt is accomplished by harvesting the left subclavian artery as a free autogenous graft and placing it between the aorta and the main pulmonary artery.



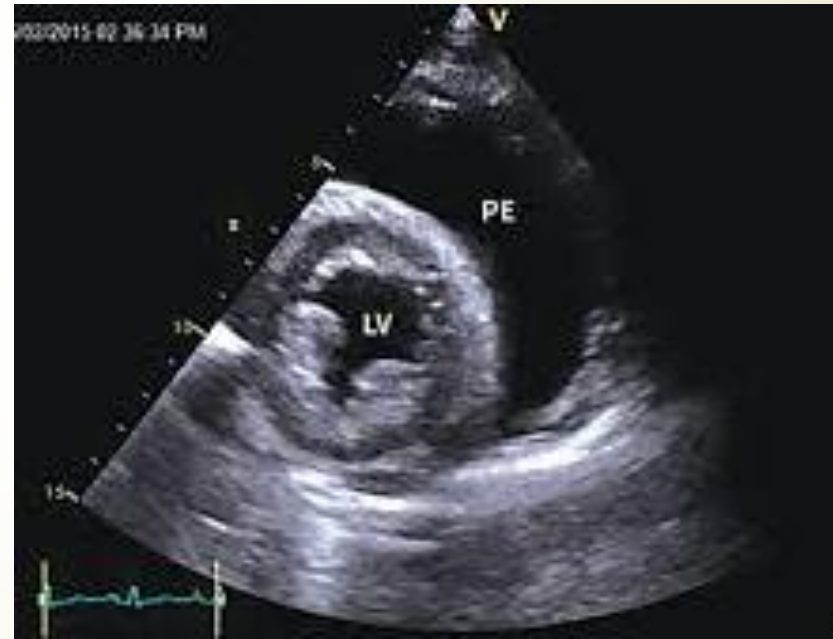
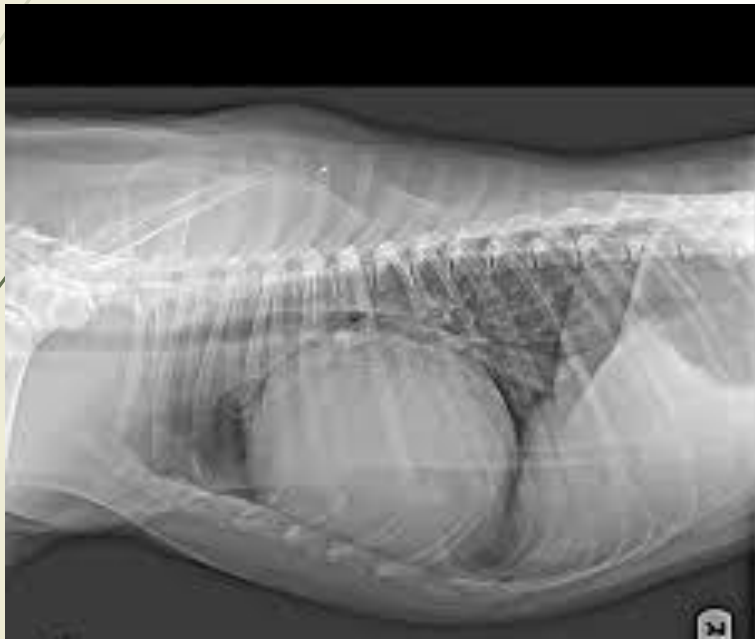
PERICARDIAL EFFUSION AND PERICARDIAL CONSTRICTION

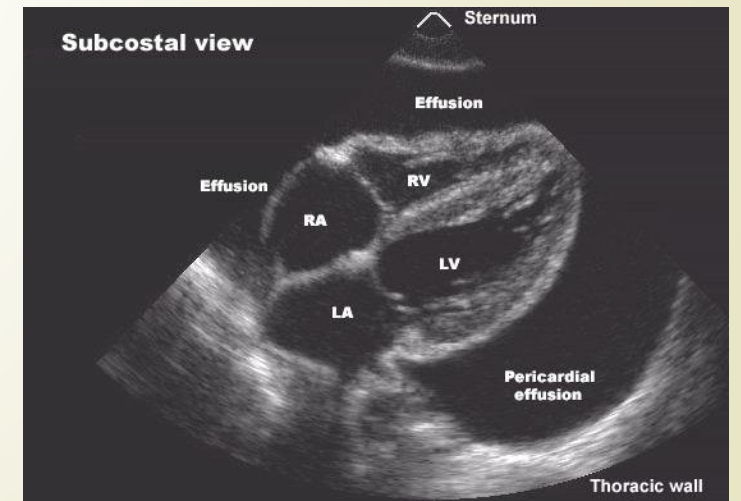
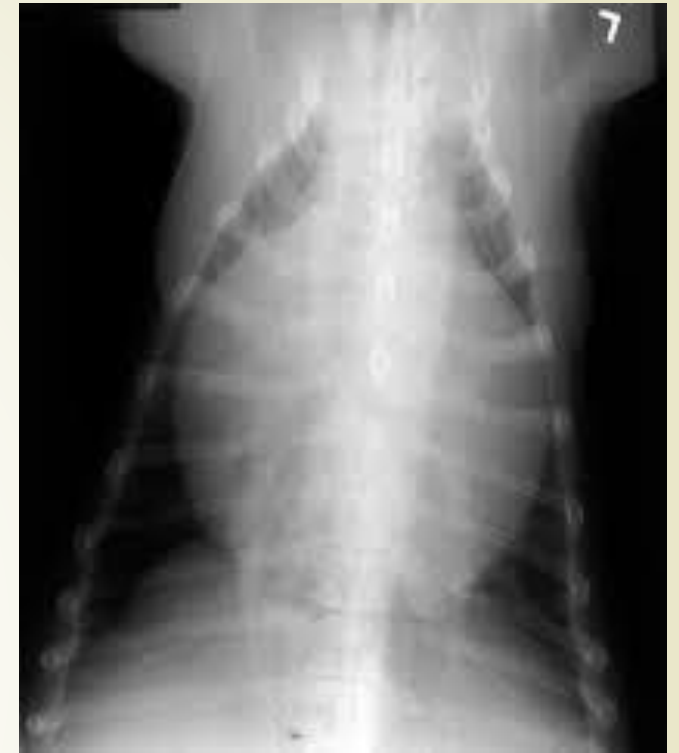- The pericardium is a fibroserous envelope that encompasses the heart and great vessels.
 - Pericardial effusion is an abnormal accumulation of fluid within the pericardial sac.
 - Cardiac tamponade refers to the decompensated phase of cardiac compression that results from an unchecked rise in intrapericardiac fluid pressure.
- 


- 
- Pericardial constriction results from restrictive fibrosis of the parietal and/or visceral pericardium that interferes with diastolic function of the heart.
 - Diseases that affect primarily the pericardium account for approximately 1% of cardiovascular disease.
 - Pericardial diseases are uncommon in cats; pericardial effusion is most often related to CHF

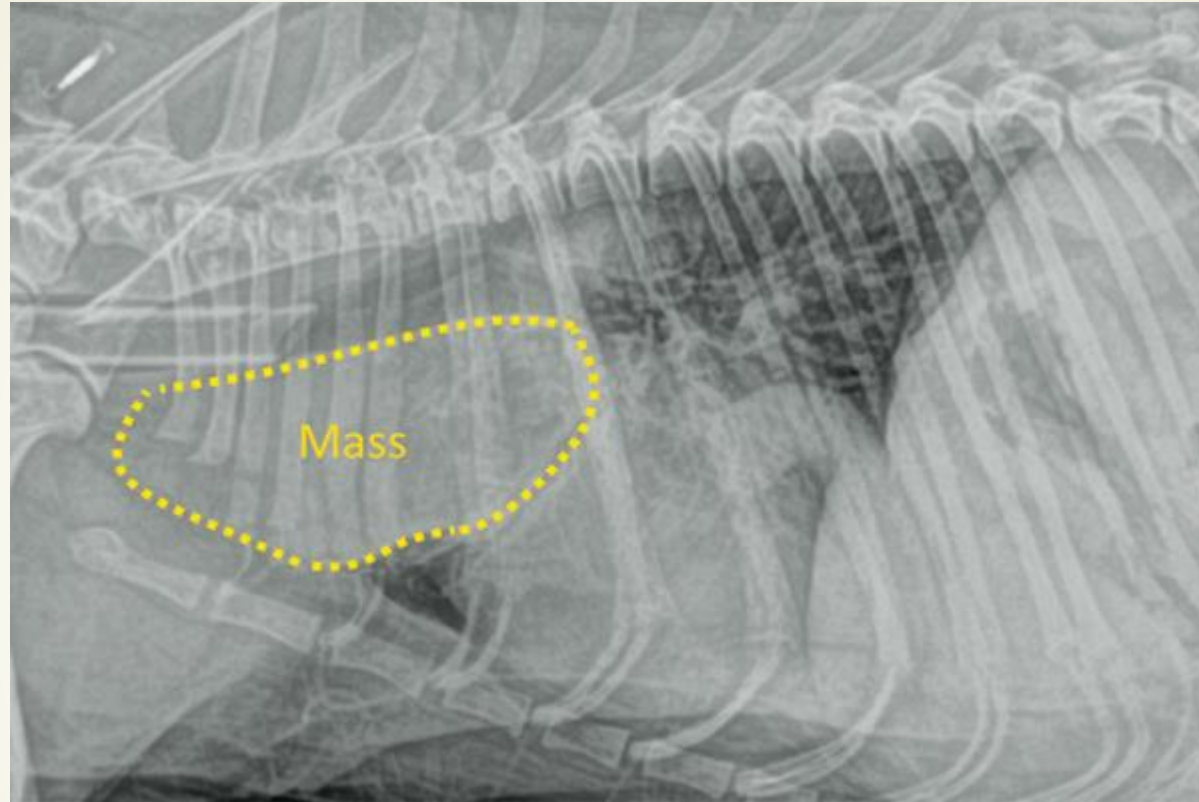
- ▶ The most common of which are those resulting in the accumulation of pericardial effusion.




- ▶ Pericardial effusion can be transudative, exudative (inflammatory), or sanguineous.
- ▶ Causes of pericardial transudation include right-sided CHF, hypoproteinemia, and incarceration of a liver lobe within the pericardial cavity.
- ▶ Transudative pericardial effusions are usually subclinical.



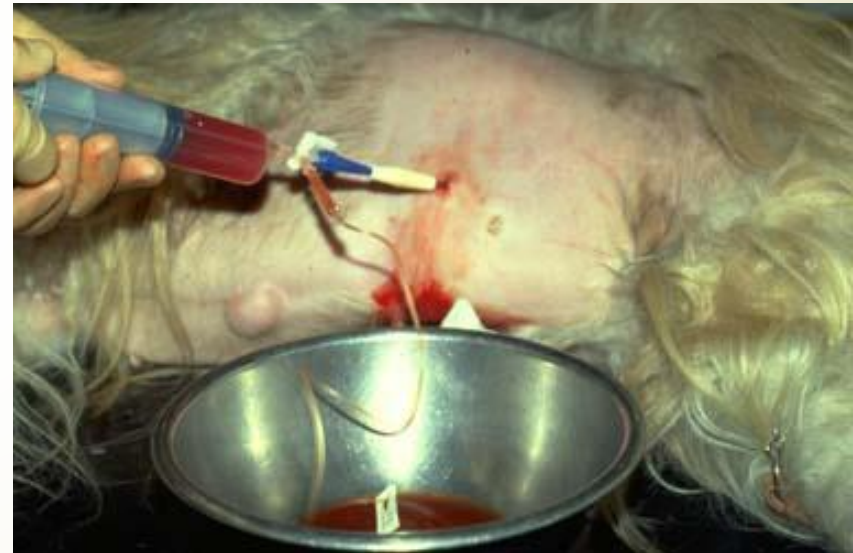
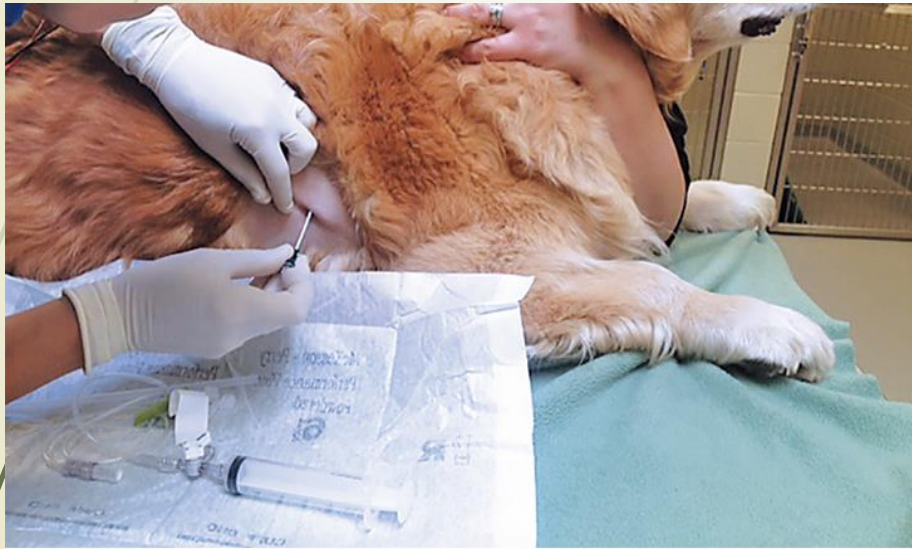- 
- Infectious pericarditis is an uncommon cause of pericardial effusion in dogs and cats, usually producing a purulent or fibrinous exudate.
 - Bacterial pericarditis can arise from bite wounds to the thorax, migrating foreign bodies, or hematogenous seeding.
 - Feline infectious peritonitis and toxoplasmosis are potential causes of feline inflammatory effusions.



The most common causes of pericardial effusion in dogs are neoplasia and benign idiopathic effusion.

- 
- ▶ Idiopathic (benign) pericardial effusions are common in dogs; this condition has not been reported in cats.
 - ▶ Idiopathic benign and neoplastic pericardial effusions are more commonly observed in large and giant breed dogs.
 - ▶ Clinical signs; weakness, lethargy, exercise intolerance, and/or collapse. Patients often have right-sided congestion, ascites, and/or pleural effusion.
 - ▶ The most common owner complaint with constrictive pericarditis is abdominal enlargement.
 - ▶ Dyspnea, tachypnea, weakness, syncope, and/or weight loss are noted less frequently

- ▶ Pericardiocentesis is the treatment of choice for initial stabilization of dogs and cats with pericardial effusion and cardiac tamponade.
- ▶ When performed properly, pericardiocentesis is associated with minimal complications.

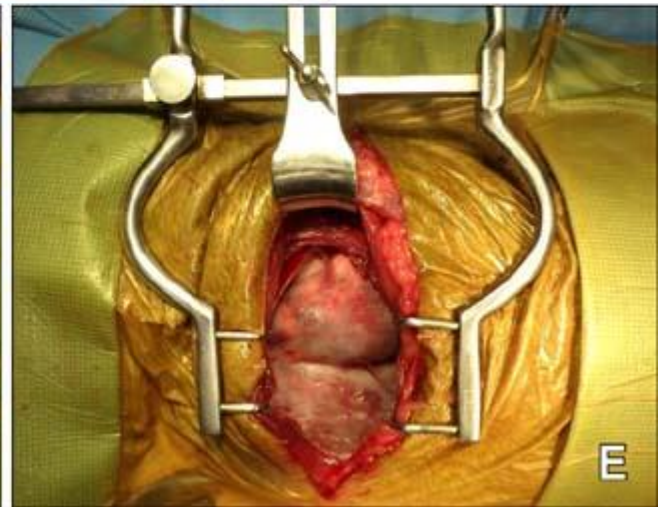
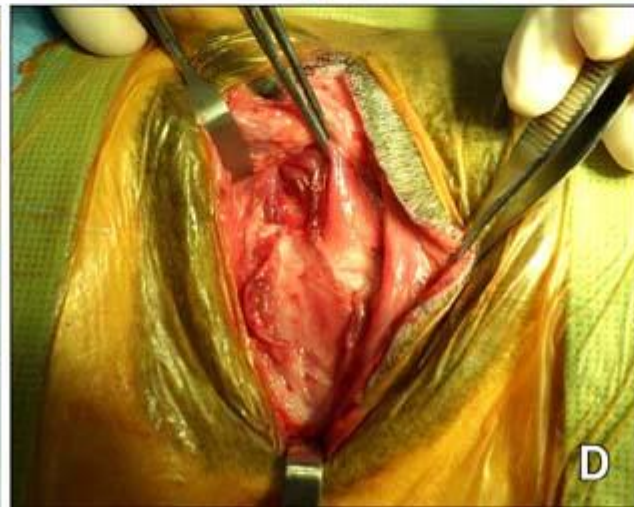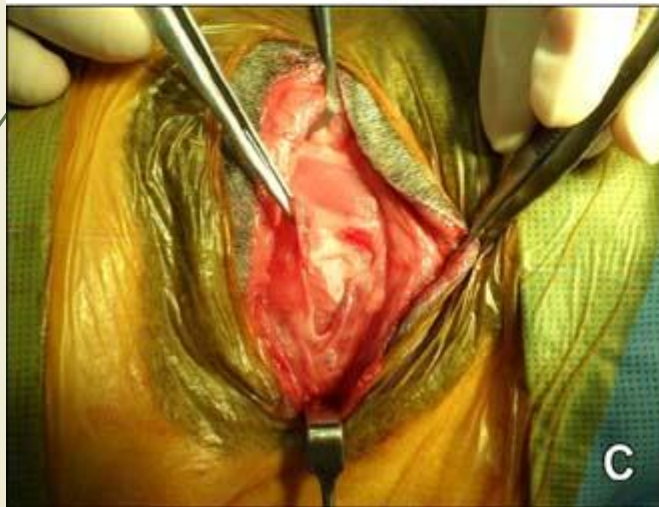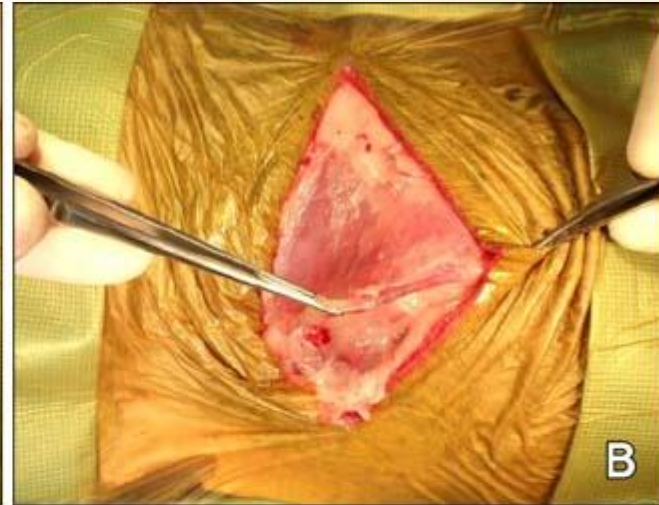
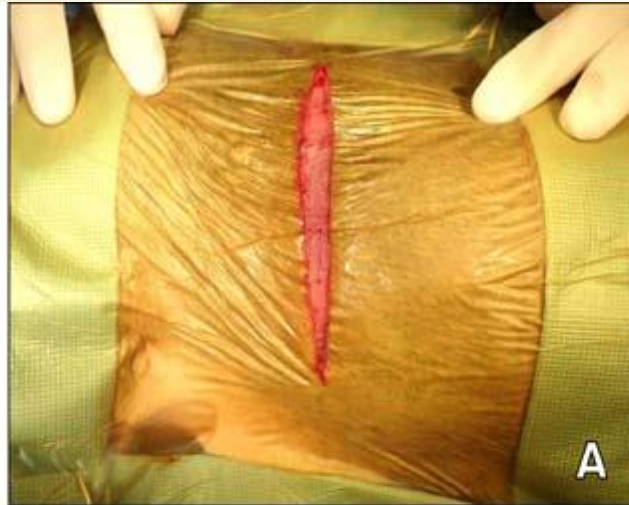


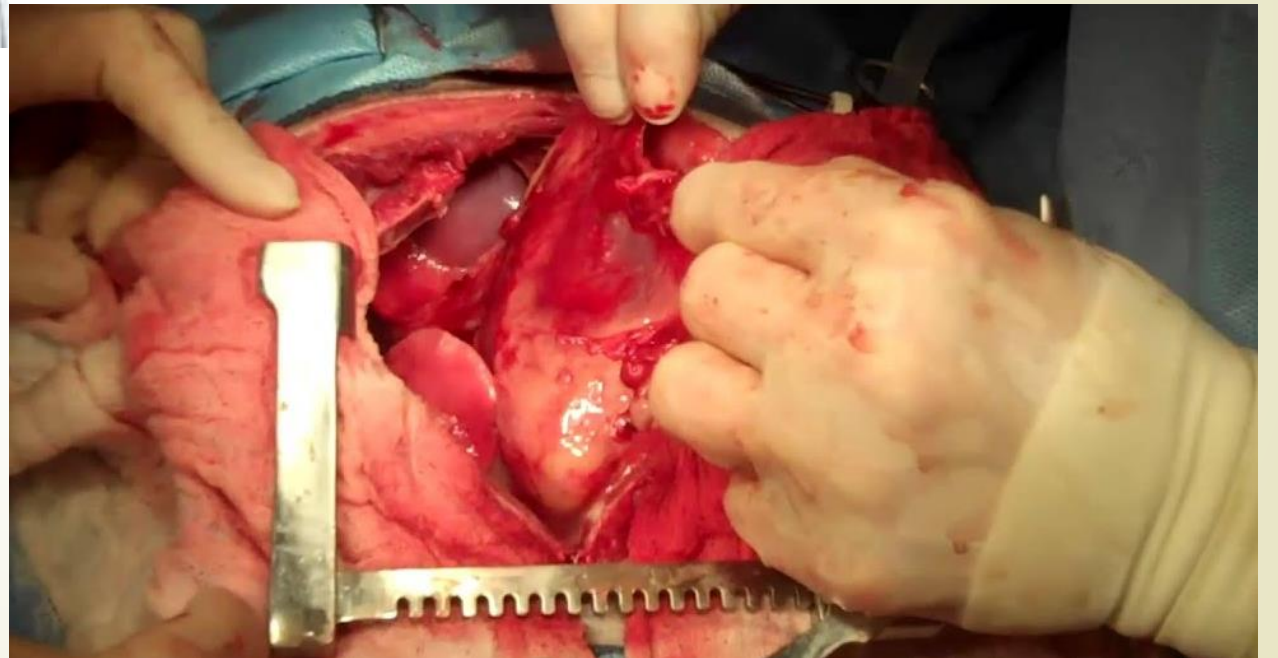
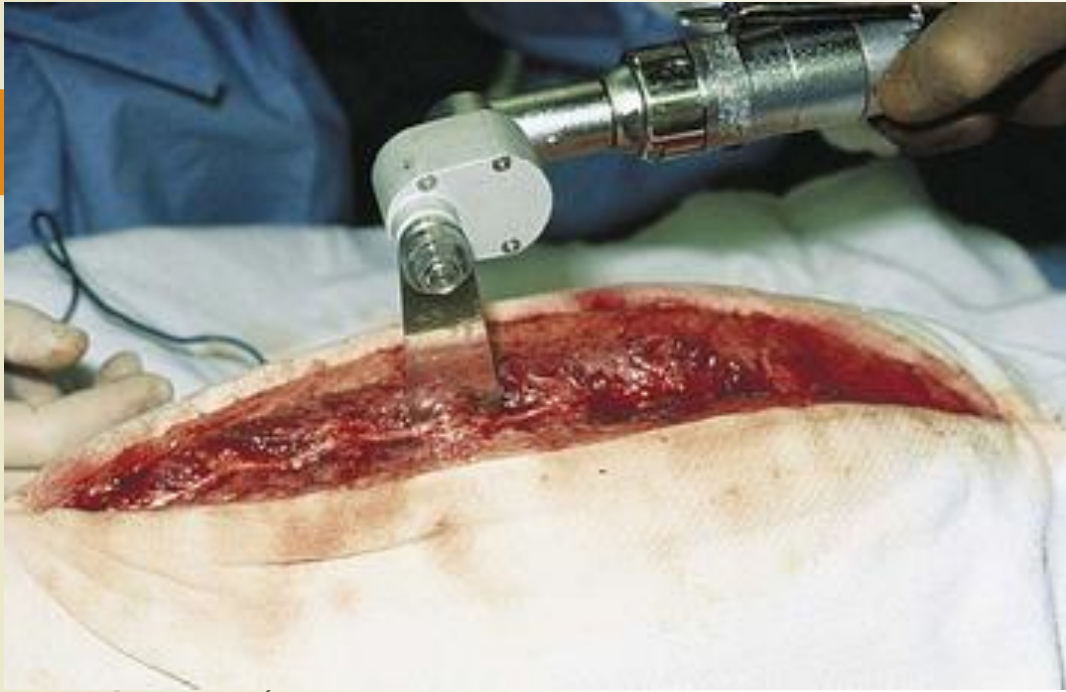
This is most commonly between the fourth and fifth intercostal spaces at the costochondral junction. Attach a 14 to 18 g needle or over-the-needle catheter to a three way stopcock, extension tubing, and syringe to allow constant negative pressure to be applied during insertion and drainage.





SURGICAL TREATMENT

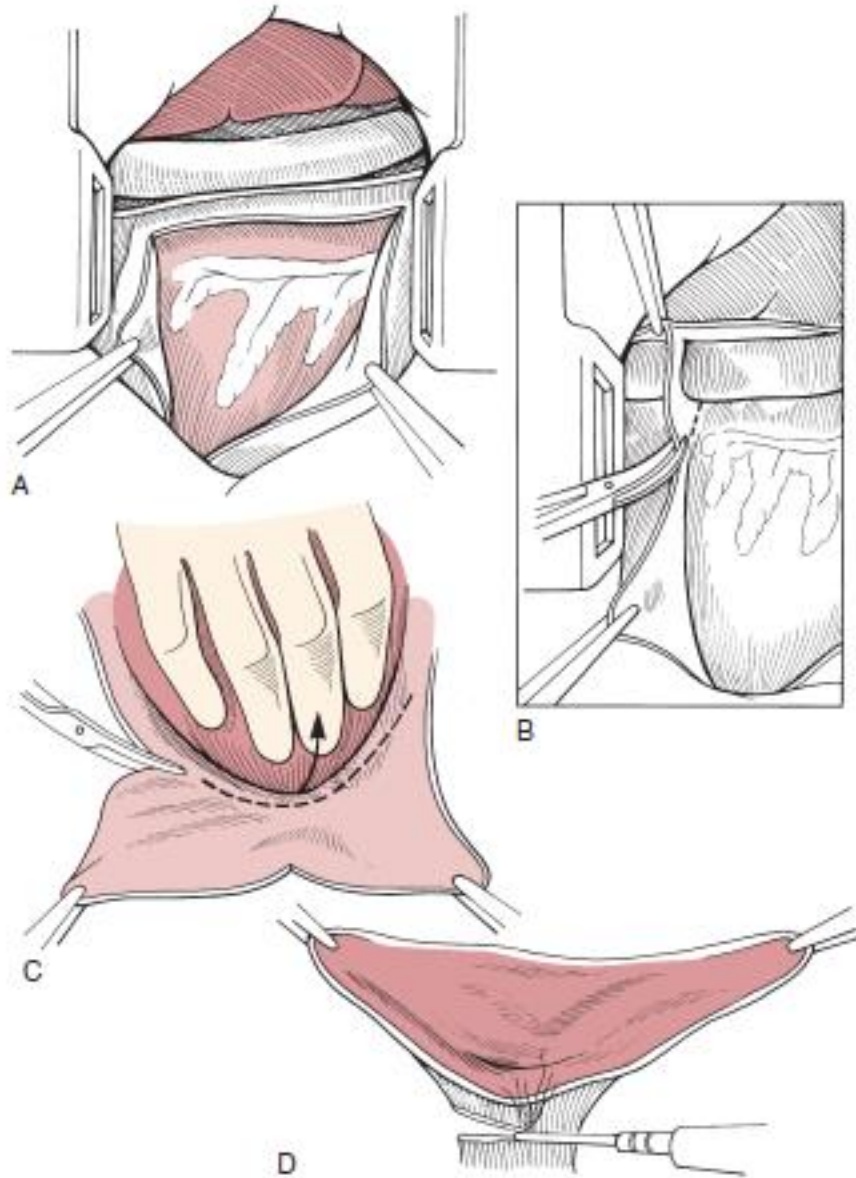
- ▶ Although temporary relief of cardiac tamponade is provided by pericardiocentesis, long-term palliation of pericardial effusion often requires pericardiectomy.
- ▶ Pericardiectomy can be performed through an intercostal thoracotomy or a median sternotomy or it can be done with thoracoscopy.





- 
- 
- ▶ Partial, subtotal, or total pericardiectomy can be performed depending on the underlying cause and the surgical approach (thoracotomy, sternotomy, or thoracoscopy) chosen.

Subphrenic (Subtotal) Pericardiectomy via Right Thoracotomy



A, For subtotal pericardiectomy via a **right fifth intercostal thoracotomy**, incise the epicardium vertically and horizontally ventral to the right phrenic nerve.

B, Carefully extend the incision around the vena cava, taking care to identify the vessel Wall while making the incision.

C, Gently retract the heart and extend the incision across the left side, ventral to the left phrenic nerve.

D, Divide the pericardiophrenic ligament with cautery or between ligatures. Removal of smaller portions of the pericardium may be equally as effective.

- Total Pericardiectomy
- Thoracoscopic Pericardiectomy!!

