

Chapter 8

Digestive diseases (pharynx to anorectum)

Frédéric Gaschen

Part 1: Diseases of the pharynx, masticatory muscles, and salivary glands

DYSPHAGIA

Definition/overview

The word 'dysphagia' is derived from Greek and means difficulty in eating and swallowing. A closely related term is odynophagia, which describes pain while eating/swallowing. The three phases of the normal swallowing reflex are described in **Table 8.1**.

Etiology

Three types of dysphagia are recognized.

Oral dysphagia

Oral dysphagia relates to a difficulty prehending food and forming a bolus of food. It can occur with most oral and dental diseases. Additionally, tongue atrophy or paralysis and diseases of the masticatory muscles and temporomandibular joint can also lead to oral dysphagia.

Pharyngeal dysphagia

Pharyngeal dysphagia is characterized by abnormal passage of food through the oropharynx. It may occur

with pharyngeal diseases such as pharyngeal edema, trauma and foreign bodies, intraluminal masses, and extraluminal masses (e.g. grossly enlarged lymph nodes, retropharyngeal abscess, salivary gland enlargement), or result from abnormalities in the tightly regulated swallowing reflex. Affected animals may show numerous unsuccessful attempts to swallow, regurgitate immediately, gag, cough, and experience nasal reflux. Aspiration pneumonia is common. Diagnosis is confirmed by fluoroscopy that shows failure of the pharynx to constrict and the upper esophageal sphincter (UES) to relax. In the absence of an obvious cause for dysphagia, rabies should be considered in unvaccinated dogs. Dogs with laryngeal paralysis or myasthenia gravis may show concurrent pharyngeal dysphagia. If no cause can be identified, the prognosis of pharyngeal dysphagia is generally poor.

Cricopharyngeal dysphagia

Cricopharyngeal dysphagia is characterized by a failure of the UES to relax (achalasia) or a lack of coordination between pharyngeal contraction and UES relaxation (dys-synchrony). This disorder is rare, and is usually observed in puppies at the time of weaning. Detailed oropharyngeal inspection yields no abnormal findings. Diagnosis is confirmed with a fluoroscopic swallowing study showing that the food remains in the pharynx in spite of normal

Table 8.1 Physiology of swallowing.

Oropharyngeal phase	Voluntary oral stage: formation of food bolus in the oropharynx, passage to the base of tongue, pharyngeal peristaltic contractions, bolus propelled to the laryngopharynx
	Pharyngeal phase: contraction of oral and tongue muscles with closure of pathway between oral cavity and pharynx, elevation of the soft palate, glottis closure, and tipping of the epiglottis after rostral displacement of the larynx
	Cricopharyngeal phase: relaxation of the UES (cricopharyngeal and thyropharyngeal muscles) to allow food bolus to be propelled into the upper esophagus
Esophageal phase	A primary peristaltic wave is generated in the pharynx and propagated through the esophagus to propel the bolus to the LES (lower esophageal sphincter). If the primary wave is not successful, a secondary wave is quickly generated by esophageal distension
Gastroesophageal phase	Relaxation of the LES and passage of the bolus into the stomach

pharyngeal motility. A congenital neurologic disorder is suspected. In the absence of complicating factors, the prognosis for dogs with confirmed cricopharyngeal achalasia is good after myotomy or myectomy of the cricopharyngeal muscle. Injection of botulinum toxin A into the muscle through an oral approach with endoscopic guidance has been anecdotally successful. However, the effect is limited to 2–4 months. The procedure may help identify patients who would most benefit from surgery.

Pathophysiology

Bouvier des Flandres dogs may be affected with a congenital pharyngeal myopathy. Golden Retrievers are overrepresented among dogs with cricopharyngeal dysphagia. Large breed dogs are also predisposed to laryngeal paralysis, a disease more commonly associated with pharyngeal and upper esophageal dysfunction

Clinical presentation

While dogs and cats with oral dysphagia are reluctant or unable to chew properly, animals with pharyngeal or oropharyngeal dysphagia are unable to swallow the food bolus in spite of repeated attempts. If the affected animal takes a quick breath of air between swallowing actions, food may enter the larynx and trachea, eliciting a cough. Dogs will try again and again, and will sometimes succeed in achieving a more adequate swallowing action. They regurgitate the food bolus, which is covered with saliva. Their ability to drink from a water bowl may be maintained or impaired as well. Animals are generally hungry and weight loss and lean body condition are common. Other signs include coughing and nasal discharge.

Diagnosis

Diagnosis relies on clinical signs (**Box 8.1**). A thorough oral and pharyngeal examination, ideally in the sedated animal, is often valuable. Radiographs of the pharynx are recommended in animals with suspect foreign body (FB) or other causes of obstruction. Fluoroscopic swallow studies can be very useful to confirm the type of dysphagia, but are only available in referral centers. If aspiration pneumonia is suspected, chest radiographs are helpful to evaluate the severity and extent of the process.

Box 8.1 Practical tip on the clinical approach to dysphagic dogs and cats.

First, observe the animal while it is eating. Videos filmed by the owner can be helpful as well. This allows recognizing the different types of dysphagia and designing a targeted further approach

Management

Nonspecific measures include optimizing the consistency of the food (generally, moist food is best tolerated). Specific treatments correcting the primary disease are most helpful if available (see above). Additionally, in severe or untreatable cases, endoscopically or surgically placed low profile gastrostomy tubes allow bypass of the pharynx and proximal esophagus in order to provide enteral nutrition.

PHARYNGITIS AND TONSILLITIS

Definition/overview

Inflammation causes hyperemia and swelling of the pharyngeal mucosa, which may be associated with tonsillar enlargement and protrusion of the tonsils out of the palatine fossae. Tonsillitis is not uncommon in the dog, particularly in young miniature and toy breeds, but is quite rare in the cat. The inflammation is usually bilateral; however, it may be unilateral in association with FBs such as grass blades, pieces of wood, and grass seeds.

Etiology

Acute pharyngitis with or without secondary tonsillitis may occur following trauma, foreign bodies, insect stings, snake bites, allergic reactions, chemical or thermal injuries, and viral infection of the upper respiratory tract (cat). Additionally, disorders causing chronic vomiting, gagging, coughing, or regurgitation may be associated with acute tonsillitis.

Clinical presentation

Coughing, gagging, retching, or expectorating white foamy mucus (which may be confused with vomiting by the pet's owner) are commonly reported. Dysphagia, repeated swallowing attempts, odynophagia, hypersalivation, excessive licking, and pica can also be observed. Some animals can present with decreased appetite, malaise, and fever. Pharyngeal examination reveals a hyperemic (dog) or injected (cat) pharynx, possibly with enlarged tonsils protruding out of the palatine fossae. Hyperemia, mottled appearance, petechiations, and white specks are reliable signs of acute inflammation. Chronically inflamed tonsils may just be enlarged with an irregular surface.

Differential diagnosis

Tonsillitis should be differentiated from tonsillar neoplasia such as lymphoma (unilateral or bilateral enlargement [**Figure 8.1**]) or squamous cell carcinoma (SCC) (unilateral, highly malignant).

Diagnosis

Diagnosis is based on the abnormal appearance of the pharynx and tonsils in association with the existence of compatible clinical signs. Secondary tonsillitis is common, and a thorough search for a primary underlying disease should be performed. Radiographs of the pharynx and retropharyngeal area may reveal the presence of FBs or space-occupying processes (**Figures 8.2, 8.3**). Fine needle aspiration or brush cytology may help rule out neoplasia and confirm inflammation.

Management

For acute cases, treatment usually consists of a 10–14-day course of antibiotics (e.g. amoxicillin and clavulanic acid), possibly with analgesics if indicated. In chronic cases with significantly enlarged tonsils, tonsillectomy may be required if the tonsils become an obstacle preventing passage of food into the pharynx.

Prognosis

Good, although acute tonsillitis may recur. The disorder usually resolves spontaneously with time.

DISEASES OF THE SALIVARY GLANDS

The four salivary glands of dogs and cats are the submandibular (located rostrolaterally from the submandibular lymph node), sublingual, parotid (under mandibular ramus), and zygomatic (infraorbital) glands. Salivary gland diseases are uncommon in dogs and very rare in cats.

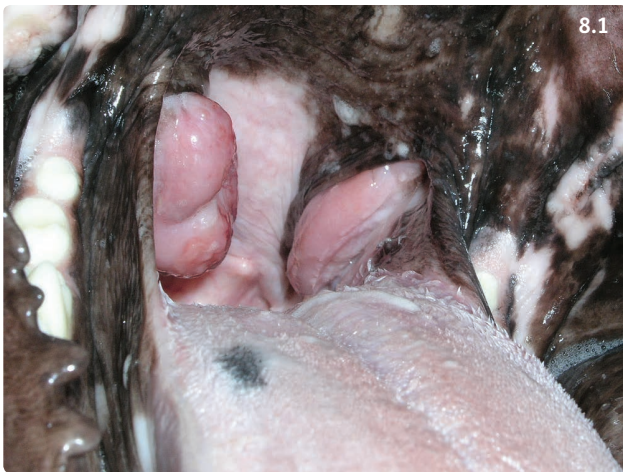

Figure 8.1 Bilaterally enlarged tonsils in a middle aged mixed-breed dog. Cytology from a fine needle aspirate revealed lymphoma. (Courtesy R. Husnik)

MUCOCELE, SIALOCELE

Definition/overview

Sialocele is the most frequently diagnosed salivary gland disorder of dogs. It consists of an accumulation of saliva in the periglandular tissues due to salivary duct obstruction and/or rupture. The wall of the mucocele is not epithelial, therefore mucoceles are not true salivary gland cysts.

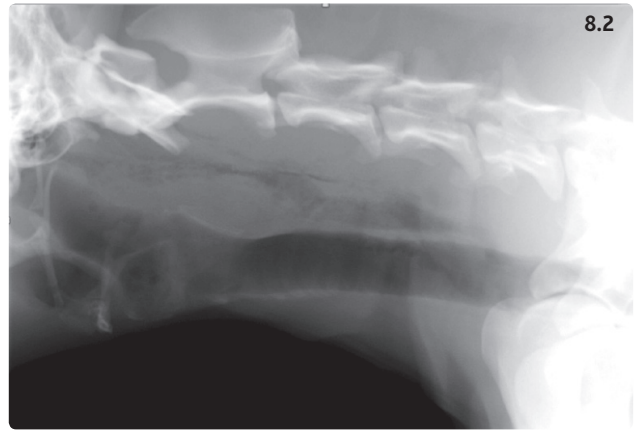


Figure 8.2 Proximal cervical radiograph from a 5-year-old Belgian Shepherd Dog taken 2 hours after the owner pulled a stick that appeared to be stuck in the dog's throat. There is retropharyngeal accumulation of air. Persistent wood fragments cannot be ruled out based on these films. Esophagoscopy was negative, and the dog recovered with antibiotic treatment.

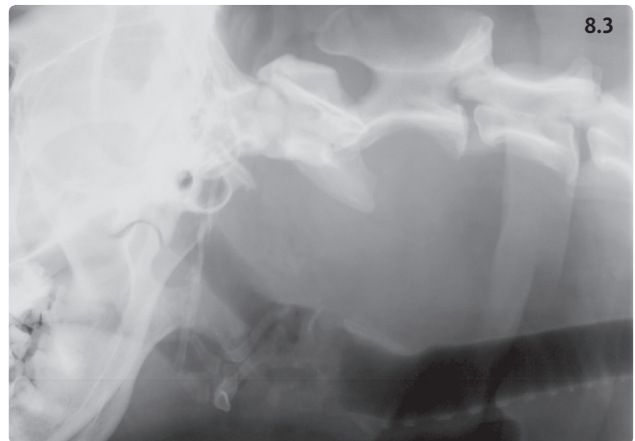


Figure 8.3 Proximal cervical radiograph of an 8-year-old Bernese Mountain Dog with dysphagia. A space-occupying lesion is pushing the pharynx, esophagus, and trachea ventrally. Fine needle aspiration revealed histiocytic sarcoma.

They can occur in the vicinity of each salivary gland; however, the sublingual and submandibular glands are the most frequently affected. German Shepherd Dogs and Poodles appear to be more susceptible to developing sialoceles.

Etiology

Trauma is thought to be the most frequent cause of sialocele (direct trauma, FB, sialadenolith), although signs of original trauma have usually resolved by the time the sialocele is diagnosed.

Clinical presentation

A large usually nonpainful mass is observed in the upper cervical region, the pharynx, or the oral cavity (**Figure 8.4**). Oral and pharyngeal sialoceles may cause dysphagia and oral bleeding following self-trauma. Pharyngeal and cervical mucoceles can occasionally cause dyspnea.

Differential diagnosis

Other causes of salivary gland enlargement such as inflammation (sialadenitis) and neoplasia.

Diagnosis

Diagnosis is based on history, physical examination, and results of fine needle aspiration of the mucocele with a large-bore needle (blood tinged, thick mucooid fluid with few neutrophils). Diagnostic imaging (ultrasound, sialography) can help confirm which gland is involved.

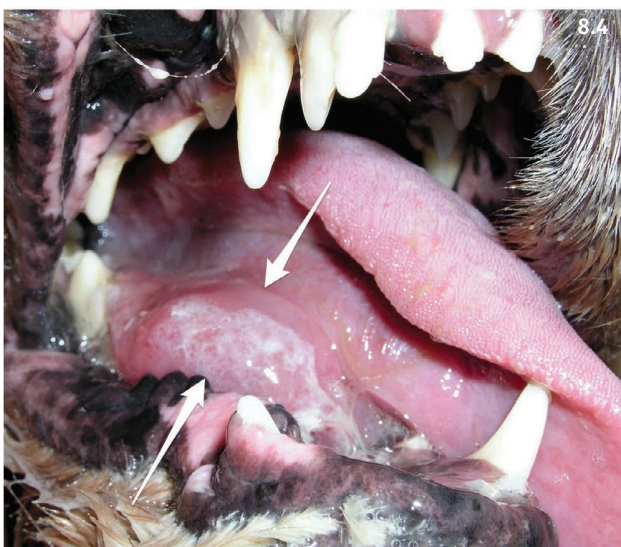

Figure 8.4 A ranula or sialocele affecting the sublingual salivary gland is visible at the base of the tongue of this dog (arrows). (Courtesy R. Husnik)

Management

Treatment consists of removal of the ipsilateral sublingual and submandibular gland as well as drainage of the fluid accumulation.

Prognosis

Prognosis is good following surgery.

SIALADENITIS

Sialadenitis describes inflammation of the salivary glands. A syndrome of inflammation and necrosis is occasionally observed in dogs. The condition leads to enlargement of one or several glands (most frequently the mandibular gland [**Figure 8.5**]). In the presence of severe inflammation, pain and dysphagia can occur. Therapy for sialadenitis is symptomatic and supportive. In severe cases, surgical removal of the gland may be indicated. A nonpainful, noninflammatory swelling has been described in association with vomiting, and seems to respond to phenobarbital therapy.

SALIVARY GLAND NEOPLASIA

Salivary gland neoplasia occurs rarely (more frequently in cats than in dogs). The submandibular gland is most commonly affected. Adenocarcinoma is the most common type.

MASTICATORY MUSCLE MYOSITIS

Definition/overview

Masticatory muscle myositis (MMM) is a common focal inflammatory myopathy of dogs. It selectively affects the muscles of mastication, including temporalis, masseter,

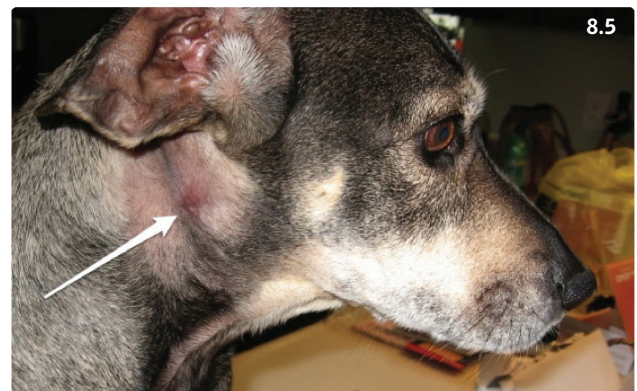


Figure 8.5 A swelling is visible in this dog with sialadenitis of the mandibular salivary gland (arrow). (Courtesy M. Schaer)

pterygoid, and rostral digastricus muscles, while sparing the spinal and limb muscles. Large breed dogs and Cavalier King Charles Spaniels are overrepresented among dogs with MMM.

Etiology/pathophysiology

MMM is caused by an autoimmune process directed against type 2M (superfast) myosin and a myofibril-associated protein, both exclusively found in masticatory muscle fibers.

Clinical presentation

In acute cases, clinical signs include acute swelling of the temporalis and masseter muscles (**Figure 8.6**), masticatory myalgia, restricted jaw movement, pain on opening of the mouth, and exophthalmos. Muscle atrophy and fibrosis with or without restricted jaw movement is present in chronically affected dogs.

Differential diagnosis

The differential diagnosis for dogs with difficulty and/or pain on opening of the mouth is listed in **Table 8.2**. Atrophy of the masticatory muscles may also occur as a result of chronic corticosteroid therapy.

Diagnosis

A serum assay with an excellent sensitivity (85–90%) and specificity (100%) allows detection of circulating autoantibodies against masticatory muscle type 2M fibers (<http://vetneuromuscular.ucsd.edu>). Serum creatine kinase (CK) activity may be mildly increased or normal. In acute cases, electromyography (EMG) usually reveals abnormal activity. Diagnostic confirmation is obtained with biopsy of the temporalis or masseter muscle (**Box 8.2**) with histopathology and type 2M autoantibody immunohistochemistry. The severity of inflammation and presence of fibrosis are assessed.

Management

Immunosuppressive doses of corticosteroids should be used (e.g. prednisone, 2 mg/kg/day) until the normal range of jaw motion returns and serum CK, if elevated, returns to normal. The dose should then be gradually decreased until the lowest alternate day dose is reached that will keep the dog free of clinical signs. This low dose should then be continued for at least 6 months. MMM is usually very steroid responsive; however, other immunosuppressive agents such as azathioprine may be added in dogs experiencing significant corticosteroid side-effects so that a faster weaning off of steroids is possible. Insufficient doses of corticosteroids for inadequate

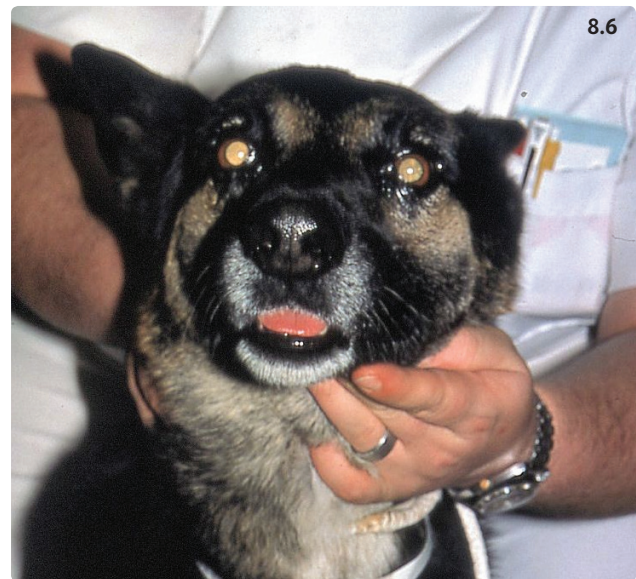

Figure 8.6 German Shepherd Dog with masticatory muscle myositis. The left masseter muscle is visibly swollen. (Courtesy M. Schaer)

Table 8.2 Diseases causing difficulty or pain on opening of the mouth in dogs.

Masticatory muscle myositis
Temporomandibular joint disorders: ankylosis, osteoarthritis
Retrobulbar masses: cellulitis, abscess, granuloma, neoplasia
Zygomatic arch, coronoid process: fracture
Craniomandibular osteopathy
Tetanus

Box 8.2 Practical tip on collection of temporalis muscle biopsies.

Make sure the subcutaneous platysma muscle is incised, the thick fascia overlying the temporalis muscle is incised and retracted, and the temporalis muscle itself is exposed and biopsied. The platysma muscle does not contain type 2M fibers and is not affected by masticatory muscle myositis.

periods of time result in relapse of the disorder and worsening of the fibrosis.

Prognosis

Prognosis is good with early diagnosis and treatment. If diagnosis and treatment are delayed until marked atrophy and fibrosis are present, prognosis is poor for return of jaw function and muscle mass. Delayed therapy and/or inadequate doses are common causes for poor clinical outcome.

Part 2: Diseases of the esophagus

Overview

The esophagus is a frequently forgotten part of the gastrointestinal (GI) tract. Esophageal diseases occur relatively commonly in dogs, but are infrequent in cats. They may have serious implications and severely debilitate affected animals. The resulting esophageal dysfunction may lead to regurgitation of undigested food with a high risk of food inhalation and aspiration pneumonia. Additionally, chronic esophageal problems may lead to undernourishment and associated complications. Foreign bodies, strictures, and neoplasia may cause intraluminal obstructions. Vascular abnormalities with compression of the esophagus may also compromise the esophageal lumen. Esophagitis is a frequent complication of esophageal diseases and of gastroesophageal reflux and vomiting. Severe cases may result in development of strictures. Congenital or acquired functional disorders cause esophageal dysmotility and may eventually result in megaesophagus (ME).

Esophageal anatomy

The UES consists of striated muscle fibers of both cricopharyngeal and esophageal origin. The two spirally arranged muscularis layers of the esophagus wind in opposite directions. In cats, they consist of striated muscle fibers in the proximal third of the esophagus (cervical segment), while they only contain smooth muscle fibers in the distal two-thirds of the esophagus (thoracic segment). In contrast, the muscularis layers of the canine esophagus are made exclusively of striated muscle fibers over the whole length of the esophagus. The lower esophageal sphincter (LES) is a thickening of the esophageal muscle located before the gastroesophageal junction.

Normal esophageal function

Esophageal motility is triggered by passage of a food bolus through the pharynx (Table 8.1). Afferent impulse

Table 8.3 Clinical signs associated with esophageal diseases in dogs and cats.

Regurgitation Dysphagia Swallowing attempts 'on empty' Halitosis Excessive salivation Odynophagia (esophagitis) Anorexia/inappetence (esophagitis) Ravenous appetite (motility disorders, megaesophagus) Tachypnea, dyspnea, cough, exercise intolerance, fever (aspiration pneumonia)

is conducted by the glossopharyngeal and vagus nerves to the nucleus solitarius in the brainstem. The information is processed with the help of the reticular formation and the nucleus ambiguus, where the motor neurons are located. These are activated and transmit impulses to the vagus nerve.

Clinical presentation

The clinical signs consistent with esophageal disease are summarized in Table 8.3. Regurgitation describes passive retrograde evacuation of undigested food or liquids, and may be associated with pharyngeal or esophageal dysfunction. Differentiation of regurgitation and vomiting relies on several well-defined clinical parameters but can be challenging at times (Table 8.4).

Table 8.4 Parameters that help differentiate regurgitation from vomiting*.

Parameter	Regurgitation	Vomiting
Chronology	Usually occurs immediately or soon after food intake, although exceptions may occur	May occur at any time point, after ingesting a meal or in between meals
Appearance	Typically looks like undigested food covered with saliva	May have many different appearances and look more or less digested. The presence of bile or digested (dark) blood suggests gastric origin
Behavior	Usually occurs without prodromal phase	Often preceded by nausea (frequently with hypersalivation)
Abdominal contractions	Usually absent	Retching typically present
Associated clinical signs	Dysphagia, odynophagia, hypersalivation, repeated swallowing attempts, weight loss if chronic	Nausea, lethargy, anorexia, weight loss
Risk of aspiration pneumonia	High	Moderate

* **Note:** there may be considerable overlap in the signs associated with regurgitation and vomiting.

ESOPHAGEAL OBSTRUCTION

ESOPHAGEAL FOREIGN BODY

Esophageal FBs are a common problem in dogs while they are infrequently diagnosed in cats.

Etiology

In dogs, esophageal FBs are frequently observed in small breeds, but may occur in any size dog. The foreign material often consists of beef, pork, veal, or chicken bone(s) coated with various amounts of connective tissue. Dog treats swallowed with insufficient chewing have also been reported. Fishing hooks when swallowed also get stuck in the esophagus. Esophageal FBs are most often located at one of three sites: thoracic inlet, heart base, or cranial to the distal sphincter of the esophagus.

Clinical presentation

Animals are often presented with a suggestive history (e.g. ingestion of bones, toys missing). The clinical signs typically include regurgitation, dysorexia, excessive drooling, odynophagia, halitosis, and retching. Additional signs (e.g. lethargy, anorexia, dyspnea, shock associated with systemic inflammatory response syndrome [SIRS], or sepsis) may occur in association with complications such as esophageal perforation with mediastinitis or pleuritis, or aspiration pneumonia.

Differential diagnosis

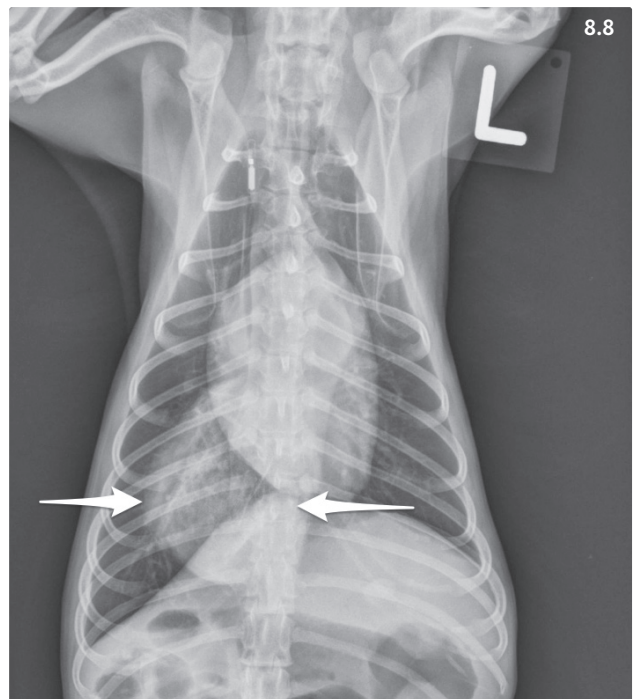
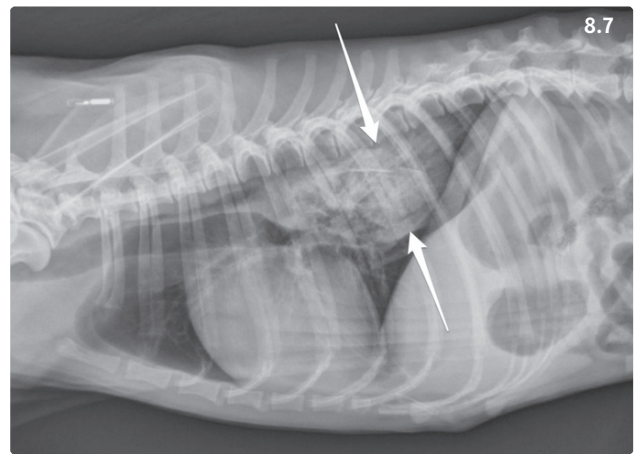
Other esophageal diseases: stricture, esophagitis, ME, and esophageal tumors. Additionally, differentiation between clinical signs of esophageal FB and those of vomiting and associated diseases can be difficult at times (Table 8.4).

Diagnosis

The presence of an esophageal FB is best confirmed using chest radiographs that reveal a soft tissue mass in the esophagus at the level of the obstruction (Figures 8.7, 8.8). In most instances, the use of barium sulfate is not required, and risks associated with its use can be avoided (aspiration pneumonia, damage to endoscopic equipment if esophagoscopy is performed soon after the esophagram). It is important to evaluate radiographs for the presence of free air in the mediastinum and pleural effusion, as these may indicate esophageal perforation or rupture.

Management/prevention

Treatment consists of extracting the FB under endoscopic or fluoroscopic guidance as soon as possible (Figure 8.9). If extraction through the oral cavity is too difficult, the



Figures 8.7, 8.8 Four-year-old male Papillon Spaniel. (8.7) Right lateral thoracic radiograph. A large soft tissue opacity is visible in the caudal half of the thoracic esophagus (dorsal and ventral limits shown by arrows). Interpretation: esophageal foreign body without indication of esophageal perforation and pleuritis. (8.8) The ventrodorsal thoracic radiograph shows the same soft tissue opacity in the esophagus caudal to the heart base (arrows).

FB can be pushed into the stomach. Bone, cartilage, and fibrous tissue material can generally be digested by gastric juice and eliminated naturally. If passage through the pyloric canal seems impossible, gastrotomy and extraction of the FB is performed.

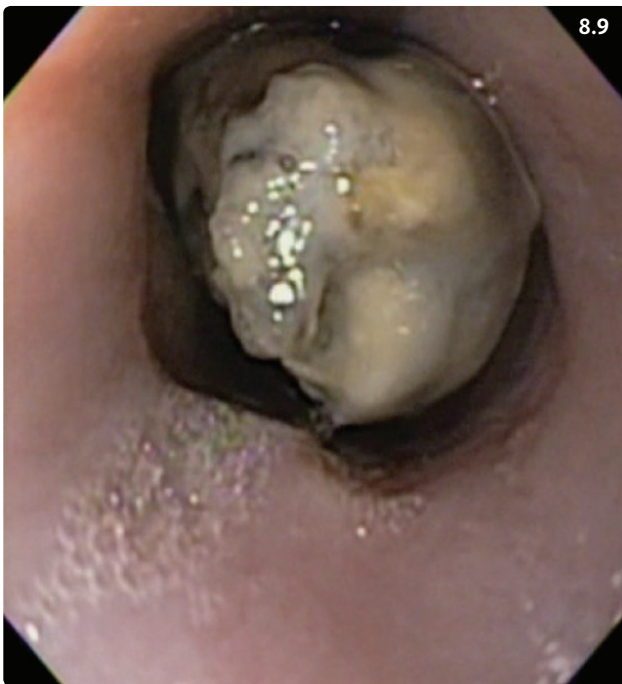

Figure 8.9 Esophagoscopy showing a bone foreign body in the caudal thoracic esophagus.

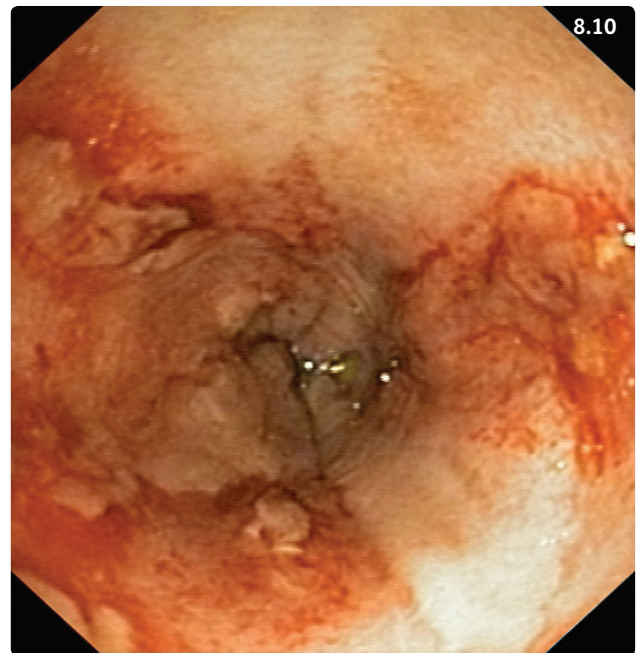


Figure 8.10 Endoscopic view of moderate esophageal mucosal lesions located cranial to the lower esophageal sphincter after removal of an esophageal foreign body in a dog. (Courtesy R. Husnik)

In case of esophageal perforation or rupture, a surgical approach is generally necessary. If severe esophageal mucosal lesions are present following extraction, a 24–48-hour fasting period is recommended. In the most severe cases, endoscopic placement of a regular or low profile gastrostomy tube is required to provide nutrition without compromising mucosal healing for the period following FB removal. Additionally, treatment of esophagitis and prevention of gastroesophageal reflux and further esophageal mucosal damage is recommended (see Esophagitis).

Access to bones or disproportionately large pieces of meat that are unlikely to reach the stomach should be limited if the dog does not chew them. Five to six ml of water should be administered with a syringe after pilling cats with any drug, but particularly doxycycline and clindamycin tablets.

Prognosis

Generally, the prognosis for esophageal FB after nonsurgical removal is good to excellent. Esophagitis is present in up to 80% of dogs after FB removal (**Figure 8.10**), but seems to resolve relatively rapidly. Esophageal strictures are a feared complication that may develop over time, particularly in dogs with severe esophageal mucosal lesions.

BENIGN ESOPHAGEAL STRICTURE

Strictures occur less commonly than FBs in dogs and in cats.

Etiology/pathophysiology

Benign strictures are a complication of severe esophagitis (FB, gastroesophageal reflux, dry swallow of pills to cats, ingestion of caustic substances). They occur with deep inflammation when lesions extend to the submucosa and muscularis layers of the esophageal wall. They are characterized by excessive scar tissue formation with narrowing of the esophageal lumen and resulting partial or total obstruction.

Clinical presentation

The history often reveals esophageal disease (for instance esophageal FB) or general anesthesia (with gastroesophageal reflux) prior to the development of signs. The animal shows frequent regurgitation, which can be associated with a particular food consistency. A dog with esophageal stricture may regurgitate dry food but not a puréed diet. Moreover, the clinical signs typical of esophagitis may also be present.

Differential diagnosis

See Esophageal foreign body.

Diagnosis

Thoracic radiographs are useful to rule out other causes of esophageal obstruction (e.g. esophageal FB, external compression). Diagnosis is confirmed either by esophagoscopy (**Figure 8.11**) or contrast esophagram. Administration of contrast agents may lead to aspiration pneumonia, and may damage endoscopic equipment if an esophagoscopy is performed soon after the contrast study. If esophageal perforation is suspected, and an esophagram is indispensable, low osmolar iodinated contrast agents are preferred over barium sulfate. It is essential to differentiate stricture of the esophageal lumen from external compression.

Management

Treatment involves dilating the stricture(s) under endoscopic or fluoroscopic control using balloons of different diameters (**Figures 8.12, 8.13**) or 'bougies' of different sizes. Multiple sessions at intervals of 1–2 weeks are often necessary. Submucosal injection of triamcinolone at the level of the stricture prior to dilation or bougienage can help reduce the number of procedures required (**Figure 8.14**). Drug therapy is similar to that for esophagitis (see below). Systemic administration of prednisone/prednisolone is ineffective. Esophageal stenting is an option to consider in cases refractory to dilation attempts.

Prognosis

Without treatment, the prognosis is poor to grave due to the risk of aspiration pneumonia and malnutrition. After stricture dilation, the prognosis is guarded to good: several dilation attempts may be required to re-establish patency of the lumen for a normal size food bolus. In some instances, patency can only be partially restored, thus requiring liquid or moist food (and not dry kibbles) to be fed. Occasional regurgitation episodes may not be avoidable.

OTHER CAUSES OF OBSTRUCTION

VASCULAR RING ANOMALIES

Vascular ring anomalies cause entrapment of the esophagus at the level of the heart base. The most common vascular ring anomaly is persistent right aortic arch (PRAA), which is characterized by the presence of a fibrous band that connects the main pulmonary artery and the anomalous aorta and causes extraluminal compression and entrapment of the esophagus. Regurgitation typically occurs when puppies or kittens are weaned to solid food, and aspiration

pneumonia is a common complication. Affected puppies are generally hungry and with time become malnourished and lose weight. Diagnosis relies on the typical history and clinical signs, and is confirmed with thoracic radiographs that reveal esophageal dilation cranial to the heart base and deviation of the trachea to the left, cranial to the cardiac silhouette that is visible on ventrodorsal or dorsoventral views (**Figures 8.15–8.17**). Treatment of vascular ring anomalies consists of thoracotomy and transection of the compressive fibrous band. Prognosis of PRAA is generally good after surgery. In some cases, normal motility may not return if the cervical esophagus was very dilated or if an esophageal diverticulum was formed. While most dogs are reported to do well, some may need continuous support such as upright feeding (see Megaesophagus, Management).

ESOPHAGEAL TUMORS

Esophageal tumors occur rarely. Leiomyoma is the most common benign neoplasm in dogs, and often occurs in the caudal esophagus. Fibrosarcoma and osteosarcoma may develop in dogs infected with *Spirocerca lupi* (see below). Other tumors include leiomyosarcoma, lymphoma, and metastatic lymphoma. The most common primary esophageal neoplasia of cats is SCC. Clinical signs may be very discrete unless the tumor causes significant luminal obstruction. Diagnosis relies on radiographs, which may show esophageal dilation cranial to the mass. A contrast esophagram may be helpful. Esophagoscopy is required for final confirmation, with collection of biopsies for histopathologic analysis. Tumor excision with esophageal resection and anastomosis can be attempted, but the surgical procedure may be associated with post-operative morbidity. Esophageal stenting is a palliative option to consider.

ESOPHAGITIS

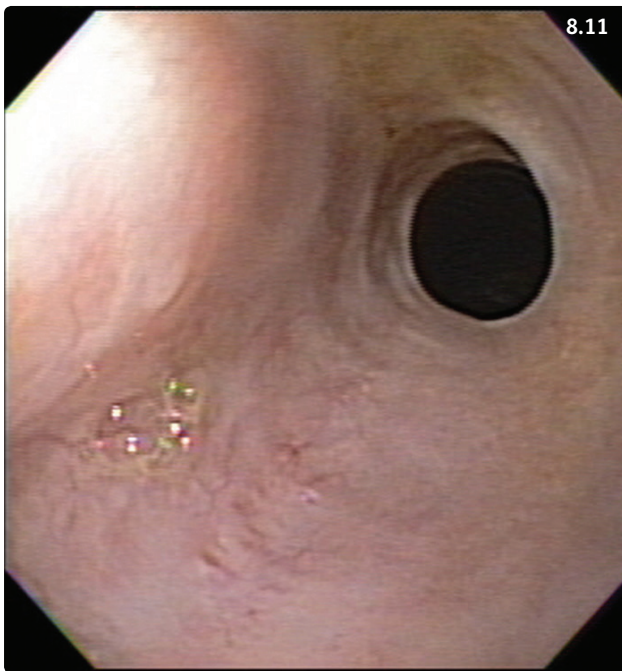
Definition/overview

Esophagitis is a disease characterized by inflammation of the esophageal mucosa. It may occur in dogs and cats, and mild cases may go unnoticed.

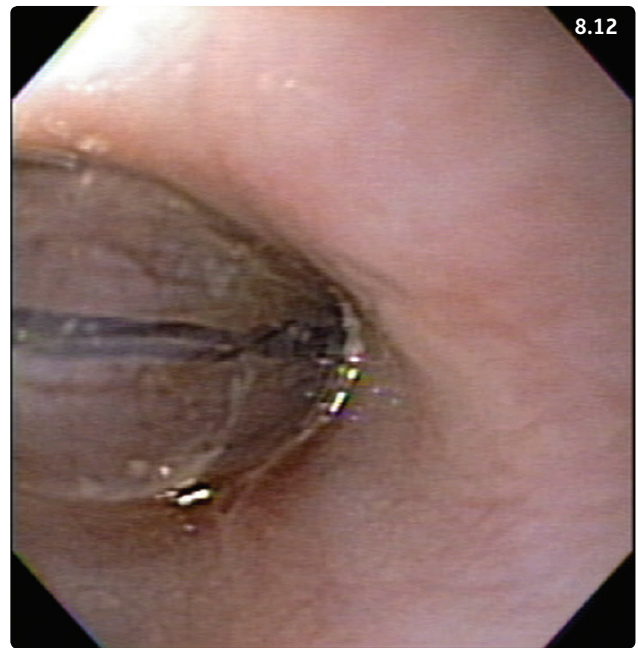Etiology/pathophysiology

Noninfectious inflammation

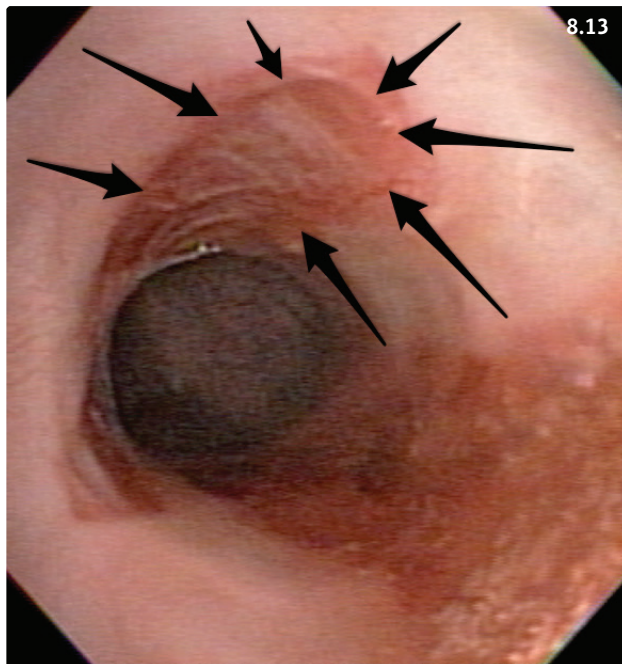
The esophageal mucosa may easily be damaged by gastric acid and bile in gastroesophageal reflux disease, as gastric acid induces the formation of proinflammatory cytokines in the esophageal mucosa (**Figure 8.18**). Esophagitis may be a complication of LES relaxation during general anesthesia. Esophagitis may also occur in animals with frequent and severe vomiting. In addition,



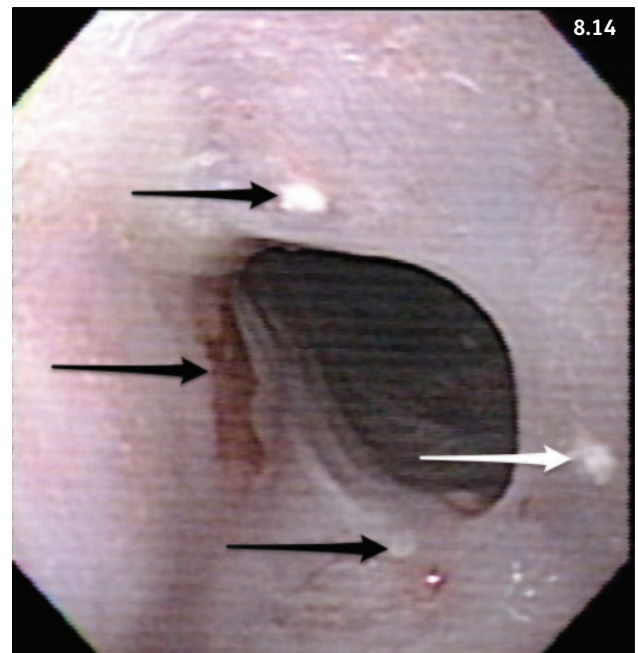
8.11



8.12

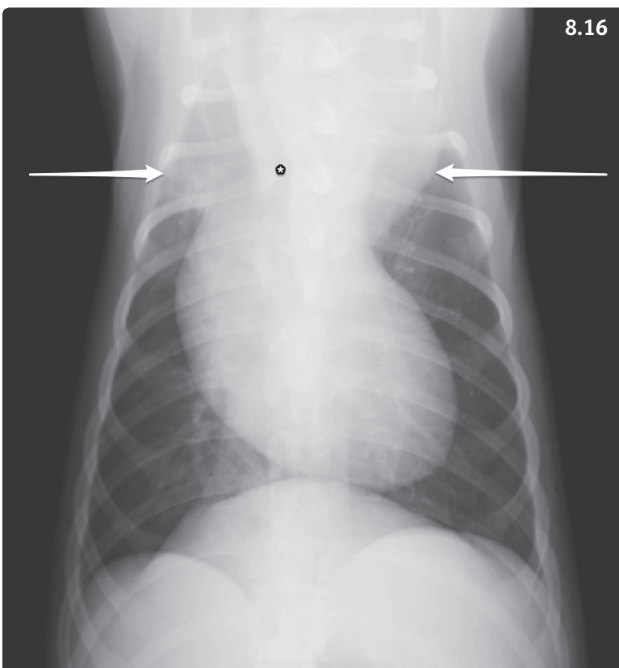
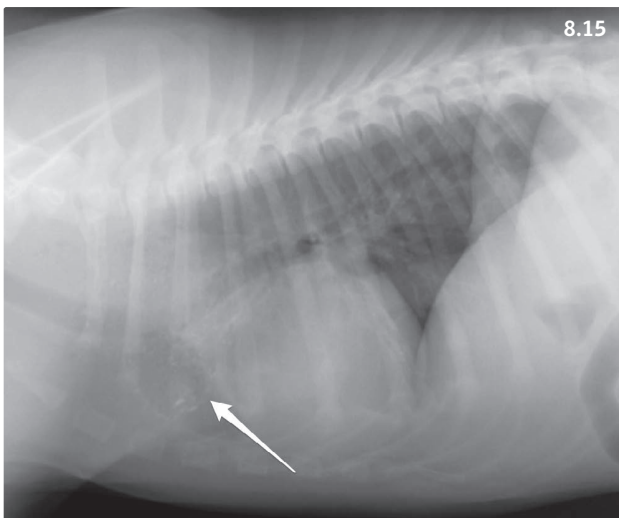


8.13



8.14

Figures 8.11–8.14 Esophageal stricture in a 3-year-old female spayed Golden Retriever with a 2-week history of regurgitation. The regurgitation was attributed to severe reflux esophagitis associated with an intestinal foreign body and concurrent pancreatitis. Note the narrowed esophageal diameter due to a fibrous ring. (8.11) A balloon catheter filled with saline is in place to dilate the stricture. (8.12) The dog after balloon dilation of the stricture. (8.13) There is a tear in the dorsal esophageal mucosa exposing the underlying structures (arrows). Esophageal tear and perforation are possible complications of stricture dilation. A conservative approach is indispensable during dilation attempts with increasing balloon sizes. (8.14) 0.5 ml triamcinolone acetate 20 mg/ml is injected submucosally in four sites at the base of the stricture (arrows).



Figures 8.15, 8.16 A 3-month-old German Shepherd Dog with a persistent right aortic arch. (8.15) Lateral radiograph. The dilated esophagus is seen as a soft tissue opacity in the cranial mediastinum that displaces the trachea ventrally. Note the presence of granular material in the dilated esophagus cranial to the cardiac silhouette (arrow). (8.16) Ventrodorsal radiograph. The dilated esophagus is recognizable as a structure of soft tissue density in the cranial mediastinum (white arrows). Note the deviation of the trachea to the left cranial to the heart base (arrows).

esophageal FBs and swallowing of caustic substances may cause esophageal mucosal inflammation. In cats, administration of doxycycline, clindamycin, and other drugs in

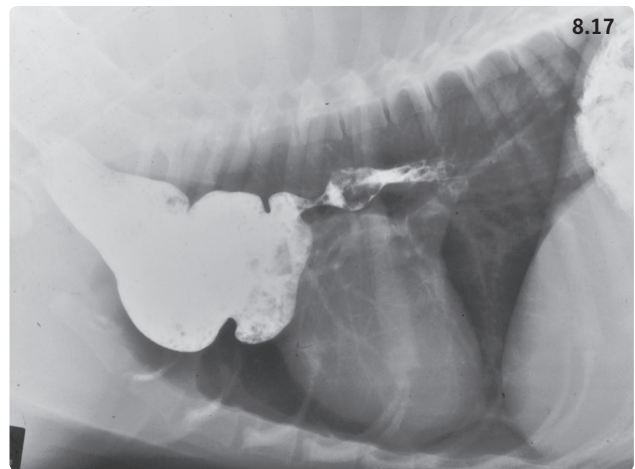


Figure 8.17 Contrast esophagram of a dog with a persistent right aortic arch. The dilated esophageal pouch located in the cranial mediastinum is clearly visible.

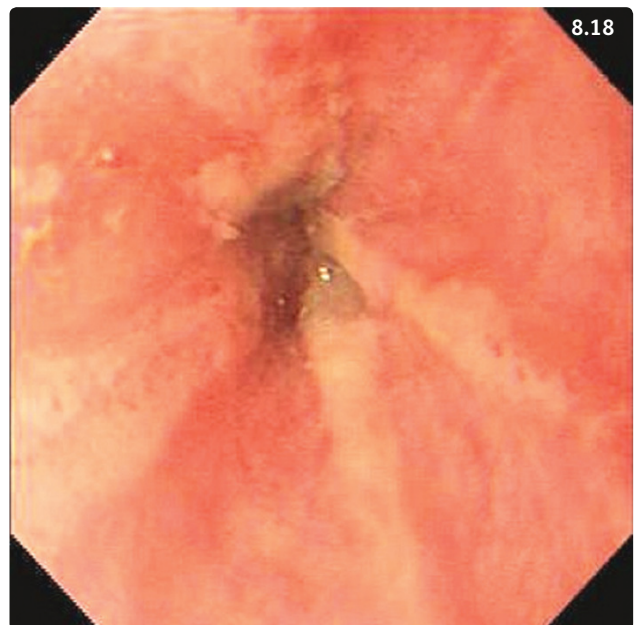


Figure 8.18 Esophagoscopy showing severely inflamed esophageal mucosa surrounding the lower esophageal sphincter due to gastroesophageal reflux. (Courtesy M. Schaer)

the form of oral tablets without subsequent water flush may cause severe esophagitis and possibly esophageal stricture.

Infectious inflammation

In endemic areas (worldwide tropical and subtropical regions), *Spirocerca lupi* is a common cause of esophagitis. The ingested larvae migrate extensively and eventually mature into adults after a prepatent period of 3–9 months.

The adult worms generally inhabit the esophageal submucosa and adventitia, and cause the formation of granulomatous nodules of less than 1 cm to more than 4 cm diameter in the caudal esophageal wall. Esophageal infections with the oomycetal agent *Pythium insidiosum* occur infrequently in endemic areas (worldwide tropical and subtropical regions), and may cause severe esophagitis.

Clinical presentation

Clinical signs are characteristic of esophageal diseases (Table 8.3). Mild cases of esophagitis may remain subclinical or mild signs may go unnoticed by the owners.

Differential diagnosis

Includes all the other esophageal diseases described in this chapter.

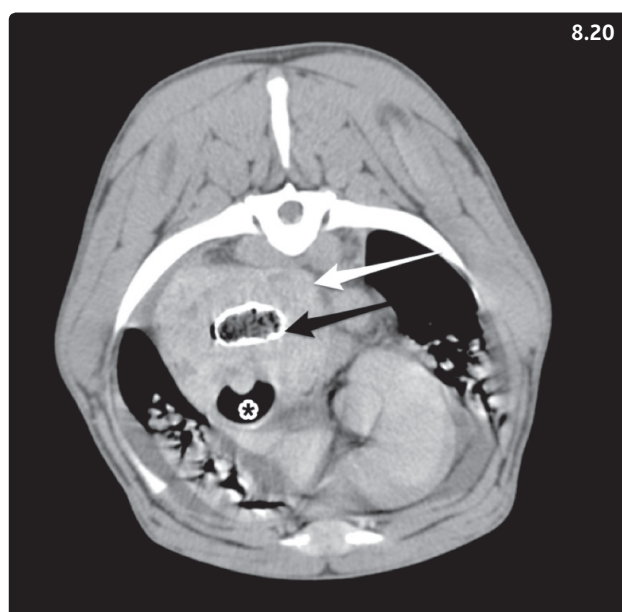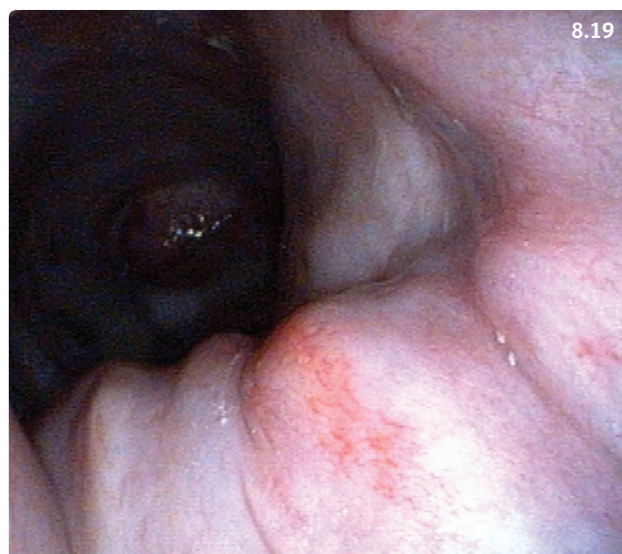Diagnosis

A tentative clinical diagnosis is made on the basis of clinical signs and history. Confirmation of diagnosis and assessment of the extent and severity of lesions requires endoscopic examination. Collection of esophageal wall biopsies is often challenging, but histologic evaluation may yield additional information on the cause of the esophagitis. For the diagnosis of spirocercosis, diagnostic tests have the following sensitivities: esophagoscopy 100% (Figure 8.19), presence of parasite ova on fecal flotation 80%, and radiographic detection of esophageal nodules 50%. Diagnosis of esophageal pythiosis relies on histopathology and immunochemical stains of esophageal biopsies. The typical esophageal wall thickening with involvement of local lymph nodes may be apparent on thoracic radiographs, ultrasound, and CT (Figure 8.20). An ELISA test for serum antibodies is available.

Management

Symptomatic treatment of esophagitis is focused on protection of the mucosa against further damage and facilitation of mucosal healing. Fasting for 24–48 hours is recommended, if feasible without compromising the dog's condition. In severe cases, placement of a gastrostomy tube via endoscopy or surgery is beneficial to provide enteral nutrition and prevent complications associated with malnutrition. A diet low in fat is recommended because high fat diets may be associated with increased episodes of gastroesophageal reflux.

Sucralfate suspension is used to promote mucosal healing (1 g q8h for large dogs, 0.5 g q8h for smaller dogs). Inhibitors of gastric acid secretion, preferably a proton pump inhibitor such as omeprazole (1mg/kg PO q12h), and a prokinetic agent that accelerates gastric emptying (metoclopramide, 0.5 mg/kg PO, SC q8h, or CRI of 1–2 mg/kg



Figures 8.19, 8.20 Mixed-breed dog with dysphagia and esophageal obstruction. (8.19) Esophagoscopy shows an irregular mucosal surface. (8.20) Post-contrast CT scan of the cranial mediastinum. The esophageal wall is severely and irregularly thickened (white arrow, serosal surface; black arrow, mucosal surface covered with a fine layer of barium; asterisk, trachea). (Courtesy LSU SVM Diagnostic Imaging Service)

over 24h) or promotes gastric emptying and increases the distal esophageal sphincter tone (cisapride, 0.5–1 mg/kg PO q8h) should be administered, preferably 30–60 minutes before meals.

Treatment of spirocercosis consists in administration of specific parasiticides. Doramectin is an avermectin

licensed for use in cattle but used off-label in dogs. Recommended protocols include 0.2–0.4 mg/kg SC every 14 days for 3–6 injections, or 0.5 mg/kg PO q24h for 6 weeks. These very high doses of avermectins must not be administered to Collies and other herding breeds that are prone to develop potentially lethal central nervous complications due to a mutation in the MDR-1 gene.

Treatment of esophageal pythiosis is challenging. Surgical excision of the lesion with safe tissue margins is the preferred treatment of GI pythiosis but is not feasible in the esophagus. Medical treatment of unresectable pythiosis is often unrewarding (itraconazole, 10 mg/kg PO q24h and terbinafine, 5–10 mg/kg PO q24h). Anti-inflammatory doses of prednisone can be used in the hope of decreasing local inflammation and to palliate clinical signs.

Prognosis

Noninfectious inflammation

Mild and moderate cases generally have a good prognosis. Severe inflammatory mucosal lesions may lead to esophageal stricture development.

Infectious inflammation

Esophageal neoplasia (osteosarcoma, fibrosarcoma) is a common complication of *S. lupi* infection and requires a surgical approach if the mass significantly obstructs the esophageal lumen. Esophageal pythiosis carries a poor to grave prognosis.

MEGAESOPHAGUS

Definition/overview

ME is characterized by generalized dilatation of the esophagus. It is the most common cause of regurgitation and a common esophageal disease in dogs, but is a rare occurrence in cats.

Etiology

Congenital ME occurs in puppies and rarely in kittens, while acquired ME is seen mostly in middle aged to older adult animals. The diseases frequently associated with ME in the dog are listed in **Table 8.5**. Among those, idiopathic ME and ME secondary to focal myasthenia gravis (MG) are most common. Acquired ME is also a feature of feline and canine dysautonomia.

Pathophysiology

With the exception of focal MG, the pathogenesis of canine and feline ME has not been fully elucidated. In dogs with MG, autoantibodies are formed against nicotinic

acetylcholine receptors located at the neuromuscular junction in striated muscle. MG is discussed in further detail in Chapter 12 (Disorders of the nervous system and muscle). Congenital ME and other forms of acquired ME most likely result from malformation or changes in the complex neural network responsible for esophageal innervation.

Miniature Schnauzers, Fox Terriers, German Shepherd Dogs, Great Danes, Irish Setters, Labrador Retrievers, Shar Peis, and Newfoundlands are at increased risk for development of primary idiopathic ME.

Clinical presentation

The clinical signs are similar to those of other esophageal diseases (**Table 8.3**), and regurgitation is the most frequent complaint in dogs with ME. Secondary esophagitis is a common complication. The risk of aspiration pneumonia is high; accordingly, affected animals may present with exercise intolerance, cough, tachypnea, and dyspnea.

Differential diagnosis

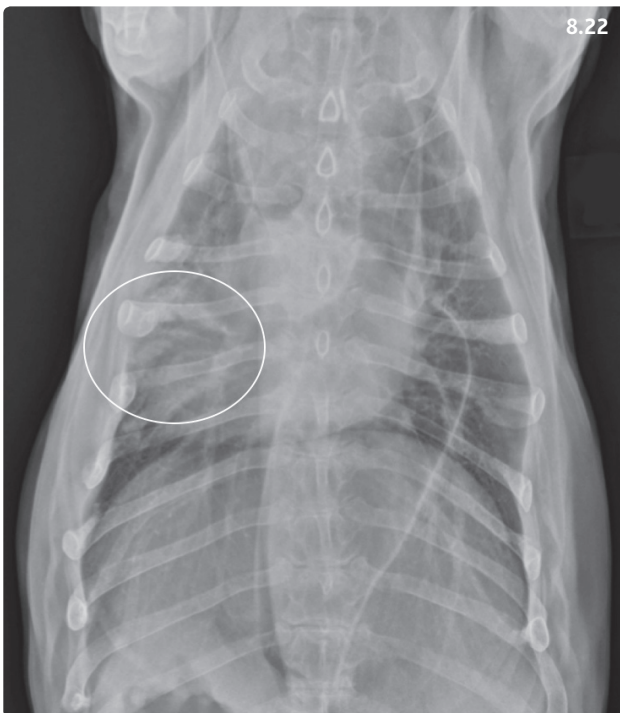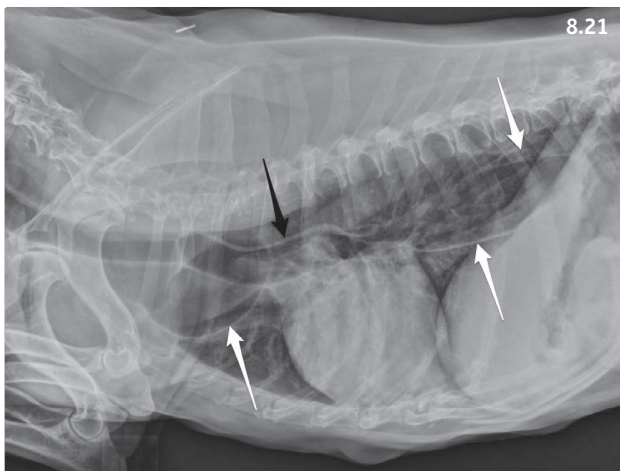
Includes all the other esophageal diseases described in this chapter.

Diagnosis

The first step in the diagnostic approach is to rule out esophageal obstruction (FB, stricture) by taking a detailed history and obtaining good quality thoracic radiographs. A generalized dilatation of the esophagus is usually easily identified on the thoracic films (**Figures 8.21, 8.22**). It is important to carefully check for aspiration pneumonia in these patients. This is best done by thoroughly examining the distal parts of the lung lobes, in particular the right middle, and left and right cranial lobes for presence of interstitial or alveolar infiltrate (**Figure 8.22**).

Table 8.5 Causes of megaesophagus in the dog.

Congenital megaesophagus: <ul style="list-style-type: none"> • Congenital myasthenia gravis • Congenital neuropathy
Acquired megaesophagus: <ul style="list-style-type: none"> • Idiopathic megaesophagus • Myasthenia gravis • Esophagitis • Endocrine diseases (hypoadrenocorticism, possibly hypothyroidism) • Toxicosis (e.g. lead toxicity) • Polymyositis, polyneuropathy • Less common causes: other neurologic diseases (botulism, tetanus, dysautonomia, rabies), systemic lupus erythematosus



Figures 8.21, 8.22 Nine-year-old female spayed Basset Hound with megaesophagus due to focal myasthenia gravis. (8.21) Right lateral radiograph. The white arrows point to the dorsal and ventral walls of the esophagus, which are both clearly visible. The black arrow points to summation of the dorsal tracheal and ventral esophageal walls (tracheal stripe sign). (8.22) Ventrolateral radiograph. The walls of the dilated esophagus are clearly visible in the caudal mediastinum. Air bronchograms within the circle are indicative of aspiration pneumonia in the caudal subsegment of the left cranial lung lobe.

The systematic approach is continued by screening animals for primary diseases associated with secondary ME. A minimal database consisting of CBC,

biochemistry panel (including serum CK), and urinalysis is recommended. Next, screening for endocrinopathies (adrenocorticotropic hormone [ACTH] stimulation test, possibly serum thyroxine and endogenous thyroid-stimulating hormone [TSH]), and a search for opacities in the cranial mediastinum (looking for possible thymoma associated with MG) are recommended. A sensitive and specific serum assay documenting the presence of auto-antibodies against nicotinic acetylcholine receptors is available for the diagnosis of MG (<http://vetneuromuscular.ucsd.edu>). Endoscopic examination of the esophagus may be useful in unclear cases and to allow visualization of the extent and severity of the esophagitis, if present. In cases with suspected polymyositis or polyneuropathy, electrodiagnostics (EMG, nerve conduction studies) and collection of muscle and nerve biopsies for histopathologic evaluation should be considered.

Management

Dietary management is essential. It is important to try various options such as dry food kibbles, canned food formed into meat balls, and food blended with water in different consistencies (thick or thin slurry) because each animal may respond differently. Dogs and cats with ME should be fed a calorie-dense diet in a vertical position and be maintained in that position for 10–15 minutes after the meal in order to use gravity to facilitate aboral movement of the food bolus. Small dogs can be held on a person's lap for that time. Medium size and large dogs can be fed on stairs and maintained with their forelimbs higher than their hindlimbs. The Bailey chair is a useful device to keep medium size and large dogs in a vertical position during and after meals (**Figure 8.23**). This aspect of treatment can be a challenge for dogs with pre-existing orthopedic diseases such as coxofemoral arthritis.

In severe cases, placement of a gastrostomy tube may be beneficial to ensure appropriate nutrition and timely delivery of oral medications to the stomach, and to prevent aspiration pneumonia.

Identified underlying diseases need to be treated. For instance, the recommended treatment of MG includes administration of the acetylcholinesterase inhibitor pyridostigmine (1–3 mg/kg PO q12h, start with a low dose to minimize risk of cholinergic crisis) and immunosuppressive doses of prednisone or prednisolone (1–2 mg/kg PO q12h).

Cisapride and erythromycin increase LES tone in dogs; however, gastric prokinetic drugs do not significantly influence esophageal motility. Bethanechol is a cholinergic agent that has been shown to increase esophageal motility in some dogs and can be used in the management of clinical cases of idiopathic ME (5–15 mg/dog PO q8h,



Figure 8.23 A 10-year-old female spayed Border Collie with idiopathic megaesophagus eating in a custom-made Bailey's chair. The dog is kept in an upright position in the chair for 20 minutes after each meal.

start with a low dose to minimize risk of cholinergic crisis). Because of the high prevalence of esophagitis in patients with ME, sucralfate suspension should be administered to facilitate mucosal healing (0.5–1.0 g/dog q8h, 0.25–0.5 g/cat q8–12h). Treatment of aspiration pneumonia is mostly supportive. If secondary bacterial infection is suspected, antibiotic treatment is best based on culture and sensitivity from a bronchial wash; however, empiric treatment with a broad-spectrum antibiotic may be necessary in some cases (e.g. amoxicillin and clavulanic acid, ampicillin and sulbactam).

Home management of pets with ME is complex and time-consuming. Owners may feel overwhelmed and discouraged at first. Therefore, optimal communication between the veterinary care team and the animal's owners is essential for successful management of this condition (**Box 8.3**).

Prognosis

Recent studies from Scotland and Germany reported a short median survival time of 3 months after diagnosis regardless of the etiology in dogs with ME. In the Glasgow study, only 41% of dogs survived 1 year, 31% were alive at

Box 8.3 Practical tip for support of owners of dogs with megaesophagus.

The management of dogs with megaesophagus requires considerable dedication from the pet's owners and can be overwhelming at times. Clients should be made aware of the existence of support groups on the internet (type 'megaesophagus support group' in your favorite search engine). These groups provide useful tips to optimize the quality of homecare and to make it possible for owners to include these new tasks in their busy daily routines.

2 years, and 22% survived for 5 years. Identified risk factors for shorter survival were dogs older than 13 months of age at the time of diagnosis and presence of aspiration pneumonia at diagnosis. ME may be reversible when associated with endocrinopathies, but this represents only a small percentage of dogs with ME.

LESS COMMON ESOPHAGEAL DISEASES

Esophageal diverticulum is defined as a circumscribed outpouching of the esophageal wall that may be congenital or acquired. Congenital diverticula result from abnormal embryologic development of the esophagus. Acquired diverticula are classified as either traction (resulting from periesophageal inflammation) or pulsion forms (resulting from increased esophageal luminal pressure). Esophageal diverticula generally appear in three locations: pharyngo-esophageal, midthoracic, or caudal thoracic. The accumulation of ingesta within diverticula leads to esophagitis with disturbed esophageal motility and possibly obstruction. The clinical signs are typical of esophageal disease (**Table 8.3**). Plain radiographs should be evaluated for the presence of an air- or food-filled soft tissue density representing the impacted diverticulum, signs of aspiration pneumonia, and/or esophageal dilation. A positive contrast esophagram usually demonstrates a deviation or outpouching of the esophageal lumen. Small diverticula may be managed medically by feeding a soft, bland diet with the animal in an upright position to avoid food accumulation in the pouch. Large diverticula generally require excision and reconstruction of the esophageal wall. Prognosis is good if the diverticulum is uncomplicated by lung adhesions, abscesses, or bronchoesophageal fistulas.

Esophageal fistula is an abnormal communication between the esophageal lumen and surrounding structures. The most common fistula in the dog is the bronchoesophageal fistula (BEF) due to trauma caused by a retained sharp esophageal FB. Most canine BEFs due to

an esophageal FB connect the esophagus with either the right caudal or the middle lung lobe bronchus. Physical examination may reveal coughing, dyspnea, respiratory crackles over affected lung regions, hemoptysis, anorexia, depression, weight loss, regurgitation, and dysphagia. Coughing associated with drinking liquids is a sign frequently associated with BEF. Survey thoracic radiographs may reveal radiopaque foreign bodies in the esophagus or bronchus, pulmonary consolidation, pleural fluid accumulation, or localized interstitial, alveolar, and/or bronchial lung patterns. Contrast esophagram or esophagoscopy is required for definitive diagnosis. Treatment consists of thoracotomy and surgical correction of the fistulous tract. Lung lobectomy may be necessary if extensive pulmonary lesions are present. Prognosis ranges from good to guarded depending on the preoperative condition of the patient, the ability to resolve pulmonary infection, and the success of surgery.

HIATAL HERNIA

Definition/overview

Hiatal hernia involves herniation of parts of the stomach through the esophageal hiatus into the mediastinum. Four types of hiatal hernias (HHs) have been described in people, and most cases documented in dogs and cats are type I or sliding HH.

Etiology/pathogenesis

Type I HHs are usually due to a congenital weakness of the esophageal hiatus. They have been reported most frequently in Shar Peis and English Bulldogs and also in cats. Acquired type I HH may occur following trauma or in combination with obstructive upper respiratory disease and abnormally high negative intrathoracic pressure during inspiration, such as may occur in dogs with brachycephalic syndrome and laryngeal paralysis.

Clinical presentation

Common clinical signs are due to the secondary reflux esophagitis and include regurgitation, hypersalivation, vomiting, dysphagia, dyspnea, anorexia, and weight loss. Puppies and kittens are presented at the time of weaning to solid food, but onset of clinical signs can also be delayed into adulthood. Aspiration pneumonia is possible and affected animals may show typical respiratory signs.

Differential diagnosis

Esophageal diseases, in particular esophageal obstruction (FB, stricture), vascular ring anomaly in puppies, and acute or chronic gastritis.

Diagnosis

Diagnosis is confirmed with survey thoracic radiographs (Figure 8.24) and positive contrast esophagram (Figure 8.25) to confirm the type of HH. Sliding hernias may not be visible at the time of the examination, and fluoroscopy may be required for confirmation. The HH

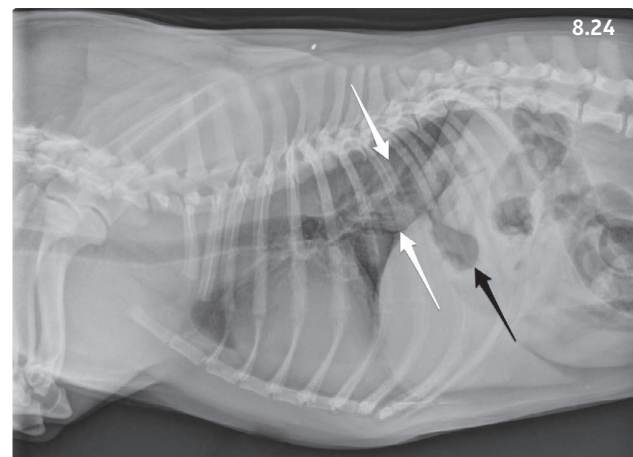


Figure 8.24 Right lateral thoracic radiograph of a 1-year-old male French Bulldog with hiatal hernia. The stomach is not in a normal anatomic position within the abdomen (black arrow) and is displaced cranially into the caudal thorax and confluent with the soft tissue opacity in the region of the esophagus (white arrows). (Courtesy LSU SVM Diagnostic Imaging Service)

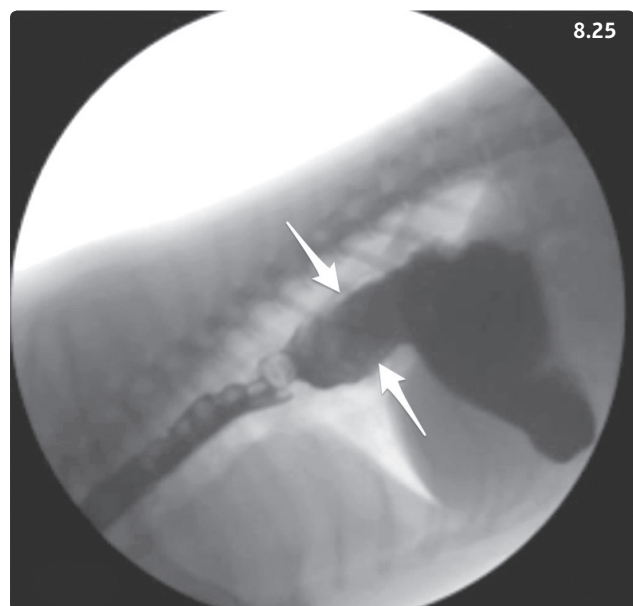


Figure 8.25 Right lateral view from a 6-year-old male neutered Welsh Corgi with dysphagia and sliding hiatal hernia. The arrows show the dorsal and ventral walls of the herniated stomach.

may also be viewed using ultrasound from an abdominal approach. Esophagoscopy allows visualization of the extent and severity of the esophagitis.

Management

Medical management is aimed at treating the secondary esophagitis and protecting esophageal mucosa from further damage (see Esophagitis, Management). A 30-day trial of medical therapy is often recommended prior to making plans for surgical correction as it may cause clinical signs to abate with restitution of adequate quality of life in a significant proportion of dogs. However, medical treatment was not successful in a series of Shar Peis presented before the age of 5 months, and surgery was recommended with no delay in such puppies. Surgical techniques include reduction of the abnormal diaphragmatic hiatus (phrenoplasty), esophagopexy, and left-sided gastropexy used alone or in combination. Clinical signs may persist after surgical reduction until resolution of secondary esophagitis.

Prognosis

Prognosis for dogs and cats with HH is generally good. Animals that respond to medical management will probably require long-term treatment (continuous or intermittent). If medical treatment fails, surgical correction has a favorable outcome in most cases.

Part 3: Diseases of the stomach

Overview

Gastric diseases are common in dogs and cats. The stomach plays a key role in the digestive process through gastric acid and pepsinogen production. It functions both as a storage organ (fundus and body) and as a grinder (antrum), reducing the size of food particles until they are small enough to pass through the pyloric sphincter, and be further processed in the small intestine.

Gastric anatomy

The stomach can be divided into five anatomic parts: cardia, fundus, body, pyloric antrum, and pylorus. The mucosa of the fundus and body folds into countless gastric glands that are lined with cells responsible for secretion of acid (parietal cells), mucus (neck cells), pepsinogen (chief cells), and GI hormones (endocrine cells) (Figure 8.26). The pyloric mucosa is thinner, and contains a lower density of glands. Pyloric glands mostly consist of mucous cells and endocrine cells (many of them producing gastrin).

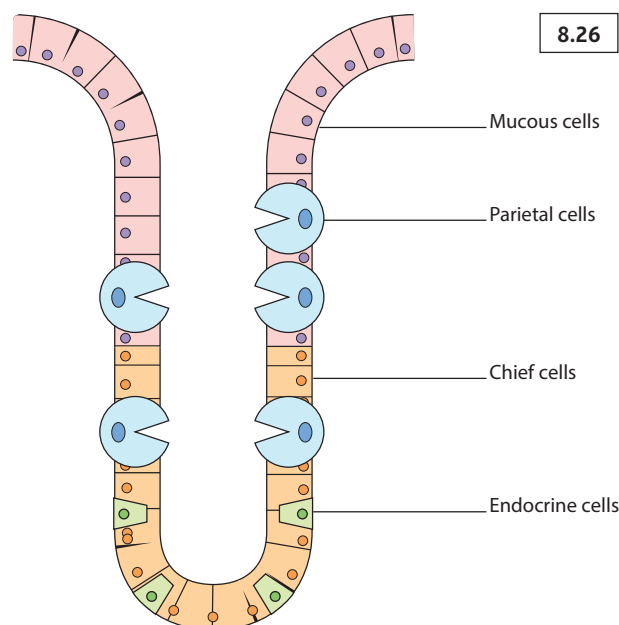


Figure 8.26 Schematic representation of the microscopic anatomy of a canine gastric gland.

Normal gastric function

Acid and enzyme production

While unstimulated gastric acid production is minimal in dogs and cats, postprandial acid production is considerable, with gastric acidity reaching a pH as low as 1 or less. Acid is produced in the parietal cells in response to three types of stimuli: activation of histamine type 2 receptors by histamine produced by neighboring enterochromaffin-like cells; muscarinic type 3 receptors activated by vagal nerve endings; or gastrin receptors (also called CCK type 2 receptors) activated by gastrin produced by antral G-cells (Figure 8.27). Enzyme secretion is limited to pepsinogen, released by chief cells and broken down to the proteolytic enzyme pepsin, and gastric lipase.

Gastric motility

After ingestion of solid food, the gastric antrum acts as a pump from which peristaltic waves originate while the gastric body acts as a high compliance reservoir. The mechanical action of the antral pump is divided into three phases: (1) propulsion, (2) emptying of fine particles into the duodenum and mixing, and (3) retropulsion of particles >1–2 mm for continued grinding. In dogs, complete emptying of the stomach is followed by synchronized housekeeping contractions (phase III migratory motor complexes).

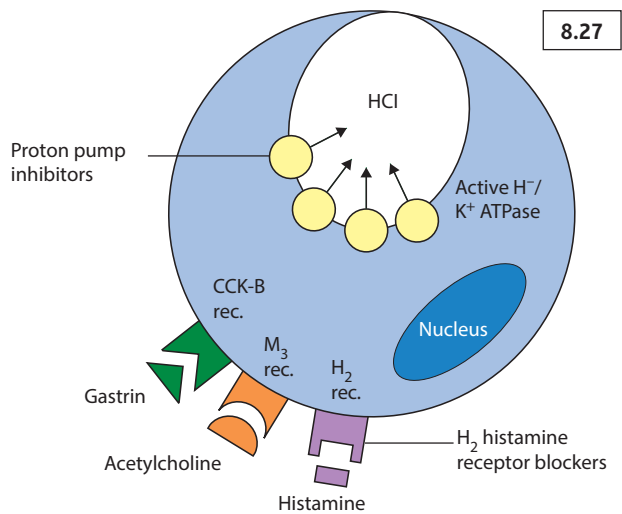


Figure 8.27 Schematic representation of a canine parietal cell. Apical proton pumps actively secrete protons into the glandular lumen under stimulation by one of three basolateral receptors: CCK-B (gastrin), M_3 (acetylcholine), and histamine type 2. The site of action of proton pump inhibitors and H_2 histamine receptor blockers is illustrated.

GASTRITIS

ACUTE GASTRITIS

Definition/overview

Acute gastritis is a clinical syndrome that occurs commonly in dogs and occasionally in cats. The diagnosis is rarely confirmed histopathologically, and affected animals are usually treated symptomatically with good success.

Etiology

The most common cause of acute gastric inflammation is dietary indiscretion or food intolerance. Other common causes include gastric FBs (including hairballs), drugs (e.g. antibiotics, nonsteroidal anti-inflammatory drugs [NSAIDs]), toxins (plant material, bleach, cleaners, heavy metals), bacteria (*Helicobacter* spp.), toxins, and viruses. Additionally, acute gastritis may also be associated with diseases primarily affecting other organs (e.g. hypoadrenocorticism, acute kidney injury, acute hepatitis, cholangitis, cholecystitis).

Clinical presentation

Sudden-onset vomiting, possibly associated with dysorexia and lethargy. Hematemesis may occur as well. The history may reveal exposure to spoiled food, drugs, or toxins. Untreated animals become dehydrated and hypovolemic.

Hypokalemia may occur as well due to potassium loss associated with vomiting and metabolic alkalosis.

Differential diagnosis

Other diseases causing sudden onset vomiting such as GI FB, acute pancreatitis, endocrine diseases (e.g. hypoadrenocorticism, diabetic ketoacidosis), acute kidney injury (e.g. toxicosis with ethylene glycol or grapes/raisins, Easter lily, leptospirosis), acute hepatitis, cholangitis, or cholecystitis.

Diagnosis

History and clinical signs are usually suggestive. Abdominal radiographs should be obtained in order to rule out the presence of a GI FB. Underlying diseases should be ruled out, particularly in older animals or in atypical cases, with the help of a minimal database (CBC, serum biochemistry, urinalysis).

Management

Treatment is mostly symptomatic and consists of antiemetics, parenteral fluids to correct fluid and electrolyte deficits, and analgesia with opiates in case of abdominal pain. Animals usually benefit from a short fast (12 hours) until vomiting has subsided, followed by frequent feedings of small quantities of an easily digestible bland food (e.g. boiled chicken and rice, or commercial prescription food) for 2–3 days. Once the animal feels better, the usual diet can be reintroduced progressively over 2–3 days.

Prognosis

Most dogs and cats with acute gastritis respond very well to symptomatic treatment. In cases with severe underlying conditions, the prognosis of the primary disease is determinant.

CHRONIC GASTRITIS

Definition/overview

Chronic gastritis is a common disease in dogs with clinical signs such as chronic vomiting. Histopathologic lesions of gastric inflammation can also be present in significant numbers of asymptomatic dogs. The prevalence of chronic gastritis in cats has not been established.

Etiology

Possible causes of chronic gastritis include infectious agents or parasites, drugs (see Gastric ulcers and erosions), or chronic FBs (see Gastric outlet obstruction). In many cases, a specific cause cannot be identified and the term

idiopathic gastritis is used. Food intolerance or allergy, occult parasitism, or other mechanisms are thought to play a role in the pathogenesis of idiopathic gastritis.

Ollulanus tricuspis is the small gastric worm that infests the feline stomach. It is 0.7–1 cm in length and is transmitted directly from cat to cat through ingestion of vomitus. Depending on the severity of the infestation, cats may remain subclinical or show severe signs of chronic gastritis. *Physaloptera* spp. are larger (2–6 cm long) and may be found in dogs and cats (Figure 8.28), although their final host appears to be the coyote. *Pythium insidiosum* is an oomycetal microorganism that may infect the canine GI tract in subtropical climates (such as the Southeast and Gulf of Mexico regions of the USA) and sporadically in other areas. Young, large breed dogs with access to the outdoors are most commonly affected and typically vomit regularly without losing their appetite. Gastric pythiosis is characterized by severe transmural antral thickening and possible gastric outflow obstruction, and may be difficult to differentiate from gastric antral neoplasia. *Helicobacter* infection is discussed in further detail below.

Clinical presentation

Chronic or chronic-intermittent vomiting of food and/or bile is the main clinical sign associated with chronic gastritis. Depending on the severity of the disease, varying combinations of hyporexia, weight loss, melena, or hematemesis may be observed.

Differential diagnosis

All diseases that may cause chronic vomiting need to be considered. These include chronic enteropathies (vomiting and hyporexia may be the only signs of inflammatory bowel disease [IBD] in cats), chronic pancreatitis, chronic diseases of the liver and biliary tree, chronic kidney disease, and endocrinopathies (dog: hypoadrenocorticism, cat: hyperthyroidism).

Diagnosis

A minimum database consisting of CBC, biochemistry panel, and urinalysis is useful to assess the presence of underlying conditions with secondary gastritis and the systemic impact of gastritis. For instance, eosinophilia may be suggestive of parasites, allergic reactions, or mast cell tumor. Hypoalbuminemia may occur with severe GI bleeding or with concurrent small intestinal involvement. Abdominal radiographs may reveal delayed gastric emptying (presence of food in the stomach after a 12-hour fast). Abdominal ultrasound is useful to assess antral wall thickness and overall gastric motility. Fecal flotation is

not very helpful for diagnosis of *Ollulanus* or *Physaloptera*. In dogs with history, physical examination, and abdominal imaging findings suggestive of gastric pythiosis, serum ELISA documenting the presence of specific antibodies may be helpful. In cases refractory to symptomatic treatment, gastroscopy allows visualization of the gastric lesions (Figure 8.29) and collection of gastric mucosal biopsies, which are evaluated histopathologically. The duodenum should also be evaluated and biopsied since gastric diseases may extend to the small intestine as well. Lymphoplasmacytic infiltrates are the most common, but infiltrates may also consist of eosinophils or other inflammatory cells. Eosinophilic gastritis may reflect the presence of parasites or allergic processes. In cats, it may be part of the feline hypereosinophilic syndrome.

Management

Symptomatic treatment is initiated with antiemetics (see Chapter 2.4: Vomiting), and protection of the gastric mucosa (Table 8.6). In addition, identified underlying diseases also need to be addressed. In dogs and cats with unexplained gastritis, empirical treatment with broad-spectrum anthelmintics such as fenbendazole (50 mg/kg q24h for 5 days [*Ollulanus* and *Physaloptera* spp.]) or pyrantel pamoate (5–10 mg/kg [*Physaloptera* spp.]) may be warranted.

Regardless of the cause of the chronic gastritis, a sensible dietary approach is necessary. Obtaining a good

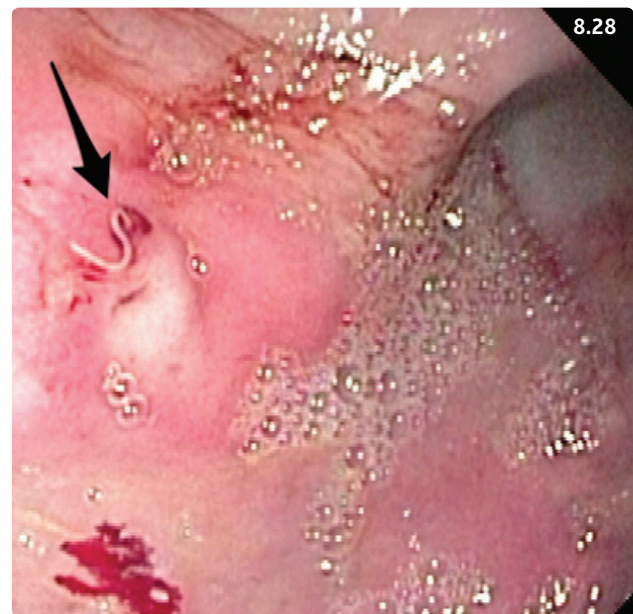


Figure 8.28 Endoscopic view of a *Physaloptera* worm (arrow) found in the gastric mucosa of a young adult male dog with chronic vomiting. (Courtesy K. Harkin)

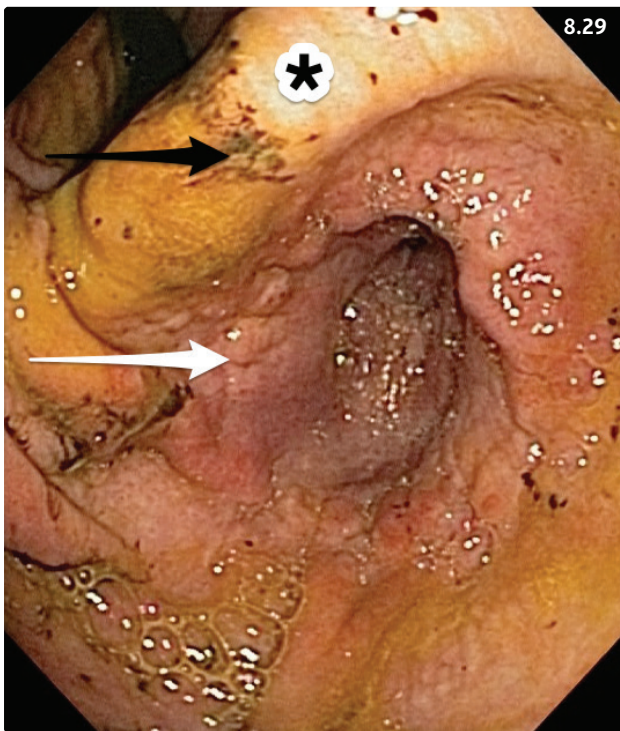


Figure 8.29 Gastrosopic view of a dog with chronic vomiting and hyporexia after endoscopic extraction of a plastic foreign body. The pyloric antrum can be seen below the incisura angularis (asterisk). The antral mucosa looks thickened (white arrow) and there are multiple mucosal erosions (black arrow). (Courtesy R. Husnik)

Table 8.6 Recommended dosages for inhibitors of gastric acid production, prostaglandin analogs, and sucralfate.

Drug	Dog	Cat
Omeprazole	0.7–1.0 mg/kg PO q12–24h	Same
Pantoprazole	0.7–1.0 mg/kg PO q12–24h	Same
Ranitidine*	1–2 mg/kg PO, SC, IV q12h; use low end of range if renal azotemia present	Same
Famotidine*	0.5 mg/kg PO, IV q12h; if renal azotemia is present q24h	Same
Misoprostol	2–5 µg/kg PO q8–12h	Unknown
Sucralfate	0.5–1 g PO q8–12h	0.25–0.5 g PO q8–12h

*H₂-receptor antagonists have been shown to be inferior to proton pump inhibitors in their ability to suppress gastric acid production in dogs and cats.

dietary history is helpful. For idiopathic chronic gastritis, the recommended diets are based on novel proteins or hydrolyzed peptides. They should be easily digestible and fed in several small meals throughout the day to optimize gastric emptying. Dietary management may be sufficient in mild cases with few or no systemic signs, and improvement generally occurs within 2 weeks of receiving the new diet. If this is not the case, a different diet may be tried for another 2 weeks, or immunosuppressive therapy may be initiated. In moderate and severe cases, immunosuppressive doses of glucocorticoids are often required (e.g. prednisone, 1–2 mg/kg q24h for 2 weeks, then slowly taper in 2-week steps to every other day, or lowest effective dose over 8–12 weeks). Additional immunosuppressives may be required in refractory cases.

GI pythiosis is best managed with surgical resection of the lesion with sufficient margins. This is often difficult to achieve in the stomach. Medical treatment of unresectable pythiosis is often unrewarding (itraconazole, 10 mg/kg PO q24h; terbinafine, 5–10 mg/kg PO q24h). Anti-inflammatory doses of prednisone can be used in the hope of decreasing local inflammation and to palliate clinical signs.

Prognosis

All identifiable causes and underlying diseases should be addressed and properly managed. Idiopathic chronic gastritis generally has a fair to good prognosis.

HELICOBACTER SPP. INFECTION

Definition/overview

Helicobacter spp. are spiral-shaped gram-negative bacteria that can live in an acidic environment. While their association with peptic ulcer and gastric neoplasia in people has been clearly documented, their pathogenic potential in dogs and cats is less well defined. *H. pylori*, the most prevalent *Helicobacter* infecting people, does not represent a significant problem in small animals. *H. heilmannii* is the predominant species isolated from cats, while *H. bizzozeronii* and *H. salomonis* are the most common species in dogs. The bacteria colonize mucus in the gastric glands and cause local inflammation.

Clinical presentation

The main clinical sign is chronic-intermittent vomiting.

Diagnosis

Diagnosis is based on ruling out other causes of chronic gastritis (see above), and confirming with gastroscopy, which may show gross lesions (Figure 8.30). Gastric

mucosal biopsies are collected and evaluated cytologically (**Figure 8.31**), histopathologically, and/or using the urease test (**Figure 8.32**).

Management

While the pathogenic potential of *Helicobacter* spp. in dogs and cats is still subject to discussion, animals presented with clinical signs of chronic gastritis, histologic evidence of gastric inflammation, and concurrent presence of spiral-shaped bacteria in the gastric mucosa and gastritis should be treated. Eradication requires treatment with different drugs usually consisting of one or more antimicrobial(s), an acid-reducing drug, and bismuth in some protocols for a duration of 14–21 days. Examples of eradication protocols are listed in **Table 8.7**.

Prognosis

Prognosis is good; however, many animals may reinfect themselves in their home environment.

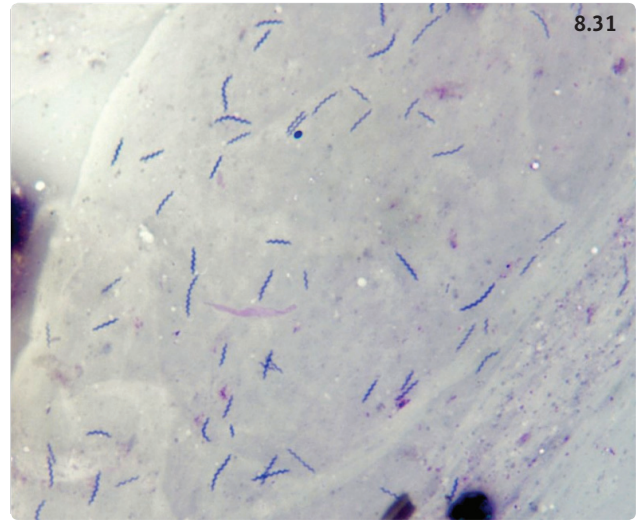


Figure 8.31 Cytology picture of a gastroscopic mucosal brushing showing multiple spiral-shaped bacteria in a dog with helicobacteriosis. (Courtesy R. Husnik)

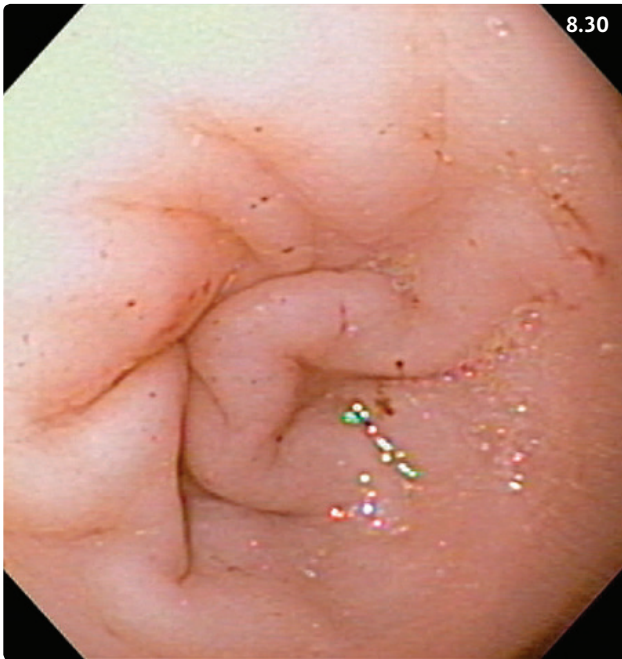


Figure 8.30 Gastroscopic view showing the pyloric antrum of a 12-year-old male neutered Domestic Shorthair cat with a 15-month history of intermittent vomiting, hyporexia, and weight loss. There are multiple erosions associated with mucosal bleeding. Histopathology revealed mild lymphoplasmacytic inflammation and numerous spiral-shaped bacteria on the mucosa. The cat responded to treatment with amoxicillin, clarithromycin, and metronidazole.

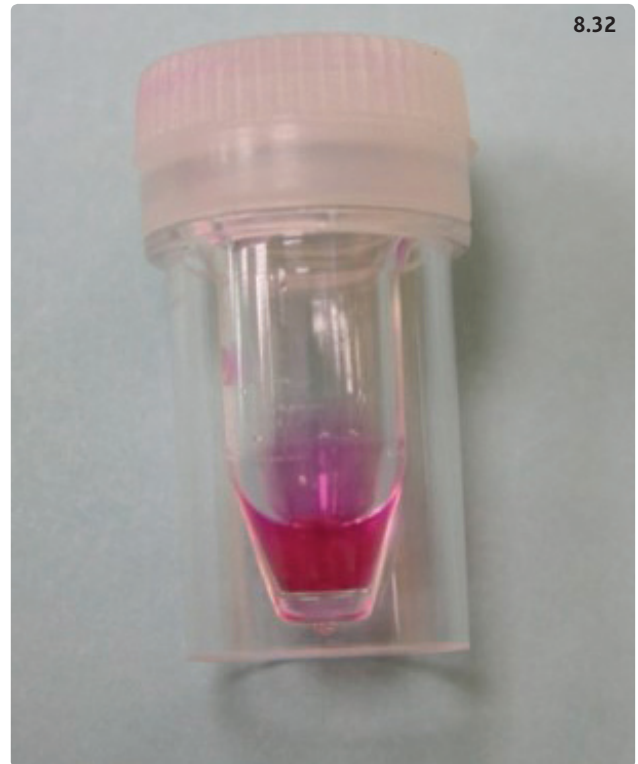

Figure 8.32 Urease test. A gastric biopsy sample was placed in this vial at the time of gastroscopy. The liquid was initially yellow and then turned red, indicating the presence of urease-producing *Helicobacter*. (Courtesy R. Husnik)

Table 8.7 Examples of oral treatment protocols for eradication of *Helicobacter* spp. in dogs and cats.

Antimicrobial	Antacid	Other	Comments
Metronidazole (10–15 mg/kg q12h) Amoxicillin (20 mg/kg q12h)	Famotidine (0.5 mg/kg q12h)		D: 2-week duration
Metronidazole (10–15 mg/kg q12h) Amoxicillin (20 mg/kg q12h)		Bismuth subsalicylate (0.22 ml/kg q6–8h)	D, C: 3-week duration
Amoxicillin (20 mg/kg q12h) Clarithromycin (7.5mg/kg q12h) Metronidazole (10 mg/kg q12h)			C: 2-week duration

D, successful use reported in dogs; C, successful use reported in cats.

Table 8.8 Causes of gastrointestinal ulceration in dogs and cats.

Dogs	Cats
Drugs NSAIDs: (1) accidental ingestion (acute toxicosis); (2) chronic administration (to treat orthopedic conditions) Steroids: (1) with intervertebral disk disease; (2) other	Drugs: NSAIDs; steroids
Neoplasia: gastric carcinoma, and other gastric tumors; mast cell tumor; gastrinoma	Neoplasia: alimentary lymphoma, and others; systemic mastocytosis; gastrinoma
Poor perfusion of gastric mucosa: hypoadrenocorticism, shock, inadequate fluid therapy during anesthesia	Poor perfusion of gastric mucosa: shock, inadequate perfusion during anesthesia
Other: <i>Helicobacter</i> spp. infection, inflammatory bowel disease, pancreatitis, liver disease, uremic syndrome, prolonged intensive physical activity (sled dogs), pyloric outflow obstruction, gastric dilatation–volvulus, gastric FB	Other: inflammatory bowel disease, hypereosinophilic syndrome, <i>Dieffenbachia</i> toxicosis, stress, gastric FB

GASTRIC ULCERATIONS AND EROSIONS

Definition/overview

Ulcers are mucosal lesions that extend to the muscularis mucosae and the deeper layers (submucosa, muscularis), and erosions are more superficial and limited to the lamina propria. While there are no reported numbers for the prevalence of GI ulcers in small animals, they appear to be uncommon in dogs and rare in cats.

Etiology

The main reported causes of gastric ulcer in dogs and cats are listed in **Table 8.8**. Long-term treatment with NSAIDs is probably the most common cause of canine GI ulcers. Administration of NSAIDs using a higher dose than that recommended by the manufacturer, or in combination with other NSAIDs or corticosteroids, significantly increases the risk of GI lesions. Dogs treated for

intervertebral disk disease are also at high risk of developing ulcerative lesions in the GI mucosa. Additionally, GI ulceration may represent a complication of a variety of diseases originating in or outside the GI tract. Gastric tumors frequently ulcerate due to compromise in the blood supply required to maintain the integrity of the gastric mucosa. Finally, secretion of gastrin by gastrinomas and histamine by mast cell tumors may lead to excessive gastric acid production and disruption of the gastric mucosal barrier, with resulting erosions and ulcerations.

Pathophysiology

The gastric mucosal barrier protects the gastric mucosa from the acidic environment of the gastric lumen. The hydrophobic mucous layer produced by the mucous neck cells provides a physical barrier separating the gastric epithelium from the gastric lumen and its content. It is rich in bicarbonate, which acts as a buffer against acid.

Other factors involved in maintaining the mucosal barrier include the high mucosal blood flow providing nutrients, bicarbonate, and oxygen to the mucosa and eliminating acid residues, the local production of prostaglandin E₂, and the rapid turnover of epithelial cells. Gastric ulcers and erosions occur in the presence of drugs or disease processes that weaken or disrupt the gastric mucosal barrier.

Clinical presentation

In dogs, the typical presentation revolves around vomiting with or without hematemesis (**Figure 8.33**). Cranial abdominal pain may be present. Signs resulting from fluid and possibly blood loss (dehydration, shock, anemia) may become apparent. While melena may be observed during the rectal examination (**Figure 8.34**), it is only obvious in



Figure 8.33 Bloody vomit with typical coffee ground appearance from a dog with a gastric ulcer due to acute NSAID toxicosis. (Courtesy R. Husnik)

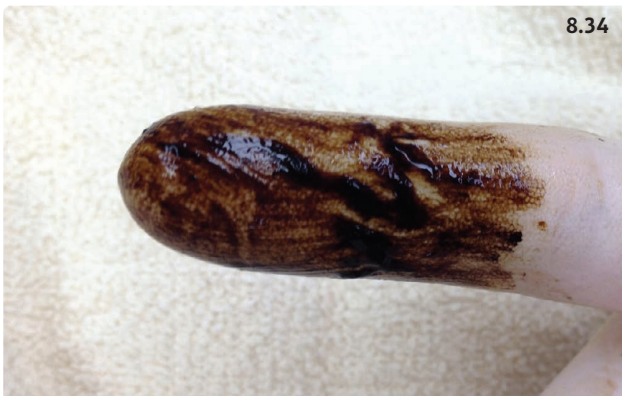

Figure 8.34 Melenic feces recovered from the rectum of a dog with gastric adenocarcinoma.

case of significant blood loss (>2.5–3.5 ml/kg body weight). In case of perforating ulcer, septic peritonitis usually develops with systemic inflammatory response syndrome (SIRS, sepsis).

Cats with GI ulceration may also be presented with vomiting, hematemesis, abdominal pain, and melena. However, some cats may only show vomiting with nonspecific signs such as anorexia and lethargy. GI ulcers associated with neoplasia (e.g. gastric tumor, mastocytosis) tend to have a more protracted course with weight loss and other clinical signs caused by the underlying disease.

Differential diagnosis

Vomiting (see Chapter 2.4, **Table 2.4.2**). Severe gastric inflammation, duodenal ulcers, and acute pancreatitis may also cause hematemesis. Furthermore, mucosal bleeding associated with coagulopathies or platelet diseases may also lead to hematemesis and melena. Abdominal pain may be associated with acute pancreatitis, GI FBs, and gastroenteritis.

Diagnosis

In animals with suggestive evidence of GI ulceration, the diagnostic approach should focus on two objectives: (1) confirm the presence of an ulcerative GI lesion, and (2) search for an underlying disease predisposing the animal to develop GI ulcers.

A minimal database consisting of CBC, serum biochemistry, urinalysis, and abdominal imaging should be obtained. The CBC may show evidence of blood loss anemia (microcytic hypochromic anemia), which may be regenerative or nonregenerative depending on the duration of blood loss, and/or changes associated with the underlying disease. Serum biochemistry may reveal an increased BUN in an otherwise fasted patient (suggestive of GI bleeding) and/or abnormal results due to fluid and electrolyte loss or to an underlying disease. Abdominal radiographs are important to rule out a GI obstruction. Additionally, they may identify signs of perforation and peritonitis (e.g. peritoneal effusion with decreased serosal detail, pneumoperitoneum). Abdominal ultrasound allows a more detailed assessment of the gastric pylorus, antrum, and body, and is useful to confirm the presence of free fluid or gas in the peritoneum. Moreover, a full abdominal scan allows evaluation of the other abdominal organs in the search for underlying disease. Masses detected during the physical examination (e.g. skin masses [mast cell tumors]) or during the ultrasound examination should be aspirated and evaluated cytologically.

The diagnostic examination of choice to confirm GI ulceration is endoscopy. Ulcers may be disseminated

throughout the gastric mucosa (long-term use of NSAIDs in dogs) or present on the lesser curvature at the entrance of the pyloric antrum (acute NSAID toxicosis, gastric tumors) (**Figures 8.35, 8.36**). Mucosal biopsies should be collected around the ulcer margins and in other areas and evaluated histologically. In cases of gastric neoplasia, an effort should be made to collect deep biopsies of the tissue surrounding the ulcer(s).

Management/prevention

Supportive treatment is essential and includes correction of fluid and electrolyte deficits and administration of antiemetics as needed. If the animal is in pain, appropriate analgesia should be provided using opioid drugs. A surgical approach is required after initial stabilization of the patient in cases of perforated ulcers and associated peritonitis.

Protection of the gastric mucosa with inhibitors of acid secretion is essential. Proton pump inhibitors (PPIs; e.g. omeprazole) are considered more effective than histamine type-2 inhibitors (H2-inhibitors; e.g. famotidine, ranitidine) for providing continuous acid suppression during their duration of action. Among H2-inhibitors, famotidine is more reliably efficacious than ranitidine and cimetidine. Inhibitors of acid secretion should be administered over a prolonged period of time to dogs and

cats with GI ulcers (4–6 weeks). Additionally, sucralfate is the drug of choice to coat ulcers and promote a quicker re-epithelization and healing. It is usually administered simultaneously with an H2-receptor blocker or PPI, although there is still some debate about the value of staggering oral administration of sucralfate and these drugs. Misoprostol is an oral prostaglandin E analog that has been used with success in dogs with NSAID toxicosis (see dosage in **Table 8.6**). Additionally, treatment of identified underlying conditions should be initiated as early as possible.

Dietary support for gastric ulcers should consist of an easily digestible diet that is low in fiber and fat and promotes rapid gastric emptying. Alternatively, in some patients, the preferred diet may need to be selected on the basis of identified underlying diseases (e.g. hydrolyzed diet in IBD, 'renal diet' in chronic kidney disease).

Prevention of GI ulcers is recommended in patients at risk. First, simultaneous administration of steroid and NSAIDs or treatments involving combinations of NSAIDs should be avoided at all costs. In animals with severe joint pain that are unresponsive to single agent therapy, opioids and/or tramadol should be considered as part of the analgesic protocol. Dogs and cats with a significant burden of mast cell tumors are likely to benefit most from H2-blocker therapy. In high-risk patients such as dogs with intervertebral disk disease treated with corticosteroids or NSAIDs, PPIs or H2-blockers are often administered in the hope of limiting the extent of gastric mucosal lesions. Similarly, dogs receiving long-term NSAIDs due

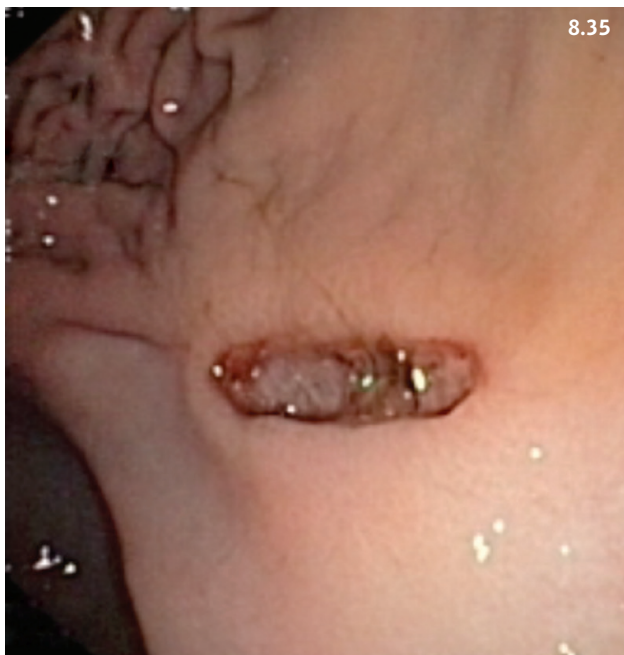

Figure 8.35 Gastroscopic view from a young Dalmatian that accidentally ingested a high dose of naproxen. A sharply delineated peptic ulcer is visible on the lesser curvature.

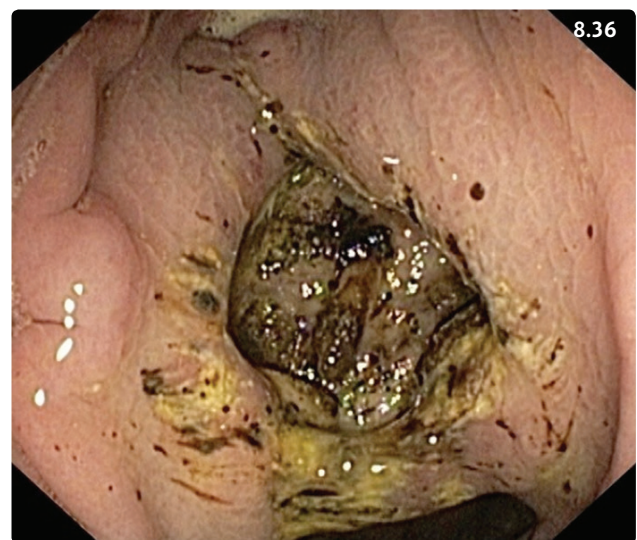

Figure 8.36 Gastroscopic view from an older mixed-breed dog showing an ulcerated gastric adenocarcinoma with a deep ulcerated center and raised edges. (Courtesy R. Husnik)

to chronic osteoarthritis or other orthopedic problems may benefit from preventive gastroprotective treatment, particularly once they have experienced signs of erosive/ulcerative gastritis. Misoprostol may be of benefit as well. Other risk situations include dogs receiving high immunosuppressive doses of corticosteroids to treat various immune-mediated diseases, although there is no documented benefit of preventive use of inhibitors of gastric acid production in these patients.

Prognosis

In the absence of perforation, canine GI ulcers are usually associated with a good outcome if their cause can be identified and eliminated (e.g. acute NSAID toxicosis). However, in many instances the underlying disease may significantly compromise the prognosis (e.g. gastric neoplasia, chronic liver failure, chronic kidney disease). Cats with GI ulcers secondary to gastric lymphoma, gastrinoma, and mastocytosis appear to have a good prognosis.

Dogs with perforated gastric or duodenal ulcers that undergo surgery usually have a reasonable survival if the underlying problem can be successfully addressed. However, only 50% of dogs with nonmalignant perforated ulcers survived in a recent study from the UK. In cats, surgically treated perforated GI ulcers appear to have a good prognosis.

GASTRIC DILATATION AND VOLVULUS

Definition/overview

Gastric dilatation–volvulus (GDV) is a syndrome that occurs in large to giant breed dogs and is characterized by rotation of the stomach on its mesenteric axis followed by gaseous gastric distension.

Etiology

The precise etiology of GDV is unknown. Identified risk factors include a narrow and deep thoracic conformation, stress, and nutritional factors that ultimately lead to rapid filling of the stomach with large quantities of food or water. For instance, once daily feeding, rapid ingestion of a meal, exercising after a meal, and eating from a raised platform all have the potential to trigger GDV.

Pathophysiology

The pylorus moves ventrally from the right to the left with a resulting rotation of 90–360 degrees, and positions itself near the gastric cardia on the left side. Gas accumulates in the stomach since neither eructation nor aboral

emptying is possible. The distended stomach compresses the caudal vena cava and the portal vein, resulting in decreased venous return to the heart, decreased cardiac output, and ultimately cardiovascular collapse.

Clinical presentation

Abdominal distension with tympany, abdominal pain, retching or vomiting (often nonproductive), hypersalivation, and acute collapse are common presenting signs. Hypovolemic and/or distributive shock may be noticeable on presentation (tachycardia, weak pulses, pale mucous membranes with abnormal capillary refill time).

Differential diagnosis

Gastric dilatation secondary to overeating, mesenteric volvulus, splenic torsion, diaphragmatic tear with gastric herniation.

Diagnosis

Typical history and physical examination are suggestive; however, they do not allow differentiation between gastric dilatation and GDV. Gastric volvulus is confirmed with right lateral abdominal radiographs (Figure 8.37). However, aggressive shock treatment and attempts to deflate the stomach are often necessary before obtaining survey abdominal films.

Management

Aggressive treatment of cardiovascular collapse using two large bore catheters placed in each cephalic vein is life-saving and needs to be initiated immediately after

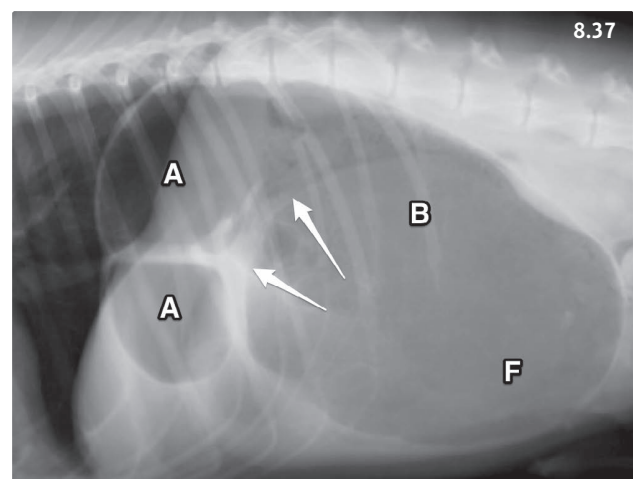


Figure 8.37 Right lateral abdominal radiograph of a dog with gastric dilatation–volvulus. The antrum (A) is visible in the dorsocranial aspect of the abdomen while the fundus (F) and body (B) are located more caudal. Compartmentalization of the stomach is visible (arrows). (Courtesy L. Gaschen)

presentation. (See Chapter 23: Fluid therapy, for proper choice of fluids and required doses.) If surgery needs to be delayed (e.g. because of fluid resuscitation), orogastric intubation is attempted in order to decompress the stomach and lavage its content (**Box 8.4**). If attempts at orogastric intubation are unsuccessful, percutaneous trocharization may be performed using a 3 inch 12–14G IV catheter that is introduced into the stomach caudally to the last rib in the left flank after the region is clipped and aseptically prepared. This usually causes some peritoneal contamination with gastric content. Ultimately, explorative celiotomy with repositioning of the stomach is followed by evaluation of gastric wall vitality (**Figure 8.38**). Partial gastrectomy may be required if segments of the stomach are devitalized; partial or total splenectomy may be necessary in the presence of splenic necrosis, infarction, or torsion. Gastropexy (pyloric antrum to right abdominal wall) is recommended to lower the likelihood of recurrence. Cardiac dysrhythmias commonly occur and need to be addressed if they significantly compromise cardiac output. Hypokalemia and hypomagnesemia need to be diagnosed and treated as they may complicate cardiac arrhythmias.

Prognosis

The overall mortality rate is currently between 10% and 27%. Negative prognostic factors include >6-hour duration of clinical signs, post-fluid therapy serum lactate

concentration >6.4 mmol/l or <4 mmol/l decrease between pre- and post-fluid lactate, and devitalized gastric wall with need for gastric resection.

GASTRIC OUTLET OBSTRUCTION

Causes of gastric outlet obstruction include gastric FBs, antral pyloric hypertrophy, and gastric neoplasia as well as gastric pythiosis.

GASTRIC FOREIGN BODY

Definition/overview

Young animals are more likely to play with foreign objects, but ingestion of gastric FBs may occur in animals of any age. While many dogs are indiscriminate eaters at risk for any type of GI FB, cats are more likely to ingest linear FBs.

Etiology

FBs may consist of bones, toys, socks, towels, or linear material such as string or wool. Linear FBs may lodge at the pylorus and cause intestinal perforation and peritonitis. Hair balls may be a problem, especially in long-haired cats (**Box 8.5**).

Pathophysiology

Gastric outlet obstruction may cause hypokalemic metabolic alkalosis.

Box 8.4 Procedure for passage of an orogastric tube in a dog with gastric dilatation–volvulus.

1. Material. Use largest diameter smooth surfaced flexible orogastric tube possible (e.g. >9.5 mm outside diameter in large dogs). Water-soluble lubricating jelly. Canine mouth speculum (e.g. roll of 2 inch adhesive tape).
2. Sedation. With exception of recumbent or severely affected dogs, mild sedation is usually required. One option is IV administration of butorphanol (0.2–0.4 mg/kg) with diazepam (0.2–0.5 mg/kg).
3. Preparation. Mark the distance from the canine tooth to the last rib on the tube using piece of tape.
4. Introduction. Cover the end of the tube with lubricating jelly and gently introduce the tube through the speculum, pharynx, and esophagus. When the level of the tape marking is reached, the tube should be at the lower esophageal sphincter. Gently rotating the tube may be required to pass the sphincter. Passage through the lower esophageal sphincter should not require force.
5. Limit. The procedure should be aborted if the stomach cannot be intubated after a few attempts. Consider percutaneous gastric trocharization (see text).

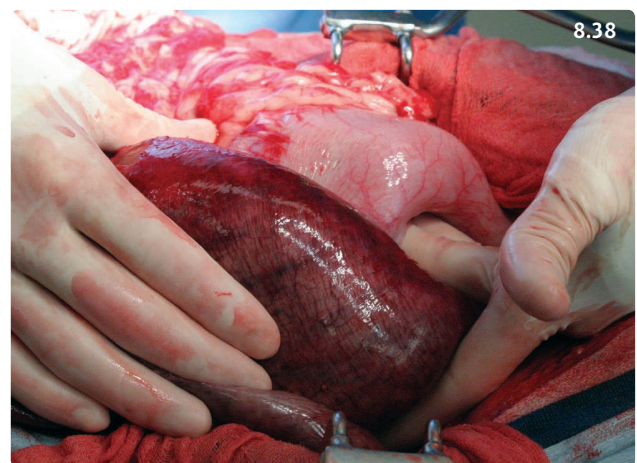


Figure 8.38 Exploratory celiotomy of a dog with gastric dilatation–volvulus after repositioning of the stomach. A devitalized portion of the stomach (antrum) is shown in the foreground and compared with the normally perfused body. (Courtesy D. Ogden)

Box 8.5 The problem of feline hairballs.

While hairballs commonly occur, particularly in longhaired cats, they do not usually cause significant health problems. Typically, affected cats vomit occasionally while remaining otherwise healthy ('healthy vomiters'). The formation of hairballs may be related to the unusual fasted digestive motility pattern displayed in cats, which may make the emptying of hair material into the duodenum more difficult. This promotes gastric retention of swallowed hair, and ultimately formation of a hairball.

In most cats, treatment involves administration of a petroleum laxative or dietary supplementation with a bulk laxative. Psyllium is sufficient to control the problem. Longhaired cats may benefit from regular clipping. In some cats, trichobezoars may form, cause chronic gastritis, and/or obstruct the gastric outlet and therefore require endoscopic or surgical extraction. Frequent vomiting of hairballs may also be an early sign of chronic enteropathies and should prompt clinicians to initiate further diagnostic tests. This is particularly true in shorthaired cats, which are usually not prone to having hairballs.

Clinical presentation

History of possible FB ingestion and acute onset vomiting in an otherwise normal animal. Anorexia and lethargy are commonly associated signs. Cranial abdominal discomfort or pain may be elicited on palpation. Dehydration and electrolyte and acid–base abnormalities are frequent complications.

Differential diagnosis

Dietary indiscretion and GI infections (e.g. parvovirus) are the most important differential diagnoses in puppies. In adult dogs, acute gastritis due to dietary indiscretion and acute pancreatitis are the top two differentials. However, any GI or systemic disease causing acute vomiting should be considered both in dogs and cats.

Diagnosis

Diagnosis is confirmed with abdominal imaging. Survey radiographs may show a dilated stomach full of food or secretions for a prolonged period after meals. In some cases, the foreign object may be visible (**Figures 8.39–8.41**). In case of doubt, contrast radiographs may help to visualize the obstruction more accurately. Alternatively, ultrasound examination of the stomach may confirm the presence of a foreign object.

Management

Gastric FBs need to be removed either endoscopically (**Figures 8.41, 8.42**) or surgically. Foreign material that has partially passed into the duodenum (e.g. socks, towels) should be removed surgically. Fluid therapy is promptly

initiated to replace deficits and stabilize the patient prior to inducing anesthesia.

Prognosis

Prognosis is generally good once the foreign material has been removed. It may be guarded to poor in severely debilitated animals or in cases with gastric perforation and peritonitis. Possible surgical complications include dehiscence and peritonitis.

GASTRIC ANTRAL PYLORIC HYPERTROPHY**Definition/overview**

Thickening of the antral wall may be due to hypertrophy of the mucosa, the muscularis, or both layers. Acquired pyloric antral hypertrophy is most commonly due to hyperplasia of the antral mucosa, and occurs preferentially in middle aged to older small breed dogs (e.g. Lhasa Apso, Pekingese, Maltese, and Shih Tzu). Congenital pyloric hypertrophy characterized by hyperplasia of the antral muscularis is a rare congenital disorder of brachycephalic breeds such as Boxers, Boston Terriers, and Bulldogs and has also been reported in Siamese cats.

Etiology/pathophysiology

The exact causes and pathophysiology remain unknown. Recently, an increased frequency of GI tract lesions was reported in brachycephalic dogs, and acquired pyloric antral hypertrophy was diagnosed endoscopically in >80% of examined dogs, although most of the dogs did not show any clinical signs. An association was suggested between the chronic inspiratory dyspnea seen in these breeds and chronic duodenogastric reflux, which may be the cause of the antral mucosal hypertrophy.

Clinical presentation

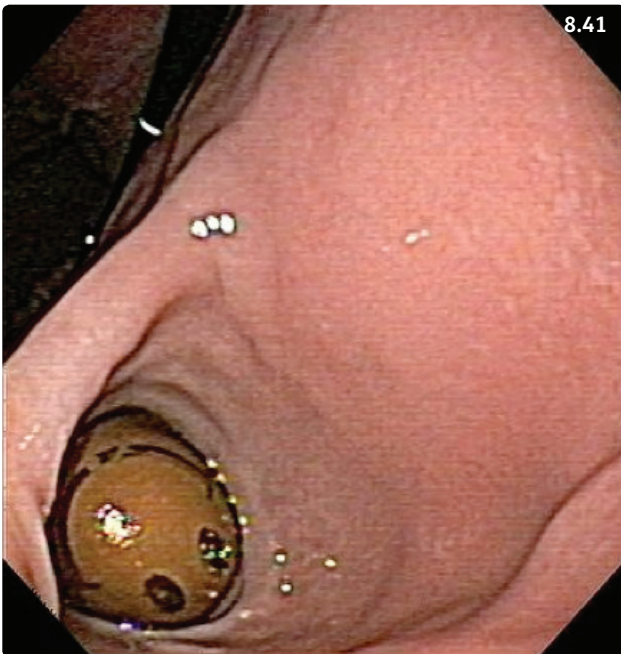
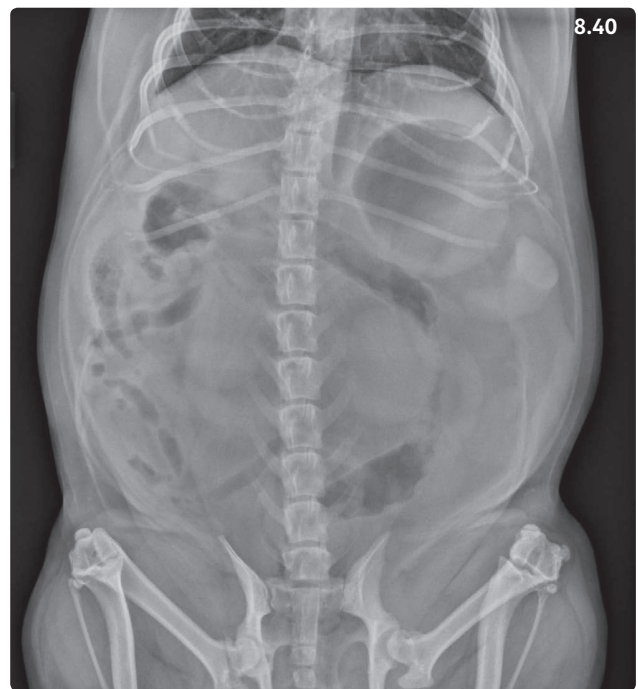
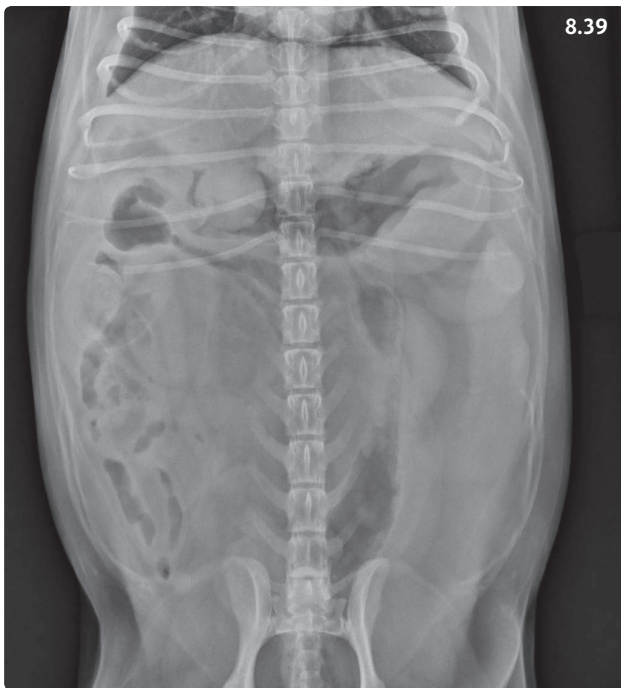Chronic-intermittent vomiting that worsens progressively with severity of the mucosal hypertrophy and resulting pyloric obstruction. In puppies and kittens with the congenital form, signs start after weaning. Projectile vomiting may occur.

Differential diagnosis

Other diseases of the stomach, chronic pancreatitis, diseases originating outside the GI tract (e.g. chronic kidney disease).

Diagnosis

Survey abdominal radiographs or abdominal ultrasound may suggest delayed gastric emptying and show thickening of the antral wall. Barium contrast studies may be useful to visualize the narrowing of the pyloric passage.



Figures 8.39–8.41 Eight-year-old male neutered Pekingese presented with a 10-day history of anorexia, vomiting, and lethargy. (8.39) Ventrodorsal abdominal radiograph. A round structure of soft tissue density is visible surrounded by gas in the pyloric antrum. (8.40) The foreign body is not visible in this dorsoventral view where gastric gas has accumulated in the fundus. This highlights the importance of obtaining both ventrodorsal and dorsoventral views for an optimal evaluation of the stomach. (Radiographs courtesy LSU SVM Diagnostic Imaging Service) (8.41) Gastroscopic view. A bouncing ball with a smiley face is visible in the pyloric antrum and could easily be extracted using an endoscopic snare.

Diagnosis is confirmed with gastroscopy or surgical exploration, and histologic evaluation of mucosal or full-thickness biopsies. Antral mucosal folds can easily be viewed on endoscopic evaluation of the stomach (**Figures 8.43, 8.44**). Histopathologic examination of mucosal biopsies confirms the mucosal hyperplasia.

Management

Treatment is surgical and consists of removing the redundant tissue and performing a Y-U pyloroplasty. Tissue specimens should be submitted for histologic confirmation. In some instances, pyloric antral resection may be required. Pyloric myotomy, while easier to perform, is usually not successful in these animals.

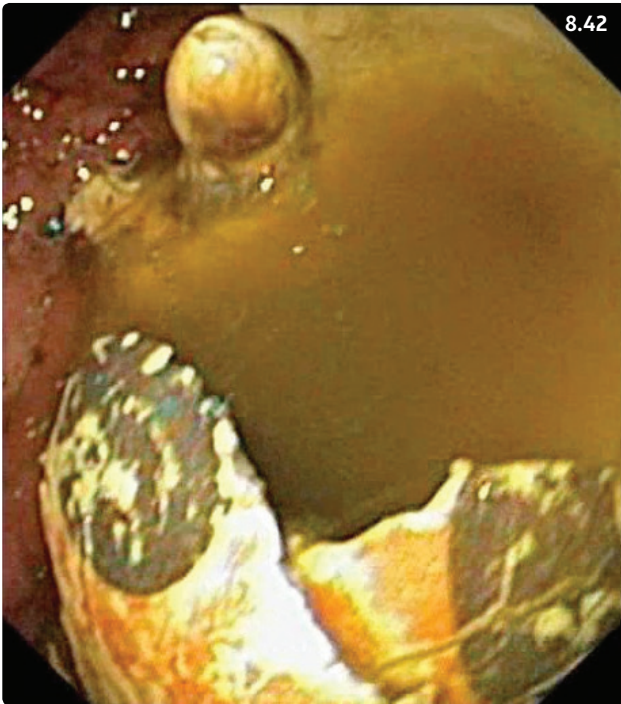


Figure 8.42 Gastroscopic view of a dog that had chewed and swallowed parts of a plastic soccer ball. Typical clinical signs had been present for 3 weeks.

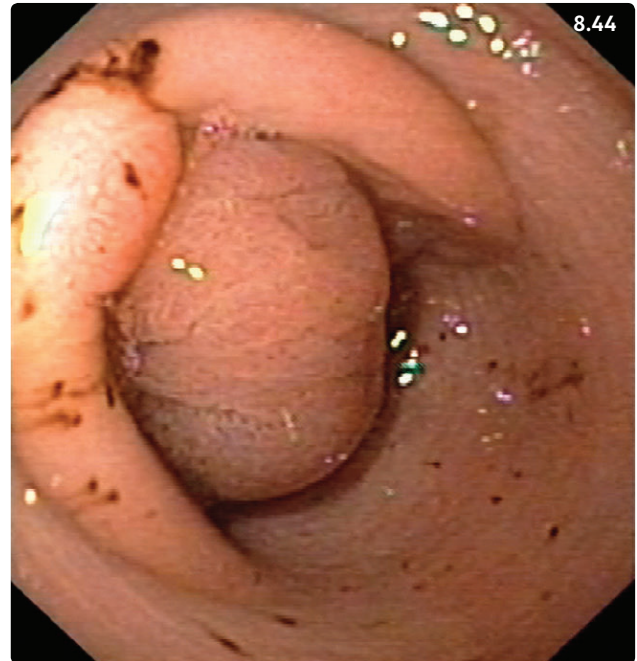


Figure 8.44 Gastroscopic view of the pylorus in a Boxer dog with gastric antral pyloric hypertrophy. Note the prominent mucosal fold obstructing the pylorus. There are multiple erosions (bleeding) surrounding the pylorus. (Courtesy P. Lecoindre)

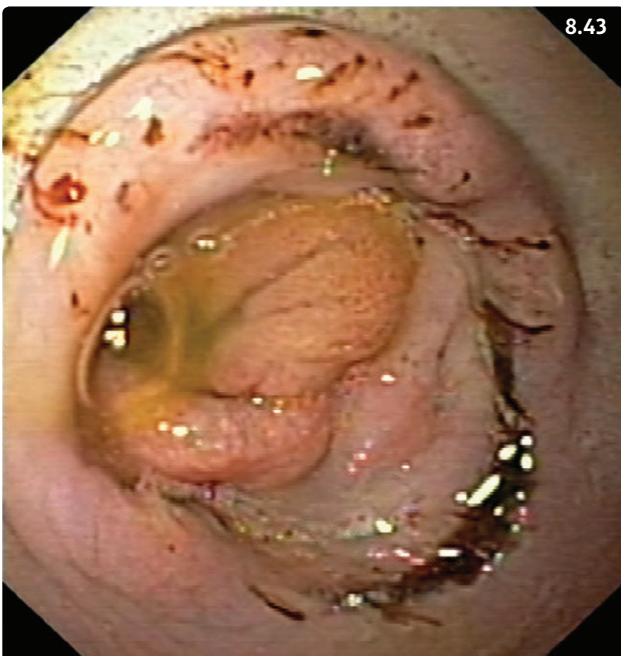


Figure 8.43 Gastroscopic view of the pylorus in a French Bulldog with gastric antral pyloric hypertrophy. Note the prominent mucosal folds surrounding the pylorus, with multiple erosions (bleeding) that may be associated with duodenogastric reflux. (Courtesy P. Lecoindre)

Prognosis

Surgery is curative and the prognosis is good. Possible surgical complications include dehiscence or lack of improvement due to inappropriate surgical technique.

NONOBSTRUCTIVE GASTRIC EMPTYING DISORDERS

Definition/overview

Motility is often the 'missing link' in the complex equation of GI health in dogs and cats. The prevalence of GI motility disorders in small animals cannot be precisely documented because obtaining a definitive diagnosis is often difficult, sometimes even impossible. However, it is thought that these disorders are of significant clinical importance.

Etiology

Elucidating the origin of nonobstructive GI dysmotility is often challenging. Often, it results from diseases located outside the GI tract, including abdominal inflammation (e.g. acute pancreatitis), immune-mediated diseases, and metabolic diseases. Alternatively, motility disorders may

also result from primary GI disorders such as GI inflammation or neoplasia. Furthermore, diseases affecting the autonomic nervous system, such as dysautonomia, also impact GI motility. Finally, postoperative ileus has been shown to cause a significant delay in gastric emptying of up to 48 hours in dogs undergoing abdominal surgery.

Clinical presentation

Vomiting of more or less digested food is the most common clinical sign, particularly when it occurs long after food intake (e.g. >10–12 hours), when the stomach should be empty. Projectile vomiting may occur in the absence of a prodromal phase. Additionally, the animal may be bloated and have pain on cranial abdominal palpation and/or signs of colic. Decreased appetite or anorexia, signs of nausea, increased belching, pica, and/or polydipsia may also be observed.

Differential diagnosis

Due to the relatively vague symptomatology, the list of differential diagnoses is long. It is essential to first rule out GI obstruction, which may require immediate surgical management.

Diagnosis

Since many underlying disorders may affect gastric motility, a minimal database (CBC, chemistry panel, urinalysis) plus survey abdominal radiographs are indicated to screen for underlying diseases and confirm the absence of GI obstruction (**Figure 8.45**). Accurate assessment of gastric emptying is difficult under practical conditions. Radionuclide scintigraphy is recognized as the current gold standard in dogs and cats but is only available at select referral centers. Radiographic studies are

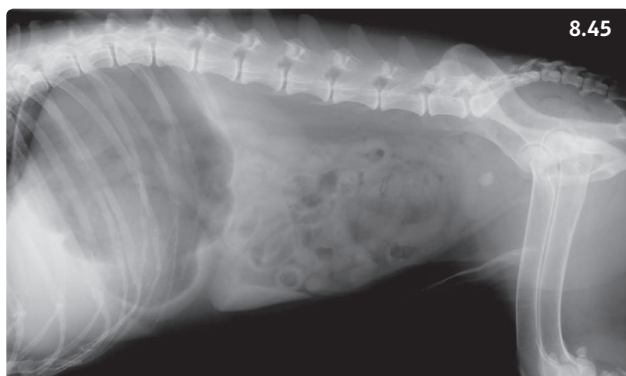

Figure 8.45 Right lateral abdominal radiograph of a 15-year-old male neutered Cocker Spaniel with recurrent episodes of bloat and colic. The stomach is dilated with gas, but there is no indication of gastric outlet obstruction. **Note:** A radiopaque cystic calculus is visible.

easily accessible in clinical veterinary practice. However, assessment of gastric emptying of liquid barium is an insensitive technique, with the exception of diagnosis of mechanical obstructions. Mixing barium with food may allow better evaluation of the solid phase of gastric emptying. Unfortunately, barium can easily dissociate from the test meal and cause the study to be unreliable. Barium-impregnated polyethylene spheres (BIPS™) have been used for evaluation of GI transit times in dogs and cats. However, correlation between gastric emptying of BIPS and the gold standard has been disappointing in dogs and in cats, and the use of these spheres has been limited. Abdominal ultrasound is a promising and widely available modality for the evaluation of gastric antral motility and gastric emptying.

Management

Proper diagnosis and treatment of any underlying disease that may affect gastric motility are essential. Therapy of functional, nonobstructive disorders of gastric motility is based on dietary modification and judicious use of prokinetic drugs.

Dietary modifications designed to facilitate gastric emptying are based on knowledge of digestive physiology. First, gastric emptying of liquid food is faster than that of solid foods. Also, diets with high caloric density tend to remain longer in the stomach. In addition, gastric emptying of fat is slower than that of proteins, which is slower than that of carbohydrates. Consequently, feeding a liquid or semi-liquid diet of low caloric density low in fat and protein should maximize gastric emptying. Finally, increased meal frequency and decreasing meal size are also useful. Dietary treatment of bilious vomiting or duodenogastric reflux consists of feeding a light meal late at night. Additionally, prokinetic drugs may be beneficial in nonobstructive disorders of gastric emptying (**Table 8.9**)

Prognosis

Prognosis is good if the primary cause of delayed gastric emptying can be corrected. Idiopathic GI dysmotility can be a challenge to manage efficiently. Dysautonomia carries a poor prognosis in cats and dogs.

GASTRIC NEOPLASIA

Definition/overview

Stomach tumors are uncommon, and typically occur in older in dogs and cats. Benign canine gastric neoplasms include adenomatous polyps and leiomyomas. Adenocarcinoma and lymphoma are the most prevalent tumor types diagnosed in the dog, followed by

Table 8.9 Site of action and recommended dosage of gastrointestinal prokinetics.

Name	Site of action	Dose
Metoclopramide	Pyloric antrum, duodenum (?)	0.2–0.5 mg/kg PO, SC q8h CRI: 1–2 mg/kg/24h
Cisapride	Lower esophagus (C), lower esophageal sphincter, pyloric antrum, small intestine, colon	0.1–0.5 mg/kg PO q8–12h; dose can be progressively increased up to 1 mg/kg q8h
Mosapride	Pyloric antrum	0.25–2 mg/kg PO q12–24h (D); currently only available in Asia
Prucalopride	Pyloric antrum, small intestine (?), colon	0.01–0.6 mg/kg PO q12–24h; currently not available in the USA
Erythromycin	Lower esophageal sphincter (D), pyloric antrum, small intestine, colon	0.5–1.0 mg/kg PO or IV q8h (after dilution)
Ranitidine	Pyloric antrum (possibly small intestine, colon)	1–2 mg/kg PO q12h, or slowly IV (after dilution)
Nizatidine	Same as ranitidine	2.5–5 mg/kg PO q24h

(D), dog only; (C), cat only; CRI, constant rate infusion.

leiomyosarcoma and stromal tumors. Lymphoma is the most common gastric neoplasia found in cats.

Etiology

The etiology of gastric tumors has not been elucidated. Canine breeds at risk for adenocarcinoma include the Belgian Shepherd Dog, Rough Collie, and Staffordshire Bull Terrier. A predisposition in male dogs has been reported for gastric adenocarcinoma and gastric lymphoma.

Clinical presentation

The early stages of gastric neoplasia usually remain subclinical. Hyporexia is the most common clinical sign followed by vomiting and weight loss. In advanced stages with ulceration of the gastric mucosa, hematemesis and melena may occur. Vomiting is due either to gastric outflow obstruction or to abnormal gastric motility associated with the neoplastic wall infiltration. Adenomatous polyps are usually subclinical unless they cause gastric outflow obstruction.

Differential diagnosis

Other disease processes causing gastric outflow or small intestinal obstruction (FBs, pythiosis). Other conditions associated with dysorexia and vomiting that originate from the GI tract or from other organ systems.

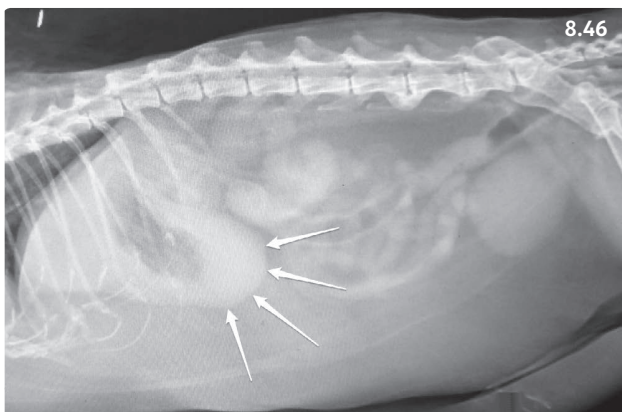
Diagnosis

A minimal database consisting of CBC, biochemistry panel and urinalysis is recommended to evaluate the general condition of the animal and screen for possible systemic

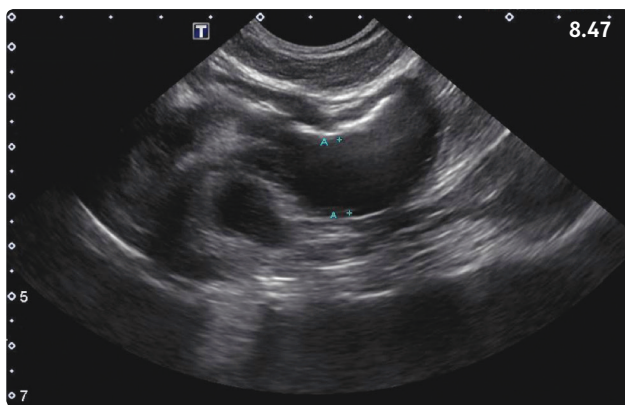
repercussions of gastric tumors such as blood loss anemia. Diagnosis is confirmed with abdominal imaging. In some instances survey abdominal radiographs may reveal an enlarged stomach with delayed emptying (**Figure 8.46**). Filling defects or ulcerated areas may be detected on contrast studies. Abdominal ultrasound often shows thickening of the gastric wall (**Figure 8.47**). Most canine gastric adenocarcinomas are located in the antral area or on the lesser curvature, while lymphomas are often diffusely infiltrative. Enlarged lymph nodes and/or hepatic nodules suggestive of local metastases may be visible (**Figure 8.48**). Double lateral thoracic radiographs are useful to screen for pulmonary metastases. Cytologic evaluation of ultrasound-guided aspirates of the abnormal gastric wall may be helpful to diagnose lymphoma (**Figure 8.49**). Endoscopic evaluation with sampling of mucosal biopsies in and around the suspect areas (**Figures 8.36, 8.50**) and histologic evaluation are useful to confirm the tumor type. While no appearance is typical for one specific tumor type, most adenocarcinomas are ulcerated. Occasionally, tumors are located in the submucosal layers, and obtaining representative endoscopic biopsies may be challenging.

Management/prognosis

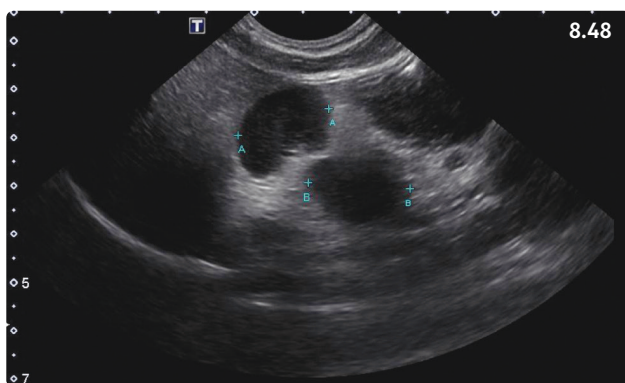
By the time animals develop clinical signs and are presented to a veterinarian, the neoplastic process is often advanced and severe. Probably due to a high prevalence of metastases at the time of diagnosis, surgical resection (antral resection and gastroduodenostomy, or Billroth type I procedure) does not significantly improve



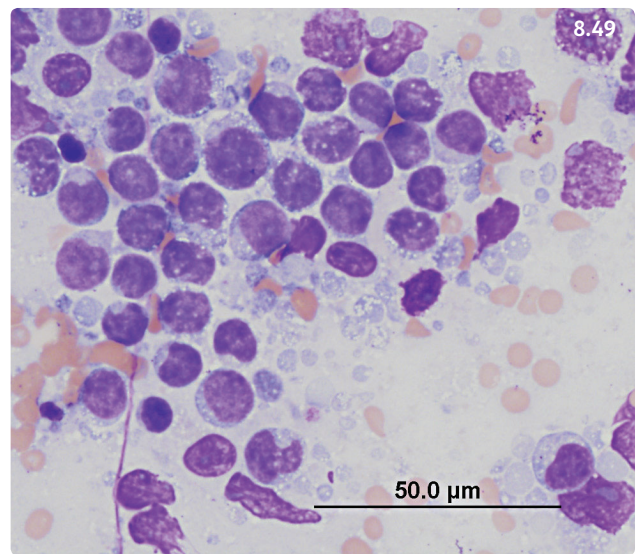
8.46



8.47



8.48



8.49

Figures 8.46–49 Twelve-year-old Domestic Shorthair cat with anorexia, weight loss, and lethargy of 4 weeks' duration. (8.46) Right lateral abdominal radiograph. The cat is severely overweight. Although the cat did not eat for 2 days, the stomach is distinctly visible and partially filled with gas (arrows). The gastric wall appears thickened at the level of the pyloric antrum (although this could also be due to summation of gastric fluid and gastric wall), and the serosal contour of the stomach is somewhat irregular. (Courtesy C. Montgomery) (8.47) Abdominal ultrasound of the same cat. The gastric wall at the level of the pyloric antrum is severely thickened (14.8 mm between the two calipers). (8.48) Abdominal ultrasound of the same cat. The gastric lymph nodes are very prominent (distance "A", 19.6 mm; distance "B", 21.2 mm). (Ultrasound images courtesy LSU SVM Diagnostic Imaging Service) (8.49) Cytologic evaluation of a fine needle aspirate from the gastric wall depicted in 8.47. A dense population of medium-sized lymphocytes and a few large lymphoblasts are visible, confirming the diagnosis of gastric lymphoma (50× objective). (Courtesy V. Le Donne)

the prognosis of dogs with gastric adenocarcinomas. However, surgery may be a successful option for canine leiomyosarcomas, with a reported median survival time of 12 months. While canine gastric lymphomas usually carry a poor prognosis, feline alimentary lymphomas may respond to specific chemotherapy protocols. Small cell feline alimentary lymphomas usually achieve prolonged remission with prednisolone (1–2 mg/kg PO daily) and chlorambucil (2 mg PO q48h) therapy. Large cell alimentary lymphomas require more aggressive chemotherapy protocols and their prognosis is less favorable.

Part 4: Diseases of the small intestine

Overview

Small intestinal diseases are common in dogs and cats. The small intestine is the intestinal segment where absorption of nutrients, electrolytes, and water takes place. Small intestinal brush border enzymes are essential for activation of pancreatic enzymes and final processing of nutrients before they can be absorbed through the mucosa using active and passive diffusion mechanisms.

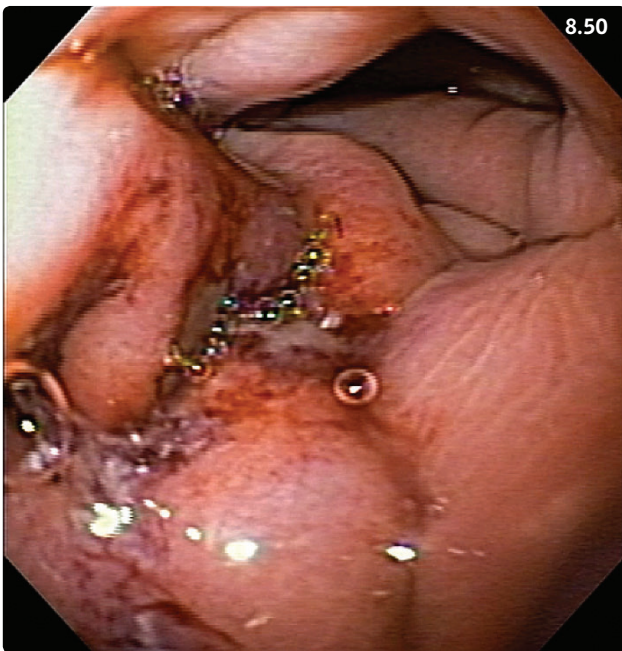


Figure 8.50 Close-up endoscopic view of a gastric adenocarcinoma in a 15-year-old female spayed Miniature Schnauzer. There are thickened mucosal folds surrounding an ulcerated area.

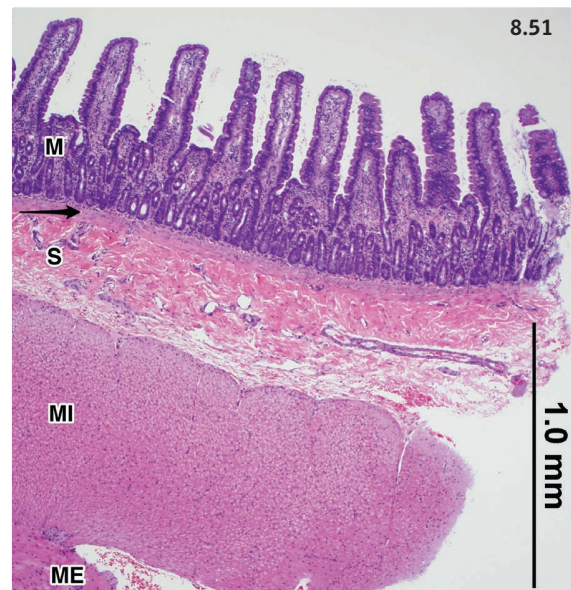


Figure 8.51 Photomicrograph of the jejunal wall in a cat at low power. M, mucosa; S, submucosa; MI, muscularis interna (circular muscle layer); ME, muscularis externa (longitudinal muscle layer); arrow (muscularis mucosae). H&E stain.

Small intestinal anatomy

The small intestine is divided into three anatomic segments: duodenum, jejunum, and ileum. The total surface of the small intestinal mucosa is multiplied by a factor of 500 through formation of mucosal villi and presence of microvilli on the luminal surface of the enterocytes. The microscopic structure consists of mucosa, submucosa, and both the internal and external muscular layers (**Figure 8.51**). The mucosa consists of villi, lamina propria, and muscularis mucosae (**Figure 8.52**). The epithelial cells multiply in the small intestinal crypts and migrate over a few days to the tips of the small intestinal villi while they are undergoing maturation.

Normal small intestinal function

Digestion and absorption

In the small intestine, pancreatic and gastric enzymes facilitate luminal digestion, while enzymes produced by epithelial cells and located in the brush border of enterocytes are responsible for triggering the activation of pancreatic enzymes and further processing of oligo- and disaccharides, small peptides, and lipids. Carbohydrates, amino acids, and fatty acids are transported actively or passively through the epithelial barrier using transcellular and paracellular pathways. Lipids undergo complex transformations in order to be absorbed into the

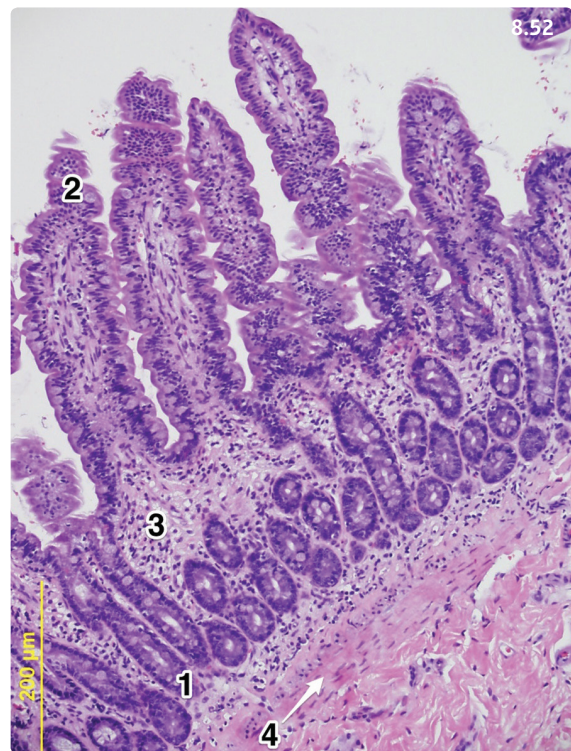


Figure 8.52 Photomicrograph of the jejunal mucosal layer in a cat. 1, jejunal crypt; 2, tip of jejunal villus; 3, lamina propria; 4, muscularis mucosae (arrow). H&E stain, 40× objective.

epithelial cells. Chylomicrons are formed in the enterocytes and diffuse into the lacteals to the thoracic duct. The intestinal barrier prevents free passage of intestinal content into the body and consists of the enterocytes with the glycocalyx that bathes their microvilli and the tight junctions that connect them on their lateral membrane.

Small intestinal motility

Three physiologic motility patterns are described in the small intestine: peristaltic waves (aboral movement of chyme over long intestinal segments), stationary contractions (leading to intestinal segmentation), and clusters of contraction (mixing and aboral movement of chyme over short segments). Diarrhea usually is associated with the occurrence of pathologic giant aboral contractions.

ACUTE ENTERITIS

Overview

Acute enteritis occurs frequently in dogs and cats and can be a sign of many diseases affecting the small intestine primarily or secondarily. The approach to diarrhea is explained in Chapter 2.6 (Table 2.6.1 lists the characteristics of small bowel diarrhea; Table 2.6.2 lists the various causes of acute diarrhea). This chapter provides further details on common causes of acute enteritis. Overall, viral and parasitic causes of enteritis are more commonly diagnosed in puppies and kittens, while bacterial enteritis and dietary indiscretion can occur at all ages; finally, acute hemorrhagic diarrhea syndrome (AHDS) affects middle aged to older dogs.

VIRAL ENTERITIS

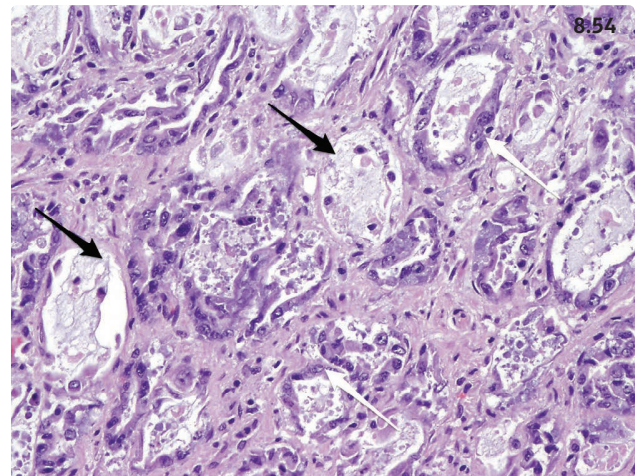
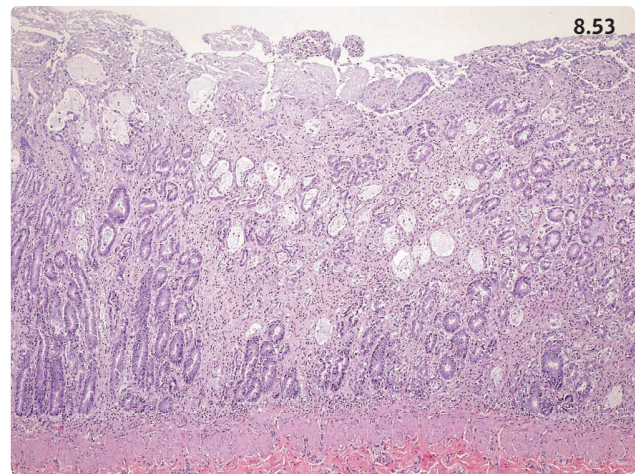
CANINE PARVOVIRAL ENTERITIS

Overview

The etiology, pathogenesis, diagnosis, and prevention of canine parvovirus infection are also discussed in Chapter 21 (Infectious diseases). The virus targets rapidly dividing cells such as small intestinal crypt cells (Figures 8.53, 8.54). It eventually greatly diminishes the absorptive capacity of the small intestine and compromises the intestinal barrier. The risk of bacterial translocation, bacteremia, and sepsis is greatly enhanced by the concurrent neutropenia.

Clinical presentation

The following breeds are at higher risk of infection: Rottweiler, Doberman, Labrador Retriever, American Staffordshire Terrier, German Shepherd Dog, and Alaskan Malamute. The most severe cases occur in puppies



Figures 8.53, 8.54 Six-month old dog with parvovirus infection. (8.53) Photomicrograph of the jejunal mucosa. There is severe villous atrophy with necrotic crypts (see 8.54). H&E stain, 40x objective. (8.54) Photomicrograph of the jejunal crypts. Several crypts lack epithelial lining (black arrows) and are filled with necrotic material, while others show evidence of epithelial regeneration (white arrows). (Courtesy N. Wakamatsu)

between the ages of 4 and 12 weeks, at the time when maternal immunity fades away. However, parvovirus infection is prevalent in dogs until 6 months of age. Anorexia and vomiting are often the first clinical signs observed. They are followed a few hours later by foul smelling, often bloody diarrhea (see Figure 2.6.7). Without treatment, puppies rapidly dehydrate. Fever is generally associated with secondary bacterial infection.

Intense vomiting and diarrhea may cause metabolic acidosis that often responds well to IV fluid therapy with crystalloids and colloids, and generally does not require administration of sodium bicarbonate. Hypokalemia results from GI loss and may contribute to the occurrence of intussusception. In severe cases,

severe complications, including sepsis and disseminated intravascular coagulation, may occur.

Differential diagnosis

In puppies or in young dogs presented for acute vomiting, the differential diagnosis must include GI FB and intestinal intussusception, which should be ruled out with abdominal radiographs. “Garbage can gut” and severe infestation with intestinal parasites may also cause hemorrhagic gastroenteritis.

Diagnosis

A preliminary diagnosis of parvovirus infection is made in the presence of acute hemorrhagic gastroenteritis in a young dog that is not adequately vaccinated. The probable presence of a highly contagious disease justifies drastic measures in order to prevent the spread of the infection in the veterinary hospital (isolation of the sick dog, thorough disinfection). Confirmation of diagnosis requires fecal testing for parvoviral antigen using a cage-side test. The antigen test may be positive during the viral shedding period, which lasts for 10–12 days after infection. However, the result may be false negative as viral shedding may wax and wane. Also, the test can give a false-positive result in dogs that have been recently vaccinated with a modified live vaccine. In such cases, fecal PCR may be useful to differentiate vaccine and wild type virus. Neutropenia is a typical finding in dogs with parvovirus infection; however, it is not always present at the time of the initial veterinary visit. Detection of other laboratory changes may be useful to set up an adequate treatment plan. Electrolyte abnormalities, especially hypokalemia, should be corrected. Panhypoproteinemia (characterized by simultaneous presence of hypoalbuminemia and hypoglobulinemia) is due to intestinal protein loss. Depending on the severity of the problem, natural or synthetic colloids should be used to support oncotic pressure.

Management

Aggressive treatment is required and consists of rapid correction of fluid deficits and electrolyte imbalances. Crystalloids and colloids are used in adequate amounts with added electrolyte solutions as needed. However, a recent scientific abstract has suggested good success in treating dogs with parvovirus infection on an outpatient basis (Box 8.6).

It is essential to stop the vomiting as quickly as possible. A variety of antiemetic agents are available (see Chapter 2.4, Table 2.4.1). A combination of these antiemetic drugs with different modes of action is sometimes required to obtain the desired result. Recent research

Box 8.6 Practical tip: outpatient treatment of canine parvovirus infection.

An outpatient treatment for dogs with parvoviral enteritis was evaluated in a recent study. After initial in-hospital stabilization with IV fluids, the outpatient treatment consisted of:

- SC administration of isotonic fluids (40 ml/kg q8h after replacement of fluid deficits)
- Enteral nutrition
- Daily SC injections of maropitant (1 mg/kg)
- One SC injection of cefovecin (8 mg/kg), a proprietary long-acting 3rd generation cephalosporin.

The 80% survival rate compared favorably with the 90% recovery rate in hospitalized parvovirus patients treated with IV fluids. Also, there was no difference in time to recovery between the hospitalized and the outpatient group. The results of this study appear to document the validity of an alternative option for owners who cannot afford the costly hospitalization for puppies and young dogs infected with parvovirus.

Source: Preisner K, Sullivan L, Boscan P *et al.* (2013) Evaluation of an outpatient protocol in the treatment of canine parvoviral gastroenteritis. *J Vet Intern Med* **27**(3):721 (Abstract)

has shown the benefits of early feeding in very small amounts; dogs that received early nutrition after they stopped vomiting had a lower mortality and a faster weight gain during recovery.

Because of the risk of secondary bacterial infection, parenteral administration of broad-spectrum antibiotics such as amoxicillin and clavulanic acid (12.5–20 mg/kg IV q12h) is recommended. Parenteral aminoglycosides (with risk of nephrotoxicity) or fluoroquinolones (e.g. enrofloxacin, 10 mg/kg q24h, off-label in growing dogs) may be added to improve efficacy against gram-negative bacteria.

Disinfection of contaminated surfaces is essential in order to prevent spread of infection. Disinfectants with demonstrated efficacy against parvovirus include sodium hypochlorite, aldehydes, and oxidizing agents. A 1:30 dilution of commercially available bleach is efficacious after 10 contact minutes. However, bleach is a mucosal irritant and may damage metals, rubber, plastic, and cement. It is inactivated by light, thus it is preferable to prepare solutions immediately before their use. It is also inactivated in the presence of organic material such as mud or feces. Oxidizing solutions such as hydrogen peroxide (Virox[®], Accel[®]) and potassium peroxide monosulfate (Virkon[®], Trifectant[®]) claim extremely high efficacy within minutes with minimal corrosive effect.

Prognosis

Dogs with mild to moderate disease generally have a good prognosis if appropriate treatment is initiated early. In severe cases the prognosis is fair because complications are more common and therapy is more intensive. Overall, quick diagnosis and early and aggressive treatment optimize therapeutic success.

OTHER VIRAL INTESTINAL INFECTIONS

Feline panleukopenia and canine and feline coronavirus infections are discussed in detail in Chapter 21 (Infectious diseases).

BACTERIAL ENTERITIS

Overview

The term intestinal microbiota describes all microorganisms naturally present in the intestinal lumen. The small intestinal microbiota has important functions in the preservation of anatomic structures and for the proper occurrence of physiologic processes necessary for digestion of food and absorption of nutrients. It also plays an important role in the prevention of colonization of the mucosa by pathogenic bacteria, and exerts a positive influence on the development of the enteric immune system.

Rarely, dogs and cats may develop bacterial enteritis. Responsible pathogenic agents include *Campylobacter*, *Clostridium perfringens* and *Clostridium difficile*, and *Salmonella* spp., as well as specific strains of *Escherichia coli*. However, these same bacteria can also be isolated in the feces of healthy dogs and cats. While the exact role of bacterial enteropathogens in dogs and cats with enteritis remains controversial, they may present a risk of zoonotic infection for people after contact with shedding dogs and cats. These facts have contributed to an unclear situation that renders diagnostic and therapeutic decisions difficult. If these bacteria are not the source of the animal's problems, use of antibiotics is not recommended because it may lead to development of resistant strains, which in the long term may have repercussions on public health. Additional research is necessary to more clearly define the role of enteropathogens in canine and feline intestinal diseases.

CAMPYLOBACTERIOSIS

Etiology

Campylobacter spp. are slender, curved gram-negative bacilli with polar flagellae that generally have a spiral shape (Figure 8.55). According to numerous studies,

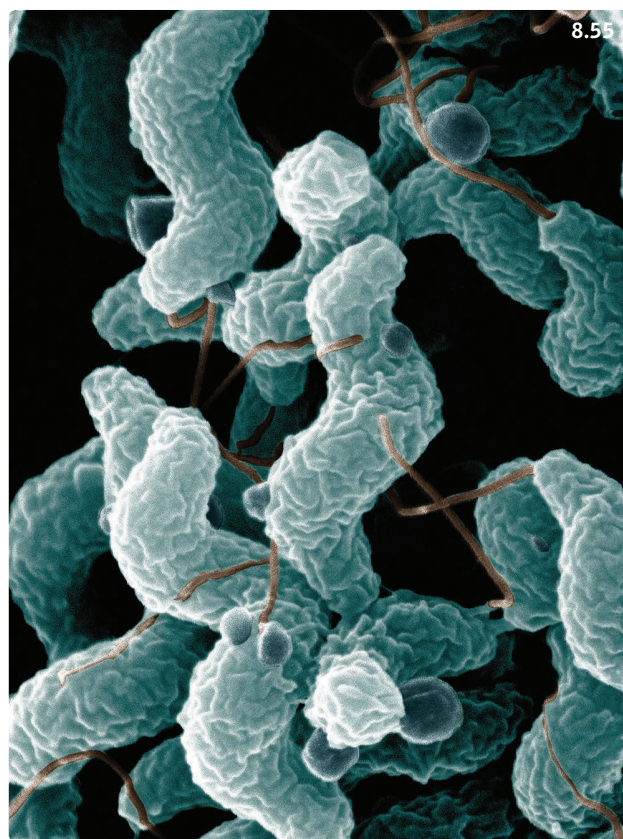


Figure 8.55 *Campylobacter jejuni*. Scanning electron microscope view. (Source: USA Department of Agriculture)

C. upsaliensis, *C. jejuni*, *C. helveticus*, and *C. coli* may be present in the feces of healthy and diarrheic cats and dogs.

Pathophysiology

Campylobacter attach to enterocytes, invade them, and produce enterotoxin-like substances. However, the true role of *Campylobacter* as a cause of diarrhea in dogs and cats is difficult to assess, since both healthy and diarrheic animals may shed these bacteria in their feces. In people, *Campylobacter* may cause abdominal discomfort, fever, and (possibly bloody) diarrhea. The disease is often self-limiting, but may require antibiotic treatment. Risk factors for infection in people include consumption of poultry cooked at home, drinking water from a well, a lake or a river, and daily contact with a dog. Consequently, fecal excretion of *Campylobacter* in healthy pets appears to represent a possible source of infection.

Clinical presentation

Campylobacter may colonize both the small intestine (jejunum, ileum) and colon and cause enterocolitis. Therefore, clinical signs may include small and/or large intestinal

diarrhea of varying severity in puppies and kittens as well as adult animals. The disease is usually self-limiting (1–2 weeks).

Differential diagnosis

Other causes of acute enteritis and/or colitis such as parvovirus infection (in puppies), parasite infestation with hookworms, whipworms, *Giardia*, *Cryptosporidium*, or *Tritrichomonas* (cats), other bacterial infections, dietary indiscretion, AHDS (see below).

Diagnosis

Clinical signs of acute enterocolitis (with possible complications such as dehydration) and positive fecal culture or PCR test are suggestive. However, *Campylobacter* may also colonize the intestine as opportunists and be retrieved in feces from healthy and sick dogs and cats. Documentation of spiral-shaped bacteria on fecal cytology is not a useful tool to confirm the diagnosis because it does not allow differentiation between *Campylobacter* and other nonpathogenic, spiral-shaped gram-negative bacteria.

Management

In animals with diarrhea, vomiting, and/or other clinical signs of enterocolitis, appropriate antibiotic treatment is often recommended even if the cause-to-effect relationship between fecal presence of *Campylobacter* and clinical disease is difficult to confirm. Antibiotics of choice for treatment of campylobacteriosis in dogs and cats include macrolides (e.g. erythromycin, 10–20 mg/kg PO q12h; azithromycin, 5–10 mg/kg q24h for 10–14 days) and fluoroquinolones (e.g. enrofloxacin, 5–10 mg/kg PO q24h for 1 week). Repeat culture or fecal PCR is recommended after completion. Use of probiotics may be beneficial (**Box 8.7**). Owners should be advised about proper hygiene.

Prognosis

Generally excellent. If an unrelated enteropathy is present, therapeutic success depends on identification and treatment of the underlying disease.

CLOSTRIDIAL INFECTION

Etiology

Clostridia are gram-positive anaerobic bacteria that produce endospores. *Clostridium perfringens* is broadly distributed in the environment. It has been cultivated from 70% or more feces of healthy dogs and diarrheic dogs. It produces enterotoxin, and only 5–14% of isolates from healthy dogs and 15–34% from diarrheic dogs are

Box 8.7 Practical tip: use of probiotics in acute enteritis.

Probiotics are living microorganisms that may modulate intestinal immune function, promote epithelial cell homeostasis, exert neuromodulatory effects, block the effects of pathogenic bacteria, and have nutritional benefits.

Probiotics designed for use in dogs and cats and manufactured by reputable pharmaceutical or pet food companies are preferred, as over the counter products have been shown not to be as reliable. Some products contain one bacterial strain while others have several strains.

They have been shown to shorten the duration of acute diarrhea in shelter cats and to decrease the time to first normal feces in dogs with acute enteritis. In a recent open study of dogs with IBD, a multi-strain highly concentrated probiotic administered for 60 days appeared to be as efficient as a combination of prednisone and metronidazole.

Probiotics should be administered for 2–4 weeks to animals with acute enteritis and probably for months in dogs and cats with chronic enteritis. It may be preferable to delay the initiation of probiotic treatment in dogs with bloody diarrhea and compromised intestinal mucosal barrier until the hemorrhagic diarrhea has resolved.

enterotoxigenic. Enterotoxigenic *C. perfringens* causes food-associated toxin infections in people. *Clostridium difficile* produces two toxins (toxins A and B). In various studies *C. difficile* was detected in feces from healthy puppies and their dam, from healthy adult cats and dogs, and from cats and dogs with diarrhea presented to veterinary clinics. In people, infections with toxigenic *C. difficile* are a frequent cause of nosocomial enteric infections, and are associated with antibiotic use and pseudomembranous colitis.

Pathophysiology

High concentrations of pathogenic clostridial toxins in the intestinal lumen may cause enteritis, but this hypothesis has not been confirmed.

Clinical presentation

In dogs and cats, clostridial infections have been associated with nosocomial diarrhea, hemorrhagic enterocolitis, and acute or chronic small and/or large bowel diarrhea. *C. perfringens* may also be implicated in the pathogenesis of AHDS (see below).

Differential diagnosis

See Campylobacteriosis.

Diagnosis

Confirmation of diagnosis is problematic in small animals. Fecal isolation or PCR amplification of *C. perfringens* or *C. difficile* does not confirm that clostridia are indeed responsible for the diarrhea. Similarly, a fecal endospore count performed on fecal smears is not reliable. Fecal enterotoxin and toxins A and B can be detected using immunoenzymatic methods, and the presence of toxin genes can be confirmed with PCR amplification. However, the precise value of diagnostic tests for clostridial toxins in confirming the pathogenicity of *C. perfringens* or *C. difficile* still needs to be established.

Management

Clostridial enteritis and/or colitis are generally self-limiting and respond well to supportive treatment. The necessity for antimicrobial therapy is subject to discussion. *C. perfringens* and *C. difficile* are considered to be sensitive to ampicillin, metronidazole, and tylosin. Use of probiotics may be beneficial (**Box 8.7**). In cases of hospital-associated diarrhea, the required disinfection measures must be implemented, and a good infection prevention protocol should be enforced.

Prognosis

Excellent if proper treatment can be given.

SALMONELLOSIS

Etiology

Salmonella are rod-shaped facultative anaerobic gram-negative bacteria of the Enterobacteriaceae family. The majority of *Salmonella* relevant to veterinary medicine are serovar *S. enterica* subspecies *enterica*.

Pathophysiology

Salmonella are enteroinvasive bacteria that may induce acute mucosal inflammation resulting in enterocolitis, mucosal sloughing, and secretory diarrhea. While most *Salmonella* infections remain localized to the GI tract, bacterial translocation and septicemia may occur and cause severe systemic complications. Generally, healthy adult carnivores are resistant to salmonellosis. The prevalence of healthy carriers is highest in shelters.

In people, salmonellosis is characterized by diarrhea, fever, and abdominal cramps, often mild to moderate in severity and followed by spontaneous recovery. The most common infection pathway is through ingestion of contaminated food, in particular chicken eggs and egg-based products, but also pork and chicken meat or contaminated vegetables. Even though dogs and cats are only rarely

implicated in outbreaks of human salmonellosis, isolated foci have been associated with visits to a veterinary hospital. This is why excellent hygiene is recommended around dogs and cats shedding *Salmonella*, particularly if sensitive subjects such as very young children, elderly people, and immunocompromised patients may be exposed.

Clinical presentation

Fever, vomiting, small and/or large bowel diarrhea, anorexia, weight loss, and lethargy. In case of bacterial translocation, signs of sepsis and involvement of other organs.

Differential diagnosis

See Campylobacteriosis.

Diagnosis

Fecal isolation and serotyping of *Salmonella*, PCR. CBC may show changes suggestive of systemic inflammation, and biochemistry profile may indicate involvement of other organs.

Management

Treatment consists of administration of antimicrobial drugs on the basis of documented sensitivity of the isolated strain.

Prognosis

Animals recovering from clinical salmonellosis may become healthy *Salmonella* carriers for weeks after the clinical signs have subsided. This may be due to persistence of *Salmonella* in the lymph nodes. *Salmonella* may survive for long periods in the environment.

PARASITIC ENTERITIS

The Companion Animal Parasite Council (CAPC) maintains a very informative and freely accessible website on intestinal parasitoses of small animals that should be consulted for additional information (www.capcvet.org).

HOOKWORMS

Etiology

Hookworms are common in tropical and subtropical areas (*Ancylostoma caninum* – dog; *A. tubaeforme* – cat) and warm coastal regions (*A. braziliense* – dog, cat), but also in cooler climates (*Uncinaria stenocephala* – dog). Adult hookworms live in the small intestine and produce eggs that are shed with the host's feces, and develop to 3rd stage larvae (L3), which are infectious. Dogs and

cats infect themselves by ingesting L3 (direct fecal–oral transmission, ingestion of infected paratenic hosts such as flies, cockroaches, and dung beetles), or through penetration of the skin by L3. In dogs, puppies can be infested by nursing an affected bitch (transmammary infection). Some larvae undergo arrested development in muscle and can be reactivated during stressful events and migrate to the intestine.

Pathophysiology

Adult hookworms ingest the host's blood and cause intestinal inflammation (Figure 8.56).

Clinical presentation

The clinical signs consist mainly of small bowel diarrhea. Blood loss anemia can be life threatening in puppies (Figure 8.57). Hyporexia, weight loss, poor hair coat, and pica may also be observed. In dogs that were infected percutaneously, pruriginous skin lesions may occur at the points of entry, particularly in the interdigital spaces.

Differential diagnosis

Other causes of acute enteritis. Acute blood loss anemia in puppies may also be caused by heavy flea infestation, which may occur concurrently to hookworm infestation in stray puppies and kittens from tropical and subtropical areas.

Diagnosis

Fecal flotation and visualization of the parasite ova (Figure 8.58).

Management/prevention

Treatment with pyrantel pamoate (5–10 mg/kg PO, repeat after 7–10 days) is approved for all hookworm species. Fenbendazole (50 mg/kg PO q24h for 3 consecutive days) is also efficient. The efficacy of avermectins such as moxidectin, milbemycin oxime, and ivermectin differs between species. Supportive treatment as required: for example, anemic puppies and kittens often require blood transfusion (whole blood or packed red blood cells).

Detailed preventive treatment protocols can be found on the CAPC website.

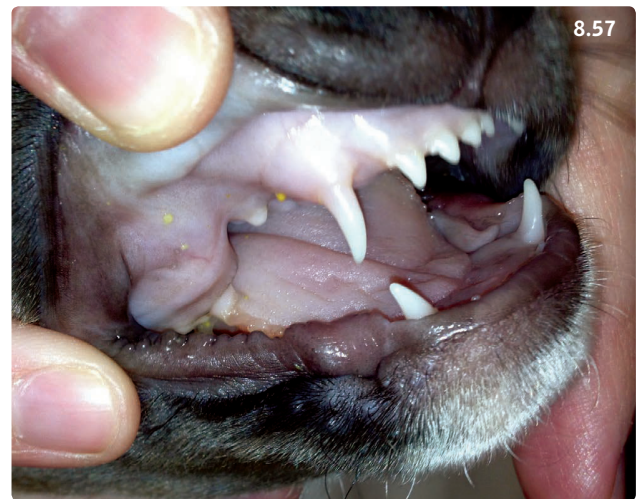


Figure 8.57 Pale oral mucous membranes in a 12-week-old mixed-breed puppy with massive hookworm infestation.

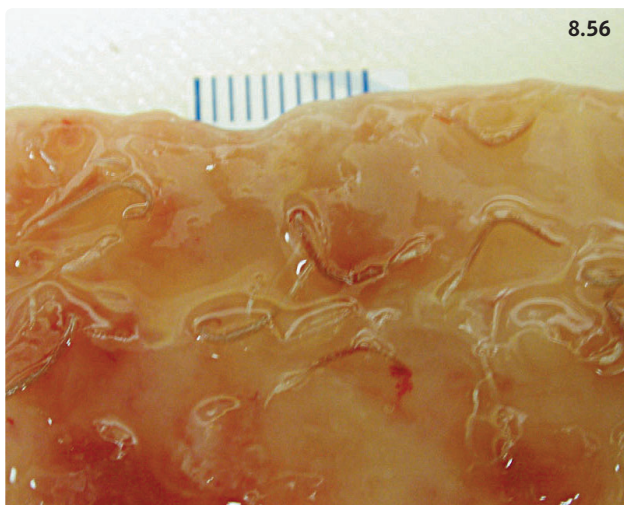


Figure 8.56 Postmortem view of hookworms causing damage to a dog's small bowel mucosa.

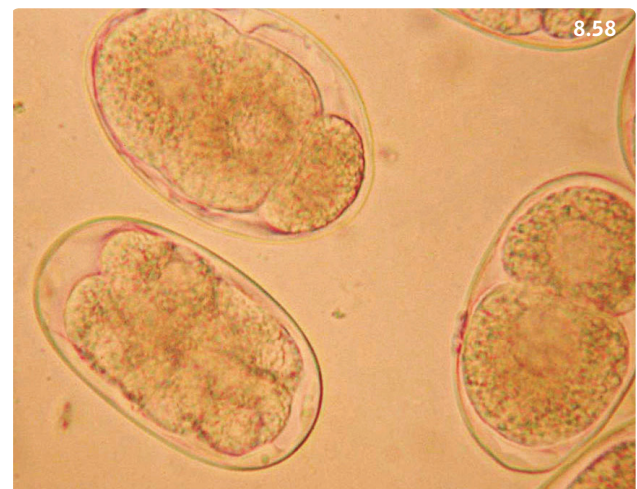

Figure 8.58 Photomicrograph of an *Ancylostoma caninum* ova. (Courtesy E. Greiner)

Public health consideration

Cutaneous larva migrans can occur when hookworm larvae penetrate human skin and result in a pruriginous but self-limiting dermatitis.

Prognosis

Good to excellent.

ROUNDWORMS

Etiology

Ascarids that may infest small animals include *Toxascaris leonina* (dogs and cats), *Toxocara canis* (dog), and *Toxocara cati* (cat). Additionally, *Baylisascaris procyonis* (the raccoon roundworm) may also occasionally infest dogs in North America. Adult roundworms live in the small intestine (Figure 8.59) and produce eggs that are shed in the feces. Larvae are released upon ingestion of embryonated eggs and migrate to the liver and lungs. Pulmonary lesions can induce clinical signs in puppies. Larvae then undergo tracheal migration, and eventually infest the small intestine, or somatic migration, with formation of cysts in tissues with possible reactivation in stressful situations.

Pathophysiology

Adult roundworms cause enteritis, particularly in puppies and kittens.

Clinical presentation

Puppies and kittens: vomiting, small intestinal diarrhea, poor general health, and development of a potbelly are common. Heavy infestation can result in small intestinal obstruction or intussusception. It can also cause pulmonary signs such as coughing and tachypnea. Adult dogs

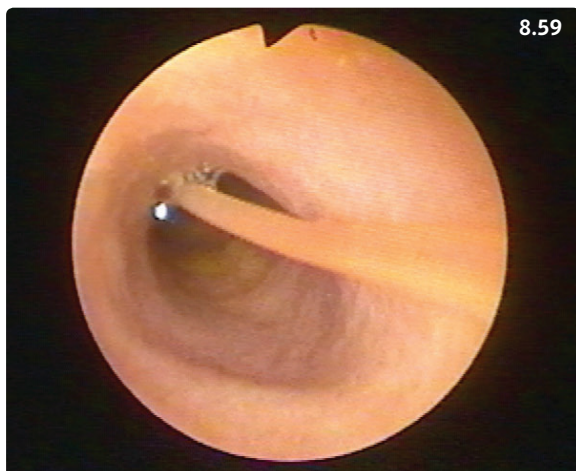


Figure 8.59 Endoscopic view of an adult roundworm in the duodenum of a cat. (Courtesy R. Husnik)

and cats: infestation is less common, and less likely to cause clinical signs.

Differential diagnosis

In puppies and kittens other causes of acute enteritis; intestinal FBs if the roundworms cause bowel obstruction.

Diagnosis

Fecal flotation and visualization of the parasite ova (Figure 8.60).

Management/prevention

Piperazine, pyrantel pamoate, fenbendazole, and selected avermectins (e.g. milbemycin oxime, moxidectin) should be given to eliminate roundworms. Supportive treatment should be administered as required.

Detailed preventive treatment protocols can be found on the CAPC website.

Public health consideration

In people, ingestion of embryonated eggs from *Toxocara* spp. may lead to larva migrans and cause pulmonary and hepatic disease, retinitis, and neurologic disease. *Toxocara* larva migrans can have a devastating outcome in people.

Prognosis

Excellent.

ISOSPORA SPP.

Etiology

Dog – *Isoospora canis*, *I. ohioensis*, *I. neorivolta*, *I. burrowsi*.
Cat – *I. felis*, *I. rivolta*. Sporulated oocysts are ingested

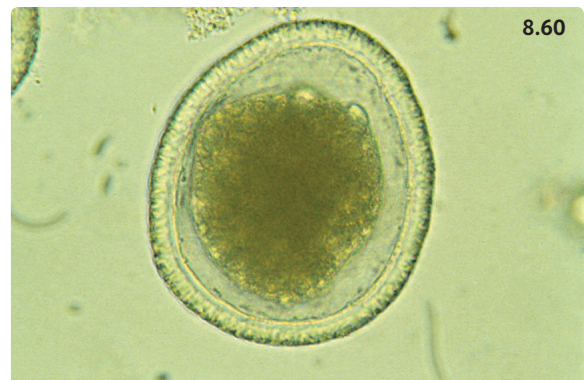


Figure 8.60 Photomicrograph of a *Toxocara canis* egg. (Courtesy E Greiner)

(directly or via paratenic hosts) and further develop in the small intestinal enterocytes (entero-epithelial cycle).

Pathophysiology

Isospora spp. replicate in the small intestine and may induce villus atrophy, lacteal dilation, and hyperplasia of the lymphatic follicles in Peyer's patches.

Clinical presentation

Clinical signs generally only occur in puppies and kittens, and may consist of vomiting, watery diarrhea, abdominal pain, and dysorexia. Dehydration and death can occur in severe cases.

Differential diagnosis

Other causes of acute enteritis in puppies and kittens.

Diagnosis

Isospora spp. oocysts are usually large and easy to detect on microscopic examination of supernatant fluid after fecal flotation.

Management

While the disease is generally self-limiting, treatment may be required in clinical situations. The poorly absorbed sulfa drug sulfadimethoxine (50–60 mg/kg PO q24h for 5–20 days) is the only approved anticoccidial drug for dogs and cats in the USA (and in the UK). Other antiprotozoal drugs, such as ponazuril (20 mg/kg PO q24h for 1–3 days), are frequently administered off-label to dogs and cats after adequate compounding. In breeding facilities and shelters, proper cleaning of the environment (prompt elimination of feces before oocysts sporulate, steam cleaning of contaminated surfaces), treatment of dams prior to parturition, and preventive anticoccidial treatment of all puppies and kittens may be required.

Prognosis

Excellent.

DIETARY INDISCRETION

Definition/overview

Dietary indiscretion is probably the most common cause of acute gastroenteritis in dogs. Overall, puppies and young dogs are more commonly affected than older dogs. Some canine breeds such as Retrievers are known to be prone to dietary indiscretion. Cats are more discriminant eaters, and dietary indiscretion is rarely diagnosed in this species.

Etiology

Ingestion of unusual food such as food prepared for human consumption, garbage that may contain food in various stages of decomposition, or any other food not usually part of the affected dog or cat's diet.

Pathophysiology

Toxins from rotting food cause small intestinal mucosal irritation and may cause osmotic and secretory diarrhea. Unusual food, such as food prepared for human consumption cannot be properly digested and absorbed, and thus can cause osmotic diarrhea.

Clinical presentation

Acute diarrhea (with or without vomiting) is the most common presentation. Lethargy, hyporexia, dehydration and electrolyte imbalances, and abdominal discomfort are common accompanying signs.

Differential diagnosis

Other causes of acute gastroenteritis/enteritis such as parasite infestation and viral or bacterial enteritis. In vomiting animals, intestinal obstruction should be ruled out with appropriate abdominal imaging (**Figure 8.61**). In puppies with possible exposure and questionable immune status, parvovirus infection should be ruled out prior to hospitalization.

Diagnosis

History and presentation are often very suggestive.

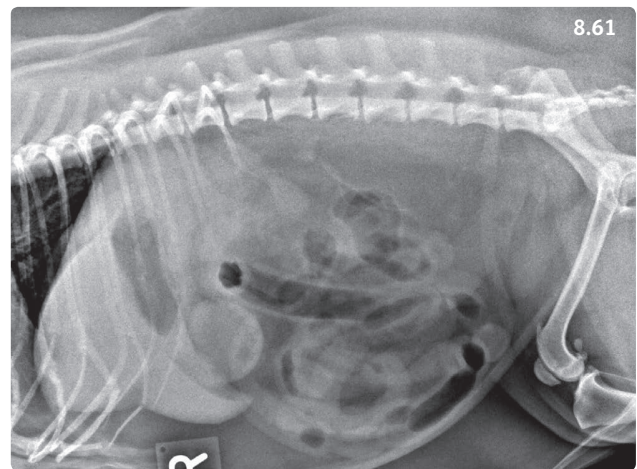


Figure 8.61 Right lateral abdominal radiograph from an adult mixed-breed dog with dietary indiscretion and functional ileus. Generalized distension of small intestinal loops is present. (Courtesy L. Gaschen)

Management

Supportive with administration of fluids (IV, SC, or PO depending on the severity of clinical signs), and antiemetics in vomiting or nauseous animals. A 12–24-hour fast is implemented (puppies will require parenteral glucose solution during fasting in order to avoid hypoglycemia), followed by offering small meals consisting of commercial or home-made, easily digestible diet for 3–5 days and progressive return to a balanced diet after that. Probiotics may be useful (**Box 8.7**). In dogs with severe diarrhea and abdominal discomfort, loperamide (0.1–0.2 mg/kg PO q8h) or diphenoxylate (0.1 mg/kg PO q8h) may be indicated for 24–72 hours, although this is only rarely necessary. Dogs that live in multi-story high-rise buildings might also be candidates for antidiarrheal drugs because of the difficult logistics for bringing them outdoors for defecation.

Prognosis

Good to excellent in most cases. Recurrences are common in dogs prone to eating offending foods.

ACUTE HEMORRHAGIC DIARRHEA SYNDROME

Definition/overview

AHDS is a new name proposed to describe the canine syndrome known for decades as hemorrhagic gastroenteritis (HGE). A recent study demonstrated that affected dogs do not have any gastric inflammation. The syndrome can affect dogs of all breeds and all ages, although middle aged dogs of small and toy breeds seem to be predisposed.

Etiology

The etiology of AHDS/HGE is not known, although abundant *Clostridium perfringens* were shown to be present in the duodenum of affected dogs. Other hypotheses include dietary or microbial toxins and severe dietary indiscretion.

Pathophysiology

It is unclear if clostridial proliferation is a cause or a consequence of the disease. Clostridial toxins do not appear to be significantly involved in the pathogenesis. In addition, acute enteritis has negative repercussions on species diversity of the intestinal microbiota, and may cause acute dysbiosis.

Clinical presentation

Acute onset bloody diarrhea (**Figure 8.62**), possibly with vomiting and anorexia. Affected dogs are usually very dehydrated and in various stages of hypovolemic shock. Lethargy and abdominal pain are also common.

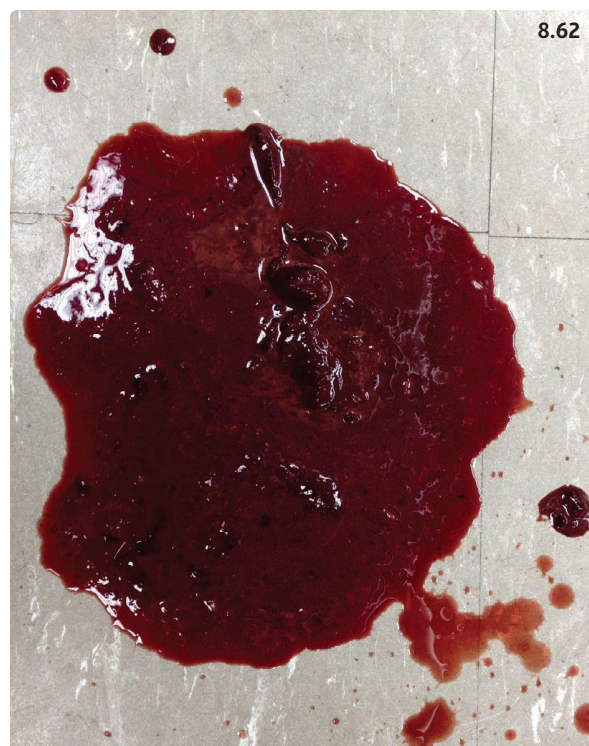

Figure 8.62 Hemorrhagic diarrhea from a dog with acute hemorrhagic diarrhea syndrome.

Differential diagnosis

Parvovirus infection, bacterial infections, salmon poisoning disease, severe parasite infestations, dietary indiscretion, intestinal volvulus or intussusception, acute necrotizing pancreatitis, acute liver disease, hypoadrenocorticism, sepsis, immune-mediated thrombocytopenia, and vitamin K antagonist rodenticide toxicosis.

Diagnosis

Initially, affected dogs typically have a high PCV (often above 65%) and a normal or low serum concentration of total solids (or total proteins, albumin, or globulins). White blood cell counts may be normal, high, or low depending on the severity of disease. Mild thrombocytopenia is common. Other serum biochemistry changes may include pre-renal azotemia, increased liver enzymes, hypoglycemia, and electrolyte abnormalities. Metabolic acidosis is often present. Abdominal radiographs usually show an enteritis pattern with fluid- and gas-filled small intestinal loops.

Management

Aggressive fluid therapy. IV boluses of isotonic crystalloid solutions (10–20 ml/kg) should be given to treat hypovolemic shock. Addition of synthetic colloids such as hetastarch may be useful (5–10 ml/kg with 10 ml isotonic

crystalloids, continued with CRI of 1 ml/kg/hour). Perfusion and cardiovascular status should be reassessed every 15 minutes, and further boluses administered as required until normal blood pressure is restored. Fluid deficits should be replaced over a 6–12-hour period with crystalloid solutions, adding the maintenance requirements and estimated ongoing losses due to continuing diarrhea. Electrolyte deficits such as hypokalemia should also be corrected. Other treatments include antiemetics and possibly gastric antacids if decreased perfusion of the gastric mucosa is suspected (see **Table 8.6**). The PCV generally normalizes in response to aggressive fluid therapy, and the serum protein concentration usually drops to levels indicative of hypoproteinemia, with both low serum albumin and globulin concentrations (**Figure 8.63**).

Broad-spectrum antibiotics should be administered IV in severe cases with existing or impending sepsis. This is particularly important when mucosal sloughing is present. However, in the absence of these problems, systemic use of antibiotics is not recommended. A recent study showed that cases of mild to moderate severity do not appear to benefit from antimicrobial treatment when endpoints such as time to resolution of diarrhea and length of hospital stay are compared between dogs given amoxicillin and clavulanic acid and those receiving placebo. Probiotics are recommended after resolution of bloody diarrhea (**Box 8.7**).

Dogs with AHDS/HGE should be fasted for 12–24 hours and then offered small quantities of easily digestible food frequently (boiled chicken and rice, adequate commercial prescription diets). Puppies should receive parenteral glucose supplementation.

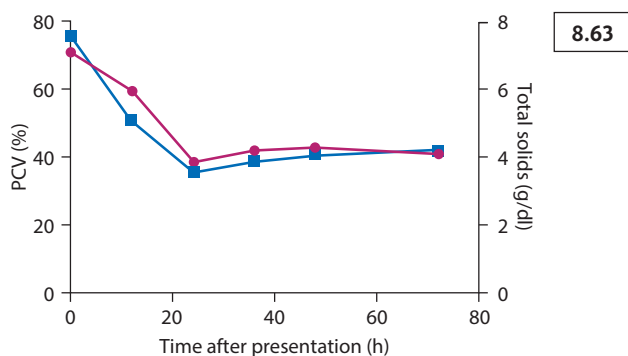


Figure 8.63 Evolution of PCV (red line) and total solids (blue line) with treatment in a 6-year-old Miniature Schnauzer dog with acute hemorrhagic diarrhea syndrome. The initial PCV was 70% (reference range 35–55). The total solids plummeted from 7.5 to 3.5 g/dl within 24 hours with aggressive fluid therapy (reference range 5.8–7.5).

Prognosis

Good when dogs are presented early in the course of the disease. Most dogs can be discharged following 1–7 days of fluid therapy (median 3 days in a recent study). Serious complications may include disseminated intravascular coagulation, sepsis, and aspiration pneumonia in vomiting animals. AHDS/HGE may be fatal if the emergent needs of the patient are addressed too late.

INTESTINAL OBSTRUCTION

Etiology

Small intestinal obstruction most often results from FBs such as peach pits, corn cobs, toys, and fish hooks in dogs and linear foreign bodies in cats. Other differential diagnoses for intestinal obstruction include intussusception and neoplasia. Intussusceptions (**Figure 8.64**) are seen mostly in young animals, particularly in conjunction with severe acute enteritis, such as parvovirus infection or ascarid infestation, but can also be seen in cases of chronic diarrhea, such as IBD, and intestinal neoplasia. Intestinal volvulus (torsion) is a rare disorder in dogs that involves intestinal rotation at the root of the mesentery, with complete occlusion of the cranial mesenteric artery (**Figure 8.65**). This results in bowel necrosis, release of toxins, and life-threatening hypovolemic and septic shock. Most cases have been reported in adult, medium to large breed male dogs.

Pathophysiology

Small intestinal obstruction generally causes an accumulation of intestinal content, fluid, or gas in the loops located cranial to the site of obstruction. Intussusceptions

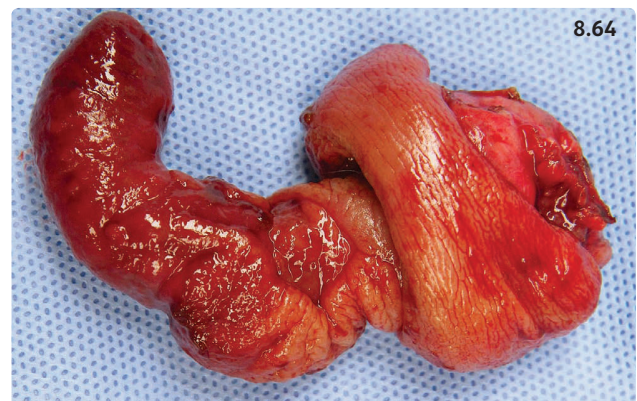


Figure 8.64 An ileocolic intussusception was diagnosed and surgically removed from a 1-year-old male Beagle with chronic diarrhea. Shown is the cecum that was prolapsed into the ascending colon. (Courtesy A. Grooters and K. Saile)

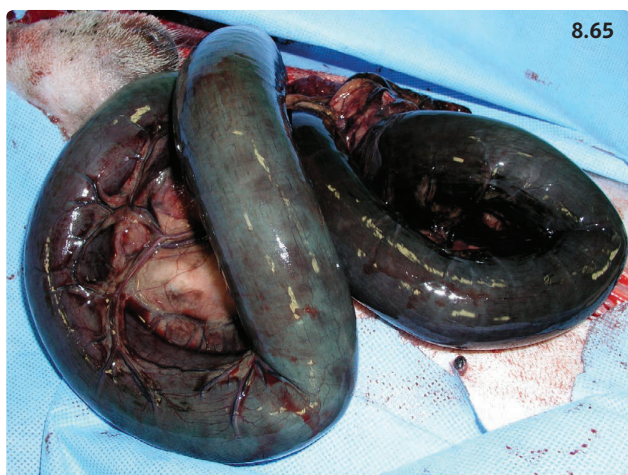

Figure 8.65 Intestinal volvulus in a dog. The small bowel loops are dilated with a hemorrhagic, necrotic wall. (Courtesy R. Husnik)

are thought to occur as a complication of abnormal intestinal motility associated with enteritis or with abnormal intestinal masses.

Clinical presentation

Clinical findings are related to the site, severity, and cause of the obstruction. Complete upper intestinal obstruction results in severe vomiting associated with fluid loss and dehydration and possible hypovolemic shock. Partial obstructions often present with an insidious onset of vomiting and intermittent chronic diarrhea.

Differential diagnosis

Dietary indiscretion or other causes of acute gastroenteritis and acute pancreatitis are the top differentials.

Diagnosis

The history is sometimes helpful for raising suspicion of a FB. A thorough physical examination is important in all cases, including inspection of the base of the tongue for linear foreign bodies, especially in cats (see Chapter 2.4: Vomiting, **Figure 2.6.9**). Abdominal palpation may reveal discomfort or pain, and an FB or intussusception may be identifiable. Abdominal radiographs are essential to document or rule out obstruction (**Box 8.8**). Signs of intestinal obstruction are readily recognizable (**Figures 8.66–8.69**). In severe cases, signs of bowel perforation, such as decreased serosal detail and free abdominal gas, may be present as well. Additionally, abdominal ultrasound may help confirm the diagnosis of intussusceptions and masses. A minimum database consisting of CBC, biochemistry panel, and urinalysis may help characterize the

Box 8.8 Practical tip: antiemetics may mask the signs of gastrointestinal foreign bodies.

Several effective antiemetics are currently available to veterinarians:

- Metoclopramide, which can be administered as a CRI to dogs and cats receiving IV fluids (1–2 mg/kg q24h)
- Ondansetron (0.5–1 mg/kg IV or SC q12h) and dolasetron (0.6–1 mg/kg SC or IV q12h)
- Maropitant (1 mg/kg IV or SC q24h)

These antiemetics may suppress vomiting in patients with gastric or small intestinal foreign bodies, and thus delay proper treatment involving foreign body retrieval via exploratory celiotomy or endoscopy (for gastric foreign bodies only). Delayed treatment may make it necessary to resect intestinal tissue (when enterotomy would have been sufficient with early intervention) or even increase the risk of perforation. Consequently, abdominal radiographs should be performed as soon as possible in dogs and cats with history and clinical signs compatible with a GI foreign body in order to rule out obstruction.

fluid and electrolyte losses and document inflammation or sepsis in complicated cases.

Management

Treatment of intestinal obstruction involves surgical removal of the cause of the obstruction (**Figure 8.70**). Broad-spectrum antibiotics should be given IV to patients with signs of intestinal perforation (e.g. amoxicillin, 20 mg/kg q8h; enrofloxacin, 10 mg/kg q24h; and metronidazole, 10–15 mg/kg q12h).

Prognosis

In the absence of complications such as intestinal perforation, the prognosis after surgical extraction of a FB is excellent. The risk of suture dehiscence at the enterotomy or enterectomy site is higher in the presence of peritonitis (i.e. perforation). There is a risk of recurrence for intussusceptions unless the underlying disease is controlled. For intestinal volvulus, the prognosis is usually grave.

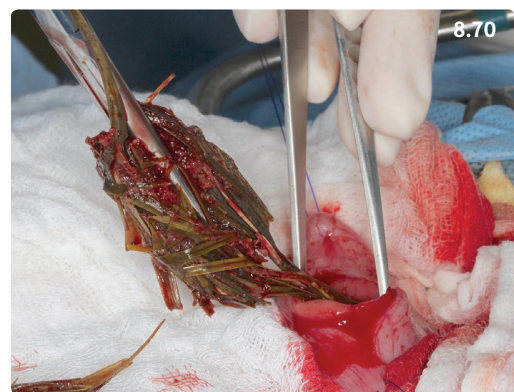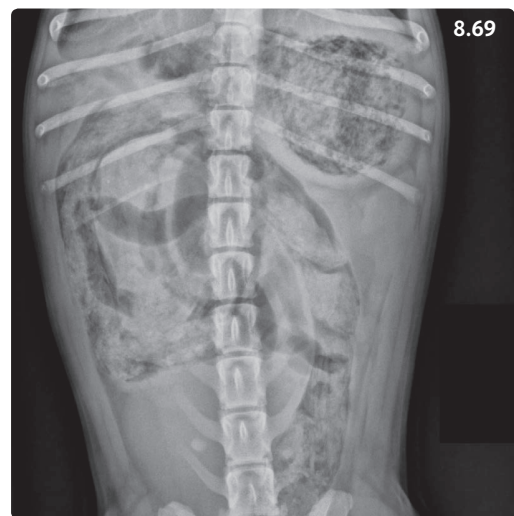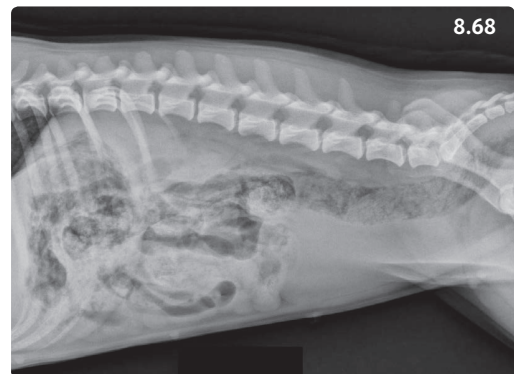
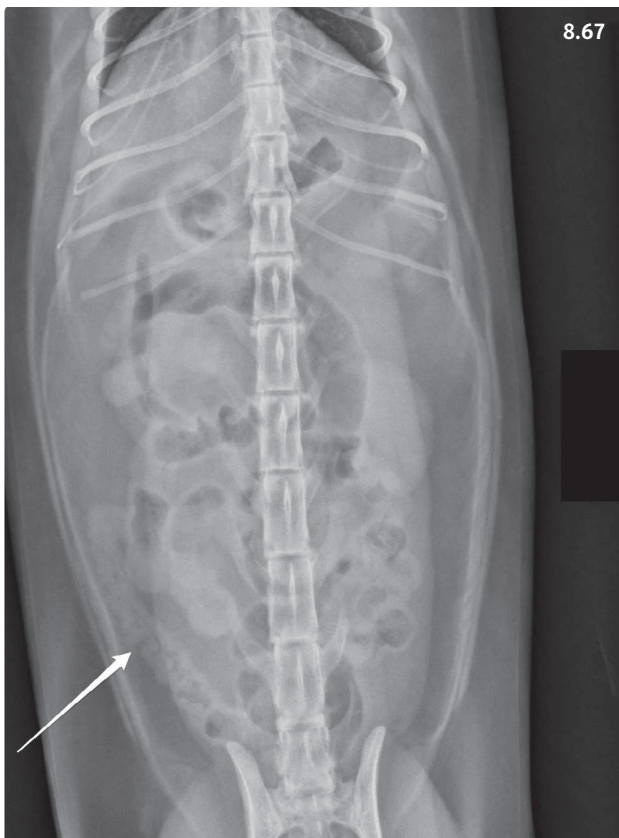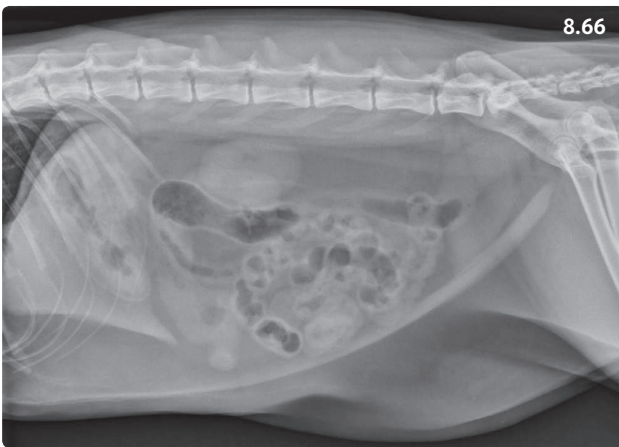
CHRONIC ENTERITIS

PARASITIC ENTERITIS

CANINE SCHISTOSOMIASIS

Etiology

Heterobilharzia americana is the agent of canine schistosomiasis, an uncommon disease endemic in the Southeast of the USA and areas bordering the Gulf of Mexico. Raccoons



Figures 8.66, 8.67 Cat with a linear foreign body. (8.66) Right lateral abdominal radiograph. All small intestinal loops are located centrally, diffusely plicated, and corrugated in appearance. There are multiple rounded, comma-shaped and paisley-shaped gas opacities of varying size throughout the small bowel. (8.67) Ventrodorsal radiograph of the same cat. The arrow points to a caudally displaced small bowel loop that displays a plicated appearance with content of mixed soft tissue and gas density. (Courtesy L. Gaschen)

Figures 8.68–8.70 A 2-year-old female Jack Russell Terrier presented with a 4-day history of vomiting. (8.68) Right abdominal radiograph. The serosal detail is decreased throughout the abdomen. The stomach, small intestines, and colon contain a large amount of material with heterogeneous soft tissue and gas density. (8.69) Ventrodorsal radiograph of the same dog. (Courtesy LSU SVM Diagnostic Imaging Service) (8.70) Grass is extracted through a mid-jejunal enterotomy. Large amounts of grass were present throughout the gastrointestinal tract and were impacting the small intestine. (Courtesy A. Grooters and K. Saile)

are the parasite's reservoir host. Freshwater snails are obligatory intermediate hosts.

Pathophysiology

Percutaneous infection occurs through free-swimming cercariae. After migration, adult *Heterobilharzia* produce ova in the terminal branches of the mesenteric veins. The ova are shed through the intestinal mucosa in the feces. Granulomatous inflammation can be found in the intestinal submucosa (Figure 8.71) and in other organs as well.

Clinical presentation

Acute to chronic mixed small and large bowel diarrhea. Dysorexia/anorexia, weight loss, often cachexia, lethargy, melena, and/or hematochezia are common.

Differential diagnosis

Includes IBD (including protein-losing enteropathy [PLE]), severe parasitic enteritis, intestinal neoplasia.

Diagnosis

Blood work may reveal anemia, hypoalbuminemia, hyperglobulinemia, and eosinophilia. Hypercalcemia is present in >50% of affected dogs and may cause polyuria/polydipsia. Radiographs may show mineralization of the small intestinal wall. Diagnosis is confirmed with saline sedimentation of feces or a commercially available fecal PCR.

Management

Praziquantel (25 mg/kg q8h for 2–3 days), possibly in combination with fenbendazole (50 mg/kg q24h).

Prognosis

Depends on the severity of lesions at presentation. In a recent retrospective study, the survival rate was 55% after 6–36 months.

GIARDIASIS

Definition/overview

Studies concerning the prevalence of giardiasis in the canine and feline populations report rates of 5–10% in healthy pets and pets presented for veterinary care. The prevalence is greatest in patients that live in high-density group housing, especially when recommended disinfecting protocols are not carried out optimally. In such cases, *Giardia* cysts can easily survive in the environment and continuously infect new animals or reinfect animals after they have been treated.

Etiology

Giardia duodenalis is a flagellated protozoan that exists in two forms: a motile trophozoite of pear-shaped to ellipsoidal shape (Figure 8.72) and a cyst form that is highly resistant in the environment. Cysts are absorbed with contaminated food or water, and release trophozoites into the small intestinal lumen. Trophozoites multiply by cell division and become encysted. *Giardia* cysts have four nuclei and a thin envelope. Under favorable conditions they can persist for 3 weeks or even longer in the environment.

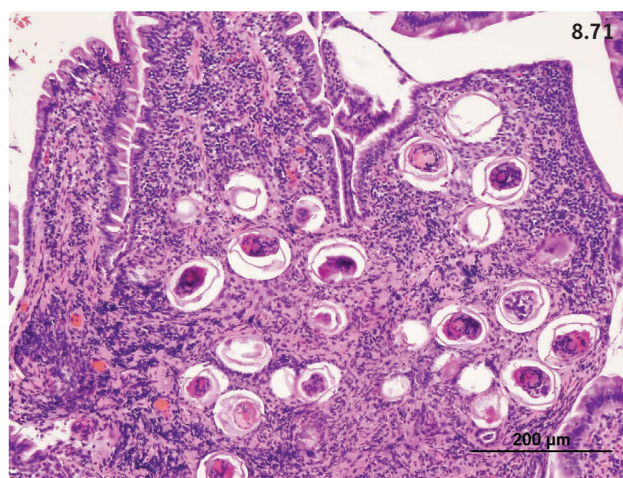


Figure 8.71 Photomicrograph of a duodenal mucosal sample from a dog with canine schistosomiasis. There are numerous eggs present in the mucosa that are associated with granulomatous inflammation. (Courtesy M. Im Hof)

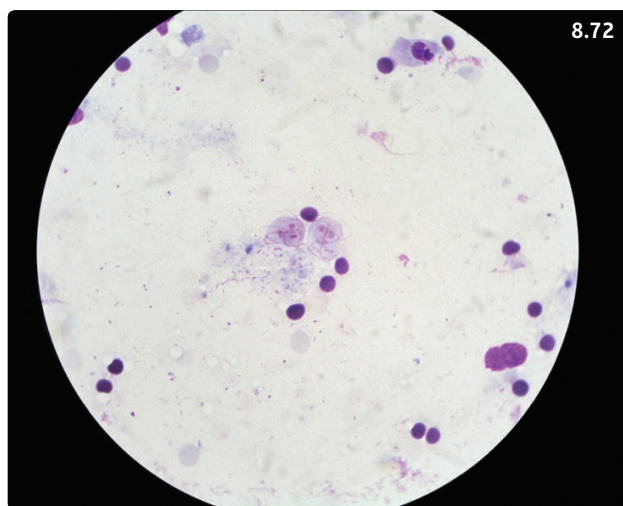


Figure 8.72 Photomicrograph of a fecal smear from a dog with *Giardia* infection. Two trophozoites are visible in the middle of the picture. Wright–Giemsa stain. (Courtesy R. Husnik)

Giardia isolates are further divided into several different genotypes or assemblages with specific host ranges. The zoonotic potential of canine and feline giardiasis is very low. Consumption of water contaminated with *Giardia* cysts is the main origin of infections in people.

Pathophysiology

Trophozoites are found in highest concentration in the duodenum. They attach to the mucosal epithelium and cause disease by affecting epithelial permeability.

Clinical presentation

Diarrhea with watery feces and admixed mucus. In severe and chronic infections, malabsorption and weight loss may occur and the animal may be in poor general condition. Importantly, many infected dogs and cats do not show clinical signs.

Differential diagnosis

Other causes of chronic-intermittent diarrhea and malabsorption, such as other parasite infections, chronic enteropathies (see below), exocrine pancreatic insufficiency, and possibly alimentary lymphoma (cats).

Diagnosis

Several diagnostic tests are available for the diagnosis of *Giardia* infections in dogs and cats (Table 8.10 and Figure 8.72). Confirmation of diagnosis can be complicated by the fact that cysts are shed intermittently.

Table 8.10 Diagnostic tests for *Giardia* in the feces of dogs and cats.

Diagnostic test	Target	Sensitivity
Flotation with zinc sulfate or sugar centrifugation	Cysts	Intermediate, operator-dependent. Can be increased from 70% to 90% if three samples collected at 2–3 day intervals are examined
IFA or ELISA	Specific antigens	Intermediate to good. Diagnostic accuracy of cage-side ELISA test is equivalent to that of antigen tests run in the laboratory
PCR	DNA sequences	Intermediate to high. Only recommended for determination of specific assemblage

Management

The goal of treatment is to stop diarrhea and attempts to fully eliminate *Giardia* infection may not be successful. In dogs, metronidazole (25–30 mg/kg PO q12h for 5–8 days) and fenbendazole (50 mg/kg PO q24h for 3–5 days) are most commonly used. In cats, metronidazole benzoate (25 mg/kg PO q12h for 7 days) is well tolerated and eliminates cyst shedding within 7–10 days of treatment. Fenbendazole can also be used at the same dose as in dogs, although its efficacy may be inferior. Other drugs, including tinidazole (44 mg/kg PO q24h for 3 days), can also be used in cats.

An increased rate of resistance of *Giardia* spp. to metronidazole and other anti-giardial agents has been reported in human patients. However, no published data concerning drug resistance of canine or feline giardiasis are currently available.

Dogs kept in group housing should be removed from their runs, shampooed, and rinsed with quaternary ammonium based disinfectants. The runs should be cleaned and disinfected before reuse. Quaternary ammonium containing disinfectants have shown an excellent efficacy for inactivating *Giardia* cysts in a short period of time.

Prognosis

Good

CRYPTOSPORIDIOSIS

Etiology

Cryptosporidium canis (dog) and *C. felis* (cat). The cycle of the parasite is complex and consists of asexual and sexual stages. Sporulated oocysts protected by a wall that is resistant to many environmental factors are passed with the feces and are infectious to appropriate hosts. Prevalence rates between 0% and 38.5% have been reported in different feline populations, while prevalence rates reported in dogs were 0–44.8%. The mode of transmission is via the oral–fecal route.

Pathophysiology

Cryptosporidium spp. are obligate intracellular parasites that infect enterocytes in the small intestine. They damage the epithelial microvilli and enterocytes, and may cause villous atrophy and inflammatory infiltration of the lamina propria.

Clinical presentation

Cryptosporidium infection may be associated with diarrhea, particularly in young animals. In some instances, chronic or intermittent diarrhea, anorexia, and weight

loss may occur. However, in many cases, animals do not show clinical signs.

Differential diagnosis

Other causes of chronic small bowel diarrhea such as other parasitoses (e.g. giardiasis), IBD, and alimentary lymphoma (cat).

Diagnosis

The oocysts are small and difficult to see in fecal preparations. Immunoassays for detection of *C. parvum* in human feces have yielded mixed results with feline and canine samples. A fecal PCR test is available to detect *Cryptosporidium* spp. in dogs and cats.

Management

The goal of treatment is to control diarrhea, and underlying diseases such as IBD should be appropriately managed. Feeding a highly digestible diet or an elimination diet may be beneficial as well. There is no drug with documented efficacy against *Cryptosporidium* spp. in small animals. Antibiotics such as azithromycin (10 mg/kg PO q24h) and tylosin (10–15 mg/kg PO q24h) have been used with some success. Nitazoxanide was used in naturally infected laboratory cats (25 mg/kg PO q12–24h) and caused vomiting and foul-smelling dark diarrhea. However, *Cryptosporidium* shedding resolved immediately after the drug was administered. Paromomycin (150 mg/kg PO q12–24 h for 5 days) has also been used in small animals. However, it does not consistently stop oocyst shedding, and is also associated with severe renal failure in cats.

Prognosis

Fair to good. While diarrhea usually resolves with or without therapy in otherwise healthy dogs and cats, treatment may be challenging in the presence of concurrent diseases.

FUNGAL AND OOMYCETAL ENTERITIS

HISTOPLASMOSIS

Etiology

Histoplasma capsulatum is a dimorphic saprophytic fungus that can be found in temperate and subtropical climates. Most cases of canine or feline histoplasmosis described in the literature come from North America, particularly from the Ohio, Missouri, and Mississippi river valleys.

Pathophysiology

Young cats and dogs are predominantly infected by inhalation of microconidia (mycelium). The infection can remain local (respiratory tract). If it propagates, it generally also involves the GI tract.

Clinical presentation

GI signs include chronic small or large bowel diarrhea. Weight loss and poor body condition score are common. Affected animals are sometimes presented with PLE. Other organ systems may be infected and cause additional clinical signs.

Differential diagnosis

Other causes of chronic diarrhea and weight loss such as parasite infections, IBD, and alimentary lymphoma (cat).

Diagnosis

The most reliable diagnosis consists in identifying the organism on cytologic smears from fine needle aspirates of lymph nodes or from rectal scrapings (Figure 8.73), or on histologic analysis of intestinal biopsies.

Management

First-line treatment includes itraconazole (10 mg/kg once daily) and must be continued for 4–6 months and at least 2 months beyond clinical remission.

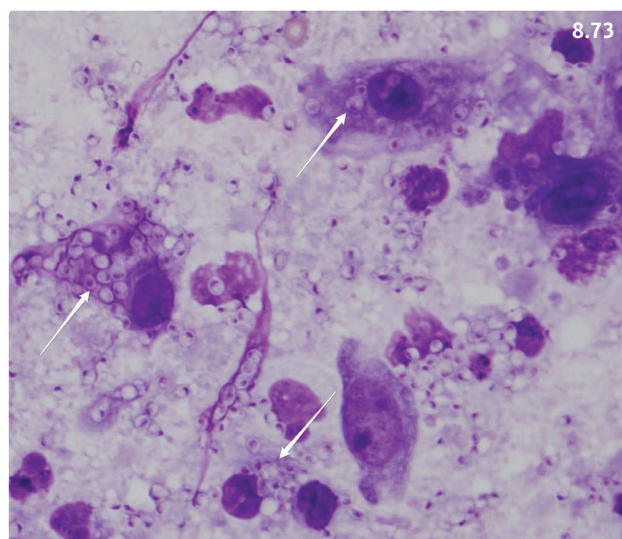


Figure 8.73 Photomicrograph of a fine needle aspirate of a mesenteric lymph node from a dog with intestinal histoplasmosis. The arrows point to macrophages filled with yeast forms of *H. capsulatum*. Wright–Giemsa stain. (Courtesy S. Gaunt)

Prognosis

Guarded to poor in dogs; fair to good in cats.

PYTHIOSIS

Etiology

Pythium insidiosum is a eukaryotic microorganism from the class Oomycota found in subtropical climates (such as the Southeast and Gulf of Mexico regions of the USA) and sporadically in other areas. It causes severe, progressive GI disease. It affects particularly large breed male dogs,

probably because of their increased risk of environmental exposure.

Pathophysiology

Motile *Pythium* zoospores are attracted to and invade damaged GI mucosa. The disease is characterized by transmural inflammation that may affect one or more of the following sites: stomach, small intestine, gastric antrum, colon, and rectum (rarely the esophagus, see above) (Figure 8.74). Local lymph nodes are often reactively enlarged.

Clinical presentation

Young, large breed dogs with access to the outdoors are most commonly affected. History commonly indicates a progressive illness. Vomiting, diarrhea, and weight loss (Figure 8.75) are also commonly observed, with possible dysorexia. In advanced cases, clinical features are suggestive of obstruction of the proximal GI tract, with vomiting and a palpable intestinal mass. Poor body condition is frequently present. Interestingly, lethargy and other signs of systemic illness are observed only in advanced cases as a consequence of complete GI obstruction or GI perforation.

Differential diagnosis

Intestinal FB, histoplasmosis, parasitic enteritis, IBD, small intestinal neoplasia.

Diagnosis

Peripheral eosinophilia, anemia, hypoalbuminemia, and hyperglobulinemia may be present. Abdominal imaging: radiographs may reveal an abdominal mass with or without obstructive pattern (Figure 8.76); ultrasound helps locate the affected segment, which is characterized by transmural thickening with disappearance of the normal small intestinal wall structure (Figure 8.77) and lymph node enlargement (Figure 8.78). Ultrasound-guided fine needle aspirates can be performed. An ELISA test for detection of serum antibodies is available (locations can be found on the web). Histopathologic diagnosis is granulomatous enteritis affecting mostly the submucosa and muscularis layers (Figure 8.79). Oomycetal organisms may be detected with special stains (Figure 8.80) or with immunohistochemistry. Fresh infected tissue may also be cultured to confirm the diagnosis.

Management

Aggressive surgical resection of the lesion with 5 cm clean tissue margins on both sides is the preferred treatment for GI pythiosis. Enlarged abdominal lymph nodes

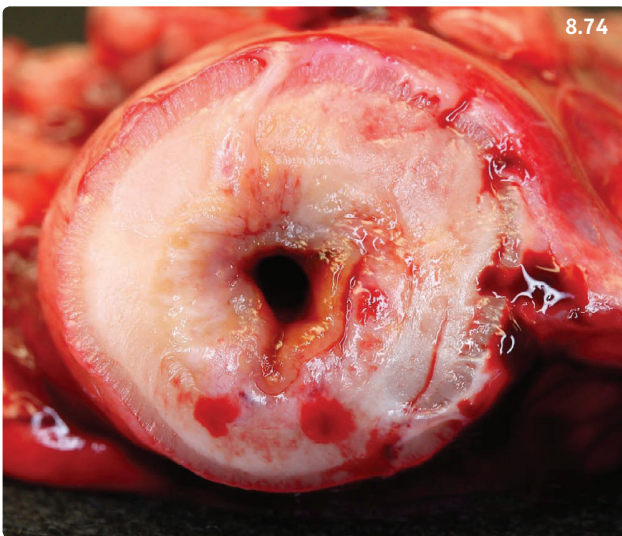


Figure 8.74 Cross-section of a resected jejunal segment from a 2-year-old mixed-breed dog with intestinal pythiosis. The wall is severely thickened and the normal structure is not recognizable. The severe narrowing of the jejunal lumen caused partial intestinal obstruction. (Courtesy A. Grooters)

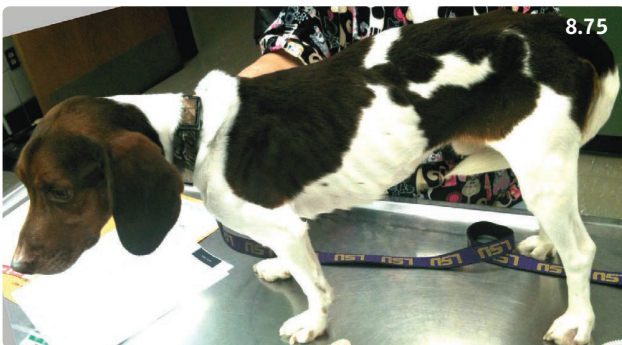

Figure 8.75 Three-year-old male Beagle with a progressive history of chronic-intermittent vomiting. The dog has lost weight and is cachectic. Intestinal pythiosis was diagnosed.

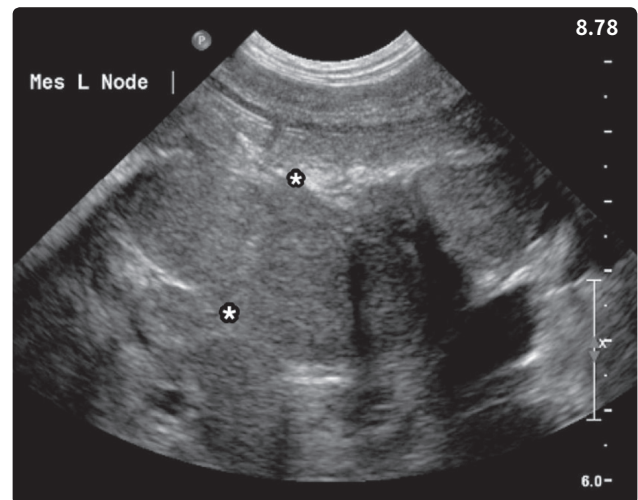
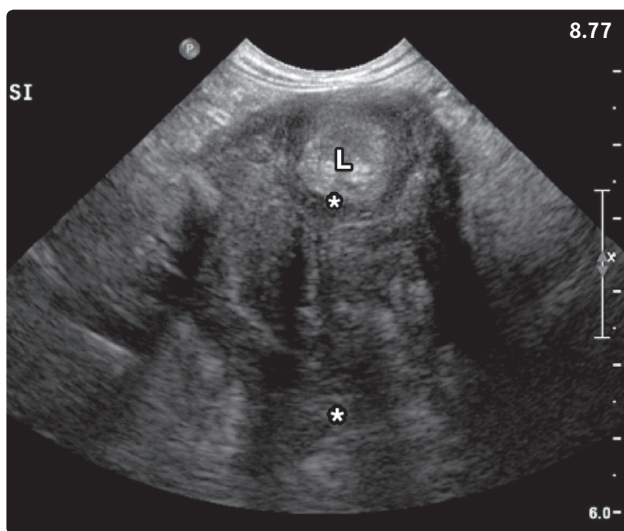
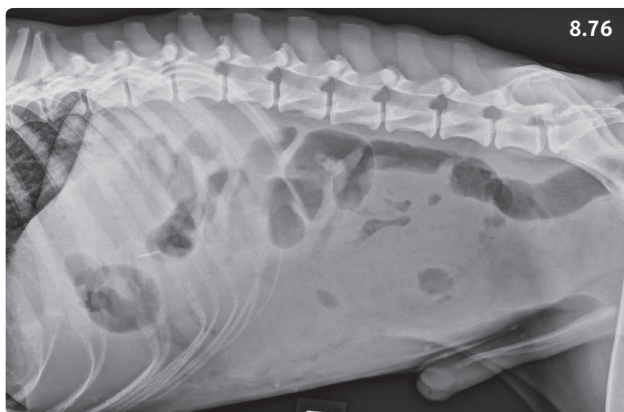


Figure 8.76–8.78 Two-year-old male Catahoula Cur with intestinal pythiosis. (8.76) Left lateral abdominal radiograph. There is an ill-defined central abdominal soft tissue mass that displaces the intestines dorsally and ventrally. (8.77) Abdominal ultrasound. The cross-section of this small intestinal segment reveals a markedly thickened wall (~3 cm) with abnormal layering (between asterisks). L, intestinal lumen. (8.78) Abdominal ultrasound. Note the very enlarged mesenteric lymph node (between asterisks). The measured size was 2.2 × 6.4 cm. (Courtesy LSU SVM Diagnostic Imaging Service)

should be biopsied, but their resection is not absolutely essential since they are rarely infected. Except in cases where total resection with 5 cm clean margins could be performed (usually mid-jejunal masses), medical treatment with a combination of itraconazole (10 mg/kg PO q24h) and terbinafine (5–10 mg/kg PO q24h) is recommended. Prednisone (1 mg/kg PO q24h) can also be used to decrease local inflammation and to palliate clinical signs in the short term. ELISA serology should be performed at the time of diagnosis and 3 months postoperatively, and medical treatment can be discontinued if the titer decreases by >50%.

Prognosis

Poor, except if complete surgical resection of the GI lesion is possible. Recurrence is common unless full resection with clean margins could be achieved. The disease is fatal if untreated.

CHRONIC CANINE ENTEROPATHIES

Definition/overview

The general term ‘chronic enteropathy’ (CE) has been used frequently in recent years to describe dogs and cats with chronic intestinal diseases of unknown origin. Diet-responsive diarrhea (DRD), antibiotic-responsive diarrhea (ARD), and IBD are different forms of chronic enteropathy. They may form a continuum, with DRD being the mild form of CE and IBD requiring immunosuppressive treatment representing the severe form of the disease.

Etiology

Based on research in rodent models, people, and dogs, IBD results from a combination of factors that include dysregulation of the immune system and its interactions with

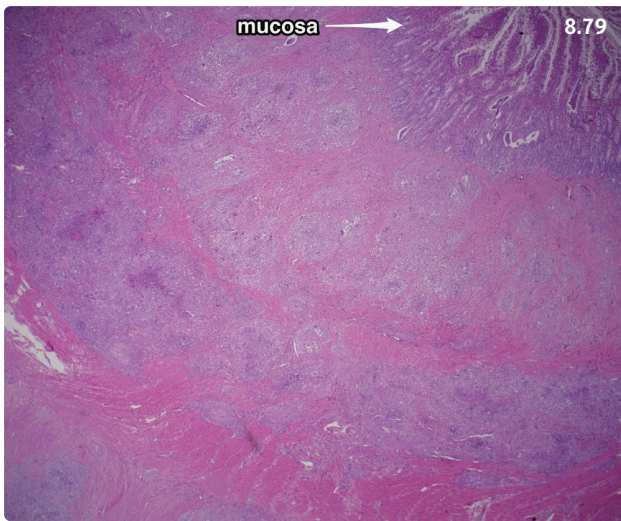


Figure 8.79, 8.80 Dog with pythiosis affecting the jejunum. (8.79) Low-magnification photomicrograph of the intestinal wall. The mucosa is visible at the top right of the image (arrow); the deeper structures (submucosa, muscularis) are obliterated by granulomatous and eosinophilic inflammation. H&E stain. (8.80) High-magnification photomicrograph of an intestinal lesion. Infectious organisms with morphology suggestive of *P. insidiosum* are nonspecifically stained. Grocott's methenamine silver stain. (Courtesy LSU SVM Pathology Service)

intestinal microbiota and/or dietary components, and compromised integrity of the intestinal mucosal barrier.

Specific forms of IBD have been recognized as occurring more frequently in several canine breeds. For instance, in the Southeast UK, Weimaraners, Rottweilers, German Shepherd Dogs, Border Collies, and Boxers were at increased risk of developing IBD. Examples of established breed associations include lymphangiectasia and duodenal crypt inflammation with PLE in Yorkshire

Terriers, PLE and protein-losing nephropathy in Soft-Coated Wheaten Terriers, and cobalamin deficiency in Shar Peis. German Shepherd Dogs have a high prevalence of intestinal dysbiosis/ARD and IBD.

Pathophysiology

Recognition of commensal intestinal microbiota by the innate immune system is altered. Toll-like receptors (TLRs) are pattern-recognition receptors located on immune and epithelial cells that are essential for appropriate recognition of intestinal microbiota. Polymorphisms in various TLRs have been identified in the intestinal mucosa of dogs with CE, which may trigger an inflammatory response. In addition, significant changes in the intestinal microbiota were detected using molecular biological approaches that do not rely on microbial culture. In dogs and people, IBD reduces the diversity of the intestinal microbiome. Furthermore, in dogs with IBD, the bacterial taxa Firmicutes (including the Clostridiales), Bacteroidetes, and Fusobacteria are diminished, and Proteobacteria (including Enterobacteriaceae) are increased. It is not clear whether these changes are the origin of the intestinal inflammation or if they reflect the altered environment in the chronically inflamed gut, or both.

Clinical presentation

Chronic or chronic-intermittent diarrhea of more than 3 weeks' duration. Mild CE may cause intermittent clinical signs, whereas progressive and severe clinical signs are common in severe IBD. Poor body condition with poor hair coat is frequent with severe disease. Dehydration is possible. Thickened small intestinal loops may occasionally be palpated. Animals may show pain or discomfort on abdominal palpation. Ascites, hydrothorax, and peripheral edema may occur in cases of significant protein loss (see Protein-losing enteropathy). Clinical activity scoring systems have been validated for use in the dog: CIBDAI (Canine Inflammatory Bowel Disease Activity Index) and CCECAI (Canine Chronic enteropathy Clinical Activity Index) (Table 8.11). Clinical activity scoring is useful for documenting the severity of clinical signs at presentation and for accurate evaluation of clinical response to treatment.

Differential diagnosis

General differentials include chronic intestinal FB, intestinal parasitoses, bacterial enteritis, fungal enteritis, and diseases originating outside the GI tract such as chronic kidney disease, chronic liver disease, chronic pancreatitis, exocrine pancreatic insufficiency, and atypical hypoadrenocorticism.

Table 8.11 Clinical activity indices used in dogs with chronic enteropathies.

CIBDAI ¹	CCECAI ²
<p>A: Attitude/activity 0 = normal 1 = slightly decreased 2 = moderate decreased 3 = severely decreased</p> <p>B: Appetite 0 = normal 1 = slightly decreased 2 = moderately decreased 3 = severely decreased</p> <p>C: Vomiting 0 = no vomiting 1 = mild (1 episode/week) 2 = moderate (2–3 episodes /week) 3 = severe (>3 episodes/week)</p> <p>D: Stool consistency 0 = normal 1 = slightly soft feces 2 = very soft feces 3 = watery diarrhea</p> <p>E: Stool frequency 0 = normal 1 = slightly increased (2–3 times daily) or fecal blood, mucus or both 2 = moderately increased (4–5 times daily) 3 = severely increased (>5 times daily)</p> <p>F: Weight loss 0 = none 1 = mild (<5% body weight) 2 = moderate (5–10% body weight) 3 = severe (>10% body weight)</p> <p>Evaluation of scores: CIBDAI 0–3: no clinical significance CIBDAI 4–5: mild IBD CIBDAI 6–8: moderate IBD CIBDAI 9 and above: severe IBD</p>	<p>A + B + C + D + E + F + G: Serum albumin concentration 0 = >20 g/l 1 = 15–19.9 g/l 2 = 12–14.9 g/l 3 = <12 g/l</p> <p>H: Ascites and peripheral edema 0 = none 1 = mild ascites or peripheral edema 2 = moderate amount of ascites or peripheral edema 3 = severe ascites/pleural effusion and peripheral edema</p> <p>I: Pruritus 0 = no pruritus 1 = occasional episodes of itching 2 = regular episodes of itching that stop when the dog is asleep 3 = dog regularly wakes up because of itching</p> <p>Evaluation of scores: CCECAI 0–3: no clinical significance CCECAI 4–5: mild enteropathy CCECAI 6–8: moderate enteropathy CCECAI 9–11: severe enteropathy CCECAI 12 and above: very severe enteropathy</p>

1 Jergens AE, Schreiner CA, Frank DE *et al.* (2003) A scoring index for disease activity in canine inflammatory bowel disease. *J Vet Intern Med* **17**:291–297.

2 Allenspach K, Wieland B, Gröne A *et al.* (2007) Chronic enteropathies in dogs: evaluation of risk factors for negative outcome. *J Vet Int Med* **21**:700–708.

Diagnosis

Diagnosis of CE consists of an elimination process to rule out other diseases of known etiology that may cause similar clinical signs: fecal flotation and a *Giardia* antigen test should be performed in all dogs. Alternatively, empiric parasiticide treatment can be administered (e.g. fenbendazole, 50 mg/kg q24h for 3–5 days). Subsequently, the

diagnostic process is different for dogs with mild clinical signs and no evidence of complications such as hypoproteinemia, and for dogs that are more severely affected.

Mildly affected dogs can undergo a treatment trial with a novel protein or hydrolyzed peptide diet without further diagnostics (see Management, below), while severely affected dogs should be evaluated more thoroughly with collection of a minimal database including

CBC, serum biochemistry, and urinalysis. Presence of hypoalbuminemia, often accompanied by hypoglobulinemia, suggests PLE, particularly if other causes can be ruled out. Sensitivity of abdominal ultrasound is intermediate, and scans may be normal or show focal or diffuse loss of wall layering, presence of mucosal striations or spicules, wall thickening, and enlarged and/or hypoechoic mesenteric lymph nodes. If lesions are present, localization to a specific intestinal segment may be helpful (**Figures 8.81, 8.82**).

Upper GI endoscopy and exploratory celiotomy are both good procedures for collecting intestinal mucosal biopsy samples, and each offers different advantages and drawbacks (**Table 8.12**). Observation of severe mucosal lesions during duodenoscopy is a negative prognostic factor.

Procurement of biopsy samples is necessary to further evaluate disease severity. Biopsy specimens of adequate quality and quantity are required for accurate interpretation by pathologists. The most important justification for histology is to rule out a neoplastic infiltrate. However, it is also useful to evaluate the magnitude of intestinal mucosal inflammation based on the severity and type of the infiltrate and the severity of the architectural mucosal changes. A newly established scoring system takes both architectural and inflammatory mucosal changes into account. Inflammatory infiltration may be of varying severity and consist of lymphocytes and plasma cells (lymphoplasmacytic enteritis), eosinophils, neutrophils or macrophages, or combinations thereof (**Box 8.9**). Examples of small intestinal mucosal architectural changes include villus stunting (**Figure 8.83**), surface epithelial injury, crypt distension (**Figure 8.84**), lacteal dilation (**Figure 8.85**), and mucosal fibrosis. It is noteworthy that in animals responding to treatment, histopathologic lesions do not seem to improve in correlation with clinical signs. This finding may suggest that CE can be controlled clinically, but not healed.

Management

In most instances, the goal of treatment is to manage the clinical signs. Full recovery is possible in mild cases.

The standard approach for a dog with mild to moderate chronic recurrent diarrhea of unknown origin without systemic repercussions is to initiate a food trial with a novel protein or hydrolyzed peptide diet. Many dogs respond at least partially within 10–14 days (**Figure 8.86**). For those who do not, the next step may consist of another treatment trial with another novel protein or hydrolyzed peptide diet and/or antimicrobials.

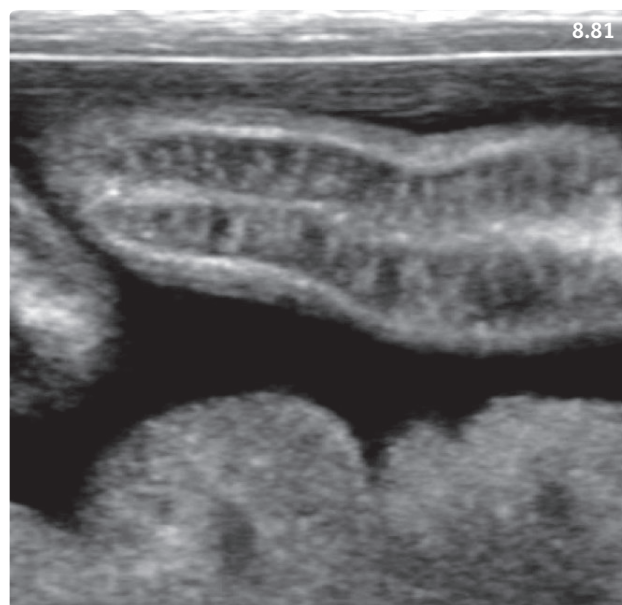


Figure 8.81 Abdominal ultrasound of a dog with inflammatory bowel disease, crypt disease, and protein-losing enteropathy. The normal layers of the intestinal wall are not recognizable in this oblique section of a small intestinal loop. Hyperechoic striations are present and run from the lumen to the serosa. There is free abdominal fluid. (Courtesy LSU SVM Diagnostic Imaging Service)

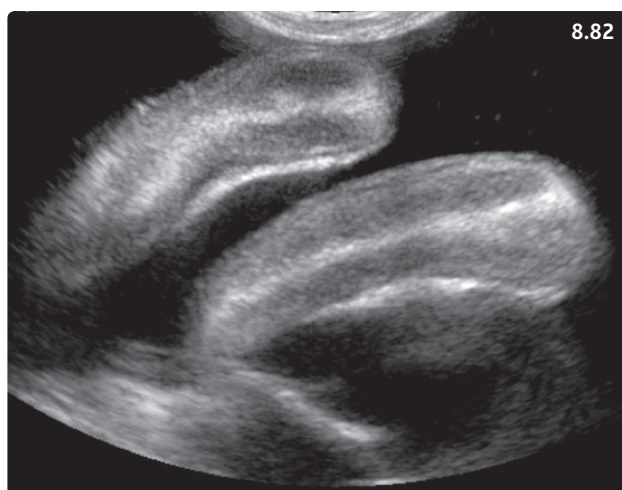


Figure 8.82 Abdominal ultrasound of another dog with severe inflammatory bowel disease and protein-losing enteropathy. The normal layers of the intestinal wall are obliterated by an irregular hyperechoic pattern. There is free abdominal fluid. (Courtesy LSU SVM Diagnostic Imaging Service)

While dysbiosis (change in the composition of the intestinal microbiota) occurs in most dogs with IBD, a subset of young large breed dogs with CE (particularly

Table 8.12 Advantages and drawbacks of endoscopy and surgery for collecting intestinal mucosal biopsies.

	Endoscopy	Celiotomy
Availability of equipment	Limited	Universal
General anesthesia required	Yes	Yes
Rapidity	Depends on endoscopist's experience	Depends on surgeon's experience
Access to gastrointestinal tract	Stomach, duodenum, sometimes proximal jejunum, ileum, colon	Whole GI tract. Full-thickness biopsies of the colon are a more risky procedure
Access to other abdominal organs	No	Yes
Evaluation of intestinal mucosa	Yes	No
Quantity of biopsies	++ to +++	+
Quality of biopsies	+ to +++	+++
Associated risks of complication	Very rare	Minimal, but present, particularly in case of severe panhypoproteinemia
Postinterventional recovery	Rapid	Longer

Box 8.9 Further considerations with different types of intestinal infiltrates.

Lymphoplasmacytic enteritis: most common type of inflammatory infiltrate, nonspecific. A mild to moderate lymphoplasmacytic mucosal infiltrate may be present in the absence of clinical signs.

Eosinophilic enteritis: rule out parasitic enteritis or allergic causes, and in cats eosinophilic syndrome. Idiopathic eosinophilic enteritis may occur in dogs and cats. While it usually responds well to steroids in dogs, this disorder is often steroid resistant in cats.

Neutrophilic (or suppurative) enteritis: bacterial infectious component cannot be ruled out, and treatment with broad-spectrum antibiotic should be considered alone or in association with immunosuppressive drugs.

Granulomatous enteritis: rule out fungal enteritis. Idiopathic transmural granulomatous enteritis usually carries a poor prognosis.

but not exclusively German Shepherd Dogs) respond to prolonged treatment with antimicrobials such as tylosin (20 mg/kg PO q12h) or metronidazole (10–15 mg/kg PO q12h). This may result from an inability of these dogs' immune systems to interact adequately with their intestinal microbiota. Clinical experience accumulated over the past decades indicates that prolonged treatment (4–8 weeks) is necessary, and that relapses are not uncommon.

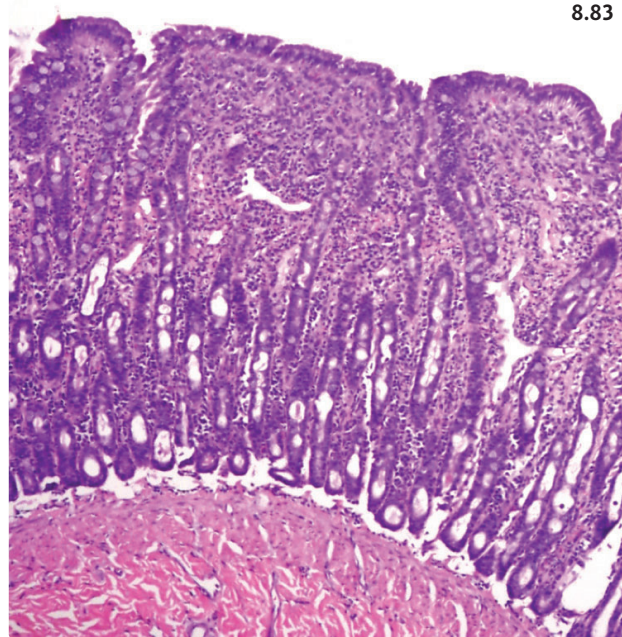


Figure 8.83 Photomicrograph of the duodenal mucosa of a 10-year-old female spayed Domestic Shorthair cat with chronic inflammatory bowel disease. There is marked blunting and fusion of the intestinal villi (compared with Figure 8.52), and a moderate lymphoplasmacytic infiltrate. H&E stain.

In refractory cases, and in dogs with severe disease and evidence of systemic involvement, a more thorough work up with acquisition of a minimal database should be initiated (see Diagnosis, above).

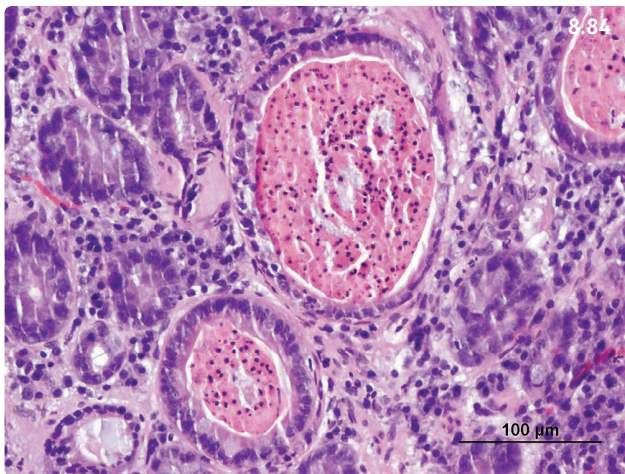


Figure 8.84 Photomicrograph of the duodenal mucosa of a dog with protein-losing enteropathy. Two intestinal crypts are markedly distended and filled with necrotic material. The diagnosis was moderate lymphocytic plasmacytic duodenitis with severe crypt lesions. H&E stain.

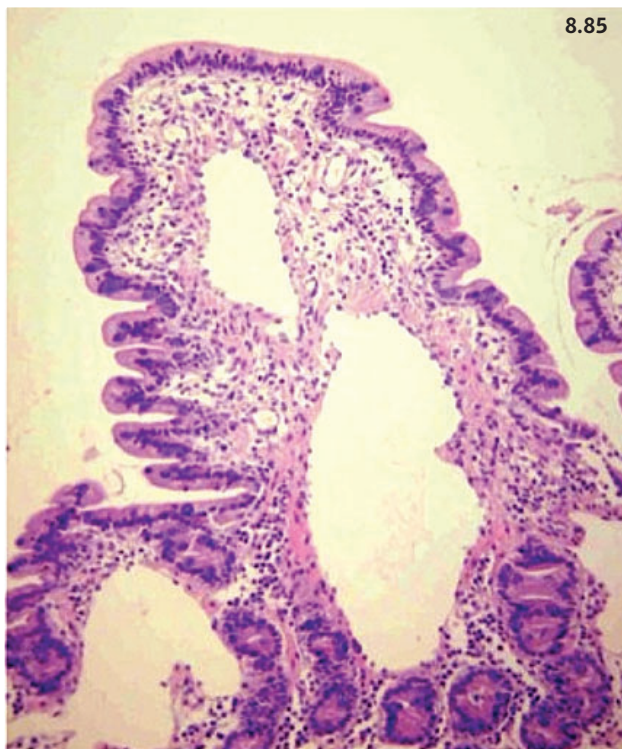


Figure 8.85 Photomicrograph of the duodenal mucosa of a Yorkshire Terrier with protein-losing enteropathy. The villus is markedly distended and dilated lacteals partially filled with eosinophilic material are visible. The diagnosis was moderate idiopathic lymphangiectasia. H&E stain.

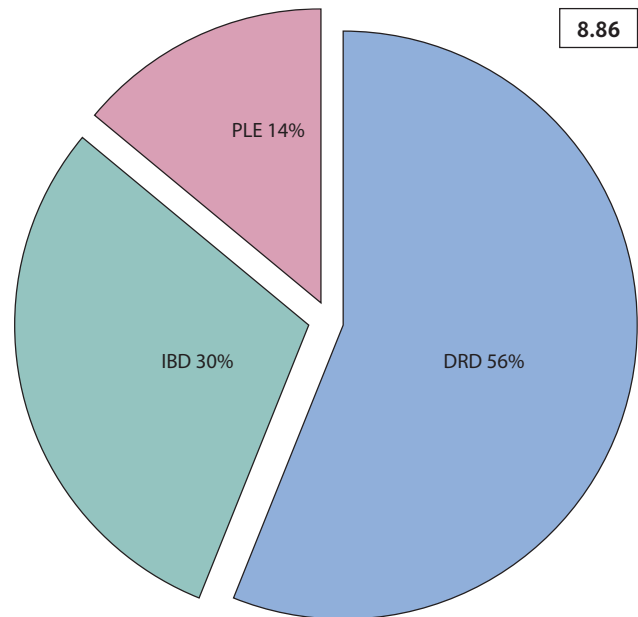


Figure 8.86 Pie chart summarizing the data from a study that included 70 dogs with chronic enteropathy referred to the University of Bern Veterinary Teaching Hospital. 56% of dogs responded within 10 days to a novel protein diet (DRD, diet-responsive diarrhea), while 30% required steroid treatment, and 14% had severe protein-losing enteropathy. (Source: Allenspach K, Wieland B, Gröne A *et al.* (2007) Chronic enteropathies in dogs: evaluation of risk factors for negative outcome. *J Vet Intern Med* 21:700–708.)

In dogs with histopathologic evidence of IBD, immunosuppressive doses of prednisone or prednisolone (**Table 8.13**) are generally the mainstay of initial treatment. Initially, very high doses (e.g. 2 mg/kg q12h) are recommended for a few days, followed by a regular immunosuppressive dose (2 mg/kg/day, in 1 dose or divided into 2 doses). Dietary treatment consists of hydrolyzed peptide or novel protein diet, which has been shown to be superior to easily digestible low-fat diet for long-term maintenance of remission in moderate to severe canine IBD. A recheck is scheduled after 1–2 weeks to reassess the situation. In cases showing good response, the dose of prednisone should be maintained for another 2 weeks, then slowly decreased in 2–4-week steps.

Treatment failure should prompt the clinician to review the diagnosis and ascertain that no mistakes or erroneous assumptions were made in the diagnostic process. Refractory IBD patients must be examined thoroughly to detect intercurrent diseases that may be contributing to treatment failure. For instance, a significant proportion of dogs with IBD (particularly those with PLE) may develop hypcobalaminemia because of severe involvement of the distal small intestine. Cobalamin

Table 8.13 Dosage of oral immunosuppressive drugs used in the treatment of inflammatory bowel disease in small animals.

Drug	Canine dose	Feline dose	Side-effects
Prednisone, prednisolone	1–2 mg/kg q12–24h	Prednisolone preferred. Same dose as canine	In dogs they include polyuria/polydipsia, panting, alopecia, pot-bellied appearance, calcinosis cutis. Rare in cats, may cause diabetes mellitus
Budesonide	3 mg/m ² q24h	1 mg/cat q24h	Same as above
Azathioprine	Initially 2 mg/kg q24h for 3 weeks, then 1–2 mg/kg q48h. Up to 3 weeks of treatment may be necessary for the drug to reach maximal effect	Do not use in cats	Hepatotoxicity, pancreatitis, rarely bone marrow suppression
Chlorambucil	Initially 4–6 mg/m ² q24h for the first 7–21 days, then the dose can be decreased by 25–33%, or the dosage interval increased to every 2–3 days	2 mg/cat 3 times weekly	Rarely bone marrow suppression
Cyclosporine	5 mg/kg q12–24h	Same as canine	Vomiting, nausea, gingival hyperplasia

deficiency may cause a delayed response or lack of response to adequately designed immunosuppressive treatment. Serum cobalamin concentration should be determined. Subcutaneous supplementation is essential in these animals (**Table 8.14**). Relatively frequently, dogs with moderate to severe IBD require treatment with a combination of immunosuppressive agents (**Table 8.13**). In cases with unacceptable corticosteroid side-effects, another immunosuppressive drug may be added in the hope of decreasing the prednisone dose. Alternatively, budesonide can be used. Budesonide is a glucocorticoid that undergoes high first-pass hepatic metabolism after intestinal absorption, but still affects the pituitary–adrenal axis. Budesonide may cause fewer side-effects than prednisone; it has been used in large breed dogs, which tend to be more prone to severe polyuria and polydipsia. There is no documented benefit in using the controlled release formulation compared with the generic substance.

Prognosis

Good in mild cases that respond to dietary trials. Return to a less expensive commercial food may be possible after 2–3 months of dietary treatment; however, some dogs require life-long administration of an elimination diet. Guarded to poor in dogs requiring medical treatment.

Table 8.14 Treatment protocol for hypocobalaminemic dogs and cats with chronic enteropathy.

Dose per SC injection		
Cats:	Any weight	250 µg
Dogs:	<4.5 kg	250 µg
	4.5–9 kg	400 µg
	9–18 kg	600 µg
	18–27 kg	800 µg
	27–36 kg	1,000 µg
	36–45 kg	1,200 µg
	>45 kg	1,500 µg
<p>Schedule: Administer once weekly dose for 6 weeks, then one dose 30 days later. Recheck serum cobalamin 30 days after the last injection. If it is:</p> <ul style="list-style-type: none"> • Above the reference range, and the underlying process has been successfully managed, discontinue cobalamin injections. • Within the reference range, continue monthly treatment. • Below the reference range: reassess the patient. 		

Source: Texas A&M University GI Laboratory website (<http://vetmed.tamu.edu/gilab>), with permission.

PROTEIN-LOSING ENTEROPATHY

Definition/overview

Intestinal protein loss is a sign of failure of digestive function that may result from severe acute or chronic inflammatory lesions or from a disruption of chyle absorption and intestinal lymph flow.

Etiology/pathophysiology

Primary intestinal lymphangiectasia occurs preferentially in Yorkshire Terriers, Shar Peis, Maltese, Norwegian Lundehunds, and Rottweilers. The pathogenesis of primary intestinal lymphangiectasia is still poorly understood. It results from obstruction to the flow of lymph in the intestinal wall. Secondary intestinal lymphangiectasia is commonly associated with significant intestinal mucosal inflammation (e.g. IBD) and neoplasia (alimentary lymphoma).

IBD may also directly cause PLE. The inflammatory process located in the GI mucosa may lead to protein loss both by preventing absorption of nutrients and by compromising the integrity of the intestinal mucosal barrier, leading to exudation of proteins into the intestinal lumen. PLE of Soft-Coated Wheaten Terriers is a specific form of IBD affecting this breed worldwide. In approximately 50% of these dogs, PLE and protein-losing nephropathy (PLN) occur concurrently, and the pathogenesis includes a hypersensitivity component.

Crypt dilation and necrosis have been frequently associated with PLE. Dogs with small intestinal crypt abscesses have significant hypoalbuminemia and ultrasound changes of their intestinal mucosa, and their clinical presentation is generally severe.

Clinical presentation

Chronic intermittent small intestinal diarrhea with possible vomiting is a common presentation. In severe cases, dysorexia/anorexia and malnutrition with evidence of malabsorption and weight loss may be observed (**Figure 8.87**). Importantly, significant intestinal protein loss and hypoalbuminemia may also occur without obvious diarrhetic episodes. In the presence of severe hypoalbuminemia (serum albumin <2.0 g/dl, often ≤ 1.5 g/dl), the main complaint may relate to significantly decreased oncotic pressure causing cavitory effusion (**Figure 8.88**) and subcutaneous edema (**Figure 8.89**).

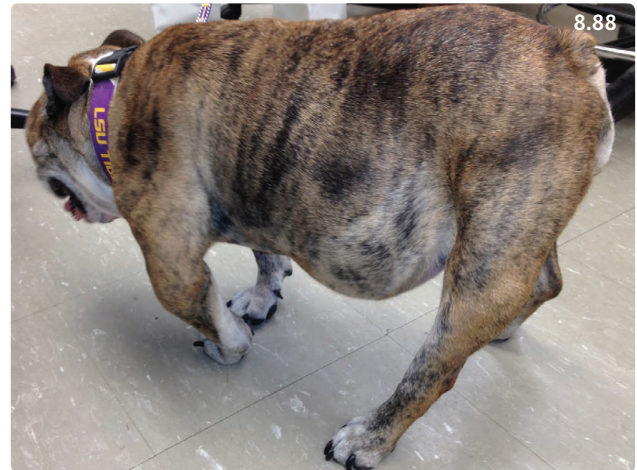

Figure 8.88 Ten-year-old female spayed English Bulldog with chronic inflammatory bowel disease and protein-losing enteropathy. The abdomen is severely distended due to ascites. The dog also had pleural effusion.

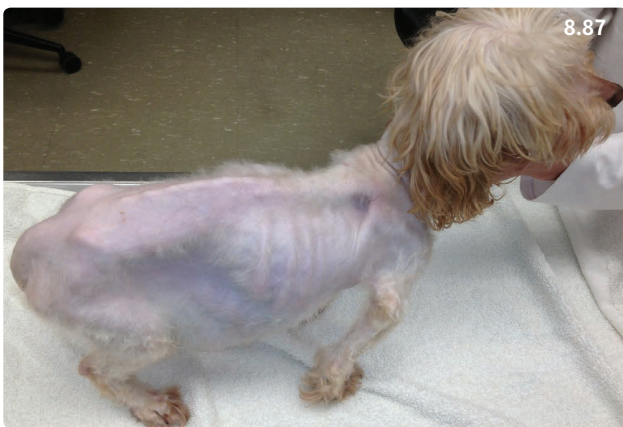

Figure 8.87 Four-year-old male neutered Maltipoo with severe chronic inflammatory bowel disease and protein-losing enteropathy. The dog is cachectic and a pot-bellied abdomen is visible (ascites).



Figure 8.89 One-year-old male Montagne des Pyrenées with inflammatory bowel disease and protein-losing enteropathy. There is subcutaneous edema around both hocks. (Courtesy R. Husnik)

Differential diagnosis

Hypoalbuminemia and associated signs may also occur with liver failure, PLN, third spacing of proteins (vasculitis), or cutaneous loss.

Diagnosis

First, the origin of the protein loss should be established by ruling out other processes. Generally, PLE is associated with panhypoproteinemia due to nonselective protein loss, but exceptions may occur. Other common abnormalities of dogs with PLE include hypocholesterolemia, hypocalcemia (total and ionized), hypomagnesemia, and lymphopenia.

Once the GI tract has been confirmed as the site of protein loss, further work up should include abdominal ultrasound, a technique with acceptable sensitivity that often helps assess the severity and anatomic distribution of intestinal lesions. Hyperechogenic mucosal striations are frequently observed in dogs with PLE, and appear to be quite specific (see **Figure 8.81**).

Endoscopy may reveal a broad range of changes of varying severity (**Figures 8.90, 8.91**). The diagnosis of the cause of PLE requires histopathologic analysis of intestinal biopsies (see **Figures 8.84, 8.85**). In some instances, dogs with severe hypoalbuminemia are poor anesthetic candidates, and it is sometimes preferable to avoid taking excessive risks and postpone endoscopy or surgery. Additionally, many dogs with PLE have bicavitary effusion, and thoracic radiographs are recommended as a screening tool for the presence of thoracic effusion, which may represent an additional anesthetic risk.

Management

Dogs with PLE are in a catabolic state, and adequate nutrition is essential. In dogs with primary idiopathic intestinal lymphangiectasia, dietary modification centers on feeding a highly digestible diet with low to very low fat content (10–15% on a dry matter basis) to prevent further dilation and rupture of lacteals. Additionally, the diet should contain highly bioavailable dietary proteins and be low in crude fiber. Dietary therapy should probably be maintained for the length of the dog's life. In dogs with PLE associated with underlying IBD, good success has been reported with exclusive feeding of a diet consisting of hydrolyzed proteins. Novel protein diets are an alternative approach.

In dogs with primary intestinal lymphangiectasia, anti-inflammatory glucocorticoid therapy (e.g. prednisone, 1 mg/kg/day) is useful and often required for proper management of the disease. The main desired effect is to decrease the inflammation associated with lipogranulomas secondary to chyle leakage and therefore

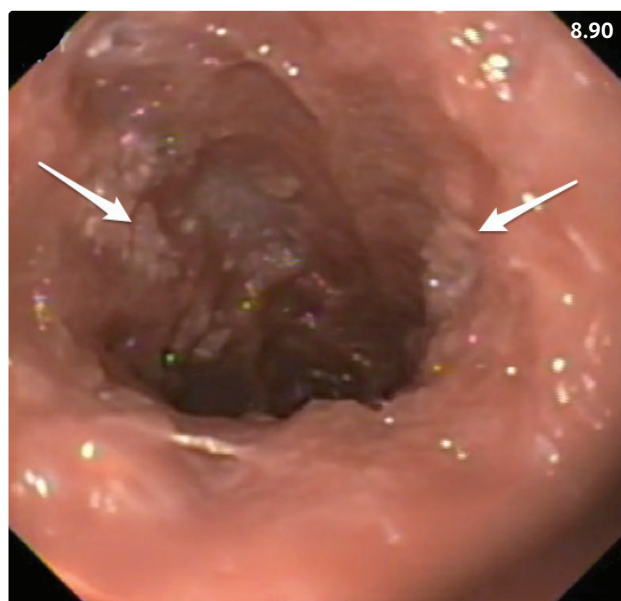


Figure 8.90 Endoscopic picture from the duodenum of the same dog as in **Figure 8.81**. The surface of the intestinal mucosa is very irregular and abnormal, and patches of recognizable villi are visible (arrows).

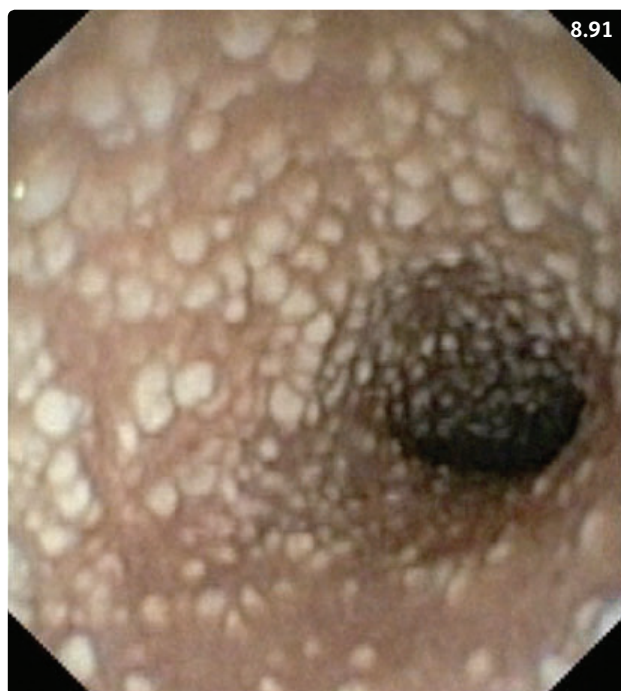

Figure 8.91 Endoscopic view of the duodenum of a 5-year-old Yorkshire Terrier. There are numerous multifocal white spots in the mucosa that represent dilated villi filled with chyme. The histopathologic diagnosis was idiopathic lymphangiectasia.

help restore an adequate flow in the intestinal lymphatics. In some dogs, anti-inflammatory treatment can be slowly weaned off over 2–3 months or longer.

Immunosuppression is the basis for treatment of severe IBD with PLE (Table 8.13).

Complications

Low serum cobalamin concentrations are commonly found in dogs with PLE, especially in the presence of underlying IBD, and may delay proper healing of intestinal inflammation. Treatment consists of weekly SC injections of vitamin B12 (Table 8.14).

Recent studies have revealed the high prevalence of hypercoagulability in dogs with PLE, which increases the risk of potentially fatal thromboembolic events. Hypercoagulability does not appear to resolve after successful treatment of PLE. Administration of low doses of aspirin (0.5–1 mg/kg/day) and/or clopidogrel (1–5 mg/kg/day) may be considered in order to prevent thrombosis.

The decrease in serum total calcium is associated with severe hypoalbuminemia. Additionally, low serum ionized calcium concentration occur in association with low 25-hydroxyvitamin D and increased levels of parathyroid hormone in dogs with PLE. In dogs with a moderate to severe decrease in ionized calcium, treatment with calcium and vitamin D is recommended. Concurrent hypomagnesemia may compromise the success of treatment and should be corrected if present.

Prognosis

Generally, hypoalbuminemia (serum albumin <2 g/dl) is associated with a less favorable outcome. A few studies show a high mortality among Yorkshire Terriers with intestinal lymphangiectasia (50–60%). In the author's practice, some Yorkshire Terriers with idiopathic intestinal lymphangiectasia respond well to a strict diet alone or with anti-inflammatory doses of glucocorticoids. There are no known parameters that allow early segregation of dogs likely to be refractory to dietary and steroid treatment. Crypt abscesses in the small intestine are associated with significantly shorter survival.

CHRONIC FELINE ENTEROPATHY

Definiton/overview

While the etiology and pathophysiology are thought to be similar to canine CE, the presentation and approach of cats with CE is partially different.

Clinical presentation

The most commonly observed clinical signs are vomiting, anorexia, diarrhea, and weight loss (Figure 8.92). However, some cats may have a normal to increased appetite, and many cats, unlike dogs, will not have diarrhea at

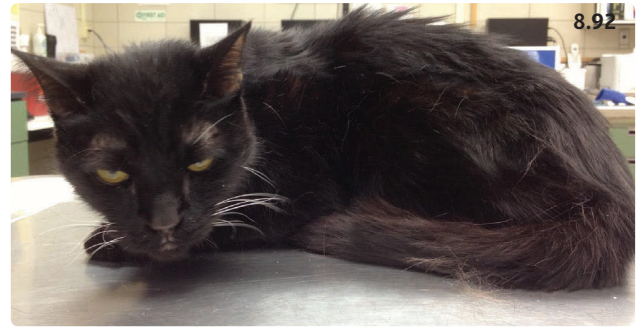


Figure 8.92 Fourteen-year-old male neutered Domestic Longhair cat with chronic diarrhea and occasional vomiting. The cat is lethargic, cachectic, and his hair coat is in poor condition. Inflammatory bowel disease and alimentary lymphoma are among the top differentials.

presentation. Other cats will be presented for dysorexia/anorexia and weight loss. The signs are often waxing and waning, and the owners may seek veterinary attention only late in the course of disease. Abnormal findings on physical examination of cats with CE include loss of body condition, dehydration, palpation of thickened bowel loops, and/or abdominal pain.

Differential diagnosis

Includes diseases originating outside the digestive tract such as hyperthyroidism, diabetes mellitus, chronic kidney disease, and heartworm disease, but also liver disease and pancreatitis. Alimentary lymphoma, particularly diffusely infiltrative low-grade alimentary lymphoma, may be very difficult to differentiate from IBD.

Diagnosis

The clinical signs may be very nonspecific, and the first step is to rule out diseases that may present with a similar clinical picture. A minimal database of CBC, chemistry profile, serum thyroxin concentration, and abdominal imaging (particularly ultrasound) is recommended. Confirmation of diagnosis requires histologic evaluation of intestinal biopsies collected using endoscopy or celiotomy (Table 8.12, Figure 8.83).

Management

As is the case in dogs, a high proportion of cats with CE may respond to an appropriate diet change (e.g. novel protein or hydrolyzed peptides). Other cats may respond to antimicrobials: metronidazole (10–15 mg/kg PO q12h) is popular, although its therapeutic margin in cats is narrow. Tylosin (20–40 mg/kg PO q12h) is a good alternative. Both drugs also have immunomodulating effects.

Immunosuppressive therapy is the mainstay of IBD treatment. It is best initiated when histologic evidence of intestinal mucosal infiltration is available, but could

also be the final option of the empirical treatment sequence started with dietary trial and antimicrobials. Prednisolone (2–4 mg/kg PO q24h or divided into 2 daily doses) is administered for 10–14 days. Once the clinical signs have been controlled for 2 weeks or longer, the dose is reduced by one-half every 10–14 days. The final goal is to maintain the cat on the lowest effective dose, or even to consider discontinuation of steroid treatment if feasible. If the owner is unable to pill the cat, methylprednisolone acetate can be given (10 mg/kg SC q2–4weeks, and tapered to q4–8weeks). Repository steroids may cause more side-effects and do not appear to be very successful in the author's experience. Refractory cases are usually treated with chlorambucil or cyclosporine (**Table 8.13**). Chlorambucil is generally used in combination with prednisolone (2 mg/cat PO every other day [in cats >4 kg body weight] or every 3 days [in cats <4 kg body weight] and then tapered to the lowest effective dose). A CBC should be checked every 2–4 weeks for signs of myelosuppression. Although there are no published reports of cyclosporine use in cats with IBD, the dose generally recommended is approximately 5 mg/kg once daily (25 mg/cat).

Prognosis

In one study, 80% of cats with IBD treated with diet change and prednisone had a positive response to treatment, although clinical signs did not completely resolve. Cats with severe histologic lesions or eosinophilic inflammation may be more difficult to manage. Failure to respond to treatment may indicate refractory IBD or lymphoma. Feline IBD is a disease that is managed but rarely cured.

PARALYTIC ILEUS

Etiology

Primary nonobstructive disorders of intestinal motility are rare. Secondary alterations in motility of the small intestine occur with many diseases. Enteritis is associated with abnormal intestinal motility patterns that resolve with successful treatment of the inflammation. Intestinal hypomotility and ileus may occur after abdominal surgery (postoperative ileus [POI]) or during ischemic or inflammatory conditions affecting abdominal organs, such as peritonitis, pancreatitis, or parvovirus infection. Hyperthyroidism in cats may also alter intestinal transit time and cause diarrhea.

Pathophysiology

POI is thought to be due to inhibition of neural pathways and release of proinflammatory mediators and

corticotrophin releasing factor. They may be complicated by the use of opiates for analgesia.

Clinical presentation

Vomiting, bloated abdomen, abdominal discomfort or pain, and/or signs of colic. Hyporexia/anorexia, nausea, increased belching, pica, and/or polydipsia may also be observed.

Differential diagnosis

Differential diagnoses are numerous. Small intestinal obstruction (see above) can result in a very similar presentation, and all necessary steps must be taken to rule it out. Autonomic neuropathy (dysautonomia) is a rare disease, but should also be considered in the appropriate clinical setting.

Diagnosis

Physical signs, abdominal radiographs often show dilated small intestinal segments in the absence of an obstructive pattern (see **Figure 8.61**). Precise evaluation of small intestinal motility is difficult under clinical conditions.

Management

Proper diagnosis and treatment of any underlying disease that might affect gastric motility is an essential premise. Therapy of functional, nonobstructive disorders of gastric motility is based on dietary modification and judicious use of prokinetic drugs. Dietary management is attempted at first: small amounts of a low-fat, low-protein diet given at frequent intervals can help reduce the symptoms of delayed gastric emptying. Medical therapy can be attempted if dietary management alone is unsuccessful (**Table 8.9**).

Prognosis

Generally good if the problem is secondary to an underlying disease that can be treated successfully. Idiopathic disorders of small intestinal motility often represent a therapeutic challenge.

MALIGNANT SMALL INTESTINAL NEOPLASIA

Etiology

In dogs, small intestinal tumors occur relatively frequently (1–8% of all canine cancers). Epithelial tumors include adenocarcinoma, mucinous adenocarcinoma, ring cell carcinoma, and undifferentiated carcinoma and represent 29% of all small intestinal tumors, as does lymphoma. Furthermore, 23% of small bowel neoplasms are leiomyosarcoma. These tumors may metastasize to

mesenteric lymph nodes, liver, peritoneum, and lungs (adenocarcinoma metastasis rate is ~50%).

In cats, small intestinal tumors are also relatively common (6–13.5% of all feline cancers), and consist mostly of alimentary lymphoma (74%) and adenocarcinoma (17%). Siamese cats appear to be predisposed. Depending on the source, between one-third and three-quarters of all feline lymphomas are localized in the GI tract. Two main forms are recognized: low-grade alimentary lymphoma (LGAL), which causes a diffuse infiltration of the intestinal wall and consists of T cells; and high-grade alimentary lymphoma (HGAL) which causes focal or segmental disease and consists of B cells.

Pathophysiology

The cause of intestinal neoplasia in dogs and cats is unknown. An association between alimentary lymphoma and chronic inflammation (IBD) has been hypothesized in cats but not demonstrated.

Clinical presentation

Clinical signs develop late in the course of disease. They include chronic progressive vomiting, small bowel diarrhea, hyporexia/anorexia, and melena. An abdominal mass is palpable in 50% of cases with a discrete neoplasm. In diffusely infiltrative tumors, thickening of the small intestinal wall may also be palpable. Enlarged abdominal lymph nodes may also be detected. Clinical features of cats with LGAL may be identical to those of cats with IBD (Figure 8.92).

Differential diagnosis

For occlusive tumors, intestinal FB, granulomatous disease (e.g. pythiosis), other cause of vomiting such as pancreatitis, metabolic disease (e.g. chronic kidney disease). Feline IBD is the most common differential diagnosis for cats with LGAL.

Diagnosis

It may be very difficult to differentiate cats with moderate to severe IBD from those with LGAL. Collection of intestinal biopsies of adequate size for histopathologic interpretation is essential but does not guarantee that a final diagnosis will be reached (Figure 8.93). There is ongoing debate regarding the value of endoscopy (Figure 8.94) versus surgery in obtaining the samples (Table 8.12). Special immunohistochemistry stains (Figure 8.95) and PCR for antigen receptor rearrangement can be of further help in attempting to confirm a diagnosis of LGAL.

CBC may reveal anemia (chronic disease or blood loss), serum chemistry may show hypoalbuminemia and increased liver enzymes. An obstructive pattern may be

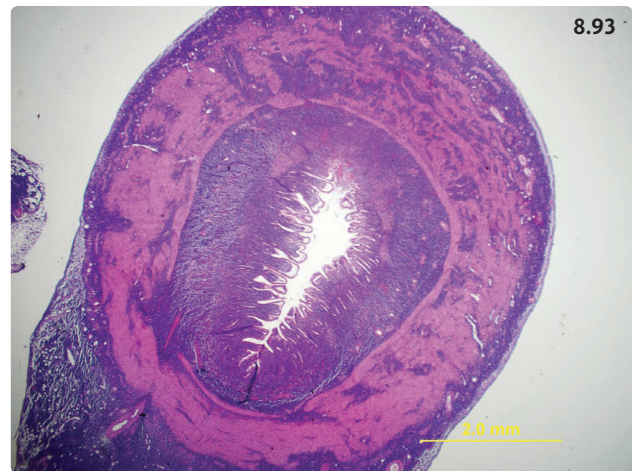

Figure 8.93 Low-power photomicrograph of a resected jejunal segment from a cat with alimentary lymphoma. The very severe infiltration with small lymphocytes extends through all layers of the wall. Inflammatory infiltrates generally do not extend beyond the muscularis mucosae. H&E stain.

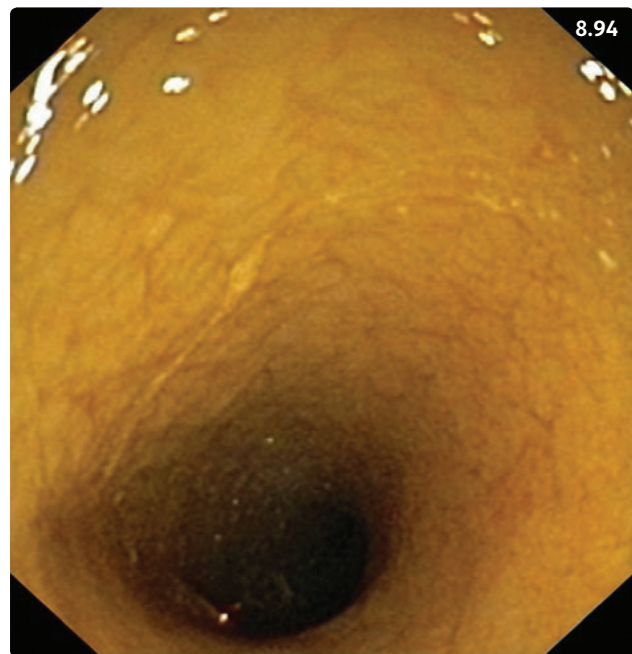

Figure 8.94 Endoscopic view of the duodenal mucosa from a cat with low-grade alimentary lymphoma. The mucosa appears irregular and granular. Changes could be similar in cats with inflammatory bowel disease. (Courtesy R. Husnik)

seen on abdominal radiographs; thoracic films may reveal metastases. Abdominal ultrasound is the most sensitive imaging method. It allows evaluation of localization, size, and extent of the mass, and can be used to guide fine needle aspiration for cytologic evaluation.

Management

In the absence of distant metastases, surgical resection with appropriate margins is the treatment of choice for most small intestinal tumors, with the exception of feline LGAL.

LGAL can be treated efficiently with a combination of prednisolone and chlorambucil (Table 8.13). Between 55% and 76% of cats achieve complete remission with a median survival time (MST) of 19–29 months. Chemotherapy for HGAL is best initiated after the mass has been resected. The CHOP protocol, consisting of prednisolone, vincristine, cyclophosphamide, and doxorubicin, is preferred. The rate of complete remission is 38–87%, with a MST of 8 months.

Prognosis

Canine adenocarcinoma carries a good prognosis with >2 year survival documented in the absence of metastases and with clean margins, and a MST of 15 months. In cases with metastasis, the MST is usually significantly shorter (3 months). In cats, survival ranges from 5 to 13 months. The benefit of postsurgical chemotherapy has not been scientifically evaluated. MST for canine leiomyosarcoma with or without metastasis ranges from 9 to 22 months.

Part 5: Diseases of the large intestine

Overview

Inflammatory diseases of the colon are frequently encountered in dogs and are less common in cats. In many instances, acute nonspecific colitis is self-limiting. Chronic colitis is often associated with a long, sometimes waxing and waning clinical course and specific treatments. Constipation is an uncommon clinical sign usually encountered in older animals, and appears to affect cats more frequently than dogs.

Anatomy and physiology of the large intestine

The large intestine consists of six segments: cecum (a short blind pouch), ascending colon, transverse colon, descending colon, rectum, and anus. The ileocolic valve and its sphincter separate the distal small intestine and the large intestine (Figure 8.96). The microscopic structure of the large intestine resembles that of the small intestine. However, the large intestinal mucosa does not form villi, the epithelial cells have fewer microvilli on their apical surface than enterocytes, and numerous goblet cells are interspersed in the epithelial layer (Figure 8.97). The colon has two main functions: water absorption, which takes place in the proximal colon, and storage and elimination of feces. Colonic motility includes a few

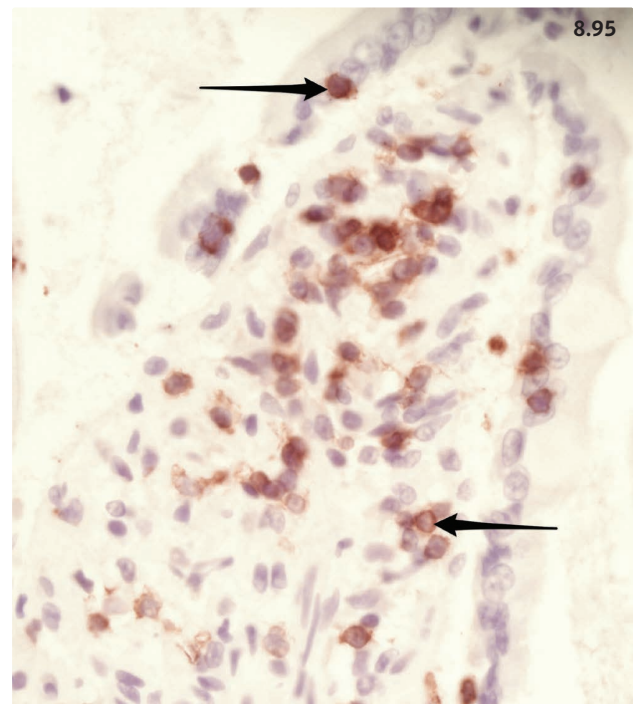


Figure 8.95 Photomicrograph of a small intestinal villus from a cat with low-grade alimentary lymphoma stained with antibodies against CD3, a T-cell marker. There are numerous cells that stain positive. T-cell alimentary lymphoma was diagnosed.

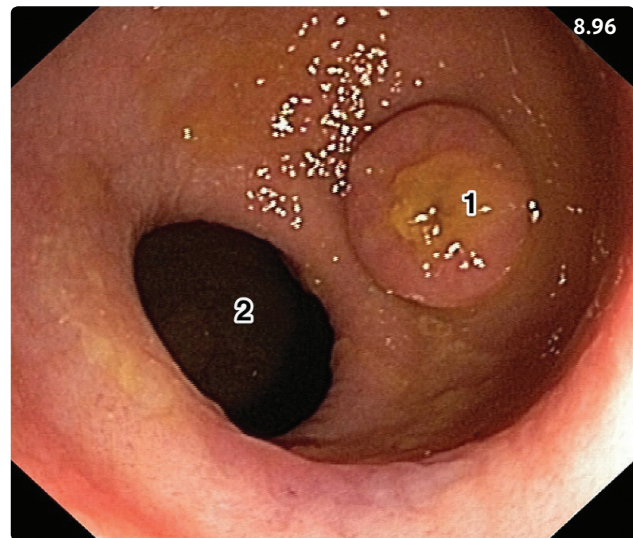


Figure 8.96 Endoscopic view from the ascending colon of a dog. The ileocolic junction (1) and the entrance to the cecum (2) are visible. (Courtesy R. Husnik)

patterns with different functions: stationary contractions mix the content and indirectly promote water absorption and peristaltic contractions move the feces aborally over

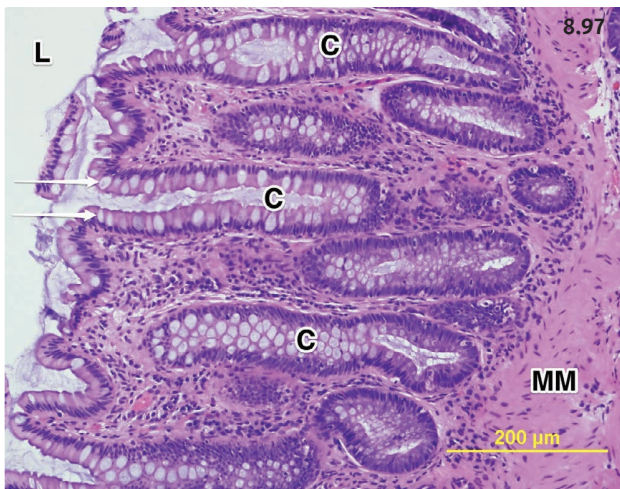


Figure 8.97 Photomicrograph of the canine colonic mucosa. The arrows point to a few of the numerous goblet cells. Mucus can be observed on the surface of the epithelium and in the colonic crypts. There is mild expansion of the lamina propria, with lymphoplasmacytic inflammation. C, colonic crypts; L, lumen; MM, muscularis mucosae.

small distances. Eventually, giant contractions precede defecation and move feces over longer segments. The gastrocolic reflex is mediated by enteric nerves and enhances colonic motility after a meal, leading to defecation.

CECAL DISEASES

Diseases of the cecum are rarely recognized as a separate entity in cats and dogs. However, the cecum is the preferred place of residence of adult whipworms. Additionally, colonic inflammation can extend to the cecum and cause typhlitis. Clinical signs are characterized by large bowel diarrhea, which cannot be differentiated from colitis.

ACUTE COLITIS

PARASITIC COLITIS (WHIPWORMS)

Definition/overview

As stated earlier, the CAPC maintains a very informative and freely accessible website on intestinal parasites of small animals and this should be consulted for additional information (www.capcvet.org).

Etiology

Trichuris vulpis is a common cause of large bowel diarrhea in dogs. Whipworm infestation in cats is rare, and caused by *T. campanula* and *T. serrata*. The infection mode is fecal-oral. Eggs develop into larvae in the small intestine and

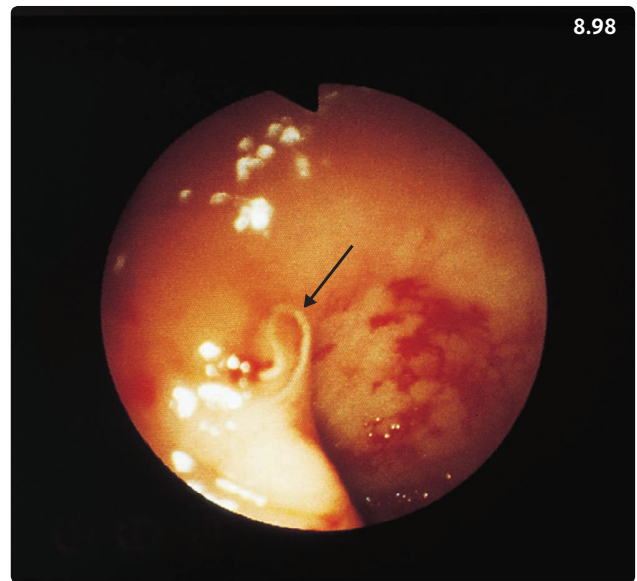


Figure 8.98 Endoscopic view of the colon of a 5-year-old mixed-breed dog with whipworm-induced colitis. The dog had severe bloody mucoid diarrhea for more than a week. Three consecutive fecal examinations were negative for parasitic ova. At endoscopy the mucosa was friable and hemorrhagic, with large numbers of *Trichuris* attached to the mucosa (arrow). The dog was treated with fenbendazole and sulfasalazine and made a good recovery.

larvae ultimately migrate to the cecum and colon, where they develop to adult worms (**Figure 8.98**).

Pathophysiology

Adult whipworms feed on cecal and colonic epithelial cells. Severe typhlitis and colitis may occur with heavy infestations; however, many dogs infested with few whipworms do not show clinical signs.

Clinical presentation

Acute or chronic large bowel diarrhea that may occur in dogs of all ages. Severely affected animals may present with lethargy, hyporexia, and dehydration. Abdominal discomfort or abdominal pain due to accumulation of gas in the large intestinal lumen may also be present. Rarely, whipworm infested dogs may show hyperkalemia and hyponatremia, which is suggestive of hypoadrenocorticism, even though their adrenal glands are fully functional.

Differential diagnosis

Other causes of acute colitis (dietary, idiopathic) or chronic colitis (IBD, granulomatous colitis). In the presence of hyperkalemia and hyponatremia, hypoadrenocorticism.

Diagnosis

Fecal flotation allows identification of the bipolar operculated eggs (Figure 8.99). However, fecal shedding of ova may only occur intermittently, particularly if immature worms are involved. Therefore, repeated fecal examinations usually increase the diagnostic yield. Alternatively, empirical treatment may be initiated with a broad-spectrum anthelmintic (see below). Further diagnostic testing is generally not required with the exception of severely dehydrated dogs and animals with pre-existing conditions. In dogs with recurrent episodes of acute diarrhea, a more detailed work up may be indicated.

Management

Fenbendazole (50 mg/kg/day for 3 days) or febantel (25 mg/kg once) are the anthelmintic drugs of choice. Because immature adults and larval stages are less sensitive to the drugs, treatment should be repeated 3 weeks later and again after 3 months. Milbemycin oxime and moxidectin used monthly to prevent heartworm infection are also useful for prevention and treatment of whipworm infestations. Whipworm ova are resistant to unfavorable environmental conditions and may represent a problem in shelter situations.

ACUTE IDIOPATHIC COLITIS

Etiology

Unknown. Some form of dietary indiscretion is usually present.

Pathophysiology

Colonic inflammation is associated with decreased non-propulsive motility and excessive propulsive motility that results in diarrhea with frequent defecation of feces of decreased consistency.

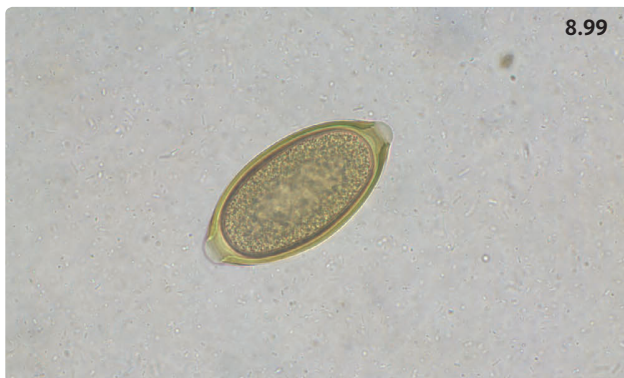


Figure 8.99 *T. vulpis* egg. The egg is lemon-shaped with a plug (operculum) at each pole. (Courtesy B. Delcambre)

Clinical presentation

Large bowel diarrhea with all typical components including hematochezia (see Figure 2.6.3), mucoid feces (see Figure 2.6.5), and tenesmus (Figure 8.100), as listed in Table 2.6.1. Acute nonspecific colitis may occur in dogs of any age.

Diagnosis

Elimination of known causes of acute colitis such as whipworm infestation and *C. perfringens* infection.

Management

The disease is usually self-limiting. Mild cases may not require any treatment. Moderate cases respond well to symptomatic treatment that includes dietary manipulations with a 12–24-hour fasting period. An easily digestible low residue diet should be fed for 48–72 hours (small meals several times daily), with progressive return to a good quality commercial diet over the following 48–72 hours. Systematic use of antimicrobials in cases of acute nonspecific colitis is not recommended because increases in the resistance of *C. perfringens* to metronidazole have been reported and are concerning. Metronidazole has been commonly used in the treatment of acute colitis because of its effects on the intestinal microbiome, its properties as a modulator of inflammation, and its spectrum against anaerobic infections. The use of probiotics provides a good alternative to antimicrobials (Box 8.7).

In cases with clinical evidence of dehydration, IV fluids should be administered using balanced isotonic crystalloid solutions at appropriate rates in order to

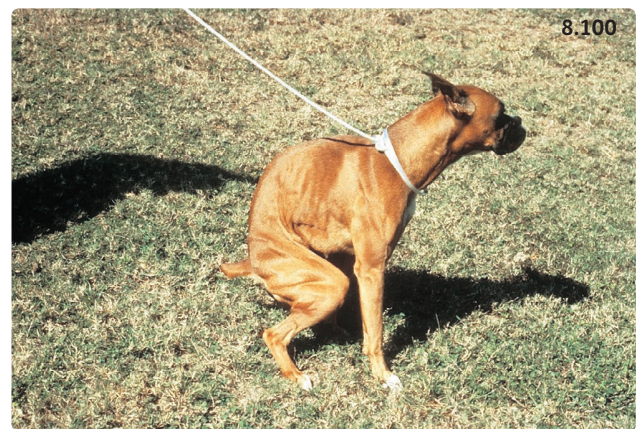

Figure 8.100 Tenesmus in a 2-year-old Boxer with chronic colitis. When walked the dog immediately attempted to defecate. It remained in this position for more than 2 minutes and produced only a small quantity of liquid feces.

rapidly replace fluid deficits and provide maintenance requirements. In dogs with severe acute colitis and consistent abdominal pain, analgesic treatment should be considered.

Prognosis

Good to excellent. The disease is generally self-limiting or it responds well to symptomatic treatment.

CHRONIC COLITIS

FUNGAL AND OOMYCETAL COLITIS

Overview

Animals infected with histoplasmosis may show signs of large bowel diarrhea. Rectal scraping or fine needle aspiration of enlarged abdominal lymph nodes may be diagnostic and reveal large numbers of fungal organisms phagocytized by macrophages (see **Figure 8.73**). Pythiosis is caused by an oomycetal organism and may occasionally diffusely infiltrate the colonic and rectal wall and cause severe clinical signs. The prognosis is generally poor (see **Figure 8.74**).

Further details about histoplasmosis and pythiosis can be found in Part 4: Diseases of the small intestine.

PARASITIC COLITIS

WHIPWORMS

(See Acute colitis.)

TRICHOMONIASIS

Etiology

Tritrichomonas foetus is a protozoal organism associated with chronic, recurring feline colitis in large multi-cat households. Most affected cats come from shelters or belong to breeders, and it is suspected that environmental stress plays a role in their susceptibility to the infection. Co-infections with *Giardia* are common. *T. foetus* is not very resistant in the environment and direct fecal-oral contact is required for transmission (e.g. multi-cat litterbox).

Pathophysiology

T. foetus live in the cecum, descending colon, and ileum, and may cause lymphoplasmacytic and/or neutrophilic inflammation of the mucosa with secondary architectural changes.

Clinical presentation

The disease affects young cats, with onset between birth and 2 years of age. Seventy-five percent or more of affected cats are younger than 1 year of age at the time of diagnosis. Affected cats either live or have lived in a large multi-cat household. Typical clinical signs include waxing and waning large bowel diarrhea, which may contain mucus and blood. The feces are soft and malodorous (**Figure 8.101**). Secondary anal inflammation may be observed.

Differential diagnosis

In shelter or other large multi-cat household situations, other infectious diseases such as infestation with *Giardia* or *Cryptosporidium* (see Chronic enteritis), alone or in combination, may also occur. However, these protozoa more often cause small intestinal or mixed diarrhea. In spite of the young age of cats with suspect *T. foetus* infections, CE should also be considered (DRD, IBD).

Diagnosis

Three methods are available for detection of *T. foetus* in the feces. Direct analysis of fresh feces after dilution with saline is an insensitive method (14%), but may yield a positive result in diarrheic feces of severely affected cats (**Figure 8.102**). Feces are best sampled by flushing the colon with saline, and should be analyzed within 2 hours. Under the microscope, *T. foetus* trophozoites may be misdiagnosed as *Giardia*; however, they have a characteristic

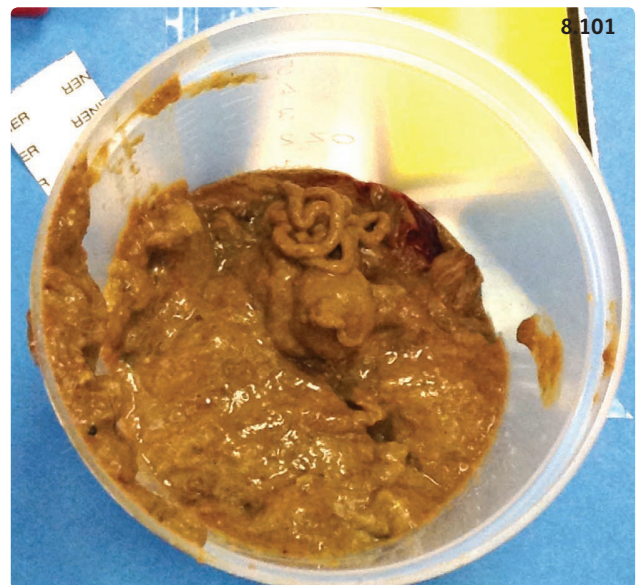


Figure 8.101 Soft and malodorous diarrhea from a cat with *T. foetus* infection. (Courtesy M.K. Tolbert)

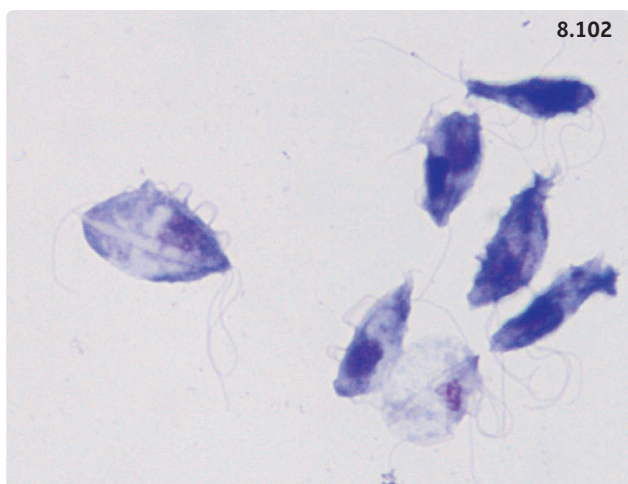


Figure 8.102 Microphotograph of stained *T. foetus* trophozoites. (Courtesy M.K. Tolbert)

forward motion that contrasts with the ‘falling leaf’ motion of *Giardia* trophozoites. Another method is to inject a small amount of fresh feces into a special culture medium (Feline In Pouch®) and evaluate the medium under the microscope at daily intervals for the presence of *T. foetus* trophozoites. The sensitivity of culture is intermediate (55%). Fecal PCR is the most sensitive method to detect *T. foetus* when the samples are collected adequately. Recommendations to increase the yield of fecal PCR can be found at www.JodyGookin.com.

Management

Treatment of *T. foetus* infection in cats is problematic as fenbendazole and metronidazole, as well as many other drugs, are ineffective. In a recent study, ronidazole (30 mg/kg PO q24h for 2 weeks) was effective at resolving clinical signs in 23 of 27 cats, with most cats becoming PCR negative. Only three cats developed side-effects consisting mostly of lethargy, vomiting, and lack of appetite that resolved after discontinuation of the drug. Ronidazole neurotoxicity has been reported within 3–9 days after initiation of treatment and resolved after discontinuation of the drug. Therefore, ronidazole should be administered only after a definitive diagnosis has been made and only at the dosage listed above. Natural resistance of *T. foetus* to ronidazole has been recently demonstrated in two cats that were refractory to treatment. Ronidazole is not approved for use in cats, and must be compounded in capsules.

Prognosis

Spontaneous resolution of *T. foetus* infection usually occurs within 2 years of onset. However, many cats may remain silent carriers and be able to infect other cats.

Ronidazole treatment is most efficacious in animals relocated to single-cat households, as the risk for reinfection is low.

CHRONIC IDIOPATHIC COLITIS

DIET-RESPONSIVE CHRONIC COLITIS

Overview

In a recent study, 56% of 70 dogs with chronic diarrhea responded to an elimination trial with a novel protein diet (see **Figure 8.86**). Of those 39 diet-responsive dogs, 27 (69%) exclusively showed large bowel diarrhea while nine (23%) had mixed large and small bowel signs. Similarly, in another study, 27 (49%) of 55 cats with chronic intestinal disease were diet responsive, while 16 (29%) were diagnosed as food sensitive. Two-thirds of the feline group had abnormal findings on colonic or rectal histopathology.

Based on these data, an elimination trial with hydrolyzed peptide or novel protein diets chosen on the basis of the animal’s dietary history should be initiated in all dogs with mild to moderate chronic idiopathic colitis. Clinical signs generally abate within 10–14 days of treatment.

INFLAMMATORY BOWEL DISEASE

Etiology/pathophysiology

The etiology and pathophysiology of IBD are described in Part 4 (Diseases of the small intestine, Chronic enteropathy). While it appears that IBD most often affects the small intestine or both small and large intestine concurrently (especially in cats), colonic IBD is a recognized disease. Synonyms include lymphoplasmacytic colitis, eosinophilic colitis.

Differential diagnosis

Whipworms, diet-responsive colitis, possibly colorectal neoplasia (see below). In cats with compatible signalment and history, *T. foetus* infection.

Diagnosis

The diagnostic approach must be comprehensive in order to rule out all other known causes of colitis (see **Figure 2.6.9**). While a treatment trial with sulfasalazine or olsalazine may be appropriate in dogs with suspect colonic IBD, colonoscopy with collection and histologic evaluation of mucosal biopsies is recommended prior to initiating immunosuppressive treatment. This will confirm the presence and assess the severity of colonic inflammation (**Figures 8.103, 8.104**) and rule out other

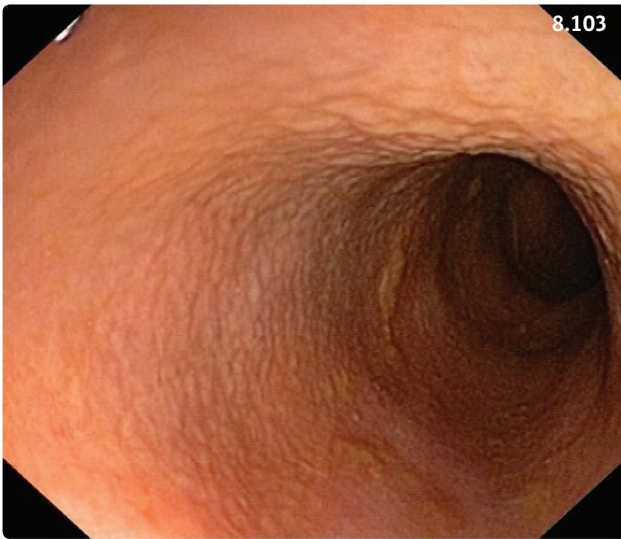


Figure 8.103 Colonoscopy view of a dog with chronic large bowel diarrhea. The inability to see submucosal vessels indicates thickening of the mucosa. The mucosal surface is irregular with a cobblestone pattern. The histopathologic diagnosis was severe lymphoplasmacytic colitis. (Courtesy R. Husnik)

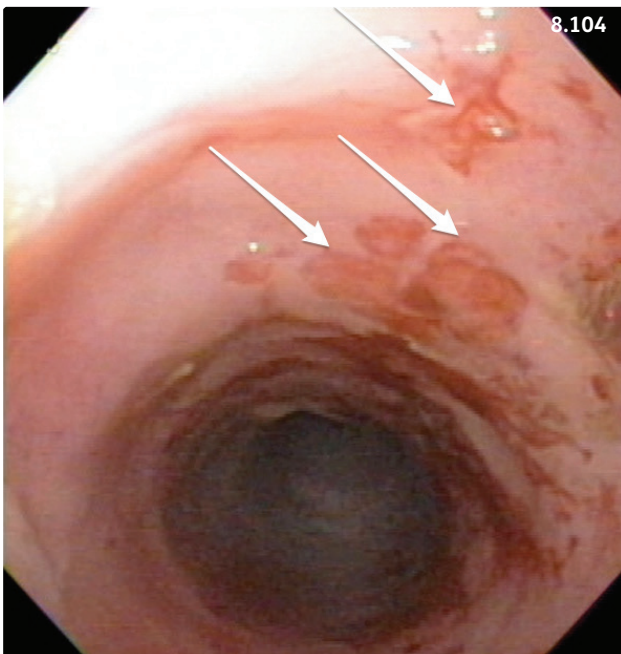


Figure 8.104 Colonoscopy picture of a 6-year-old cat with chronic large bowel diarrhea and hematochezia. There are numerous mucosal ulcerations (arrows). The histopathologic diagnosis was severe, ulcerative lymphoplasmacytic colitis. The cat improved when fed a novel protein diet and treated with immunosuppressive doses of prednisolone.

diseases such as granulomatous colitis (see below) or neoplasia (e.g. lymphoma, especially in cats). Colonoscopy requires appropriate preparation with prolonged fasting (24–48 hours), administration of electrolyte solutions with osmotic laxative effects, and possibly enemas. Rigid proctoscopy can be performed in sedated dogs; however, a full examination of the rectum, colon, and cecum is only possible using flexible endoscopes under general anesthesia.

Management

In dogs with suspect colonic IBD, an anti-inflammatory treatment trial with sulfasalazine may be attempted (10–30 mg/kg [maximum 1 gram total dose] PO q8h for 4–6 weeks). Sulfasalazine liberates 5-aminosalicylic acid in the colon, and is widely used in the treatment of dogs with colitis. After successful completion of the initial treatment regimen, it is best to slowly decrease the dose in stages of 10–14 days. Monitoring tear production regularly during treatment is essential as keratoconjunctivitis sicca is a common complication. Olsalazine (5–15 mg/kg q8–12h) may be used in dogs that do not tolerate sulfasalazine. In addition, dietary fiber supplementation is often helpful (see **Box 8.10**). In cats with colonic IBD and in dogs with confirmed colonic IBD refractory to sulfasalazine or olsalazine, immunosuppressive prednisone should be initiated (**Table 8.13**).

Prognosis

Prognosis for IBD is generally better when only the colon is affected. However, one retrospective study of dogs with IBD did not find any association between localization of disease and outcome. Nevertheless, clinical studies demonstrated that a large number of dogs and cats with colitis respond completely to dietary modification and/or, for dogs only, to sulfasalazine treatment.

GRANULOMATOUS COLITIS

Definition/overview

Granulomatous colitis (GC) is also known as histiocytic ulcerative colitis (HUC). It is a form of IBD that occurs most frequently in young Boxer dogs or, infrequently, in other breeds such as Mastiffs, Alaskan Malamutes, French Bulldogs, and English Bulldogs.

Etiology

Adhesive-invasive *E. coli* or adherent-invasive *E. coli* adhere to and invade intestinal epithelial cells and have been identified as the cause of GC. These *E. coli* are taken up by endosomes and persist in the macrophages instead of being cleared. A genetic predisposition for GC is suspected due to the preponderance of cases in young Boxer

dogs. Preliminary results from genetic studies in Boxers with GC and healthy controls point to a defective clearance of *E. coli* in macrophages.

Clinical presentation

The onset of disease generally occurs before 2 years of age. Clinical signs include severe chronic large intestinal inflammation with diarrhea, hematochezia, increased frequency of defecation, tenesmus, and presence of excessive mucus in the feces. Although physical examination findings are most frequently normal, weight loss and inappetence can be seen in severe cases (Figure 8.105).

Diagnosis

Signalment, history, and clinical signs are usually very suggestive. While it is tempting to initiate a treatment trial in these dogs, a comprehensive diagnostic work up including endoscopic biopsies is the recommended approach.

Colonoscopy typically reveals sites of severe colonic hemorrhage and ulcerations interspersed with stretches of normal appearing mucosa. Histology may show severe infiltration with neutrophils, macrophages, lymphocytes, plasma cells, and mast cells. Accumulation of large macrophages staining strongly positive with PAS in their cytoplasm is pathognomonic for GC (Figure 8.106). Confirmation of the presence of *E. coli* using fluorescent in situ hybridization (FiSH) analysis on formalin-fixed biopsies is now recommended as part of the detailed diagnostic work up of dogs with suspect HUC (Figure 8.107).

Management

Treatment of the disease consists of enrofloxacin at 10–20 mg/kg PO q24h for 4–6 weeks. Most affected dogs respond within 10–14 days of initiating therapy. While

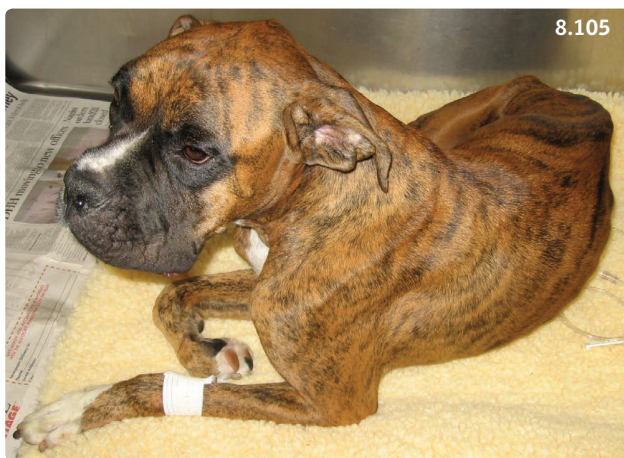

Figure 8.105 Eighteen-month-old Boxer with granulomatous colitis and chronic intermittent large bowel diarrhea, episodes of anorexia, and weight loss.

several dogs were reportedly disease-free after the drug had been discontinued, there is increasing evidence that GC may relapse after treatment. Recent reports suggest that up to 43% of dogs with GC/HUC develop enrofloxacin resistance early in the disease process and may be refractory to treatment if they are treated empirically. Therefore, it is prudent to send colonic biopsies for culture

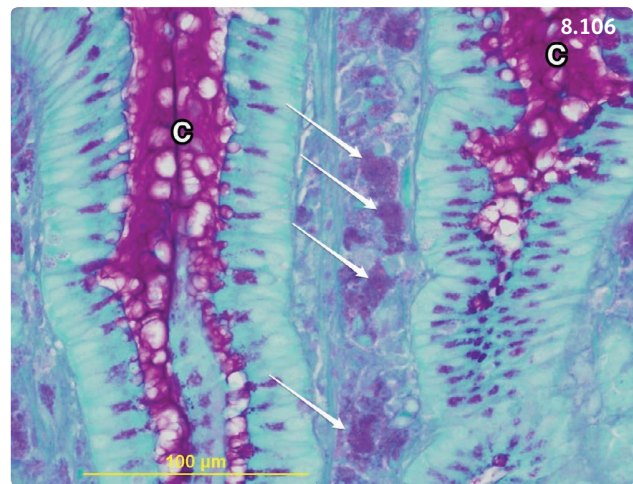


Figure 8.106 Photomicrograph from a colonic biopsy from a Boxer with granulomatous colitis. There are numerous purple-stained macrophages in the lamina propria (arrows point to four such cells). It is thought that the PAS-positive intracellular material represents accumulation of *E. coli*. PAS stain. C, colonic crypts.

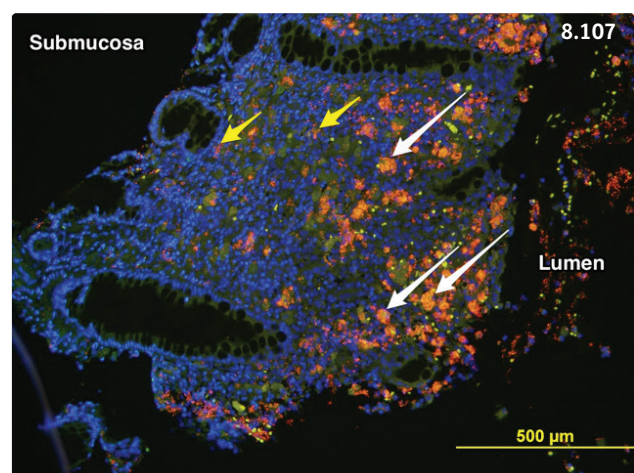


Figure 8.107 Photomicrograph of a colonic biopsy from a dog with granulomatous colitis (fluorescent in situ hybridization or FiSH). Long white arrows show some of the macrophages filled with *E. coli* while short yellow arrows show examples of clusters of *E. coli* within the mucosa. *E. coli*-Cy3 probe stains *E. coli* in red-orange; DAPI stains nuclei in blue. (Courtesy K. Simpson)

and sensitivity before starting treatment, and tailor the choice of antibiotics to the specific sensitivity profile of the cultured *E. coli*.

Prognosis

The long-term prognosis is guarded to poor.

COLORECTAL OBSTRUCTION

Etiology/pathophysiology

Luminal colonic or rectal obstruction may result from a FB or from the presence of hardened feces such as may be the case in constipated or obstipated patients. Alternatively, benign rectal strictures may occur in response to significant trauma of the rectal or distal colonic mucosa (e.g. FB, anorectal surgery). Fibrosis and cellular proliferation are responsible for narrowing of the lumen. Neoplastic masses arising from the colonic wall may also cause an obstruction to the passage of feces in the distal colon and rectum (see below). They may cause malignant strictures. Finally, space-occupying lesions occurring in neighboring organs such as the prostate or sublumbar lymph nodes may also compromise passage of feces through the distal large bowel.

Clinical presentation

Dyschezia, tenesmus (**Figure 8.108**), passage of ribbon-like feces (**Figure 8.109**), and hematochezia are frequently observed in association with partial or total colorectal obstruction. Severe retention of feces may lead to systemic repercussions such as hyporexia, lethargy, and vomiting.

Differential diagnosis

Primary colonic dysmotility, perineal hernia, anal sacculitis, and pseudocoprostasis may all cause dyschezia.

Diagnosis

In animals with a suggestive presentation, abdominal palpation and digital rectal examination often allow confirmation of the presence of partial or total obstruction of the distal large bowel. Sedation may be required for a thorough rectal examination, particularly in animals who are in pain. Radiographs and ultrasound of the abdomen and pelvic canal may be useful to detect a radiopaque FB and/or evaluate the severity of fecal retention and examine the surrounding structures. Endoscopic evaluation can be performed using a rigid proctoscope or a flexible endoscope. This allows visualization of the rectum and distal colon and collection of mucosal biopsies if a neoplastic process is suspected.



Figure 8.108 Severe tenesmus and dyschezia in a 4-year-old Husky with constipation due to a rectal stricture. The anus was scarred and extremely painful to palpation. The dog vocalized loudly each time it tried to defecate. Eventually, defecation ceased, presumably because it was too painful. Attempts at surgical correction, including anal resection, were unsuccessful and the dog was euthanized.



Figure 8.109 This 13-year-old Dachshund was presented with the complaint of tenesmus and 'narrow stools'. The dog strained hard to defecate and passed pencil thin feces. Rectal examination revealed a stricture. Biopsy revealed scar tissue and the dog responded well to balloon dilation and sulfasalazine.

Management

Most FBs can be dislodged using repeated warm water enemas with added water-soluble gel. Digital dilation of mild rectal strictures may be successful, although several procedures at intervals of 1 week are generally required. Balloon dilation usually has a higher success rate. In severe cases, or cases refractory to dilatory procedures,

surgical removal is required (rectal pull-through if possible or other procedure). The treatment of obstructive neoplasia relies on surgical excision if feasible (see below).

Prognosis

FB, benign polyp – good to excellent. Stricture, other neoplasia – guarded to poor. Anorectal surgery may lead to fecal incontinence or recurrence of stricture.

FUNCTIONAL LARGE BOWEL DISORDERS

CHRONIC IDIOPATHIC LARGE BOWEL DIARRHEA

Definition/overview

Chronic idiopathic large bowel diarrhea (CILBD) affects dogs and is characterized by recurrent large bowel diarrhea in the absence of histopathologic evidence of inflammation. It appears to be comparable to irritable bowel syndrome (IBS), a disease that is relatively common in people. One form of IBS is associated with diarrhea.

Etiology/pathophysiology

The etiology of CILBD is unknown. In people, IBS is associated with visceral hypersensitivity and patients have enhanced perception of visceral events such as contractions and gas throughout their GI tract. Stress, diet, and intestinal and colonic microbiota are all thought to play a role in the pathogenesis. Approximately 40% of dogs with CILBD have abnormal personality traits and/or are exposed to environmental stress factors. Associated behavioral issues may include separation anxiety, submissive urination, noise sensitivity, aggression, or nervous, high-strung dogs. Environmental factors may range from presence of visitors in the household and construction in the house to traveling and moving.

Clinical presentation

Dogs of all ages may be affected (median 6 years old) and exhibit chronic intermittent large bowel diarrhea. Excessive mucus in the feces (**Figure 8.110**), hematochezia, increased number of daily defecations, and/or tenesmus are common. Appetite may be decreased during diarrheic episodes and abdominal pain may be present. Vomiting may occur as well.

Differential diagnosis

Whipworm infestation, diet-responsive colitis, colonic IBD, granulomatous colitis (in Boxer dogs and Bulldogs), colonic neoplasia.

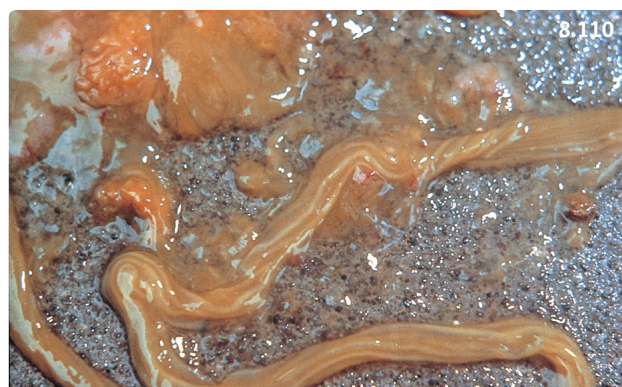

Figure 8.110 Feces from a 13-year-old mixed-breed dog with chronic idiopathic large bowel diarrhea. This dog had intermittent large bowel diarrhea only when the home environment was disturbed. Colonoscopy and mucosal biopsy were normal. The dog responded well to tranquilizers, anticholinergics, and a high-fiber diet.

Diagnosis

CILBD is a diagnosis by exclusion, and all other causes of chronic-intermittent large bowel diarrhea must be ruled out (see **Figure 2.6.9**). Diagnostic criteria for CILBD include chronic or chronic-recurring large bowel diarrhea of at least 4 weeks' duration, absence of or only minimal abnormal findings on physical examination and blood work, no other identifiable cause of diarrhea, and lack (or only minimal) changes observed during colonoscopy. Finally, histopathologic evaluation of the colonic mucosa must be unremarkable.

Management

Between 63% and 96% of dogs with CILBD respond to fiber supplementation alone (**Box 8.10**). In fiber-refractory dogs, a full behavioral assessment should be performed and behavior-modifying drugs prescribed as appropriate. In one study, approximately 60% of dogs requiring drug treatment responded, while 40% did not.

Prognosis

Prognosis is good considering the high response rate to fiber supplementation.

CONSTIPATION

Definition/overview

Constipation is characterized by infrequent or difficult evacuation of feces. Obstipation is the result of recurrent, intractable constipation. Constipation and obstipation may culminate in the syndrome of mega colon. In the cat

Box 8.10 Fiber supplementation in dogs with colitis and chronic idiopathic large bowel diarrhea.

Overall, dietary fibers enhance the structure and function of the intestinal epithelium, and also have beneficial effects on colonic motility. As a trade-off, they may have a negative impact on nutrient digestibility depending on the specific fiber type. Soluble fibers are fermented to short-chain fatty acids (SCFAs) by the colonic flora. SCFAs are an essential source of energy for colonic epithelial cells.

- Psyllium is a soluble fiber derived from the seed of *Plantago ovata*. It has great water holding capacities and forms gels in water, two properties that can contribute to improvement of fecal consistency. Psyllium was very efficient when added to a highly digestible diet in the treatment of chronic idiopathic colitis. The initial daily dosage is 0.5 tablespoon (T) for toy breeds, 1 T for small dogs, 2 T for medium dogs, and 3 T for large dogs. The fiber supplement should be administered with each meal, and the dose adapted to effect. Psyllium is included as an ingredient in a few commercial prescription diets.
- Canned pumpkin is another source of soluble fiber. It is administered with an initial dosage comparable to that of psyllium, and the dose is adapted to effect.

Other sources of SCFAs include fructooligosaccharides and beet pulp, which are included in some high-quality diets.

constipation is a relatively frequent problem while obstipation and megacolon are less common. Constipation and associated problems occur less frequently in the dog.

Etiology

Primary constipation is due to abnormal colonic motility. Neuromuscular dysfunction may occur in animals with lumbosacral disease or in cats with idiopathic megacolon. Dehydration, hypokalemia, and hypocalcemia may all negatively impact colonic motility. Inactivity and obesity may also be a cause of prolonged large bowel transit time. Furthermore, use of opiates and anticholinergics may also lead to constipation.

Secondary constipation is more common and is associated with processes that impair the transit and evacuation of colonic content, such as mechanical obstruction of the colon or rectum. Obstructions can be intraluminal (e.g. fecal impaction, FB, stricture), intramural (neoplasia), or extramural (e.g. narrowing of the pelvic canal, space-occupying lesions impinging on the descending colon or rectum).

Clinical presentation

Typical clinical signs include reduced, absent, or painful defecation, which may be progressive. Other clinical signs associated with a primary underlying disease might

be present, such as those associated with hypothyroidism, which is more common in dogs. The onset of distal bowel signs may be insidious and animals may be presented late when the problem is severe. Dyschezia may be observed (**Figure 8.108**). Chronic constipation/obstipation may have systemic repercussions such as anorexia, lethargy, weight loss, and vomiting.

Differential diagnosis

Diseases of the anorectum such as perineal hernia and anal sacculitis may cause painful defecation. Pseudocoprostasis or constipation can be caused by matted hair around the anus, which occasionally occurs in dogs and cats with long hair. Importantly, some cat owners may not be able to differentiate stranguria and dyschezia, and lower urinary tract diseases should always be ruled out.

Diagnosis

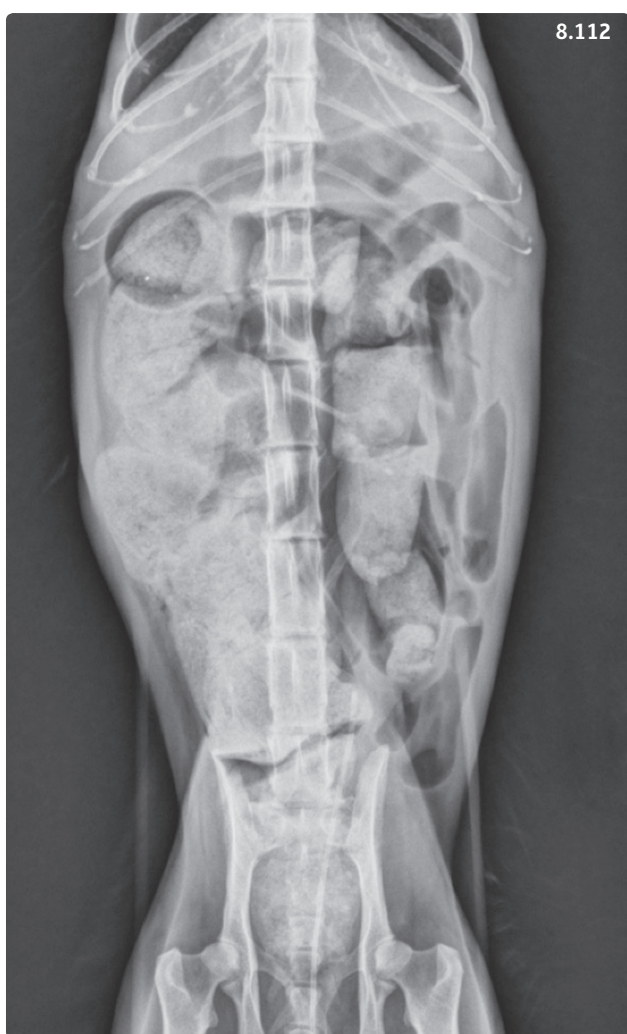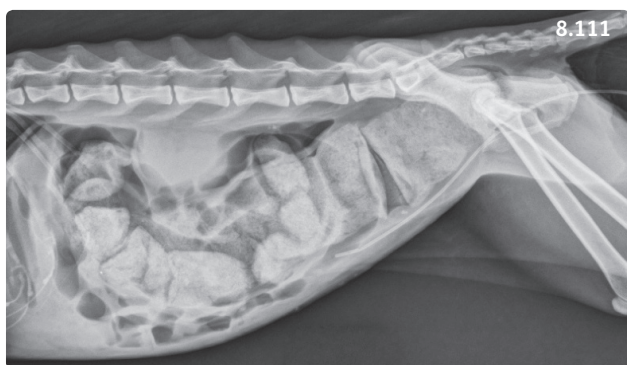A detailed physical examination is required. This may reveal varying degrees of dehydration, weight loss, and abdominal pain. Rectal palpation should be performed and may reveal pelvic canal abnormalities, a rectal FB, a stricture, or presence of a perineal hernia.

A thorough screening of animals presented with recurrent constipation is recommended to identify obstructions and underlying diseases and assess the systemic repercussions of the problem. A minimal database consisting of CBC, biochemistry panel, and urinalysis should be obtained in all cats presented for constipation to rule out metabolic causes and underlying chronic diseases such as chronic kidney disease. Abdominal radiographs help characterize the severity of colonic impaction (**Figures 8.111, 8.112**) and identify predisposing factors such as intraluminal radiopaque foreign material, intraluminal or extraluminal mass lesions, pelvic fractures, and spinal abnormalities. Extraluminal mass lesions may be further evaluated by abdominal ultrasonography and guided biopsy, whereas intraluminal mass lesions are best evaluated by endoscopy.

Management

All identified underlying problems should be treated. If the cause of the obstruction can be addressed in a timely manner, colonic function may be preserved. However, prolonged obstruction is ultimately associated with loss of colonic contractility.

The different methods for treatment of idiopathic, nonobstructive constipation include administration of oral laxatives, enemas (**Table 8.15**), and prokinetic agents such as cisapride (**Table 8.9**).



Figures 8.111, 8.112 Ten-year-old female spayed Domestic Shorthair cat. (8.111) Right lateral abdominal radiograph. There is severe dilation of the entire colon from the cecum to the rectum with large amounts of radiopaque fecal material. The cat is in poor body condition. Radiographic diagnosis is megacolon. A urinary catheter is present. (8.112) Ventrodorsal abdominal radiograph. The severely dilated and impacted colon is displaced to the right. (Courtesy L. Gaschen)

In cats with chronic recurrent idiopathic constipation, a stepwise approach has proven useful. Mild to moderate constipation (e.g. first occurrence, recurrence after a long interval with normal defecation) is best treated with an initial enema followed by treatment with laxatives. Maintaining these cats on a psyllium-enriched diet or continuing daily administration of laxatives is recommended. Addition of prokinetics is necessary when management with diet and laxatives fails. Early use of cisapride is likely to prevent the progression of constipation to obstipation and dilated megacolon in these cats. However, some cases become refractory to conservative treatment and slowly progress to obstipation and dilated megacolon.

When treating a constipated cat, enemas should be injected slowly, as rapid administration may cause reflex vomiting and rapid and excessive efflux of the liquid, and may also increase the risk of colonic perforation. If several enemas fail to induce defecation, nasoesophageal administration of PEG 3350 is a relatively noninvasive method with an excellent success rate (**Box 8.11, Figure 8.113**). This technique has significantly decreased the number of cases that need to undergo manual extraction of feces, a technique used when all other options have failed. It is best performed on an anesthetized cat with careful transabdominal colonic massage and simultaneous rectal administration of a combination of warm water or physiologic saline with water-soluble lubricants to break down the impacted feces. Some authors recommend administering a low dose of metronidazole

Box 8.11 Conservative treatment of moderate to severe colonic impaction on cats.

Polyethylene glycol (PEG) 3350 is an osmotic laxative that has been shown to be safe and palatable in cats. PEG 3350 can be administered to constipated or obstipated cats through a nasoesophageal tube as a CRI at a rate of between 6 and 10 ml/kg/hour. In a recent study, the mean total dose required was 80 ml/kg (range 40–156), and defecation occurred on average 8 hours after initiation of treatment (range 5–24). The technique has considerably decreased the need for enemas in feline practice (**Figure 8.113**).

Sources: Carr AP, Gaunt MC (2010) Constipation resolution with administration of polyethylene-glycol solution in cats. *J Vet Intern Med* **24**:723 (abstract).

Little S (2014) Personal communication.

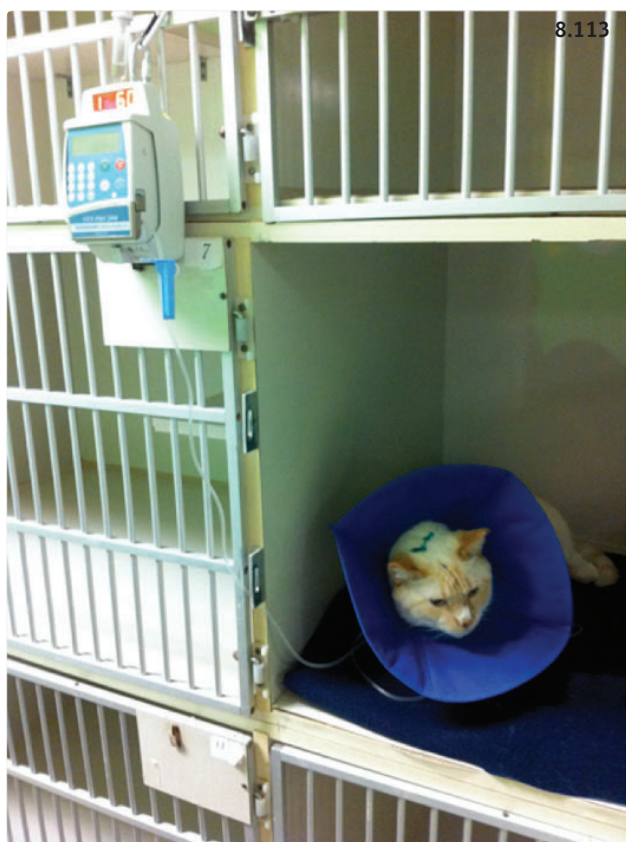

Figure 8.113 Constipated cat receiving PEG 3350 as a constant rate infusion via a nasoesophageal tube. (Courtesy S. Little)

(7.5–15 mg/kg PO q12h) in order to limit the risk of bacterial translocation during or after the procedure.

A surgical approach is the last option for severe cases with obstipation or megacolon that does not respond to conservative treatment options. Different techniques for colectomy have been successful.

Prognosis

Many cats have one or two episodes of constipation without further recurrence, although others may progress to complete colonic failure. When conservative management has failed, colectomy is usually associated with a favorable prognosis, although mild to moderate diarrhea may persist for 4–6 weeks postoperatively in some cases.

RECTAL PROLAPSE

Definition/overview

Prolapse can be partial with protrusion of anal mucosa only (anal prolapse) or complete with protrusion of all layers of the rectum (rectal prolapse).

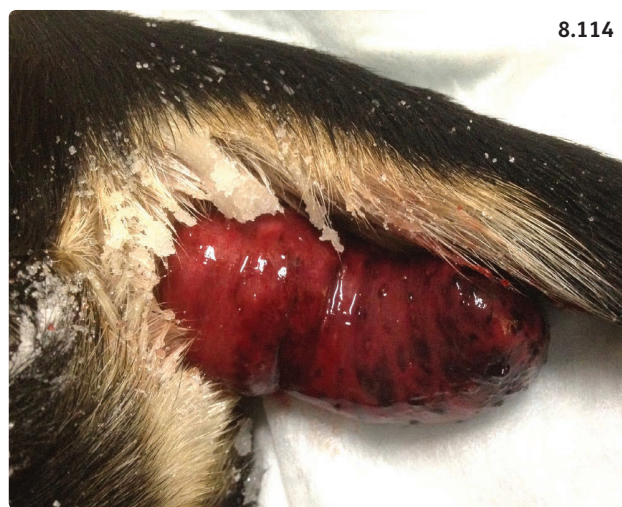

Figure 8.114 Young mixed-breed dog with rectal prolapse. Sugar has been applied to the mucosa to decrease the swelling.

Etiology

Prolapse occurs secondary to tenesmus associated with disorders of the colon, anorectum, or urogenital tract. Prevalence appears to be higher in young animals. Predisposing factors include GI parasitism, typhlitis, colitis, proctitis, colorectal neoplasia, rectal FBs, perineal hernia, diseases of the urinary bladder, prostatic disorders, and dystocia.

Clinical presentation

Anal prolapse is characterized by the presence of red, swollen mucosa protruding from the anus, particularly after defecation. In animals with a rectal prolapse, there is an often round or cylindrical mass protruding from the anus (**Figure 8.114**). The everted rectal mucosa and other wall layers can become ischemic and damaged and necrotic after prolonged exposure.

Diagnosis

A thorough physical examination is necessary to screen for the underlying diseases predisposing to prolapse listed above. If indicated, additional tests, such as fecal parasitologic examination, blood analyses, and abdominal imaging, should be performed.

Management

Reduction under sedation is easiest in animals with anal prolapse using saline and water-soluble lubricant gel. When a significant amount of mucosa is exposed or in rectal prolapse, 50% dextrose can be applied to the mucosa to reduce edema prior to careful repositioning. Corticosteroid cream can also be used to decrease

inflammation and straining. A purse-string suture is applied around the anus to narrow the anal orifice while allowing soft feces to pass through, and kept in place for 3–5 days. The animal should be fed a low residue diet; using lactulose (**Table 8.15**) to effect may be helpful. If the prolapsed rectal mucosa is traumatized or necrotic, surgical resection is required. Underlying conditions must be addressed to prevent recurrence. Colopexy may be required in animals experiencing recurrent episodes in spite of appropriate treatment.

Prognosis

Generally good if the mucosa is viable and the prolapse can be reduced. Guarded to poor if resection is required because of the risk of stricture.

COLORECTAL NEOPLASIA

Etiology

In dogs, the prevalence of colorectal neoplasia is higher than that of gastric and small intestinal tumors. The sites of predilection are the descending colon and rectum. Adenomas and polyps are relatively common (**Figure 8.115**), and *in-situ* progression to carcinoma has been documented. The most common type of malignant neoplasia is adenocarcinoma, followed by lymphoma and

stromal tumors such as leiomyosarcoma. Local tumor invasion appears to be slow, and metastasis to distant sites is uncommon.

In cats, adenocarcinoma and lymphoma are the two most frequent types of colorectal neoplasia, followed by mast cell tumors. Sites of predilection are the descending colon and ileocolic junction. Malignant feline colorectal tumors have a high rate of metastasis. Alimentary lymphoma often involves both the small and large intestines.

Pathophysiology

Colorectal neoplasms may cause mechanical obstruction. Colonic dysfunction with abnormal motility and decreased water reabsorption capacity (with subsequent diarrhea) may also occur.

Clinical presentation

In dogs, common clinical signs include hematochezia, mucoïd feces, and dyschezia, with or without concurrent diarrhea. Dyschezia may be associated with passage of feces of a smaller than usual diameter (see **Figure 8.109**). Systemic neoplasia such as lymphoma may be associated with signs suggesting involvement of other organs, hyporexia, and weight loss. In cats, vomiting, diarrhea, and weight loss are common with or without clinical signs of large bowel disease.

Table 8.15 Therapeutic options for conservative management of constipation in cats.

Laxatives (administer in well-hydrated cats only)	Bulk-forming (add to moist cat food). More useful in mild cases	Psyllium (1–4 teaspoons per meal); also available incorporated in a proprietary dry extruded diet (Royal Canin Intestinal Fibre Response®)
		Wheat bran (1–2 tablespoons per meal)
	Emollient	Diocetyl sodium succinate (10–15 ml/cat PO)
	Lubricant	Mineral oil (10–15 ml/cat PO); administer with caution due to risk of aspiration
		White petrolatum (1–5 ml/cat PO)
	Osmotic	Lactulose (0.5 ml/kg q8–12h PO) PEG 3350 (Colyte®) 1.9 g/cat; dose can be doubled if no results are seen after 48 hours. (See Box 8.11 for CRI instructions)
Stimulant	Bisacodyl (5 mg q24h PO)	
Removal of feces	Enemas	Warm water (5–10 ml/kg)
		Diocetyl sodium succinate or DSS (5–10 ml/cat)
		Mineral oil (5–10 ml/cat)
		Lactulose (5–10 ml/cat)
	Manual extraction	Under anesthesia

Differential diagnosis

Causes of chronic colitis such as IBD, GC, heavy whipworm infestation in dogs, IBD in cats. Also distal colonic or rectal FB or stricture.

Diagnosis

In dogs, rectal palpation can detect up to 80% of rectal tumors. In cats, more than half of colonic masses can be palpated abdominally. Survey radiographs may show an accumulation of feces orad to the neoplasm. Mural masses can be visualized using abdominal ultrasound, and surrounding lymph nodes can also be evaluated. Cytologic evaluation of ultrasound-guided fine needle aspirates can be useful, particularly for diagnosis of lymphoma. However, the diagnosis of most other tumors requires histopathology from a biopsy collected during colonoscopy. Endoscopy also allows a good evaluation of the severity and extent of the tumor (**Figures 8.115, 8.116**). Thoracic radiographs and abdominal ultrasound are used to stage the tumor, looking for pulmonary masses and abnormal abdominal lymph nodes.

Management

Rectal tumors are usually amenable to surgical resection using the rectal pull-through technique. Masses located in the cecum and colon require standard celiotomy for resection. The benefit of chemotherapy has not been established except for alimentary lymphoma. Currently

recommended chemotherapy protocols are best found in recent oncology texts.

Prognosis

Surgical excision is generally curative for benign tumors. While the rectal pull-through procedure has few complications, secondary infections may occur after celiotomy and resection of large bowel masses.

Canine carcinomas have been associated with a median survival of 32 months after removal in pedunculated tumors, 12 months for sessile tumors, and less than 2 months for annular tumors. The median survival time for leiomyosarcoma is 9–22 months after resection. Even though feline carcinomas benefit from an aggressive approach (subtotal colectomy), the median survival is only 4–5 months. The approach to alimentary lymphomas in cats is discussed in more detail in Part 4: Diseases of the small intestine.

Part 6: Diseases of the anus and perineum

FECAL INCONTINENCE

Definition/overview

Fecal incontinence is a rare disease that is characterized by involuntary loss of feces. Anal sphincter incontinence may be neurogenic (due to lesions damaging the innervation of the anal sphincter) or primary (in association with direct damage to the sphincter). Reservoir incontinence is uncommon and has been reported with loss of fecal storage capacity after colectomy.

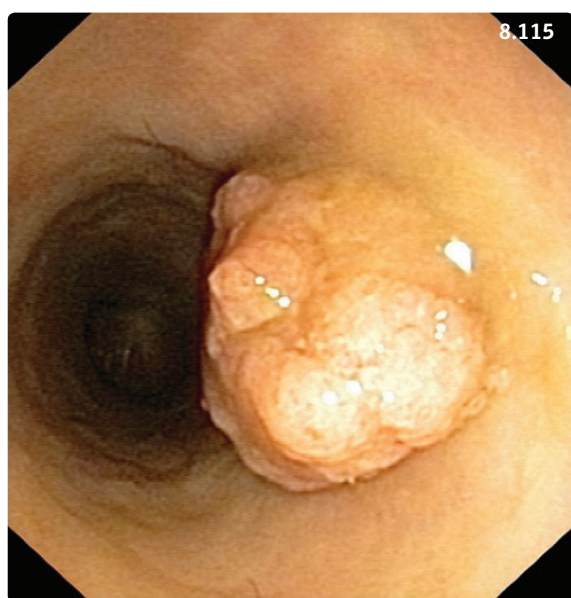


Figure 8.115 Colonoscopic view of an adenoma located in the distal colon of a dog. The parietal mass is pedunculated and could be removed with an electrocautery snare passed through the biopsy channel of the endoscope. (Courtesy R. Husnik)

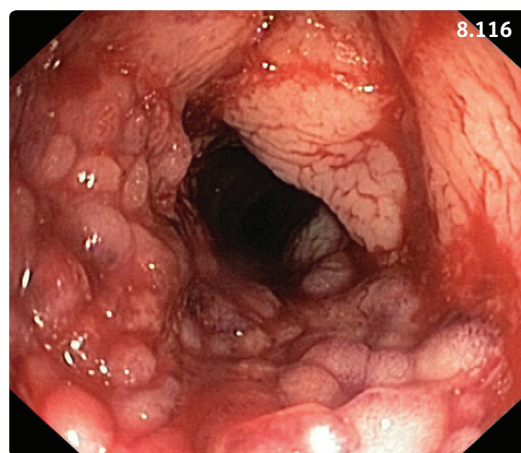


Figure 8.116 Endoscopic view of a dog with a severely abnormal rectal and colonic wall. The histopathologic diagnosis was adenocarcinoma. (Courtesy R. Husnik)

Etiology

Causes of non-neurogenic incontinence include IBD, colitis, colonic, rectal or anal/perianal neoplasia, anorectal trauma or surgery, and perianal fistula. Neurogenic incontinence is associated with sacral spinal cord disorders or peripheral nerve diseases.

Clinical presentation

Affected animals are unable to control defecation, with involuntary elimination of feces, and sometimes continuous fecal dribbling. Concurrent urinary incontinence may be present in animals with neurogenic fecal incontinence. Rectal palpation reveals significantly decreased anal tone. A thorough neurologic examination should be performed to detect other neurologic deficits.

Diagnosis

History and physical examination are usually sufficient. A search for neurologic lesions and their precise location may require cross-sectional imaging.

Management

Mild fecal incontinence may respond to opiates such as loperamide (0.1 mg/kg PO q8h). These drugs increase the tone of the internal sphincter, but are without effect on the external sphincter. Moderate to severe cases are difficult to treat, regardless of their origin.

Prognosis

Guarded to poor in many cases.

DISEASES OF THE ANAL SACS

Definition/overview

Anal sac impaction, anal sacculitis, and abscess formation are common anal sac diseases that may occur in dogs and occasionally in cats. Small breed dogs and some large canine breeds (e.g. German Shepherd Dog) appear to be at higher risk of developing anal sac diseases.

Etiology

The exact cause of anal sac disorders is unknown. Abnormal anal sac emptying may occur with decreased fecal consistency, obesity, and inactivity, or in association with painful perianal processes such as anal furunculosis. Anal sac impaction increases the risk of infection and/or abscessation.

Clinical presentation

Anal sac disease commonly causes anal or perianal pruritus and pain, with excessive licking and/or biting of the area, tail chasing, scooting, and rubbing the anus

on the ground. If the perineal area is swollen and painful, the animal may not want to sit. Other frequently associated signs include dyschezia, tenesmus, or even reluctance to defecate. A detailed examination of the perineal area, including rectal palpation, may reveal swelling and pain to the touch.

Differential diagnosis

Anal furunculosis, perianal or anal tumors, and bite wounds (especially in cats).

Diagnosis

History and clinical signs are suggestive. Swelling may be visible in the 4 and 8 o'clock positions ventral to the anus. Rectal palpation confirms the presence of swollen anal sacs, which are often painful. With impaction, pasty thick and malodorous material can be expressed from the swollen sacs. If the expressed material is bloody and/or purulent, anal sacculitis is likely and can be confirmed cytologically by the presence of large amounts of neutrophils with intracellular bacteria. Abscesses often involve the surrounding tissues, and cytology of a fine needle aspirate is diagnostic.

Management

Anal sac impaction is treated with gentle expression of the swollen anal sacs. If digital massage and expression are not successful, flushing the anal sacs with saline is recommended. Instillation of an antibiotic and steroid ointment into the empty sacs is generally recommended. In animals with infected sacs, treatment also consists of emptying and flushing the sacs and instillation of an antibiotic ointment. However, this generally requires sedation or light anesthesia. Systemic antibiotic treatment with a broad-spectrum antibiotic for 10–14 days is usually recommended. Topical treatment with hot compresses several times daily may help reduce swelling and pain. Abscesses should be lanced, flushed, and treated with systemic antibiotics. Anal sacculotomy is a last resort option for recurring cases.

Prognosis

Usually very good. Fecal incontinence is a possible complication of anal sacculotomy.

ANAL SAC TUMORS

Definition/overview

Anal sac tumors are uncommon and very often malignant neoplasms that occur in dogs. They may metastasize to regional lymph nodes and invade surrounding tissues.

Etiology/pathophysiology

The etiology is unknown. Between 50% and 90% of dogs with anal sac adenocarcinomas are hypercalcemic due to production of parathyroid hormone-related peptide by cancerous cells. This malignancy-associated hypercalcemia may ultimately lead to irreversible kidney injury.

Clinical presentation

Anal sac tumors most commonly affect older dogs, with a predilection for females. Dyschezia and perianal swelling may be observed. Up to 40% of dogs may only show clinical signs associated with hypercalcemia of malignancy: polyuria, polydipsia, vomiting, and constipation. A thorough rectal examination is essential to identify nodules associated with the anal sacs. Metastasis to sublumber lymph nodes is very common at the time of diagnosis, and liver and lungs may be affected as well.

Differential diagnosis

Other perianal tumors, perineal hernia, rectal FB, or stricture. Other causes of hypercalcemia, such as hyperparathyroidism, lymphoma, and other tumors, should also be considered.

Diagnosis

History and physical examination are suggestive. If a mass is present, cytologic evaluation of a fine needle aspirate may be diagnostic. Radiographs and ultrasonography are useful to evaluate the sublumber area, liver, and lungs for metastasis (Figure 8.117). Cross-sectional imaging may also be helpful in complicated cases. A CBC, serum chemistry profile, and urinalysis are essential to detect the presence of hypercalcemia (associated with hypophosphatemia) and possible secondary kidney damage.

Management

Wide surgical excision of the primary tumor and regional lymph node. The benefits of chemotherapy and/or radiation treatment have not been clearly established. Hypercalcemia may need to be addressed prior to surgery in order to avoid additional end organ damage (see Chapter 11: Endocrine disorders).

Prognosis

Poor to fair, with a 40% 1-year survival. Negative prognostic factors include presence of lymph node or distant metastases and tumor size.

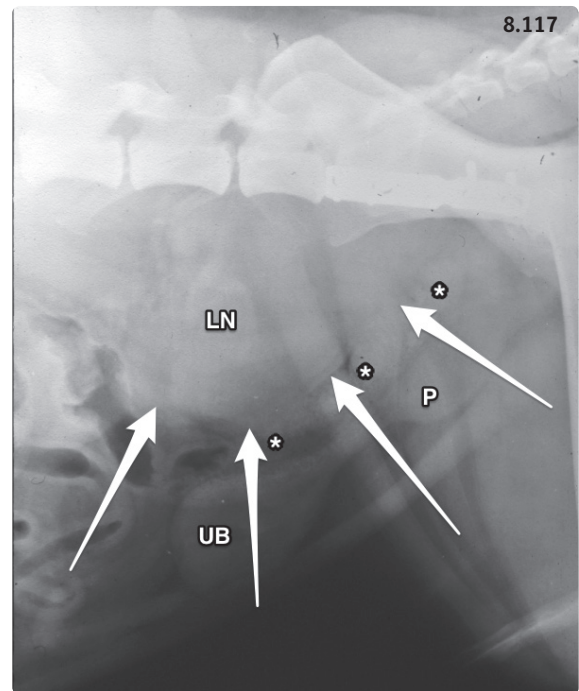


Figure 8.117 Radiograph of the caudal abdomen of a 10 year-old male Akita Inu. The dog was presented with severe hypercalcemia and dyschezia. While the primary anal sac tumor was a few millimeters in diameter, the sublumber lymph node (LN) was severely enlarged (arrows). Note the ventrally displaced colon (asterisks), urinary bladder (UB), and prostate (P). A metallic plate used to repair a pelvic fracture several years prior to presentation is visible on the ileum.

ANAL FURUNCULOSIS/PERIANAL FISTULAE

Definition/overview

Anal furunculosis is a chronic and painful disease of the canine anorectum that seems to preferentially affect middle aged to old German Shepherd Dogs and German Shepherd Dog mixed breeds, although dogs from other breeds may be also affected. The condition is characterized by inflammation, ulceration, and sinus tracts.

Etiology

The etiology is unknown, but is likely multifactorial.

Pathophysiology

The inflammatory process is chronic and consists of a mononuclear to granulomatous infiltrate. It may involve the anal sacs, their excretory ducts, the anal sphincter, and the circumanal glands. Immune dysregulation with aberrant cell-mediated immune response and excessive local production of matrix metalloproteinases has been reported in dogs with anal furunculosis. The lower carriage of the

tail in affected dogs may provide the necessary environment for worsening inflammation and infection.

Clinical presentation

Clinical signs include a painfully ulcerated perineal region with perianal discharge (**Figure 8.118**) and associated tenesmus, dyschezia, hematochezia, and/or constipation. In severe cases, anorexia, weight loss, and behavioral changes may be observed. Intensive perianal licking may be an early sign.

Differential diagnosis

Anal sac abscessation, perianal tumor, bite wound, or other traumatic injury.

Diagnosis

Thorough examination of the perianal area may be difficult without sedation. The perineum should be cleaned to appreciate the extent of the disease process. The anus and rectum should be evaluated in detail, as they may be involved as well.

Management

Immunosuppression with cyclosporine (5 mg/kg PO q12–24h for 1–3 months) is effective in 60–98% of cases but can be costly in large dogs. Concurrent use

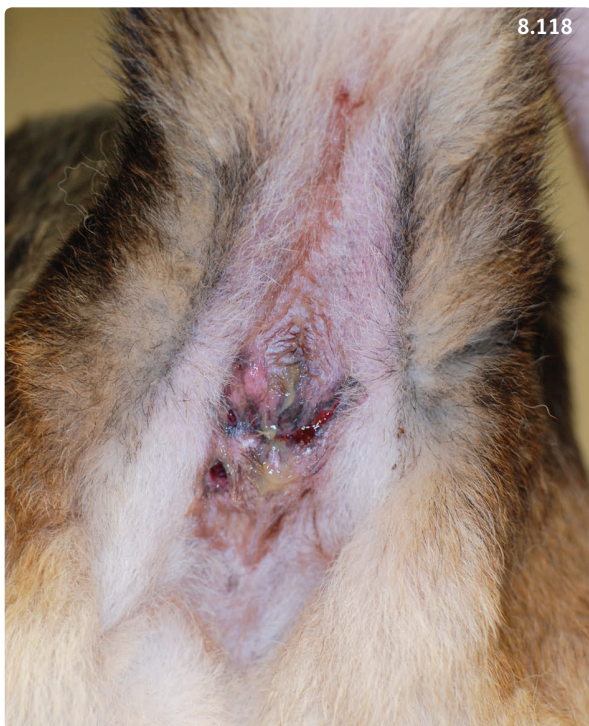

Figure 8.118 View of the cleaned and clipped perianal area of an 8-year-old female spayed German Shepherd Dog with anal furunculosis. Note several fistulous tracts oozing bloody or purulent exudate. (Courtesy LSU SVM Dermatology Service)

of ketoconazole, an inhibitor of cytochrome P450 enzymes, to increase the half-life of cyclosporine is not recommended because combination therapy results in unpredictable and often subtherapeutic cyclosporine levels. Immunosuppressive doses of prednisone (at least 2 mg/kg PO q24h) only help in one-third of cases. The effect of other immunosuppressive drugs has not been evaluated. Medical treatment followed by surgery (excision of remaining tracts, anal saccullectomy) is associated with a lower risk of recurrence. A significant number of dogs with anal furunculosis have concurrent adverse reaction to food, and feeding an elimination novel-protein or hydrolyzed diet may contribute to decreasing the recurrence rate.

Prognosis

Overall guarded. Recurrence is common. Anal sphincter incompetence and fecal incontinence are well known complications of surgery.

PERINEAL HERNIA

Definition/overview

Perineal hernia results from weakness and breakdown of the pelvic diaphragm, with deviation and herniation of the rectum (and, possibly, the urinary bladder, prostate, and small intestine) into the perineum. The pelvic diaphragm consists of the levator ani and coccygeus muscles and the perineal fascia.

Etiology

The condition occurs in middle aged intact male dogs. Predisposed breeds include Pekingese, Boston Terrier, Welsh Corgi, Boxer, Poodle, Bouvier, and Old English Sheepdog. It is occasionally seen in cats as a surgical complication of perineal urethrostomy or colectomy.

Pathophysiology

The exact pathophysiology is unknown, and the disease is most likely multifactorial. The existence of rectal abnormalities (dilation, diverticulum), androgens, gender-related anatomic differences, relaxin (a hormone synthesized in the prostate), prostatic disease, and neurogenic atrophy have all been associated with perineal hernia in dogs.

Clinical presentation

Typical presenting signs include reducible perineal swelling (**Figure 8.119**), tenesmus, dyschezia, and constipation. The disease can be unilateral (if so, the right side is more commonly affected) or bilateral. Rectal examination reveals a defect in the pelvic diaphragm surrounding the rectum. If the bladder is retroflexed, dogs may not be

able to void urine and develop postrenal azotemia with associated signs such as vomiting, anorexia, and lethargy.

Differential diagnosis

Perineal tumor.

Diagnosis

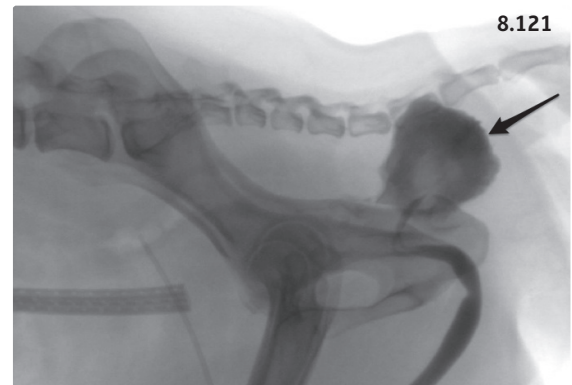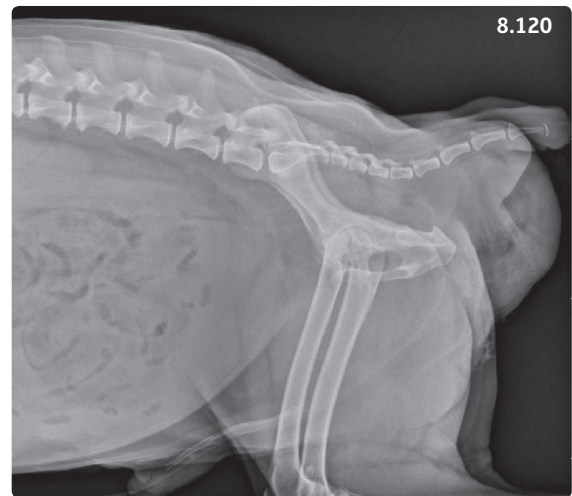History and clinical signs are usually sufficient. Survey and contrast radiographs (Figures 8.120, 8.121) or ultrasonography (Figure 8.122) are necessary to confirm retroflexion of the urinary bladder or other organs. CBC, serum chemistry, and urinalysis are useful to evaluate kidney function.

Management

Medical management, consisting of maintaining a soft fecal consistency with laxatives such as lactulose (0.5 ml/kg PO q8–12h) or a bulk-forming agent such as psyllium (Box 8.10), and occasional enemas, may be successful in the short term with mild cases. However, most cases require surgical treatment. Herniorrhaphy using the internal obturator transposition technique is usually successful. (See surgery textbooks for further details.)




Figure 8.119 Severe bilateral perineal hernia in a 10-year-old intact male Rottweiler.



Figures 8.120, 8.121 Another dog with a perineal hernia. (8.120) Caudal abdominal radiograph. A large soft tissue mass representing the hernia can be seen in the perineum. The urinary bladder is not visible in the caudal abdomen. (8.121) Positive contrast retrograde urethrocytography. The bladder is retroflexed in the perineal hernia. (Courtesy L. Gaschen)

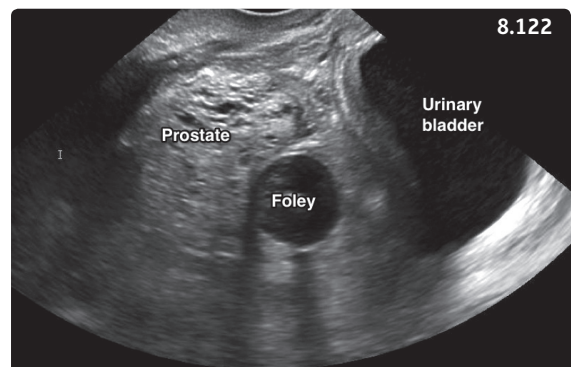


Figure 8.122 Ultrasound image of the dog in Figure 8.119. The prostate and urinary bladder are retroflexed in the retroperitoneal space. The balloon of a Foley catheter passed into the bladder is visible. Orientation: left is cranial; right is caudal.

Surgical complications include seroma, wound infection, fecal incontinence, and sciatic nerve paralysis.

Prognosis

Good if the hernia can be repaired early, guarded in dogs with chronic perineal hernia. In the latter group, recurrence is frequent and repeat surgical intervention is often challenging.

PERINEAL TUMORS

Definition/overview

The perianal region of dogs contains perianal (or circumanal) glands that are located in the dermis in a circular pattern around the anus. Perianal adenomas are the most common perianal tumors, while perianal adenocarcinomas occur considerably less frequently.

Etiology

Perianal adenomas are sex hormone dependent and occur mostly in middle aged to older males. Cocker Spaniels, Beagles, Bulldogs, and Samoyeds may be predisposed. Adenocarcinomas are not influenced by sex hormones and occur in neutered or intact male and female dogs.

Clinical presentation

Adenomas are slow growing, single, multiple or diffuse nonpainful masses located around the anus or on the perineum, and occasionally also on the prepuce, scrotum, and tailhead. Adenocarcinomas grow faster and may be similar to adenomas, but may be more firm, adhere to underlying tissues, and become ulcerated.

Differential diagnosis

Differentiating adenoma from adenocarcinoma is challenging, but important, as more aggressive treatment is required for the malignant perineal tumor. Detection of metastases is strongly indicative of adenocarcinoma.

Diagnosis

Signalment, history, and physical examination are suggestive. Cytologic evaluation of a fine needle aspirate reveals typical sebaceous cells that resemble hepatocytes. However, cytology does not allow reliable differentiation between adenoma and adenocarcinoma.

Management

Adenoma: castration and conservative surgical removal. Adenocarcinoma: wide excision of the primary tumor and affected lymph nodes. Postoperative radiation therapy may be useful. Inoperable cancers may benefit from palliative radiation treatment and chemotherapy.

Prognosis

Adenoma: excellent, low risk of recurrence after excision if the dog is neutered. Adenocarcinoma: removal at an early stage (diameter less than 5 cm) is associated with good survival.

RECOMMENDED FURTHER READING

- Ettinger SJ, Feldman EC (2010) (eds) *Textbook of Veterinary Internal Medicine*, 7th edn. Saunders Elsevier, St. Louis.
- Little SE (2012) (ed) *The Cat. Clinical Medicine and Management*. Elsevier Saunders, St. Louis.
- Nelson RW, Couto CG (2014) (eds) *Small Animal Internal Medicine*, 5th edn. Saunders Elsevier, St. Louis.
- Washabau RJ, Day MJ (2013) (eds) *Canine and Feline Gastroenterology*. Elsevier Saunders, St. Louis.
- Withrow SJ, Vail DM, Page RL (2013) (eds) *Withrow and MacEwen's Small Animal Clinical Oncology*, 5th edn. Elsevier Saunders, St. Louis.