

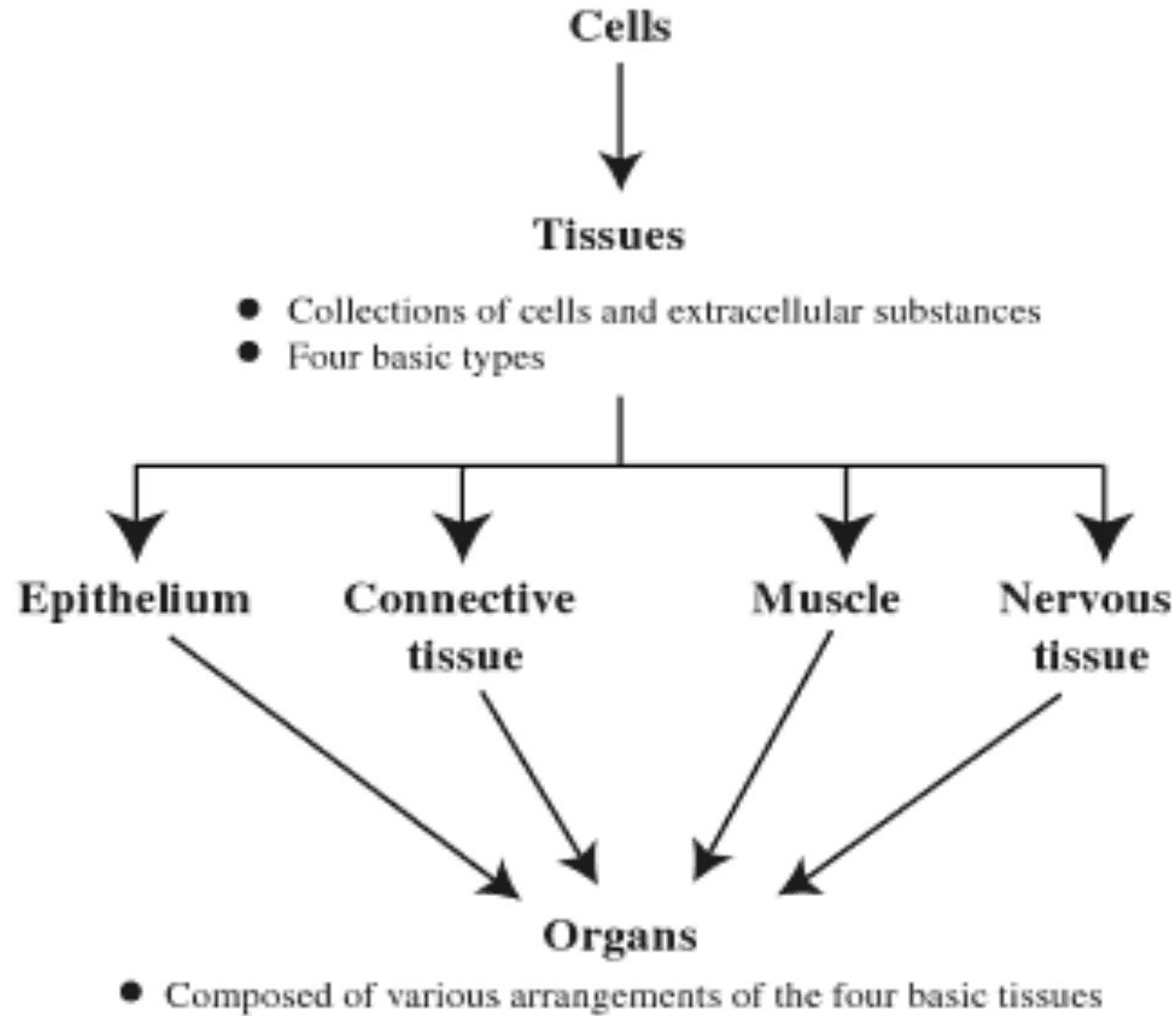
**EPITHELIUM**  
**M**

# Cells, Tissues, and Organs

Epithelium is a tissue. A tissue is an aggregation of cells and intercellular substances specialized to perform particular functions. Despite its structural and functional complexity, the animal body is composed of four basic types of tissue:

- epithelium,
- connective tissue,
- muscle, and
- nervous tissue.

Organs consists of various arrangements of the four basic tissue.



**Epithelial tissues** are composed of closely aggregated polyhedral cells with very little extracellular substance.

These cells have strong adhesion due to **adhesion molecules**, **membrane interdigitations**, and **intercellular junctions**.

These features allow the cells to form cellular sheets that cover the surface of the body and line its cavities or are arranged as three-dimensional secretory units.

The principal functions of epithelial tissues are

- **the covering and lining of surfaces** (eg, skin, intestines),
- **absorption** (eg, intestines),
- **secretion** (eg, glands),
- **sensation** (eg, gustative and olfactory neuroepithelium), and
- **contractility** (eg, myoepithelial cells).
- Because epithelial cells line all external and internal surfaces of the body, everything that enters or leaves the body must cross an epithelial sheet.

# The Forms & Characteristics of Epithelial Cells

- The forms and dimensions of epithelial cells range from high **columnar** to **cuboidal** to low **squamous** cells.
- Their polyhedral form is the result of their juxtaposition in layers or three-dimensional assemblages.

# The Forms & Characteristics of Epithelial Cells

Epithelial cell nuclei have distinctive shapes, varying from spherical to elongated or elliptic.

The form of the nuclei of epithelial cells corresponds roughly to the cell shape; thus, cuboidal cells have spherical nuclei and squamous cells have flattened nuclei.

# The Forms & Characteristics of Epithelial Cells

Because the boundaries between cells are frequently indistinguishable with the light microscope, the form of the cell nucleus is an important clue to the shape and number of cells.

The nuclear form is also of value in determining whether the cells are arranged in layers, a primary morphological criterion for classifying epithelia.

# The Forms & Characteristics of Epithelial Cells

Almost all epithelial cells are found on connective tissue.

In the case of epithelia that line the cavity of internal organs (especially the digestive, respiratory, and urinary systems) this layer of connective tissue is often called **lamina propria**.



# The Forms & Characteristics of Epithelial Cells

The lamina propria not only serves to support the epithelium but also provides nutrition and binds it to neighboring structures.

The area of contact between epithelium and lamina propria is increased by irregularities in the connective tissue surface in the form of small evaginations called **papillae**.

**Papillae** occur most frequently in epithelial tissues subject to stress, such as the skin and the tongue.

# The Forms & Characteristics of Epithelial Cells

The portion of the epithelial cells that faces the connective tissue is called the **basal surface**,

whereas the opposite side, usually facing a space, is called the **apical surface**.

The surface of the apical pole is also called the **free surface**, whereas the surfaces that are opposed to neighbor cells are called **lateral surfaces**.

# Basal Lamina & Basement Membrane

- Most epithelial cells are separated from the connective tissue by a sheet of extracellular material called the **basal lamina**.
- This structure is visible only with the electron microscope, where it appears as a dense layer, 20–100 nm thick, consisting of a delicate network of very fine fibrils (**lamina densa**).
- In addition, **basal laminae** may have an electron-lucent layer on one or both sides of the lamina densa, called **lamina rara** or **lamina lucida**.

## **Basal Lamina & Basement Membrane**

The main components of **basal laminae** are type IV collagen.

Basal laminae are attached to the underlying connective tissues by anchoring fibrils formed by type VII collagen.

These components are secreted by epithelial, muscle, adipose, and Schwann cells.

In some instances, reticular fibers are closely associated with the basal lamina, forming the reticular lamina.

Connective tissue cells produce reticular fibers.

# Basal Lamina & Basement Membrane

Basal laminae have many functions.

In addition to simple structural functions supporting the cells, they provide a **barrier** that limits or regulates the exchange of macromolecules between connective tissue and cells of other tissues.

The basal lamina is also able to influence cell polarity, regulate cell proliferation and differentiation by binding with growth *factors*, influence cell metabolism, and serve as pathways for cell migration.

The basement membrane usually is not visible in routine light-microscopic sections, but can be demonstrated with the periodic acid-Schiff (PAS) technique or silver stain.

# Basal Lamina & Basement Membrane

The basement membrane is usually formed by the association of either two basal laminae or a basal lamina and a reticular lamina and is therefore thicker.

"Basement membrane" is used to denote the thicker structure seen with the light microscope.

# Types of Epithelia

Epithelia are divided into two main groups according to their structure and function:

- **Covering (surface) epithelia** and
- **Glandular epithelia.**

**Surface epithelium** consists of sheets of aggregated cells of a similar type that cover all of the external surfaces and line all of the internal surfaces of the body.

**Glandular epithelium**, the secretory cells of endocrine and exocrine glands, results from the proliferation of surface epithelial cells into underlying connective tissue.

## **Covering (surface) Epithelia**

In covering epithelia the cells are organized in layers that cover the external surface or line the cavities of the body.

They can be classified according to the number of cell layers and the morphological features of the cells in the surface layer. **Simple epithelium** contains only one layer of cells, and **stratified epithelium** contains more than one layer.



# Covering Epithelia

Based on cell shape, simple epithelia can be **squamous**, **cuboidal**, or **columnar**.

The **endothelium** that lines blood and lymph vessels and the **mesothelium** that lines certain body cavities, such as the pleural and peritoneal cavities, and covers the viscera are examples of *simple squamous epithelium*.

All blood vessels are lined with a **simple squamous epithelium** called **endothelium**.

The **simple squamous epithelium** that covers the body cavities is called **mesothelium**.

An example of **simple cuboidal epithelium** is the surface epithelium of the **ovary**, and cells that form certain tubules in **glands (thyroid)** and in **the kidney collecting tubules**.

## Covering Epithelia

Simple columnar epithelia line the **intestines, the gallbladder, uterus**, and other organs.

Simple columnar epithelium formed by long cells with elliptical nuclei.

The epithelium rests on the loose connective tissue of the lamina propria.

A basal lamina (not visible) is interposed between the epithelial cells and the connective tissue.

The round nuclei within the epithelial layer belong to lymphocytes that are migrating through the epithelium (arrows).

## Covering Epithelia

Stratified epithelium is classified according to the cell shape of its superficial layer: **squamous**, **cuboidal**, **columnar**, and **transitional**.

**Pseudostratified** epithelium forms a separate group.

## Covering Epithelia

**The stratified squamous epithelium** is found primarily in places subject to attrition (**skin, mouth, esophagus, vagina**).

Its cells form many layers, and the cells closer to the underlying connective tissue are usually cuboidal or columnar.

As they move progressively closer to the surface the cells become irregular in shape and flatten, becoming very thin and squamous (arrow).

## Covering Epithelia

**Stratified squamous keratinized epithelium** covers dry surfaces such as the **skin**.

As opposed to **nonkeratinized epithelium**, which covers wet surfaces, the most superficial cells of keratinized epithelia involute and are transformed into dead scales of protein without *discernible* nuclei.

# Covering Epithelia

**Stratified columnar epithelium** is rare; it is present in the animal body only in small areas, such as the **ocular conjunctiva** and the **large ducts of salivary glands**.

**Transitional epithelium**, which lines the **urinary bladder**, the **ureter**, and the upper part of the **urethra**, is characterized by a surface layer of domelike cells that is neither squamous nor columnar. The form of these cells changes according to the degree of distention of the bladder.

# Covering Epithelia

**In pseudostratified epithelium**, so called because the nuclei appear to lie in various layers, all cells are attached to the basal lamina, although some do not reach the surface. The best-known example of this tissue is the ciliated pseudostratified columnar epithelium in the **respiratory passages**.

Pseudostratified columnar epithelium of the **trachea**, formed by long and short cells. As some cells do not reach the surface of the epithelium their nuclei are present in different heights of the epithelial layer. Mucus-secreting cells, called goblet cells (arrow), intermingle with ciliated lining cells. Cilia are found in cells extending up to the lumen.

# Covering Epithelia

Two other types of epithelium warrant brief mention.

**1. Neuroepithelial cells**

**2. Myoepithelial cells**

**1. Neuroepithelial cells** are cells of epithelial origin with specialized sensory functions (eg, **cells of taste buds** and of the **olfactory mucosa**).



# Covering Epithelia

**2. Myoepithelial cells** are branched cells that contain myosin and a large number of actin filaments.

They are specialized for contraction, mainly of the secretory units of the **mammary**, **sweat**, and **salivary** glands.

## **GLANDULAR EPITHELIA**

Glandular epithelia are formed by cells specialized to produce secretion.

The molecules to be secreted are generally stored in the cells in small membrane-bound vesicles called **secretory granules**.

# Glandular Epithelia

Glandular epithelial cells may synthesize, store, and secrete proteins (eg, **pancreas**), lipids (eg, **adrenal**, **sebaceous glands**), or complexes of carbohydrates and proteins (eg, salivary glands).

The **mammary glands** secrete all three substances.

Less common are the cells of glands that have low synthesizing activity (eg, **sweat glands**) and that secrete mostly substances transferred from the blood to the lumen of the gland.

## Types of Glandular Epithelia

The epithelia that form the glands of the body can be classified according to various criteria.

Unicellular glands consist of isolated glandular cells, and multicellular glands are composed of clusters of cells.

An example of a unicellular gland is the **goblet cell** of the lining of the small intestine or of the respiratory tract.

## Types of Glandular Epithelia

Ultrastructurally a goblet cell shows a basal nucleus surrounded by RER (R), a large Golgi complex (G) just above the nucleus, and an apical end filled with large secretory granules (SG) containing mucins.

This highly viscous material is secreted by exocytosis and is then hydrated to form mucus in the lumen lined by microvilli (M).

## Types of Glandular Epithelia

The term "gland," however, is usually used to designate large, complex aggregates of glandular epithelial cells, such as in the salivary glands and the pancreas.

Glands develop during fetal life from covering epithelia by means of cell proliferation and invasion of the subjacent connective tissue, followed by further differentiation.

**Exocrine glands** retain their connection with the surface epithelium, the connection taking the form of tubular ducts lined with epithelial cells through which the secretions pass to the surface.

**Endocrine glands** have lost their connection to the surface from which they originated during development.

These glands are therefore ductless and their secretions are picked up and transported to their sites of action by the bloodstream rather than by a duct system.

## Formation of glands from covering epithelia

During fetal development epithelial cells proliferate and penetrate the underlying connective tissue. They may—or may not—maintain a connection with the surface epithelium.

When the connection is maintained, **exocrine glands** are formed; with the connection lost, **endocrine glands** are formed.

# Formation of glands from covering epithelia

Exocrine glands secrete to the body surface or gut via duct systems formed from the epithelial connection.

The cells of endocrine glands, which secrete hormones can be arranged in cords or in follicles with lumens for storing the secretory product.

From either the cords (left) or follicles (right) of endocrine cells, the secretory product is released outside the cells and picked up by the blood vessels for distribution throughout the body.



# Types of Glandular Epithelia

Multicellular glands, whether exocrine or endocrine, also have connective tissue in a surrounding capsule and in septa that divide the gland into lobules. These lobules then subdivide, and in this way the connective tissue separates and binds the glandular components together.

## **General structure of exocrine glands**

Exocrine glands by definition have ducts that lead to an organ or body surface.

Inside the gland, the duct runs through connecting septa and branches repeatedly, until its smallest branches end in the secretory portions of the gland.

## General structure of exocrine glands

Exocrine glands have a **secretory portion**, which contains the cells specialized for secretion, and **ducts**, which transport the secretion out of the gland.

The morphology of these components allows the glands to be classified according to the scheme shown.

## General structure of exocrine glands

- Ducts can be **simple** (unbranched) or **compound** (with two or more branches).
- Secretory portions can be **tubular** (either short or long and **coiled**) or **acinar** (round or globular).
- Either type of secretory portion may be **branched**.
- Compound glands can have **tubular**, **acinar**, or **tubuloacinar** secretory portions.

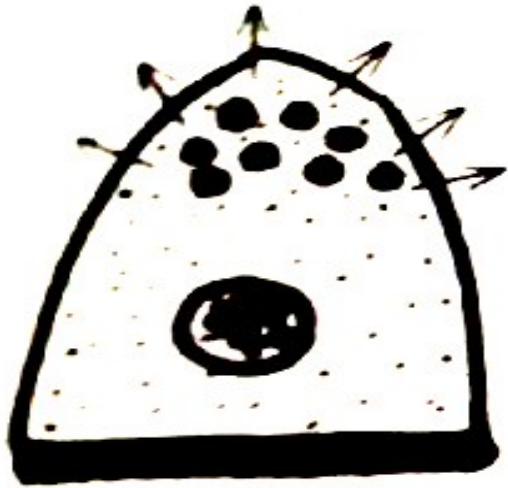
## **Structural classes of exocrine glands**

- Simple glands have unbranched ducts, although the ducts may be short or long and coiled.
- The secretory portions attached to these ducts may themselves be branched.
- The secretory portions are either tubular, if more or less cylindrical in shape, or acinar, if bulbous or saclike.

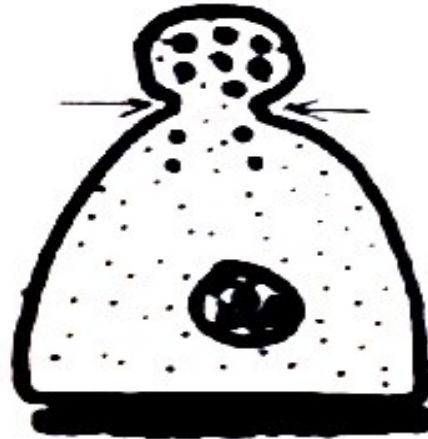
## Structural classes of exocrine glands

- If the ducts branch to serve multiple secretory units, the gland is **compound**.
- On compound glands, the secretory units may be all tubular, all acinar, or a combination of the two shapes.


## Exocrine glands are also classified functionally according to the way the secretory products leave the cell



Merocrine Secretion (Eccrine)



Apocrine Secretion



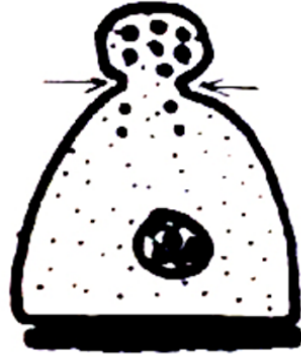Holocrine Secretion

- **Merocrine secretion** (sometimes called **eccrine**) involves typical exocytosis of proteins or glycoproteins. This is the most common mode of secretion.
- In an intermediate type, **apocrine secretion**, the secretory product is typically a large lipid droplet and is discharged together with some of the apical cytoplasm and plasmalemma.
- **Holocrine secretion** involves the cell filling with secretory product and then the whole cell being disrupted and shed. This is best seen in the **sebaceous glands** of skin.


# Functional classification of exocrine glands



Merocrin Secretion (Eccrin)



Apocrine Secretion



Holocrin Secretion

Different cellular secretion processes are used in exocrine glands, depending on what substance is being secreted.

**(a): Merocrine glands** secrete products, usually containing proteins, by means of exocytosis at the apical end of the secretory cells. **Most exocrine glands** are merocrine.

**(b): Apocrine gland** secretion involves loss of a large membrane-enclosed portion of apical cytoplasm, usually containing one or more lipid droplets. This apical portion of the cell may subsequently break down to release its contents during passage into the duct. Apocrine secretion, along with merocrine secretion, is seen in **mammary glands**.

**(c): Holocrine gland** secretion is produced by the disintegration of the secretory cells themselves as they complete differentiation which involves becoming filled with product. **Sebaceous glands of hair follicles** are the best examples of holocrine glands.



# Exocrine Glands

Exocrine glands with merocrine secretion can be further categorized as either **serous** or **mucous** according to the nature of the proteins or glycoproteins secreted and the resulting staining properties of the secretory cells.

## Serous cells

The acinar cells of the pancreas and parotid salivary glands are examples of the serous type which secrete **digestive enzymes**.

Serous cells stain intensely with any basophilic or acidophilic stain.

## **Serous cells**

The basal ends of serous cells have well-developed RER and Golgi complexes and the cells are filled apically with secretory granules in different stages of maturation.

# Mucous cells

Mucous cells, such as goblet cells, while also rich in RER and Golgi complexes are filled apically with secretory granules containing strongly hydrophilic glycoproteins called **mucins**.

When mucins are released from the cell, they become hydrated and form **mucus**, a viscous, elastic, protective lubricant material.

Mucin-containing granules stain well with the periodic acid-Schiff (PAS) method for glycoproteins.

But are not intensely acidophilic like zymogen granules of serous cells.

## **Mucous cells**

Mucous cells of large glands are organized as secretory tubules and in mixed seromucous salivary glands crescent-shaped clumps of serous cells frequently share the ends of the tubules as serous demilunes.

# Myoepithelial cells

Several exocrine glands (eg, sweat, lachrymal, salivary, and mammary glands) contain stellate or spindle-shaped **myoepithelial cells (M)** located between the basal lamina and the basal pole of secretory or duct cells.

Long processes of these cells embrace an acinus as an octopus might embrace a rounded boulder.

Along ducts they are more longitudinally arranged. Myoepithelial cells are connected to each other and to the epithelial cells by both gap junctions and desmosomes.

These cells are specialized for contraction, containing myosin and a large number of actin filaments.

Their major function is to contract around the secretory or conducting portion of the gland and thus help propel secretory products into the duct.

# Endocrin Glands

Endocrine glands are the producers of **hormones**, which are generally polypeptide or lipid-derived factors that are released into the interstitial fluid.

Hormones diffuse into the blood for circulation and bind specific receptors on target cells elsewhere in the body, often within other endocrine glands.

The receptors may also be on cells very close to the hormone-secreting cells or on the secreting cell itself; in these cases, the cellular signaling is termed **paracrine** or **autocrine**, respectively.

Hormones can be secreted from single cells that are sparsely distributed or from cells with other major functions, such as certain cardiac muscle cells.

# Endocrin Glands

In the large endocrine glands, the parenchymal cells form strands or cords interspersed between dilated capillaries (eg, the adrenal cortex) or can line a follicle filled with stored secretory product (eg, the thyroid gland).

Some endocrine glands have cells releasing more than one hormone.

Some organs such as the pancreas have both endocrine and exocrine functions, and in the liver, one cell type may function both ways, secreting bile components into a duct system, as well as releasing other products into the bloodstream.



## KAYNAKLAR

1. Delman, H. D., Eurel, J. (1998): Textbook of Veterinary Histology, Willium & Wilkins,USA.
2. Ergün, L., Şimşek, N., Bayraktaroğlu, A. G., Ergün, E. (2015): Histoloji Atlası Uygulama Klavuzu. Petek Ofset Basın Yayın Ltd.Ştd. Balıkesir.
3. Junqueira, L.C., Carneiro, J., Kelley, R. O. (1998): Basic Histology. Ninth Edition. Appleton & Lange, Stamford.
4. Özer, A., Girgin, A., Liman, N., Özfiliz, N., Özcan, Z., Erdost, H., Ergün, L., Zık, B., Özen, A., Ergün, E., Kocamış, H. (2016): Temel Histoloji, Dora Yayınevi, Bursa.
5. Özer, A., Girgin, A., Alabay, B., Liman, N., Özfiliz, N., Gülmez, N., Özcan, Z., Yörük, M., Erdost, H., Aslan, Ş., Ergün, L., Zık, B. (2008): Veteriner Özel Histoloji. Nobel Yayın Dağıtım Tic. Ltd.Şti. Ankara.
6. Özfiliz, N., Erdost, H., Ergün, L., Özen, A. (2012) Temel Veteriner Histoloji ve Embriyoloji. Anadolu Üniversitesi Yayınları. Eskişehir.
7. Ross, M.H., Pawlina, W. (2006): Histology. A Text And Atlas. With Correlated Cell And Molecular Biology, Fifth Edition, Lippincott Williams And Wilkins, Philadelphia.
8. Sağlam, M., Aştı, R.N., Özer, A. (2008): Genel Histoloji. Genişletilmiş, Yorum Matbaacılık, Ankara.
9. Tanyolaç, A. (1999): Özel Histoloji. Yorum Basın Yayın Sanayi Ltd. Şti. Ankara.