



**ANKARA UNIVERSITY FACULTY OF VETERINARY  
MEDICINE DEPARTMENT OF ANATOMY**



# Techniques for Preparation of Osteological Specimens & Types of Osteological Specimens- 2

**DR. OKAN EKİM**



Assoc.Prof. Okan EKİM

**ANKARA UNIVERSITY FACULTY OF VETERINARY MEDICINE DEPARTMENT OF ANATOMY**

# Types of Osteological Specimens

- Whole body specimen (skeleton)
- Single or multiple designed bony specimens
- Specimens for extremity bones
- Dyeing (coloring) of cranium bones
- Demonstrating of vessels or nerves on the bones



Assoc.Prof. Okan EKİM

ANKARA UNIVERSITY FACULTY OF VETERINARY MEDICINE DEPARTMENT OF ANATOMY

# 1. WHOLE BODY BONE SPECIMENS (SKELETON)

- All bones had been macerated, cleaned, rinsed and dried previously.
- Make a final check if there is missing bones on the skeleton.
- Bones should be ordered from front to back or top to bottom.
- What will the skeleton's final position be? What kind of materials will be required? Where will the skeleton be placed? At first, these should be planned meticulously.
- The materials, tools and equipments to be used should be determined.
- Drawings, photographs or anatomical illustrations of the skeleton must be obtained in advance and used during the construction.
- Exchange of ideas between colleagues.
- Imagination and accurate anatomical information are very important.



# Materials, Chemicals, Tools & Equipments

- Tools & Equipments → Hookup, pliers, pincers, hammer, tape measure, star-flat screwdriver, drill, sander, silicone gun.
- Materials & Chemicals → Metal wire, 5 mm iron sticks, marble cement, Polimax super silicone, 2K instant glue, poliurethane foam, wooden plates, penloc GTI, varnish, resin.



Assoc.Prof. Okan EKİM

ANKARA UNIVERSITY FACULTY OF VETERINARY MEDICINE DEPARTMENT OF ANATOMY

# Putting of Vertebral Column Together

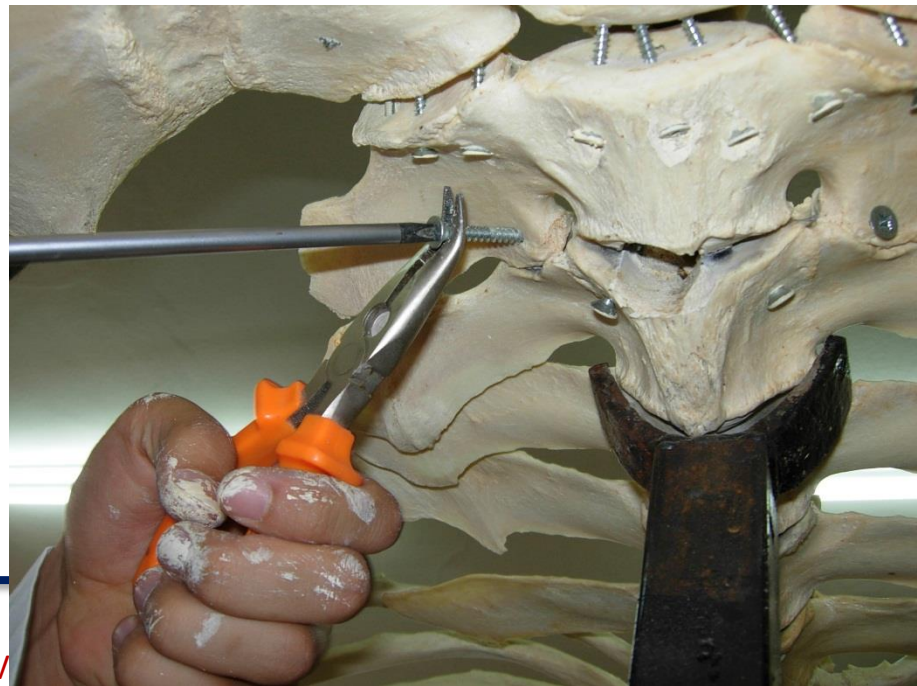
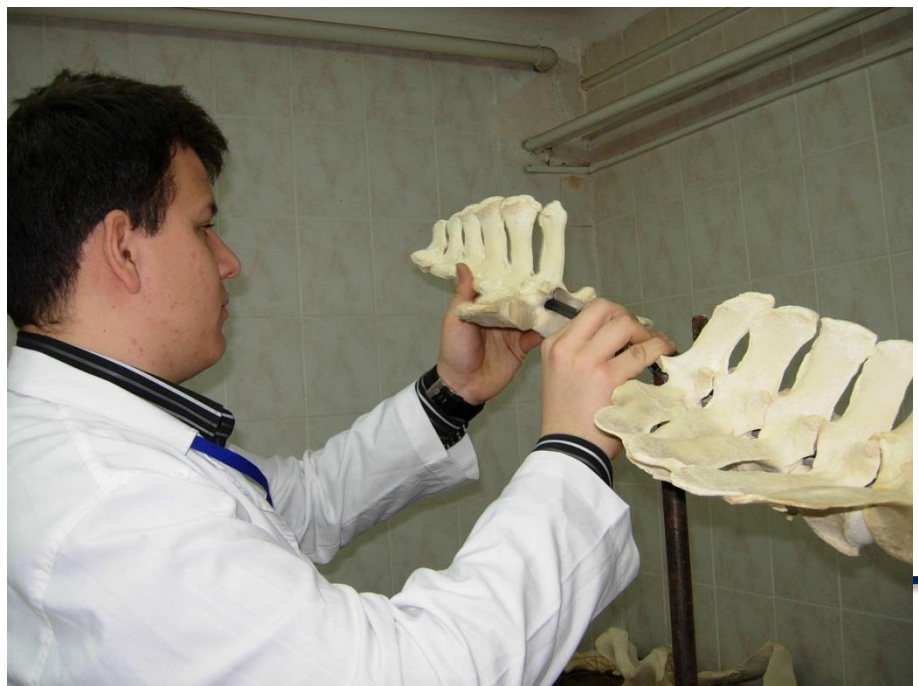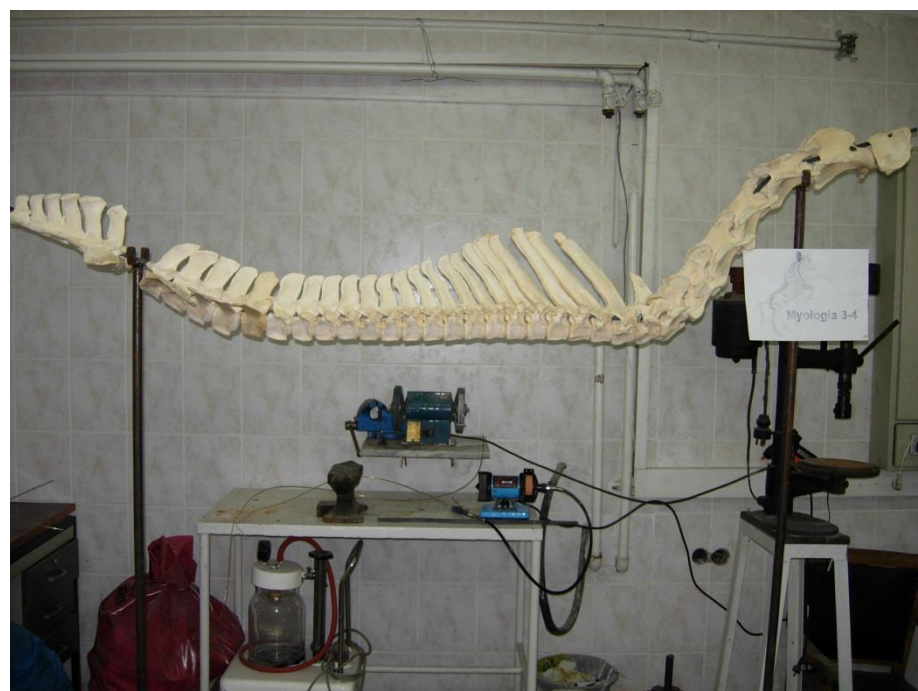- Bones were cleaned and ordered during maceration process.
- Use anatomic references for accurate shape and slope of the vertebral column. Illustrations, atlases, internet, photo.
- Use a 5 mm thick iron stick to pass from the atlas to sacral bone through the vertebral canal. Firstly, give an accurate slope and angle to the iron stick. Then pass it through the vertebral canal.
- In addition to 5 mm iron stick, use a second wire. The central point of the shafts (corpus) of all vertebrae should be drilled and this second wire should be passed through the entire vertebral column including the caudal part.



# Putting of Vertebral Column Together

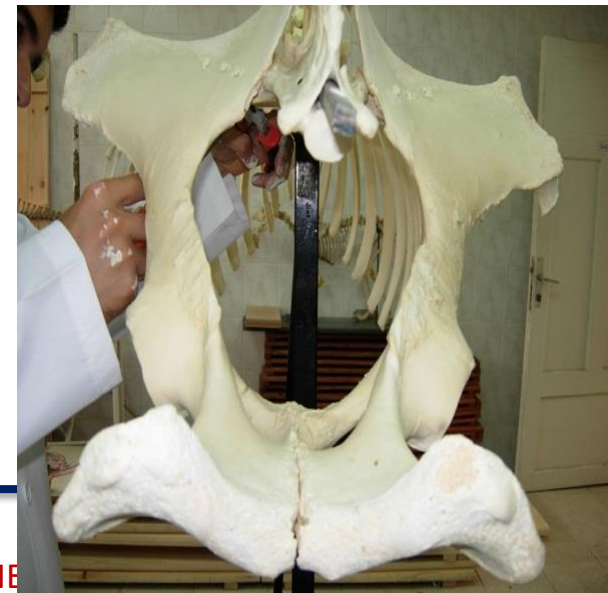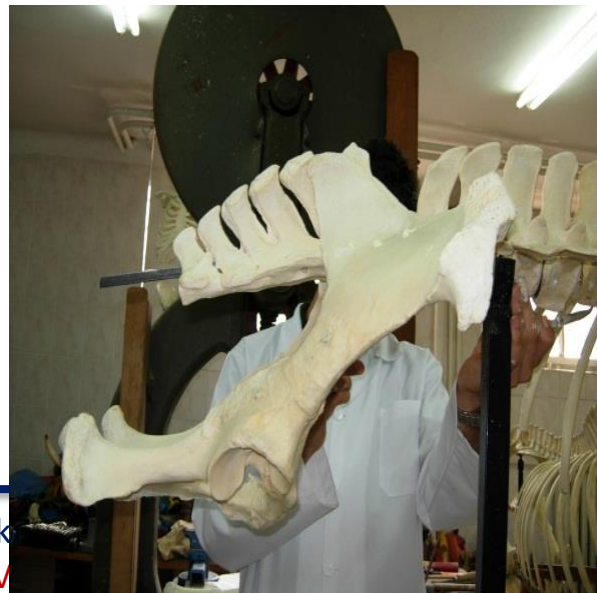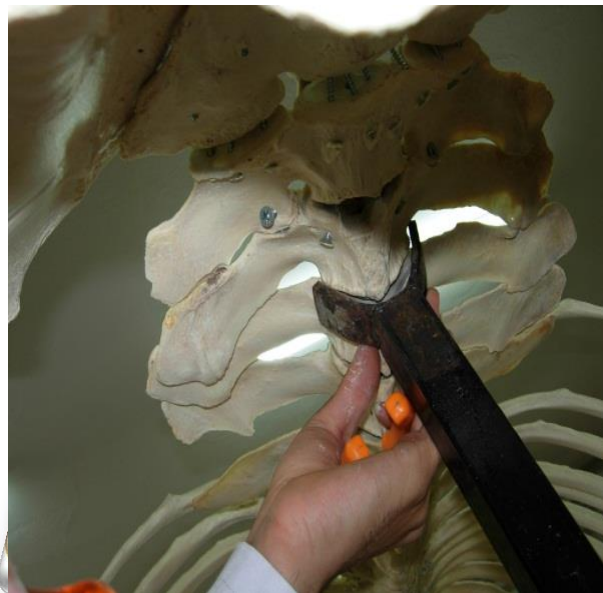
- All sequent vertebrae should be attached to each other. Caput → fossa, proc.art.cranialis → proc.art.caudalis. (Chemical → Polymax, silicone)
- Drying period for silicone is long. Therefore, use 2K instant glue for stabilization of vertebral column.
- The iron stick and wire should also be passed to cranium through the foramen magnum.
- Give the accurate position to head, pass the stick and wire through the cranium. Apply polyurethane foam to the entire cranial cavity.
- If needed, apply polyurethane foam to the vertebral column.



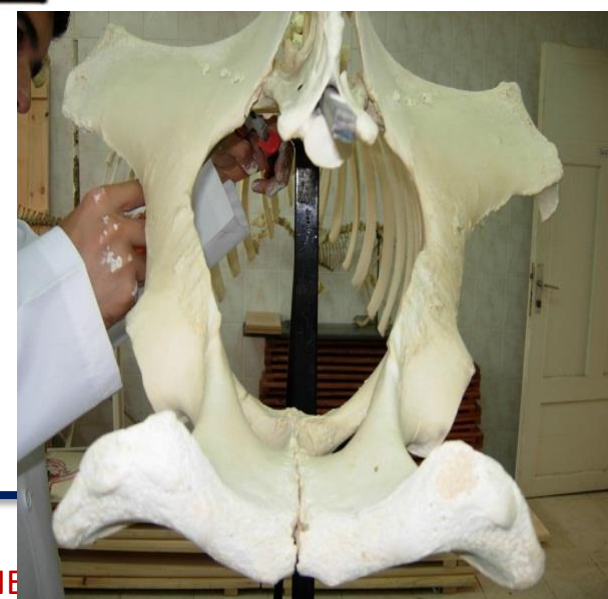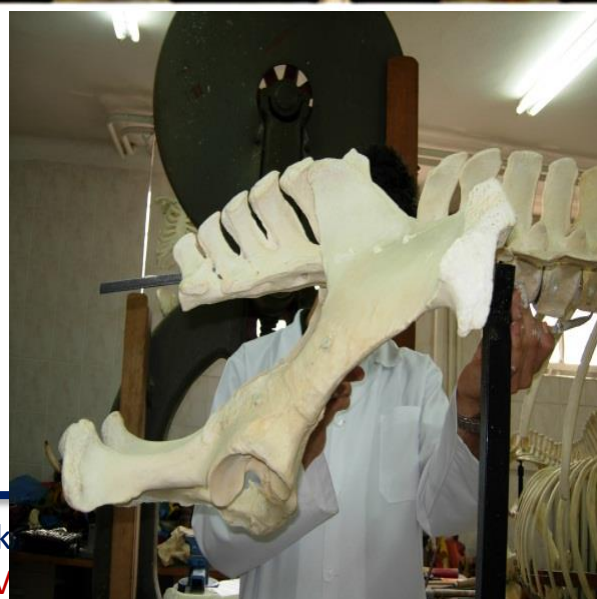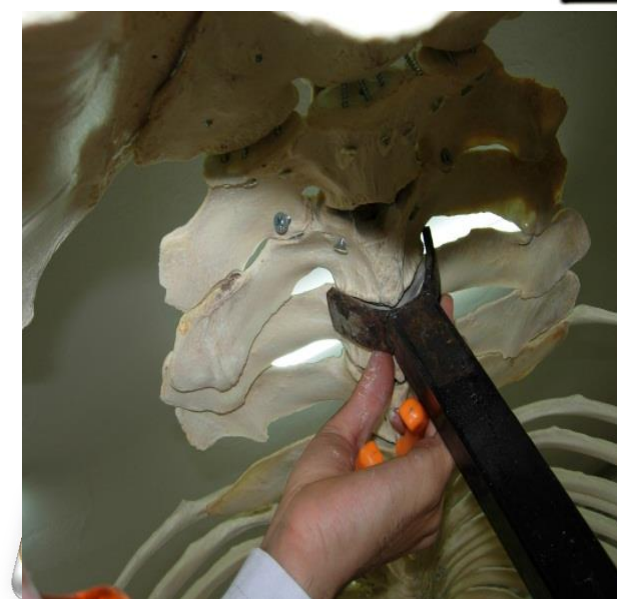
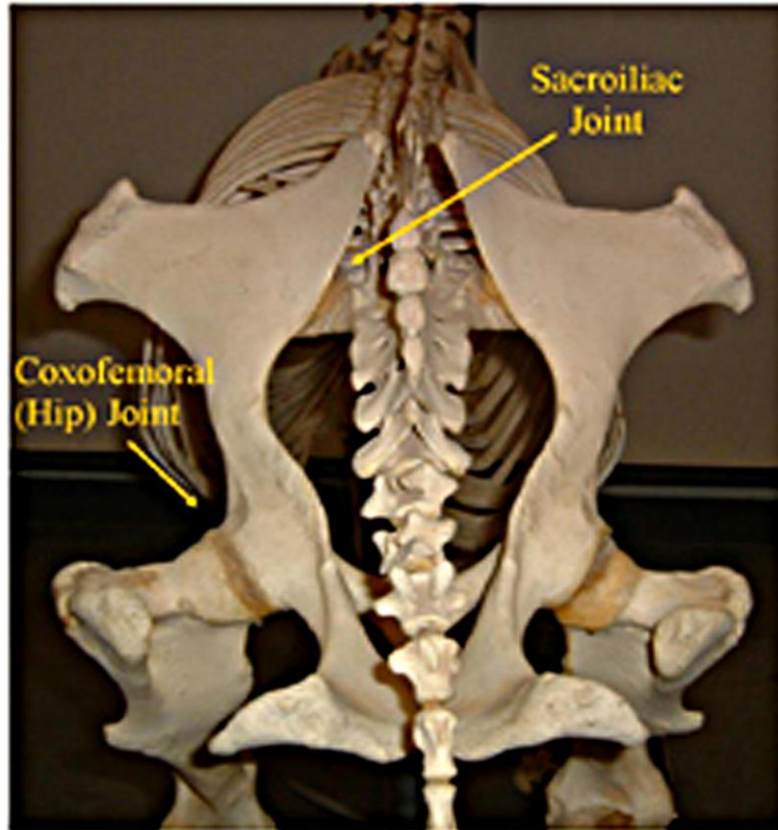


# Montage of Coxal Bone to Vertebral Column

- Imagine the final position and posture of the skeleton and plan the process.
- Touching layers are important. Apply polymax silicone to the auricular surface of coxal and sacral bones.
- Use smart screws as well as polimax for stabilising of coxal bone.
- Before drying period, send 2 to 8 pairs of smart screws through the auricular surfaces.

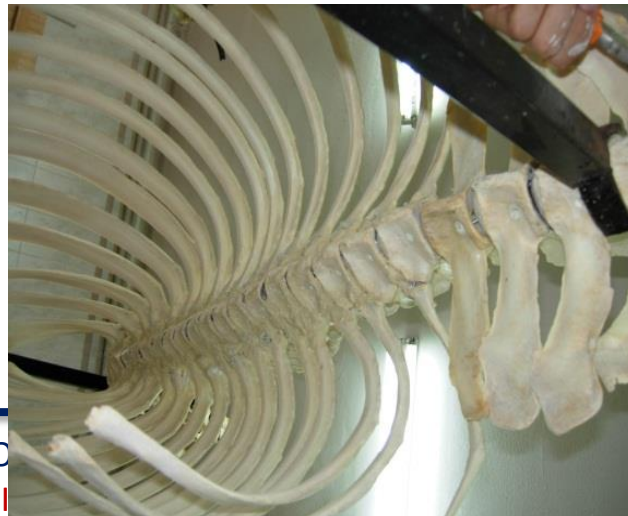





# Montage of Ribs & Sternum to Vertebral Column

- Start form sternum. Open small holes to the costal cartilages of ribs which had been kept together with the sternum previously.
- Open small holes to the distal end of the ribs (os costale) as well.
- Attach the costal bone to the related costal cartilage with a thin wire through these small holes. But don't adhere the parts.
- Now attach this sternal and costal bones to the vertebral column. Use smart screws and polimax to attach the caput and tuberculum of costae to the vertebral column.
- Give an accurate shape and position to sternum and costae.
- Then, use polymax to adhere sternum to costae which were wired each other previously.





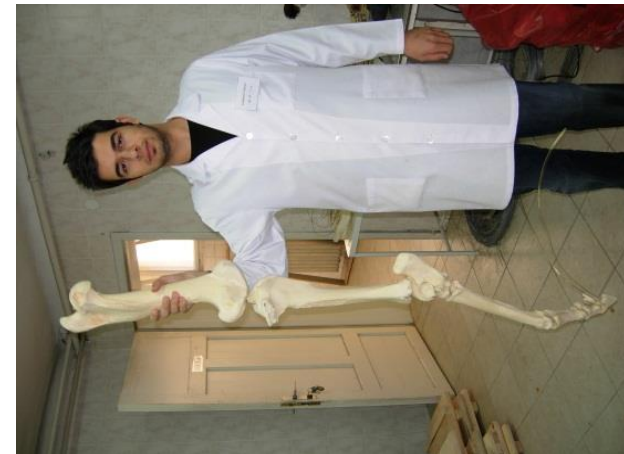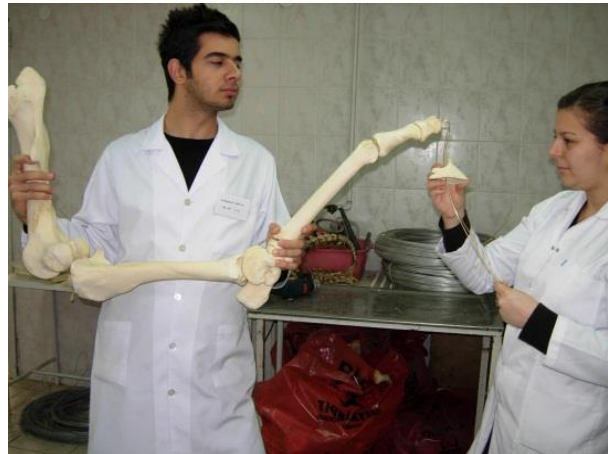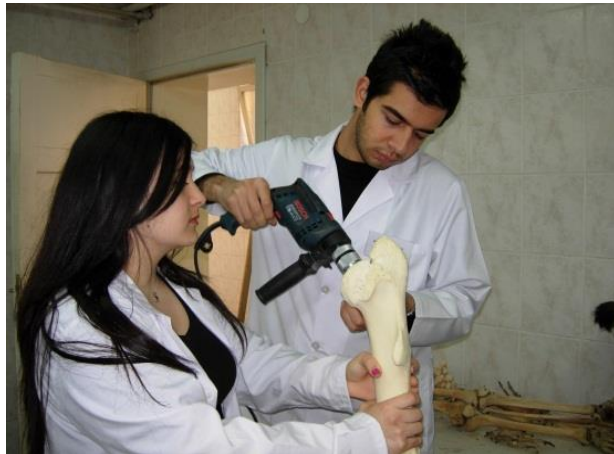---

Assoc.Prof. Okan EKİM

ANKARA UNIVERSITY FACULTY OF VETERINARY MEDICINE DEPARTMENT OF ANATOMY

# Setting Up Front & Hind Limbs

- What will the final posture of the skeleton be?
- Angles and posture of the legs are important. Use various references, illustrations, photos.
- Start from the inner surface of the scapula. Open the first hole to the cavitas glenoidalis of scapula.
- Prepare a wire. Drill the shafts (corpus/body) of entire bones from proximal to distal ends. Pass the wire through the bodies of entire bones till the distal end (facies solaris) of the distal phalanx.



Assoc.Prof. Okan EKİM

ANKARA UNIVERSITY FACULTY OF VETERINARY MEDICINE DEPARTMENT OF ANATOMY

# Setting Up Front & Hind Limbs

- Carpal & tarsal bone groups should be constituted and fused to each other previously and then a central hole can be drilled for the wire.
- For Eq Species → 1 wire, For ruminants → 2, for carnivores → 5 different wires should be passed through.
- Curl up the proximal and distal ends of the wire.
- Give the accurate shape and angles to the limbs. And attach the entire bones with the polymax silicone.
- Smart screws can be used if needed.



# Settling of Skeleton To The Plate

- Measure the final length of skeleton, forelimbs and hindlimbs before the placing of skeleton.
- Then, prepare 2 different metal sticks for vertical holding of entire skeleton in suitable lengths.
- Stabilize the 2 metal sticks to the plate distally.
- Proximal part of these 2 metal sticks should be fused to our central iron stick at the ventral part of the vertebral column.
- Open huge 2 holes at the ventral part of vertebral column and weld the parallel and vertical sticks to each other with a welding machine.
- Assemble the hind limb first. Open a hole to the basis of acetabulum. And pass the wire of hind limb through this hole. And stabilize the hind limbs with silicone and smart screws.



# Settling of Skeleton To The Plate

- Secondly, attach the forelimb to the main skeleton.
- Use polyurethane foam to attach the costal surface of scapula to the ribs.
- Distal contact points of limbs at the plate should be drilled. Therefore the distal end of the wires in the limbs can be passed through this hole.
- This provides extra immobilisation to the limbs and the skeleton as well.



Assoc.Prof. Okan EKİM

ANKARA UNIVERSITY FACULTY OF VETERINARY MEDICINE DEPARTMENT OF ANATOMY

# Exceptions and Special Cases

- For small mammalian and small bird skeletons drilling can harm to the bones. Therefore, use very thin wires or nylon fish lines can be used.
- If can not, use instant but very powerful adhesives.
- Epoxy covering, 2K instant glue, PL600 Montage, Penloc GTI, bostik.



Assoc.Prof. Okan EKİM

ANKARA UNIVERSITY FACULTY OF VETERINARY MEDICINE DEPARTMENT OF ANATOMY



# Conservation, Preservation & Demonstration

- At the end of immobilisation, plate can be covered with resin or colored resin.
- FINALLY, FINALLY, FINALLY! Use a resin to cover and coat the entire surface of the skeleton.
- Bright or opaque resins, parrelloid B52.
- Number 1-2 nolu brush



## 2. Single or Multiple Piece Osseous Specimens

- The procedure is same with the whole body osteological specimens.
- Specimens should be demonstrated on a plate.



# Thank You for Your Attention

DR. OKAN EKİM / 2018



Assoc.Prof. Okan EKİM

ANKARA UNIVERSITY FACULTY OF VETERINARY MEDICINE DEPARTMENT OF ANATOMY