

M. deltoideus

ORİGO:

Pars clavicularis; clavícula'nın 1/3 laterali

pars acromialis; acromion

pars spinalis; spina scapulae

İNSERTİO: **tuberositas deltoidea**

M. Subscapularis

Origo: fossa subscapularis

Insertio: tuberculum minus

M. supraspinatus

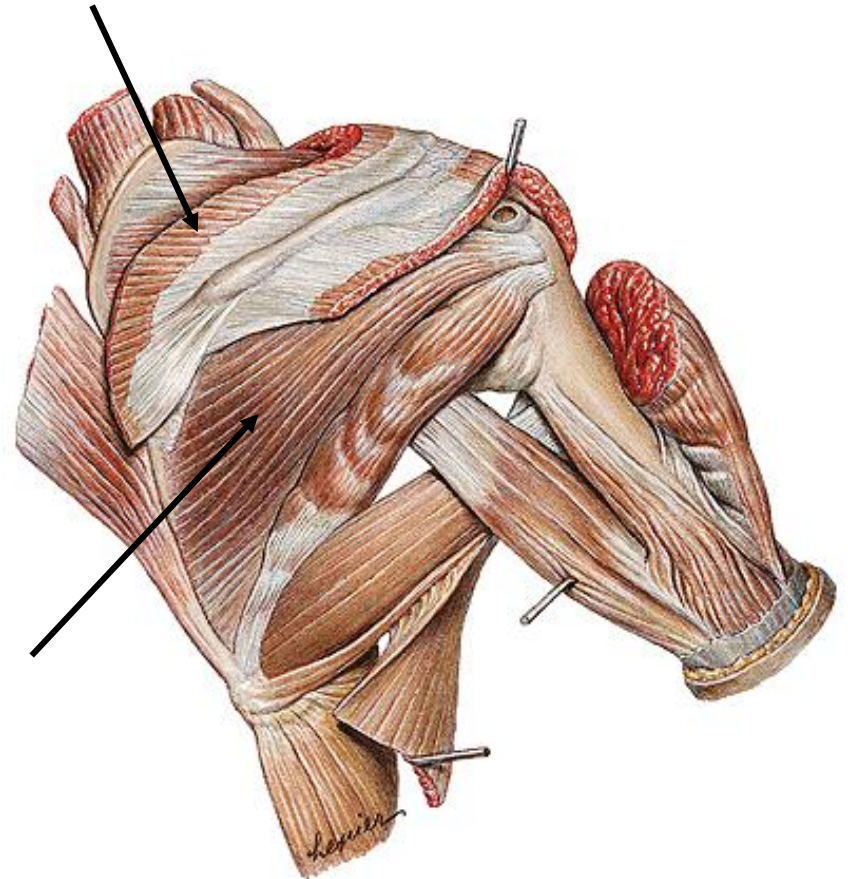
Origo:Fossa supraspinata

Insertio:Tuberculum majus

M. infraspinatus

Origo:Fossa infraspinata

Insertio:Tuberculum majus'un orta kısmı



M. teres minor

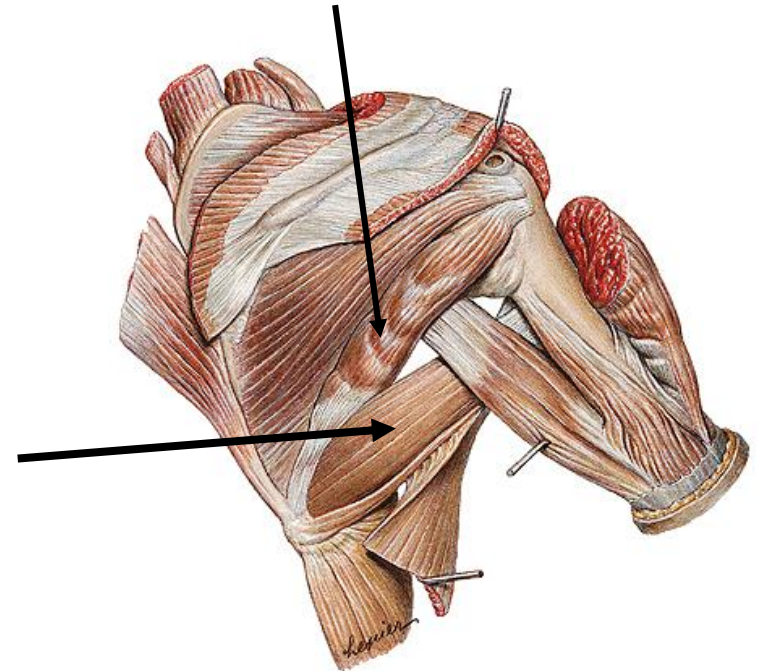
Origo: Skapulanın dış kenarının yukarı kısmından

İnsertio: tuberculum majus

M. teres major

Origo: Scapulanın angulus inferioru

İnsertio: crista tuberculi minoris



Kol kasları

Ön kompartmanda:

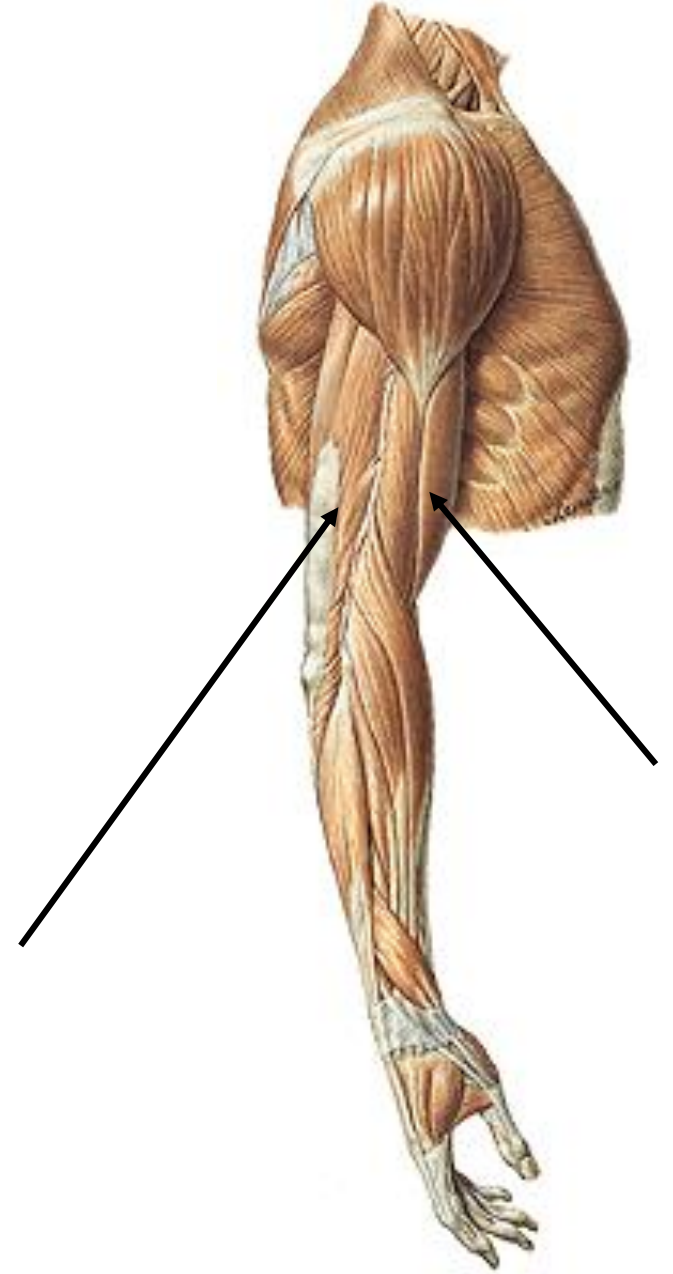
M. biceps brachii,
m. brachialis,
m. coracobrachialis,

n. ulnaris, n. medianus, a. v. brachialis, bulunur.

Arka kompartmanda:

M. triceps brachii,

n. radialis,
a. profunda brachii bulunur.



M. biceps brachii

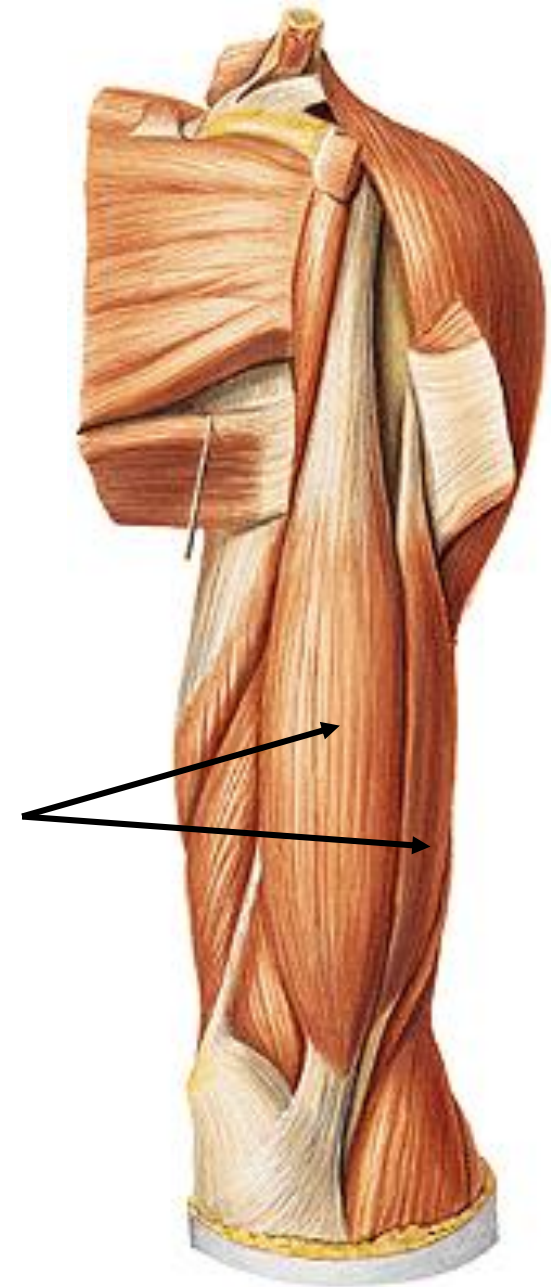
Origo:

Caput longum; tuberculum supraglenoidale

Caput breve; processus coracoideus

Insertio:

tuberositas radii



M. triceps brachii

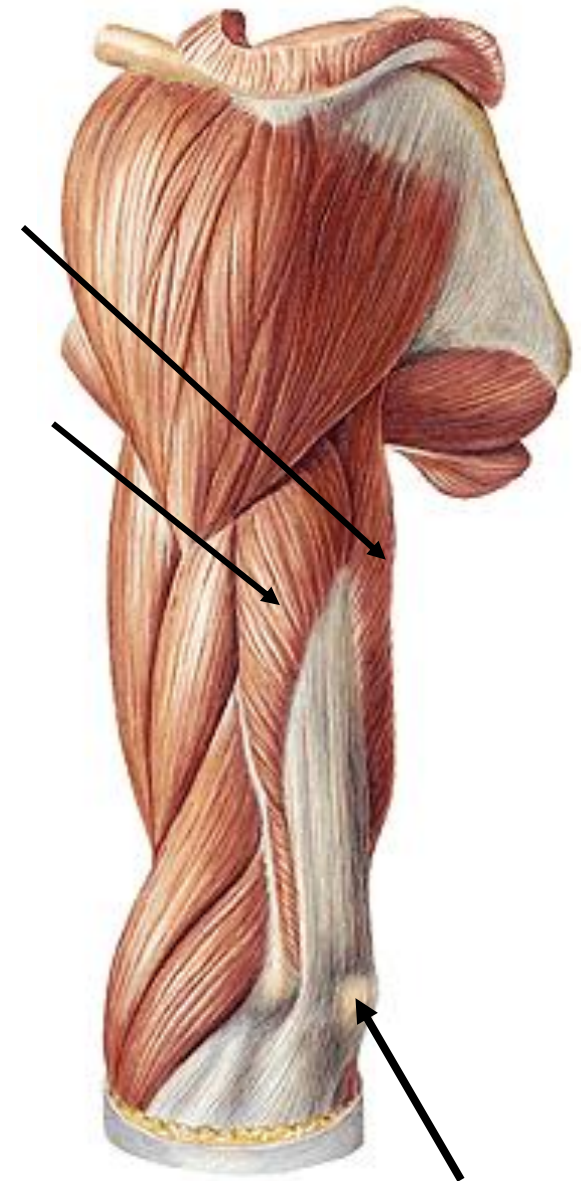
Origo:

Caput longum; humerus'un sulcus nervi radialis'in laterali

Caput laterale; humerus'un sulcus nervi radialis'in laterali

Caput mediale; humerus'un sulcus nervi radialis'in mediali.

Insertio: olecranon



olecranon

Retinaculum flexorum ve extensorum

