

# BASIC SUTURE PATTERNS

---

Dr. Murat ÇALIŞKAN

- The use of a specific suture pattern may vary depending on the area being sutured, the length of the incision, the tension at the suture line, and the specific need for apposition, inversion, or eversion of the tissues.
- Suture patterns can be broadly categorized as interrupted or continuous.

## Commonly employed interrupted suture patterns

- simple interrupted
- cruciate
- figure-of-eight
- interrupted intradermal

# Commonly used continuous suture patterns

- include simple continuous
- continuous intradermal
- Ford interlocking

- Some suture patterns, like the Lembert can be either interrupted or continuous.
- Typically, continuous patterns such as the Cushing , Connell and continuous Lembert are used **when inversion is desired**, but an interrupted pattern such as the interrupted Lembert or Halsted is occasionally used to invert tissue.
- Suture patterns are also categorized in three different groups:
  - appositional,
  - inverting,
  - and tension-relieving sutures.

# Appositional sutures

- Are ideal when there is no excessive tension on the incision, and are commonly used for closure of skin, intestine, and urinary bladder.
- Wound healing will be optimal and scar formation minimized with good apposition of wound edges.

Pattern	Features	Uses
Simple interrupted (Figure 14.2)	Easy to perform. Provides secure closure. Equal tension throughout the wound. Can cause eversion of edges if excessive knot tightening is applied.	Skin, muscle fascia, gastrointestinal tract
Interrupted cruciate and figure-of-eight sutures (Figures 14.3 and 14.4)	Stronger closure compared to simple interrupted. Less skin eversion compared to simple interrupted.	Skin, muscle fascia
Interrupted intradermal (subcuticular) (Figure 14.5)	Deep superficial-superficial deep pattern.	Skin apposition (with buried knots)
Simple continuous (Figure 14.6)	Fast and economical pattern. Leads to air/water tight seals. Knot/suture failure may lead to complete dehiscence.	Subcutis, linea alba, stomach, and small intestine
Continuous intradermal (subcuticular) (Figures 14.7 and 14.8)	Horizontal or vertical pattern. Results in excellent apposition and aesthetics if carefully and correctly applied.	Meticulous skin apposition, especially when skin sutures are not performed
Ford interlocking (Figure 14.9)	Greater security in case of a broken suture (dehiscence usually incomplete).	Skin
Gambee (Figure 14.17)	Modified simple interrupted. Prevents mucosal eversion.	Small intestinal apposition

# Inverting sutures

- are commonly used to close hollow viscera in gastric and urogenital surgery. Inversion decreases exposure of the suture when properly tightened and, therefore, may decrease contamination and adhesion formation.
- The Lembert suture can also be used for fascial imbrications such as done during correction of patellar luxation and for closure of muscle stumps when a limb is amputated.

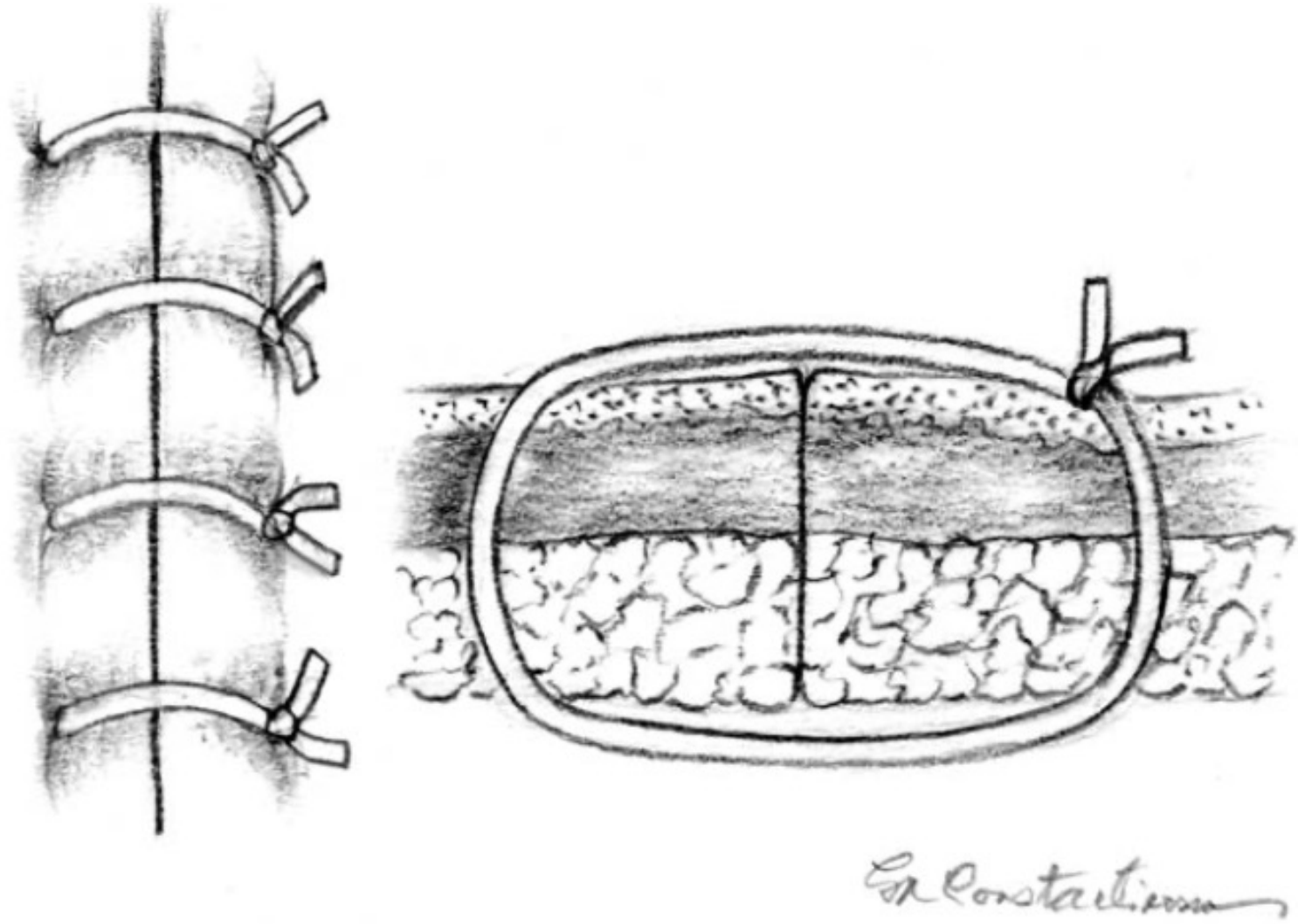


<b>Pattern</b>	<b>Features</b>	<b>Uses</b>
Lembert (Figure 14.10)	Similar to a vertical mattress except it inverts tissue. Interrupted or continuous.	Closure of hollow viscera. Imbrication of fascia.
Cushing (Figure 14.11)	Suture bites parallel to incision. Does not penetrate mucosa.	Closure of hollow viscera.
Connell (Figure 14.12)	Same as Cushing pattern, but penetrates the mucosa.	Closure of hollow viscera.
Halsted (Figure 14.13)	Variation of interrupted Lembert (looks like a combination of Lembert and horizontal mattress that results in tissue inversion).	Fascia imbrication.
Purse-string (Figure 14.18)	Variation of Lembert. Suture bites progress in a circle.	Closure around ostomy tubes. Temporary anal closure to prevent fecal contamination during surgery and to treat rectal prolapse.

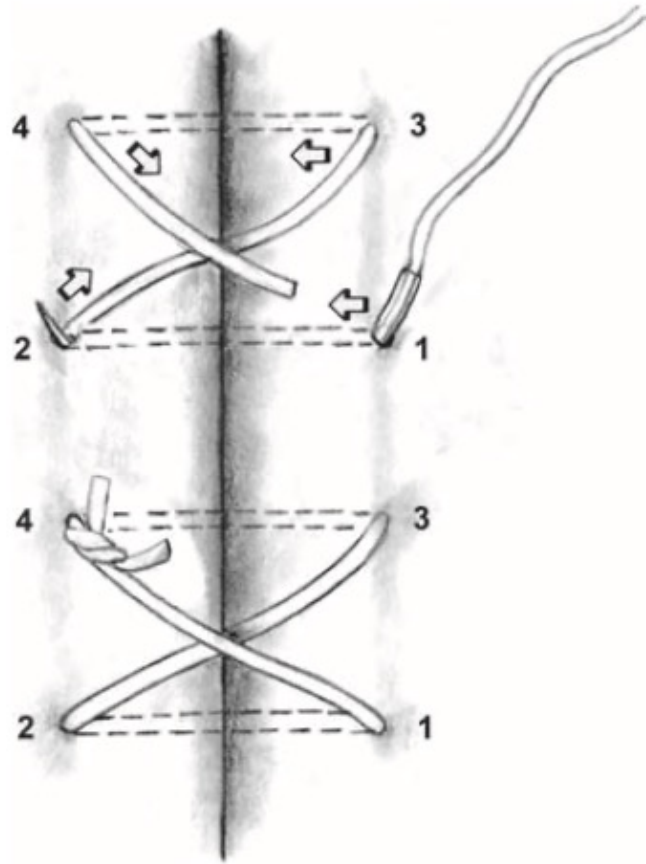
# Tension-relieving suture patterns

- are used to decrease stress on suture lines, such as in reconstructive skin surgery and herniorrhaphy.
- Tension-relieving sutures are also used in tissues where gain of wound strength is protracted, such as in nerves and tendons

Type	Features	Uses
Interrupted vertical mattress (Figure 14.14)	Everting, but can be appositional if carefully placed.	Skin, oral mucosa, and fascia
Horizontal mattress (Figure 14.15)	Everting. Can potentially cause decrease blood supply of the incorporated tissue. Usually interrupted, but can be continuous.	Skin, subcutis, and fascia
Mayo mattress (vest over pants) (Figure 14.16)	Overlaps one tissue edge over the other.	Herniorrhaphy, such as repair of linea alba dehiscence
Near and far variations (Figure 14.19)	May cause eversion. Diminish tension on the wound edges.	Skin and fascia
Walking sutures (Figure 14.20)	Placed in staggered rows. Advance skin edges toward each other.	Closure of large skin defects

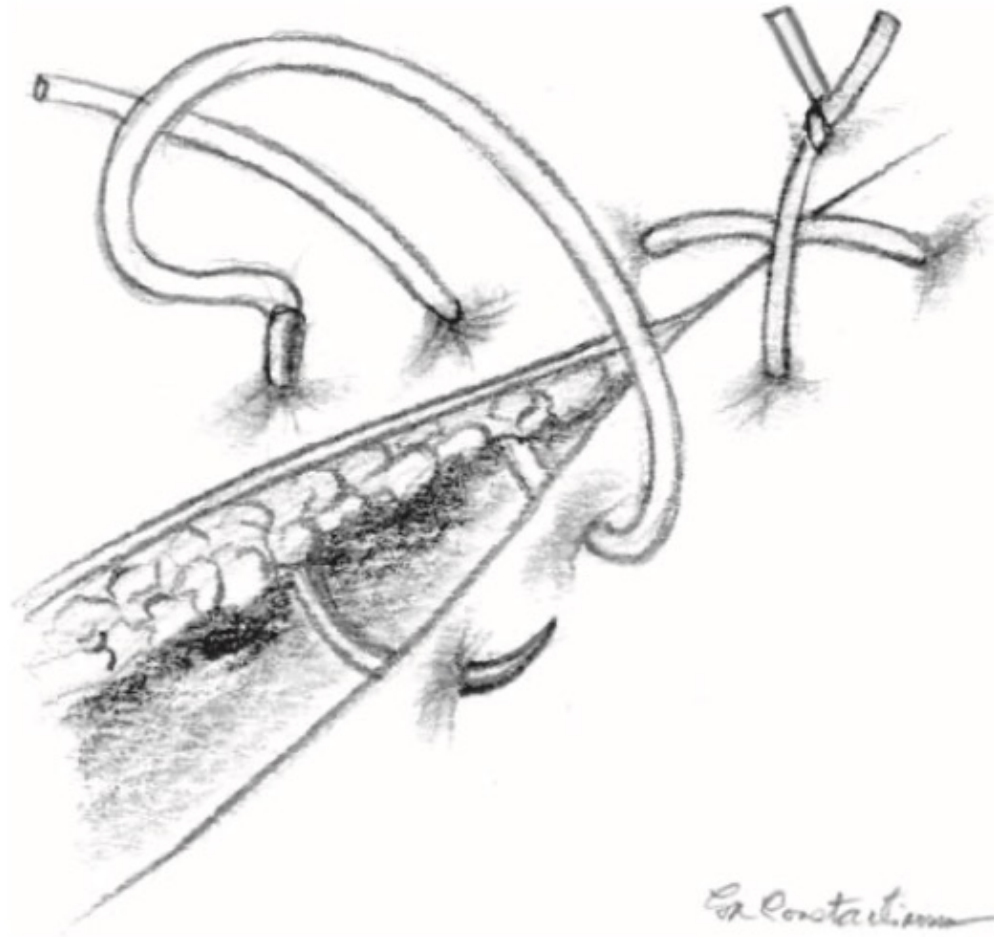


**Figure 14.2** Simple interrupted sutures (skin closure demonstrated).



*Er Constantino*


(a)



*Er Constantino*

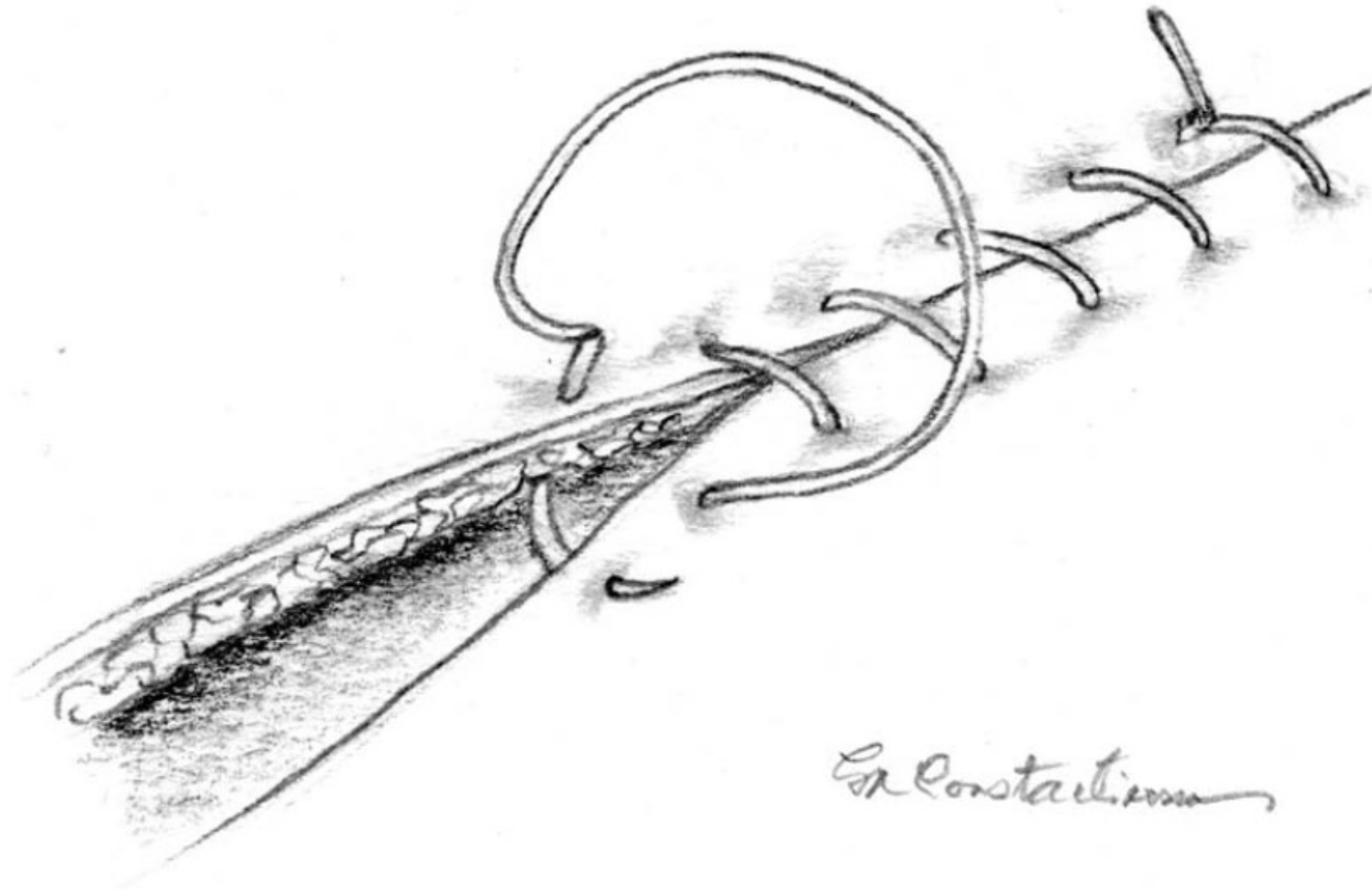
(b)

**Figure 14.3** Cruciate suture (skin closure demonstrated): (a) with and (b) without suture passes numbered.

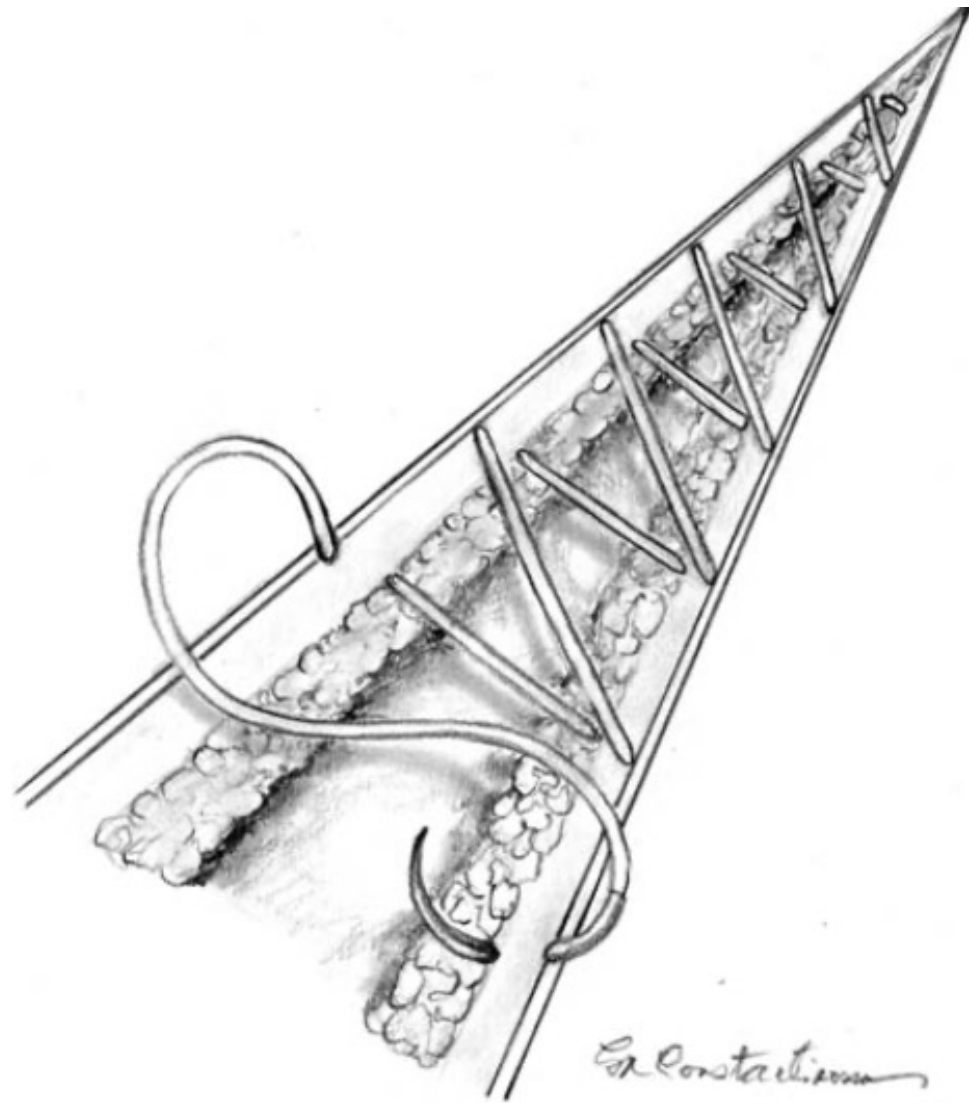


**Figure 14.5** Interrupted intradermal (subcuticular) suture with buried knot.



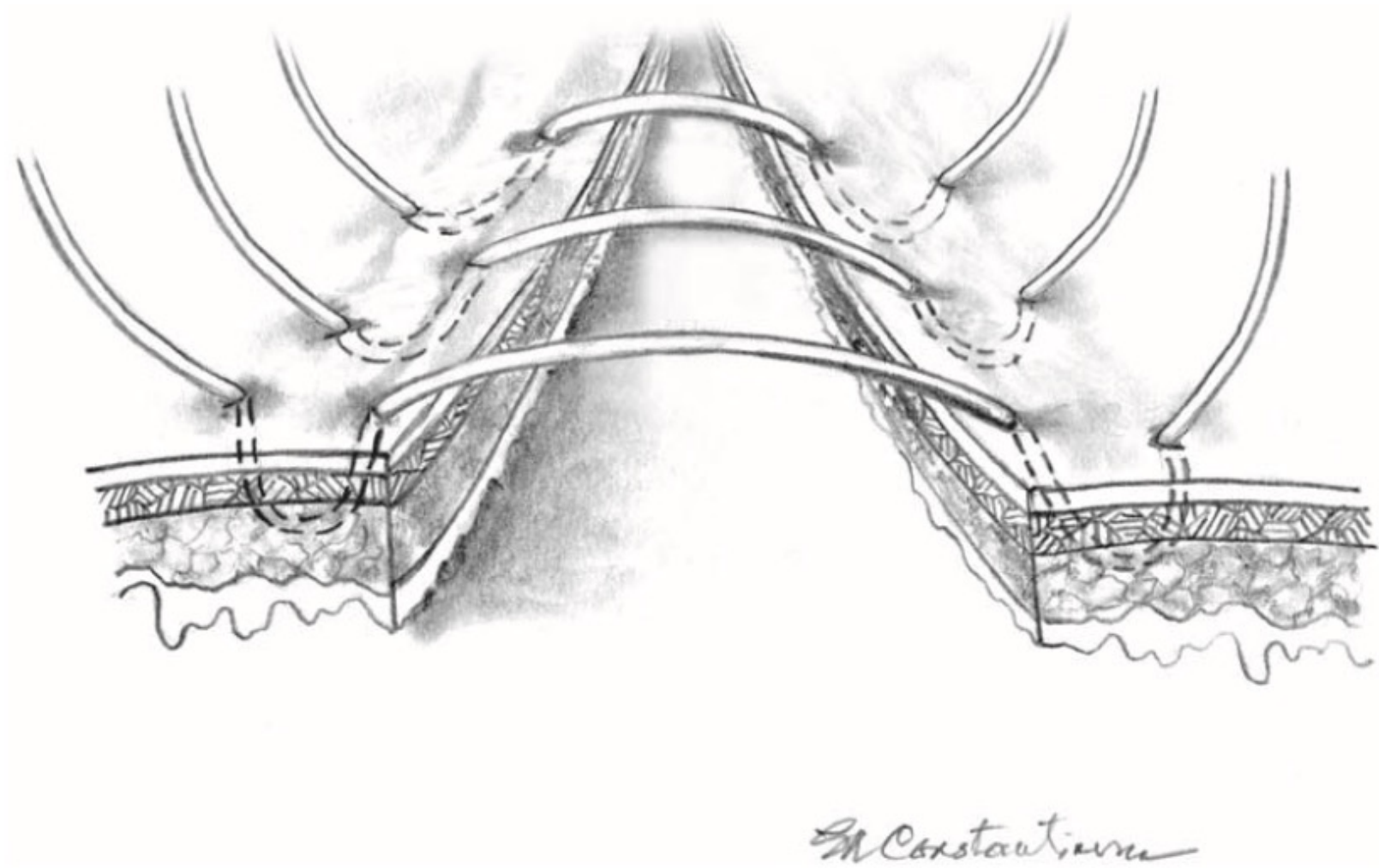


**Figure 14.6** Simple continuous suture pattern. Skin closure is demonstrated; however, this pattern is more commonly used in subcutaneous tissues and for linea alba closure.



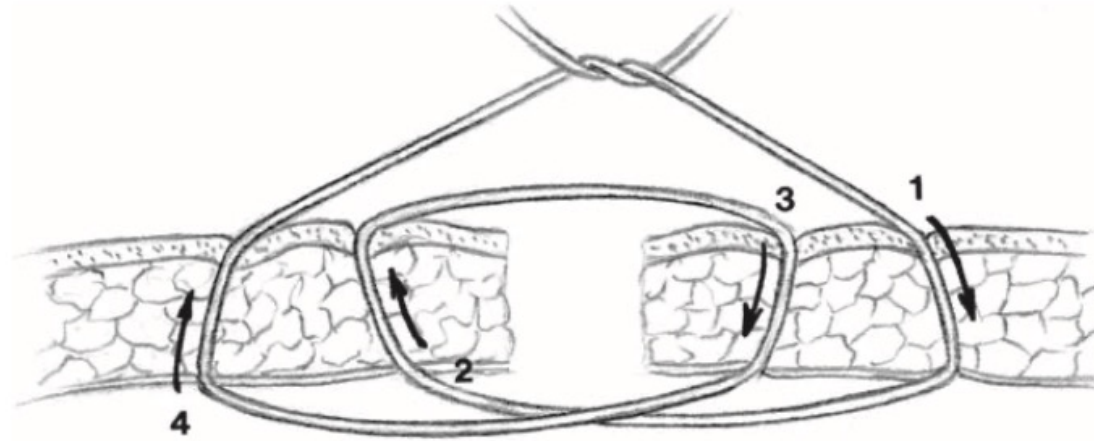
**Figure 14.7** Continuous intradermal (subcuticular) suture pattern with vertical suture bites. The needle enters perpendicular to the skin edge.



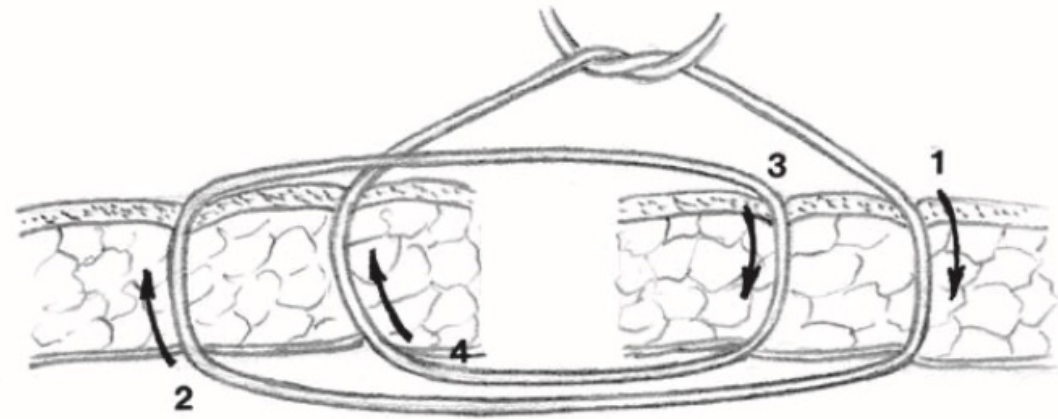


(c)

**Figure 14.10** (Continued) (c) interrupted Lembert suture.



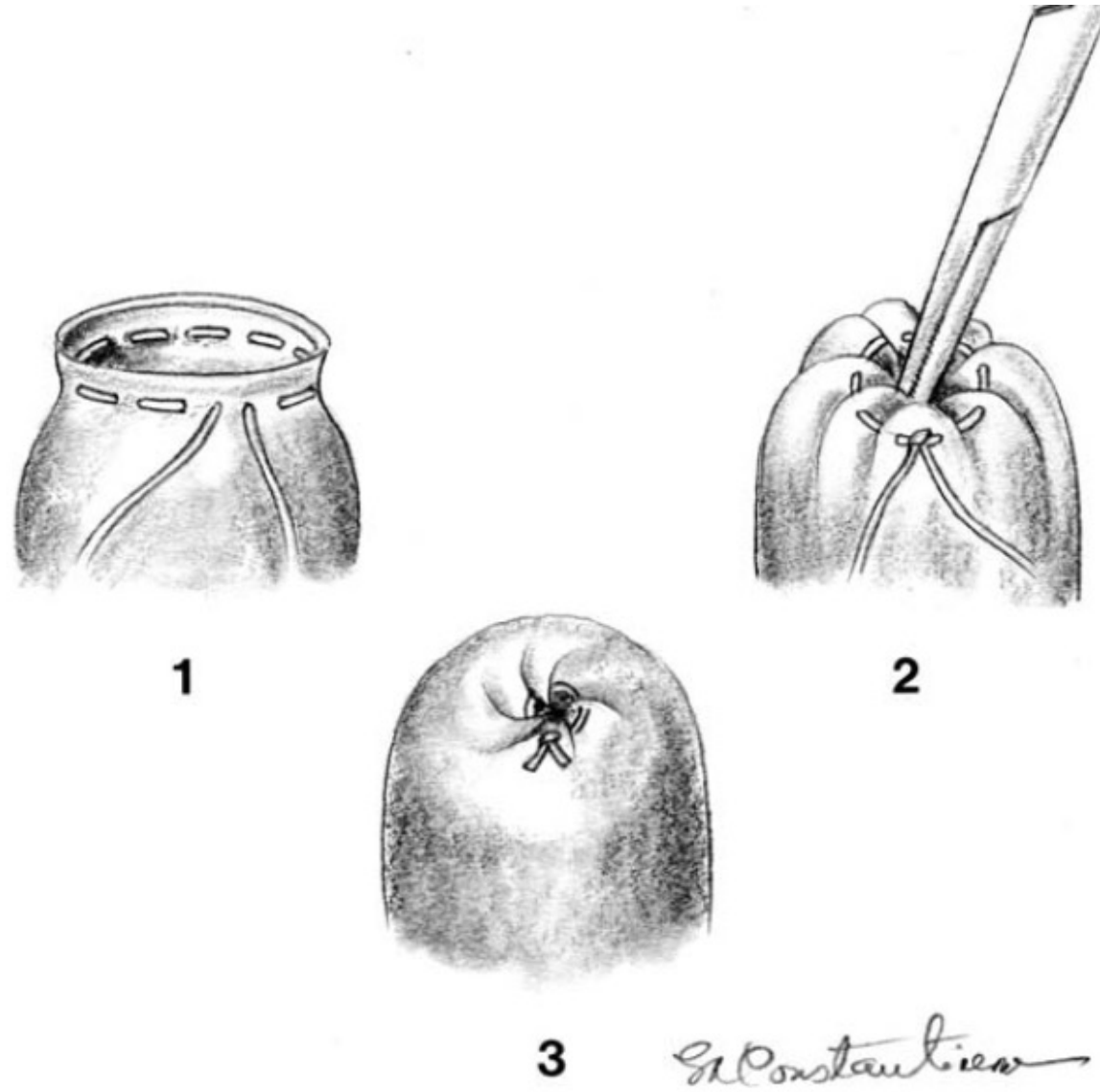
(a)



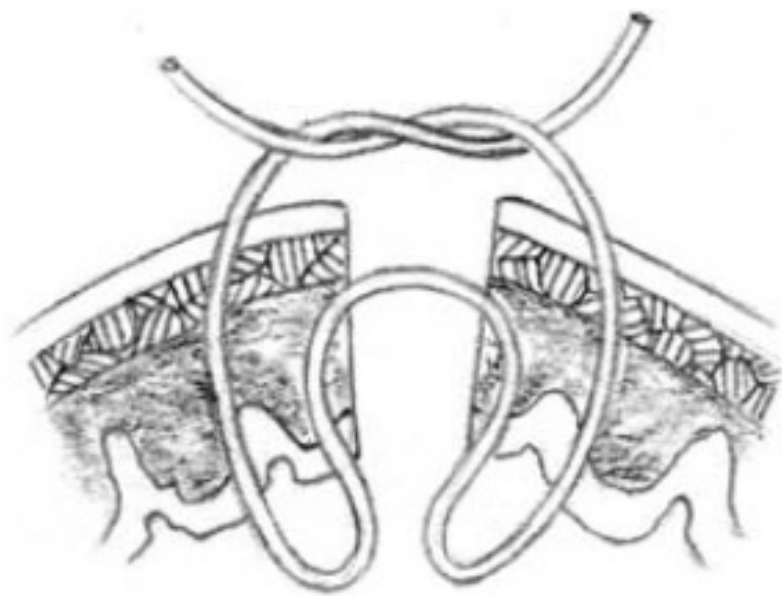
(b)

*Dr. Constanzo*

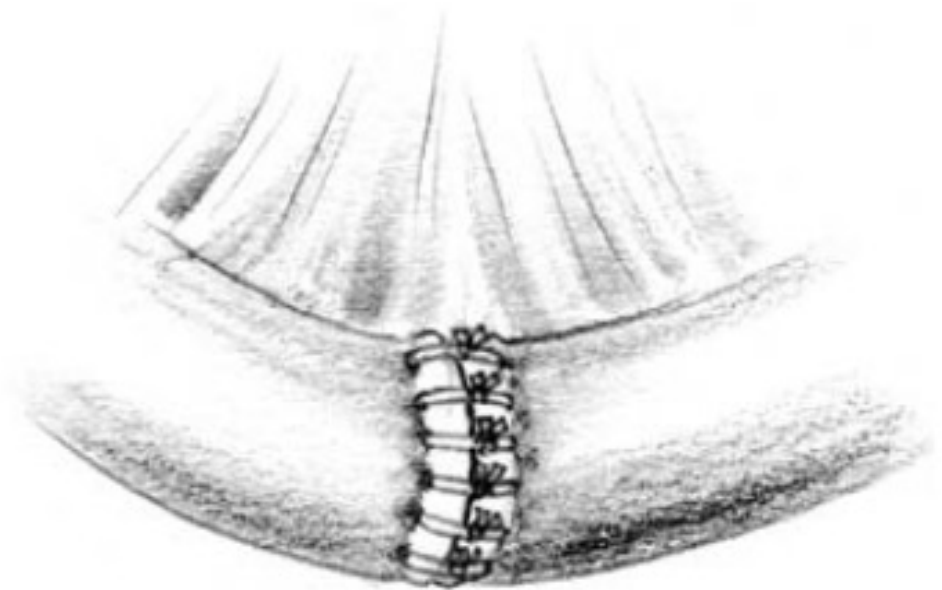
**Figure 14.19** Near and far variations: (a) far-near, near-far and (b) far-far, near-near.



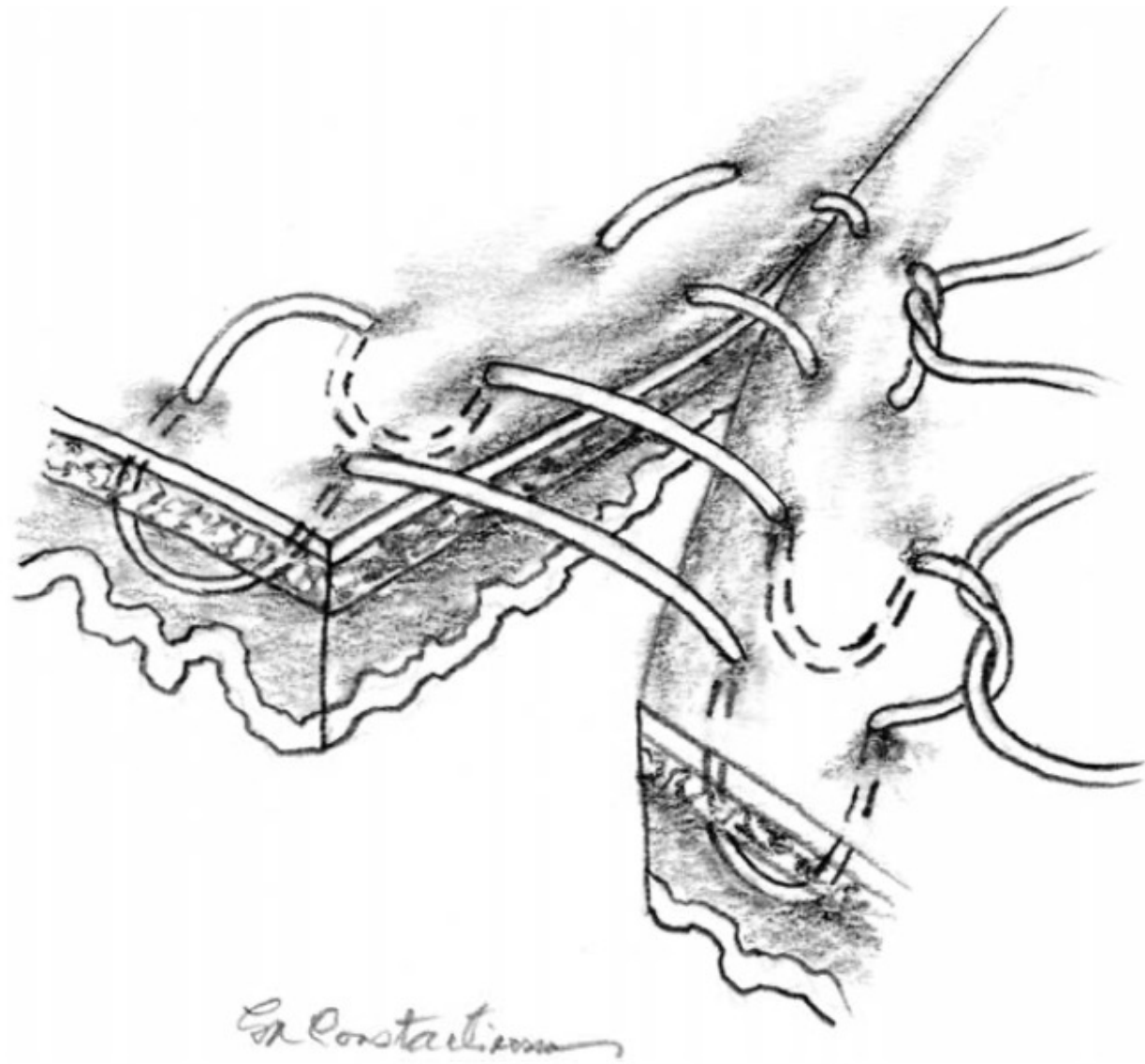
**Figure 14.18** Purse-string suture pattern.



*Dr. Constantine*

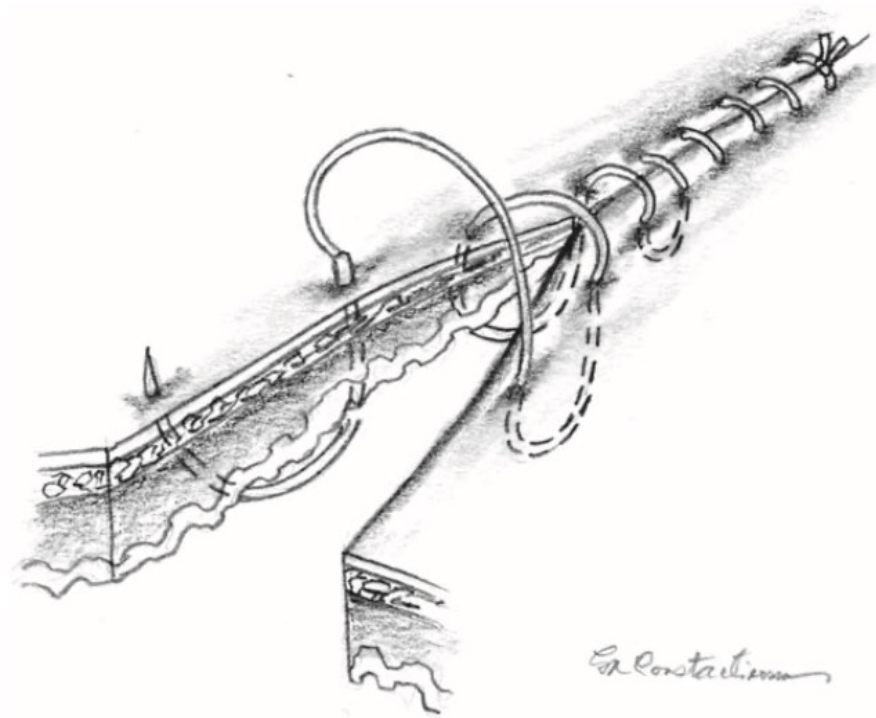


**Figure 14.17** Gambee suture.

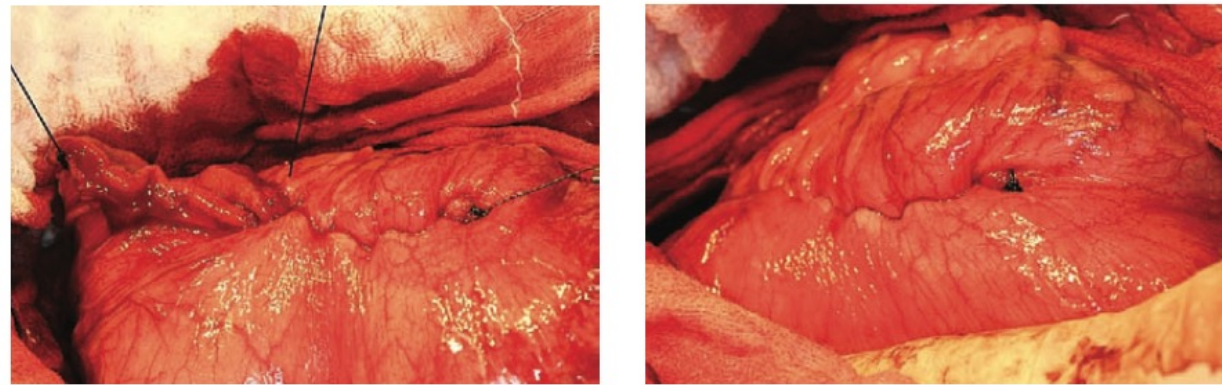


**Figure 14.13** Halsted suture pattern.



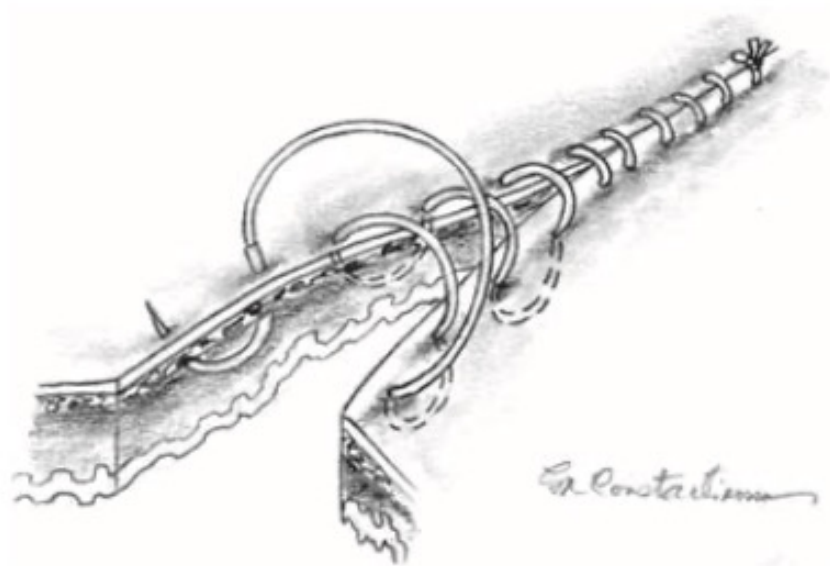


(a)

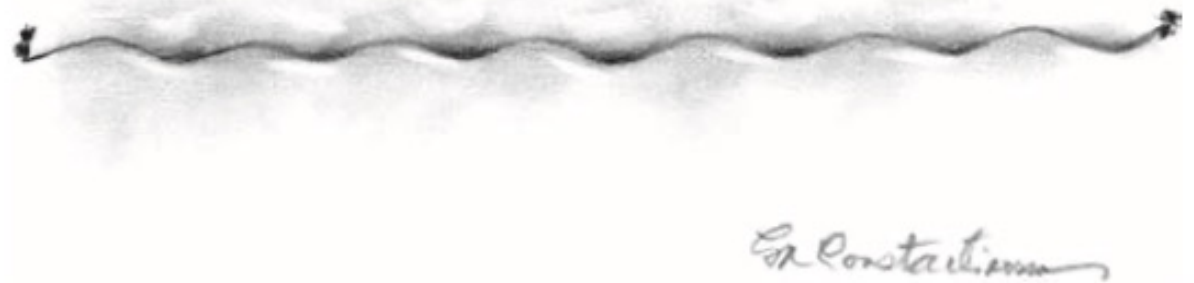

(b)

**Figure 14.12** Connell suture pattern: (a) demonstration of suture passage and (b) final appearance when properly tightened (same as drawing in Figure 14.11b) in a gastrotomy closure. Note the scalloped appearance of the finished product with no suture showing except for the knot at each end (only one end visible, which is to the right in the photograph of the finished product).

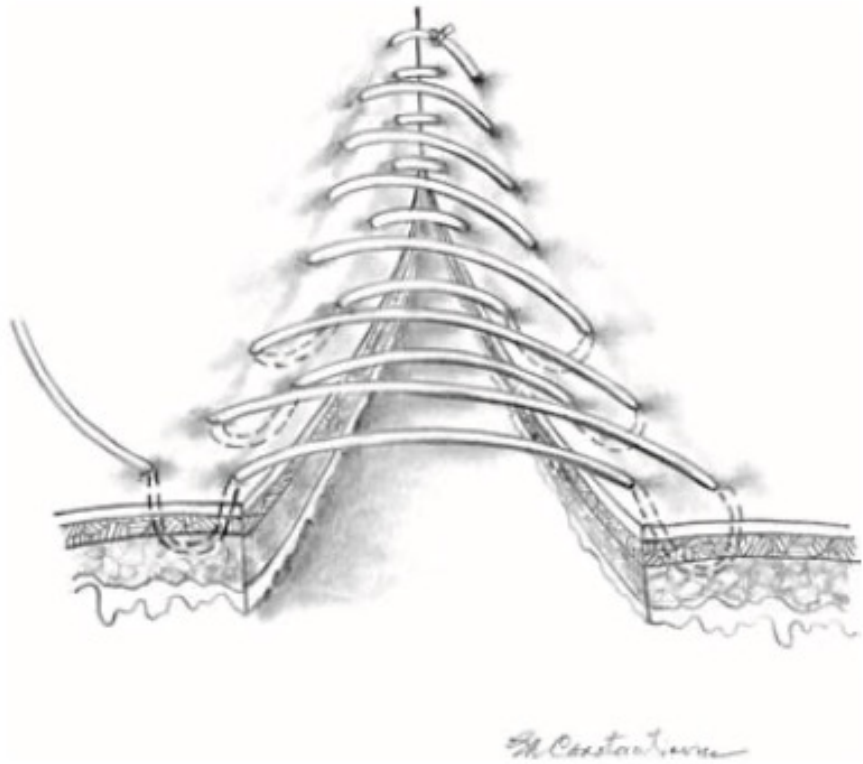

(a)

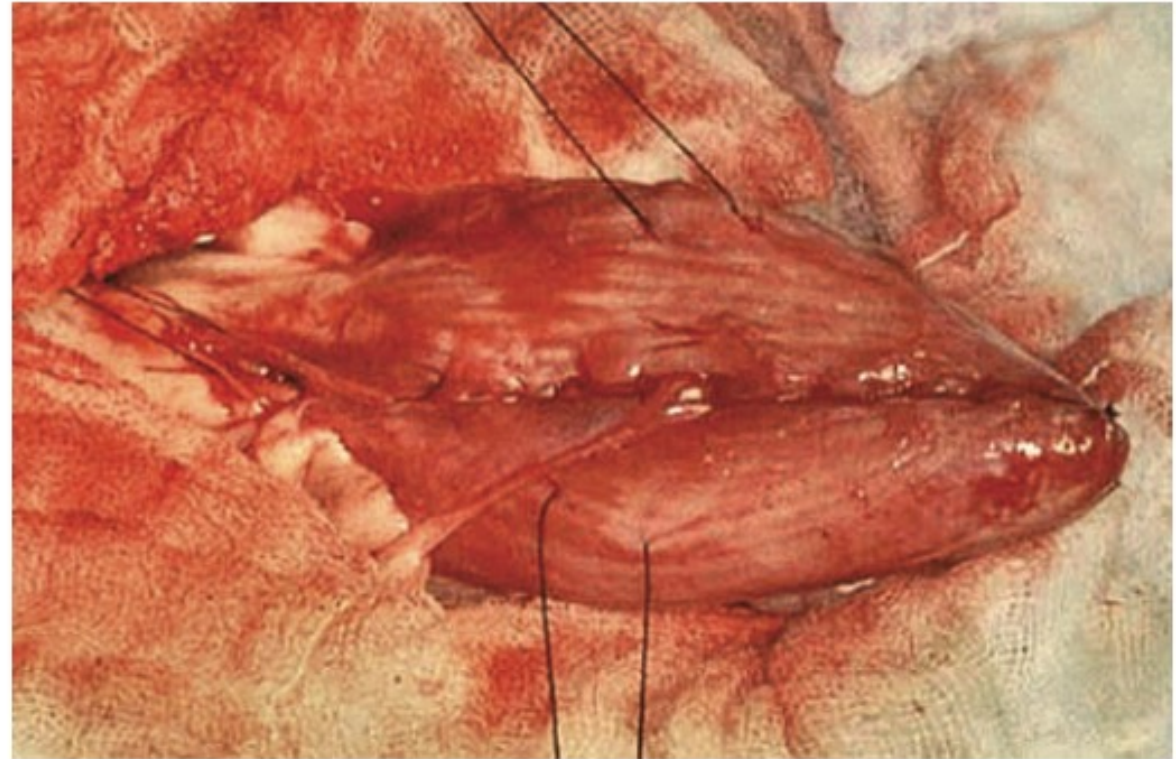


(b)

**Figure 14.11** Cushing suture pattern: (a) demonstration of suture passage and (b) final appearance when properly tightened. Note the scalloped appearance of the finished product with no suture showing except for the knot at each end.



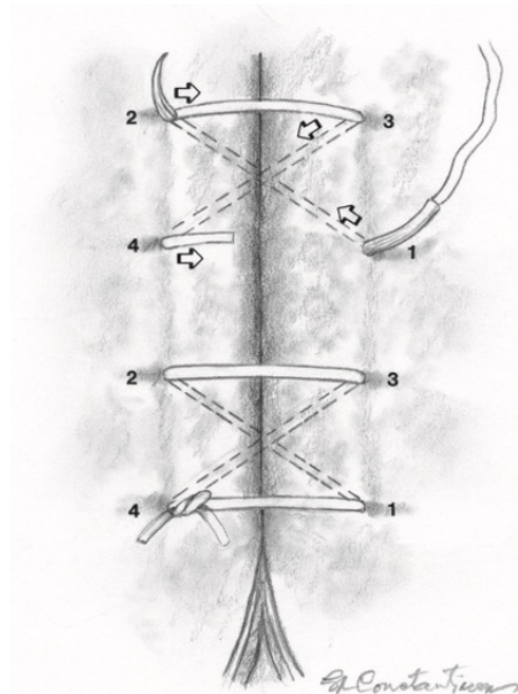
(a)



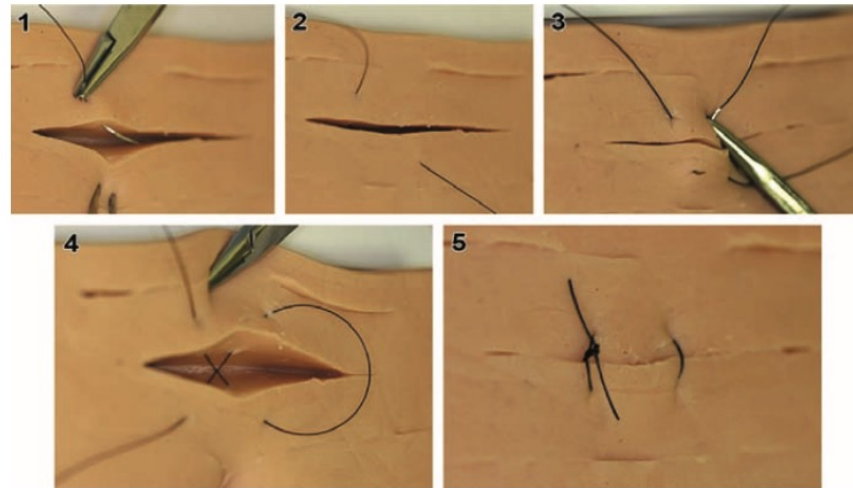
(b)

**Figure 14.10** Lembert suture pattern: (a) continuous pattern, such as for gastric or urinary bladder closure, showing suture passage without the tightening that is usually done with each passage; (b) final appearance of continuous Lembert pattern in a urinary bladder demonstrating how this suture is not readily apparent on the serosal surface when properly tightened; and



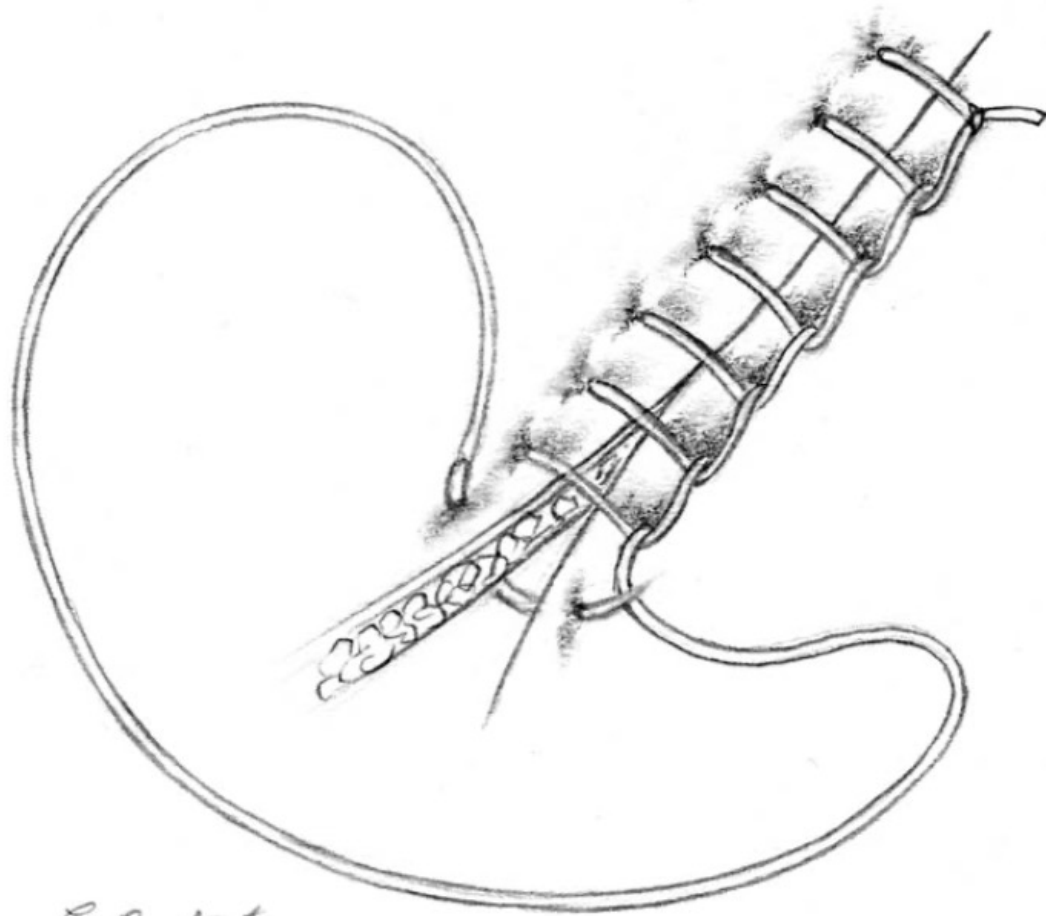


(a)




(b)

**Figure 14.4** Figure-of-eight (upside down cruciate) suture (skin closure demonstrated): (a) with suture passes numbered and (b) with nylon suture on a model. [Note: It is difficult to illustrate proper suture tightness on this model; therefore, this figure-of-eight suture appears tighter than would be desired for ordinary small animal skin incision closure.]



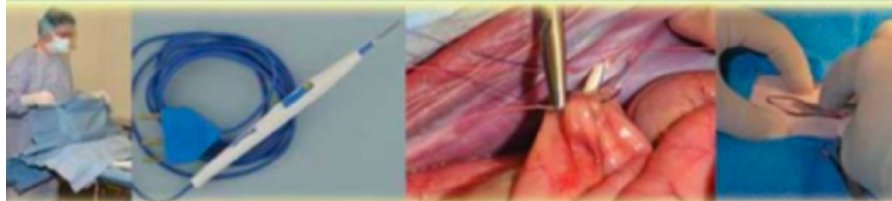
*Dr. Constanzo*

**Figure 14.9** Ford interlocking suture pattern.




**Figure 14.8** Continuous intradermal (subcuticular) suture pattern with horizontal suture bites. The needle enters parallel to the skin edge.

# Fundamentals of Small Animal Surgery



Fred Anthony Mann,  
Gheorghe M. Constantinescu  
and Hun-Young Yoon

 WILEY-BLACKWELL