

Postmortal Decomposition

Asst. Prof. Dr. Arda Selin TUNÇ

Postmortal Decomposition = Autolysis + Putrefaction

Dead things decompose so that they can be used by other organisms.

Dying is an important part of life because when things die, they decompose and return to the earth.

In this way, they can fuel new life by returning the nutrients and molecules in their body to be used again.

Decomposition

- refers to **the break-down of the body following death**. Decomposition is a process of autolysis and putrefaction.
- It is the LAST OF DEATH signs.
- Decomposition starts with melting and disintegration of organs and tissues.
- It ends when the cadaver becomes a skeleton.
- The hallmark of decomposition is **a definite odor**. At room temperature changes associated with decomposition usually become evident after about 24 h, although there may be great variation from case to case.
- Decomposition has two components: **autolysis** and **putrefaction**.

Autolysis and Putrefaction

- In biology, **autolysis**, more commonly known as self-digestion, refers to the destruction of a cell through the action of its own enzymes (“auto” means “self;” “lysis” means “breakdown”).
- It is a sterile process.
- Autolysis is initiated by the cells' **lysosomes releasing digestive enzymes** into the cytoplasm. These enzymes are released due to the cessation of active processes in the cell, not as an active process.
- **Putrefaction**, on the other hand involves overgrowth of microorganisms (especially bacteria and fungi) which feed on and break down the dead tissues.

Autolysis and Putrefaction

- Autolysis and putrefaction are augmented by environmental factors, particularly temperature.
- Warmer temperatures will speed up autolysis and putrefaction, while colder temperatures will slow it down.
- This means that a dead animal left in the heat will autolyze faster than one kept in a refrigerator.
- Similarly, a larger animal will autolyze more quickly than a smaller animal, because the internal body temperature will stay warmer longer than that of a smaller animal with less mass.
- **Sheep and pig develops as faster.**

Autolysis and Putrefaction

- **Animal and insect activities** are other environmental factors that can significantly contribute to the breakdown of the body and enhance the decomposition process.
- Decomp occurs faster in air compared to water.
- Additionally, different tissues inside the body, such as the **liver, pancreas, and intestines**, autolyze more rapidly because they have a greater amount of those self-digesting enzymes.
- **Connective tissue and other mesenchymal tissues** are resistant.
- **Bones** are virtually unaffected by autolysis and maintain their form for many years.

Autolysis and Putrefaction

- After fixation of livor mortis and the loss of rigor mortis the following occur:
- **The skin darkens and develops blisters** with slippage, the tissues soften. The abdomen distends with gas, followed by the scrotum and soft tissues, and reddish decompositional fluids purge from the mouth and nose
- **Insect activity**, particularly involving fly larvae (maggots), may become substantial.
- Decomposition also occurs more quickly at sites of injury.
- Variations in the rate and type of decomposition may occur because of local environmental factors.

Autolysis:

- - Tissue breakdown due to anoxia
- - **Involves no inflammatory responses!!!!**
- The erythrocytes in the vessels are pale and have lost the ability to stain in microscopically.
- If the tissues are rich in mesenchymal tissue or if pathologically, the organ has increase in connective tissue, Autolysis is delayed.
- Therefore, autolysis develops slowly because of connective tissue proliferation in **chronic nephritis**.
- Sheep or pig (**body fat, and amount of hair or wool covering the animal.**)
- **Sudden Death** (due to the fermentative effect of the bacteria in the digestive tract, the temperature of the cadaver increases slightly)
- Autolysis develops quickly due to a disease such as **sunstroke or Clostridial infection**.

- Especially in sheep *Cl.perfringens type D* in infections autolysis develops rapidly. Kidneys softens the gel consistency. The disease is uniformly red.
- “p u l p y kidney “(soft kidney)

- Prenatal treatment also plays a role.
- Therefore, it develops faster and more intensely in the **kidneys of horses** given glucose.

Some lesions
retain their
macroscopic
structure,
although autolysis
occurs!!!!!!

Autolysis (in tissue) in the liver
and myeloid tumor; dog.

<http://w3.vet.cornell.edu/nst/nst.asp?Fun=Display&imgID=7700>

Macroscopic Morphological Appearance

- Pale, whitish gray or dirty pinkish, red in color.
- If the texture is rich in blood, it gets dark blackish color.
- Its consistency is soft and crisp. In the advanced state it becomes slurry (especially liver, kidney, intestines).
- If there is a smell, there is a foul odor.

Macroscopic Morphological Appearance

- The muscles are pale red half-cooked.
- Esophagus, gastric mucosa in the later stage (malacie, melting).
- Peyer plaques take the view of the griddle. This is called “status cribrosus.
- The liver and kidney are broken down when pressed with a finger.

Why is Autolysis important?

- **It shows how long it has passed since death.**
- It is also an important criterion in **determining whether samples** (especially microbiological and histological samples) **should be taken.**
- The most important is that: **Advanced autolysis camouflages pathomorphological changes (lesion) and makes it difficult to detect.**
- **Especially necrosis and degeneration** (parenchyma and oily degeneration) is mixed with autolysis!

THE FORMATION OF AUTOLYSIS IS SIMILAR TO NECROSIS!

- **DIFFERENCE FROM NECROSIS**; Necrosis is focal; normal and necrosis tissues are side by side.
- There are reactions such as hyperemia and edema.
- There is from the beginning.
- That is also seen in fresh cadavers.
- Therefore, other advanced postmortal findings, such as stinking/putrefaction, have not yet developed!

The formation of autolysis is similar to necrosis!

- DIFFERENCE FROM NECROSIS; Autolysis is shaped over time. All tissues lose their structure.
- However, because each tissue has different resistance, it does not occur at all at the same time.
- In particular, this may cause confusion with necrosis in the late opened cadaver.
- **Microscopic Difference**
- In autolysis, there is no reaction other than the disintegration and dissolution of the tissue.
- There are other morphological changes in necrosis.
- There is a vascular and cellular reaction (exudation cell infiltration et al.) In the necrotic region; Regeneration or changes in the organization (granulation tissue) during the recovery period are the main ones.

Putrefaction:

- - Dead tissue is invaded by anaerobic saprophytic bacteria (from gut)
- - Digestion of tissue proteins with gas formation
- - foul smelling substances: hydrogen sulphide, indole, skatole
- - Tissue turns green, brown, or black
- - Most bacteria are anaerobes and include the Clostridia group of organisms (found in large intestine)
- - they attack proteins, fat and carbs
- - they break down into simpler substances with unpleasant odour

- Hydrogen sulphide - responsible for colour and smell
- Pseudomelanosis - green/blackish tissue discolour due to Ferrous Sulphide

Putrefaction:

- *Bacillus putrificus*, *Bacteria pyocyaneus*, *Bacterium prodigiosa*, *Proteus spp.* and *Bacterium fluorescens* are the most important decomposition bacteria.
- Some putrefaction bacteria are present in the intestine and the surface of the skin and mucosa in the intravital period.
- They spread to the organism, especially during intestines.
- It is pushed into the blood and lymph vessels with the pressure formed as a result of postmortal tympani; they go to distant tissues again under the effect of this pressure.
- This event is called “**posthium circulation**.”

Mummification and adipocere
are two special factors
and
prevent putrefaction.

Mummification:

- - in dry conditions the carcass will desiccate
- - skin and tissue become hard and leathery
- - mould may form patches on the eye
- - dryness will inhibit bacterial growth.
- It is characterized by dryness and brittle, torn skin on the prominences (cheeks, forehead, sides of the back, and hips), generally brown in color, though coexisting with white, green, or black zones because of colonization by fungus, just as leather jackets look after they have been left for some time in a musty wardrobe and start to become mildewed.

Adipocere

- a waxy substance consisting chiefly of fatty acids and calcium soaps that is formed during decomposition of dead body fat in moist or wet anaerobic conditions.
- comes from the combination of Latin adipo- (fat) and cera (wax)
- the cadaver is kept in a humid environment, not dry.
- It occurs in Cadaver ;
- if under the snow long time
- if remain in water,
- if buried in moist clay soil (environment is alkaline, lime-rich) or
- if the cadaver is greasy

Adipocere

- This produces a waxy, fatty substance that is brittle; in color, it is yellowish off-white, although when stained by decayed matter or blood, may acquire reddish, grayish, or gray-green tones.
- It also gives off a characteristic “**earthy, cheesy, and ammoniacal**” odor.

- Mumification and adiposir can be formed in the entire cadaver as well as in some parts.
- Thanks to these two postmortal changes, it maintains the cadaver form partially for a long time.
- Distinction of tissues and organs; Macroscopic description of pathological changes such as wound, scar, tumor can be done after many years

Signs of Putrefaction

- **1-Postmortal gas formation:** The decomposition of organic substances by the effect of decomposition bacteria, hydrogen sulfide, ammonia, methane (CH₄), nitrogen (N₂), hydrogen (H₂), the release of gases such as the tissue, organ and cavities of the cadaver is collected.
- a-Postmortal emphysema
- b-Postmortal tympanie

Signs of Putrefaction

- **a-Postmortal emphysema**: The gases released in advanced rotting are generally formed by the collection in the subcutaneous tissue in the shoulder, neck, hip and waist area.
- These areas are **puffy**.
- It gives a **crunchy sound on palpation**.
- When **the section is cut, a greenish, stinky and foamy liquid comes out of it**.
- Although similar findings are formed subcutaneous and muscles, this is local and is also found in fresh cadavers **in blackleg**.

Putrefaction emphysema

- **Collection of gas** in parenchymatous organs and loose tissues.
- It is the **foamy appearance** of the organ.

Signs of Putrefaction

- b-Postmortal tympanie:
- It is the accumulation of gas in the stomach and intestines as a result of decomposition.
- It should be separated from intravital tympanic .

Signs of Putrefaction

2- Odor of the decomposition: It is caused by decomposition of tissues and cells as a result of decomposition and autolysis and the spread of partially toxic products such as ptomaine, putrescine, tyramine and especially cadaverine from the cadaver environment due to the destruction of proteins.

3-Blood breakdown: During the decomposition, various bacteria pass into the blood, causing the blood to become completely **hemolysed and foamy**. Meanwhile, the intima layer of the veins is stained in dirty red (blood imbibition).

Signs of Putrefaction

4-Rupture, prolapse and displacement of the gastrointestinal tract:

Postmortem Rectal prolapse:

- It is shaped by pushing the anus outward with the pressure of excessively collected gas.
- There are no intravital changes such as necrosis or inflammatory reaction in the prolapse.

Signs of Putrefaction

4-Rupture, prolapse and displacement of the gastrointestinal tract:

Postmortem rupture:

- The result of excessive tympani is rupture of the stomach (rumen in ruminants) and intestines.
- Stomach ruptures usually occur along the large curvatura.
- The edges of the ruptured area are flat, not fragmented.
- There is no inflammatory reaction at the edges.
- The content does not spread as if sprayed into the abdominal cavity; localized in the vicinity of the ruptured area.
- Septic peritonitis does not occur.

- Postmortem invagination, volvulus, torsion:

Postmortal torsion and rotation are formed especially during the transportation of the cadaver.

It is mostly encountered in horses.

It occurs when columns filled with gas shift upwards, and those filled with stool (especially in aqueous consistency) to the ventral.

Postmortal invagination

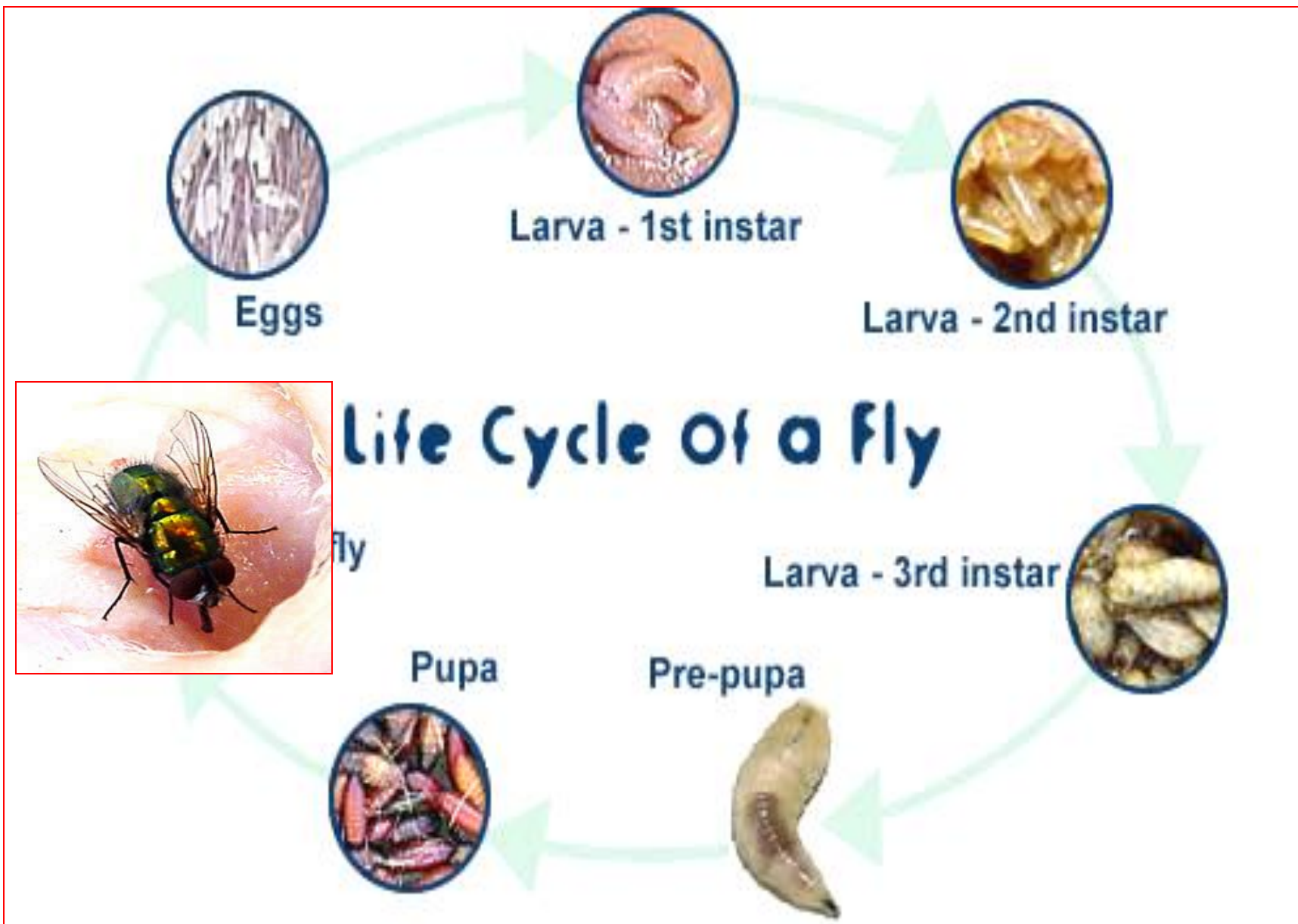
In the period following death, intestinal peristalsis does not stop and usually occurs due to the effect of severe rigor mortis. Stomach torsion; dog

The absence of hyperemia, edema and necrosis in such displacements and postmortal prolapse helps to distinguish them from intravital ones.

Signs of Putrefaction

5-Insects: Shortly after death, fly larvae (worms of flesh or wound flies) invade the cadaver. These flies are bright and have characteristic color.

- - Bluebottles and flies
- - maggots, the larval stage are most active tissue consumers
- - eggs laid on lips, nostrils or genitals
- - maggots develop ~ day
- - secrete digestive fluid that softens tissue.

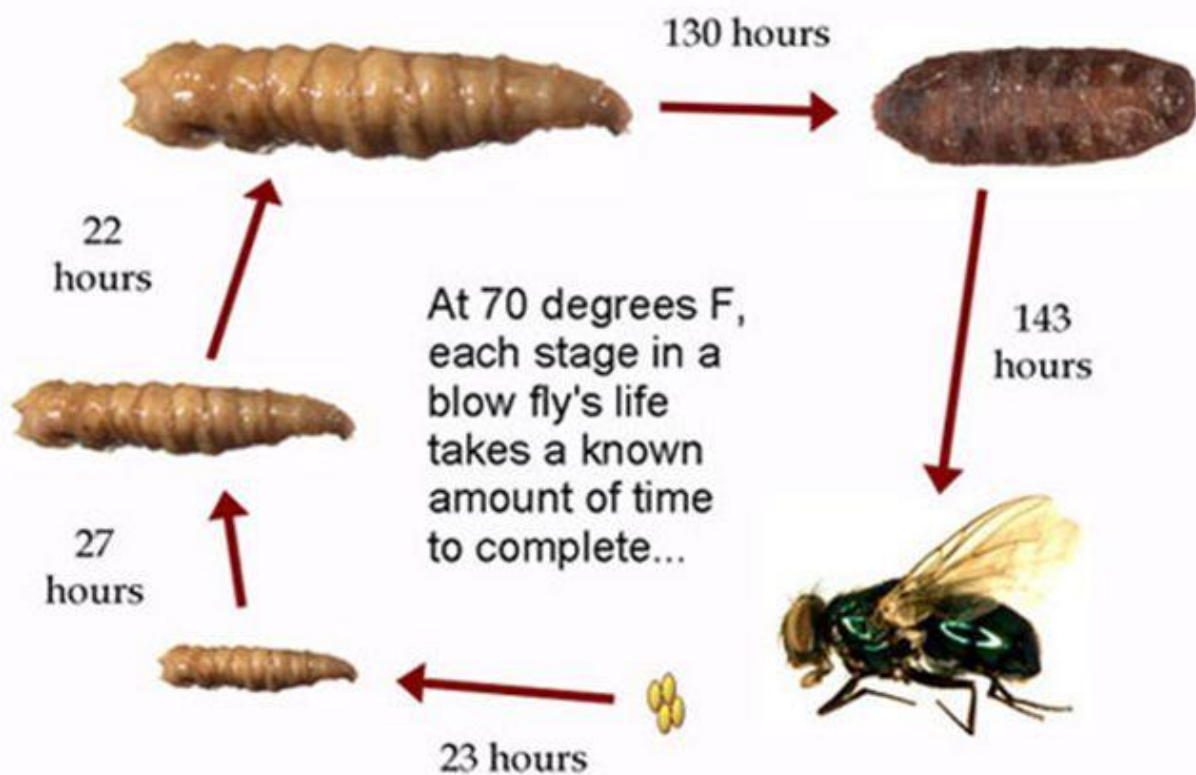


Sheep Blowfly *Lucilia sericata*. Photo: R. Major

<http://www.deathonline.net/decomposition/forensic/timing.htm>

Entomology

The blow fly life cycle has six parts: the egg, three larval stages, the pupa, and adult.



- **3 larval stages:**
 - 1st instar**
 - 2nd instar**
 - 3rd instar**

Signs of Putrefaction

- **Predators:**

- - birds peck out eyes
- - Dogs, cats, foxes, badgers, rats eat around body orifices
- - wounds are clean cut
- - no bleeding or inflamed margins