

# Respiratory Tract Disorders in Dogs and Cats



*Assoc. Prof. Ekrem Çağatay ÇOLAKOĞLU*  
*Ankara University Faculty of Veterinary Medicine*  
*Small Animal Hospital*  
*Department of Internal Medicine, Cardiology Unit*

*colakoglu@ankara.edu.tr*  
*<http://cv.ankara.edu.tr/colakoglu@ankara.edu.tr&deger=1>*  
*[www.veterinary.ankara.edu.tr](http://www.veterinary.ankara.edu.tr)*



# Goals of 5 weeks

- First 2 weeks
  - Heart disease
  - *Respiratory tract*
- Following 2 weeks
  - Hematological disease
  - Systemic infections
- Last week
  - Other remarkable notes



SIXTH EDITION

# Small Animal Internal Medicine



RICHARD W. NELSON C. GUILLERMO COUTO

Kristen M. Couto  
Eleanor C. Hawkins  
Susan M. Taylor  
Jodi L. Westropp

Autumn P. Davidson  
Michael R. Lappin  
Jessica L. Ward  
Michael D. Willard

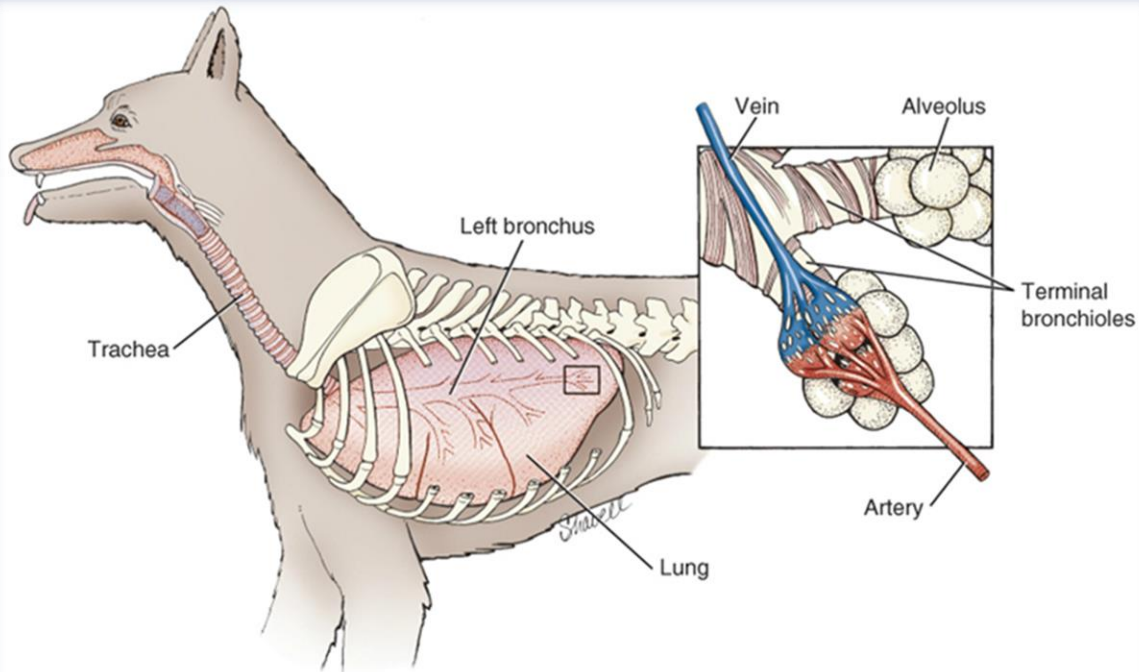
Ann-Marie Della Maggiore  
Jennifer A. Larsen  
Wendy A. Ware  
Andrew Woolcock

Stephen P. DiBartola  
J. Catharine R. Scott-Moncrieff  
Penny J. Watson

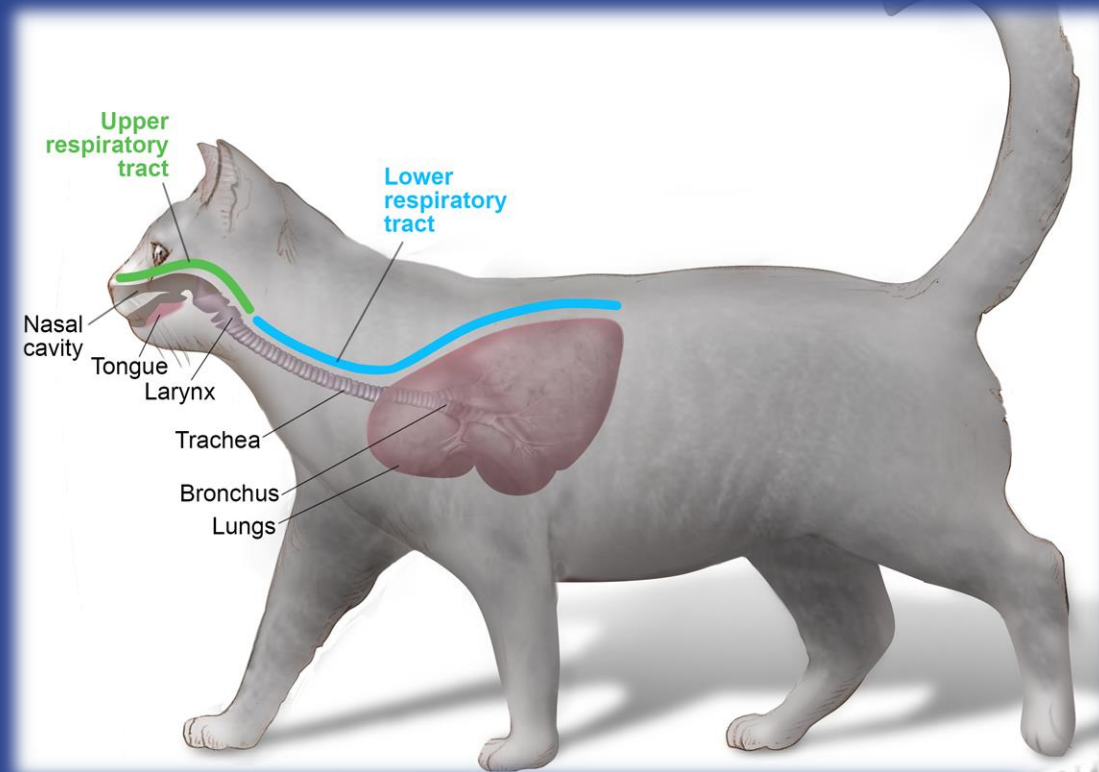
ELSEVIER



# Respiratory Tract Anatomy

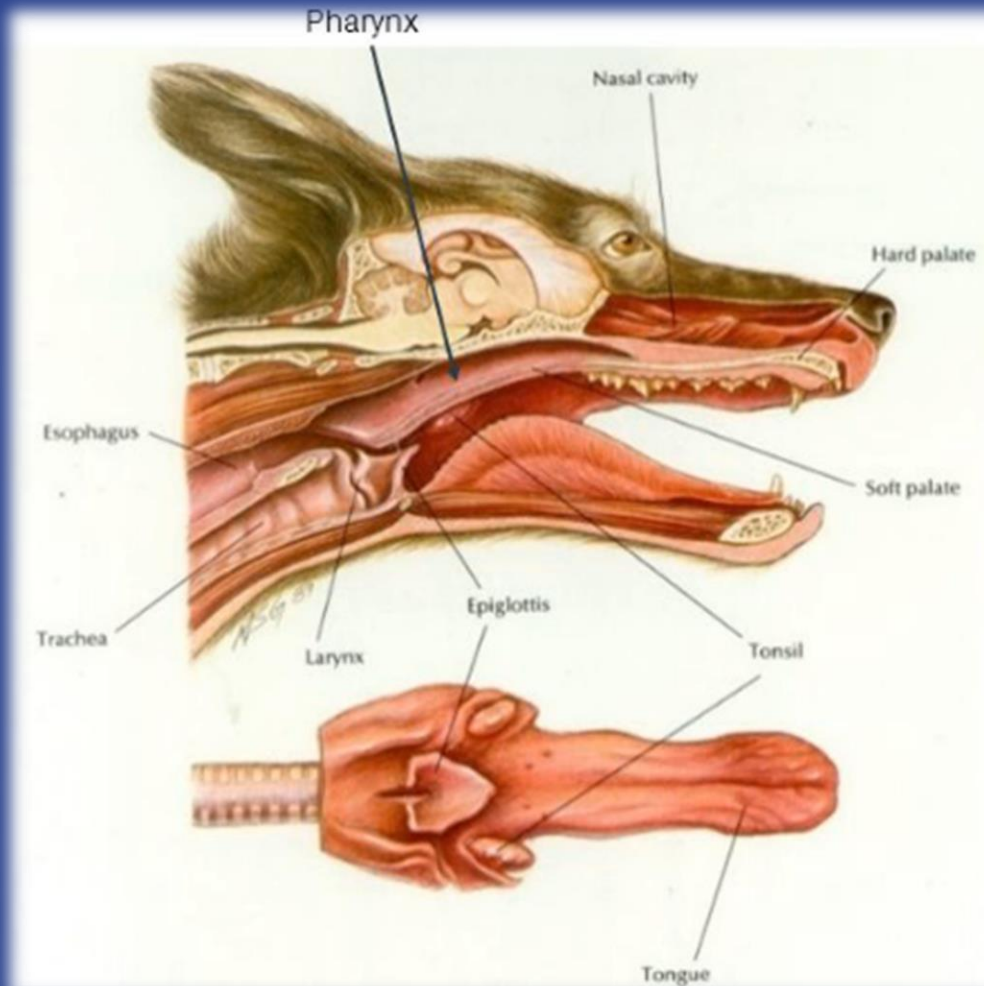


Wanamaker and Massey: Applied Pharmacology for Veterinary Technicians, 5th edition.  
Copyright © 2015 by Saunders Inc, an imprint of Elsevier, Inc.





# Upper Respiratory Tract

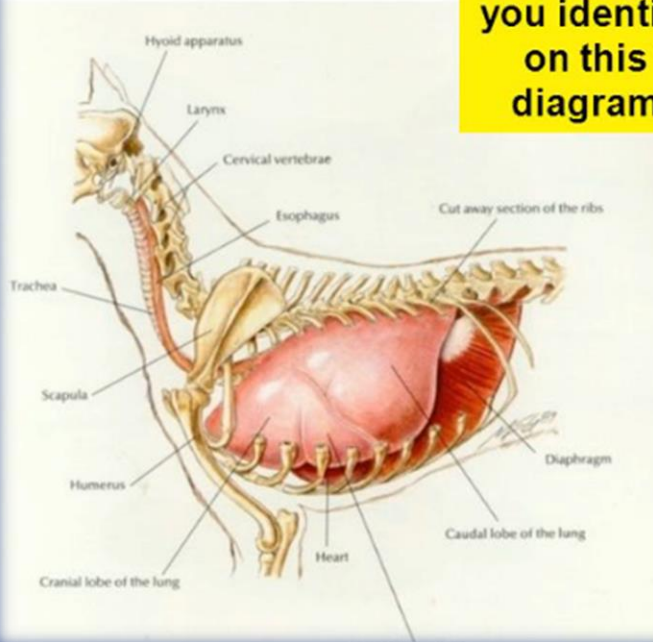


## Upper Respiratory

- Nostrils (nares)
- Nasal Passages
- Para-nasal sinuses
- Pharynx

# Lower Respiratory Tract

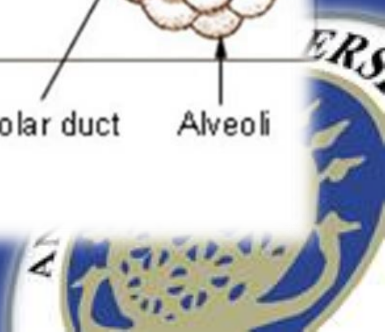
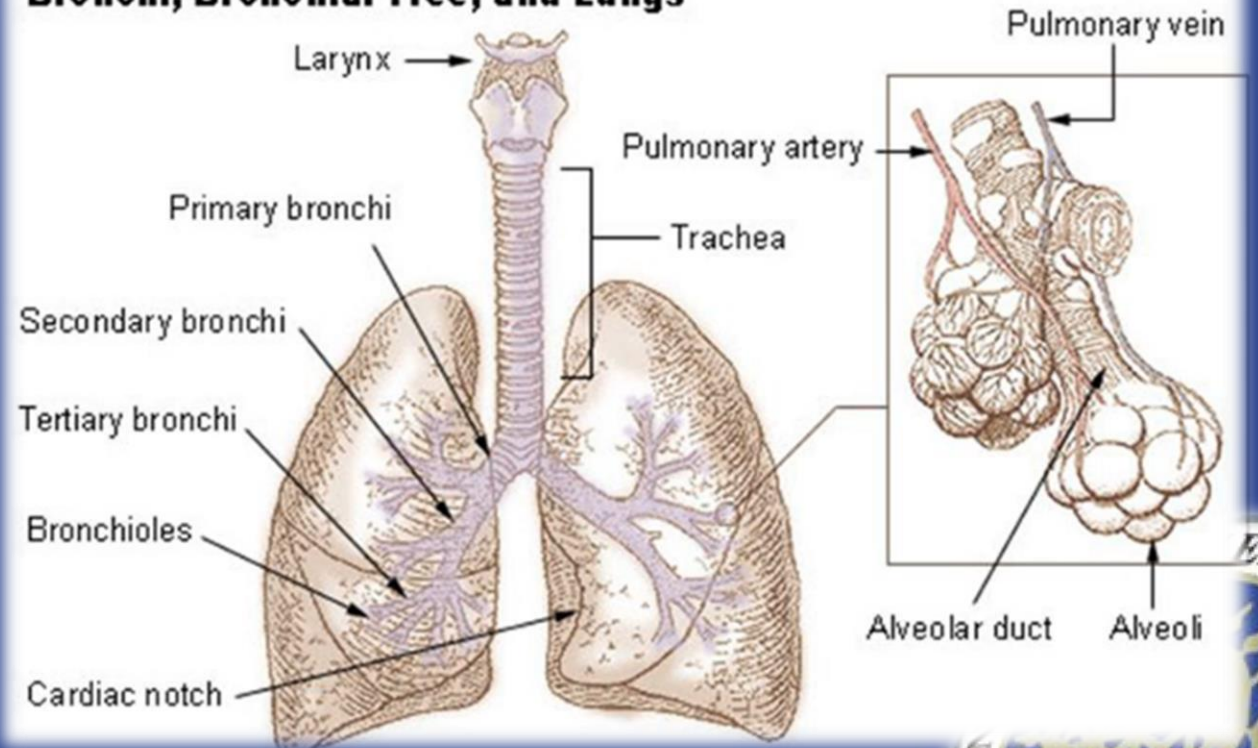
What can you identify on this diagram



## Lower Respiratory

- Larynx
- Trachea
- Lungs
- Bronchii
- Bronchioles
- Alveolar ducts
- Alveoli

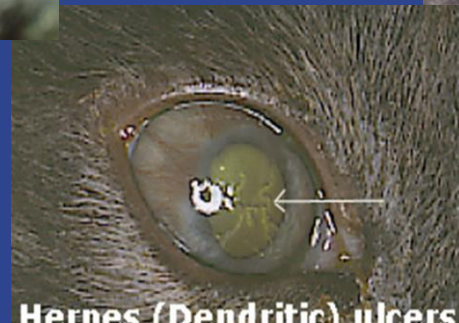
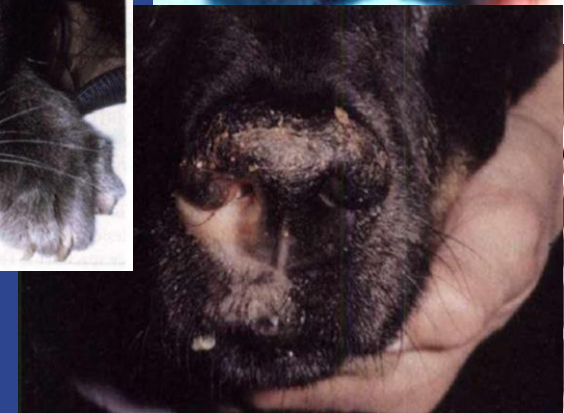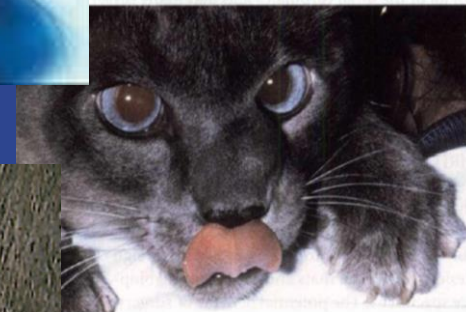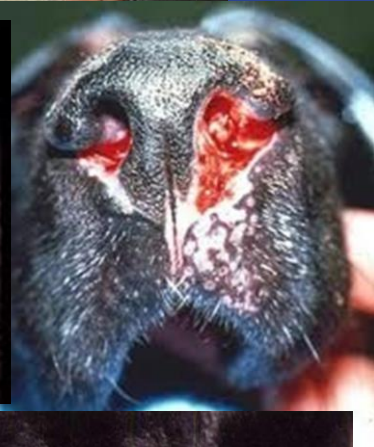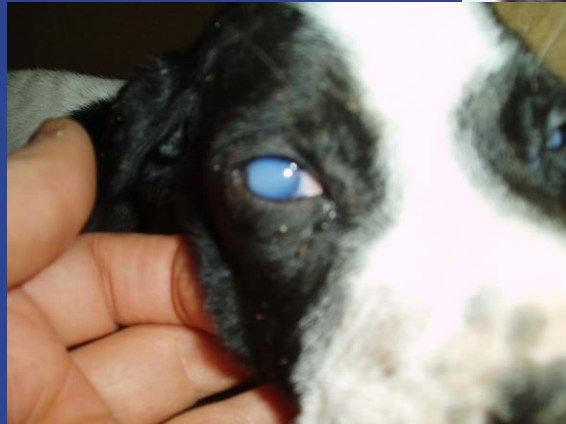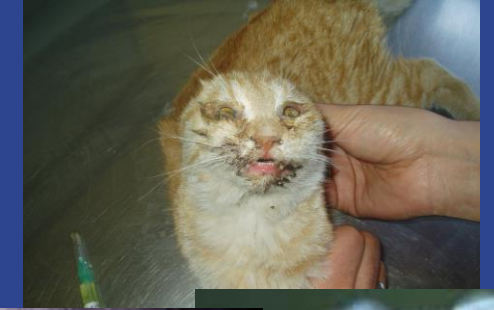
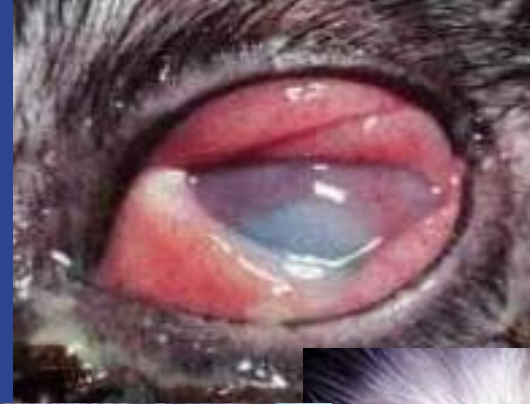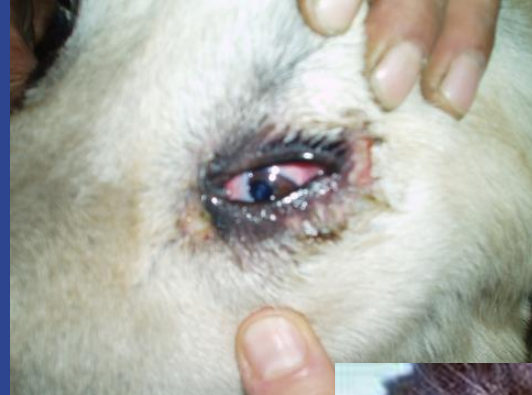## Bronchi, Bronchial Tree, and Lungs





# Clinical Manifestations of Respiratory Disease

- Nasal discharge
- Sneezing
- Facial deformity
- Coughing
- Chemosis
- Eye discharge
- Dysphagy
- Dyspnea
- Respiratory difficulty



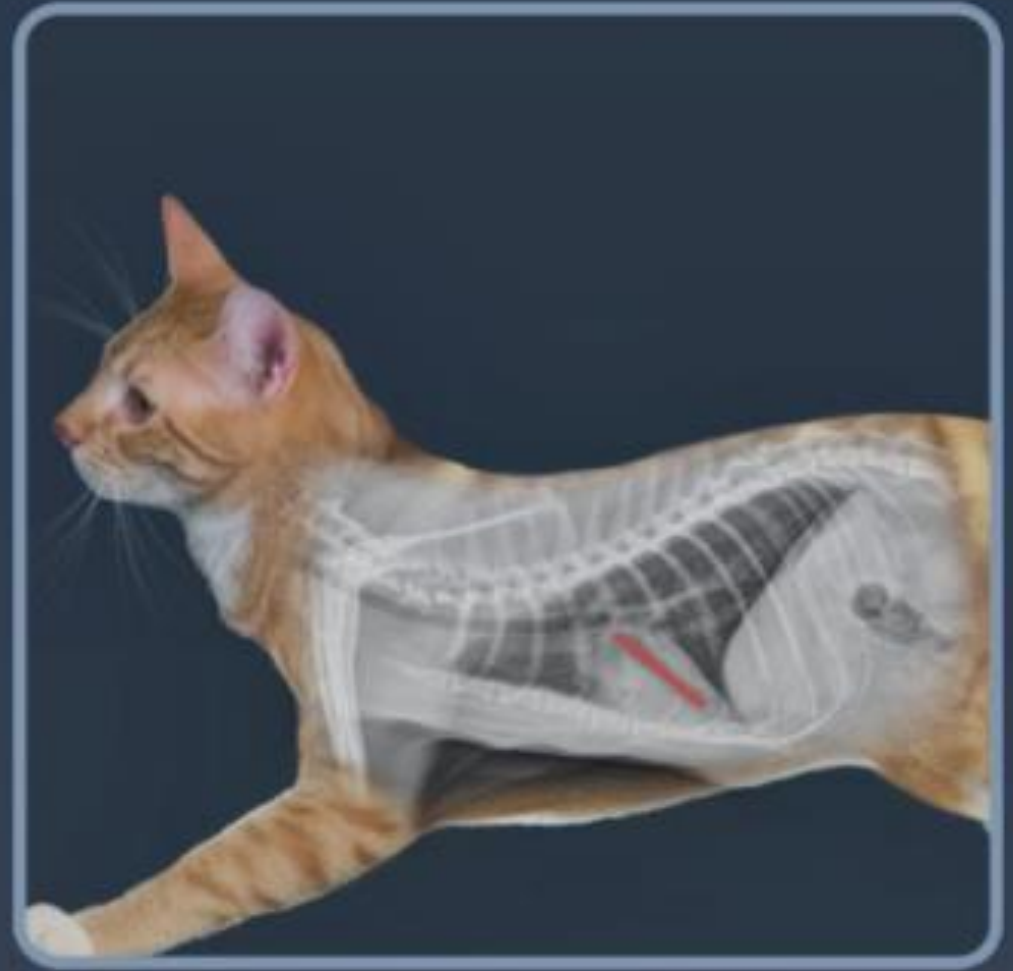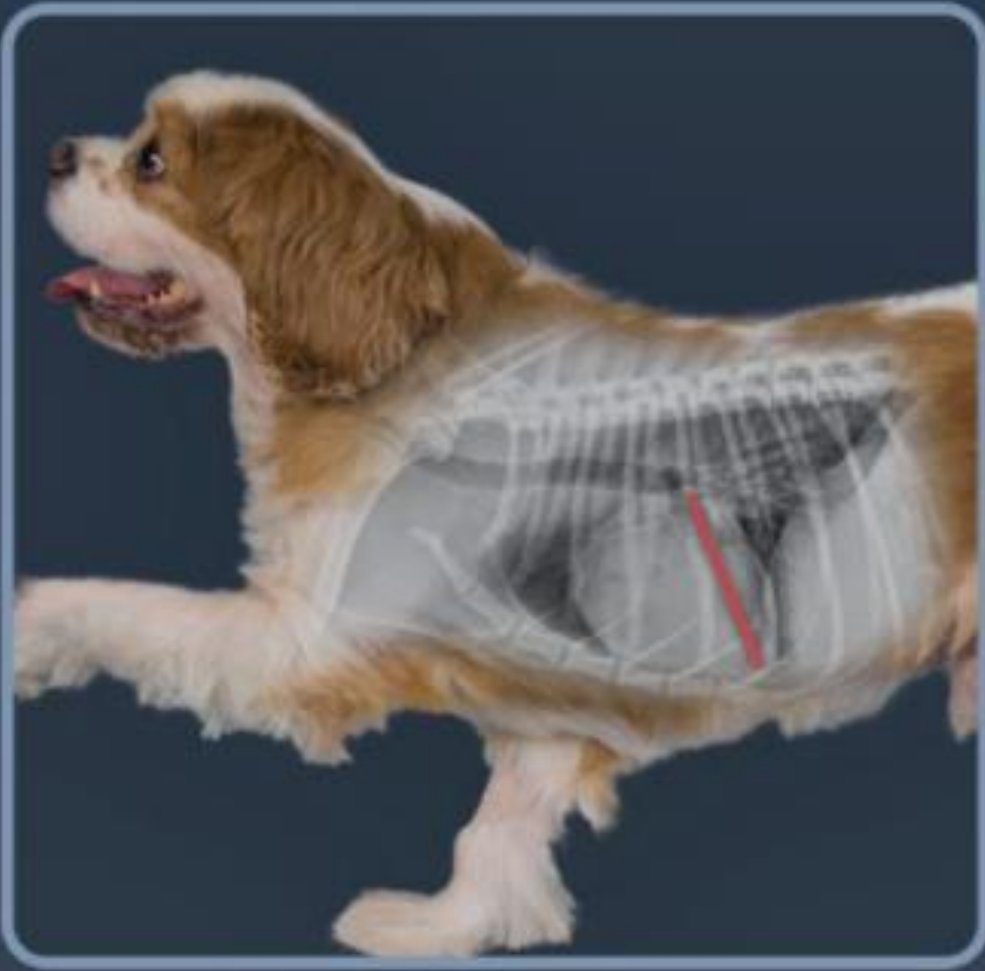Hernes (Dendritic) ulcers





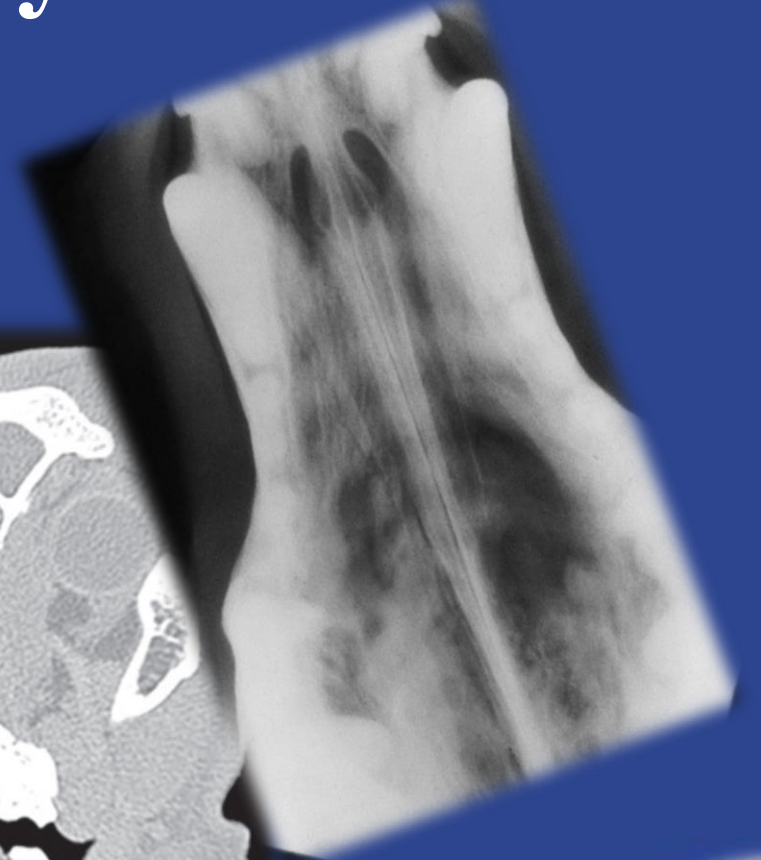
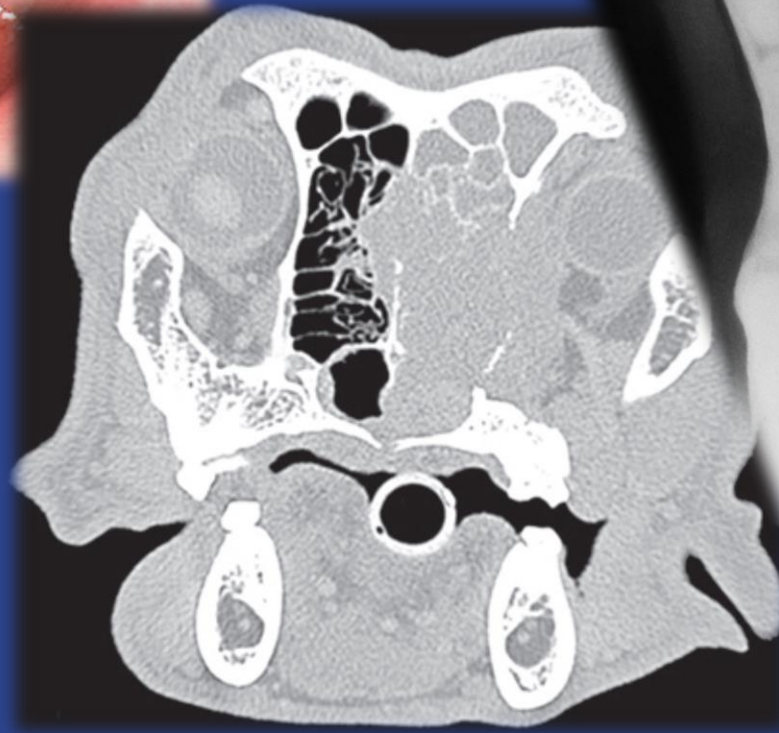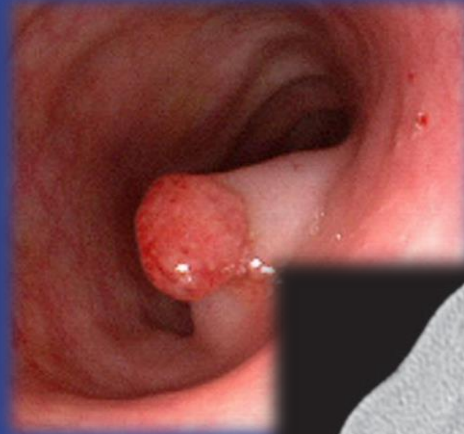


# Lung Auscultation



# Diagnosis of the Respiratory Disease

- Radiography
- Rhinoscopy
- Nasal Swap Cytology
- Nasal Culture, Biopsy
- CT
- MRI





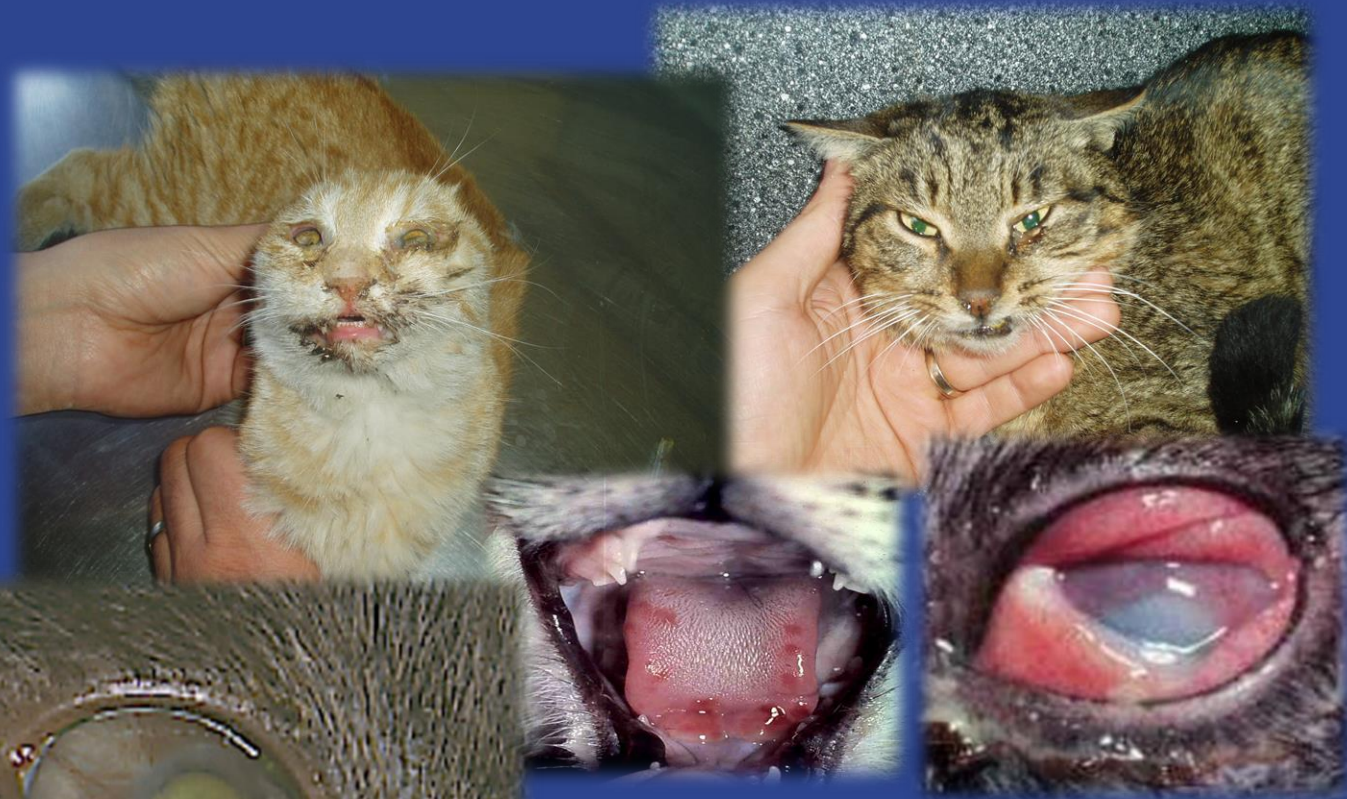# Feline versus Canine Upper Respiratory Tract Disorders-Infections

- FHV (Feline Rhinotraheitis virus)
- FCV
- Bordetella bronchiseptica
- Chlamidiaphila felis
- Allergic rhinitis
- Cryptococcosis
- Trauma
- Nasopharyngeal polyps
- Nasal tumors
- Idiopathic chronic lymphoplasmositic rhinitis
- Allergic rhinitis
- Aspergillosis
- Trauma
- Nasopharyngeal polyps
- Nasal tumors



# Feline Upper Respiratory Tract Disorders- Infections

- FHV (Feline Rhinotracheitis virus)
- FCV
- Bordetella bronchiseptica
- Chlamydiaphila felis
- Allergic rhinitis

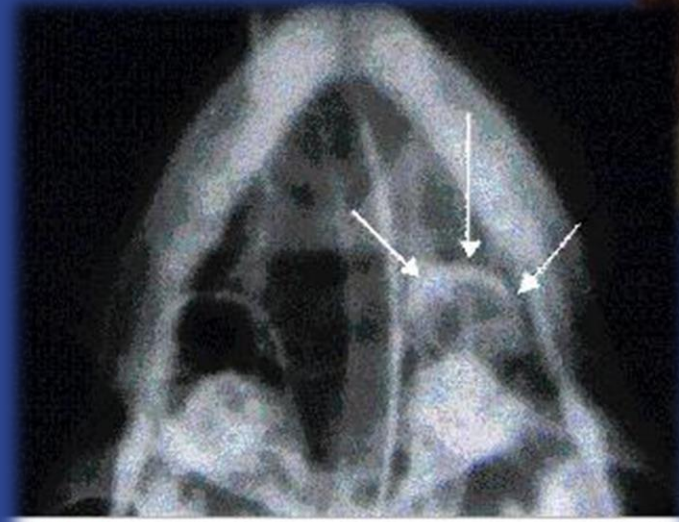


Herpes (Dendritic) ulcers

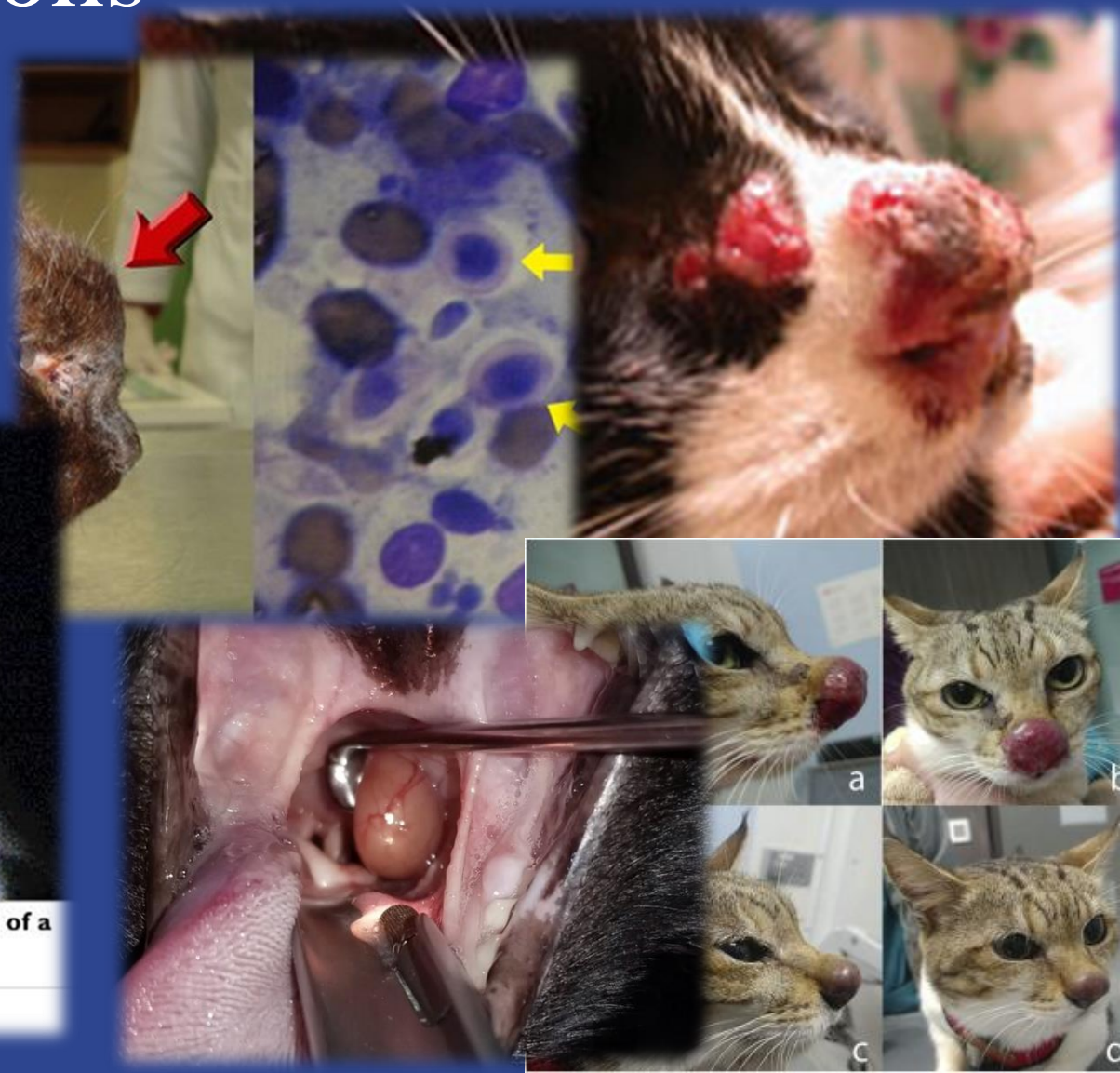

# Feline Upper Respiratory Tract Disorders- Infections

- Cryptococcosis
- Trauma
- Nasopharyngeal polyps
- Nasal tumors



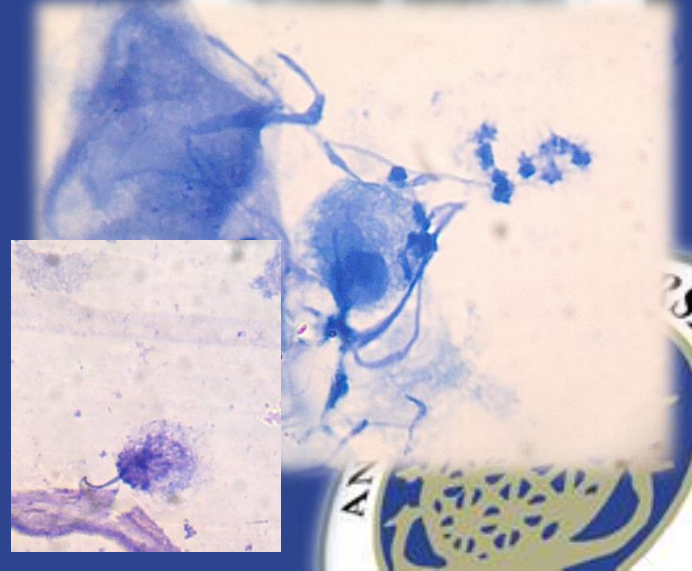
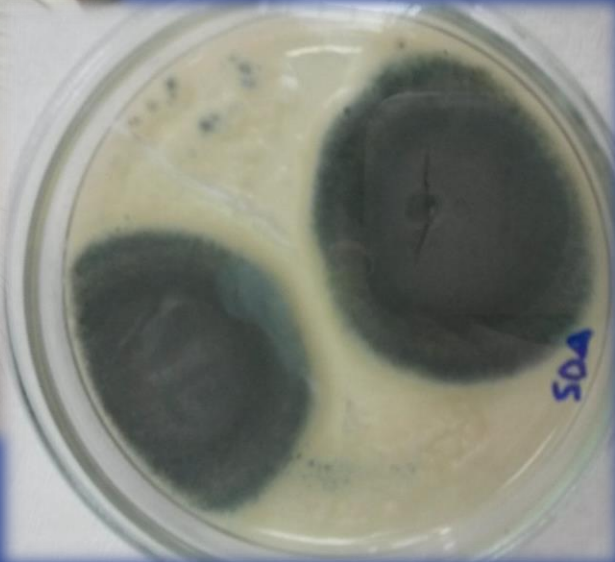
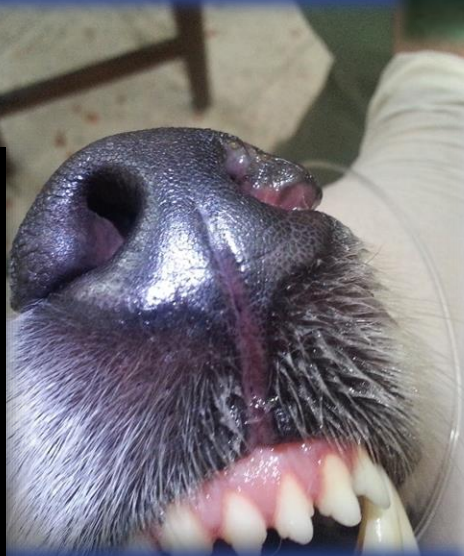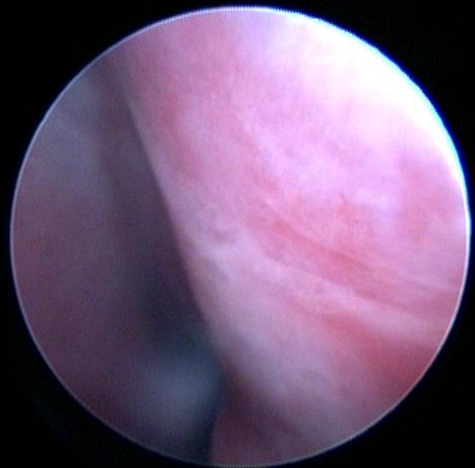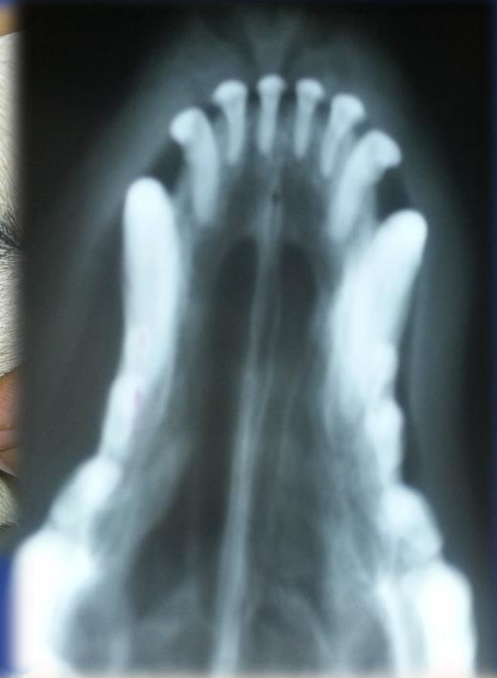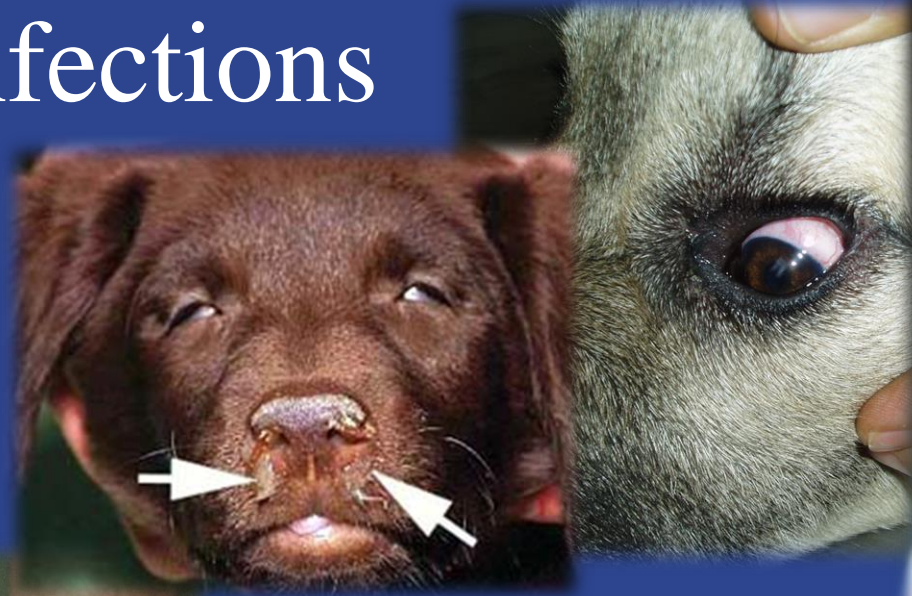**Figure 1.** Open-mouth rostrocaudal radiograph of a tympanic bulla. Arrows indicate the affected bulla.





# Canine Upper Respiratory Tract Disorders- Infections

- Idiopathic chronic lymphoplasmositic rhinitis
- Allergic rhinitis
- Aspergillosis
- Trauma
- Nasopharyngeal polyps
- Nasal tumors





# Larynx-Trachea

- Brahyocephalic syndrome

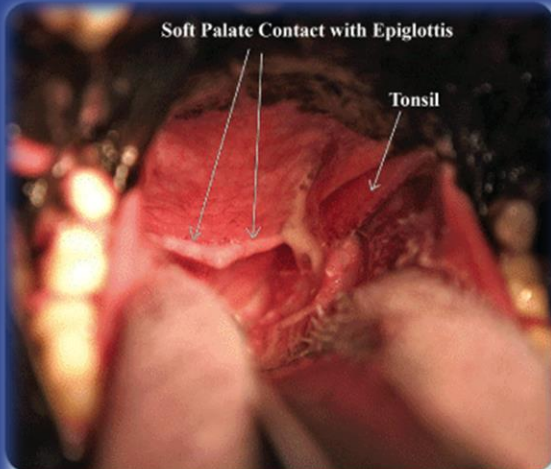
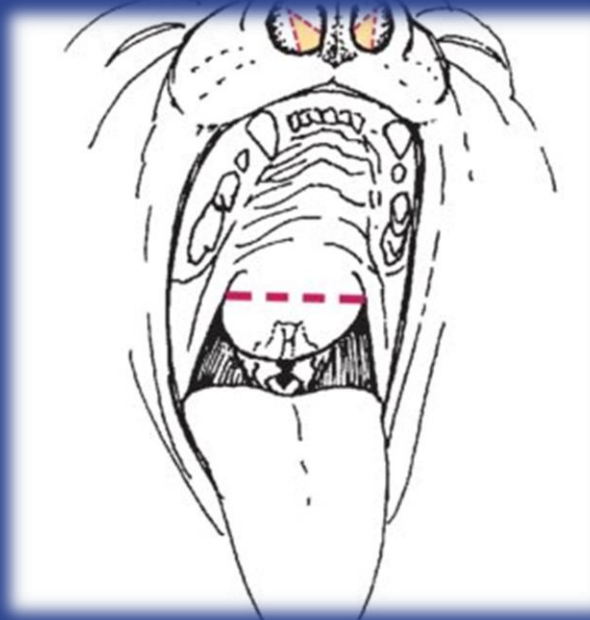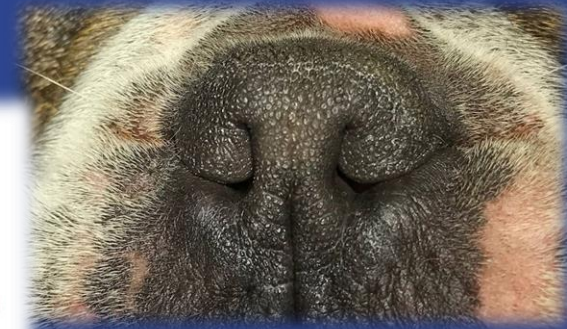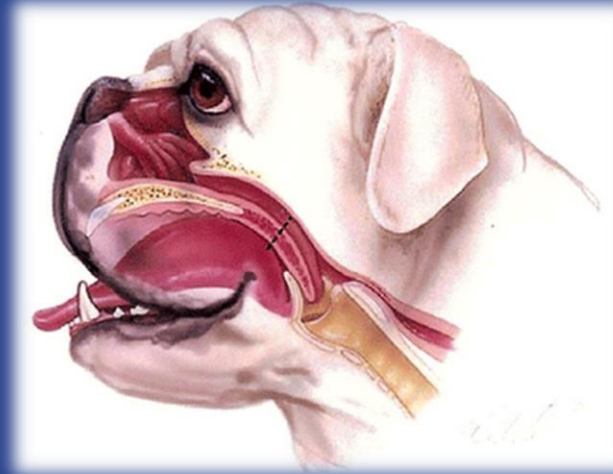
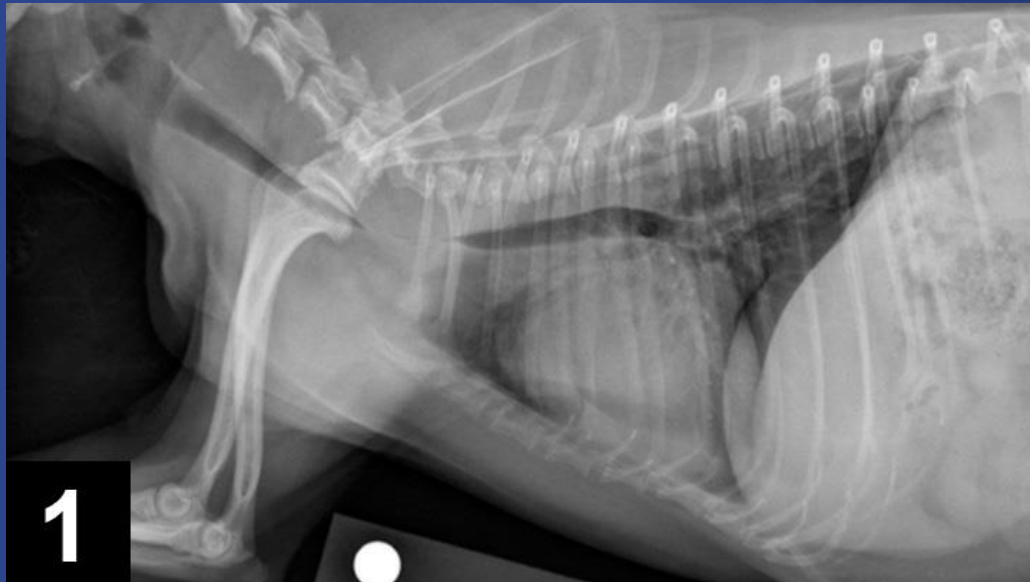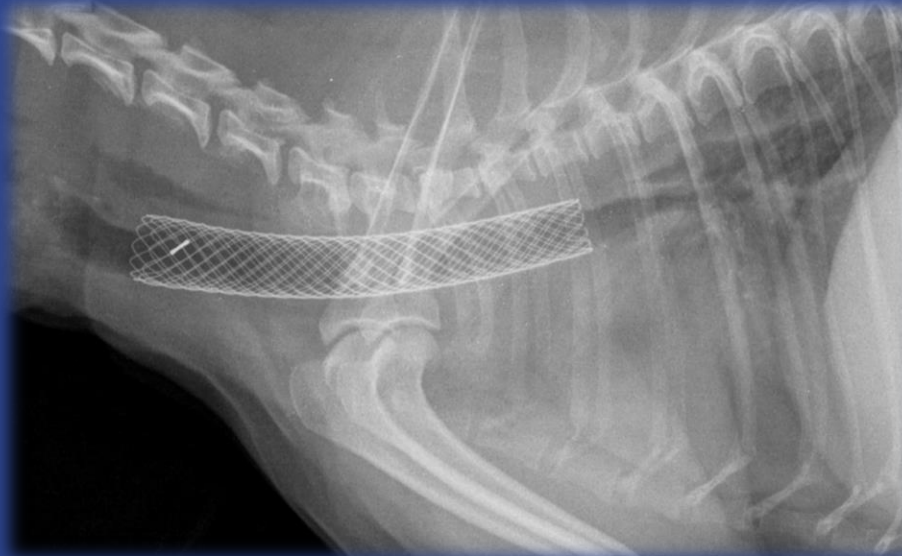
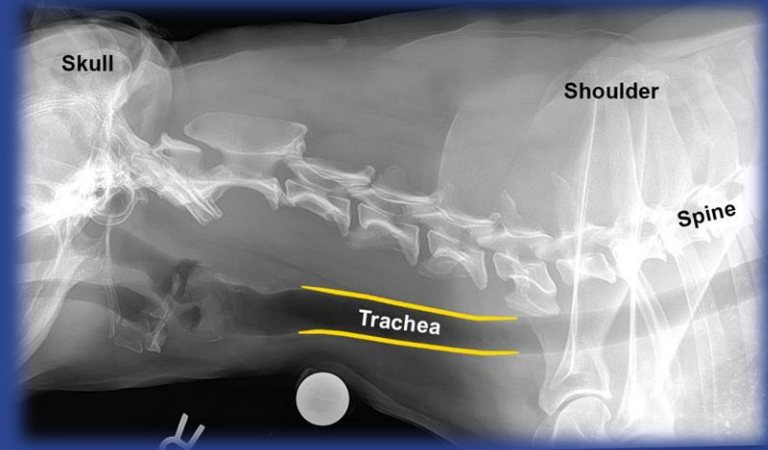


Figure 3. Intraoral photograph of an elongated soft palate and everted palatine tonsil.



# Larynx-Trachea

- Traheal collaps





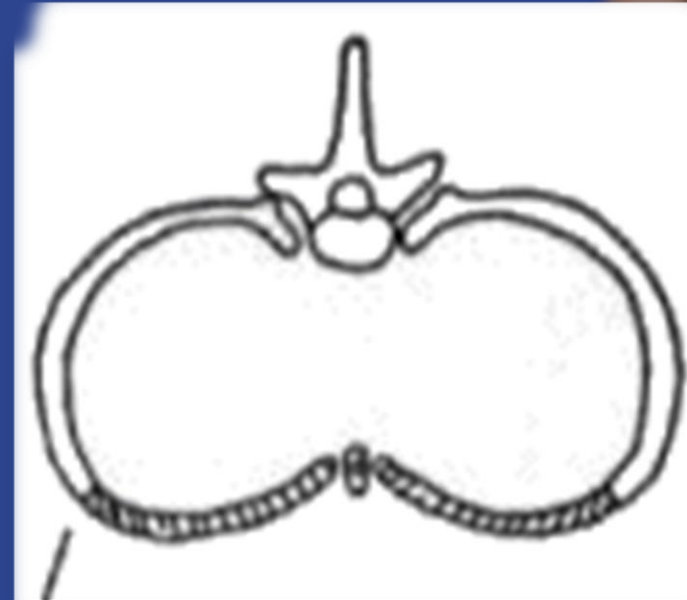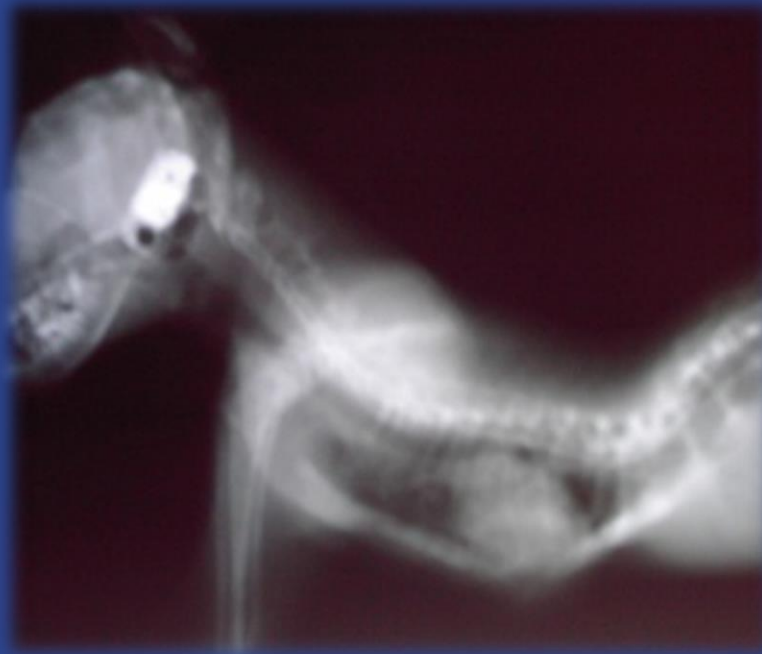
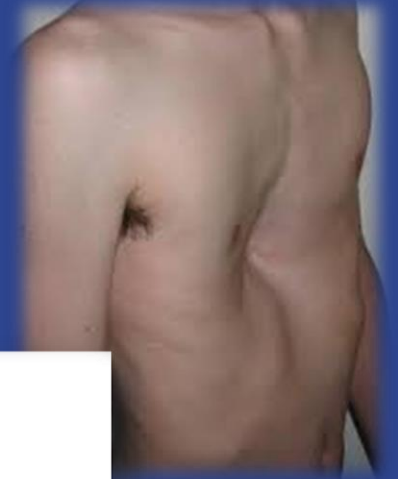# Larynx-Trachea

- Laryngeal paralysis-collaps



# Sternal Deformity

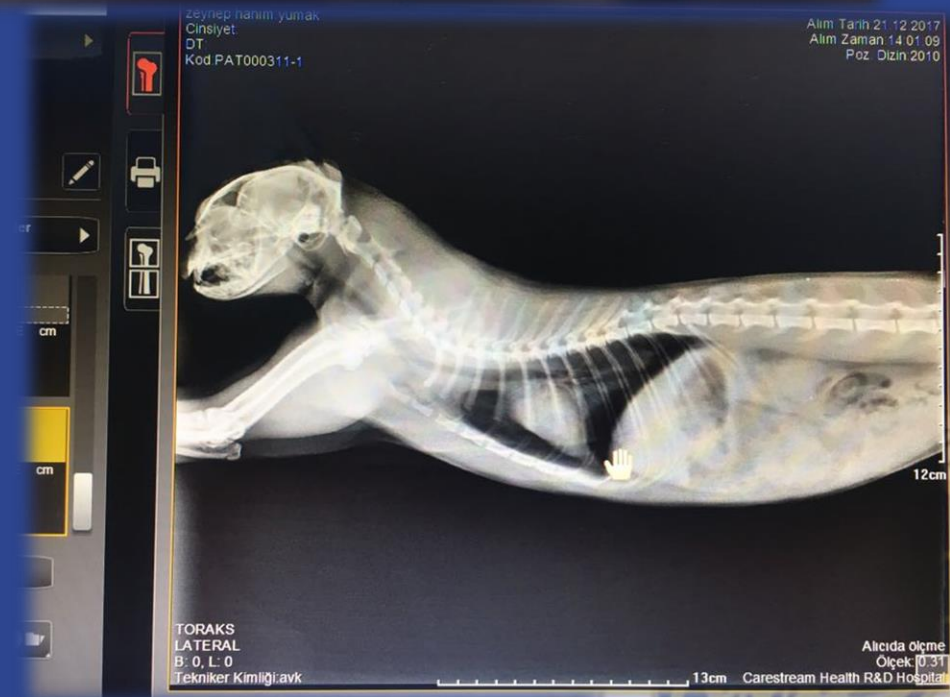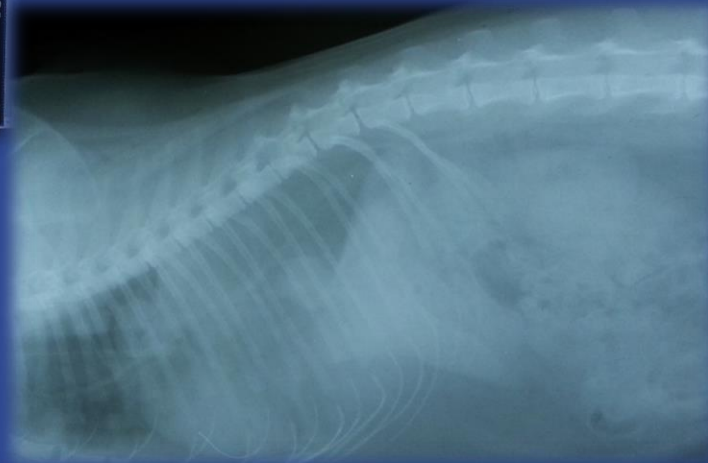
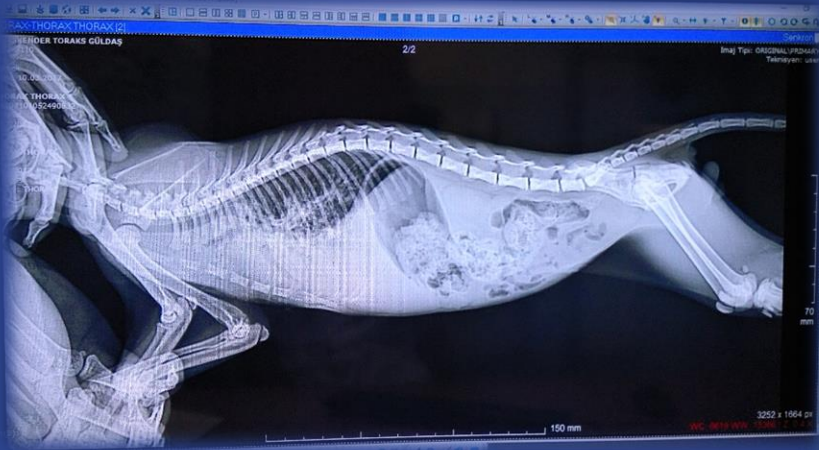
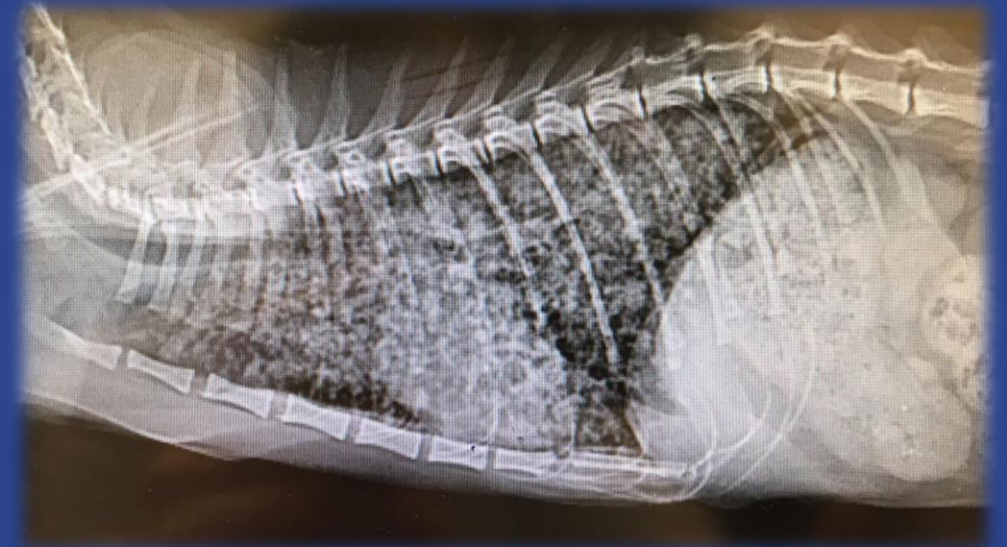
- Pectus (Funnel Chest)





# Lung

- Chronic Bronchitis in cats (Feline asthma)
- Broncopneumonia
- Fungal pneumonia
  - Blastomycosis



# Respiratory Tract Disease in Dogs and Cats



Ekrem Çağatay ÇOLAKOĞLU



ekrem.colakoglu



colakoglu@ankara.edu.tr



<http://cv.ankara.edu.tr/colakoglu@ankara.edu.tr&deger=1>

