


# The Effect of Cigarette and Alcohol Use on Oral Health

Assoc. Dr. Şivge Kurgan  
[sivgeakgun@gmail.com](mailto:sivgeakgun@gmail.com)



# Risk Factors

**Risk:** the possibility of being harmed.

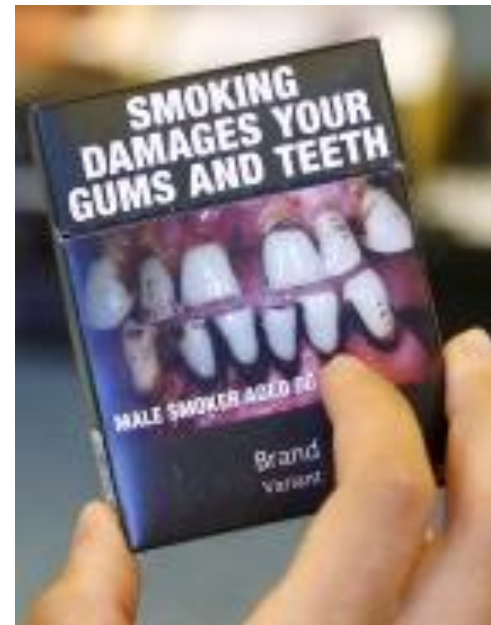- The features that increase the risk of disease in the individual are called 'risk factors'.



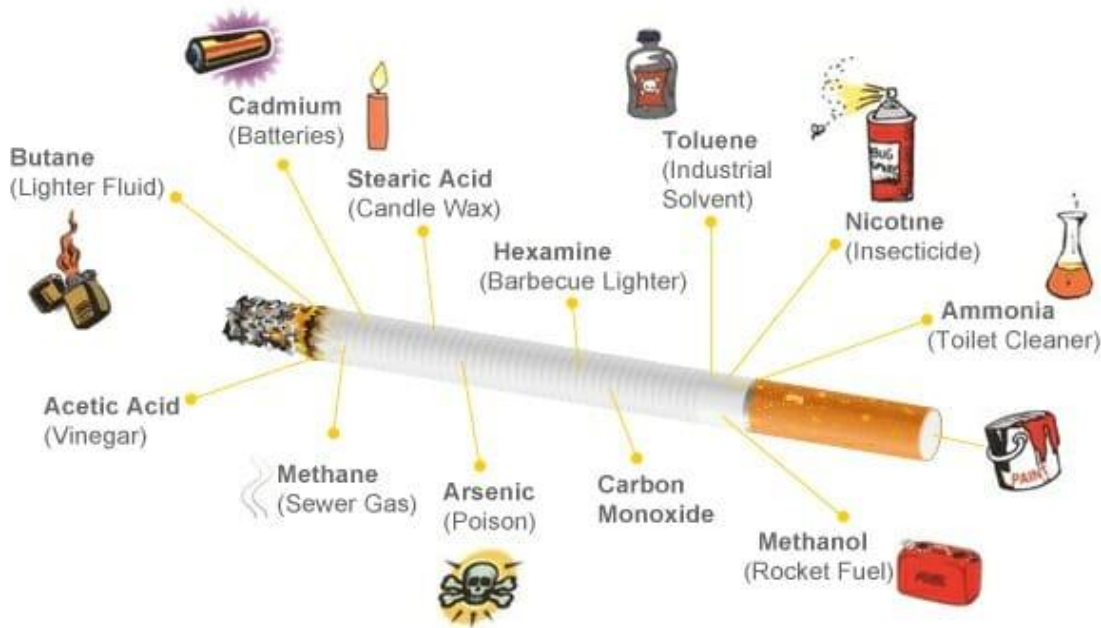# Risk Factors for Oral and Dental Health

---

- Age
- Gender
- Genetic
- Systemic diseases (such as cardiovascular, diabetes blood diseases)
- Weakened host defense
- poor oral hygiene
- Edges of unsuitable crowns and dental restorations
- Stress
- **CIGARET**
- Nutrition (Diet)
- **ALCOHOL USE**



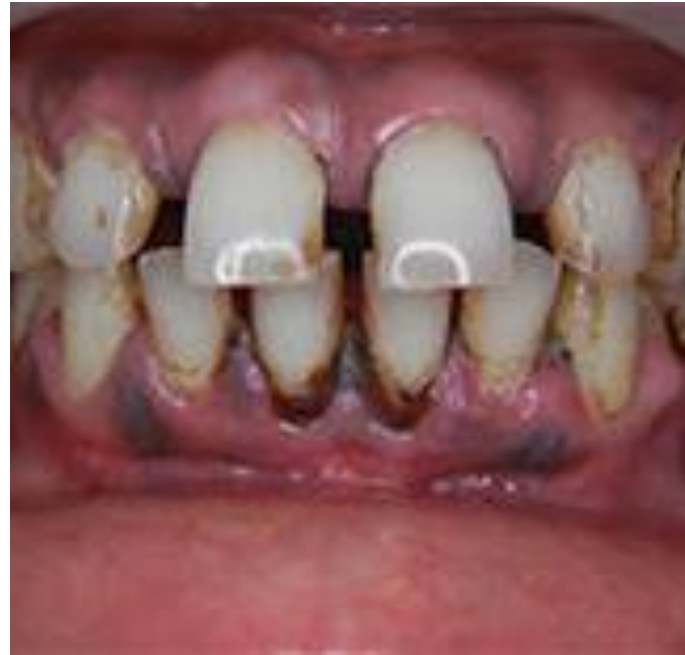## What's in a cigarette?



- ✓ It has been reported that cigarettes contain more than 4000 cytotoxic, mutagenic and carcinogenic substances.
- ✓ Toxics: Hydrogen cyanide, Nitrogen oxides, Ammonia, Catechol, Formic Acid etc.
- ✓ Carcinogenic substances: Arsenic, Chromium, Nickel, Benzopyrene, Nitrosamines, Cadmium, Formaldehyde, Acetaldehyde
- ✓ It has been reported that an average of 20-30 ml of carbon monoxide and 2-3 mg of nicotine are inhaled each time a cigarette is smoked.

# Local Effects of Smoking (nicotine)

- Nicotine enters the blood stream and causes the release of epinephrine from the adrenal glands, causing **vasoconstriction**.
- Its vasoconstrictive effect causes nutritional deficiency in tissues with microcirculation.



# *Smoking, microflora and host response*

- It is thought that there may be an **increase in the number of anaerobic bacteria** due to the decrease in oral oxidative potential during cigarette smoking.
- It has been suggested that smoking increases periodontal destruction by **altering the host response.**

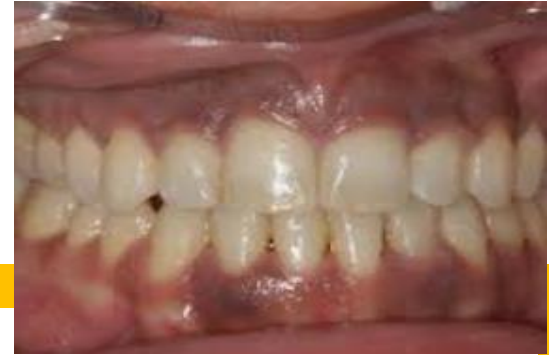# Smoking and Periodontal Diseases

- **Smoking and gingivitis:** Vasoconstriction in peripheral blood vessels affects periodontal tissues, and **gingivitis symptoms become less visible in smokers** compared to non-smokers.
- **Smoking and NUG:** smoking are among the **etiological factors of necrotizing ulcerative gingivitis** (NUG).
- **Smoking and periodontitis:** It has been reported that the **incidence of periodontitis is 3-4 times higher in smokers** compared to non-smokers, and **alveolar bone destruction increases with the number of cigarettes smoked per year.**

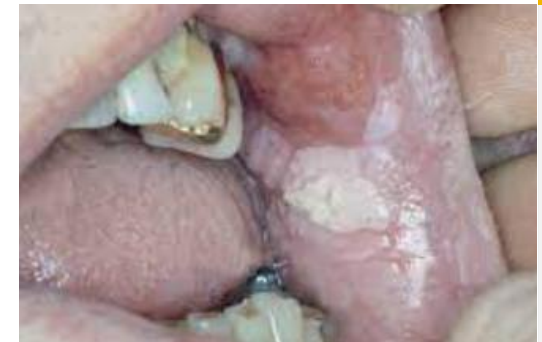# The effect of smoking on the oral mucosa and its relationship with oral cancers

- The heat of cigarette smoke may irritate the oral mucosal tissue and **cause hyperkeratosis.**
- **The positive correlation between gingival melanosis**, a benign pigmentation of the oral mucosa, and cigarette smoking was associated with the affinity of benzopyrene and nicotine to melanocyte cells.
- **According to epidemiological data, tobacco users are at high risk for oral cancers.**
- The presence of epithelial dysplasia is an important sign for the detection of cancer development, and studies have shown that **oral epithelial dysplasia is associated with smoking.**

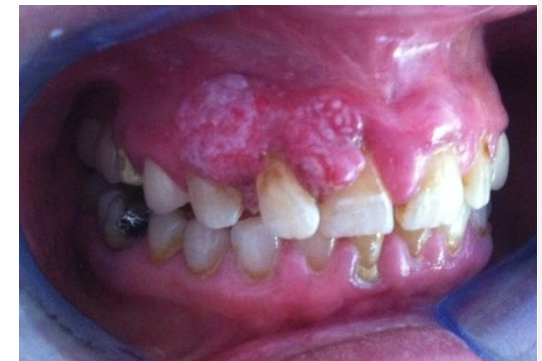Melanin pigmentation



Leukoplakia



Oral Squamous Cell Carcinoma

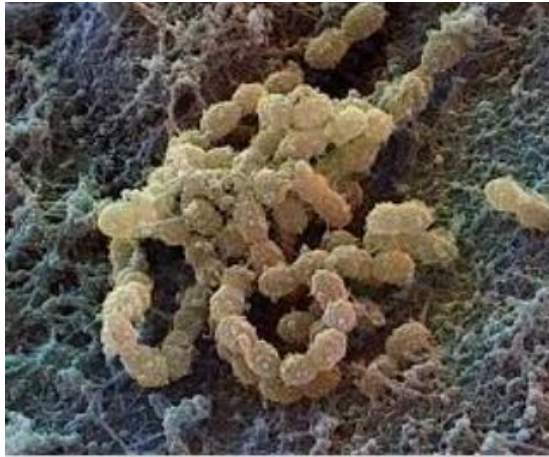




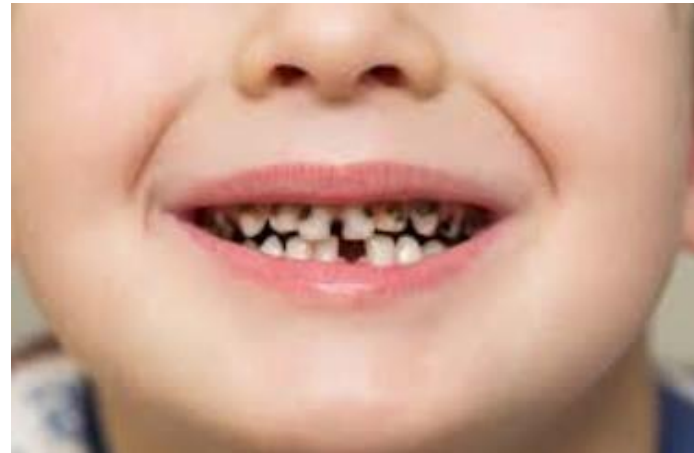# Effects of Passive Smoking in Infancy and Childhood

- There may be an **increased incidence of melanin pigmentation** in children exposed to cigarette smoke.
- Smoking during pregnancy exposes the fetus to many chemical toxins (nicotine etc.), **affecting the mineralization of primary teeth**. As a result, **hypoplasia and hypo-mineralization** can be observed.

# *Effects of Smoking on Caries Formation*



Streptococcus mutans bacteria, SEM ..



Many studies show that maternal smoking and passive smoking in children may be associated with dental caries in deciduous and permanent teeth.

## *Effects of Cigarette Smoke on Caries Formation*

- Aligne et al. in a study conducted by NHANES III in 2003 using the database of the National Health and Nutrition Examination Survey, **it was shown that there is a positive correlation between serum cotinine level and dental caries in children aged 4-11 years.**
- Nicotine lowers the level of vitamin C associated with the proliferation of *S.mutans*, lowers the pH of saliva, decreases salivary flow and saliva buffering capacity, increasing the number of other cariogenic bacteria such as lactobacilli.

# The Effect of Alcoholism on Oral Health

- **Alcoholics are at risk for dental caries, gingival disease, and oropharyngeal cancers!!!!**
- When cigarettes and alcohol are consumed together, the risk of oral cancer increases even more.

# Alcohol, Salivary Glands and Dental Caries

- The salivary glands, especially the parotid gland, may swell in long-term alcohol users.
- This condition is known as sialadenosis and is associated with ethanol-induced peripheral neuropathy.
- This causes disturbances in the metabolism of the salivary glands and in the excretion of saliva.
- Decreased salivary flow with impaired buffering capacity can lead to an increased risk of dental caries and gingival disease, especially in those who pay less attention to oral hygiene.

# Alcohol, Salivary Glands and Dental Caries

The acidic nature of alcoholic beverages and the consumption of carbohydrate-rich foods cause acid production and a decrease in salivary pH below the critical level.

- Alcoholics often have a high rate of decayed teeth.
- Alcoholics are more likely to have missing teeth than non-alcoholics.

# Alcohol and Periodontal Diseases

Long-term alcohol use has the potential to alter the host-mediated response with many systemic effects and affect the risk for periodontal diseases!!!!!!!!!!

Alcoholism can lead to periodontal disease for several reasons:

- Irritation of gingival tissue
- Bad oral hygiene habits of chronic alcoholics;
- Poor dietary habits of chronic alcoholics that lead to weak immunity;
- Weak immune response to harmful chemicals;
- Dehydration due to alcohol consumption and increased plaque formation due to decreased salivary flow etc....

# The Effect of Alcohol on Tongue

- Alcoholics who take disulfiram may often experience a metallic taste.
- Besides the direct harmful effects on oral health, alcoholics suffer from a variety of indirect effects caused by a lack of adequate nutrition. The most common effects are inflammation of the tongue (glossitis), inflammation of the gums (gingivitis), and sometimes inflammation of the corner of the mouth (angular cheilitis).



# Alcohol and Tooth Erosion

- **People who are addicted to alcohol have a high risk of developing tooth erosion.**
- Ethanol has the potential to increase the rate of degradation in organic systems with its direct and indirect effects.
- Regular and long-term consumption of acidic beverages such as wine makes the oral cavity and tooth surface acidic. This acidification dissolves the surface of enamel and makes it more vulnerable to mechanical damage (brushing, clenching etc.)
- The lower esophageal sphincter relaxes under the influence of alcohol, which causes frequent vomiting. The acidic contents of the stomach enter the mouth due to vomiting and cause erosion of enamel.
- The tooth surfaces most affected by erosion are the palatal surfaces of the upper teeth and then the occlusal surfaces of the posterior teeth. The lower teeth and the buccal surfaces of the upper teeth are least affected.

# Alcohol and Oral Cancers

- Drinking alcohol is considered a potential risk factor for oral cancers, but when consumed with tobacco it increases the risk due to the synergistic interaction.
- However, the role of alcohol in the development of oral cancers is not fully understood.

# Alcohol and Oral Cancers

Some mechanisms have been proposed to explain the carcinogenic effects of alcohol in the pathogenesis of oral cancers, these are:

- Alcohol's dehydration effect on cell walls increases mucosal permeability to other toxins and carcinogens.
- Reduction in epithelial thickness.
- Acetaldehyde produced by the metabolism of ethanol can damage the DNA of oral epithelial cells.
- Ethanol impairs salivary gland function by reducing the secretion of epidermal growth factor, which protects the oral mucosa from injury caused by acids.
- Nutritional deficiencies associated with heavy drinking can reduce the body's natural ability to use antioxidants to prevent cancer formation.



Thank you...

