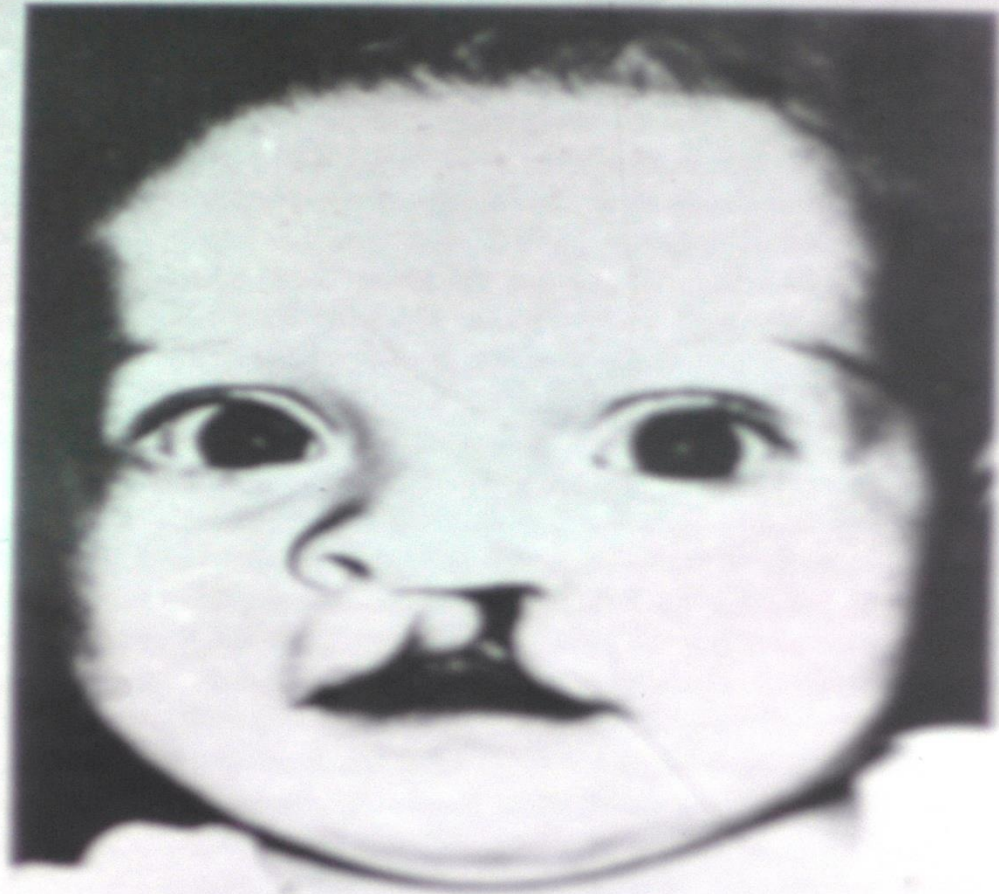
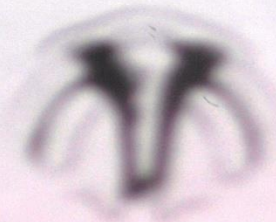
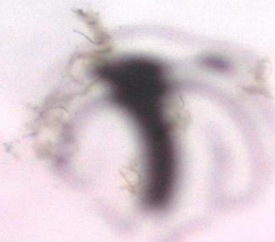Konjenital anomaliler
Dudak damak yarıkları ve
kraniofasial anomaliler



INITIAL STAGE



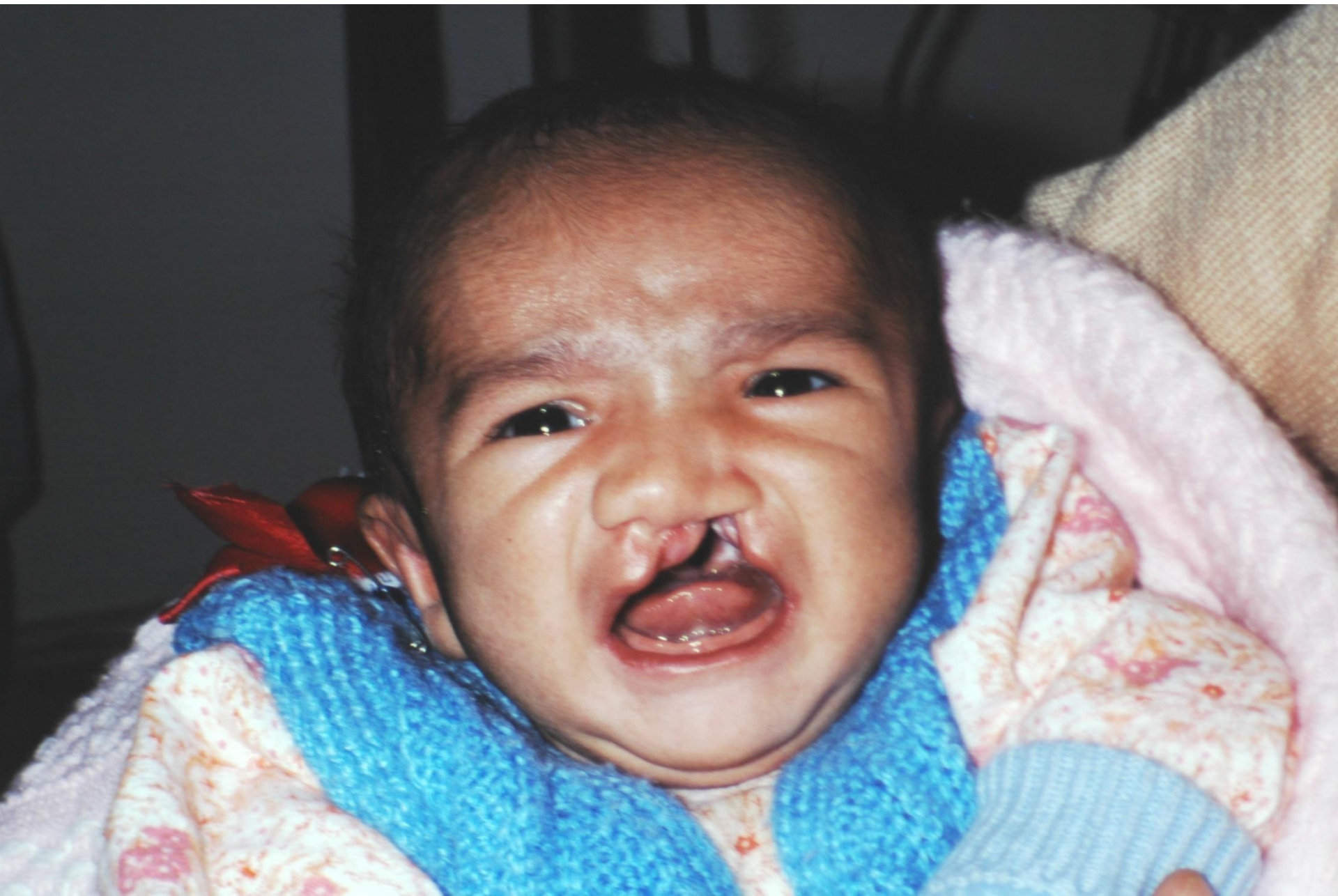SECOND STAGE

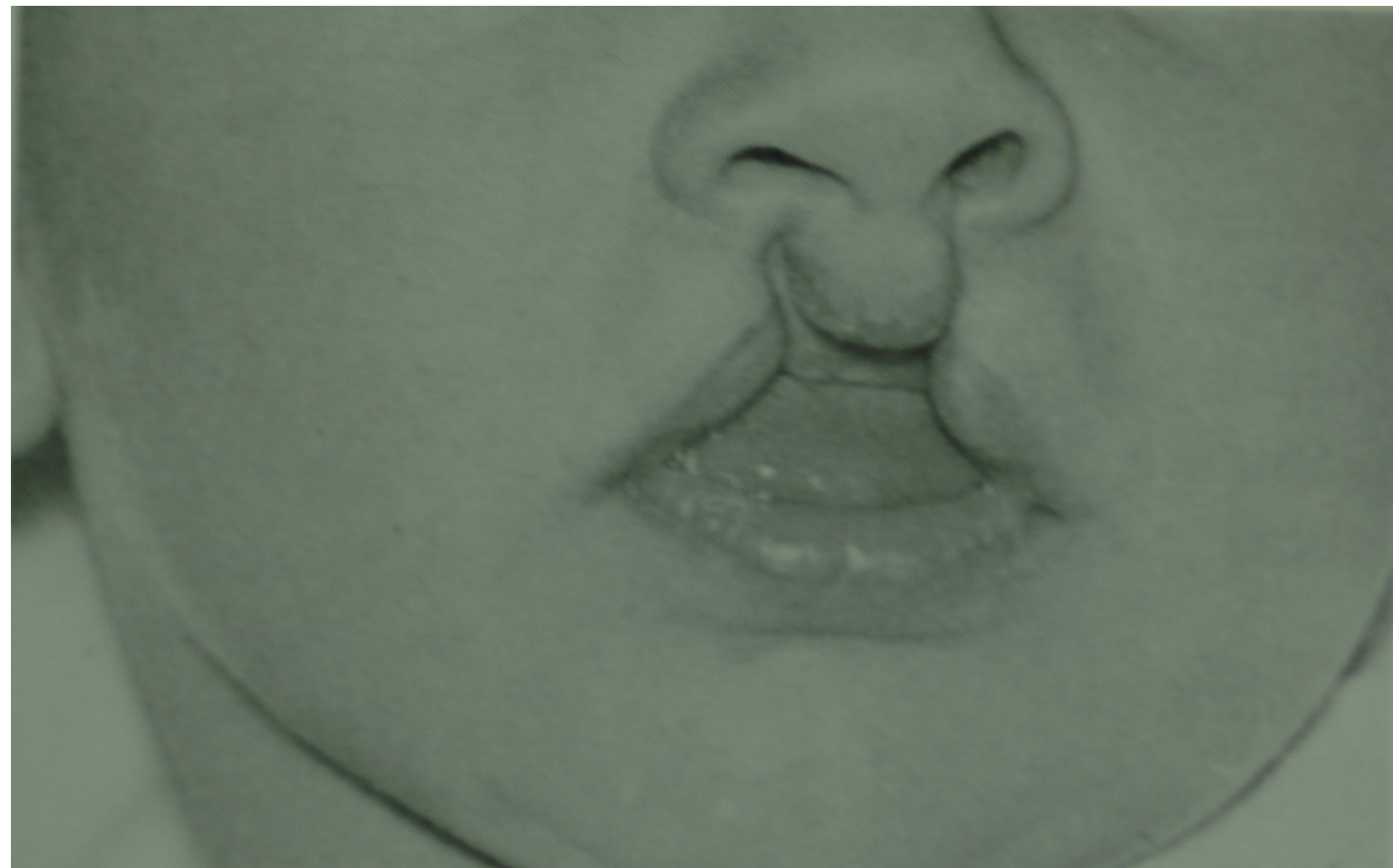

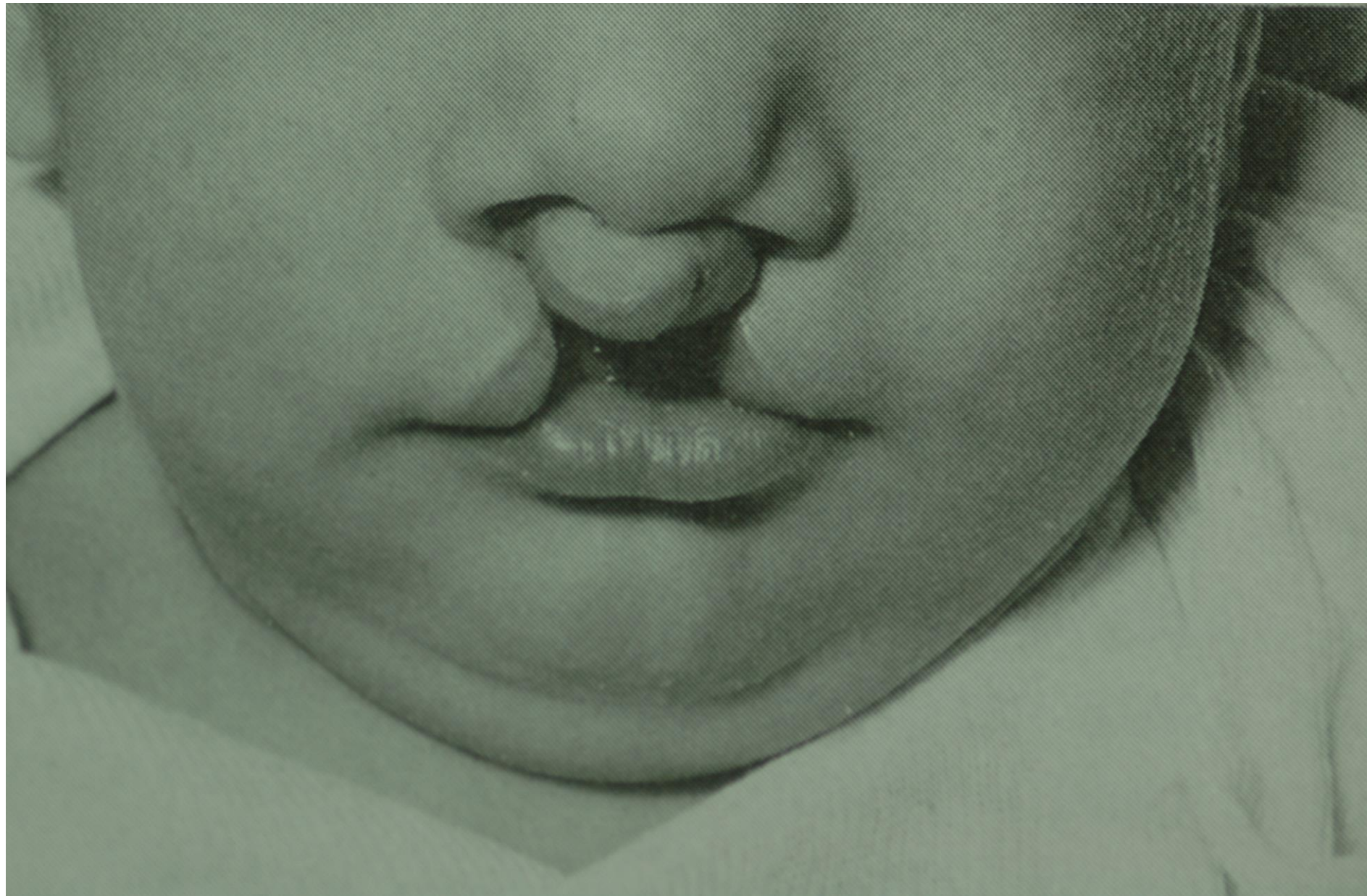THIRD STAGE

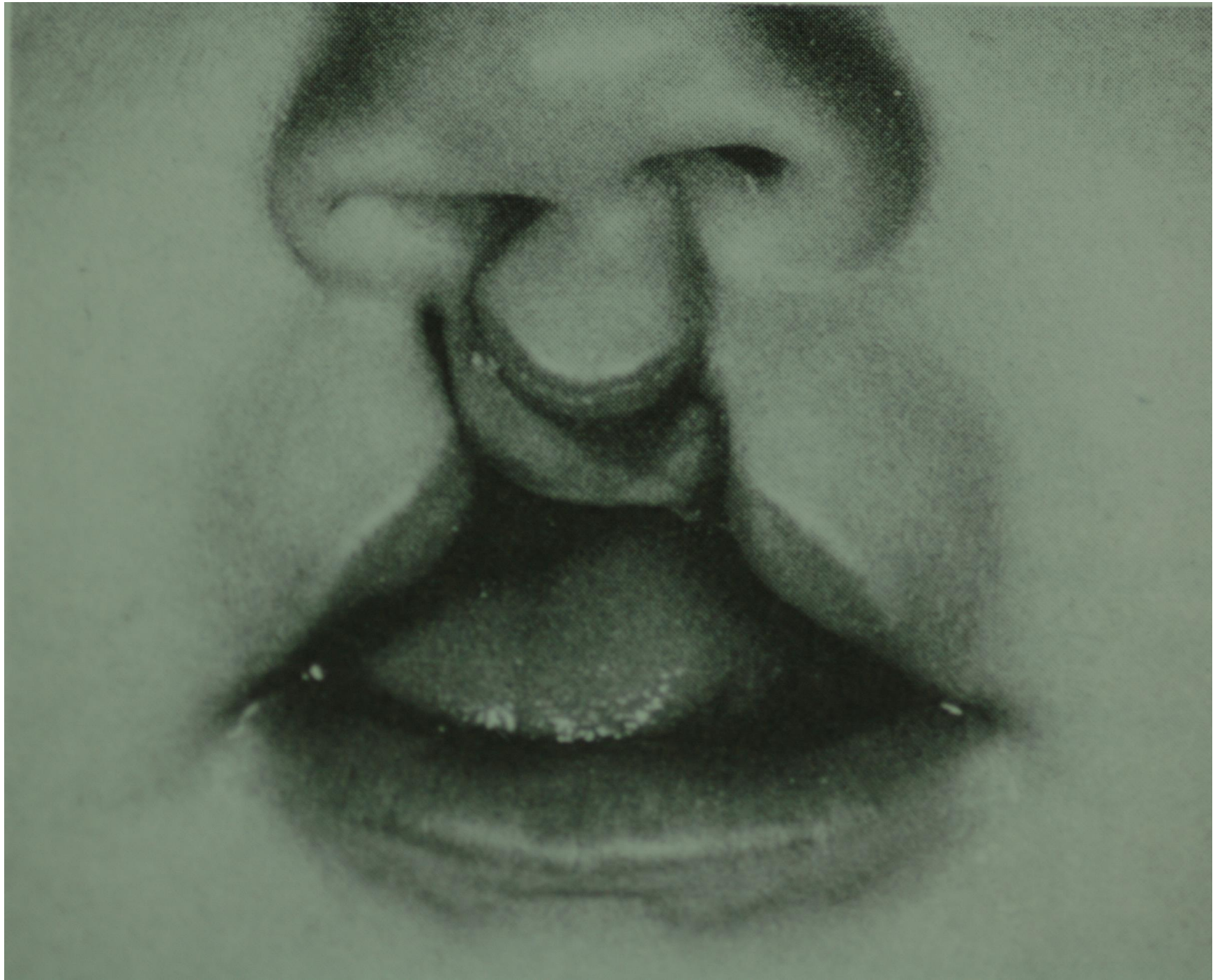

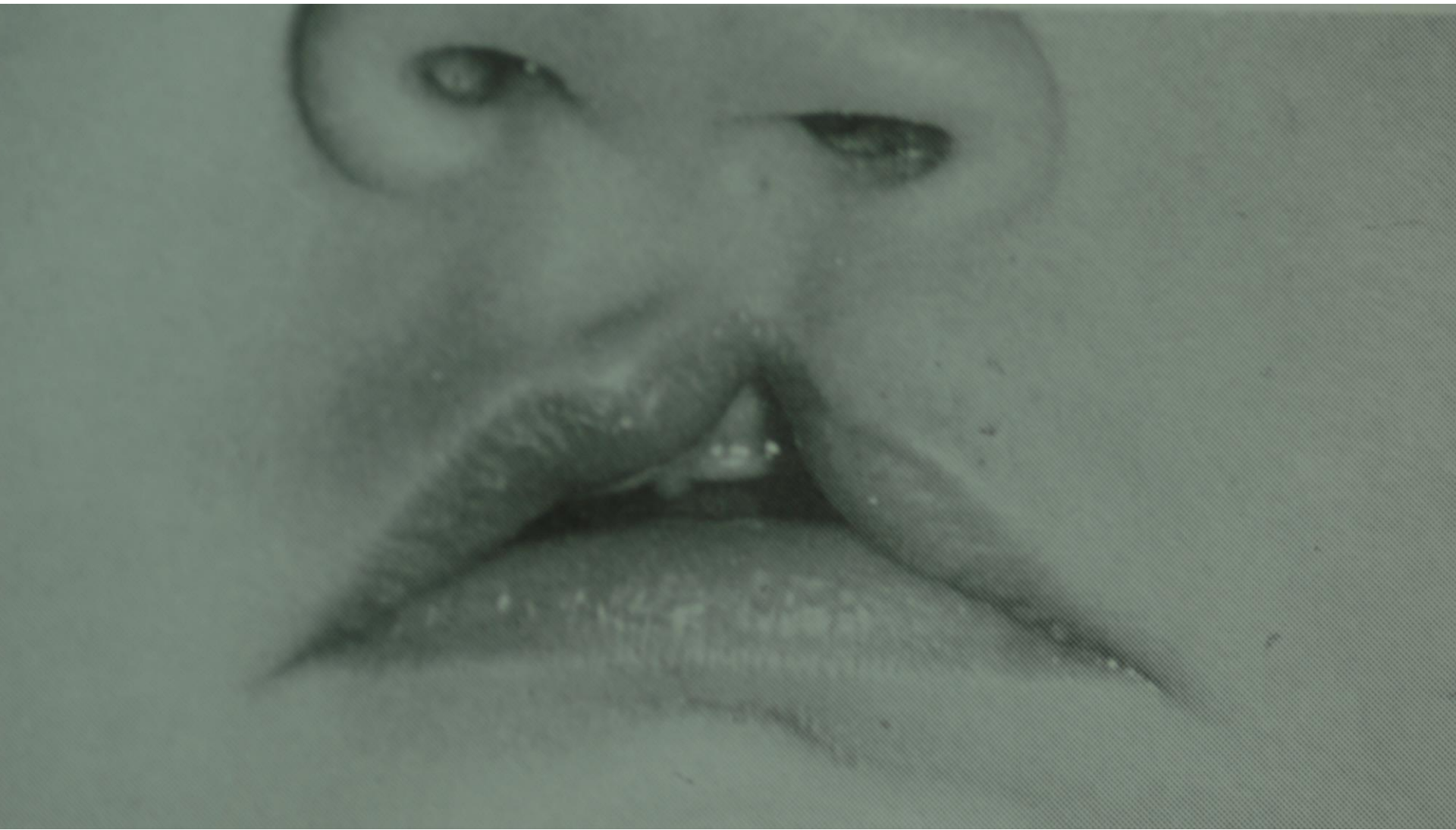FINAL STAGE

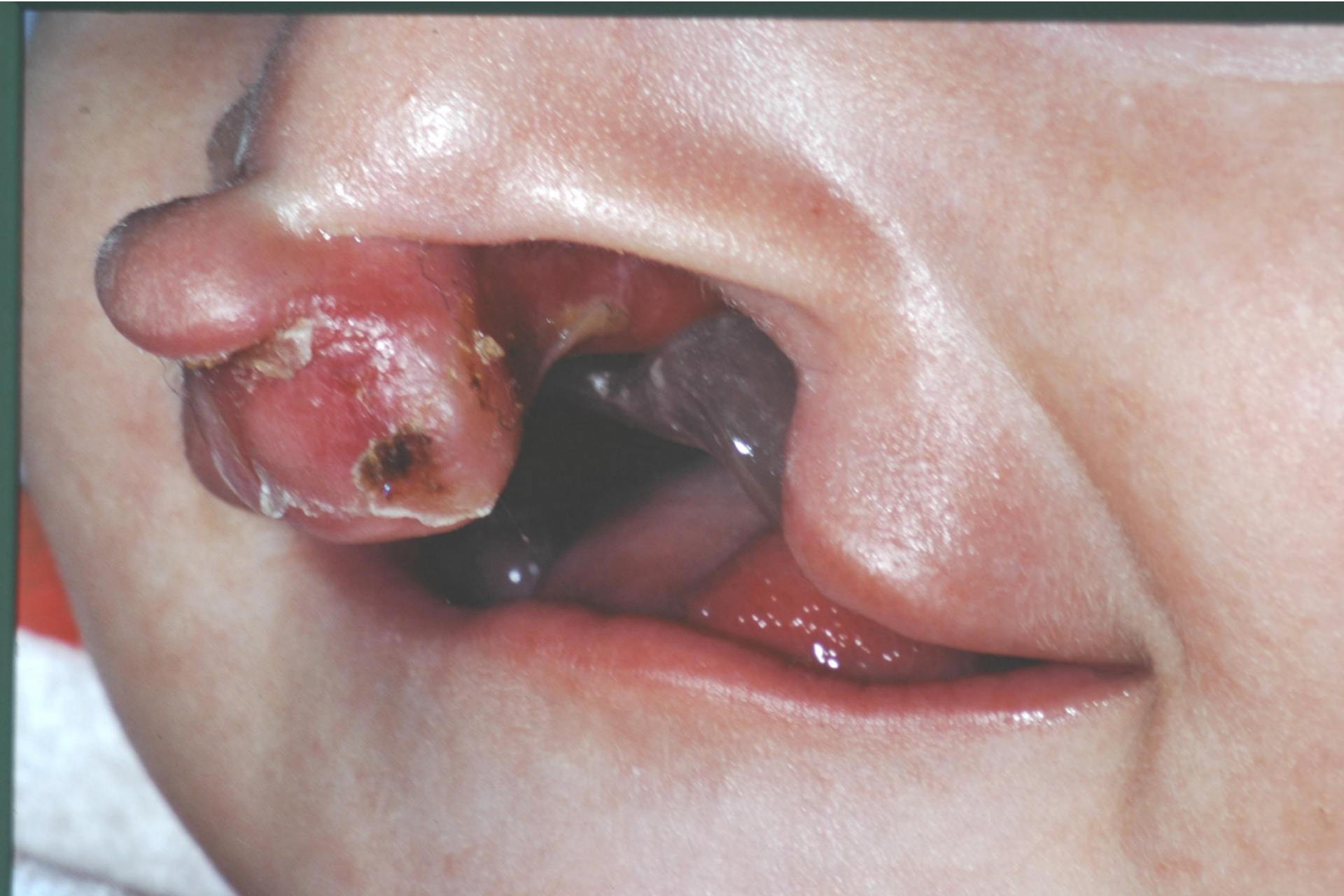


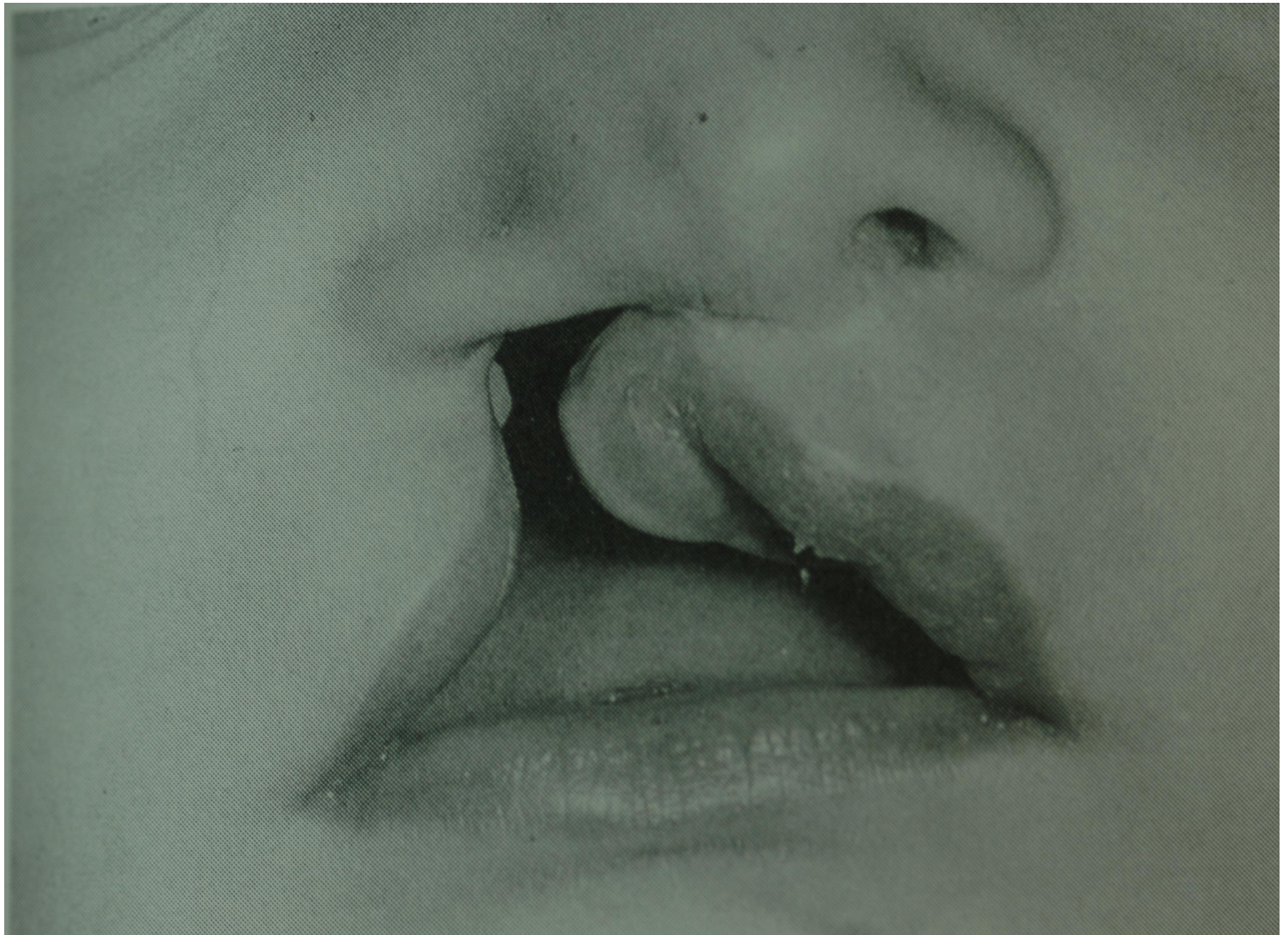


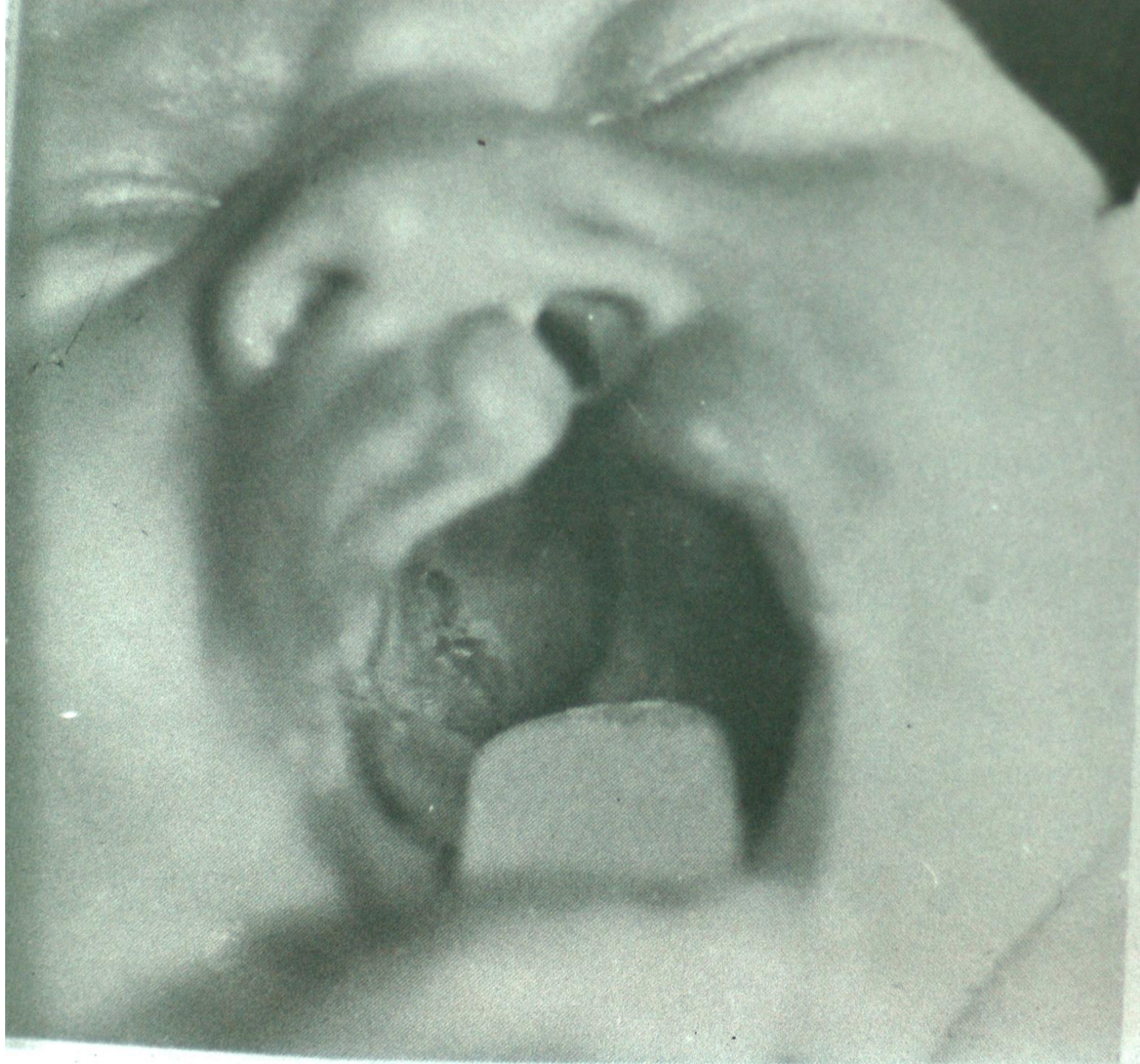


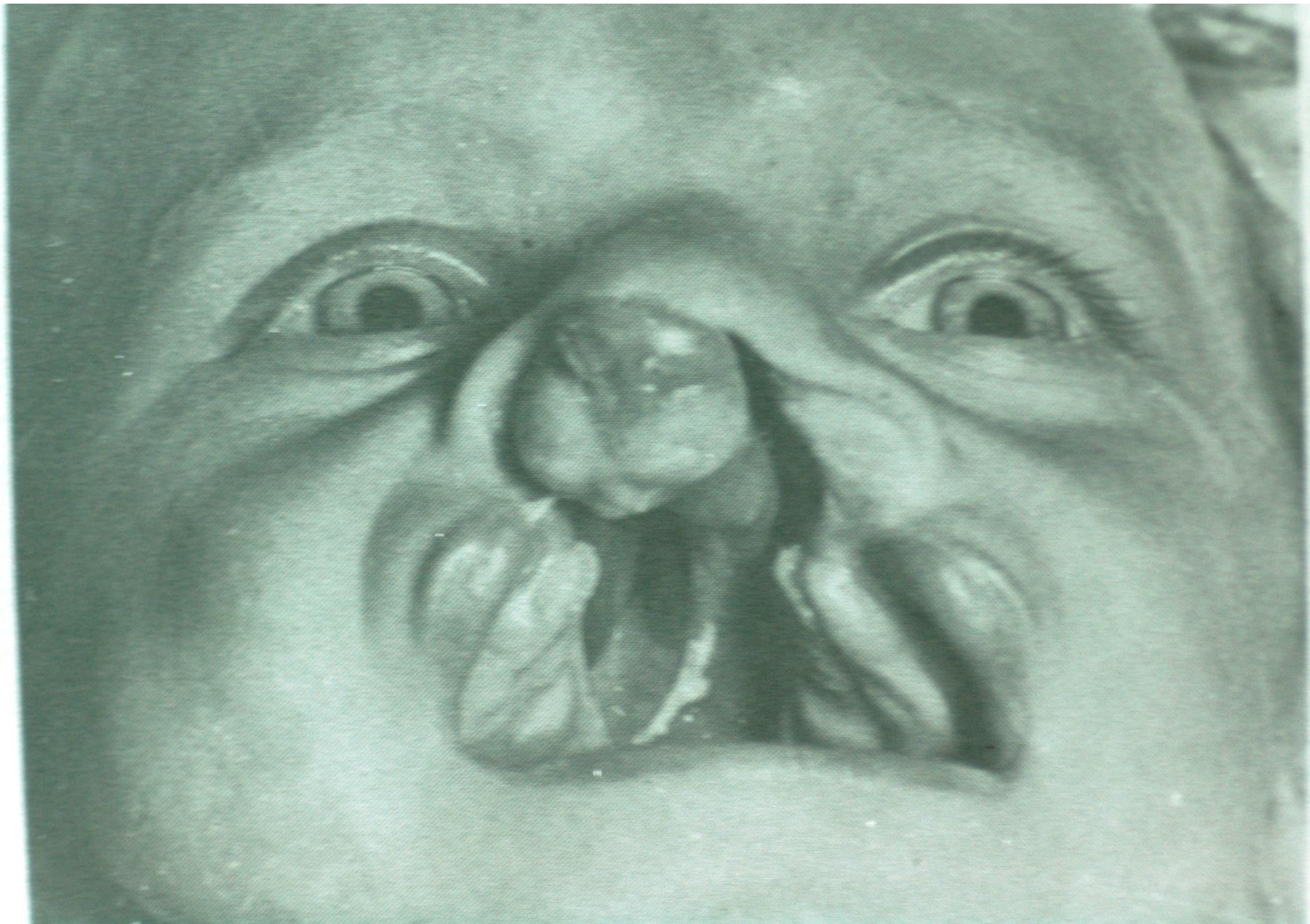










CLEFT LIP



CLASS I



CLASS II



CLASS III



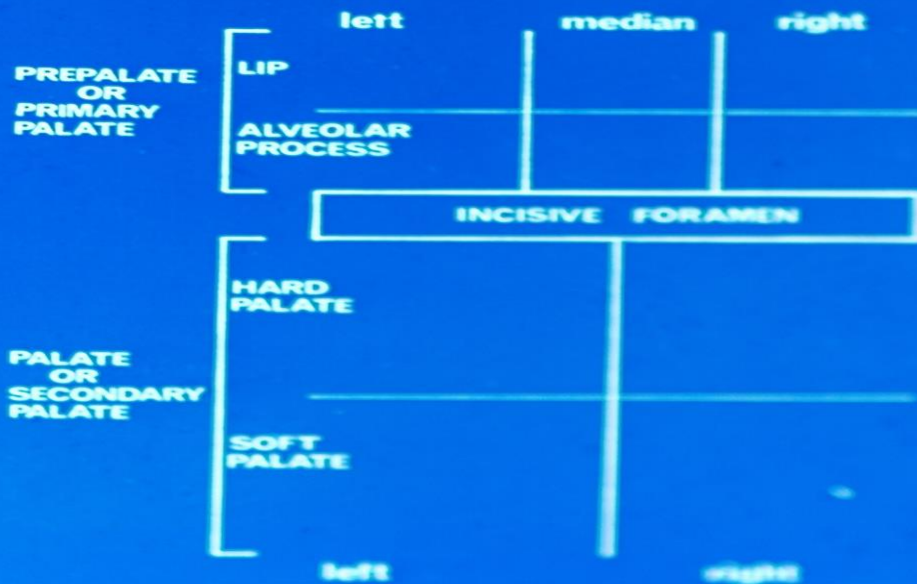
CLASS IV

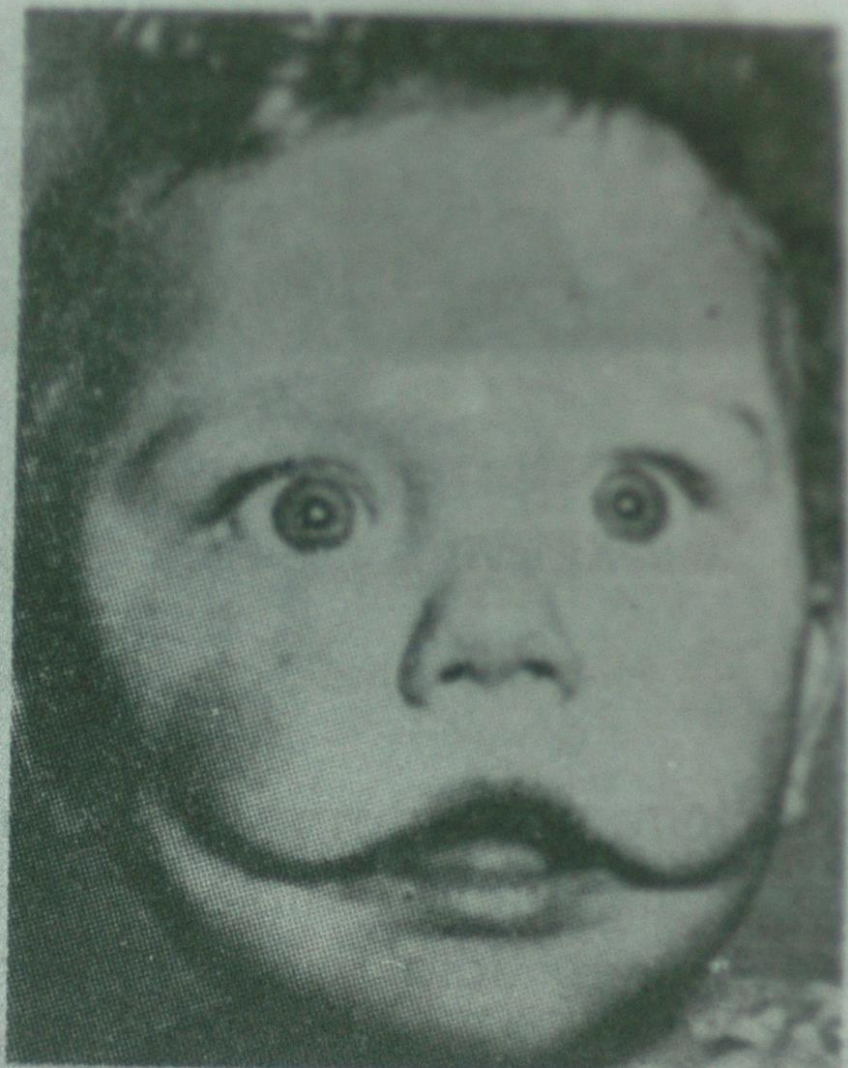
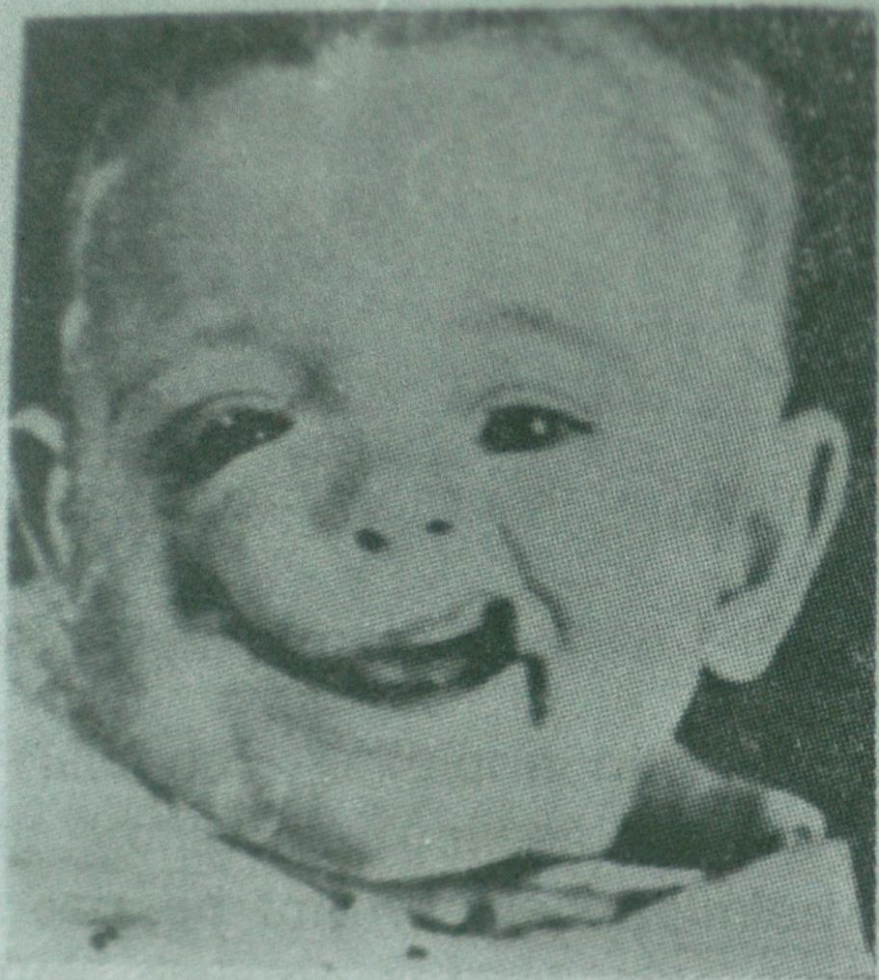
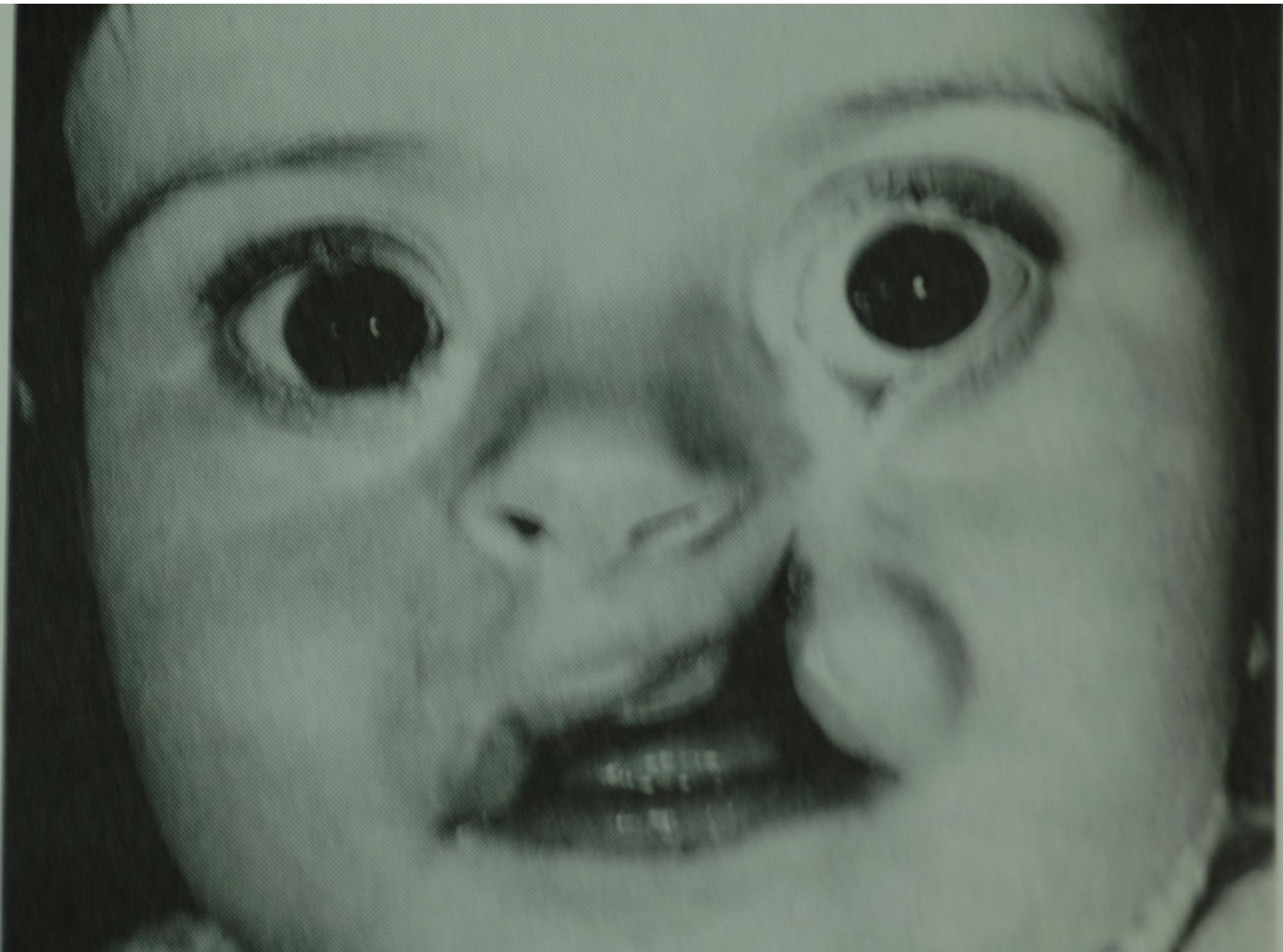
MID-LINE CLEFT PALATE

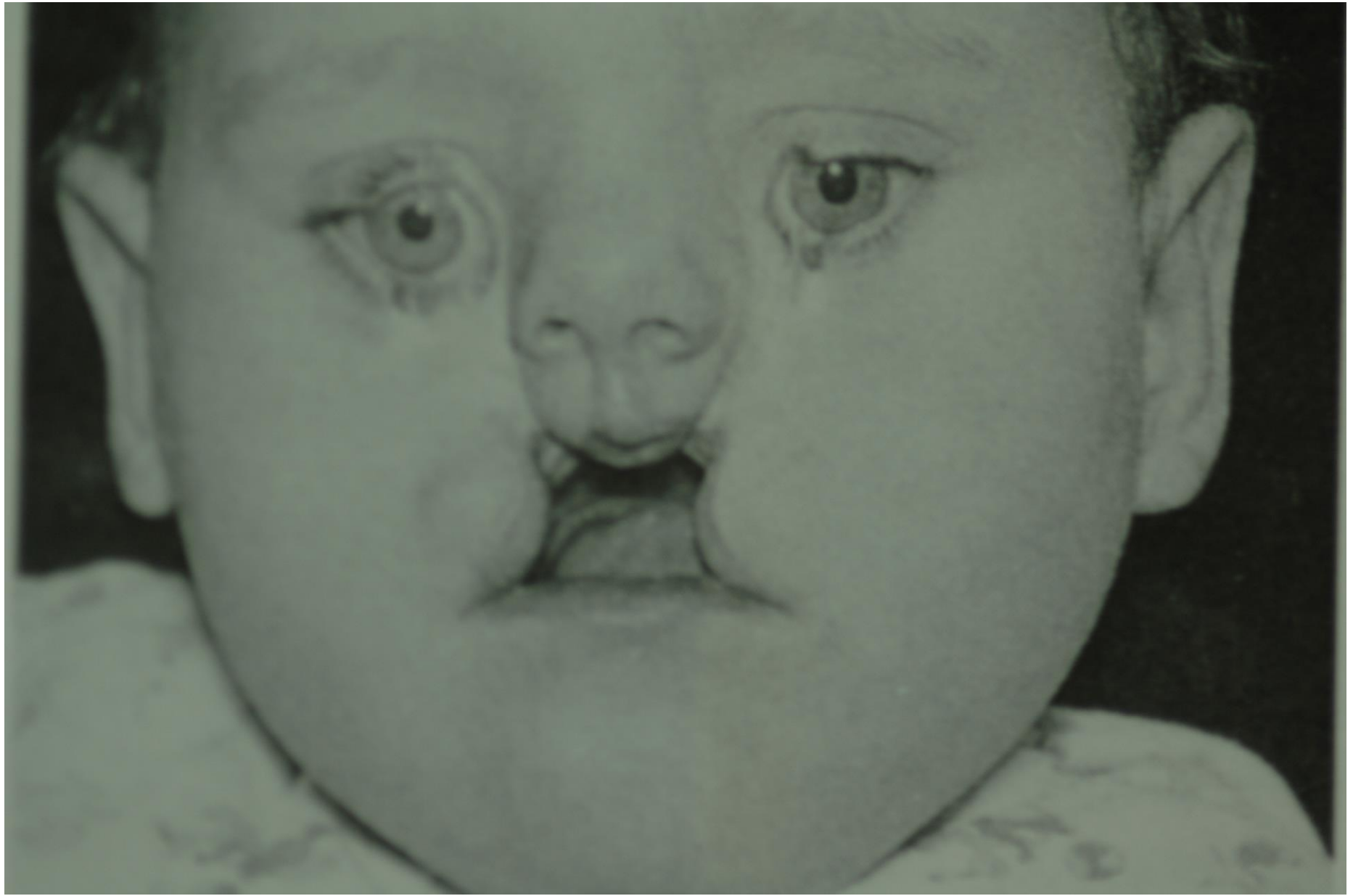

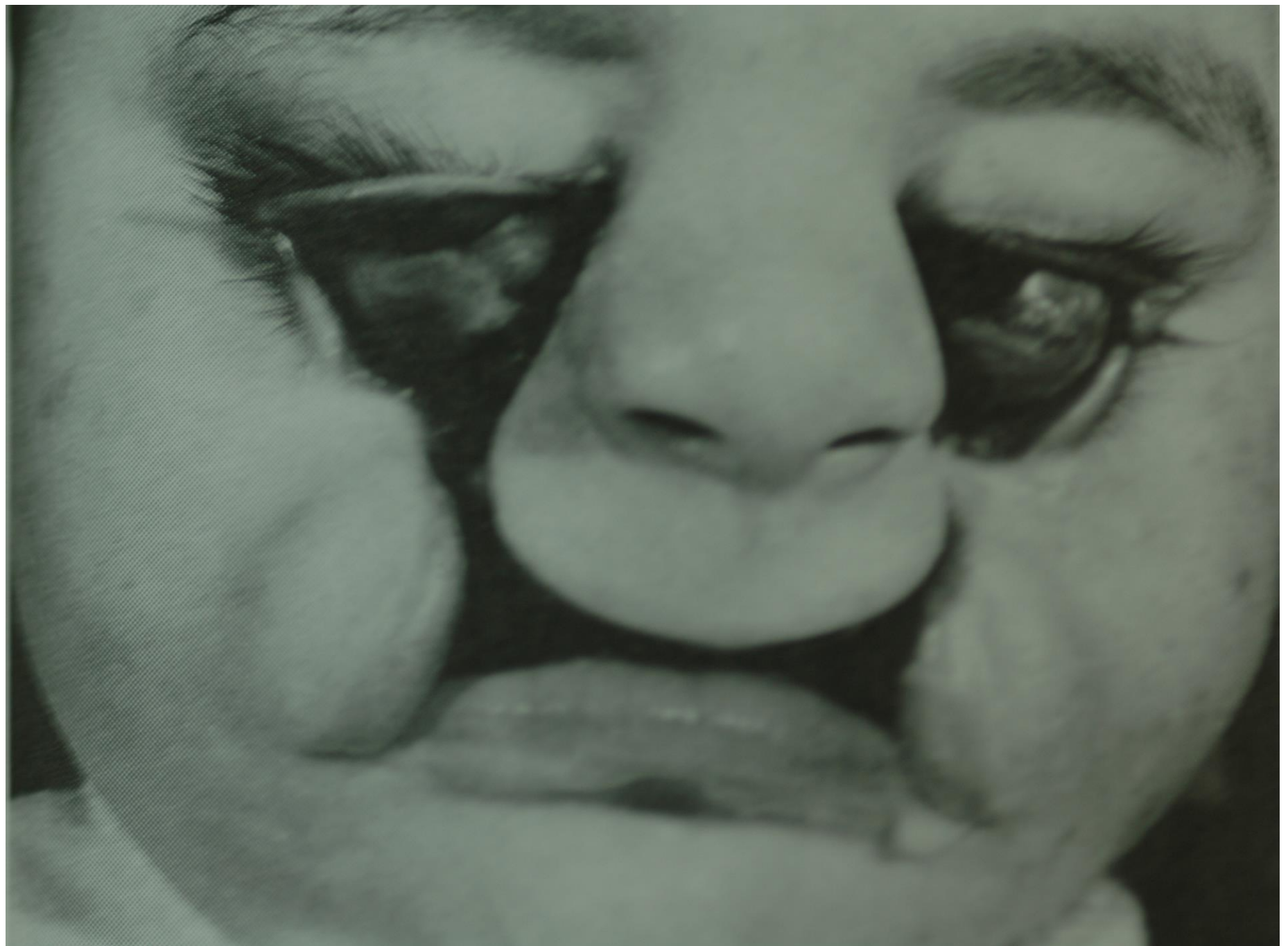
ALVEOLAR RIDGE

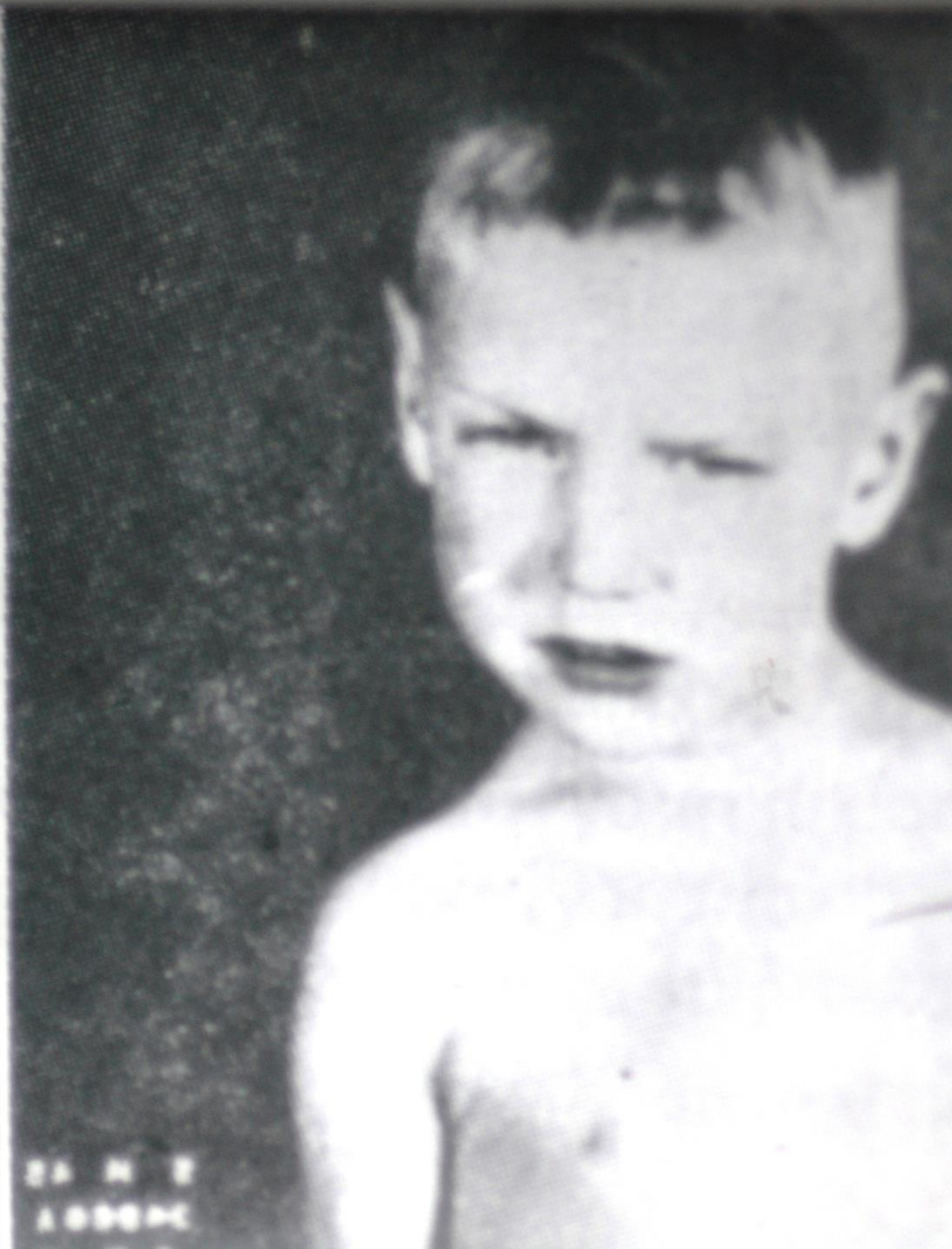
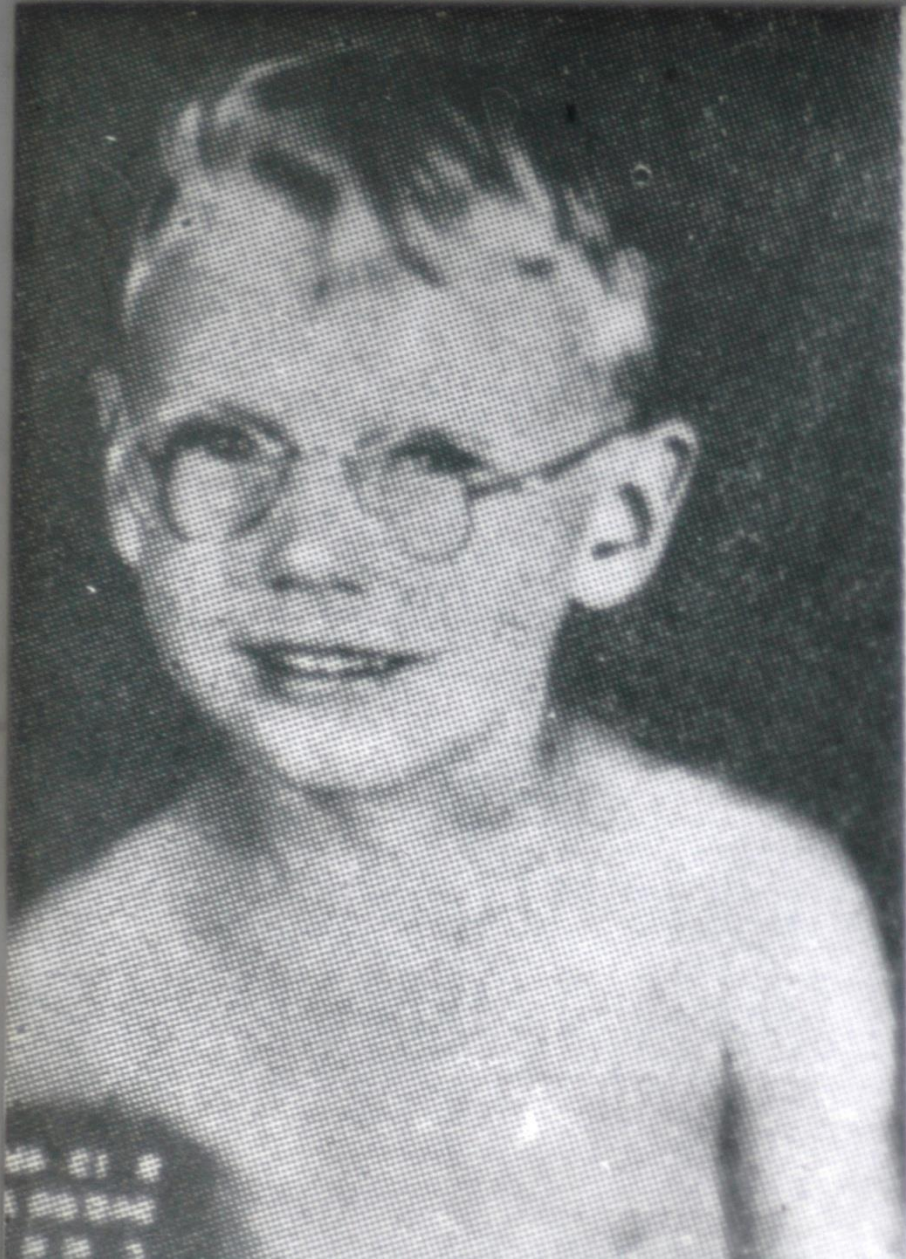


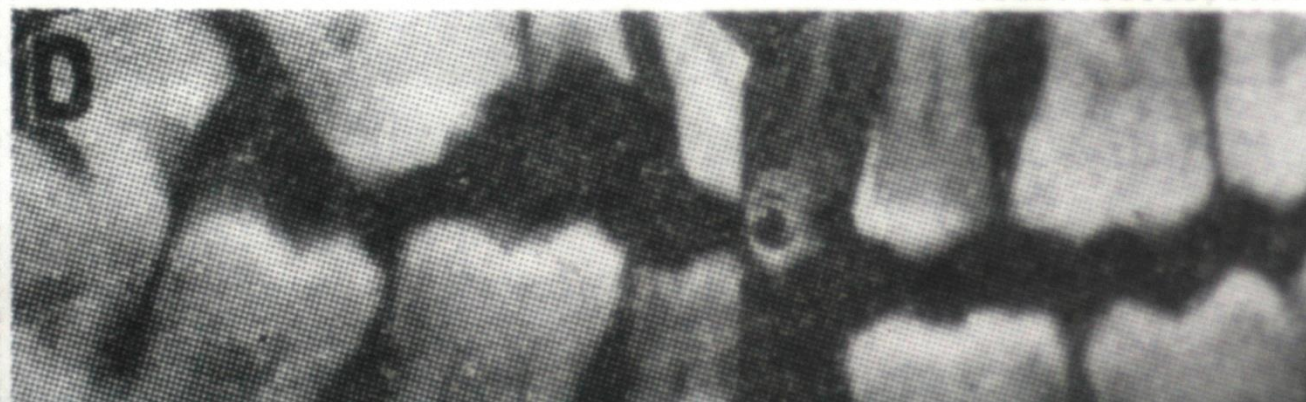
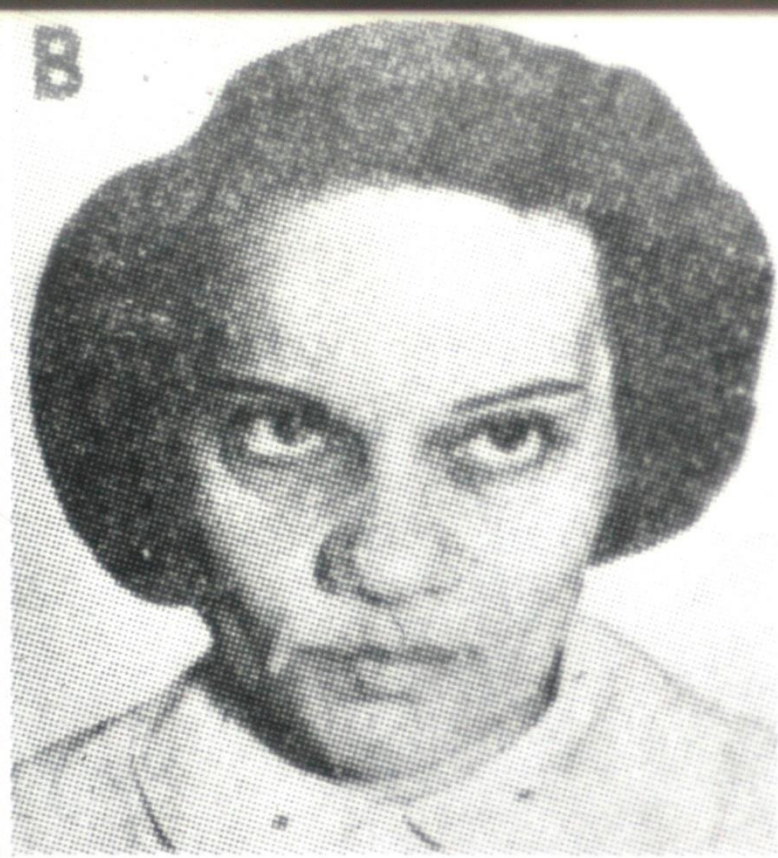


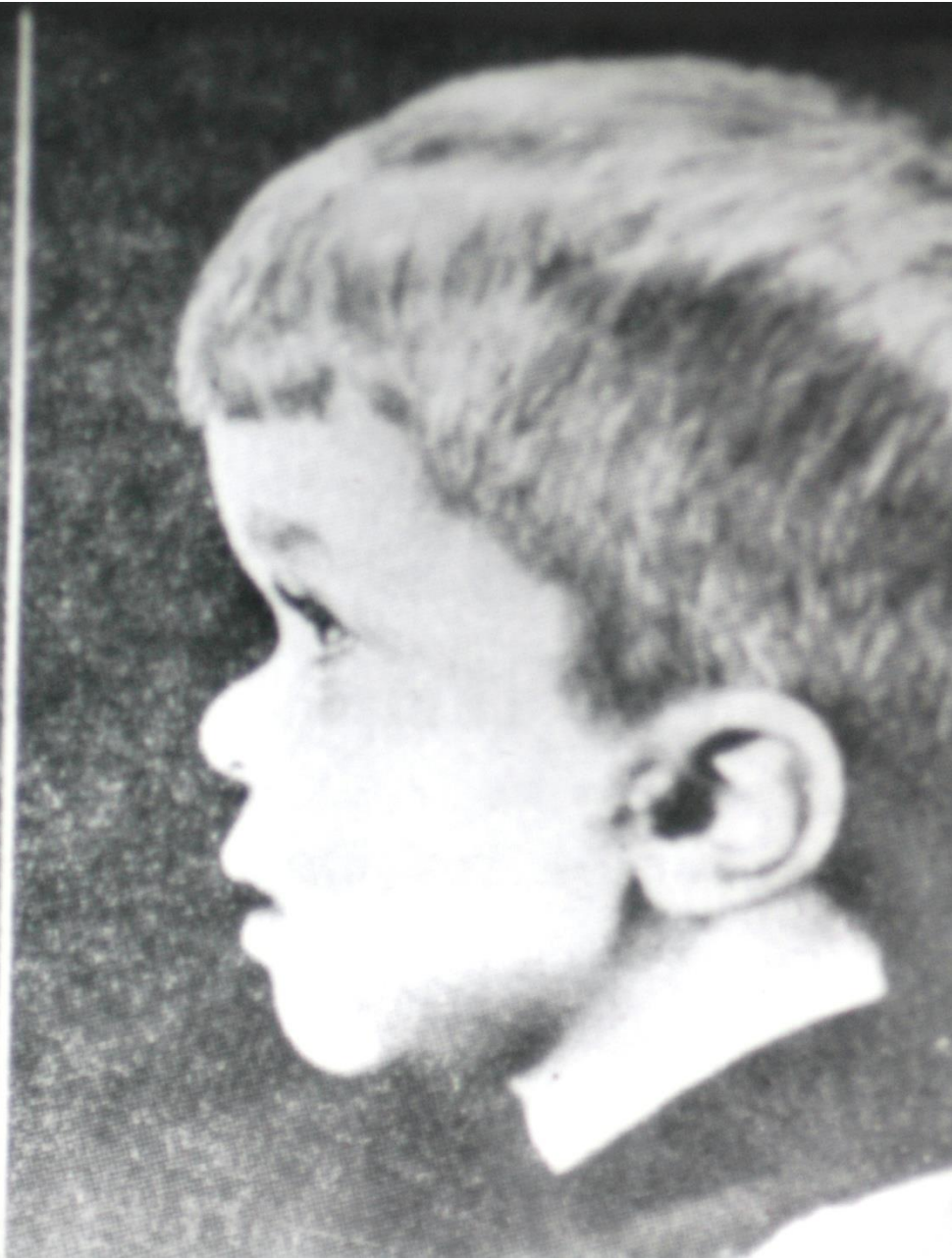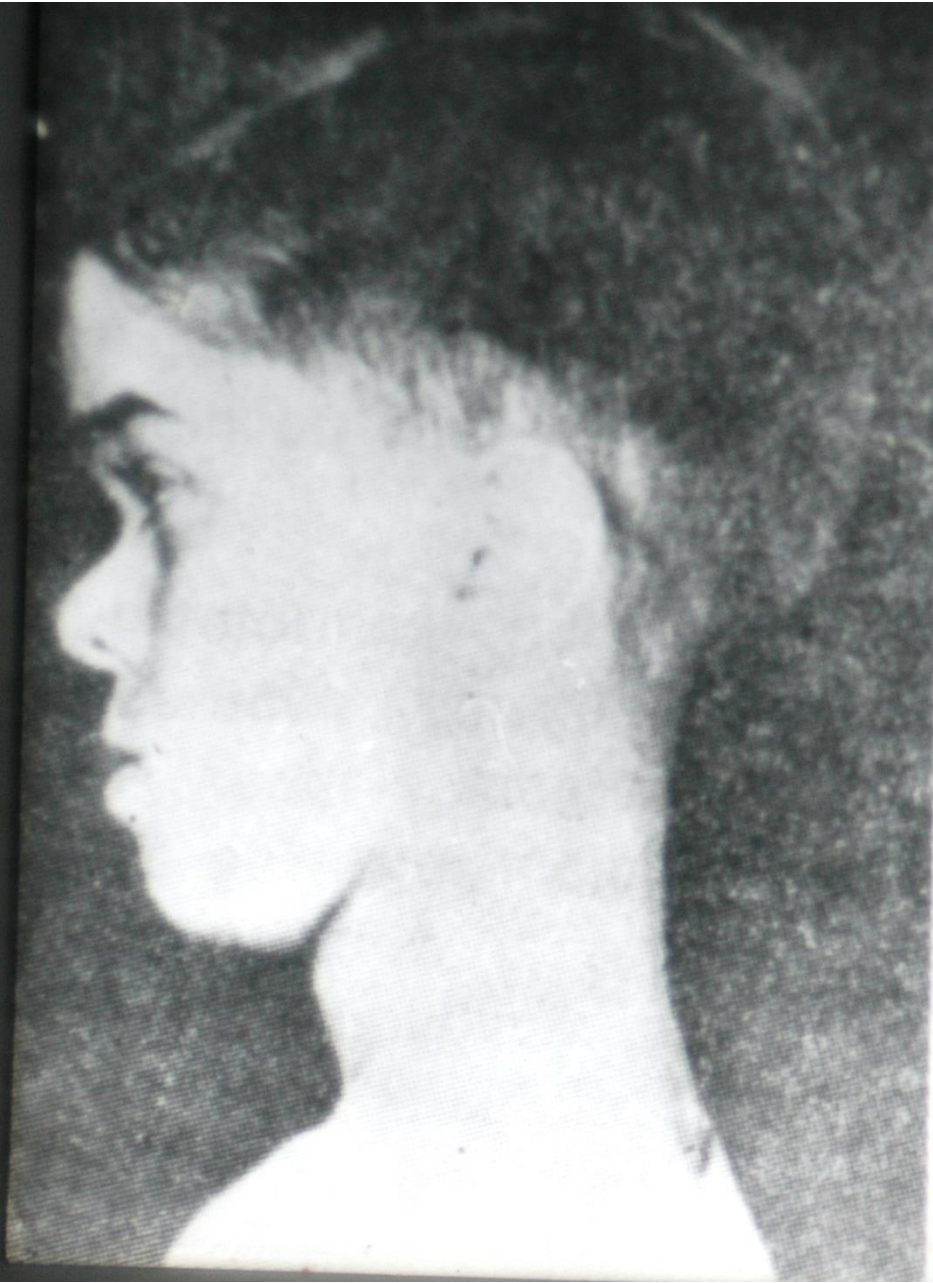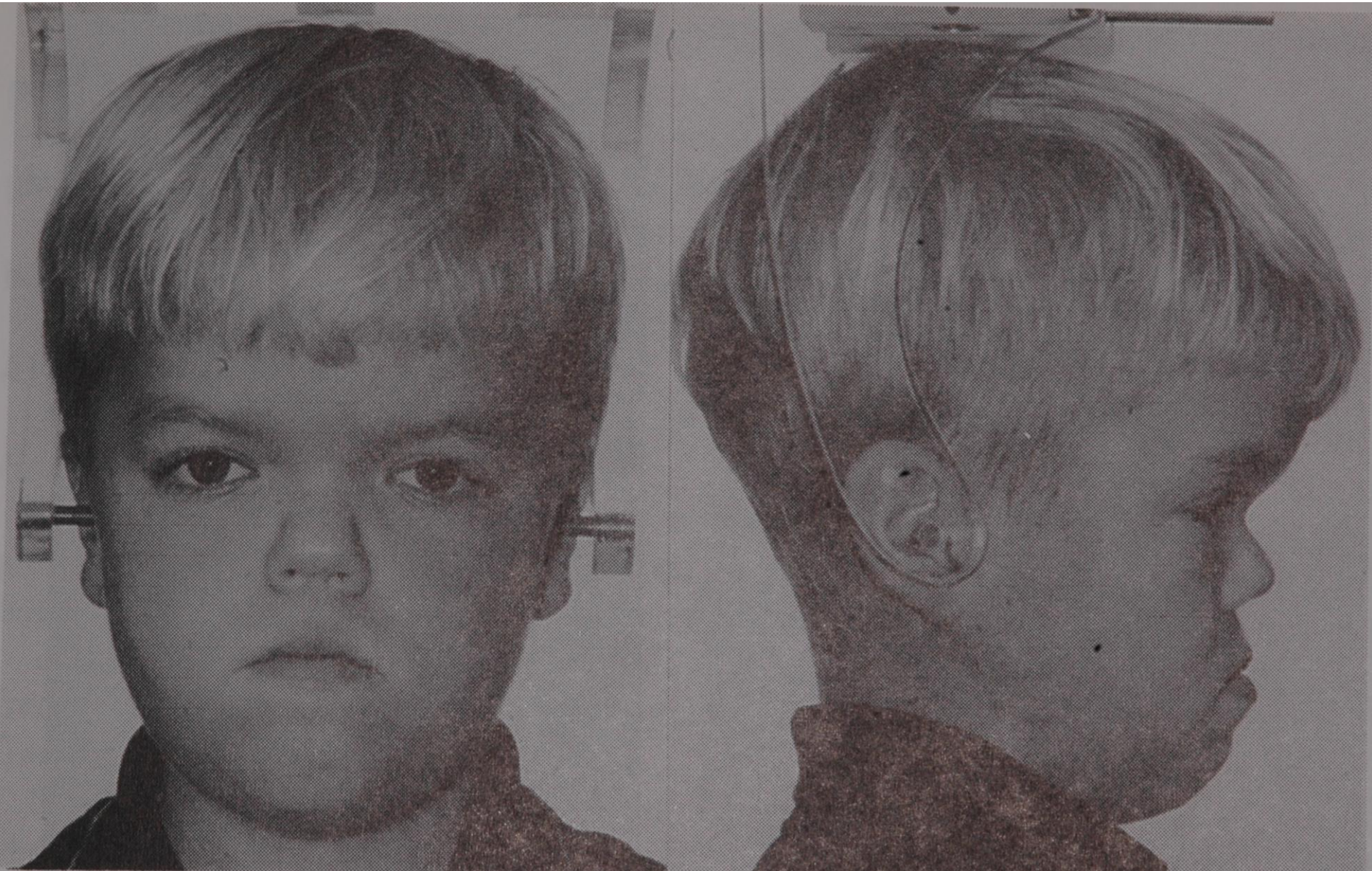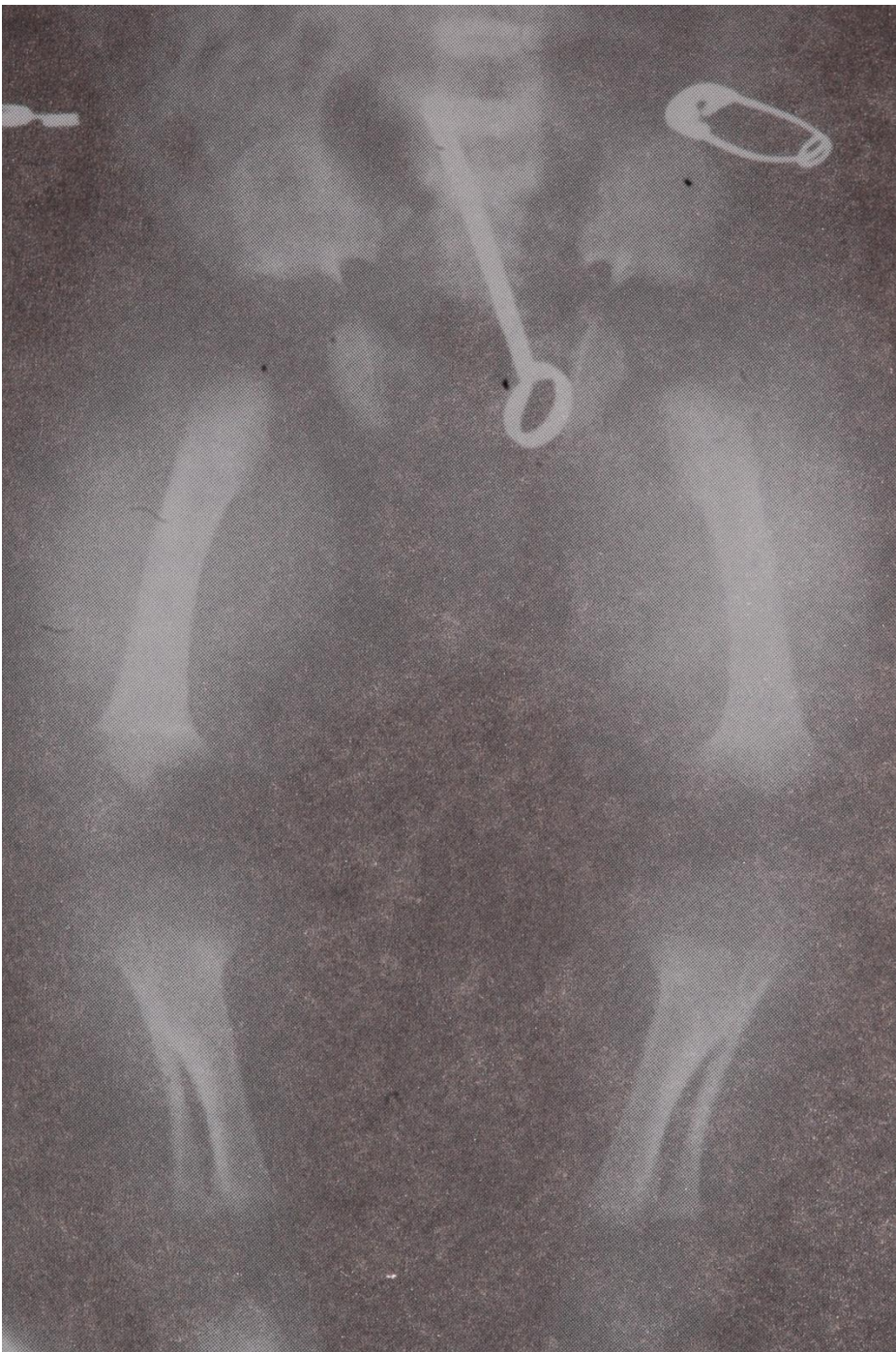




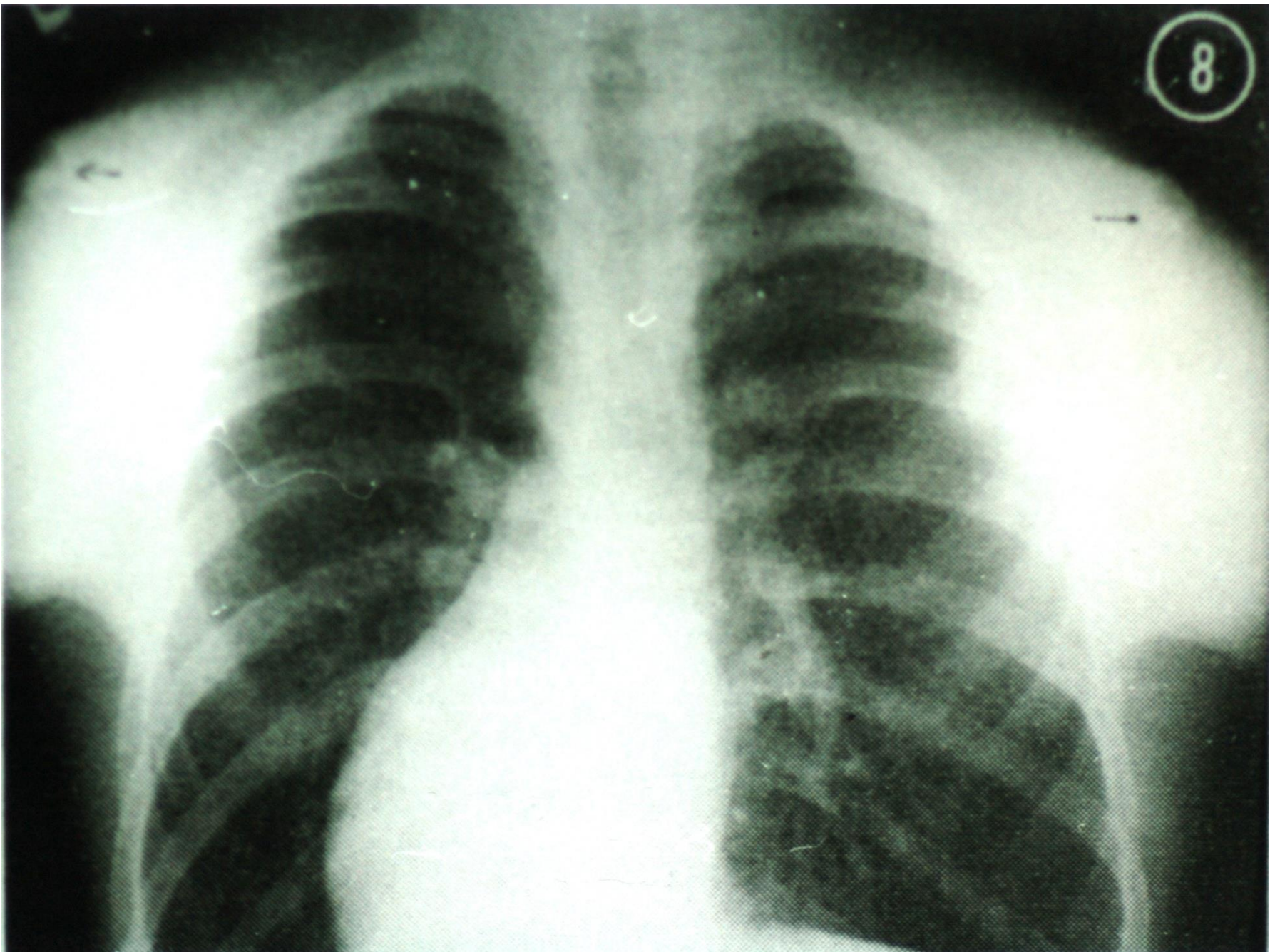






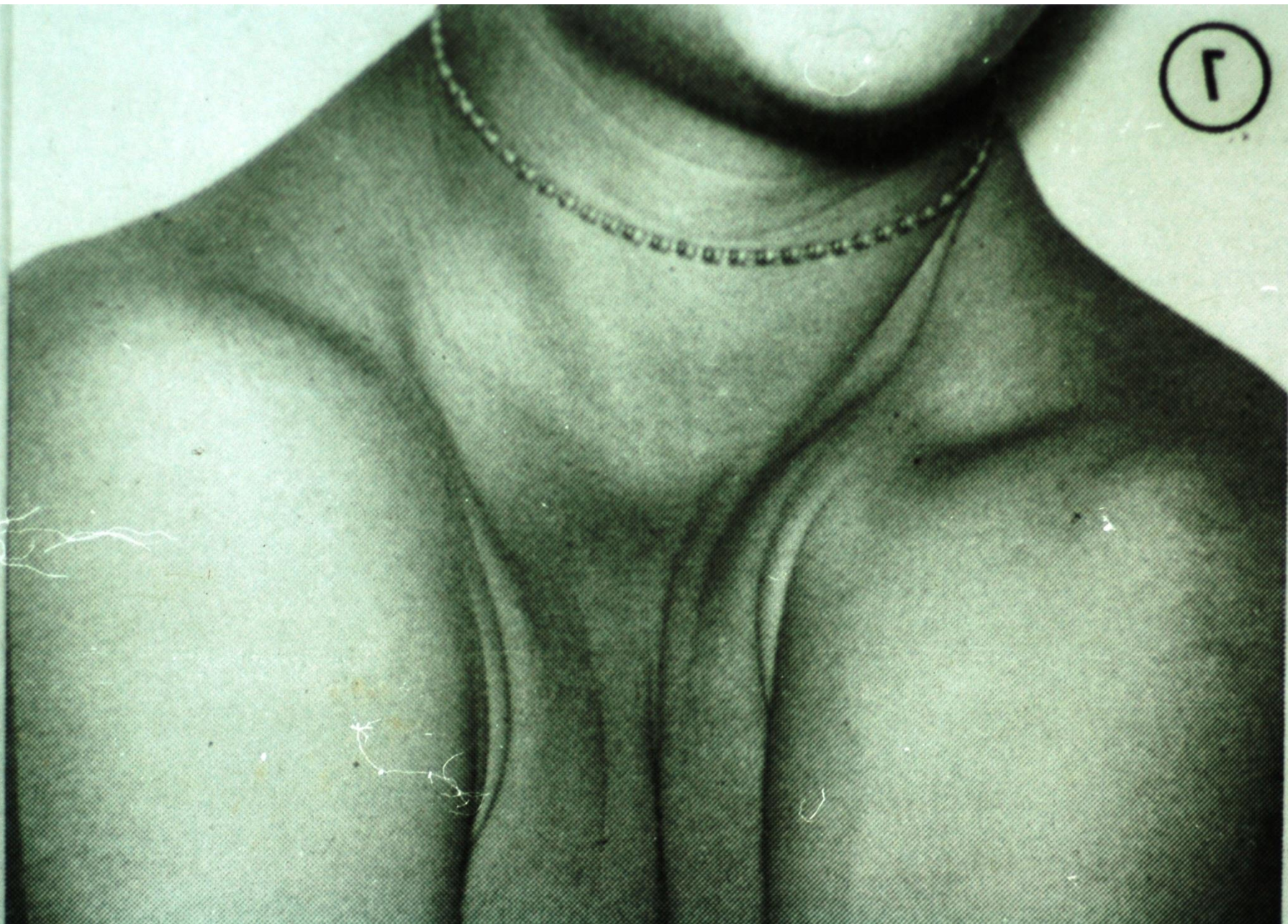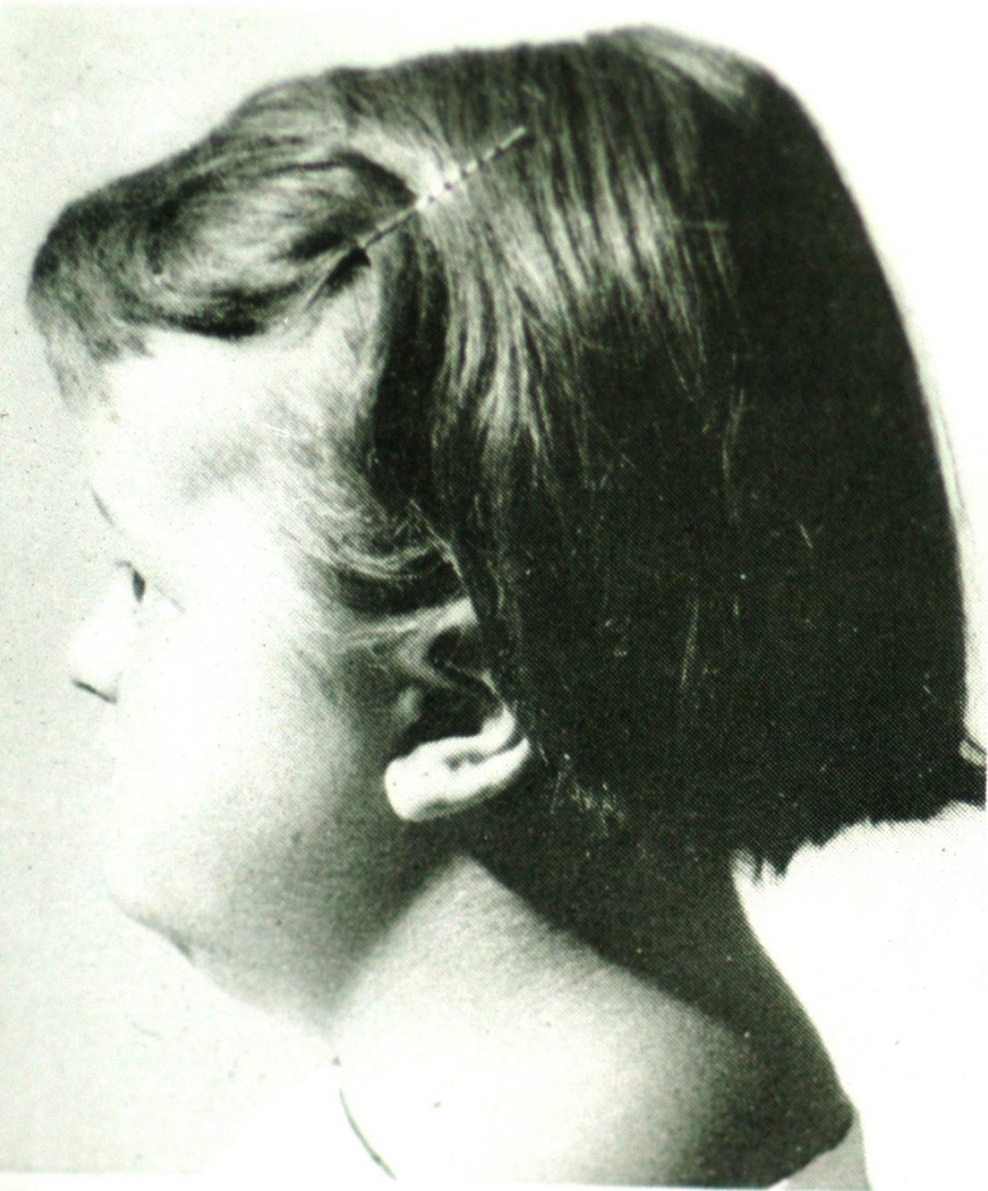


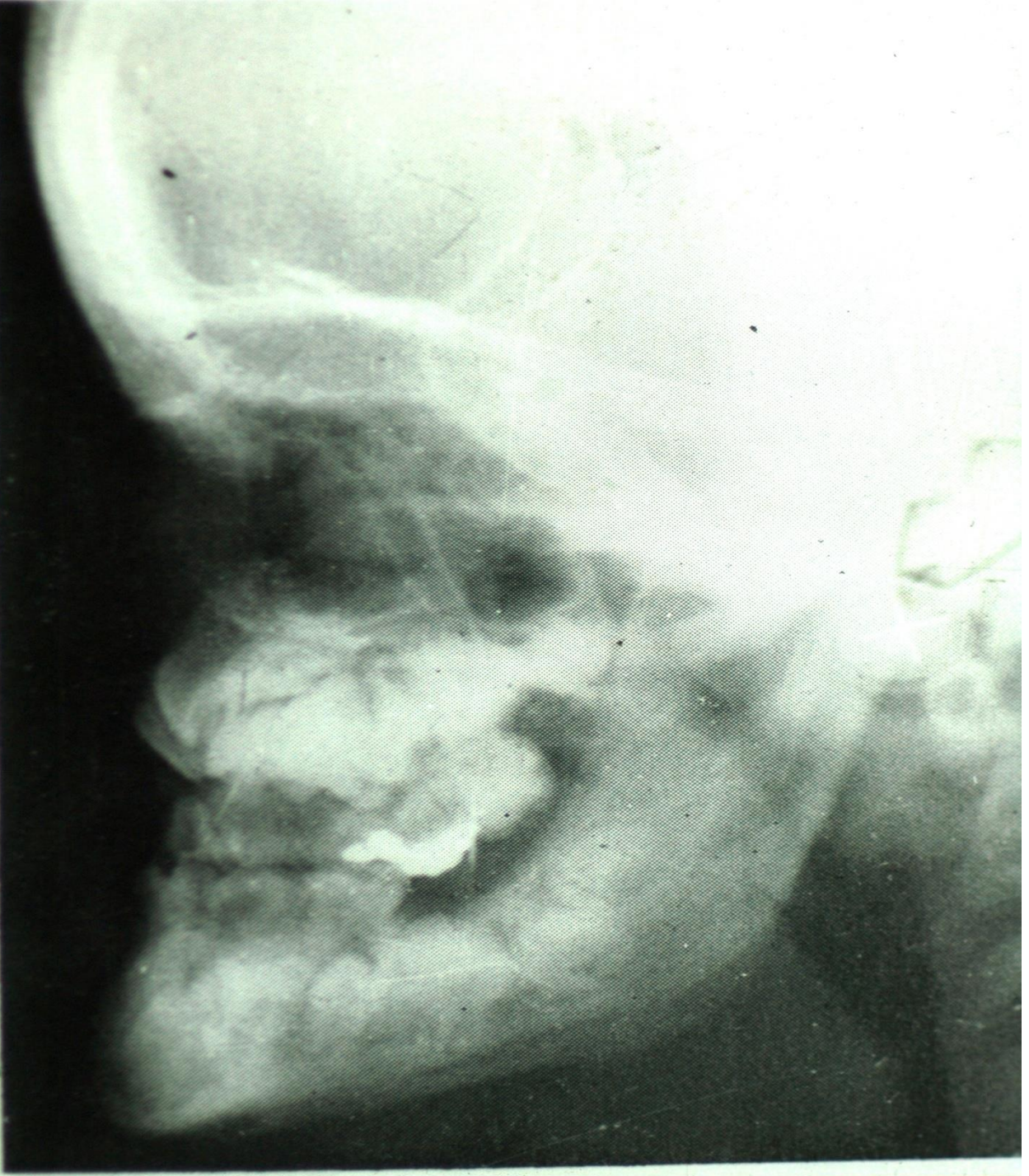8



①







3

