

SKELETON APPENDICULARE

OSSA MEMBRI THORACICI

- **Cingulum membri thoracici**

Scapula

Clavicula (fe.)

Os coracoïdes (evcil memeli hayv.yok)

*** Synsarcosis ***

1. **Stylopodium**

2. **Zeugopodium**

3. **Autopodium**

a – Basipodium

b – Metapodium

c – Acropodium

- Evcil memeli hayvanları yere basış şekillerine göre 3 gruba ayırırız :

1- Plantigrad

2- Digitigrad

3- Unguligrad

SCAPULA (K rek Kemigi)

Margo dorsalis
Margo caudalis
Margo cranialis
 Incisura scapulae
Angulus caudalis
Angulus ventralis
Angulus cranialis

Facies lateralis
Spina scapulae
 Tuber spinae scapulae (su.,eq.)
 Acromion (car.,ru.)
 Proc. hamatus (car.)
Proc. suprahamatus (fe.)
Fossa supraspinata
Fossa infraspinata
Facies costalis
Facies serrata
Facies subscapularis

Cavitas glenoidalis (fossa articularis)
 Inc. glenoidalis (inc. fossae articularis)
- Collum scapulae
 Tuberculum supraglenoidale
 Tuberculum infraglenoidale
 Processus coracoideus
- Cartilago scapulae

HUMERUS (Kol Kemiği)

Caput humeri

Collum humeri

Tuberculum majus

Tuberculum minus

Sulcus intertubercularis

Tuberculum intermedium

Corpus humeri

Tuberositas deltoidea

Sulcus m.brachialis

Condylus humeri

Trochlea humeri

Capitulum humeri (car., lateral)

Fossa olecrani

Fossa radialis

Epicondylus lateralis et medialis


For.supratrochleare (ca.)

For.supracondylare (fe)

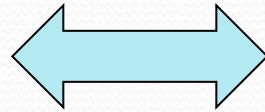
OSSA ANTEBRACHII
(ön kol kemikleri)

RADIUS

ULNA



Pronatio
Supinatio



RADIUS

caput radii
fovea capitis radii
collum radii
tuberositas radii
corpus radii
facies cranialis, facies caudalis
margo lateralis, margo medialis
trochlea radii
facies articularis carpea
crista transversa
proc. styloideus medialis et lateralis
inc. ulnaris (car.,su.)

ULNA

Olecranon
tuber olecrani
proc. anconeus
incisura radialis
proc. coronoideus medialis et lateralis
incisura trochlearis
circumferantia articularis (car.,su.)
Corpus ulnae
Caput ulnae (distal uç, eq.yok)
proc. styloideus lateralis (ru.)
spatium interosseum antebrachii (eq.)
spatium interosseum antebrachii proximale et distale (ru.)

SKELETON MANUS

- **OSSA CARPI** (ön ayak bilek kemikleri)
- **OSSA METACARPALIA** (ön ayak tarak kemikleri)
- **OSSA DIGITORUM MANUS** (ön ayak parmak kemikleri)

OSSA CARPI

Os carpi radiale
Os carpi intermedium
Os carpi ulnare
Os carpi accessorium

Os carpale primum
Os carpale secundum
Os carpale tertium
Os carpale quartum

Car.

1	2	3	4
1	2	3	4

Eq.

1	2	3	4
	2	3	4

Ru.

1	2	3	4
	2	3	4

Sulcus carpi

OSSA METACARPALIA

Os metacarpale primum
Os metacarpale secundum
Os metacarpale tertium
Os metacarpale quartum
Os metacarpale quintum

- Basis
- Trochlea (caput)
- Tuberositas ossis metacarpalia III
- Verticillus
- Sulcus longitudinalis dorsalis (Ru.)
- Incisura intertrochlearis (intercapitalis)(Ru.)

OSSA DIGITORUM MANUS

Car. : 5 , Su. : 4 , Ru. : 2 , Eq : 1

Phalanx proximalis

Trigonum phalangis proximalis

Phalanx media

Tuberositas flexoria (torus palmaris) (ru.,eq.)

Phalanx distalis (eq.)

Facies parietalis

Sulcus parietalis lateralis et medialis

Proc. palmaris lateralis et medialis

Facies articularis

Facies solaris

Facies flexoria (m.flex.digit.profundus)

Linea semilunaris

Planum cutaneum

Sulcus solearis lateralis et medialis

For. soleare laterale et mediale

Canalis solearis

Margo coronalis

Proc. extensorius

Margo solearis

Facies axialis

Facies abaxialis

(car.,su.,ru.)

OSSA SESAMOIDEA

Ossa sesamoidea proximalia
Os sesamoideum distale
Ossa sesamoidea dorsalia (ca.)