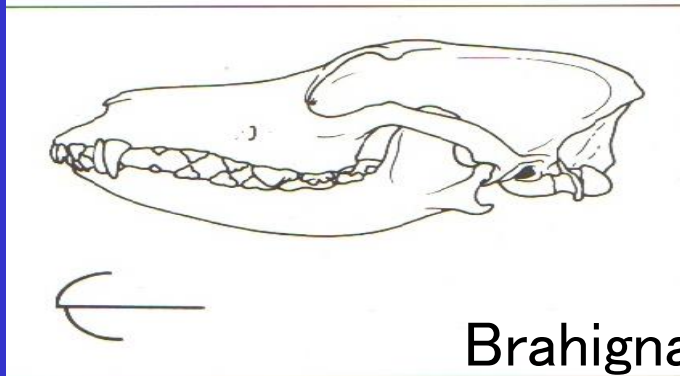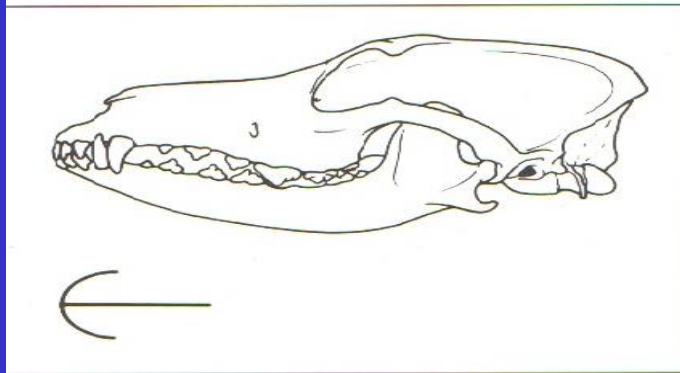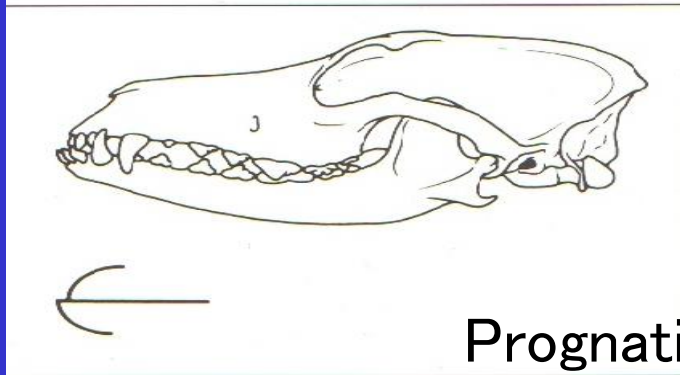


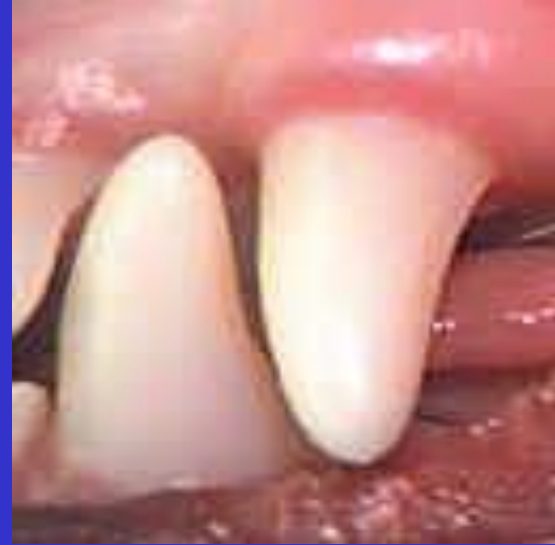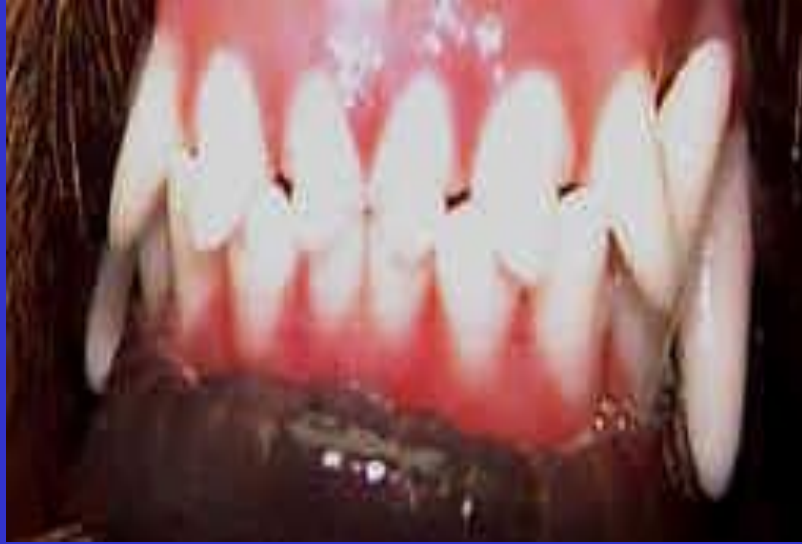Brahignati – Sazan balığı



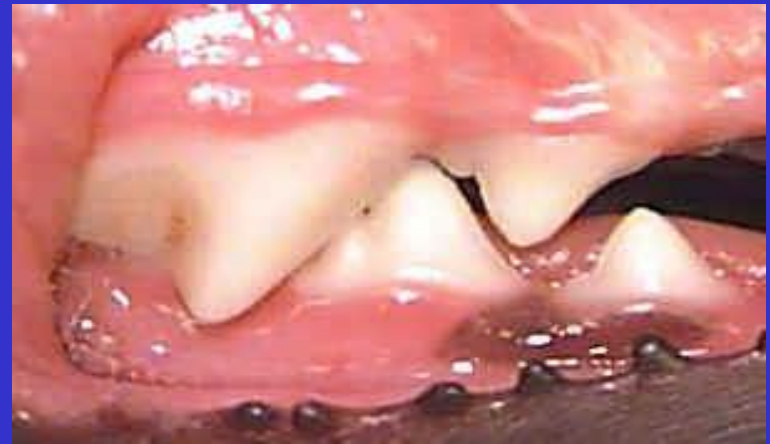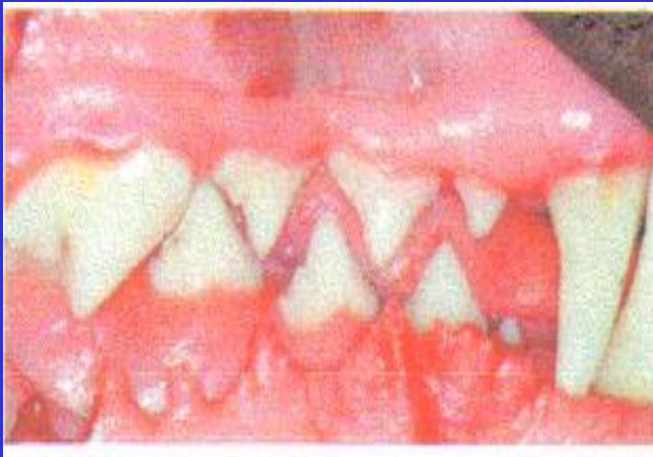Prognati – Turna balığı

Fig. 1.2 Occlusion and malocclusions: lateral view of skulls with diagrams representing the lip shapes. Top: Normal, class I bite. Centre: brachygnathic, class II bite, also known as retrusive or vershot. Bottom: Prognathic, class III bite, also known as protrusive or undershot.

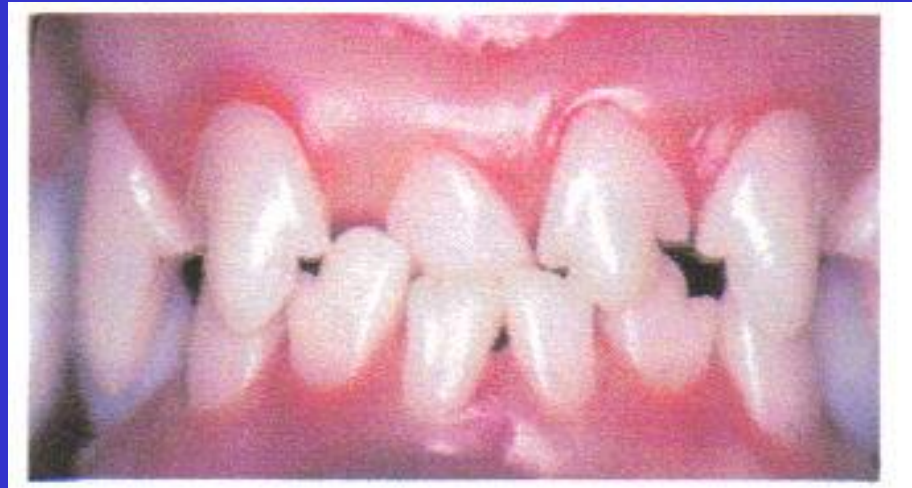KESİCİ VE KANİN DİŞLERİN NORMAL OKLUZYONU



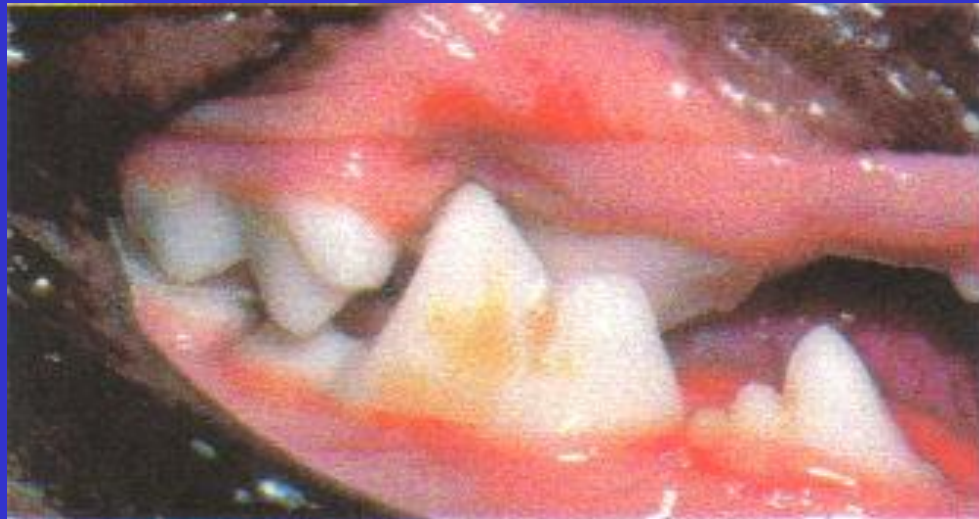PREMOLAR VE MOLAR DİŞLERİN NORMAL OKLUZYONU



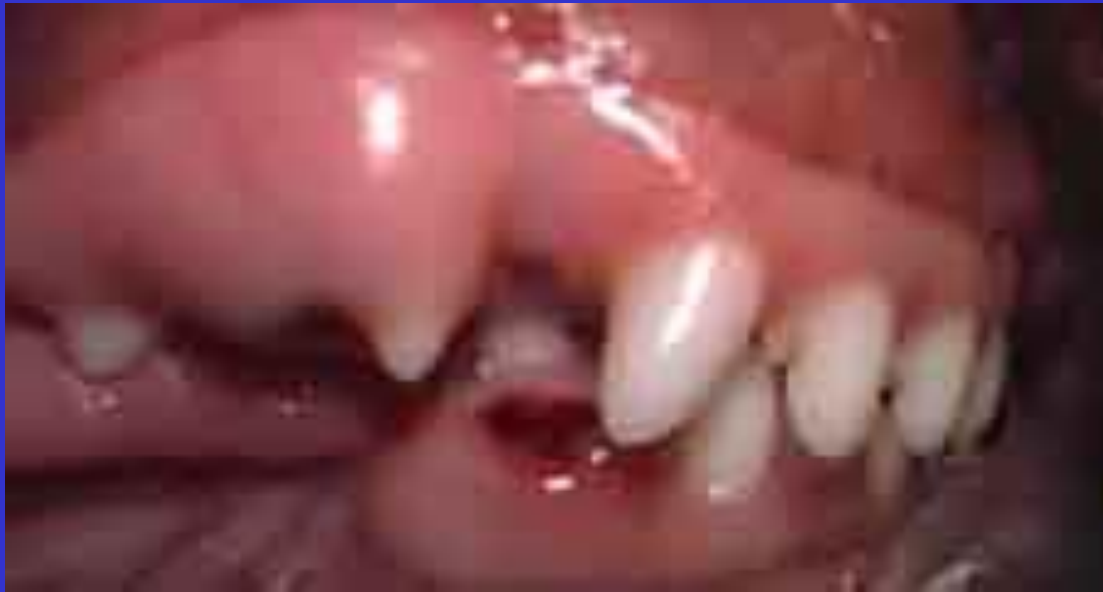ANTERIOR CROSSBITE



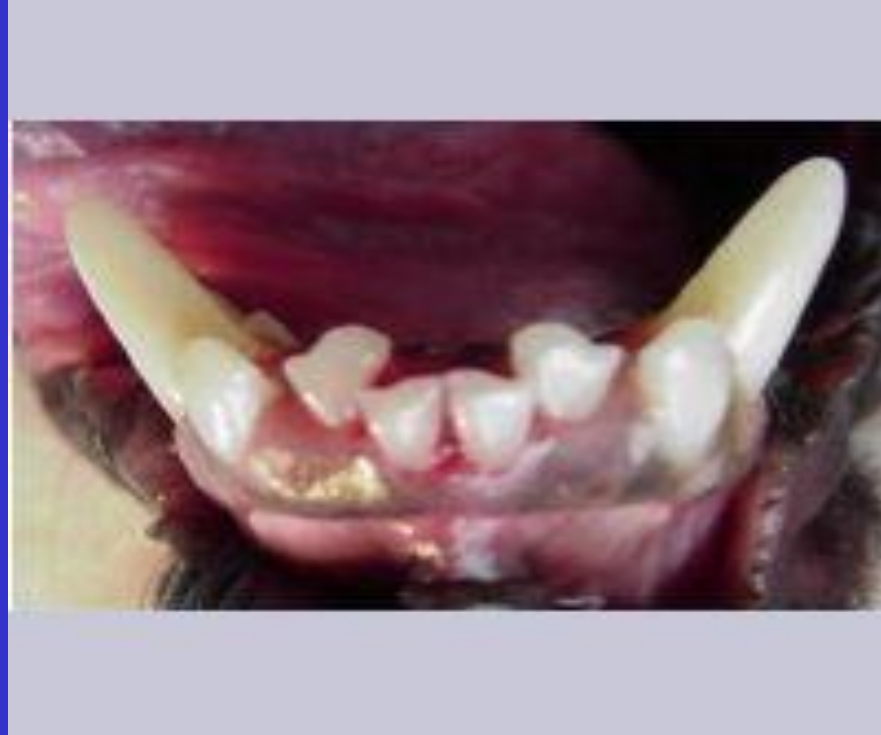POSTERIOR CROSSBITE

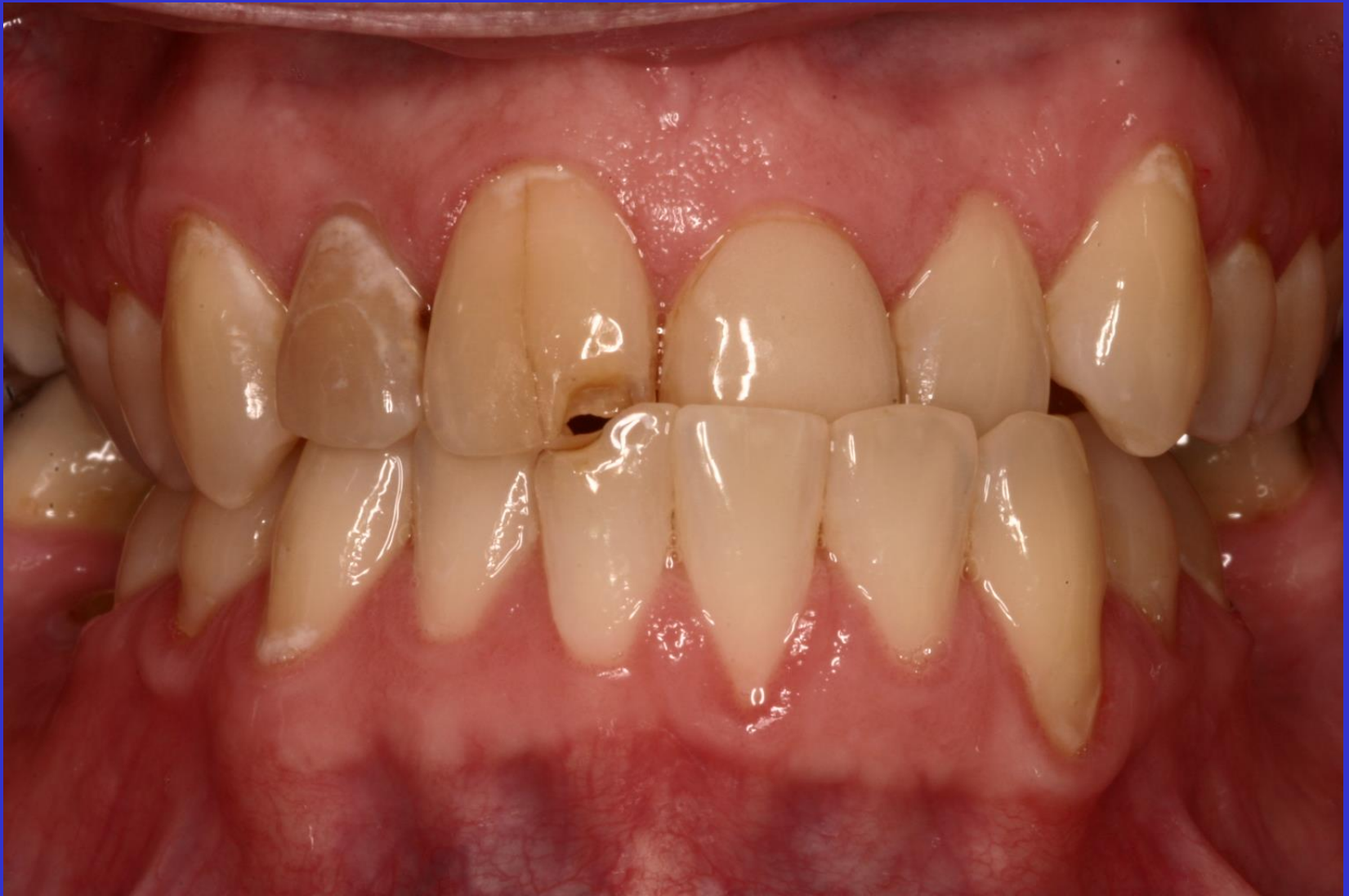

DAR MANDIBULA

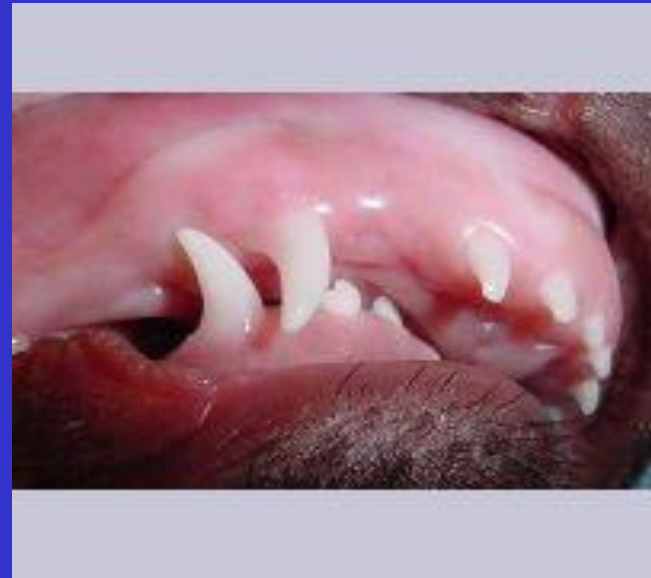
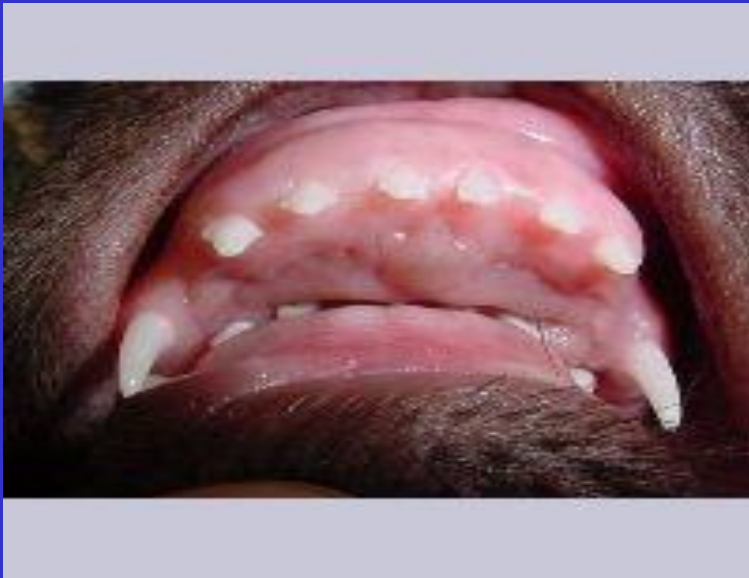
ÇAPRAŞIK YADA DÖNMÜŞ DİŞLER

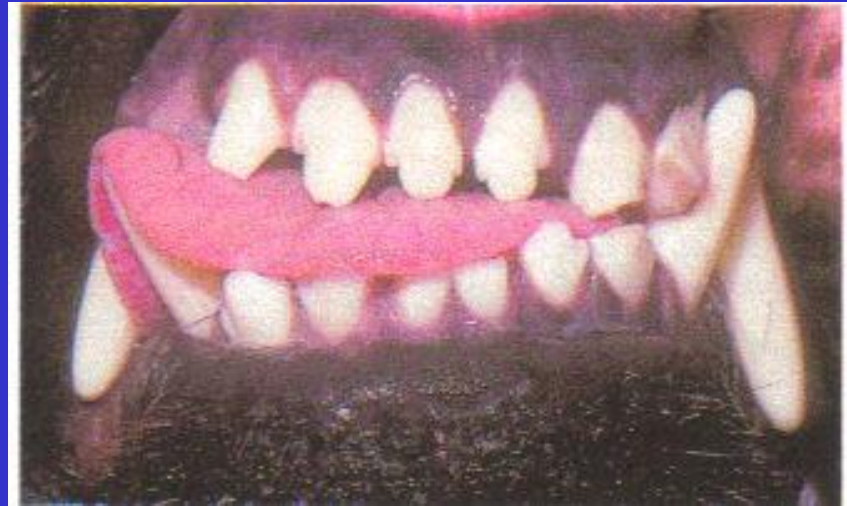



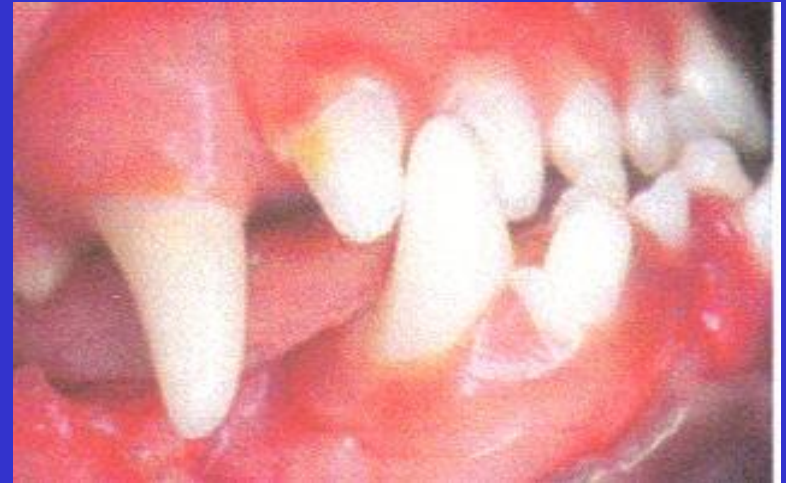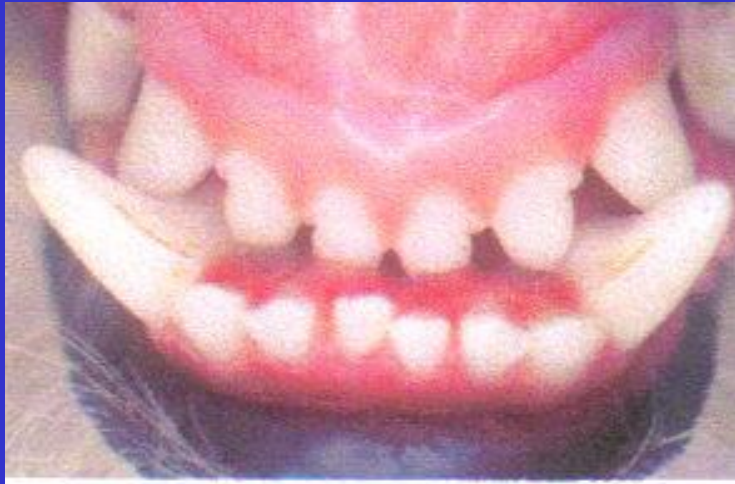KISA MANDIBULA MANDIBULAR BRACHYGNATHISM



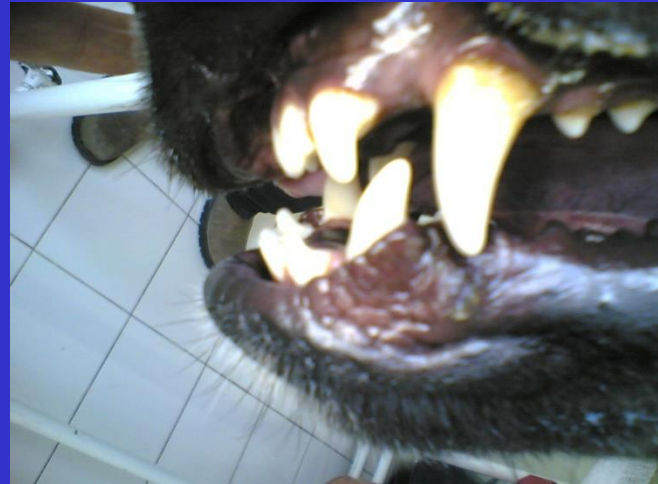
UNILATERAL WRY BITE



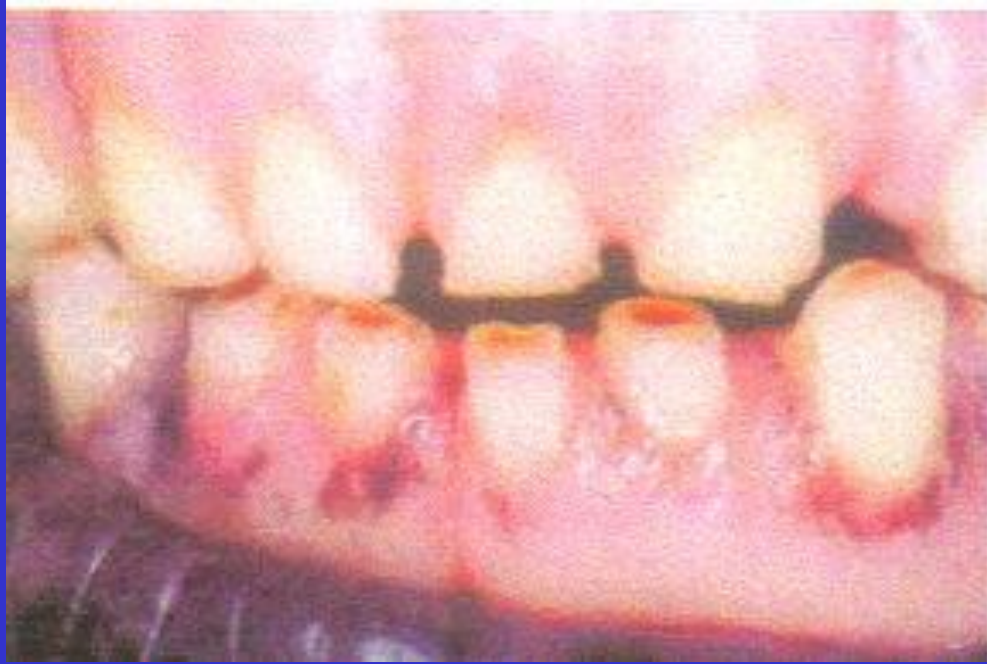UZUN MANDİBULA MANDİBULAR PROGNATİSM



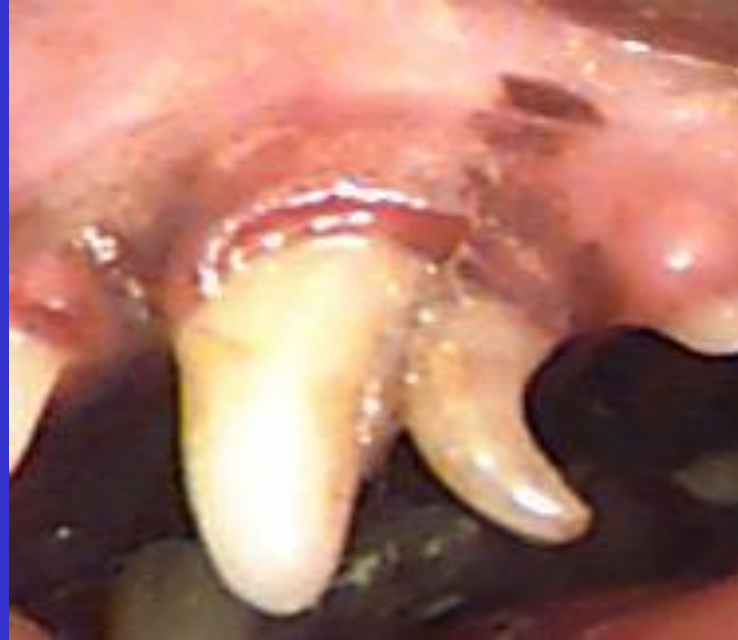MANDİBULAR PROTRUZYON



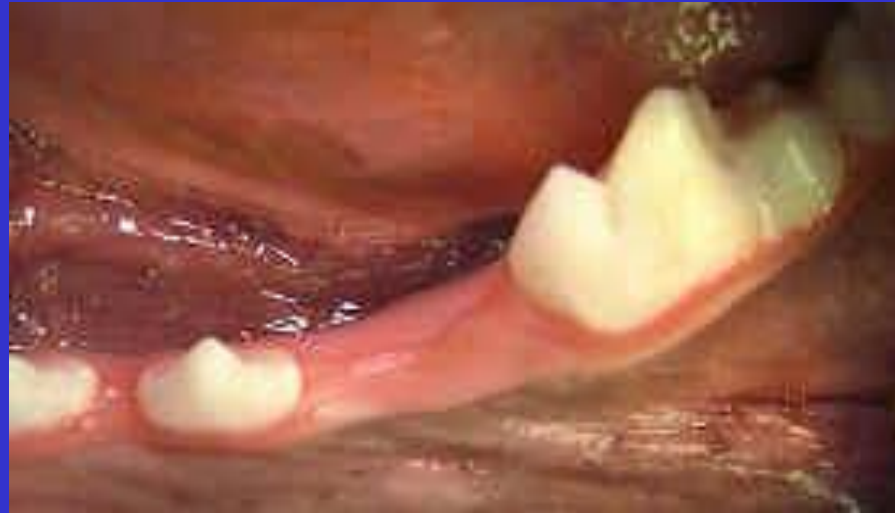SEVİYELİ KAPANIŞ



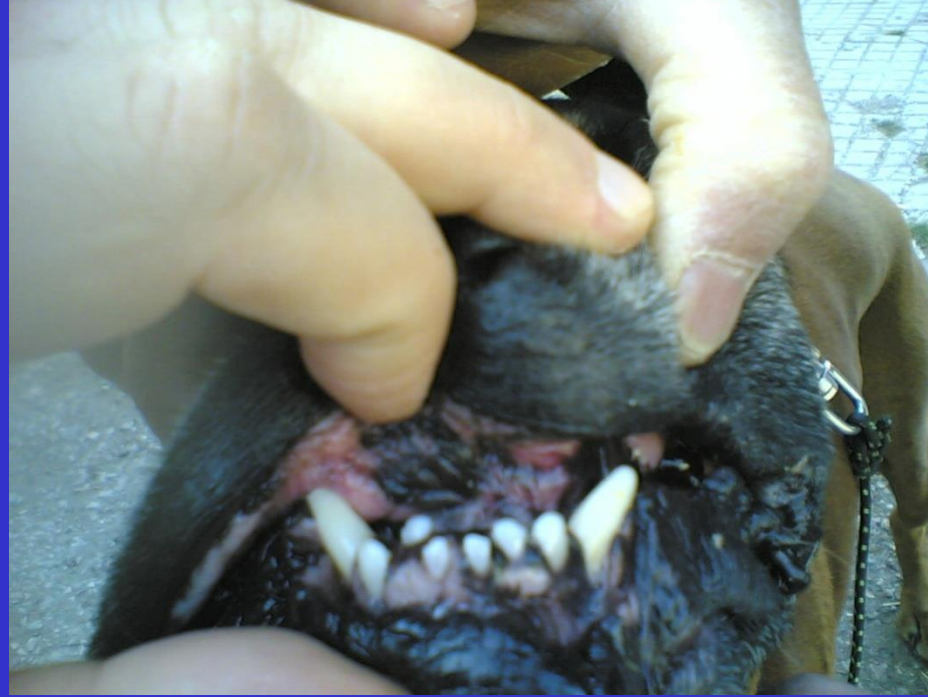TEK DİŞE AİT BOZUKLUKLAR DÜŞMEYEN SÜT DİŞİ



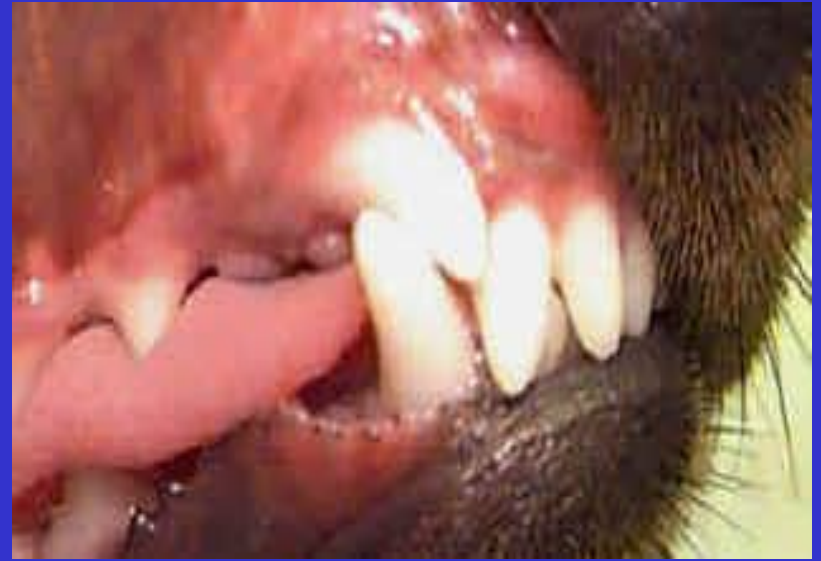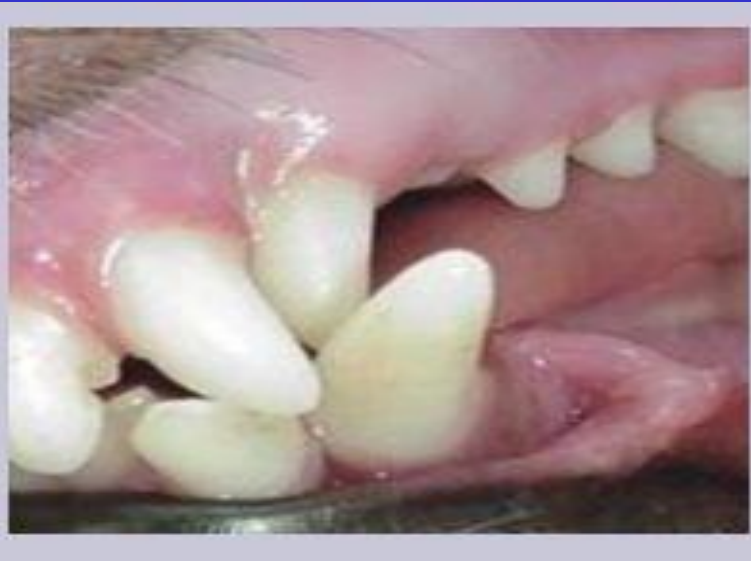KAYIP DİŞ



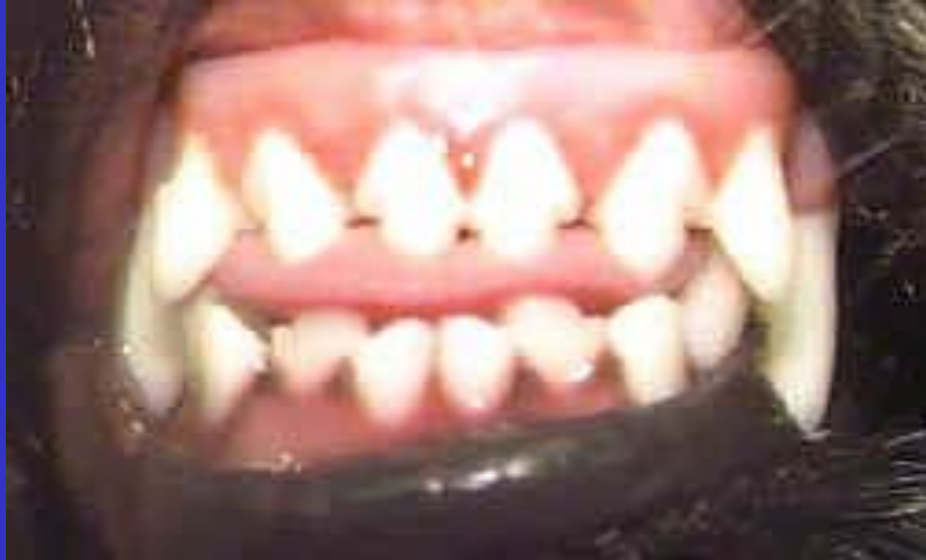YER DEĐİŐTİRMİŐ DİŐ



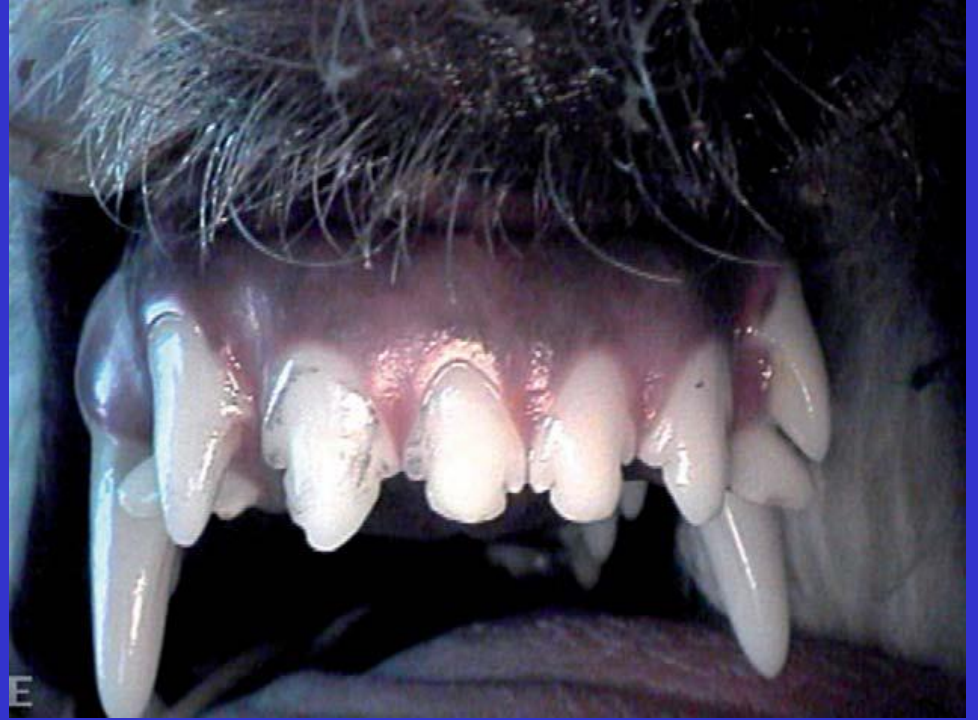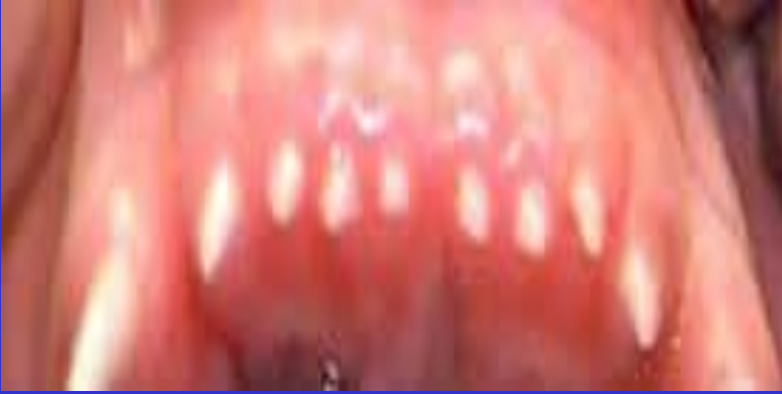DEVİYE OLMUŞ DİŞ



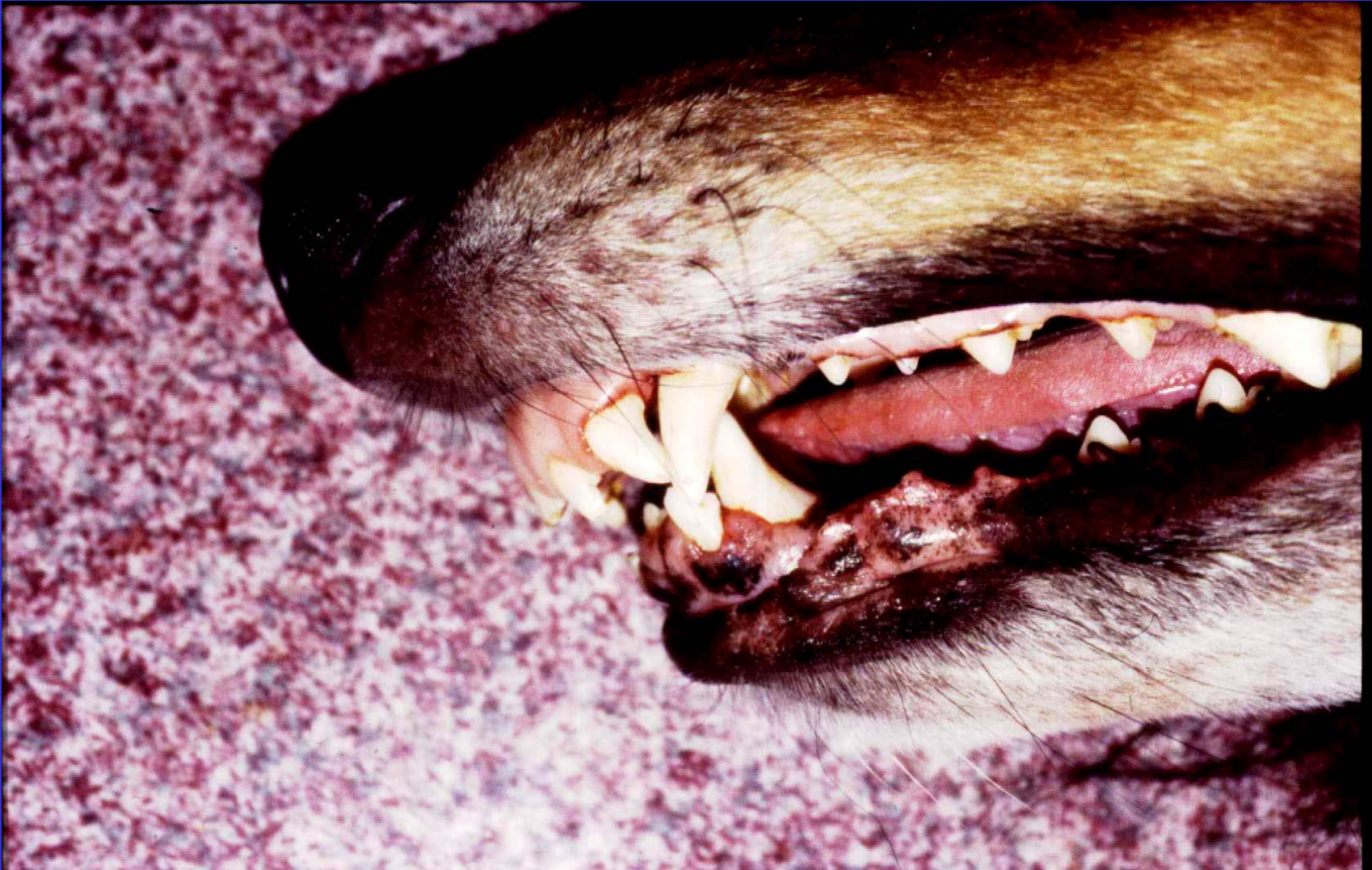ÇAPRAŞIK DİŞ

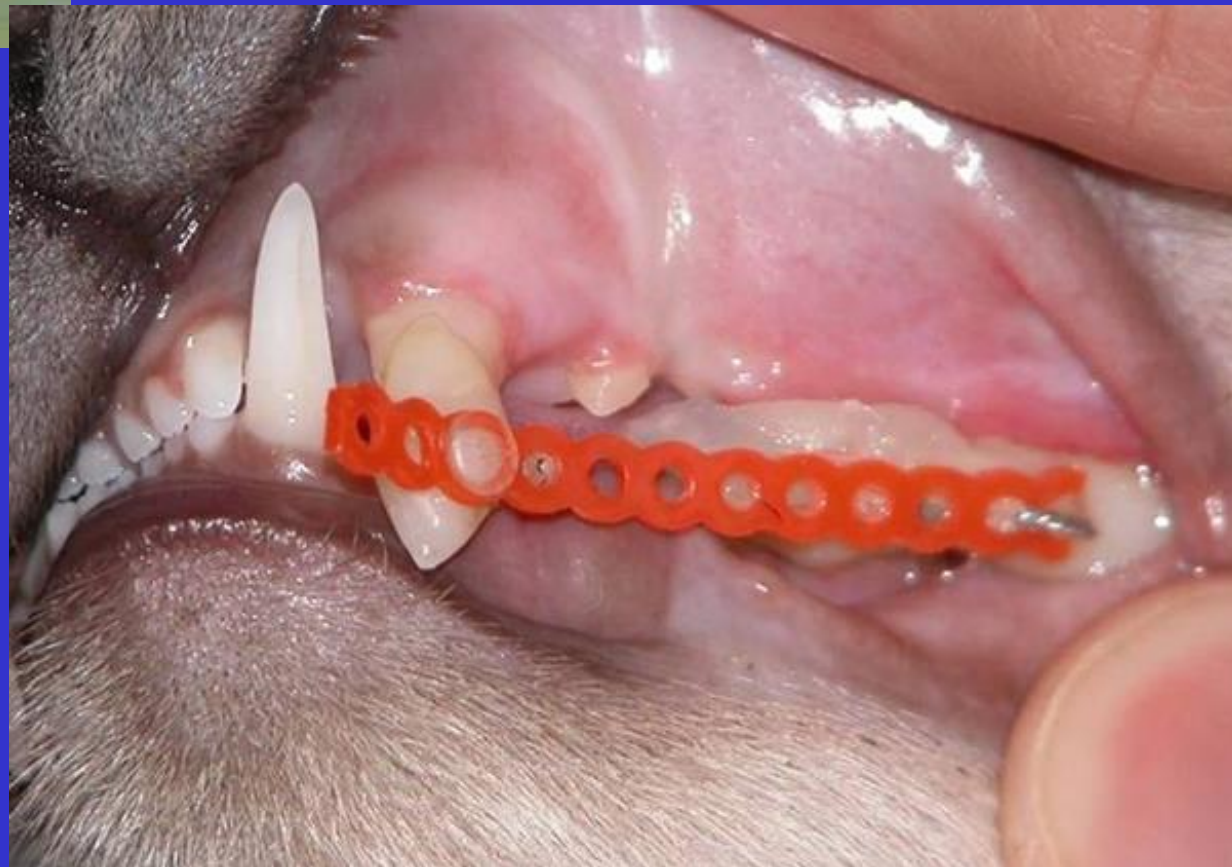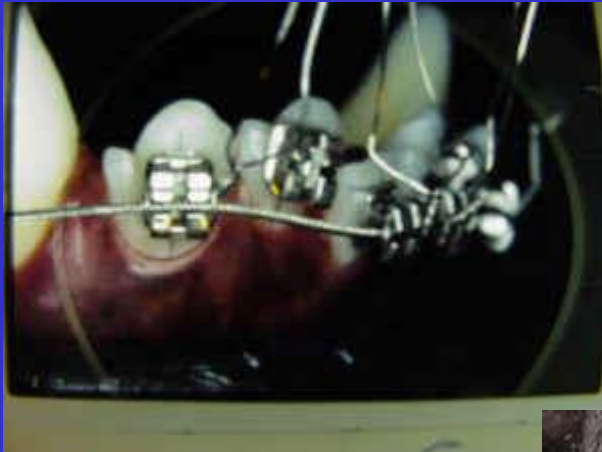


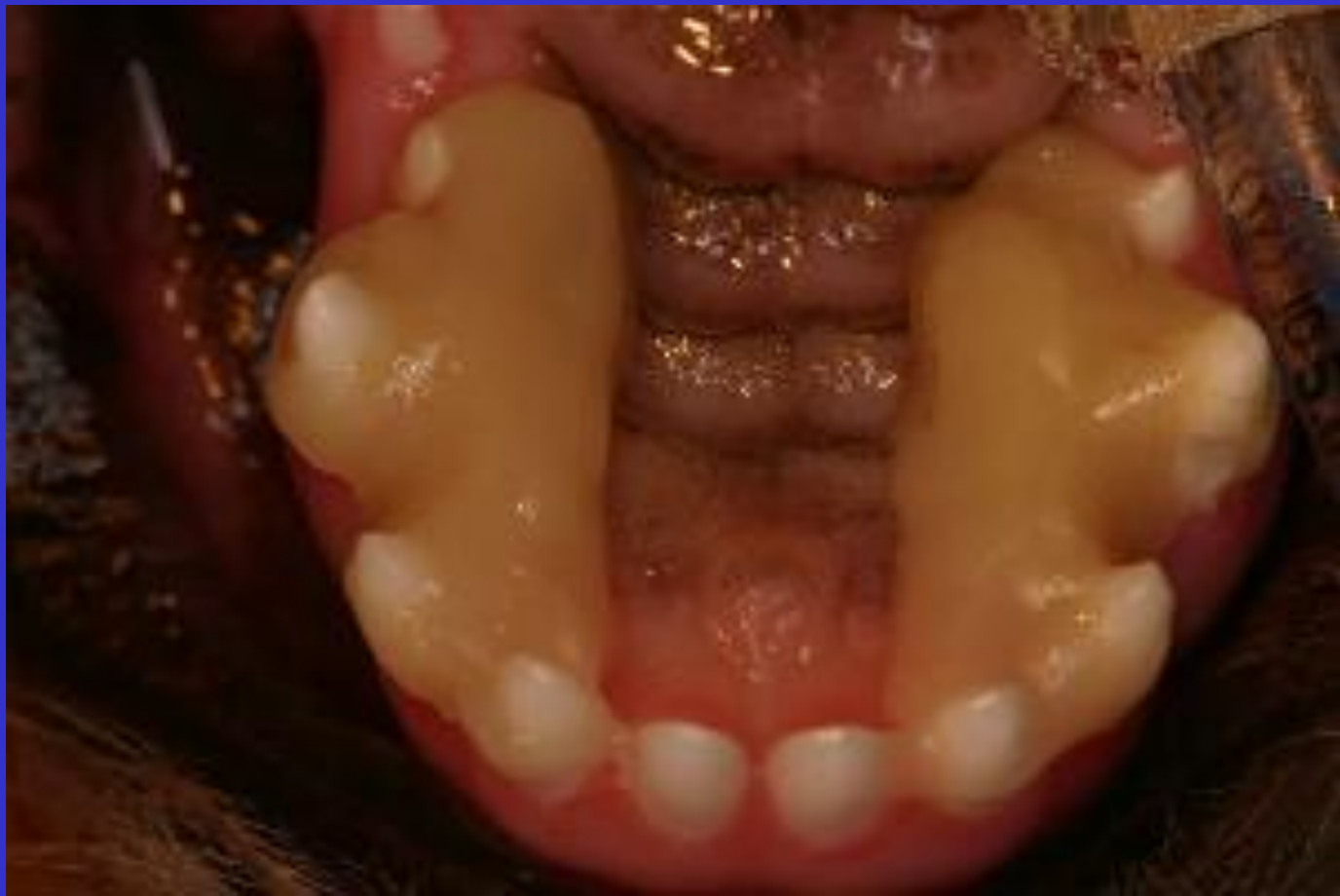FAZLA SAYIDA DİŞ

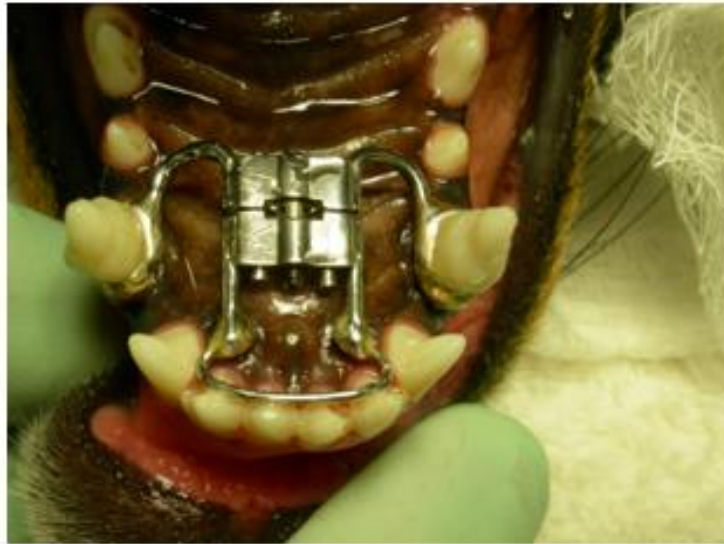

Fazla sayıda I3 malpozisyon

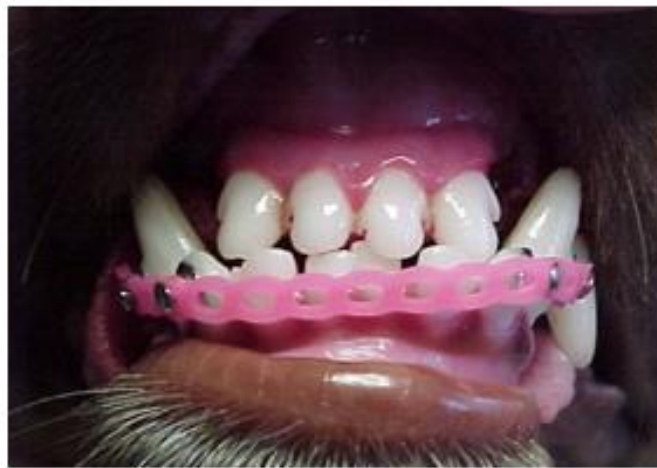




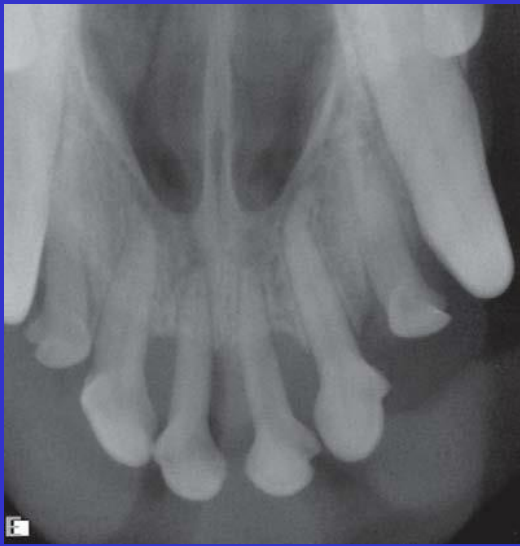


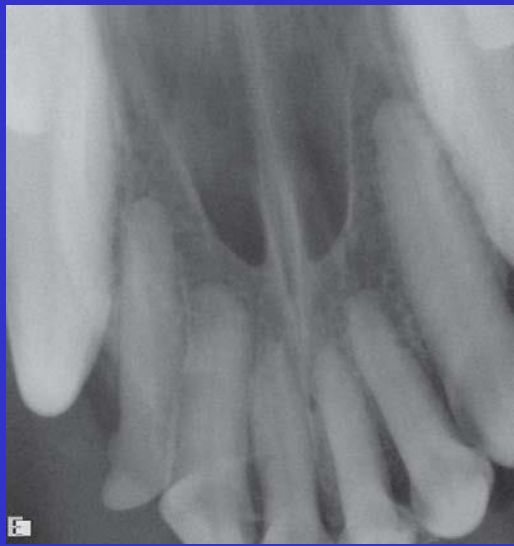After: Arch bar to move maxillary incisors into proper position.



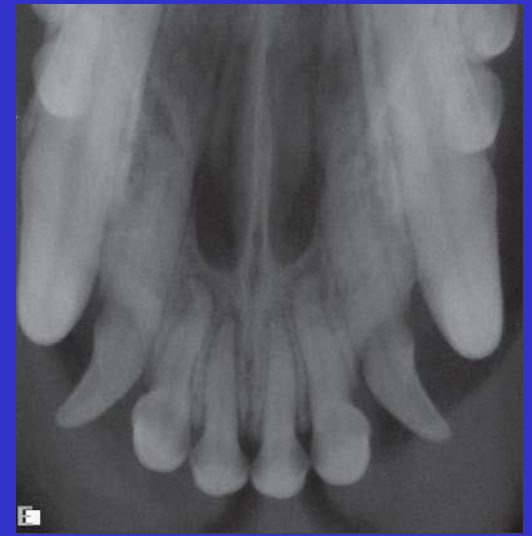
A power chain is placed on the lower incisors to correct an anterior cross bite.



İ3 Süt dişleri



Sol: süt, sağ
kalıcı



Norma İ3 deviyeye
olmuş