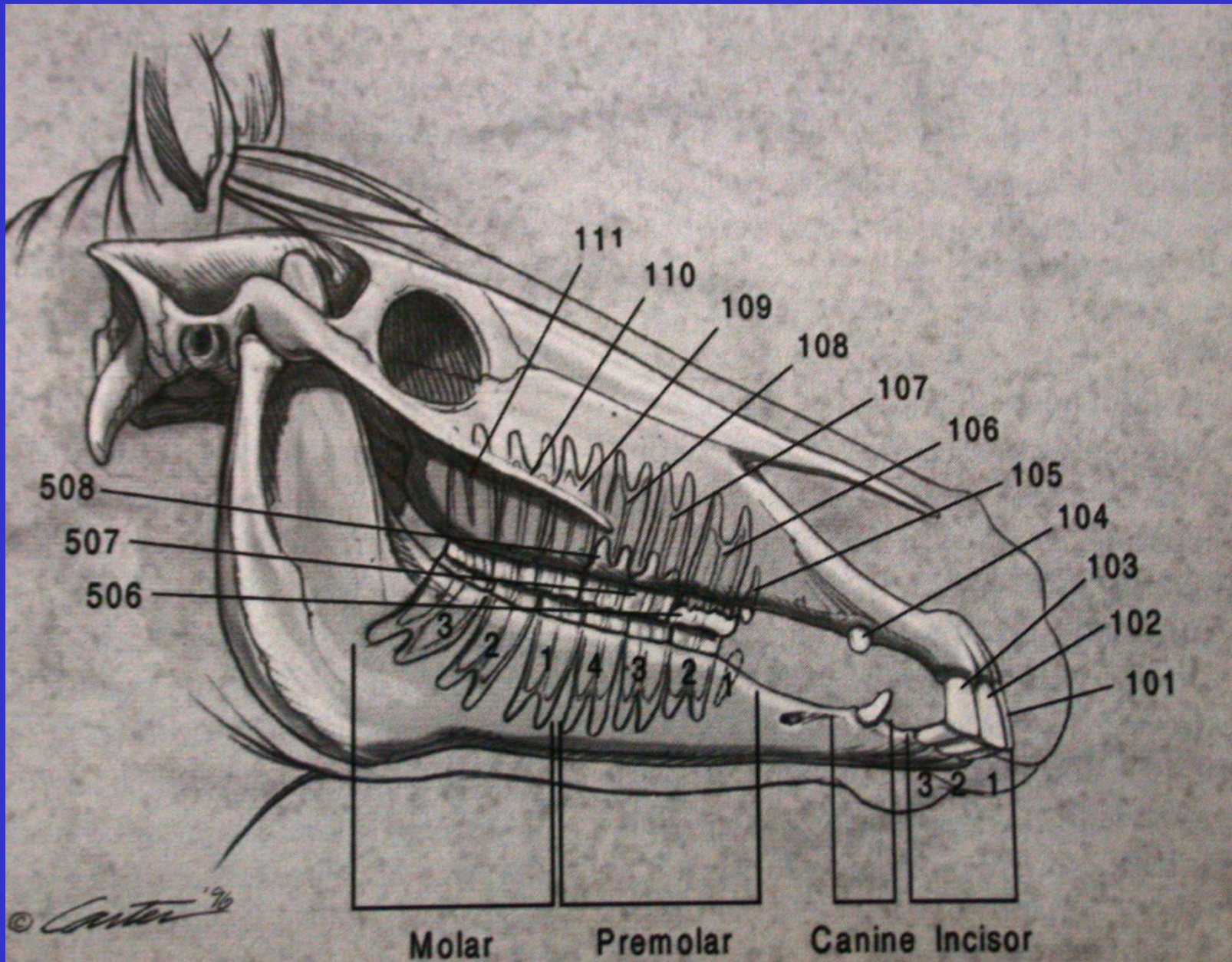
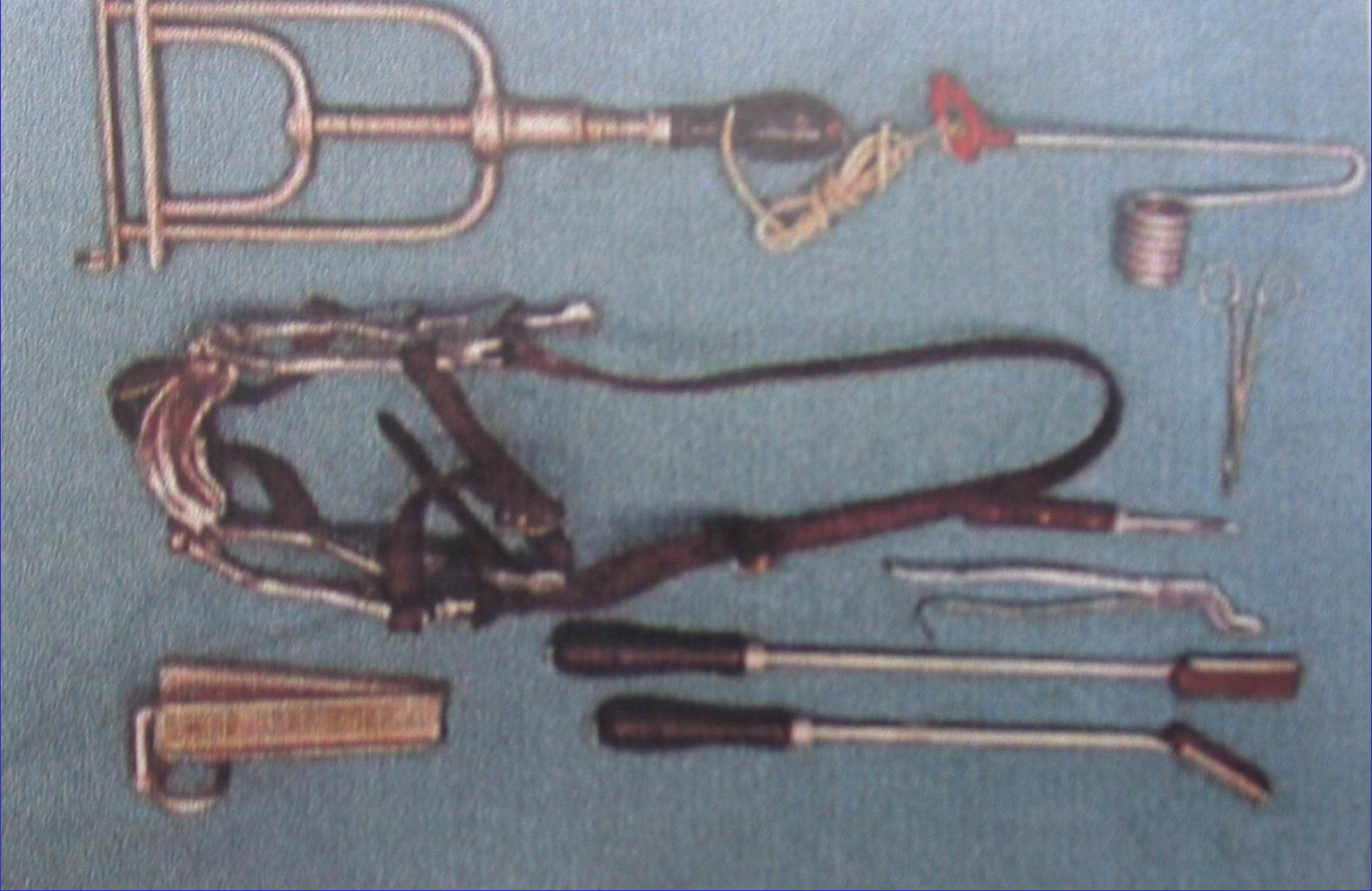
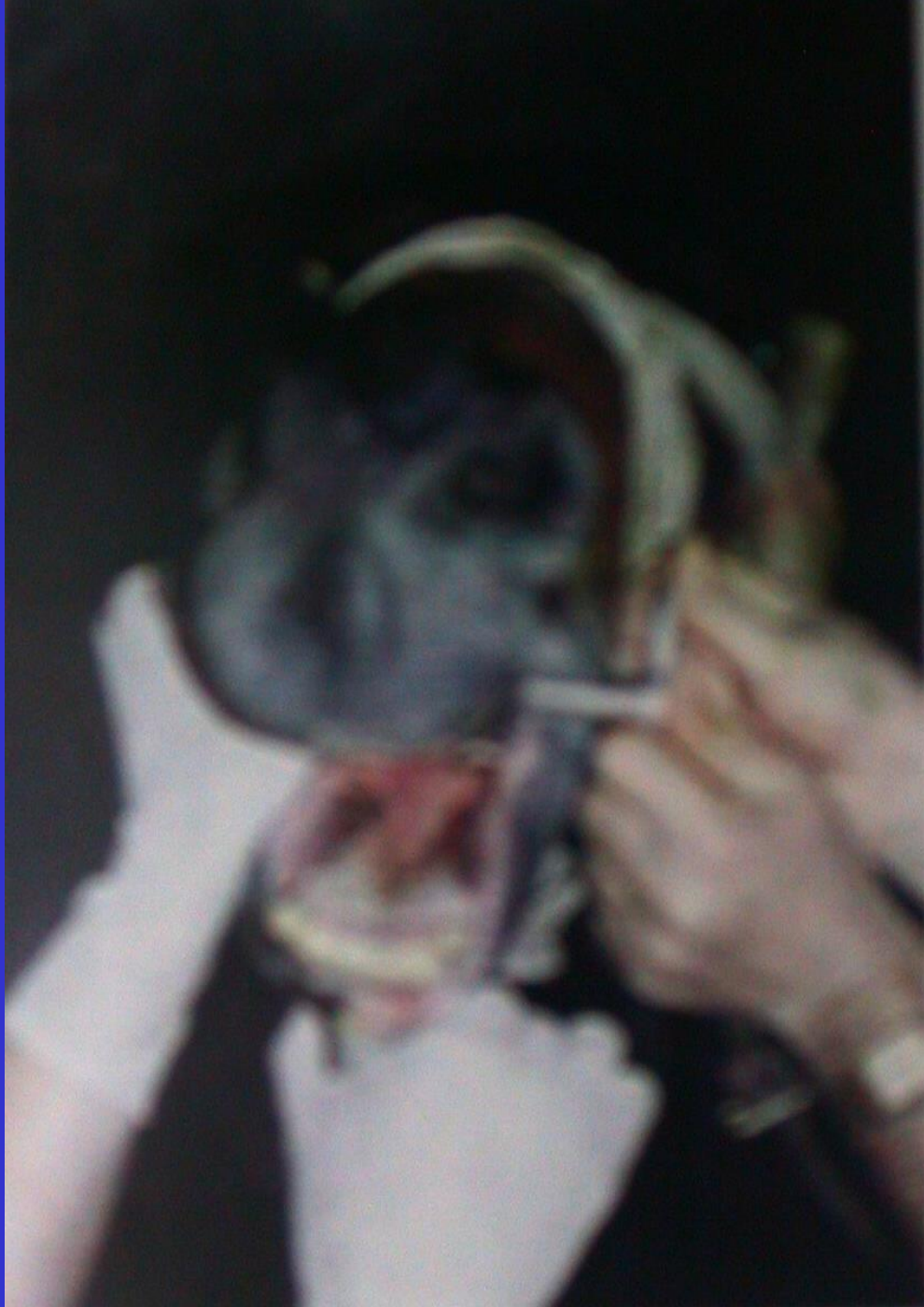
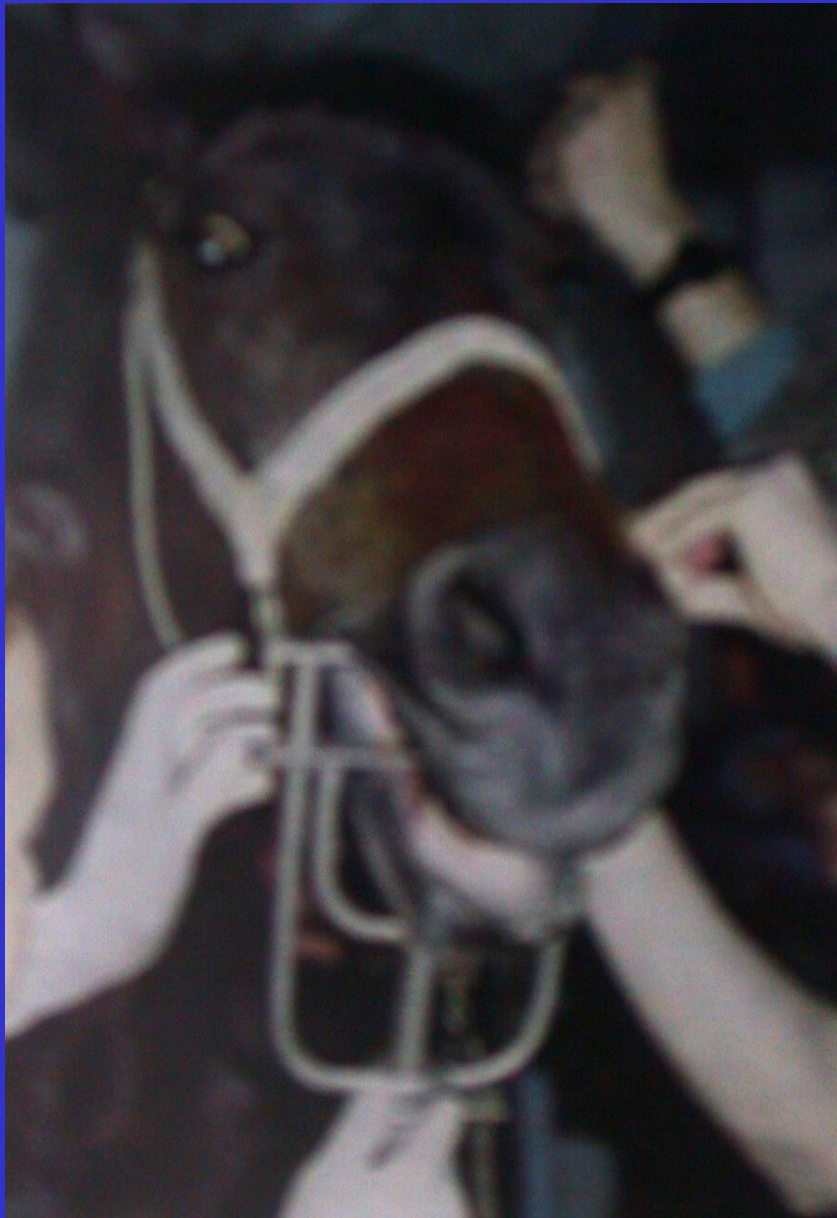
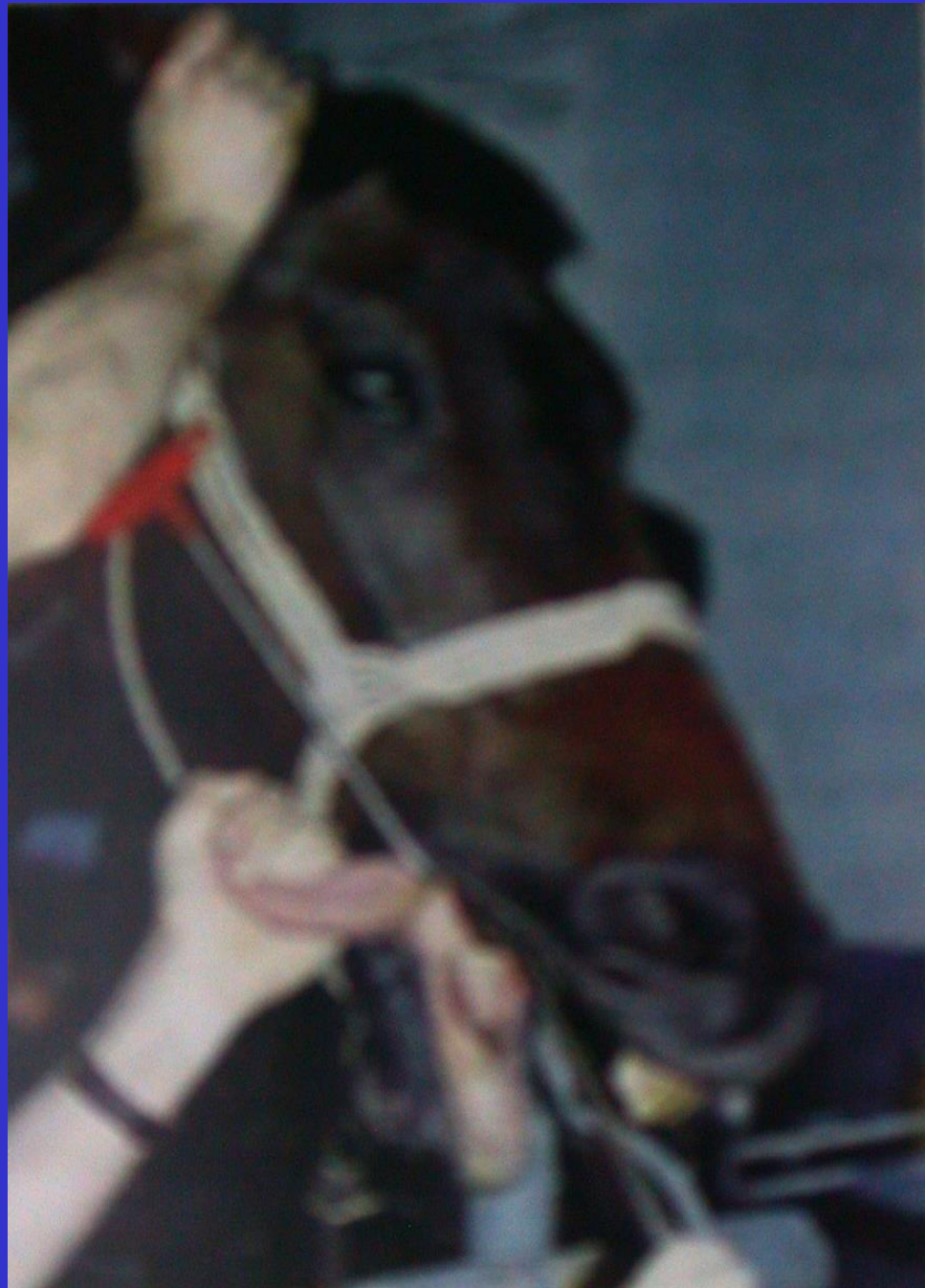AT DIŐ HEKİMLİĐİ

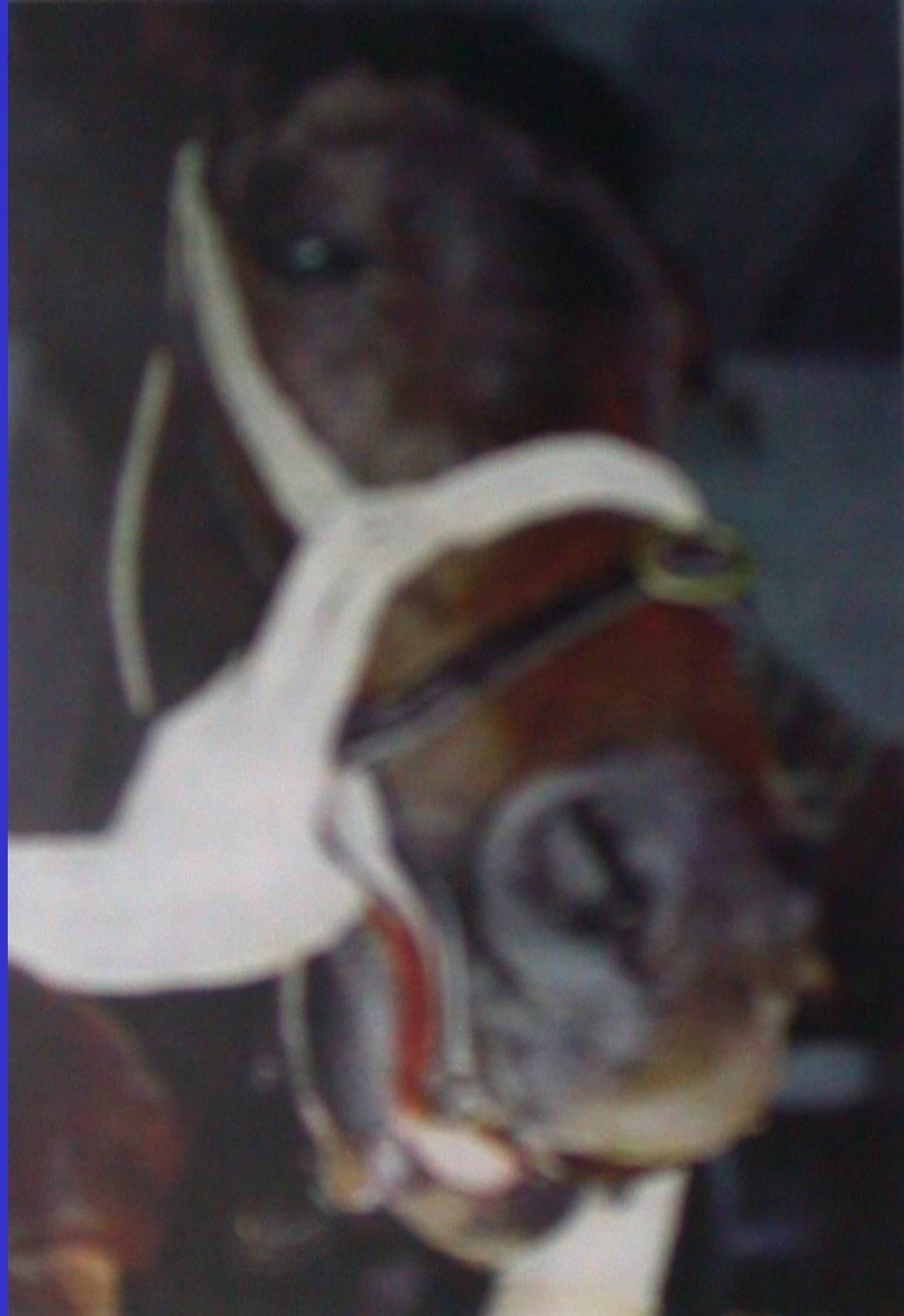


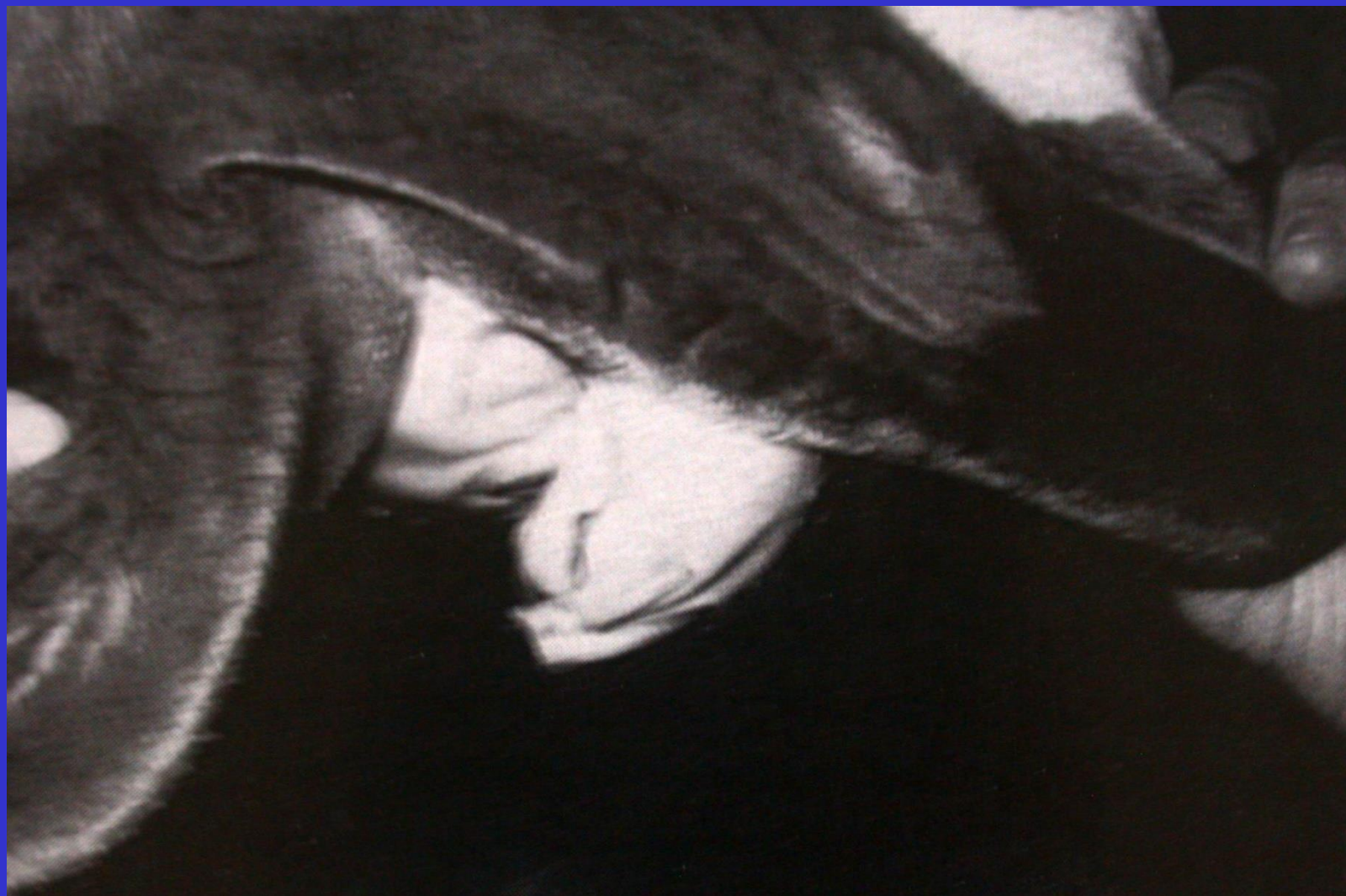


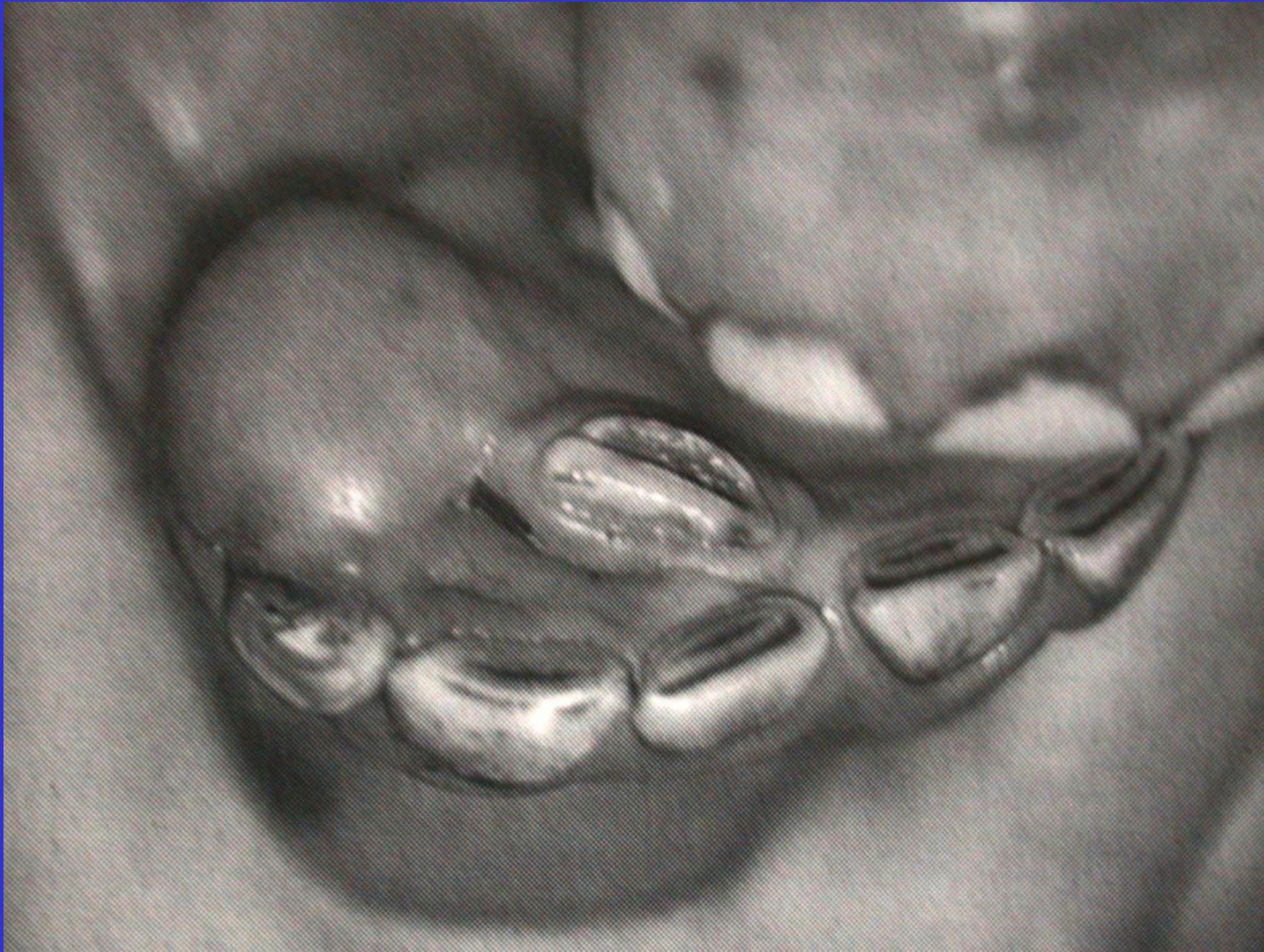



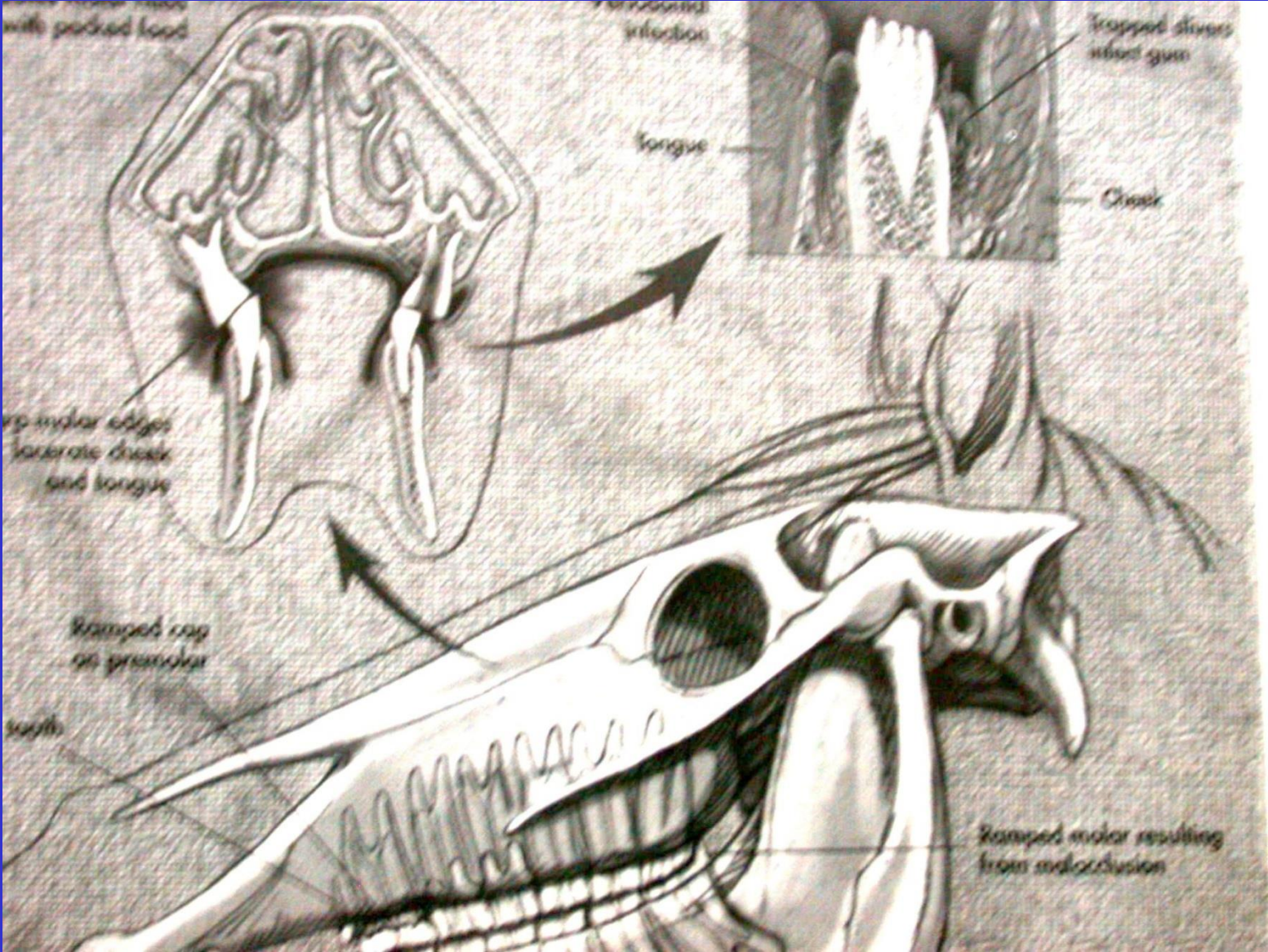





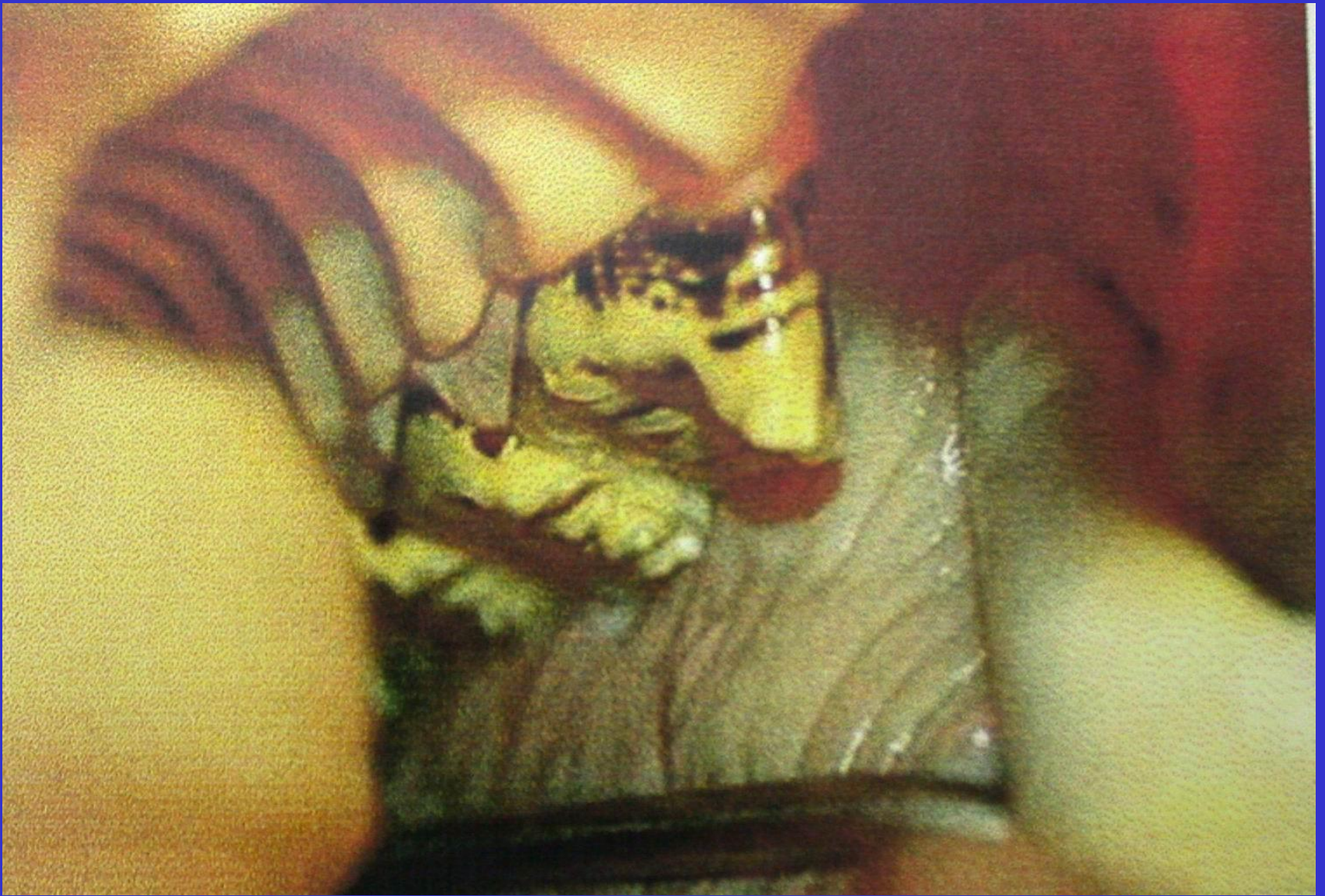
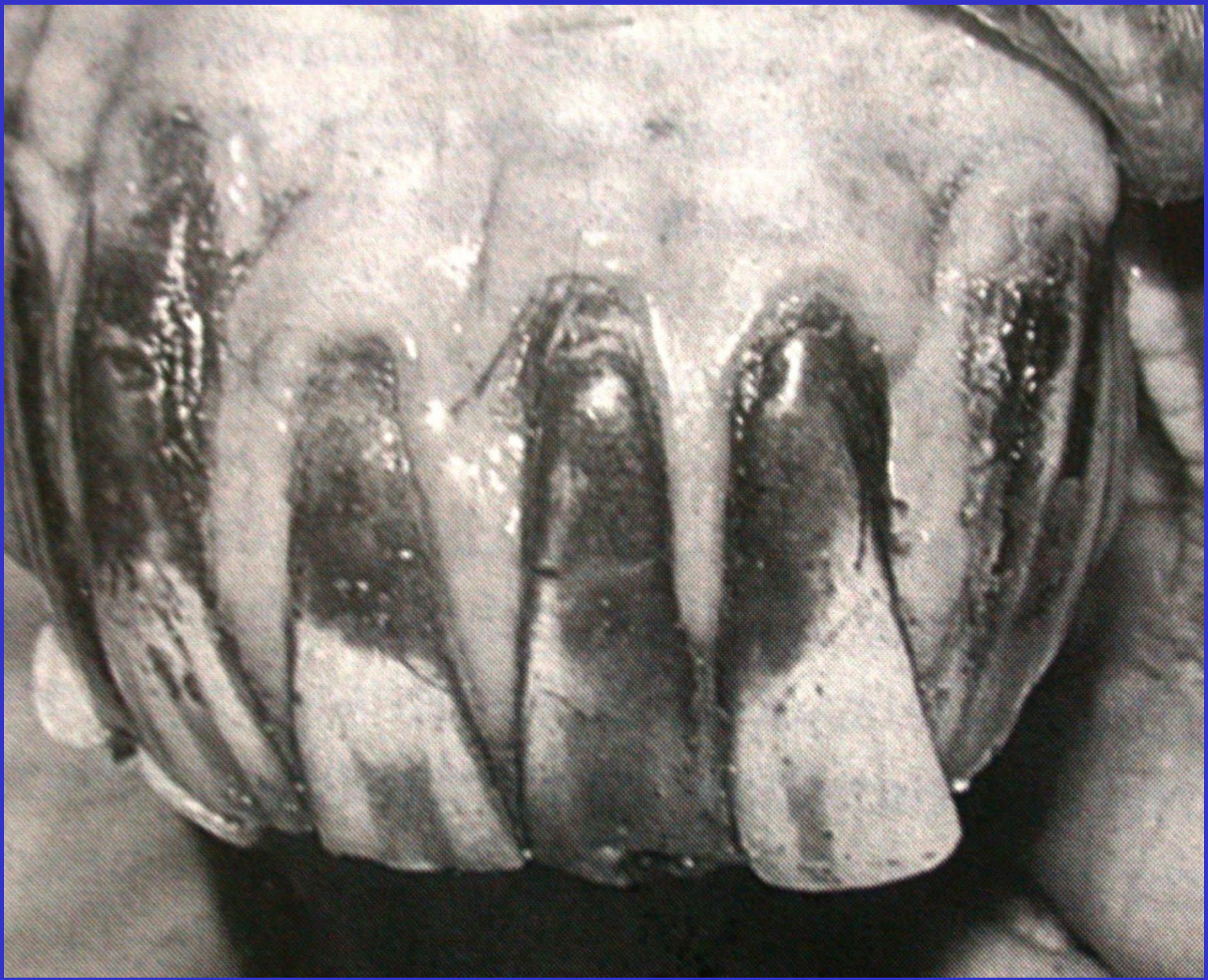DİSLOKASYON

DÜZENSİZ AŞINMALAR

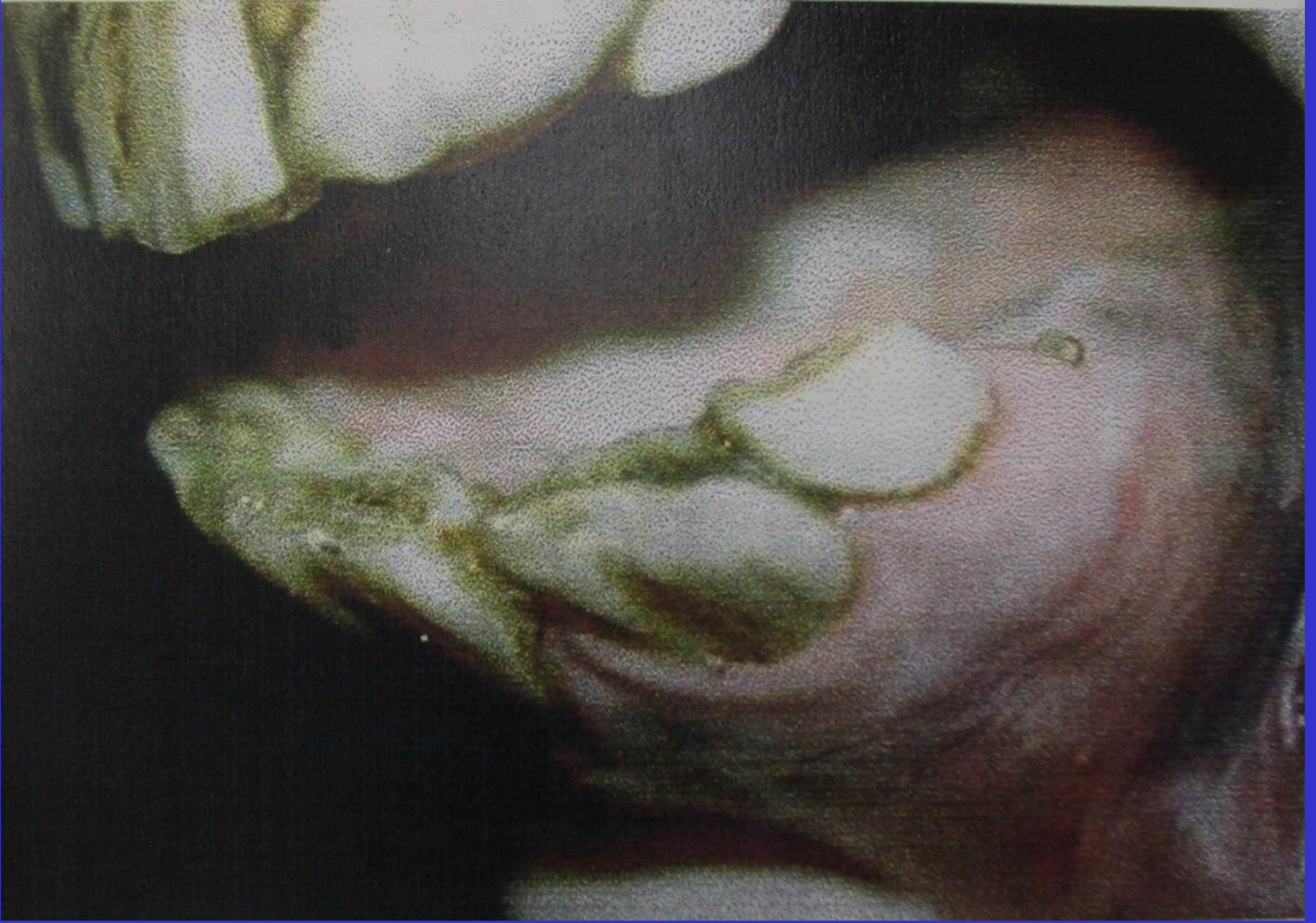




HOOK



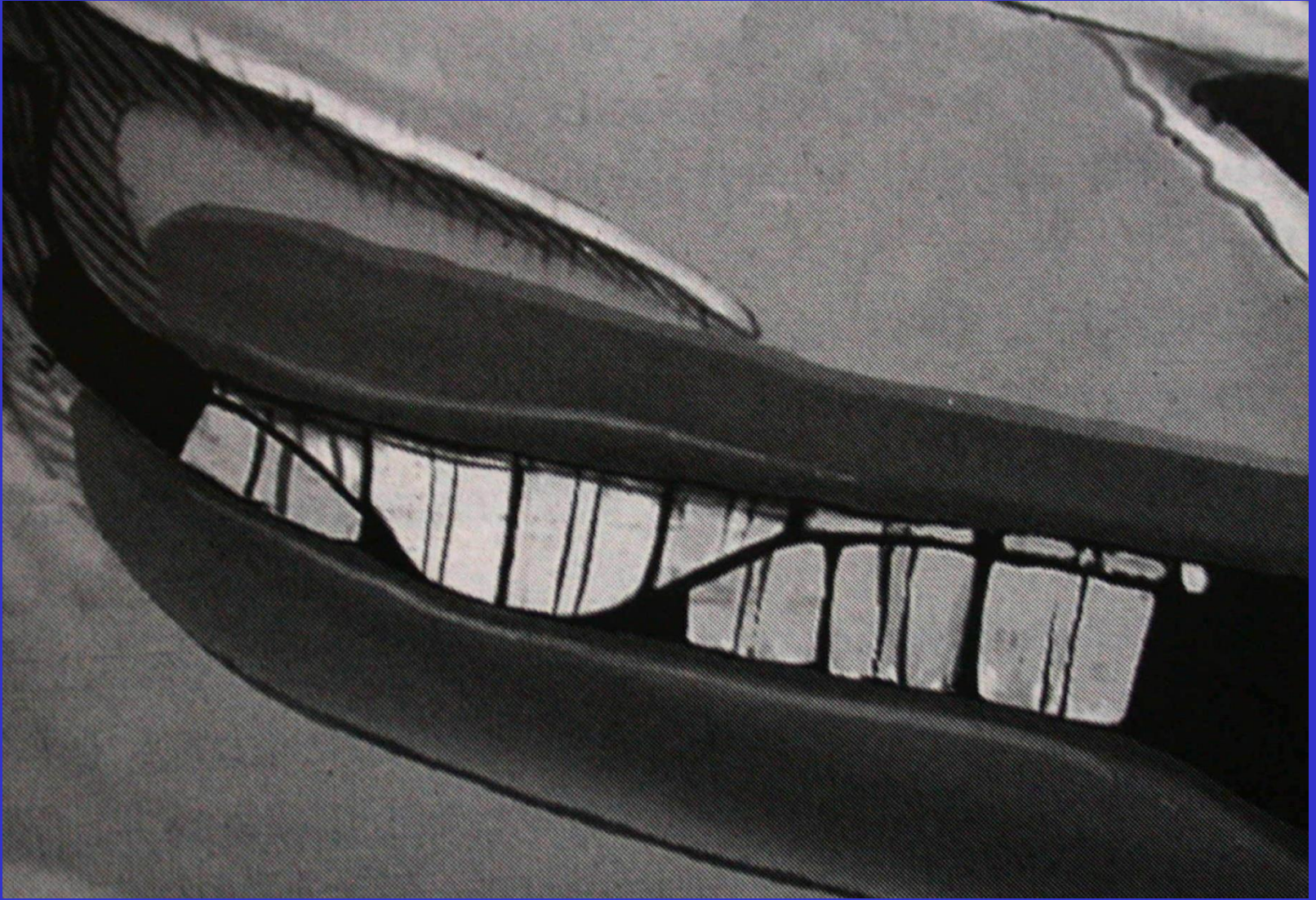
OVERBITE



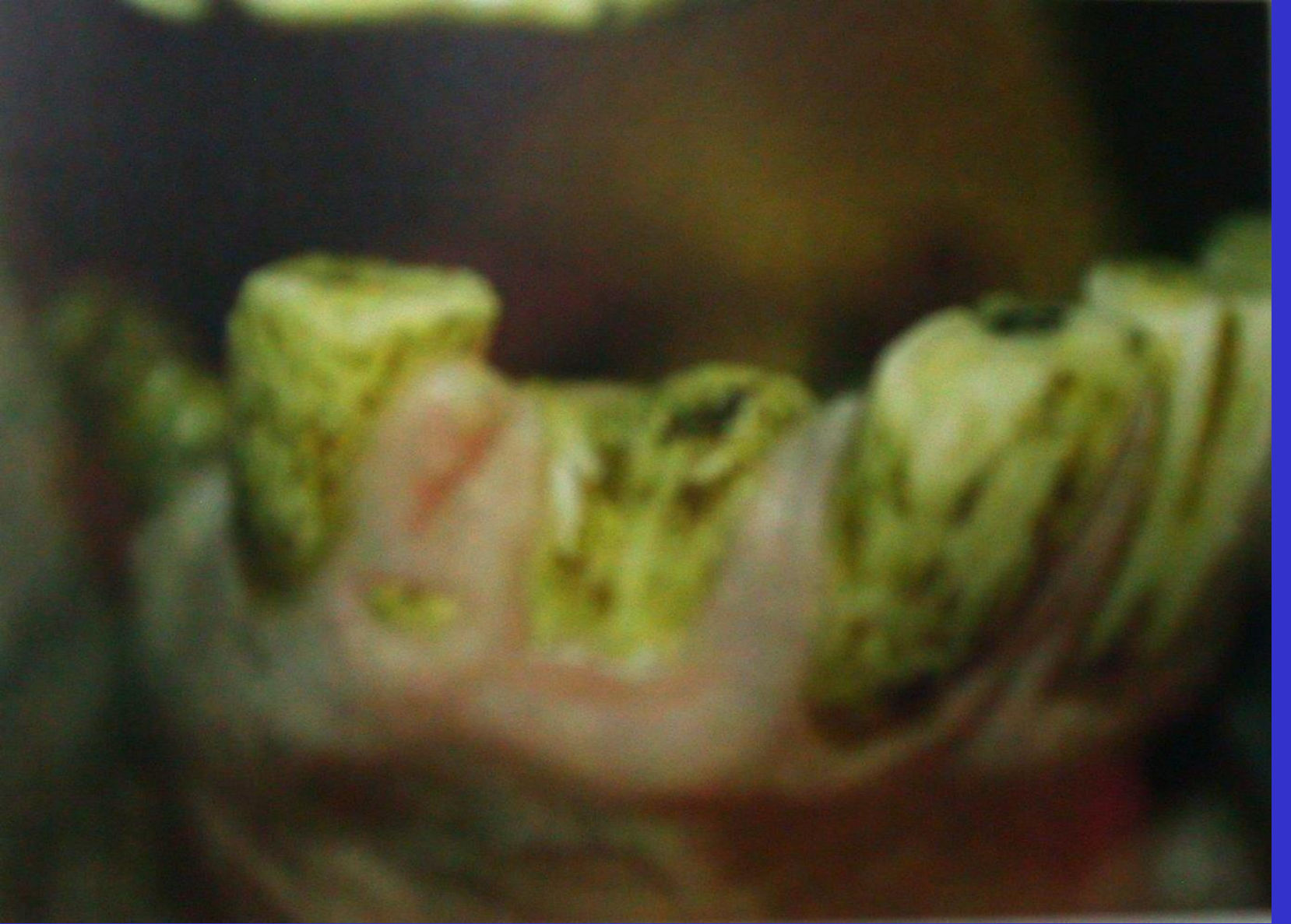DÜZENSİZ ÇİGNEME YÜZLERİ



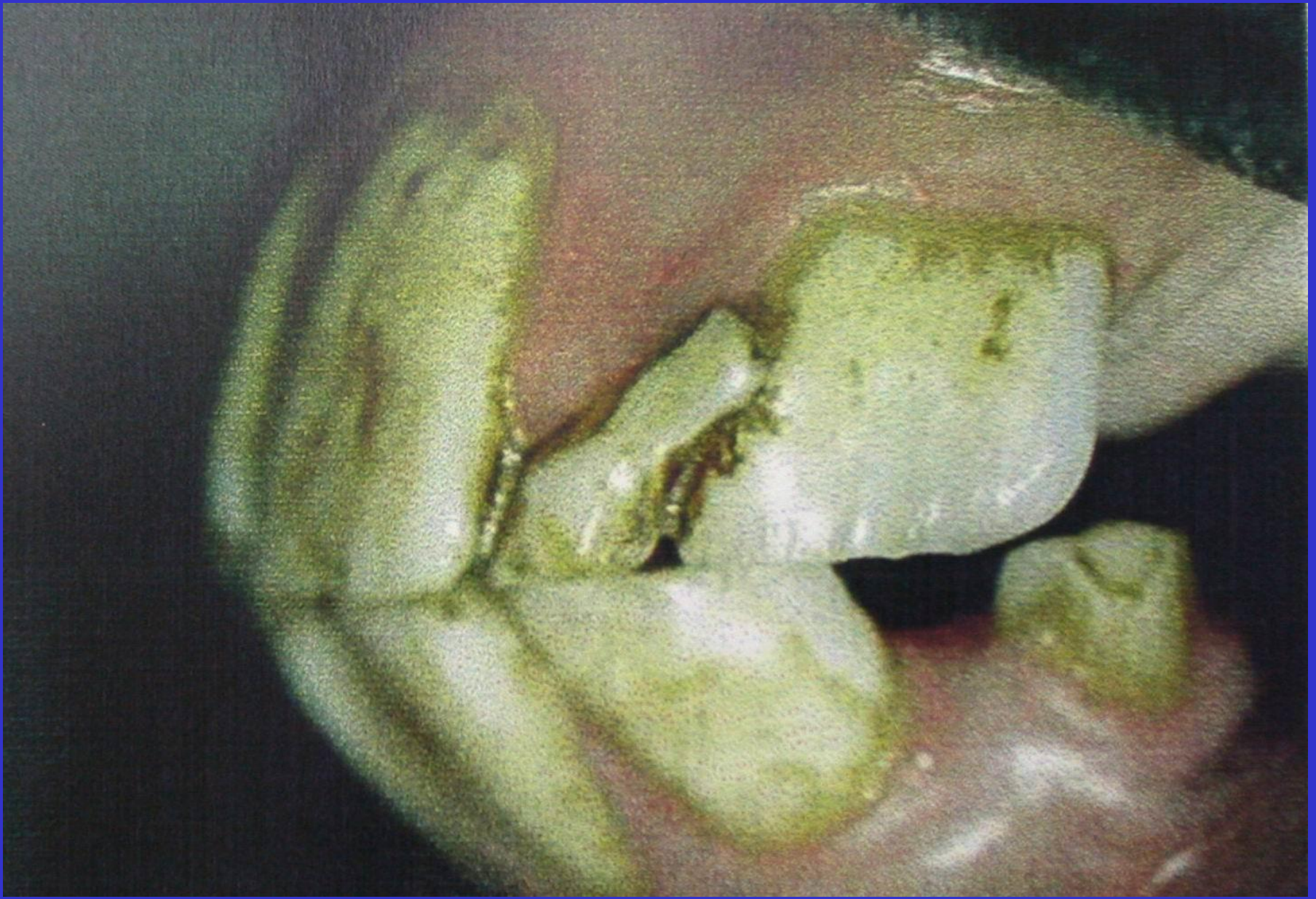DÜZ DİŞLER



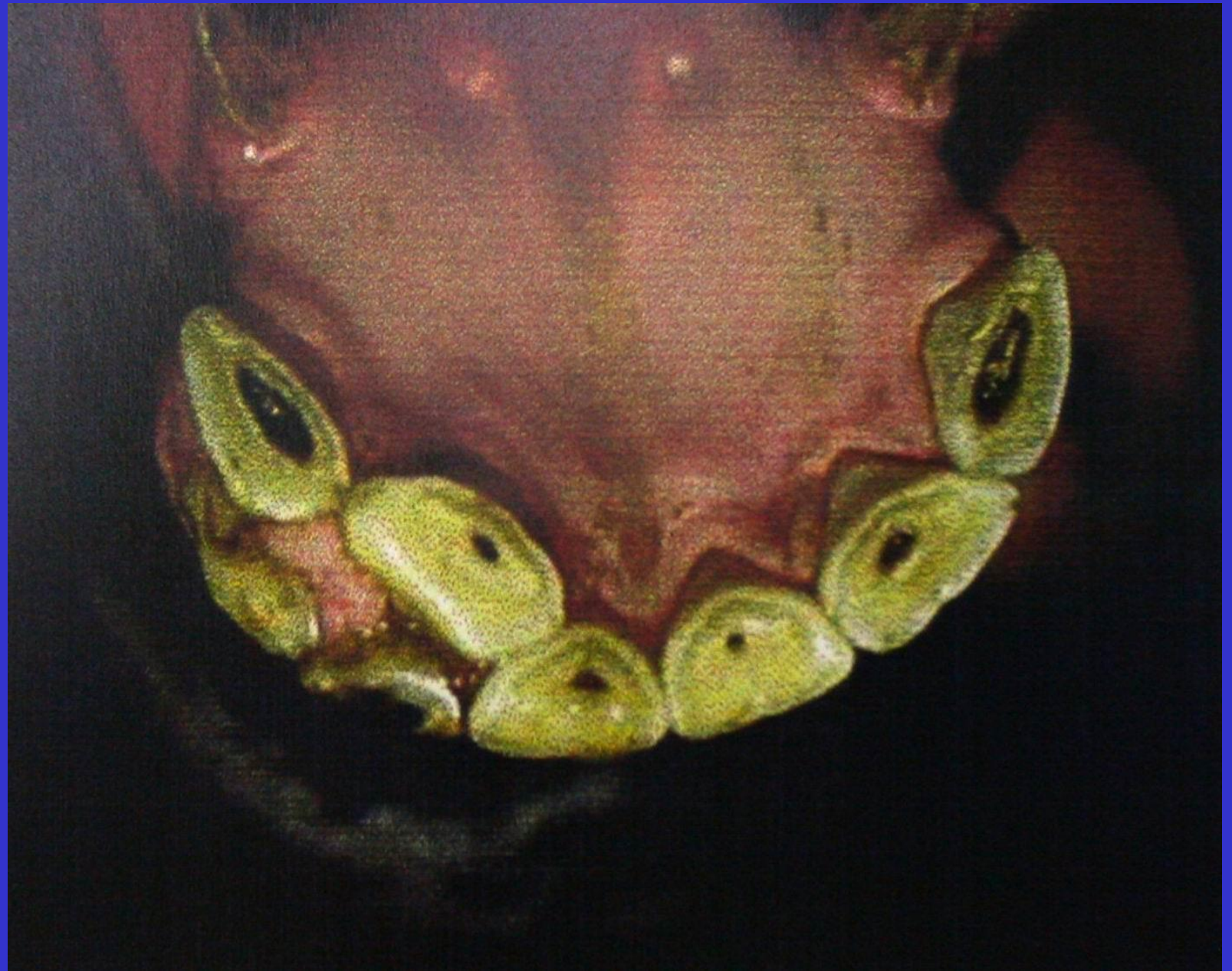MERDİVEN BENZERİ DİŞLER



SÜT DİŞİ – DÜZENSİZ ÇİGNEME YÜZLERİ

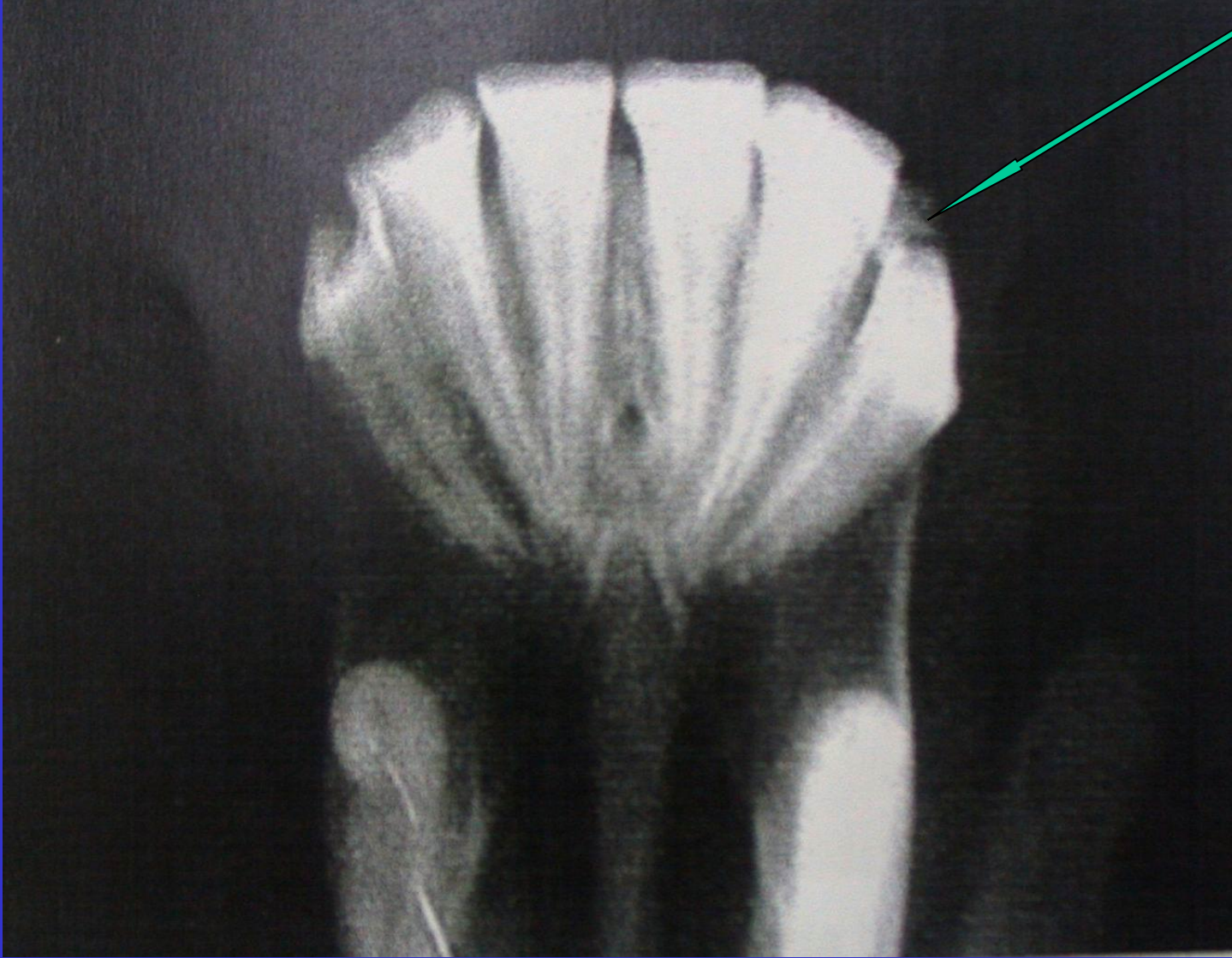


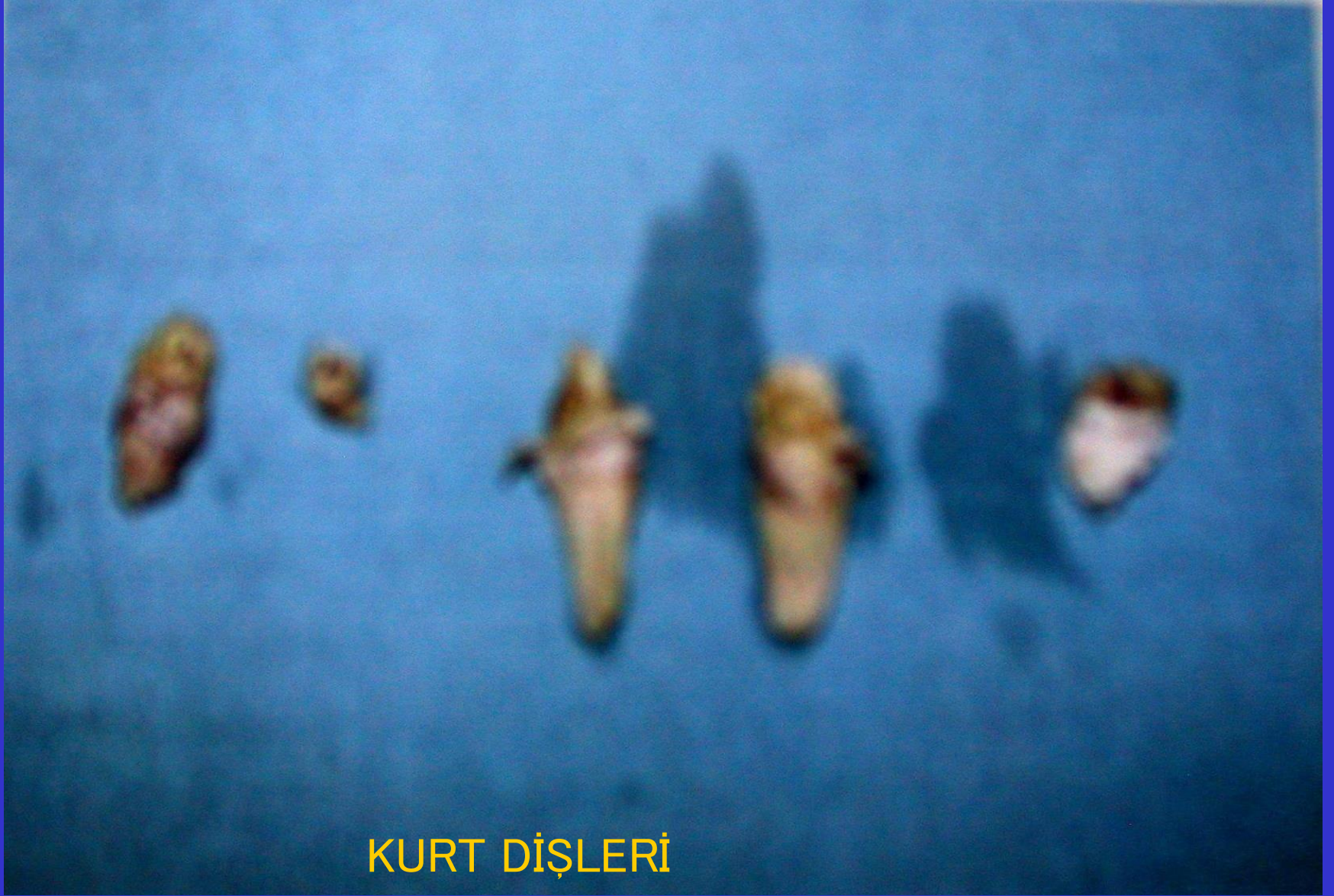SÜT DİŞLERİ



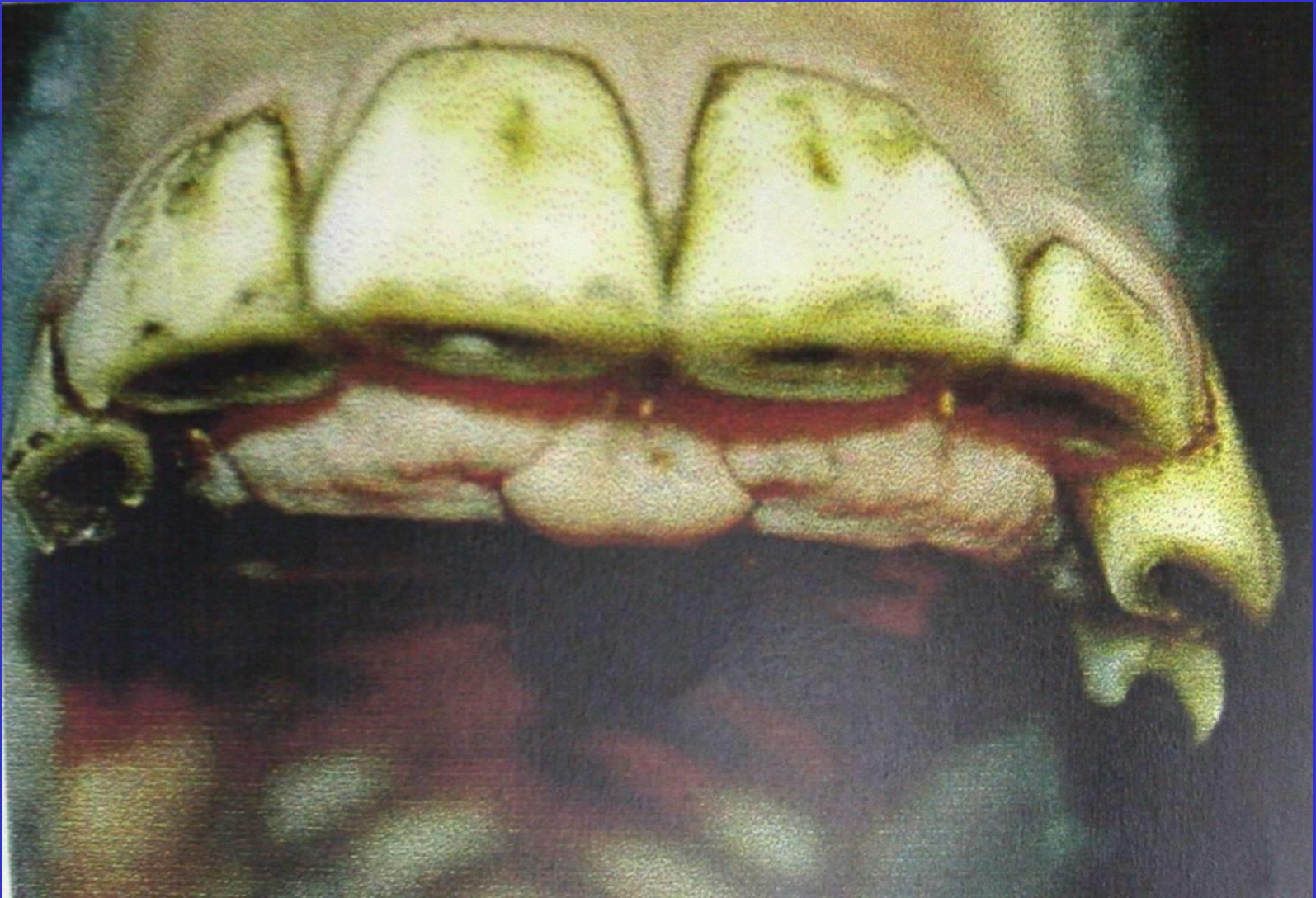VERSİO – SÜT DİŞLERİ

SÜT DİŞİ

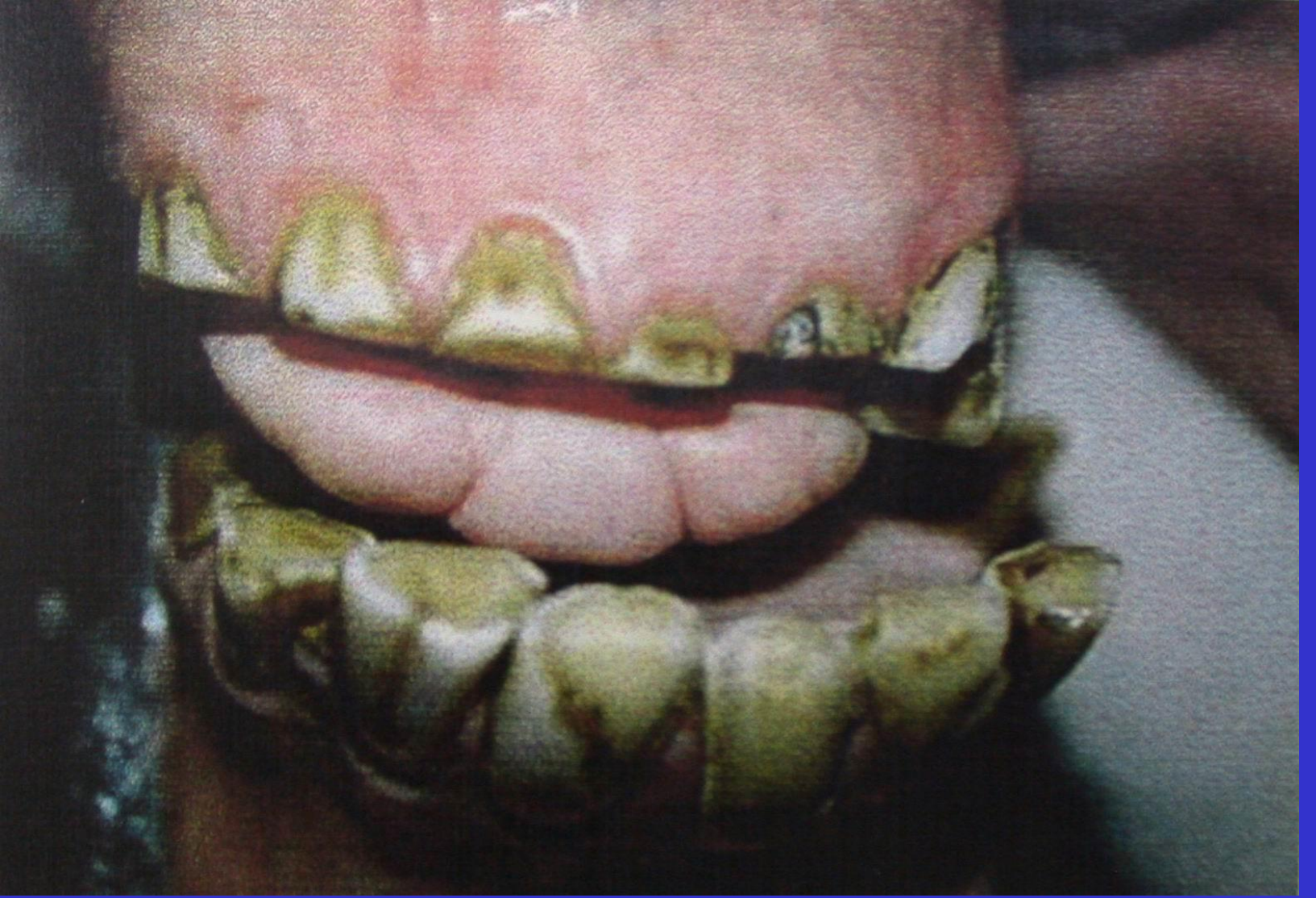



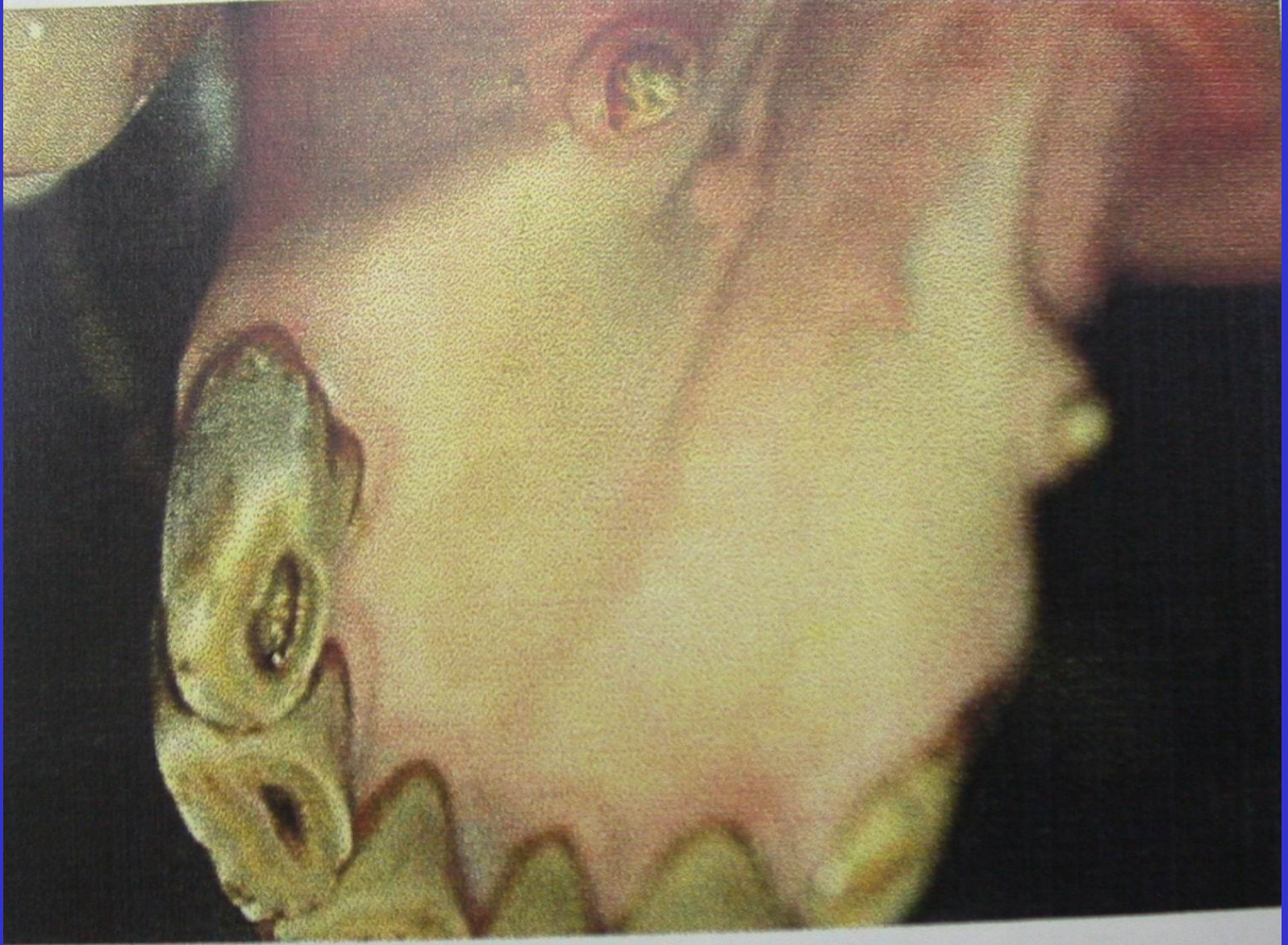
KURT DİŞLERİ




SUPERNUMERARY TOOTH

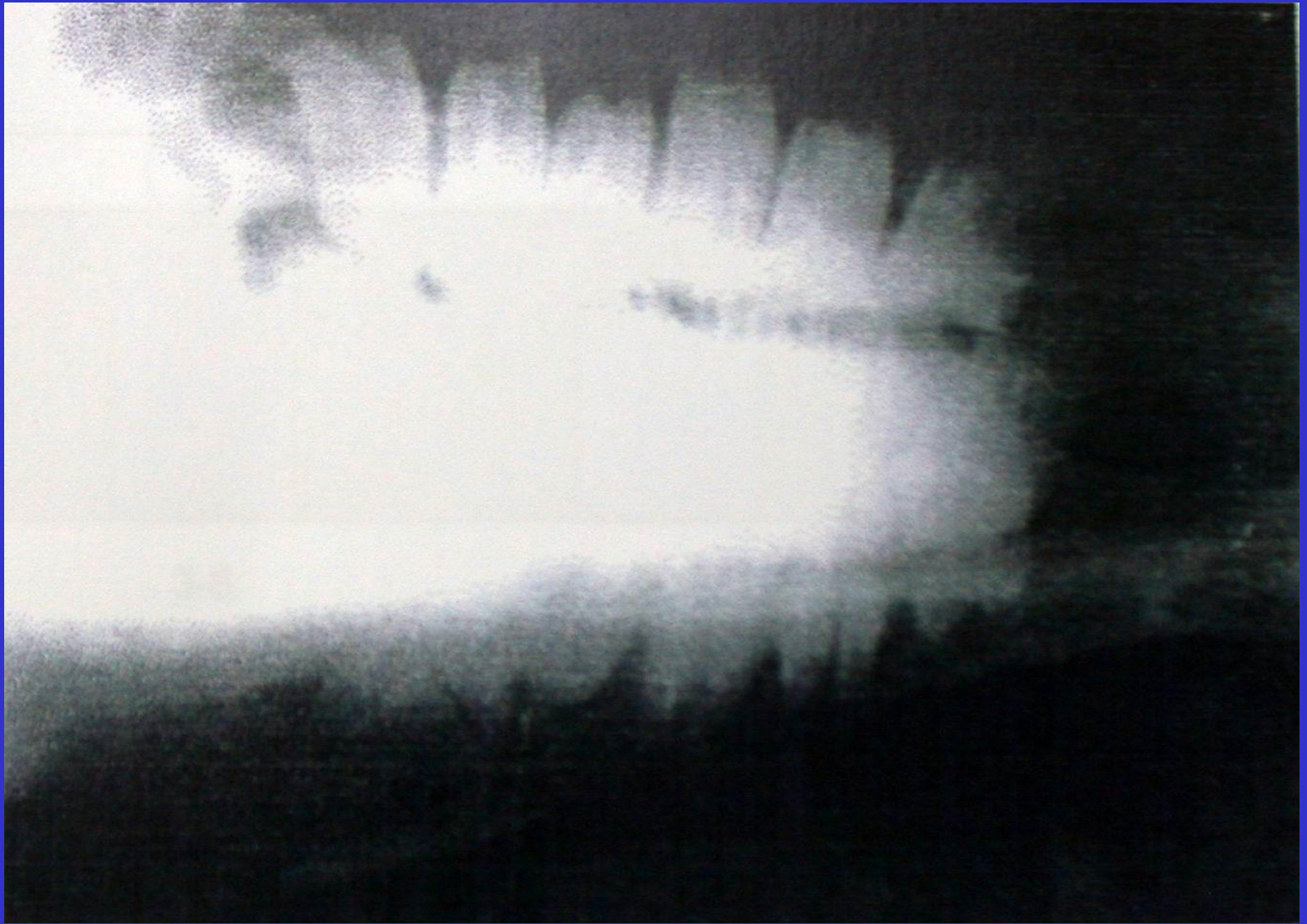



BİLENMİŞ DİŞLER

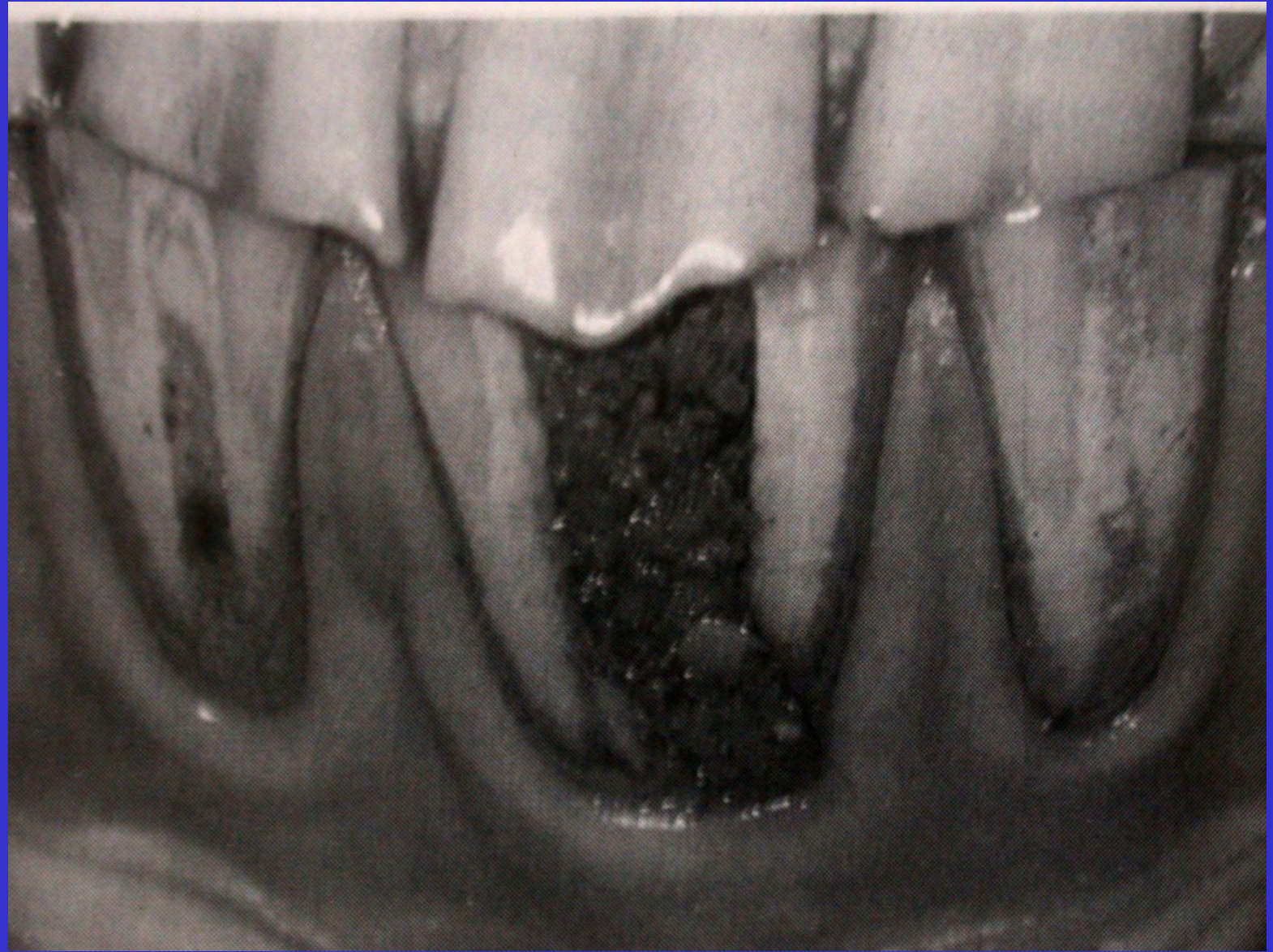

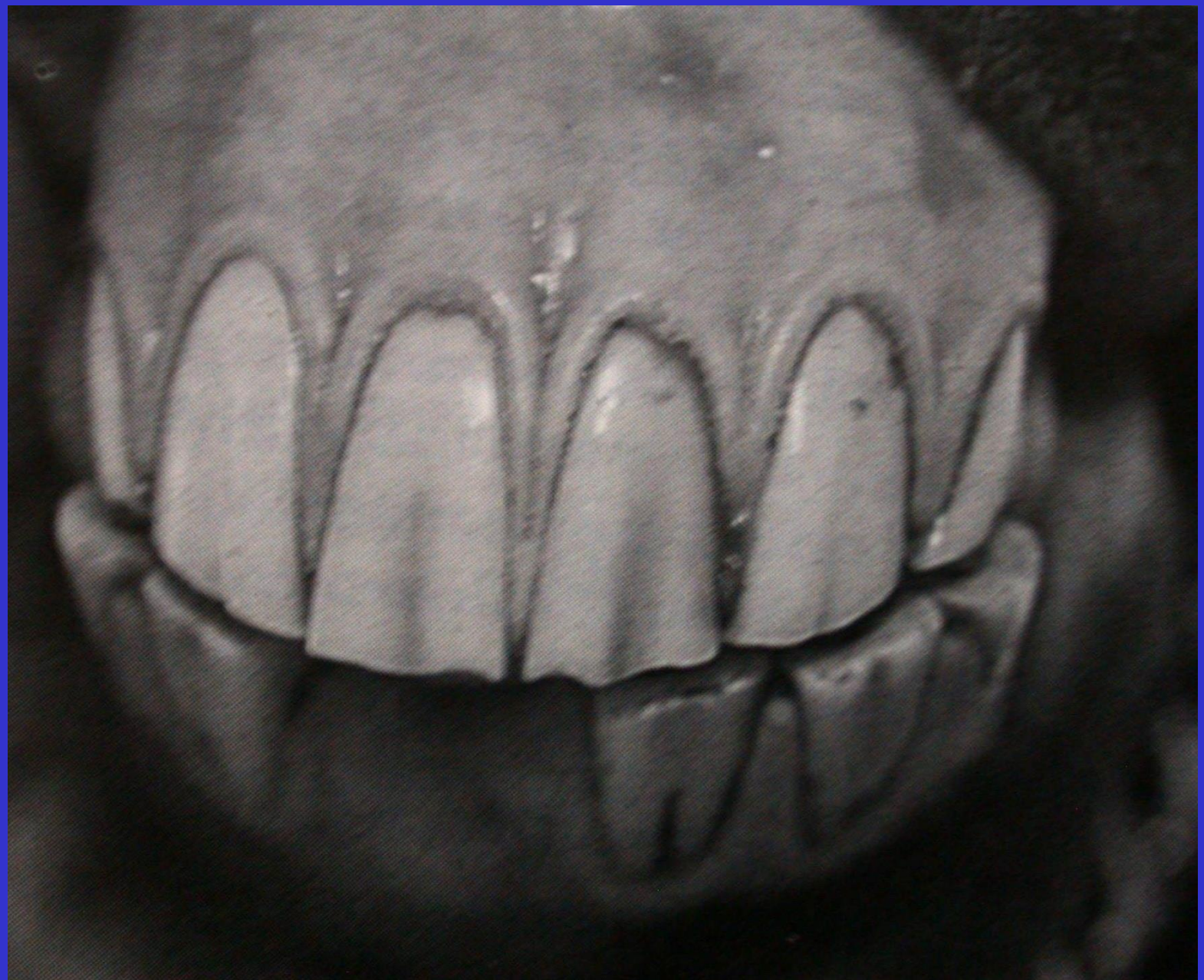KANİN DİŞLER



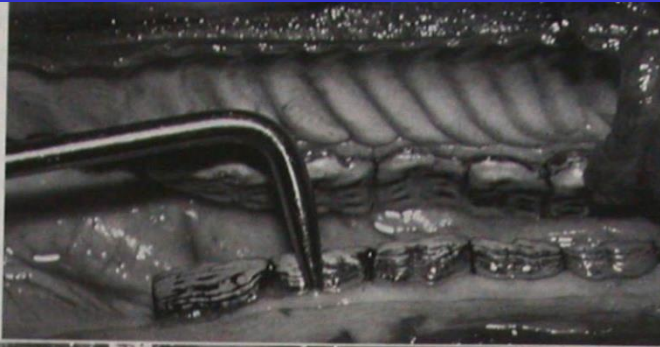




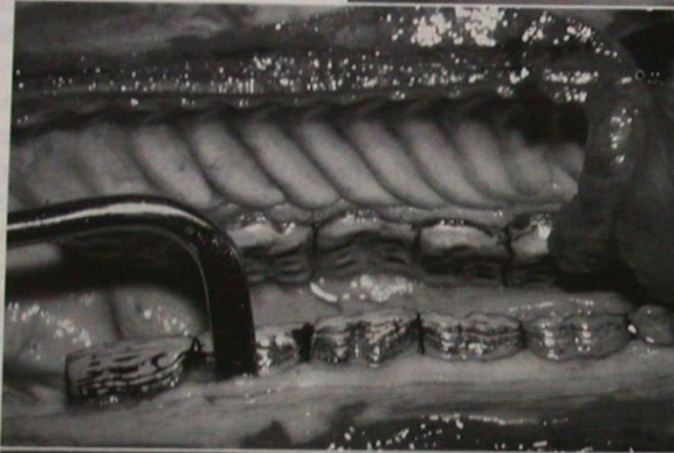



A



B



C



D



E






Fig. 10-77 Trephination of the equine skull.

ORAL NEOPLAZMALAR

Malign melanom

SCC

Fibrosarkom

Akantomatoz epulis

Fibroz osseoz epulis

Osteosarkom

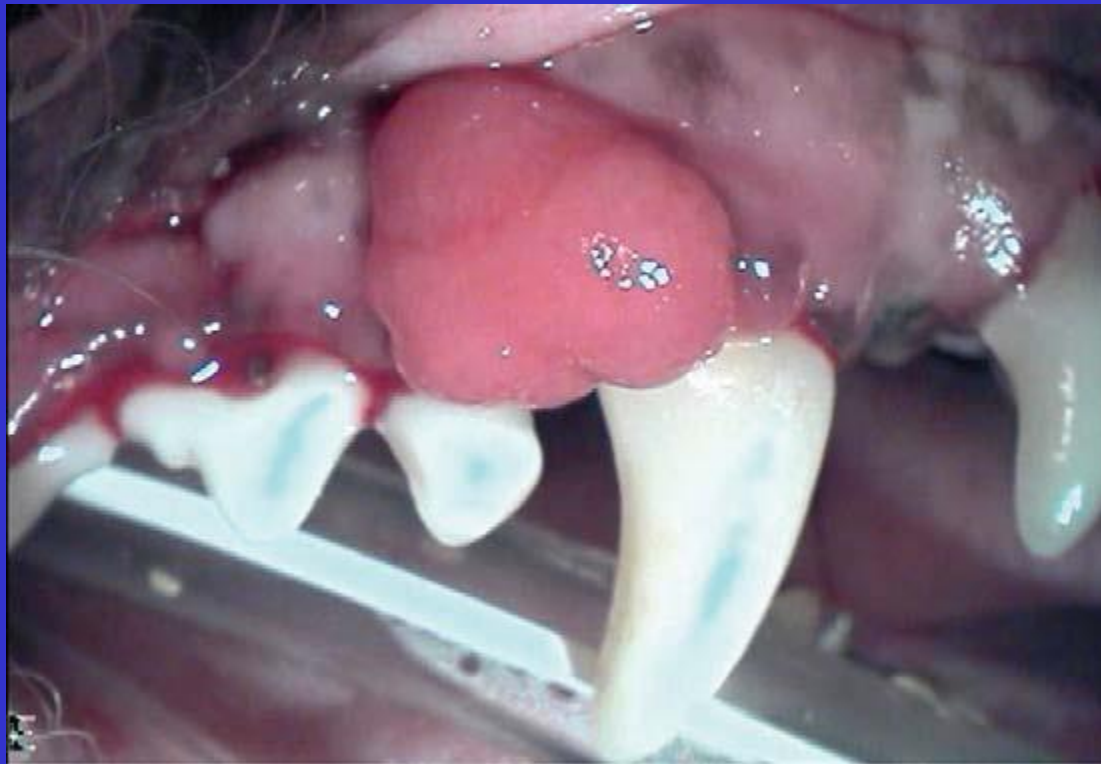Sağaltım:

Kriyoşirurji

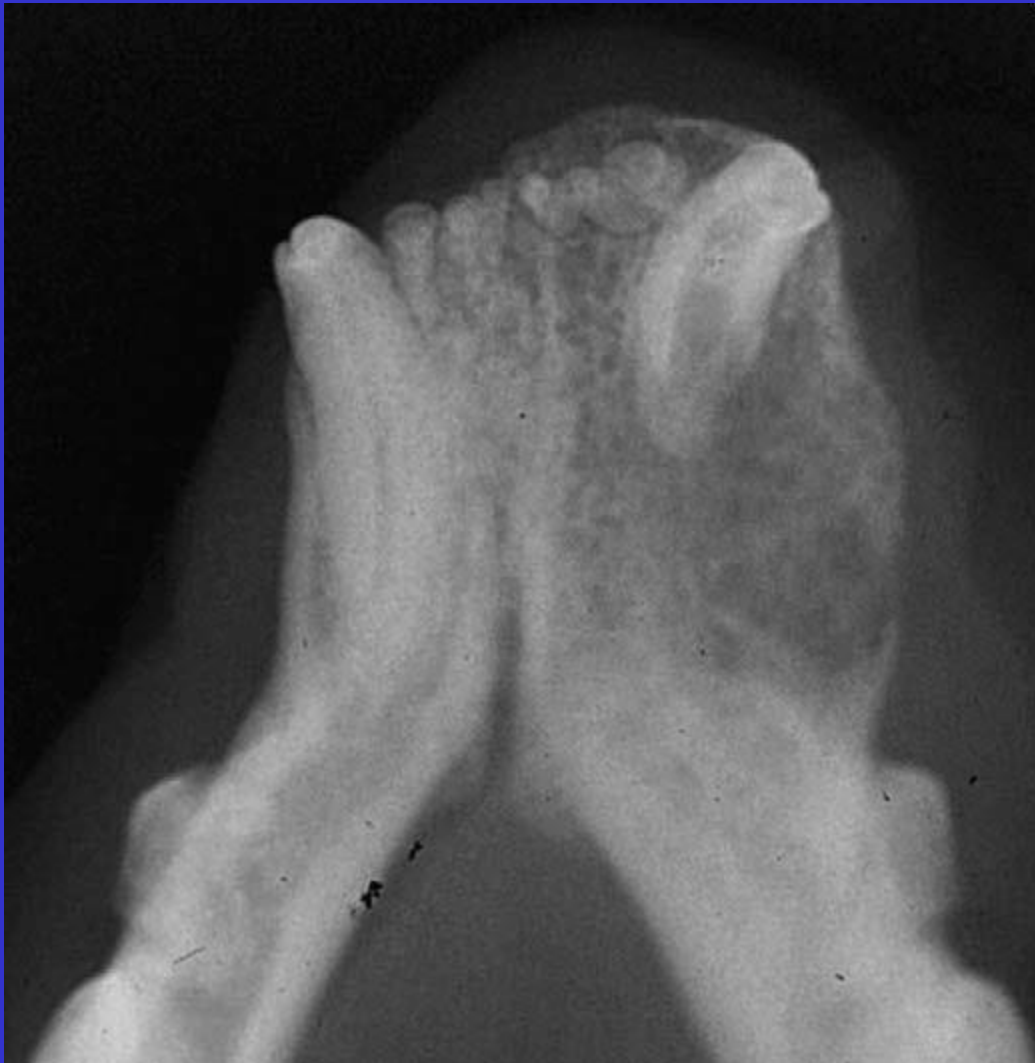Radyoterapi

Kemoterapi

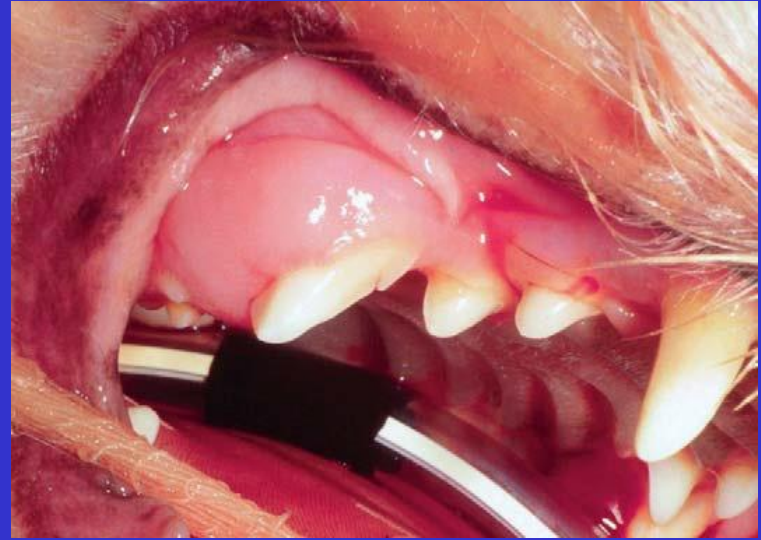
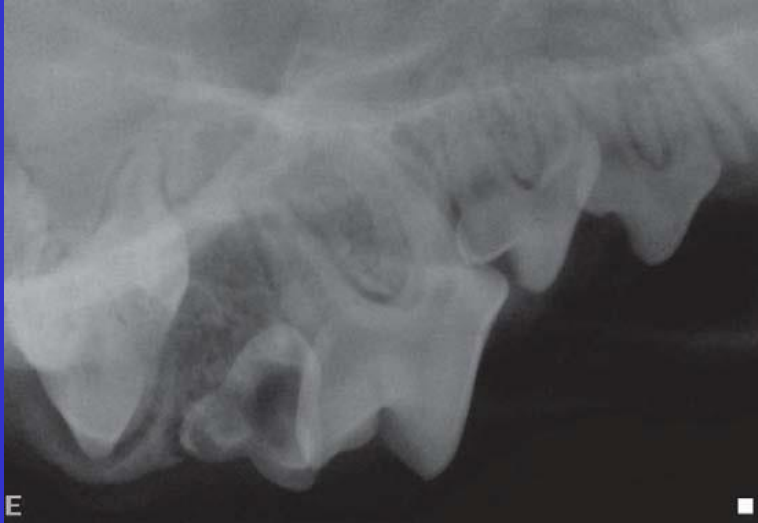Operasyon



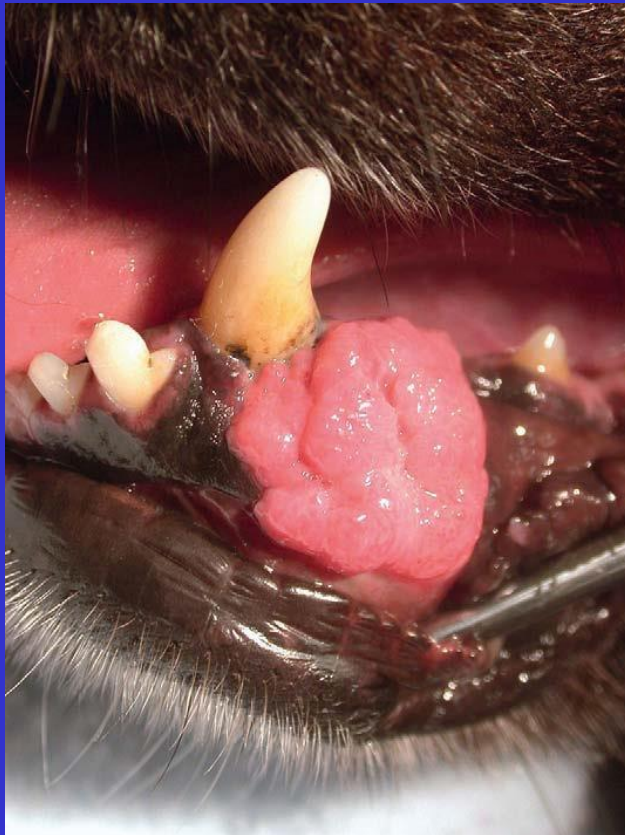Fibroz hiperplazi



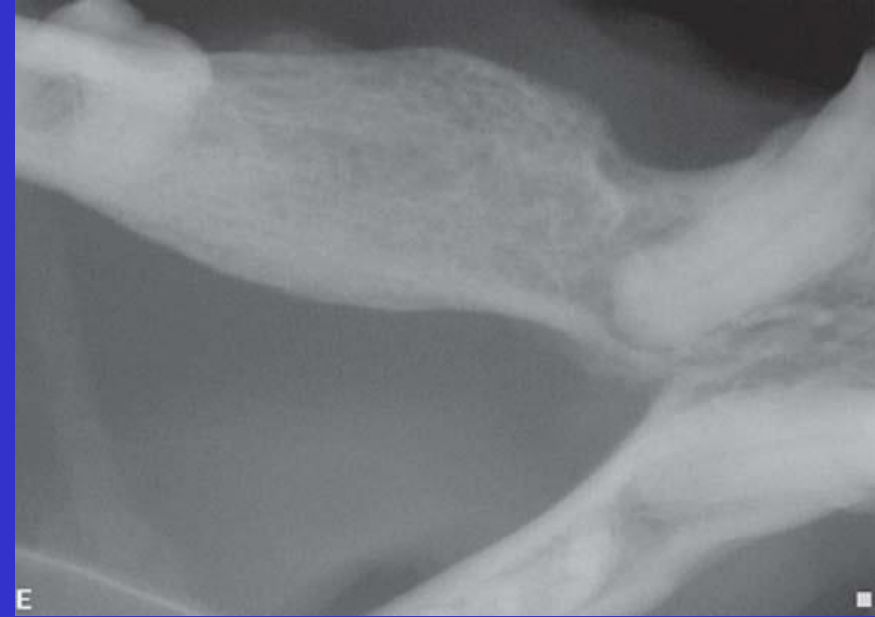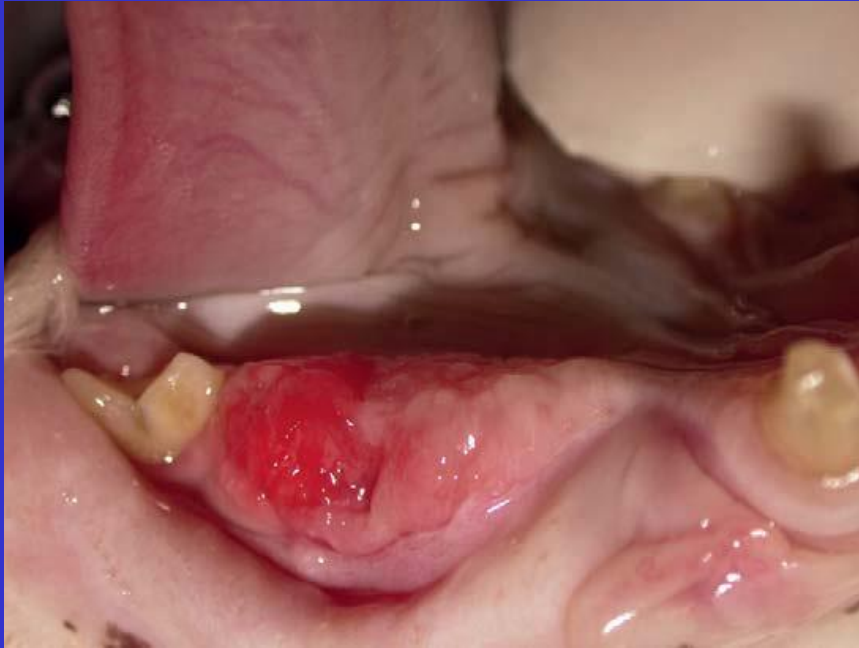Kedi osteomyelitis



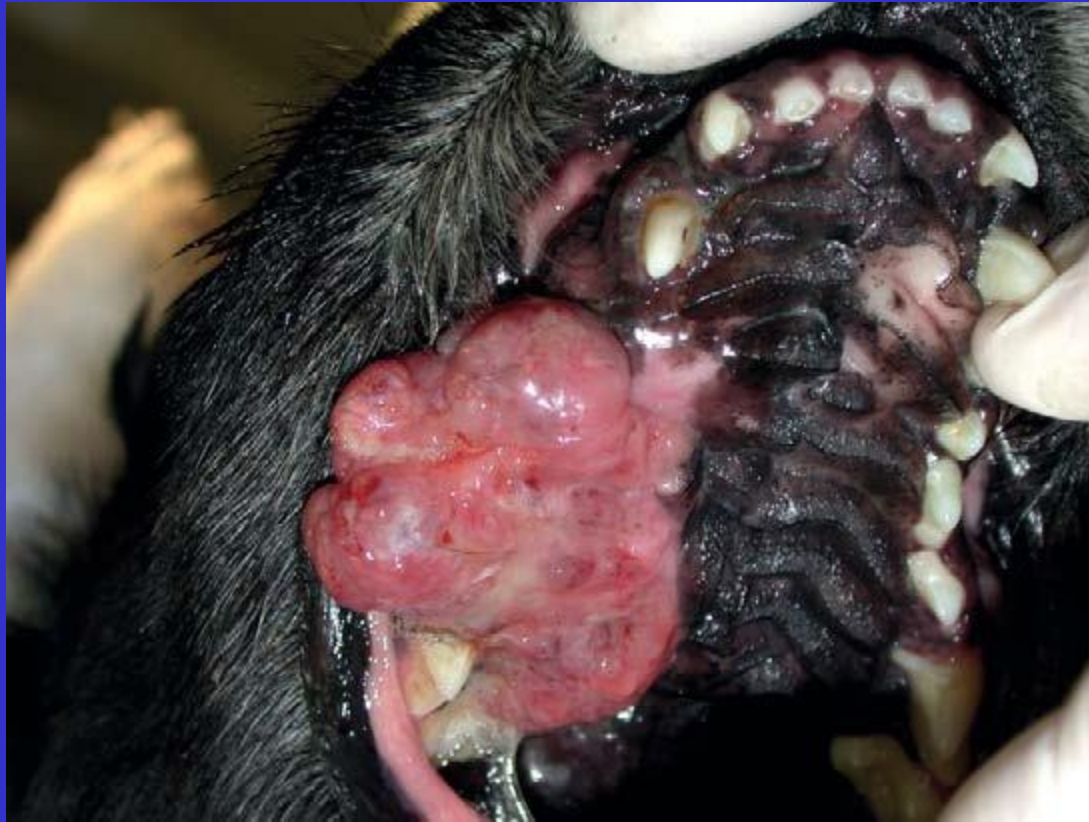Erupsiyon kisti



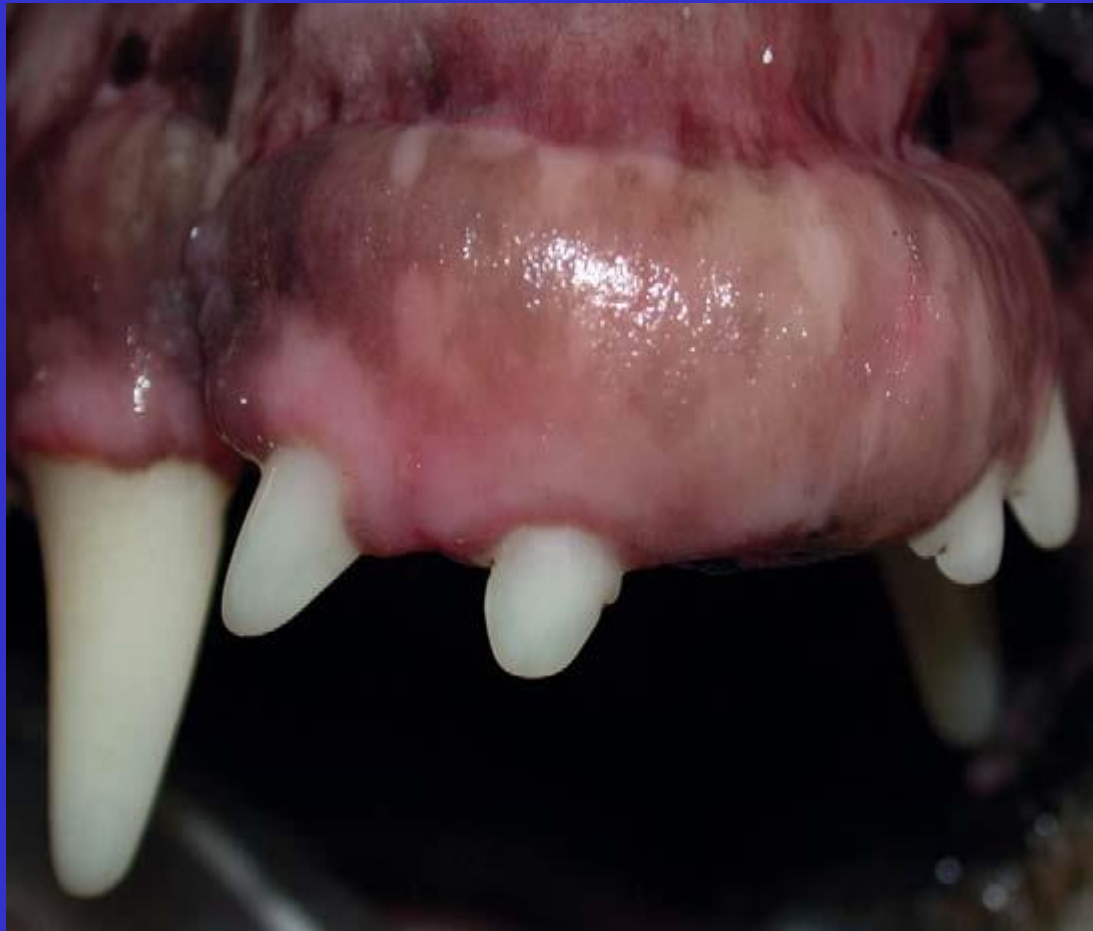Akantomatoz ameloblastoma



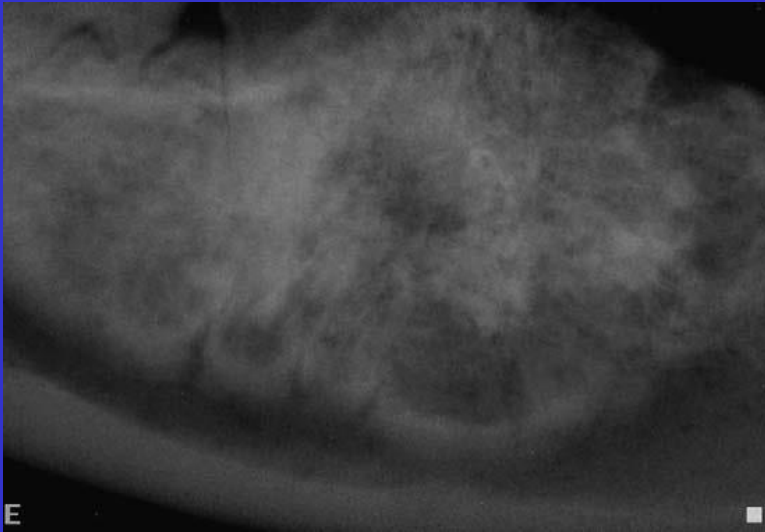
Epitelial odontojenik tümör



Malign melanom

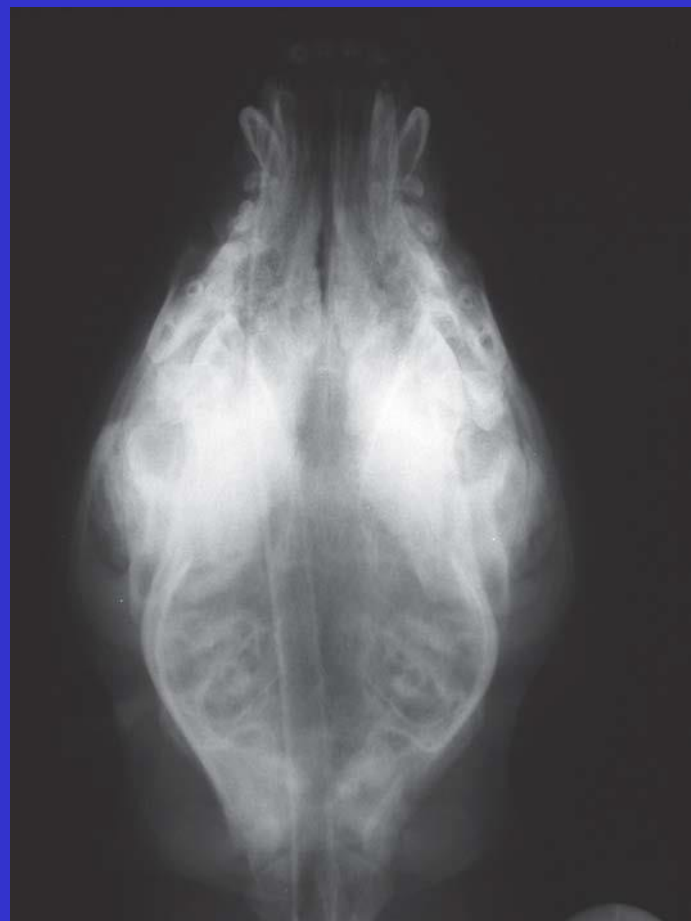

fibrosarkom

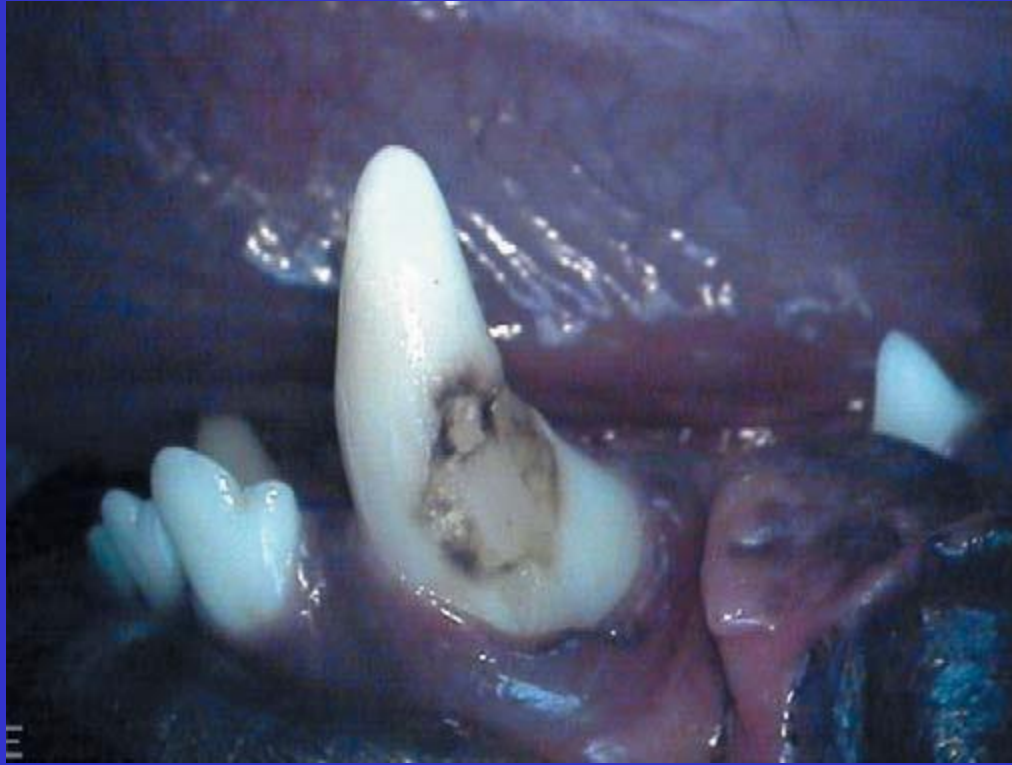

E

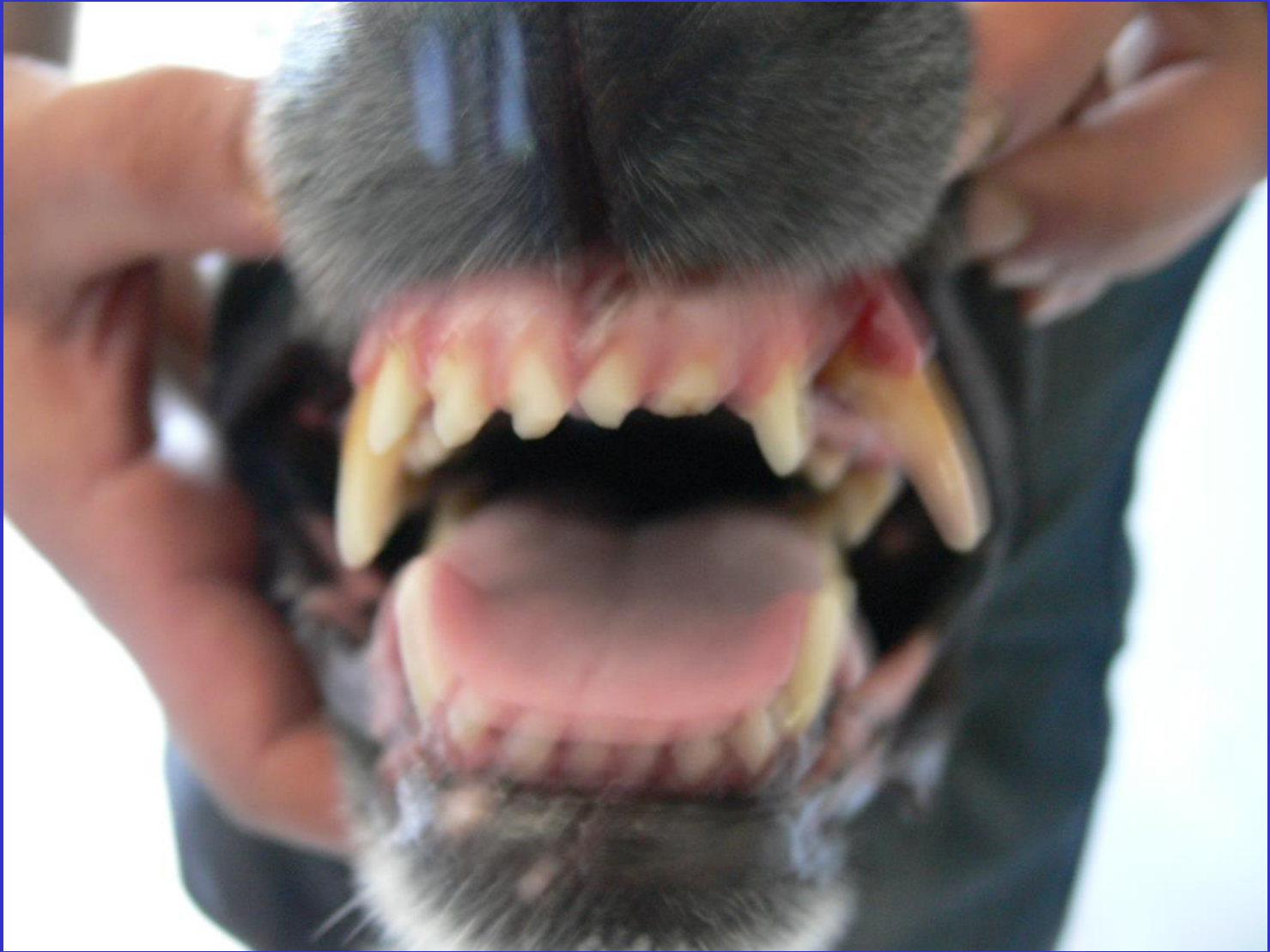osteosarkom



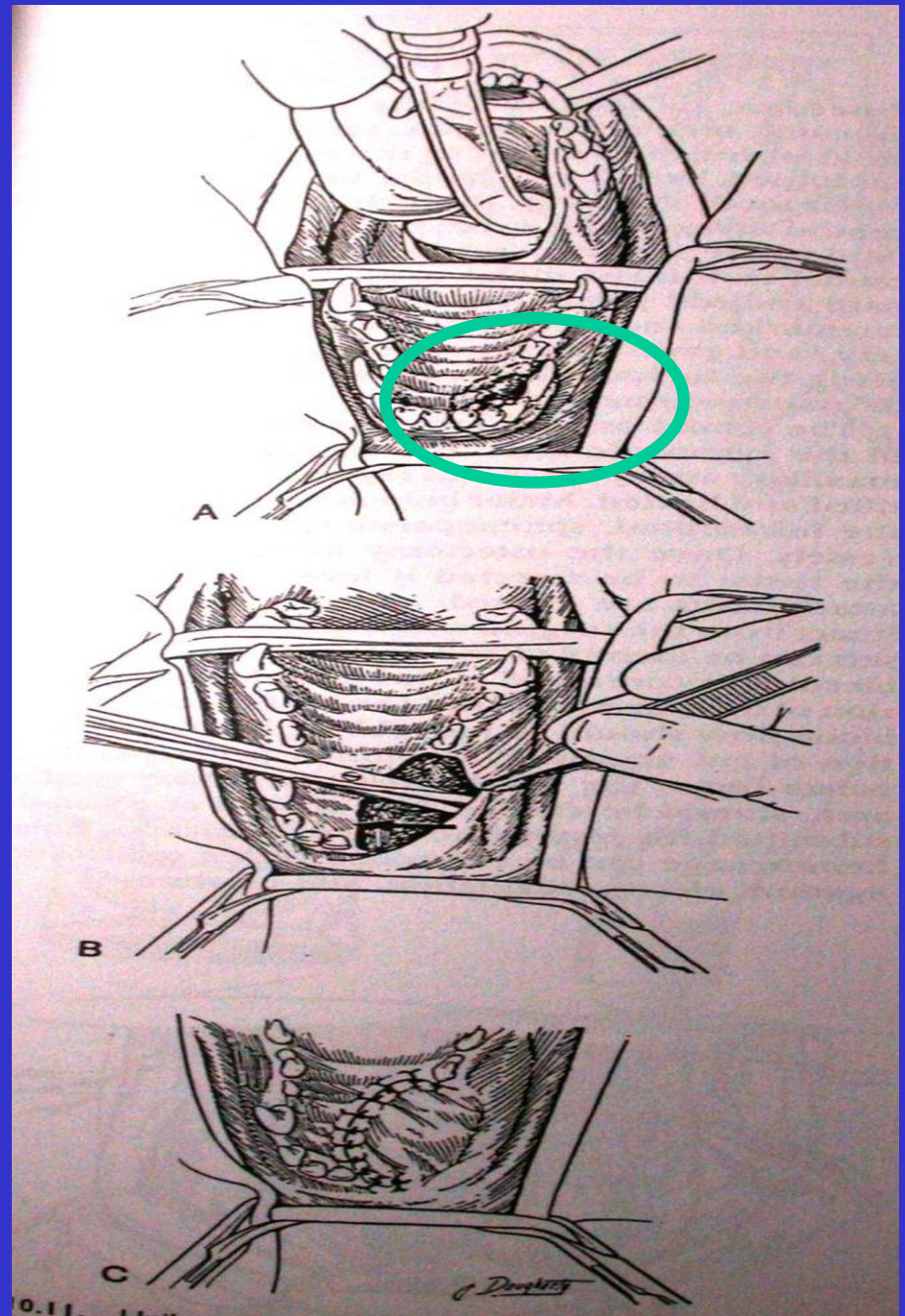
Mandibular osteopati

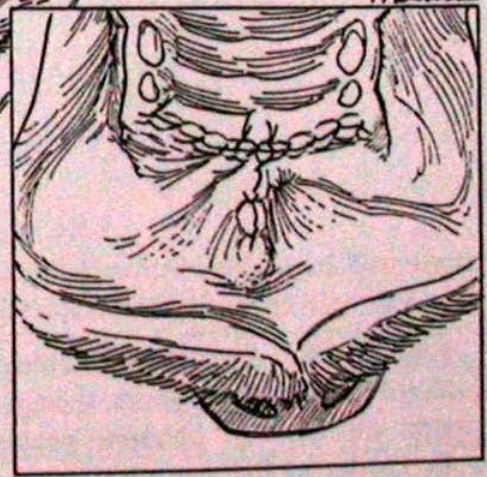
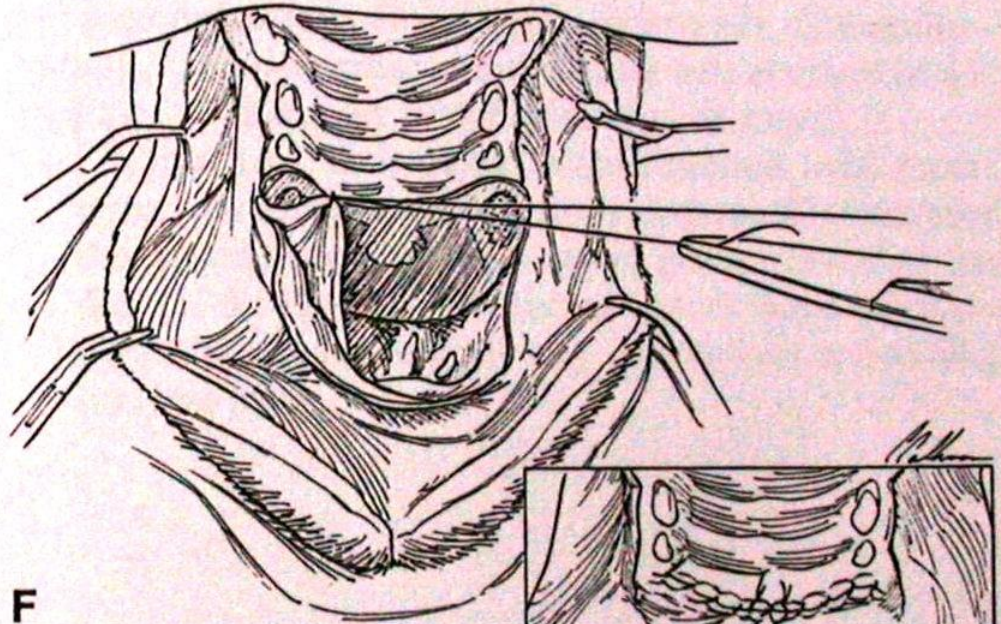
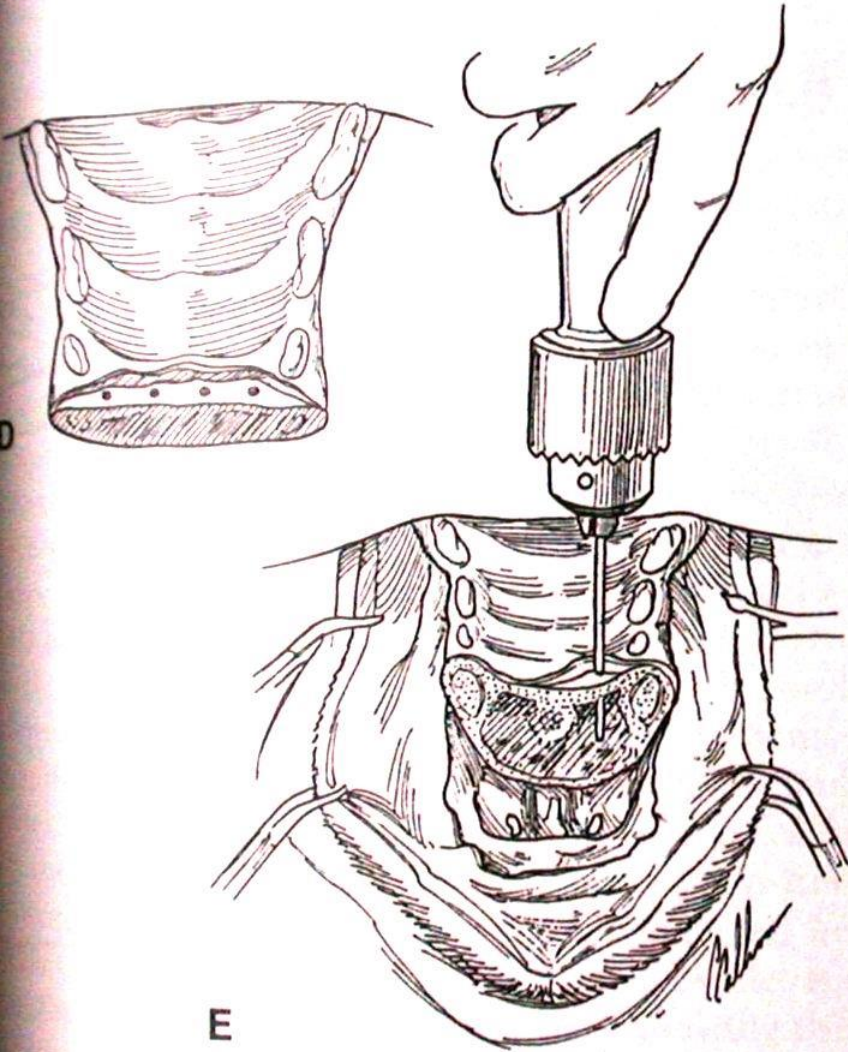


Enemal defekt



Maksillektomi





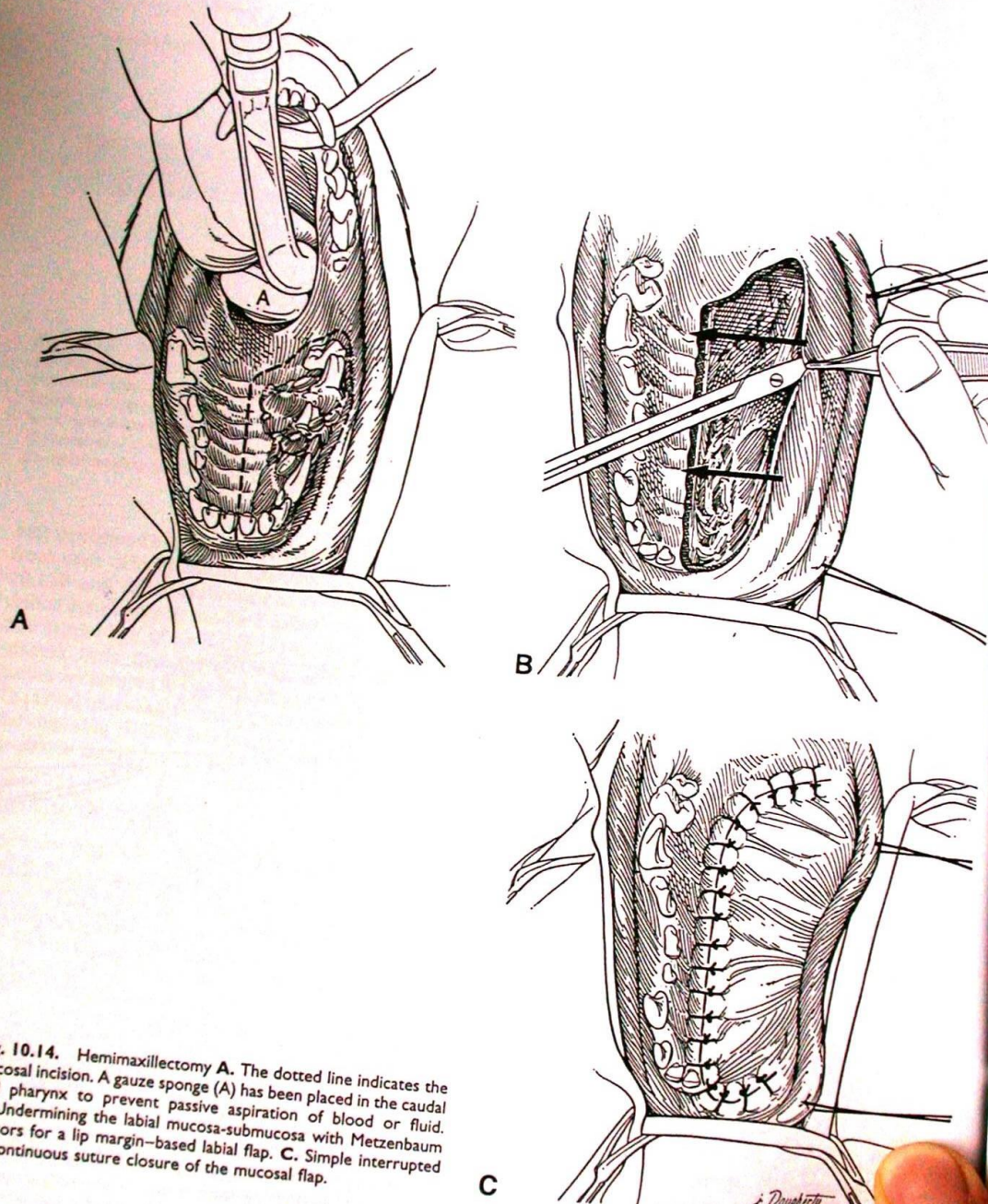


Fig. 10.14. Hemimaxillectomy **A.** The dotted line indicates the mucosal incision. A gauze sponge (A) has been placed in the caudal oral pharynx to prevent passive aspiration of blood or fluid. **B.** Undermining the labial mucosa-submucosa with Metzenbaum scissors for a lip margin-based labial flap. **C.** Simple interrupted or continuous suture closure of the mucosal flap.

C

