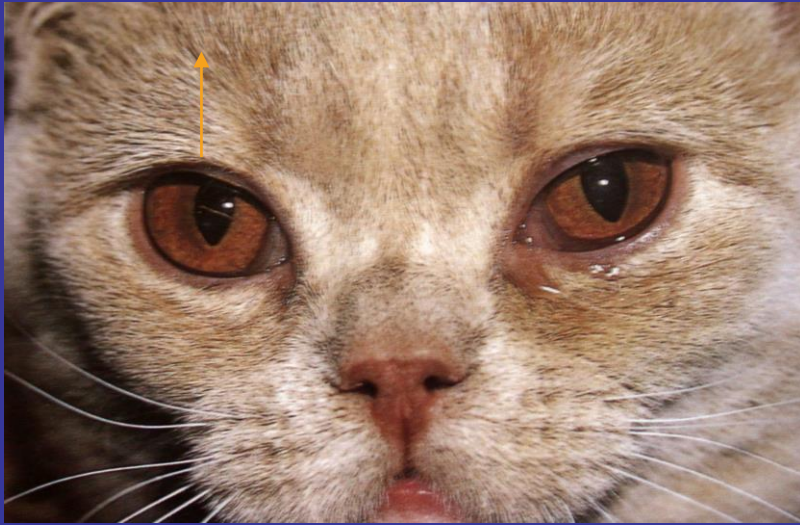




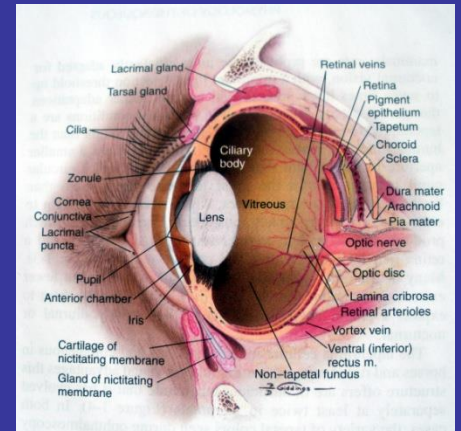
GÖZ KAPAKLARININ BOZUKLUK, ANOMALİ VE HASTALIKLARI

HORNER'S SENDROMUNDA MÜLLER'S KASI FONKSIYON KAYBI SONUCU HAFIF PİTOZİS



KAPAKLARIN FONKSİYONU

- Tarsal gland ve konjunktival goblet hücre sekresyonları PTF nin endişindeki lipit ve en içindeki mukopolisakkarit tabakasının oluşumuna katılır
- Gözyaşının evaporasyonunu engeller
- Fazla göz yaşını nazolakrimal kanala pompalar

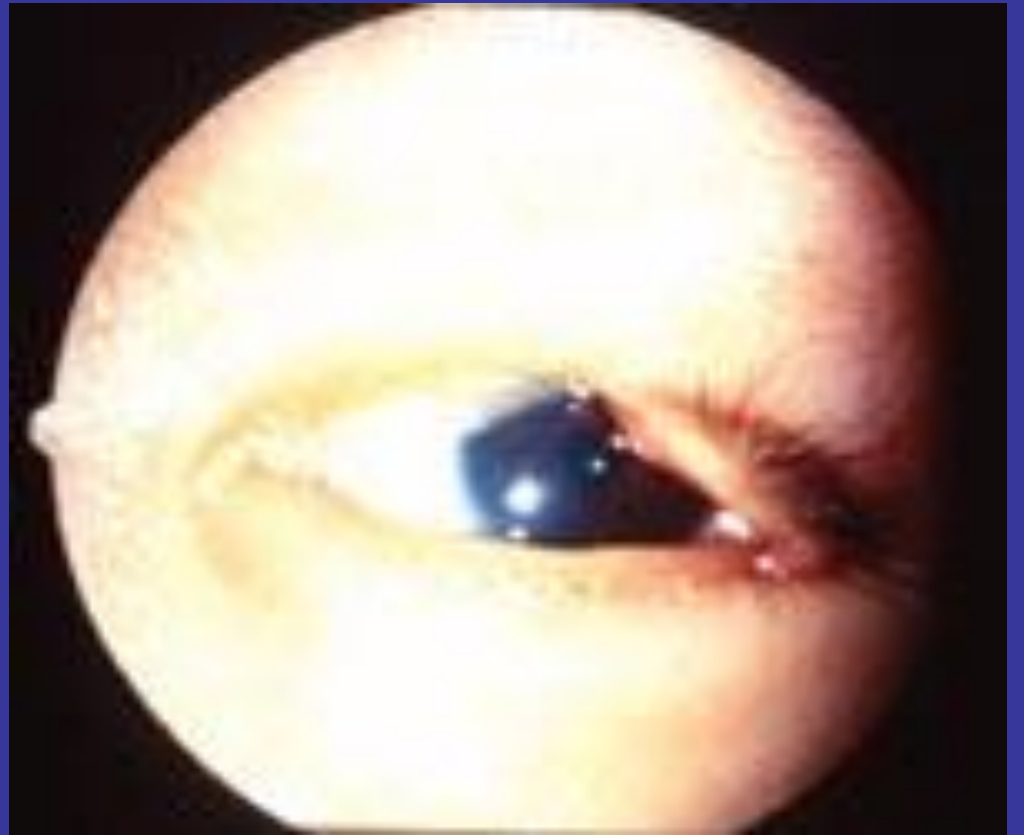


KONJENİTAL ANOMALİLER

- Coloboma
- Prominent nazal fold

KOLOBOMA

- Göz kapağı parsiel gelişim defekti



KISA BURUN, GENİŞ GÖZ KAPAĞI, PROMİNENT' GÖZLÜ IRKLAR

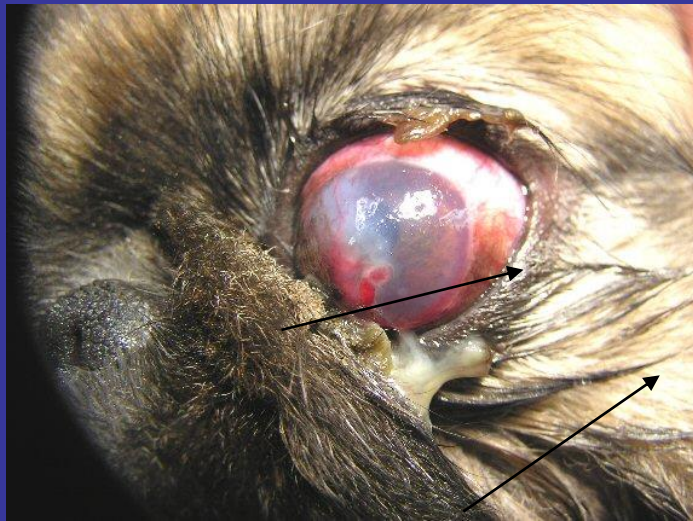- Pug
- Shih Tzu
- Pekingese



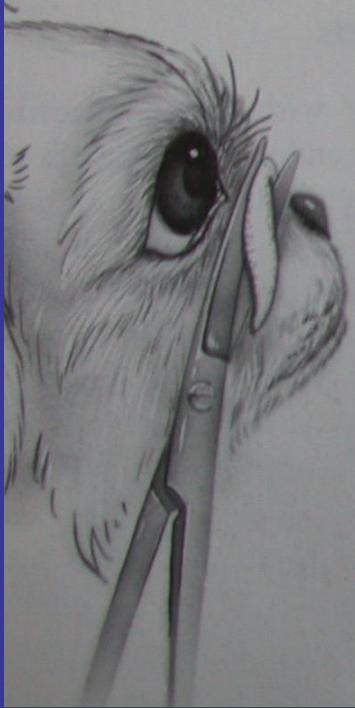BU IRKLARDA

- Tam göz kırpması şekillenmez (lagofthalmus), göz kapakları tam olarak kapanmaz
- Uyurken de göz kapakları tam kapanamaz ve
- Kornea merkezi hava ile temasda kalır
- Sonuçta korneal problemler gözlenir

PROMINENT NAZAL FOLD

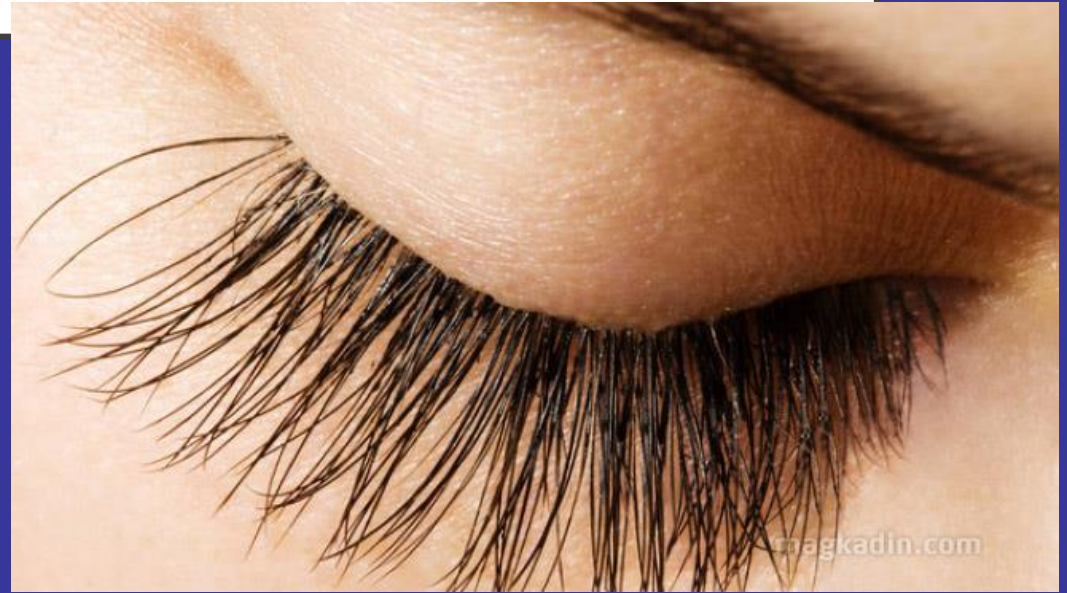

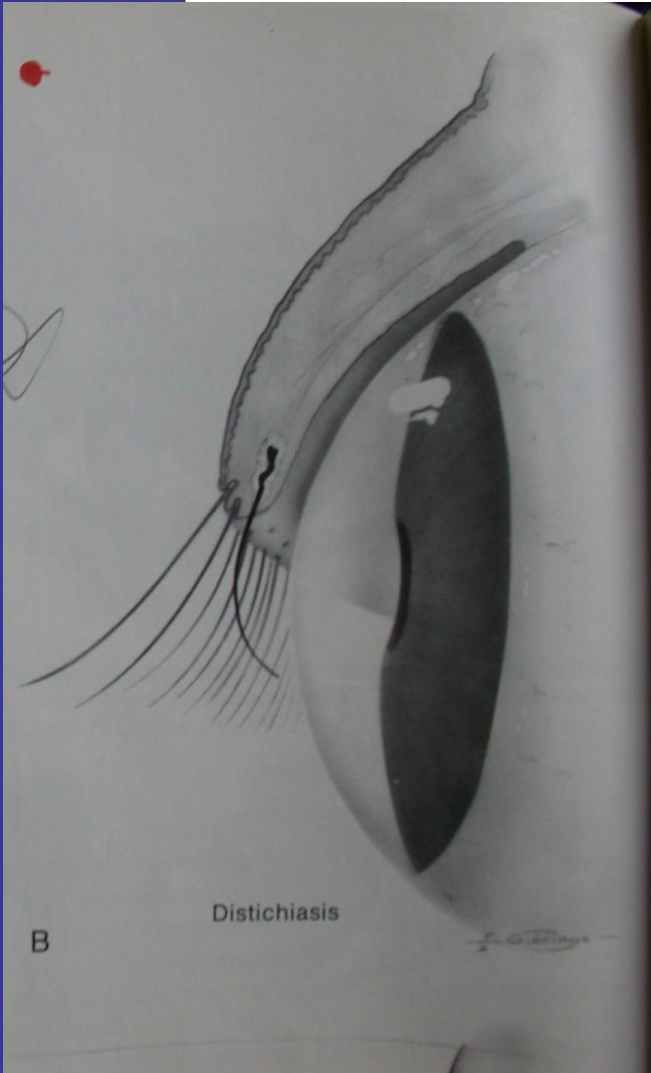
EYELIDS



KIRPIK ANOMALİLERİ

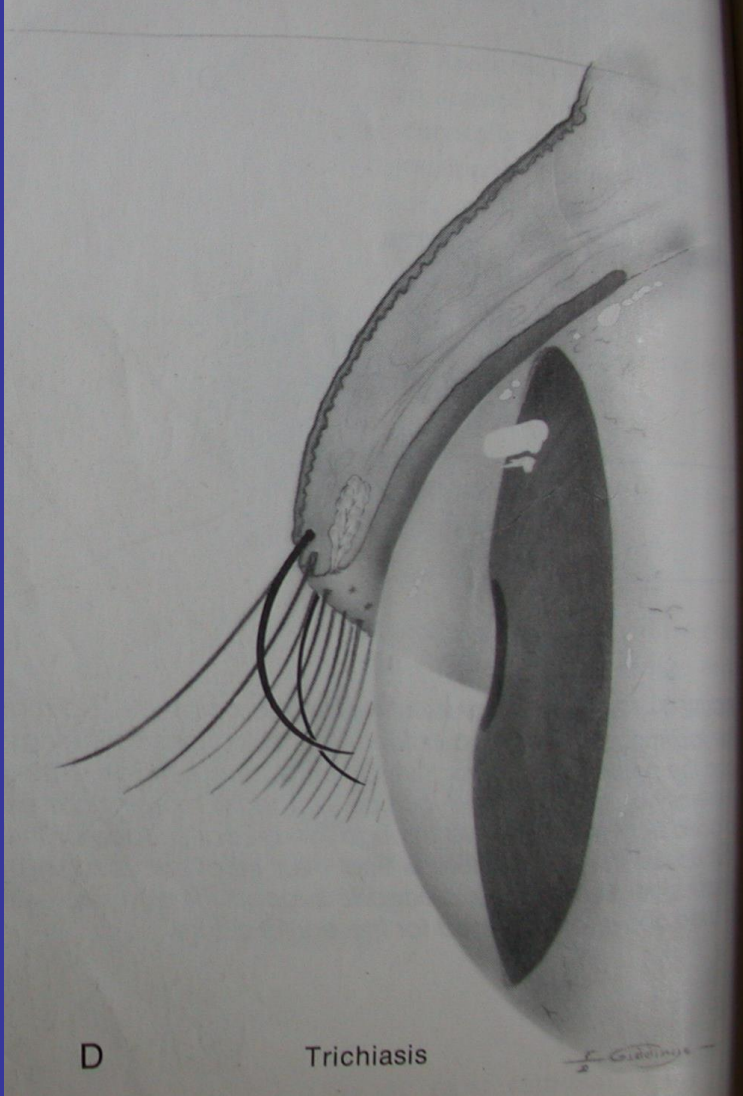
- Distikiazis
- Trikiazis
- Ektopik silia





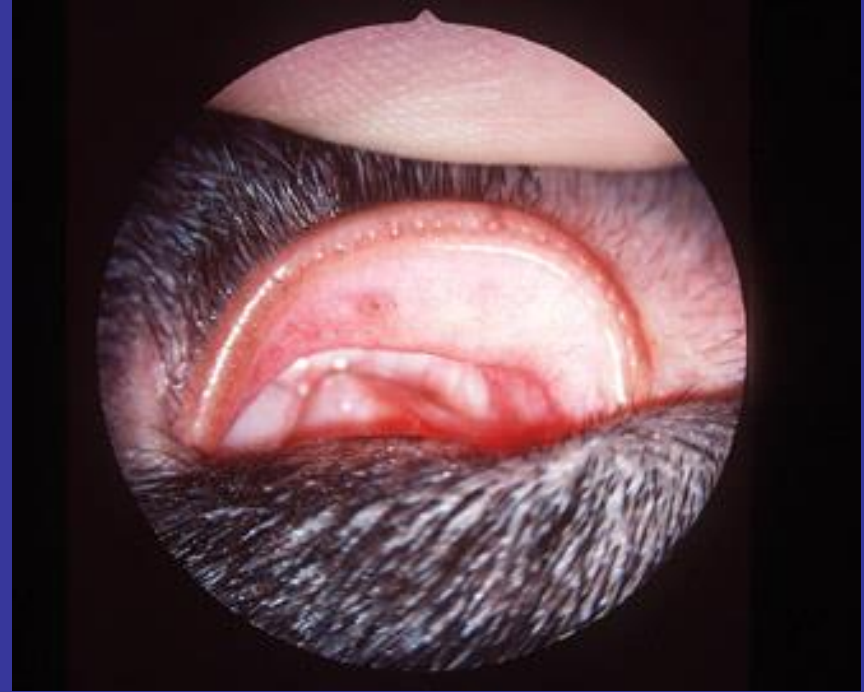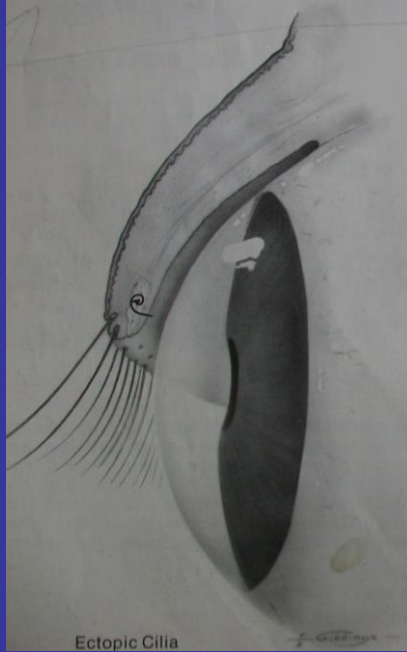
Meibomian bezinin deliğinden çıkar
korneaya dönüktür

TRIKIAZİS

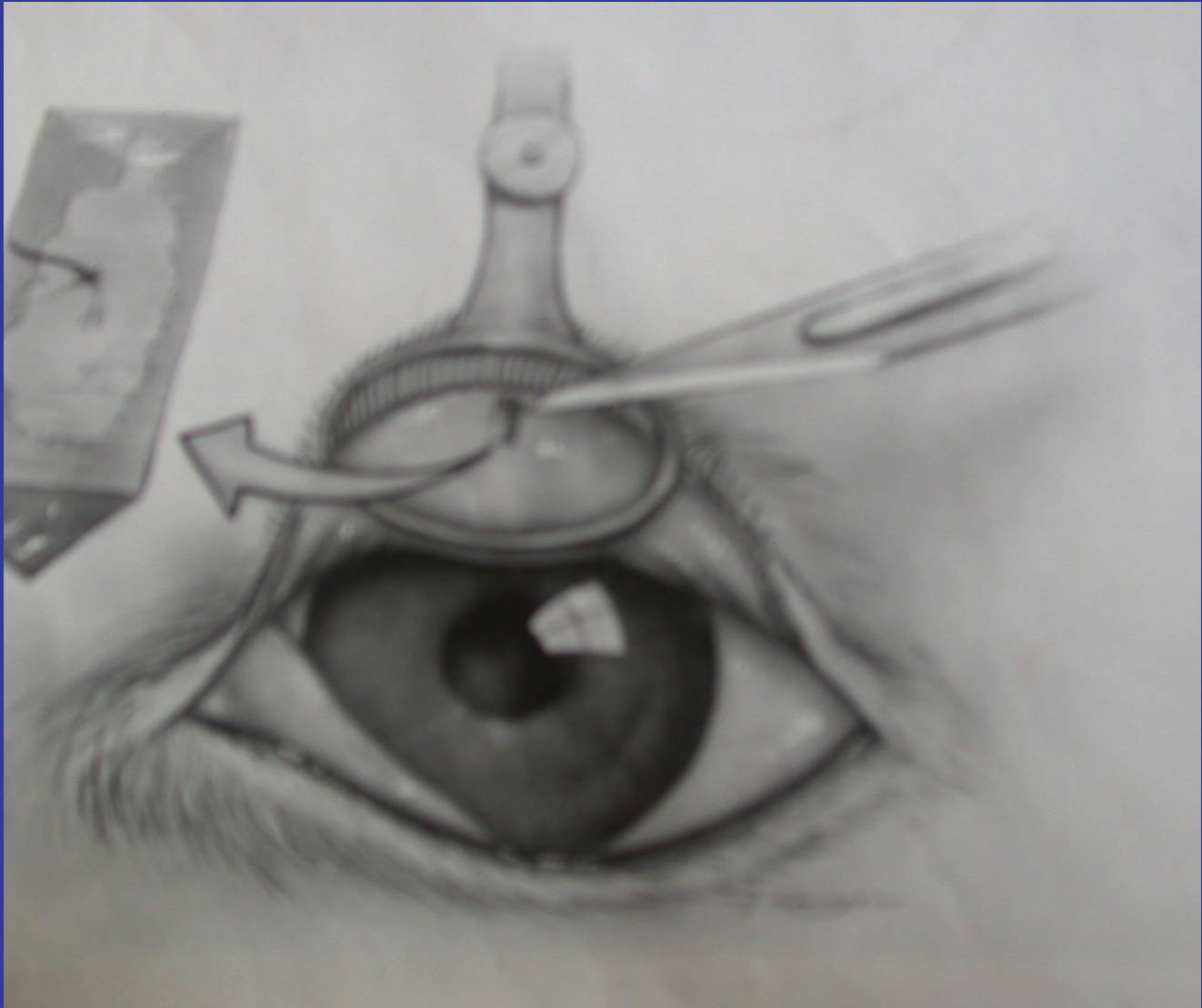


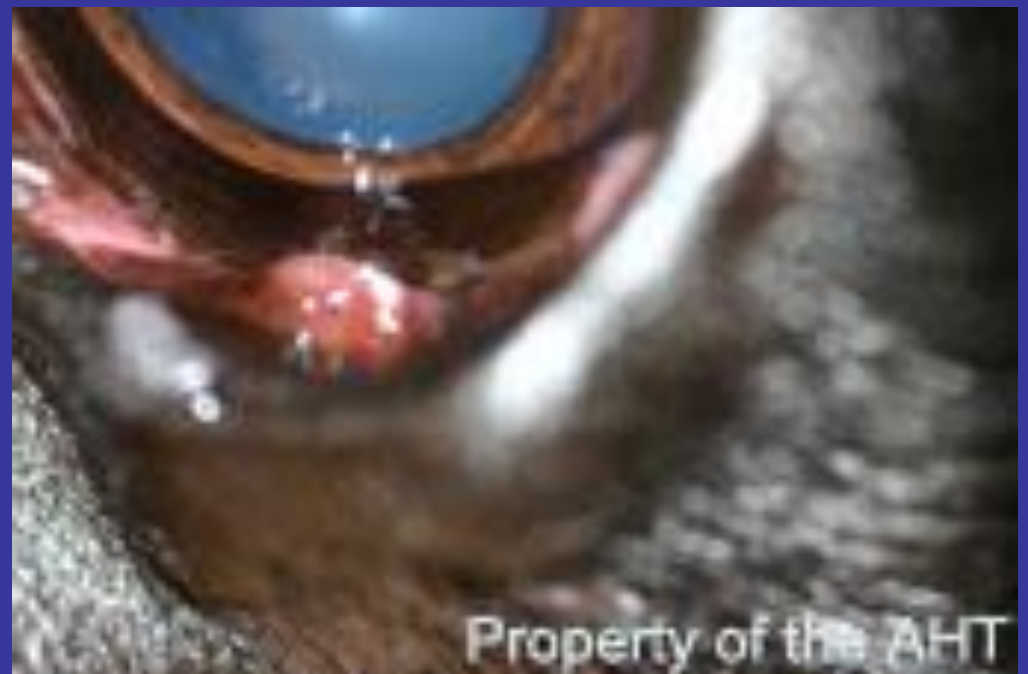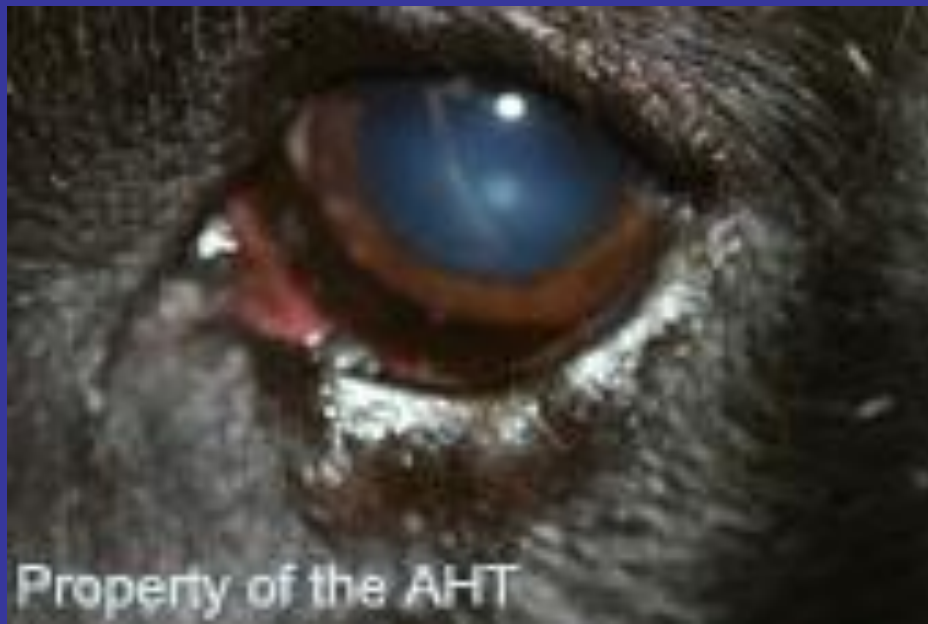Kirpik veya komşu deri kılları normal yerinden çıkar ancak korneaya yöneliktir.

EKTOPIK KIRPIK



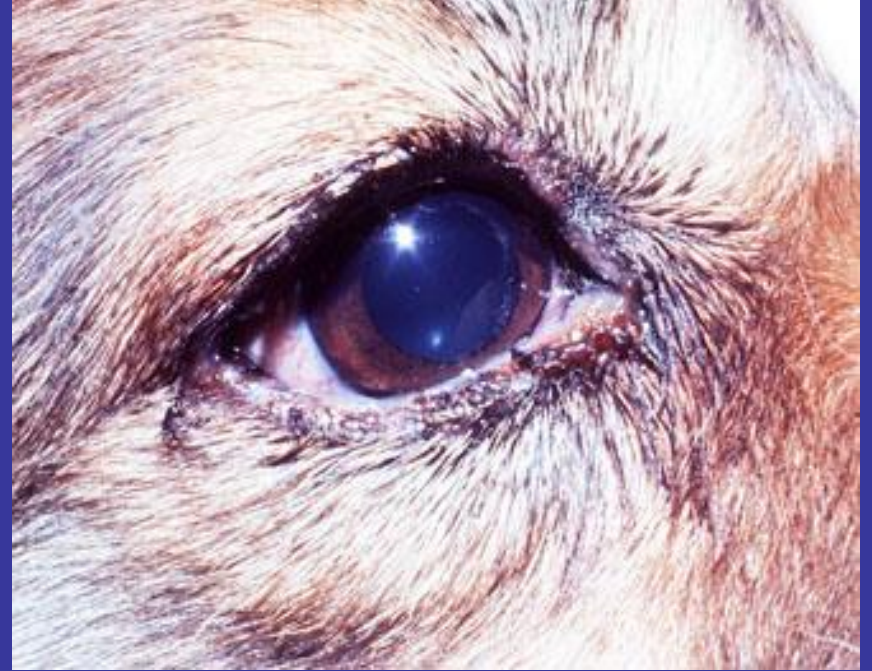Meibomian bezinden çıkar konjunktivayı delerek korneaya yönelir, irrite eder





SUPURATIF TARSİTİS, BLEFARİTİS

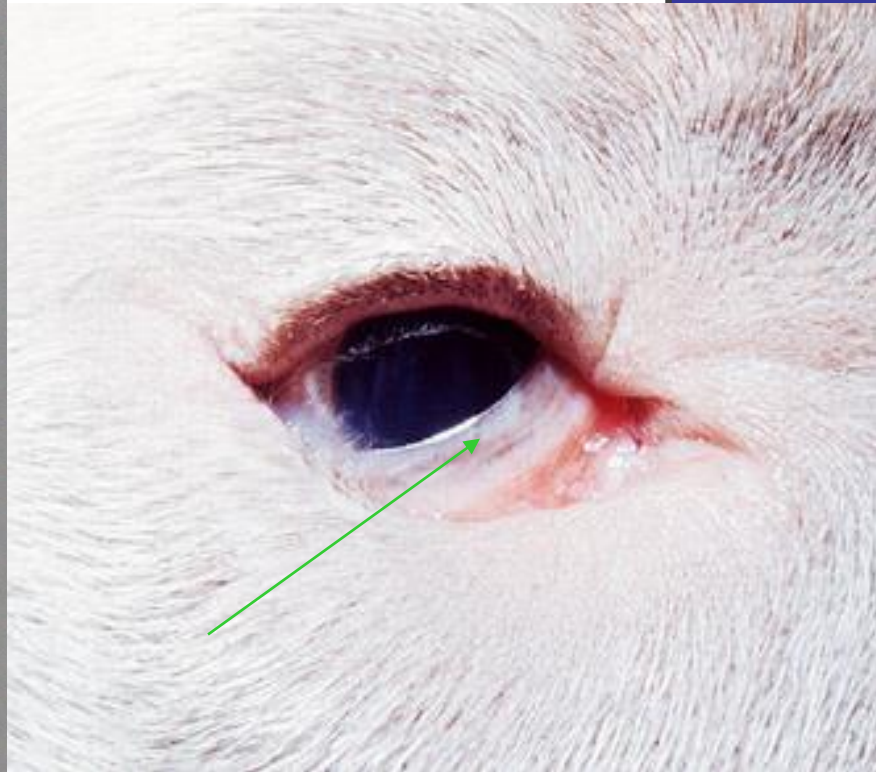
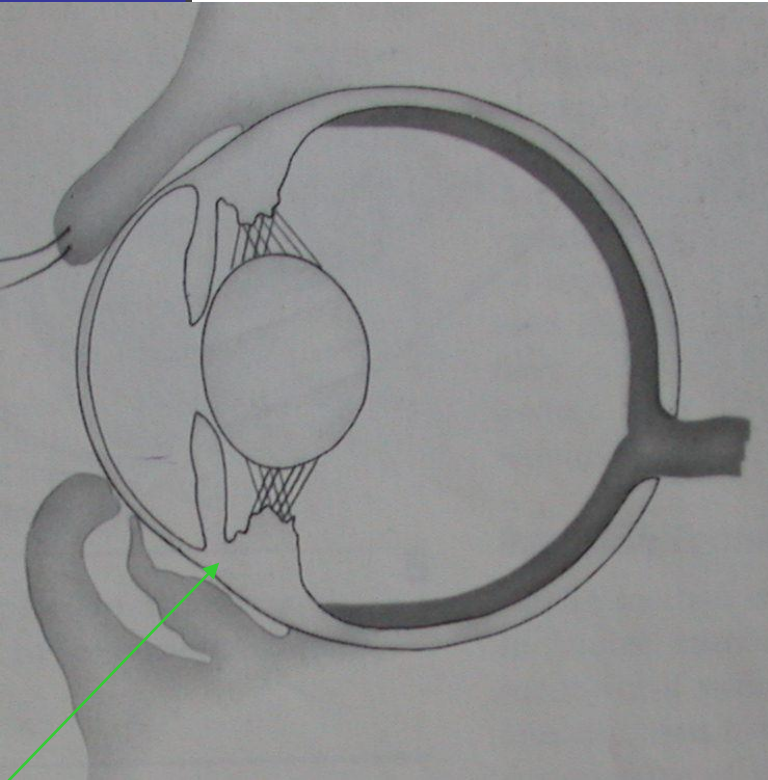
- Genellikle bakteriel kaynaklı göz kapak kenarlarının enfeksiyonlarıdır



KAPAK ANOMALİLERİ

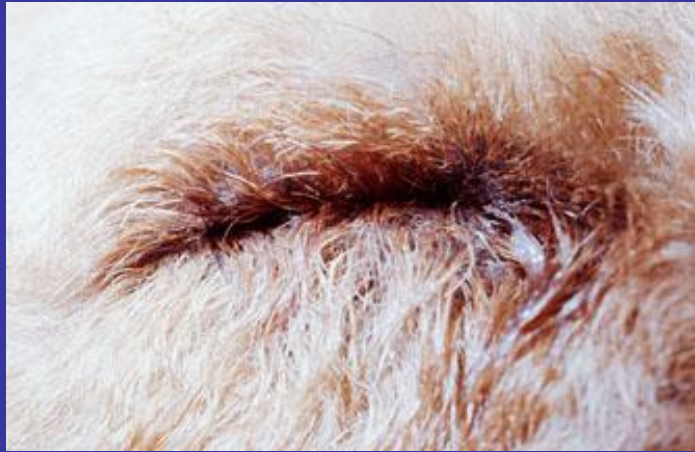- Entropion
- Ektropion
- Euroblefaron

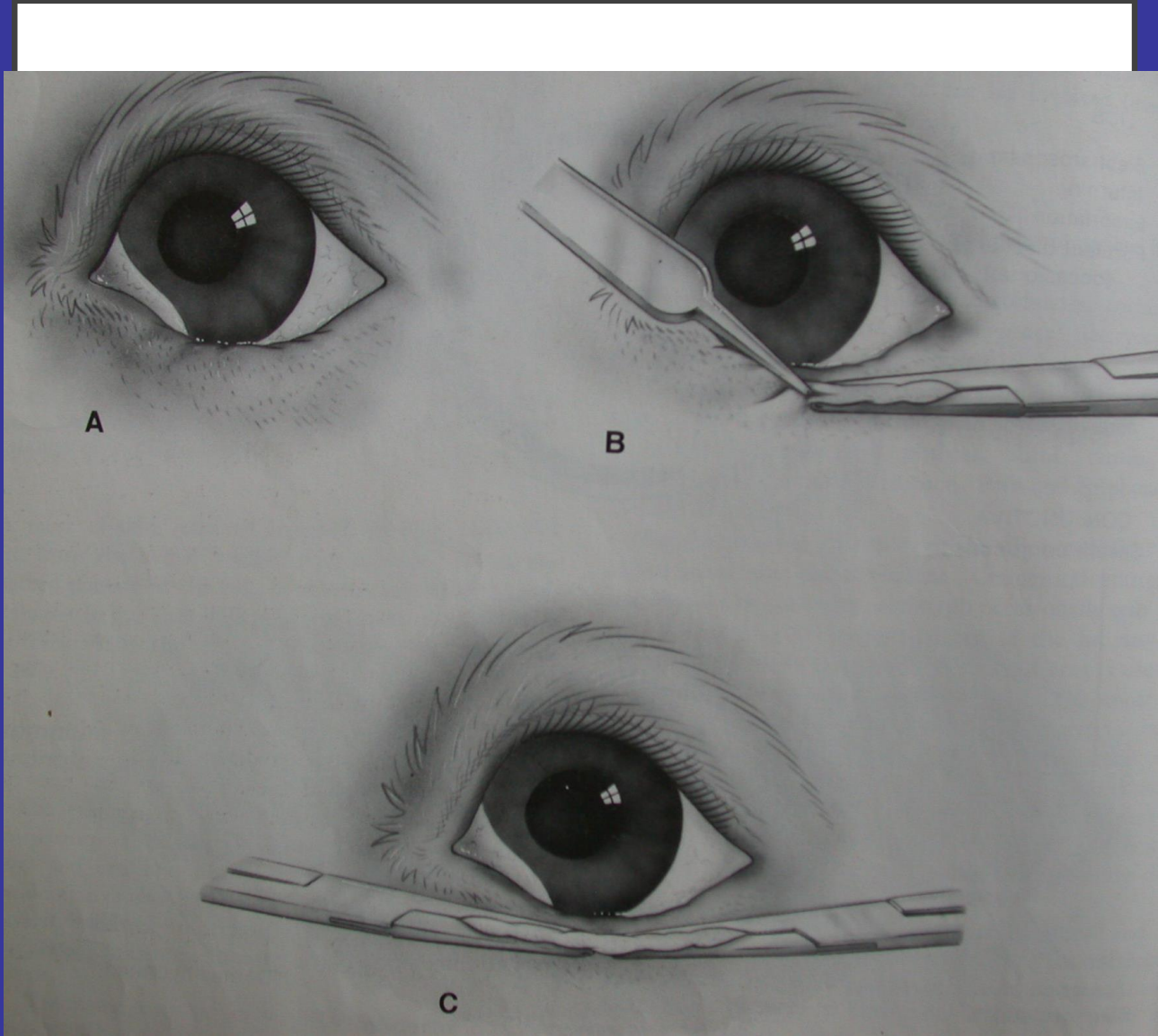
ENTROPION

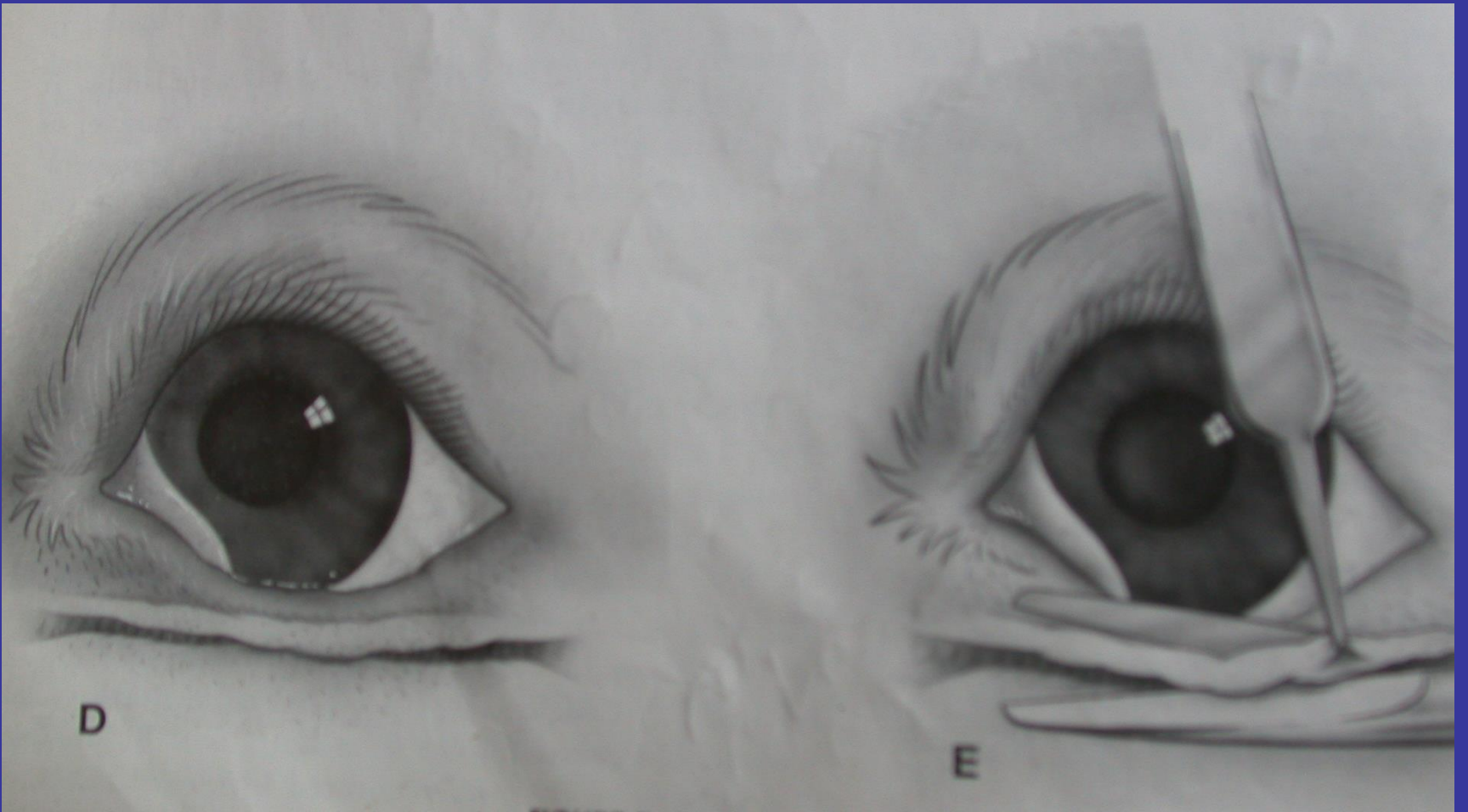


ENTROPION

- Anatomi (konjenital) entropion
- Spastik entropion (globun anterior segment ağrılarından kaynaklanan)
- Skatriziel entropion (kapak yangıları, travma, yanıklar sonrası)









D

E

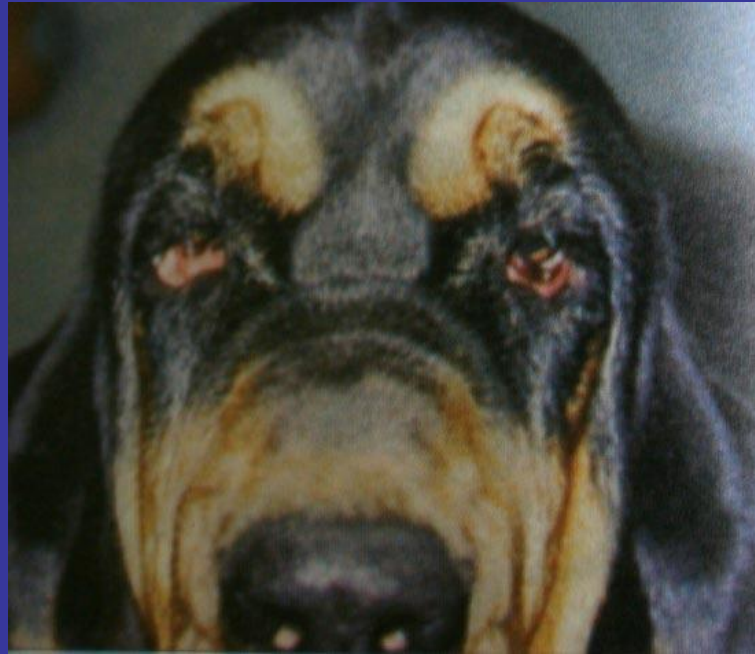

SHAR PEİ YAVRULARARINDA SUTUR TEKNİK

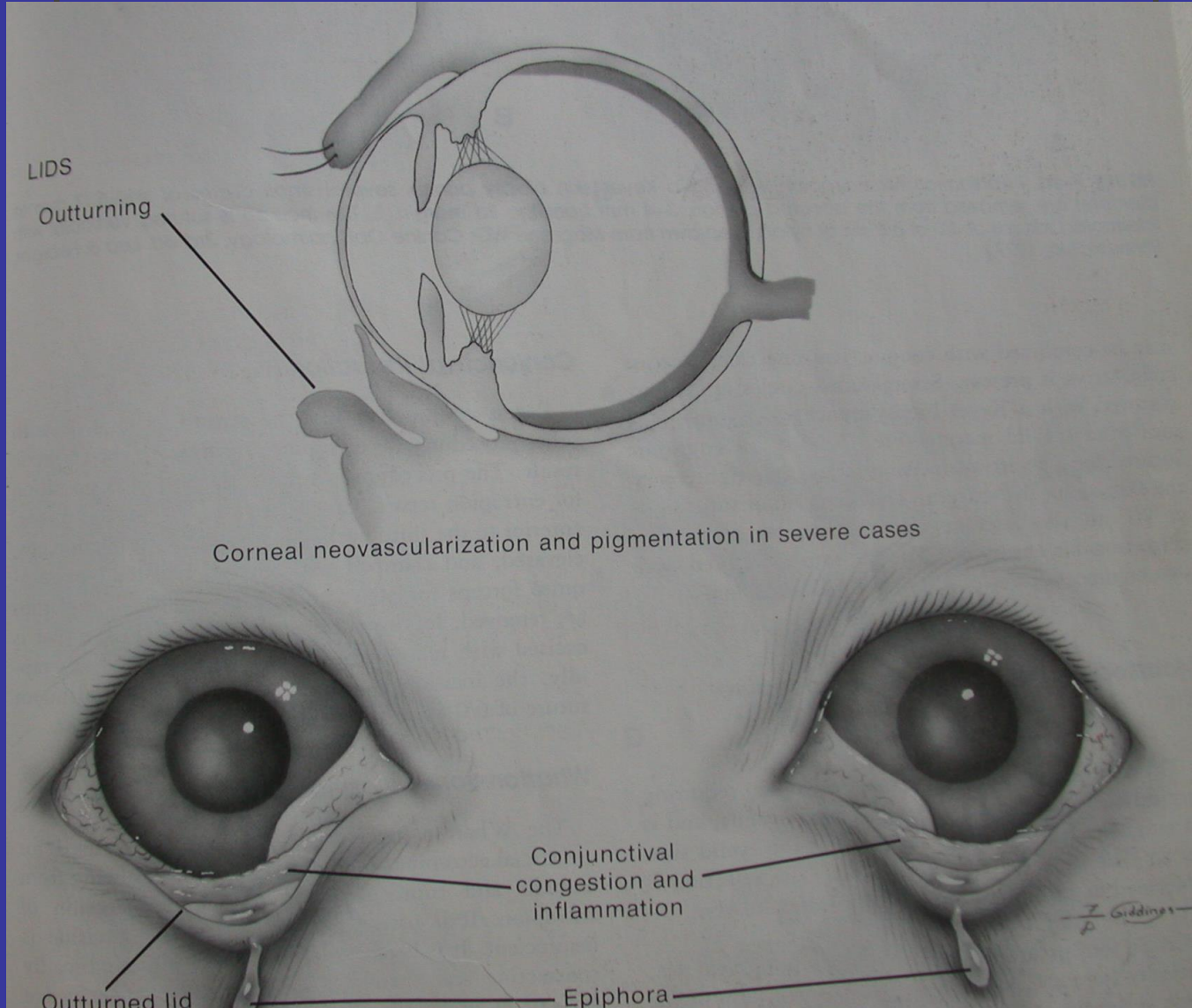


Vertikal matres


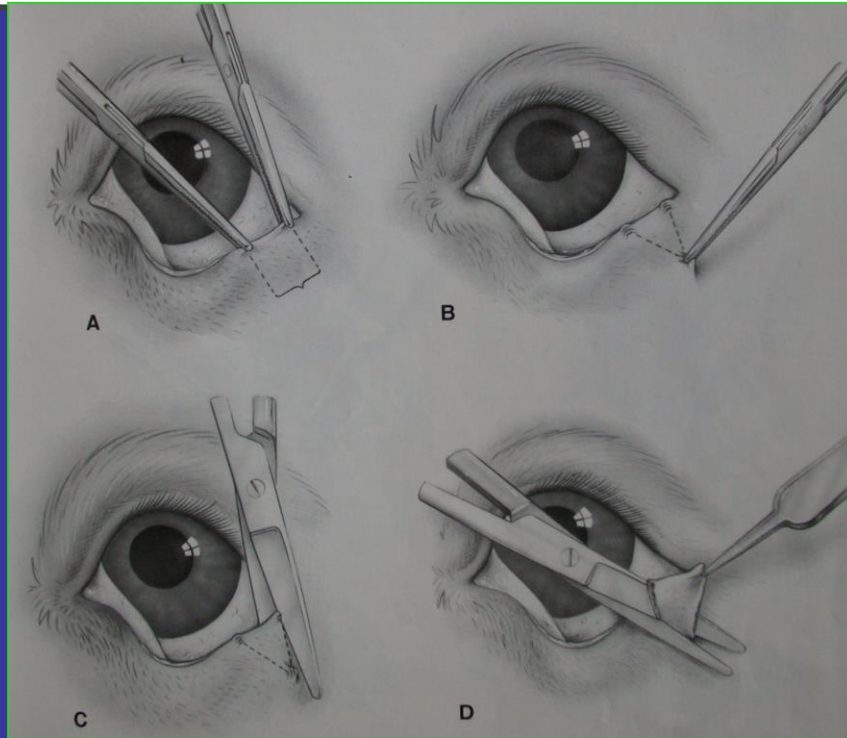
EKTROPION

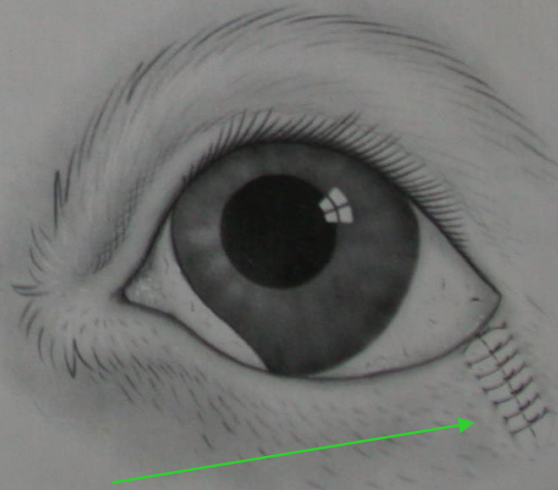
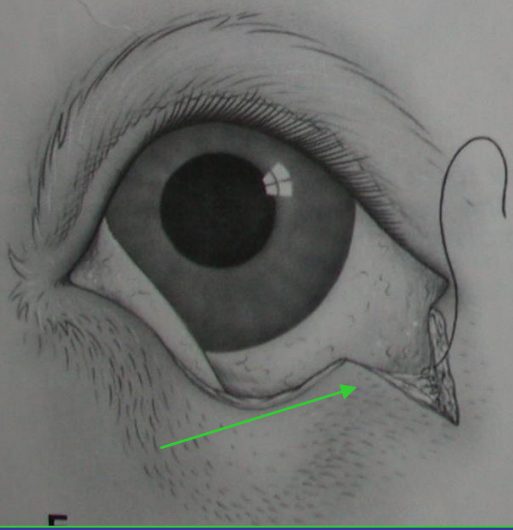
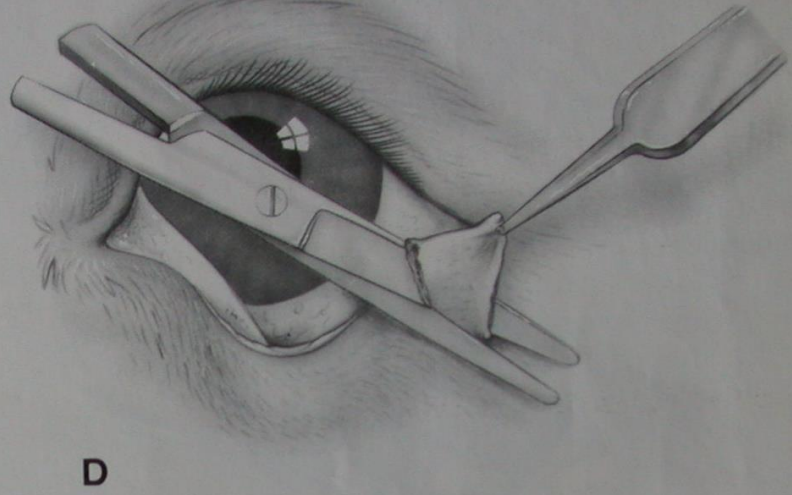
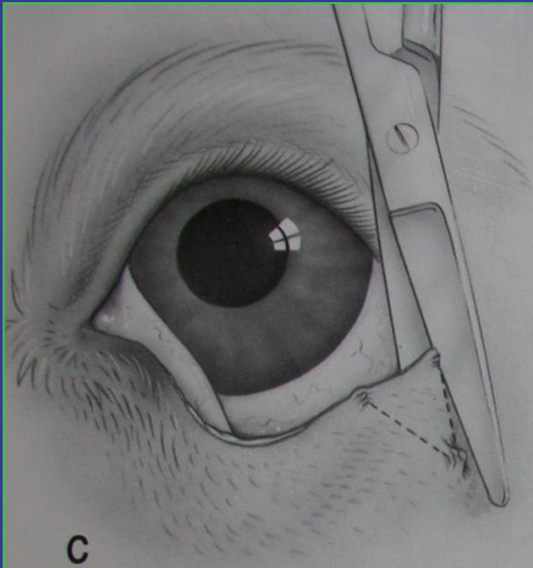


EKTROPION

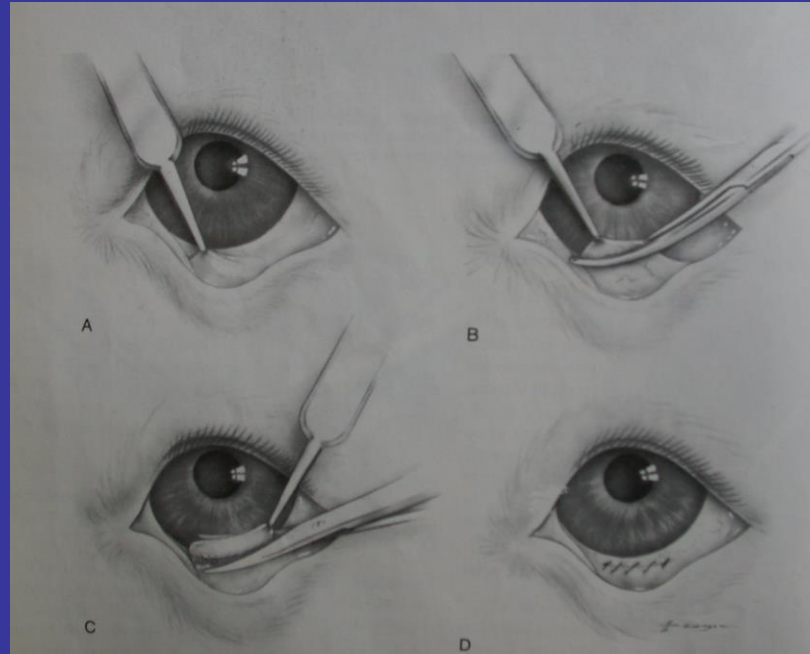


MODIFIYE KUHNT SZYMANOWSKI

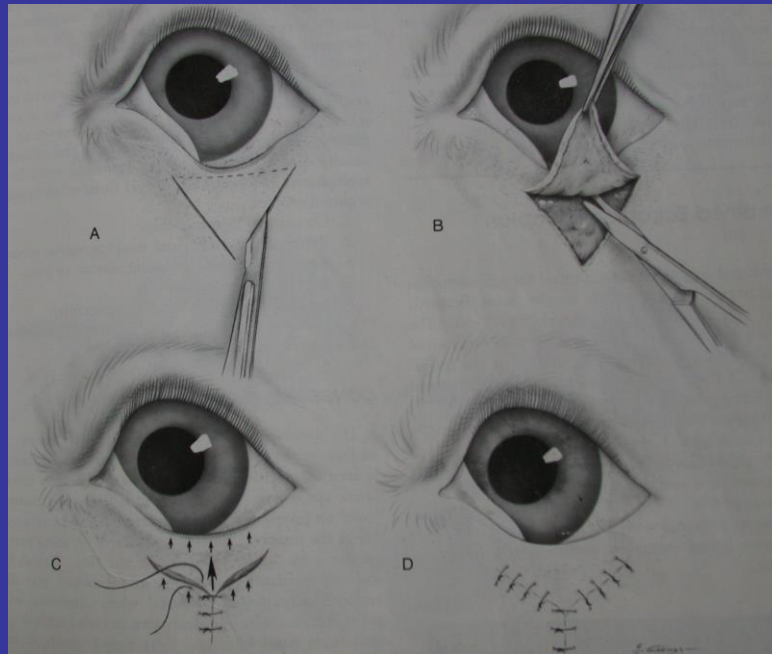




KONJUNKTIVAL REZEKSİYON

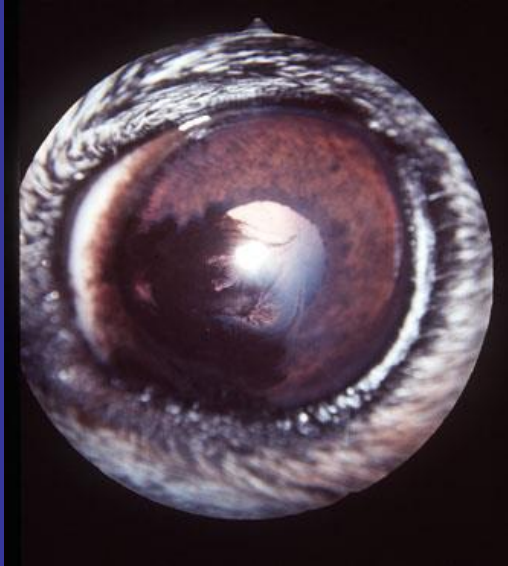


WHARTON-JONES BLEFAROPLASTI*

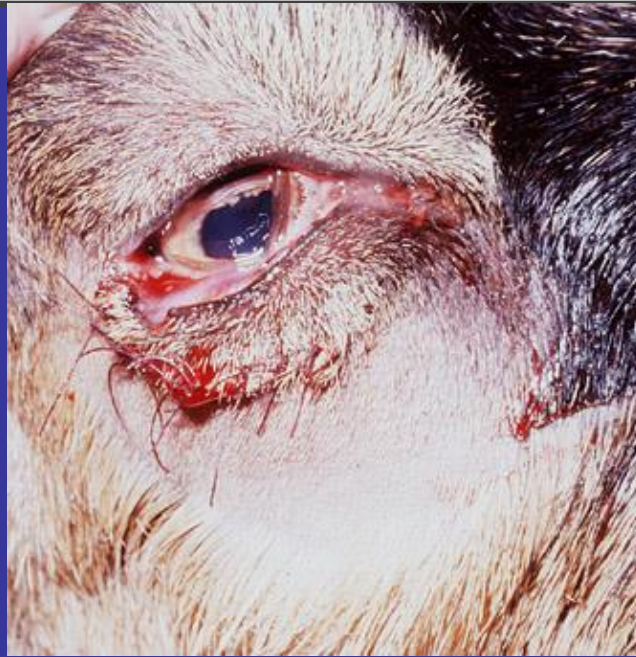

EUROBLEFARON MAKROPALPEBRAL FISSURE SENDROMU

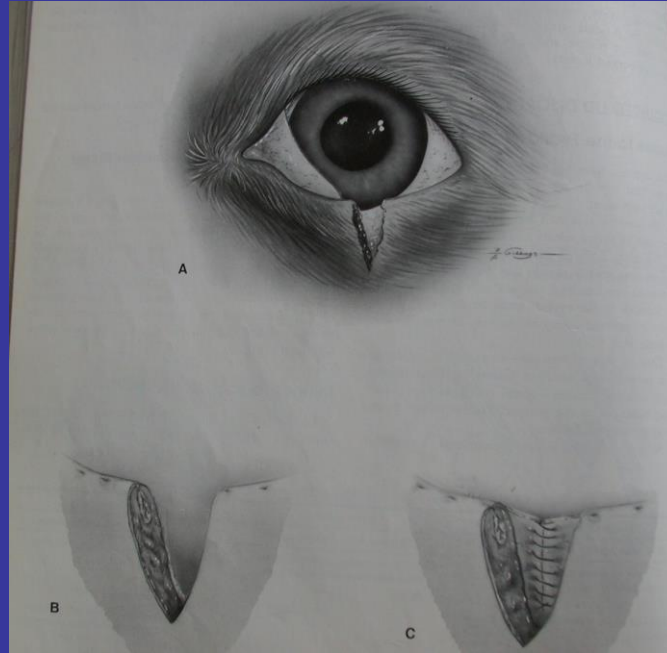
- Simetrik olarak palpebral fissurun geniş olmasıdır



KAPAK LASERASYONLARI



BASİT VERTİKAL KAPAK YIRTIKLARI



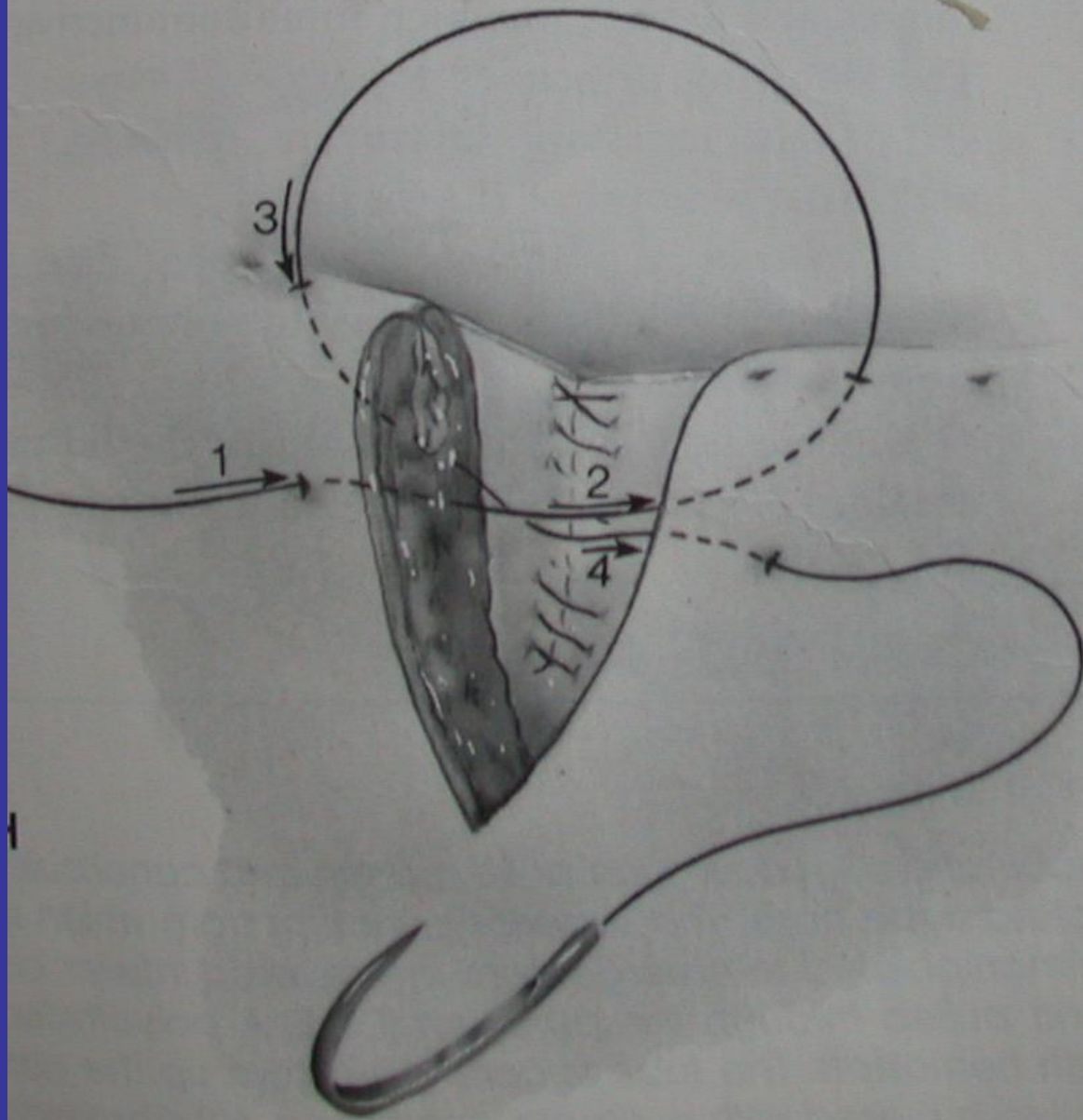

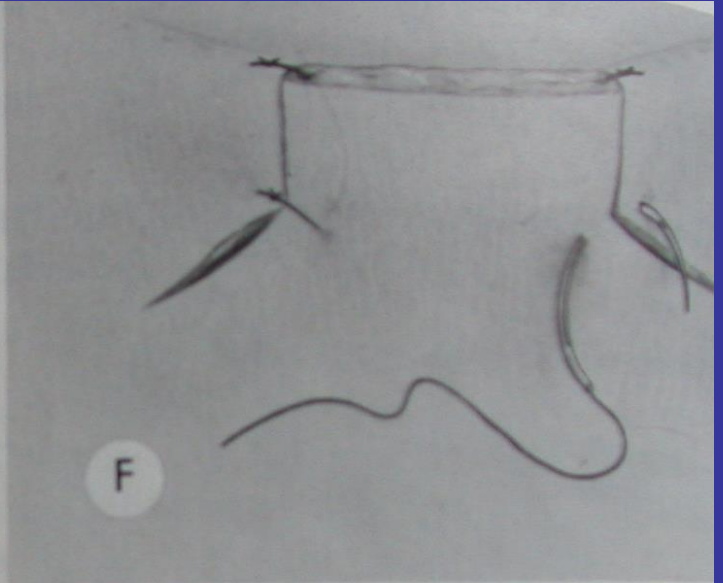
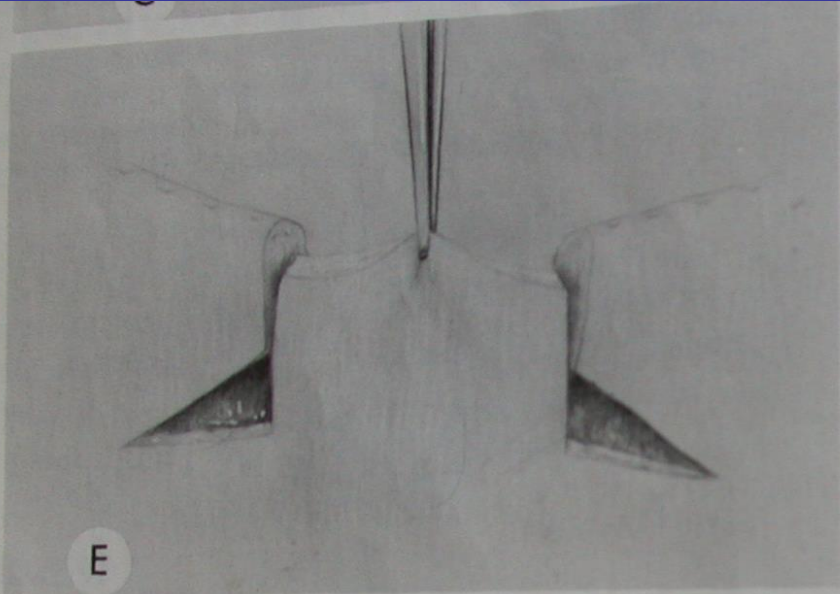


FIGURE 7-21-2. H. H. H.

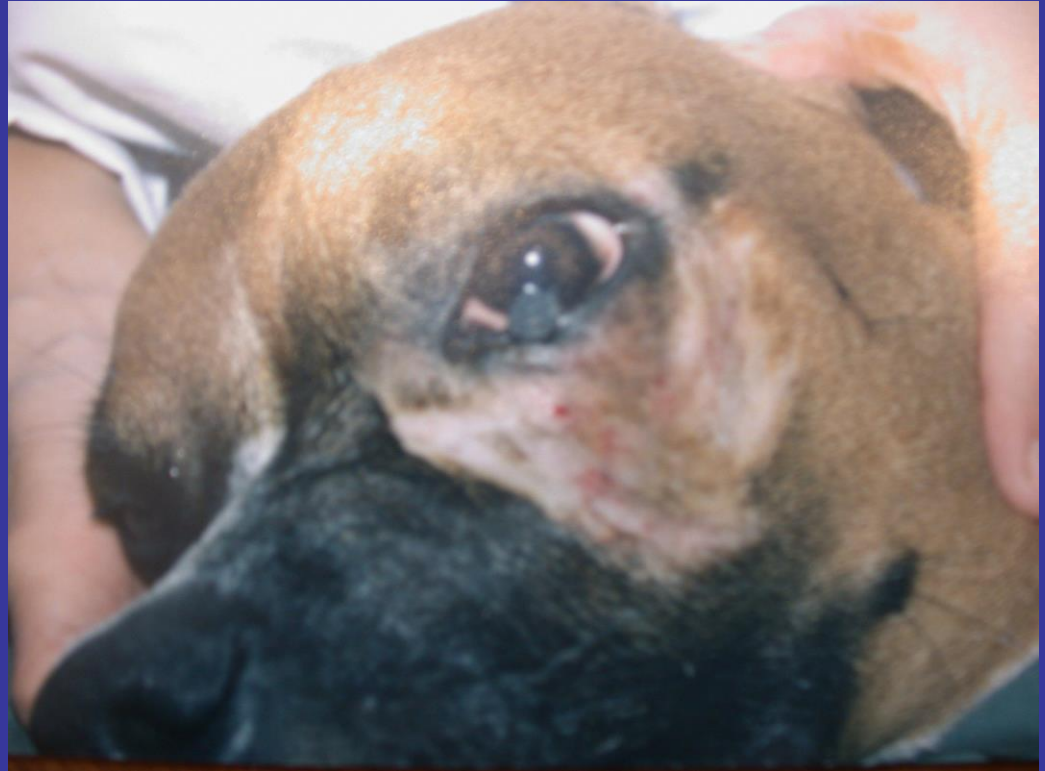

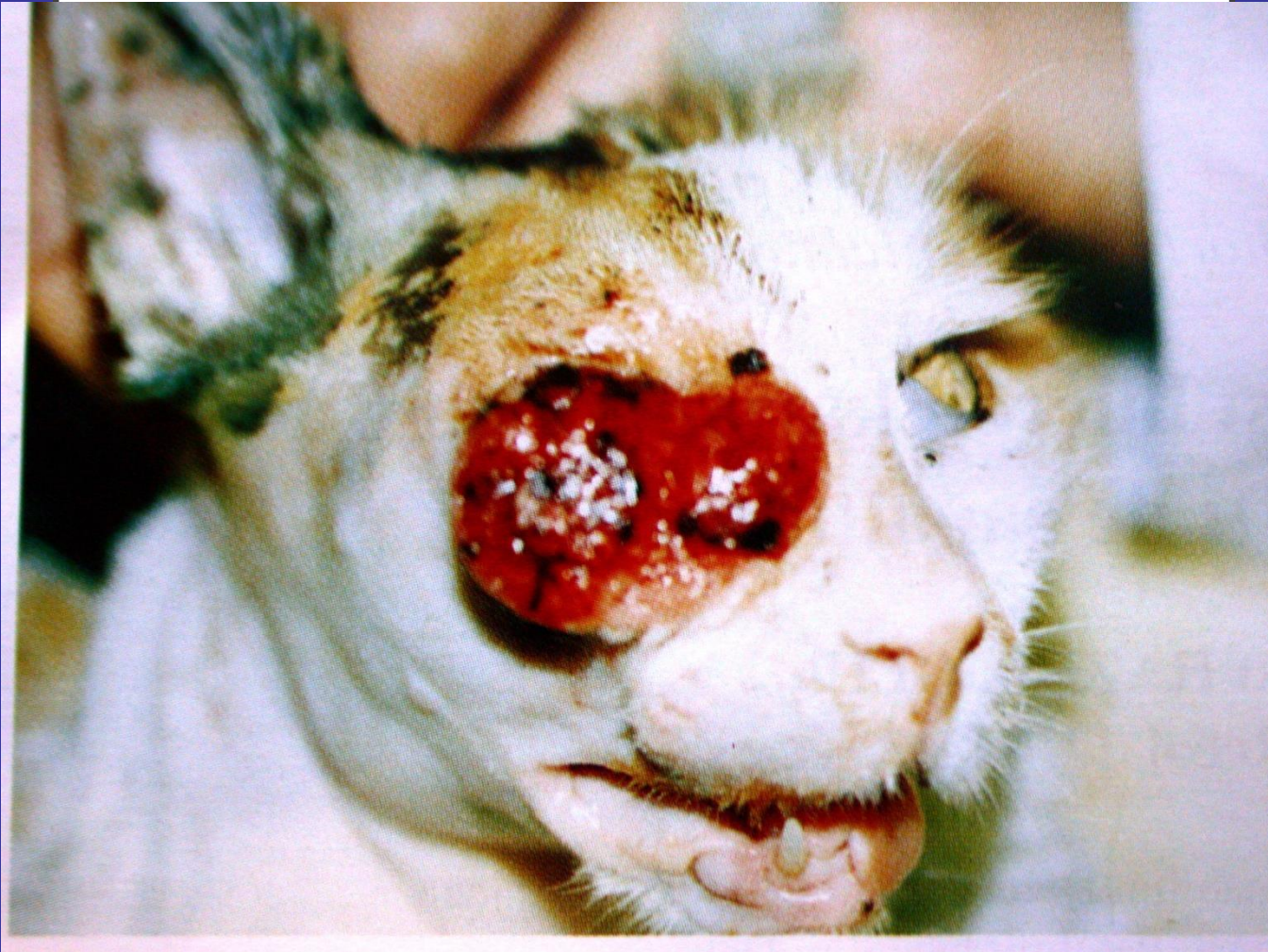GÖZKAPAĞI TÜMÖRLERİ (NEOPLAZMALARI)

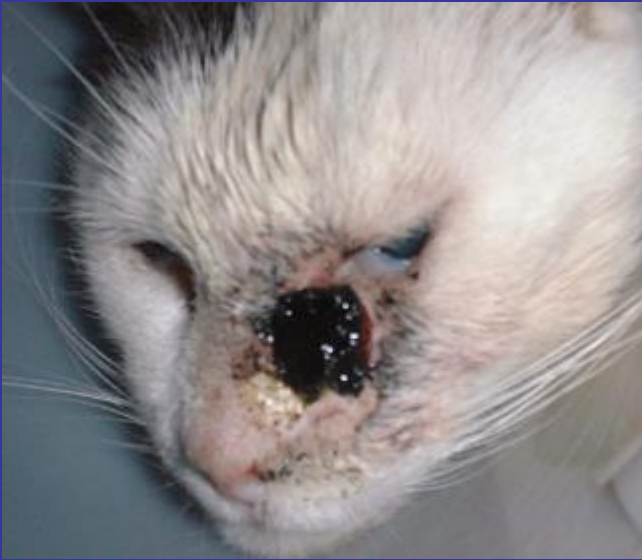- Köpek: tarsal adenoma,
squamos papilloma,
tarsal adenokarsinoma,
- Kedi: squamos cell karsinoma (SCC)
- At: SCC, fibrosarkoma

TARSAL ADENOMA

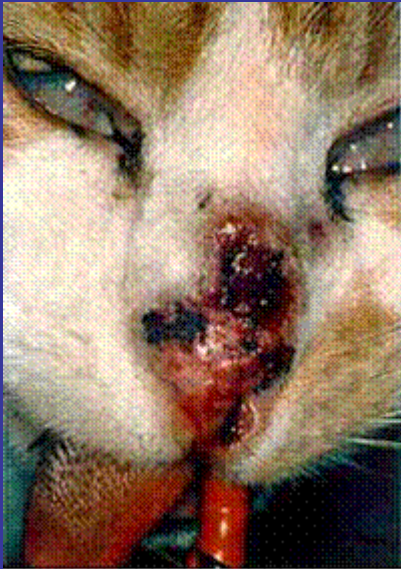- Köpeklerde en yaygın kapak neoplazisidir



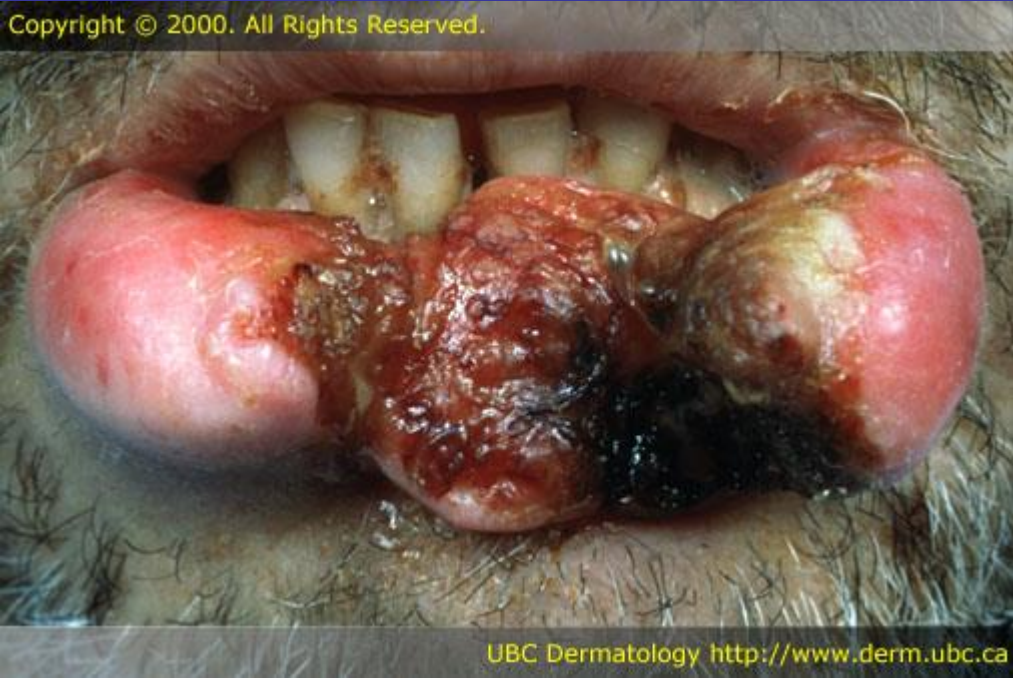



SCC



Nasal squamous cell carcinoma



Copyright © 2000. All Rights Reserved.

UBC Dermatology <http://www.derm.ubc.ca>