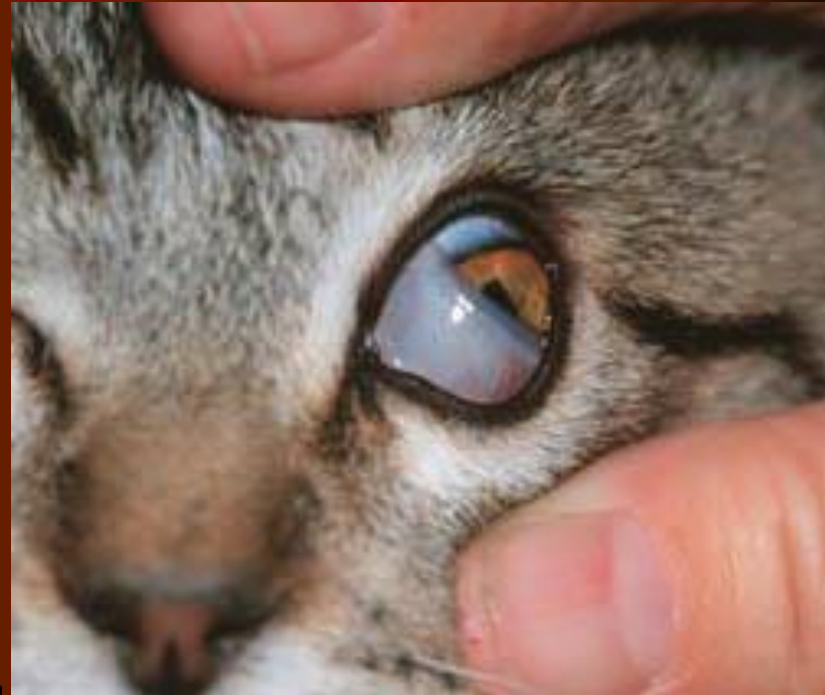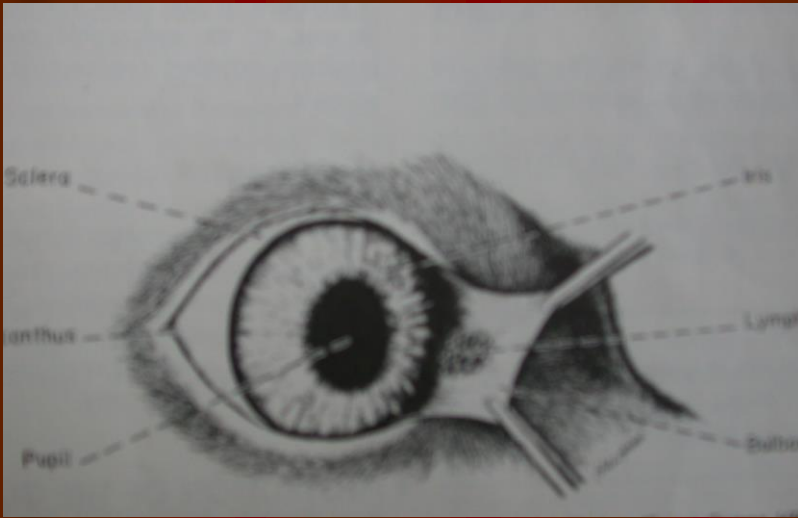


# 3. Göz Kapağı (membrana niktitans)

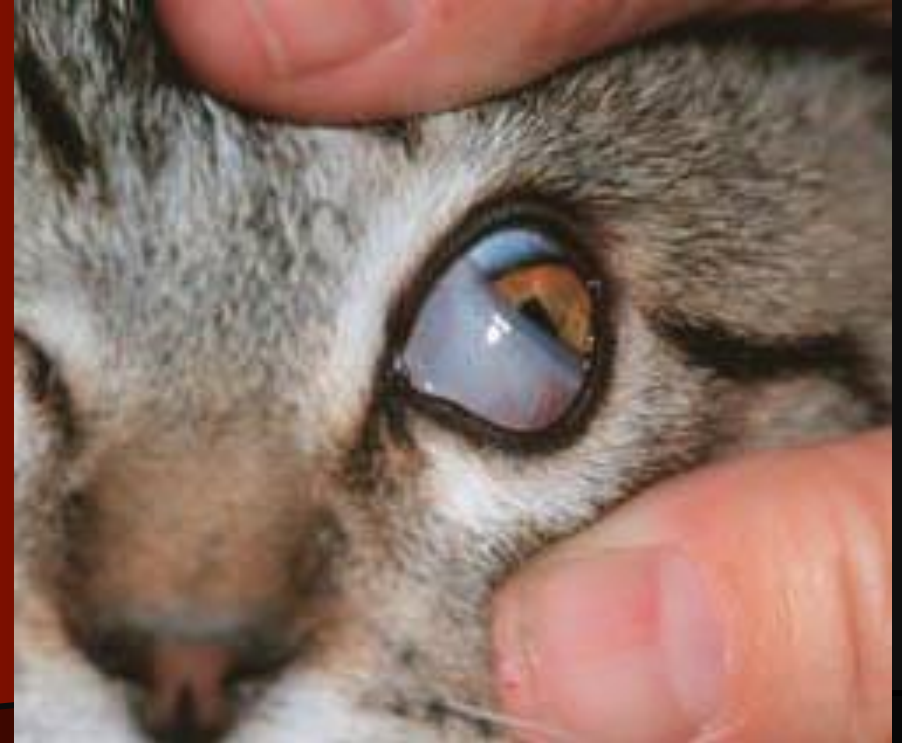

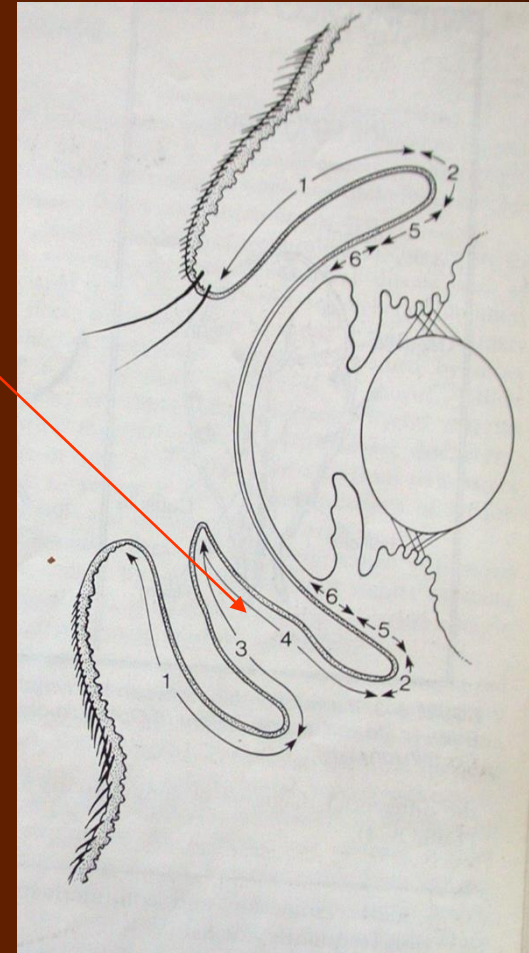
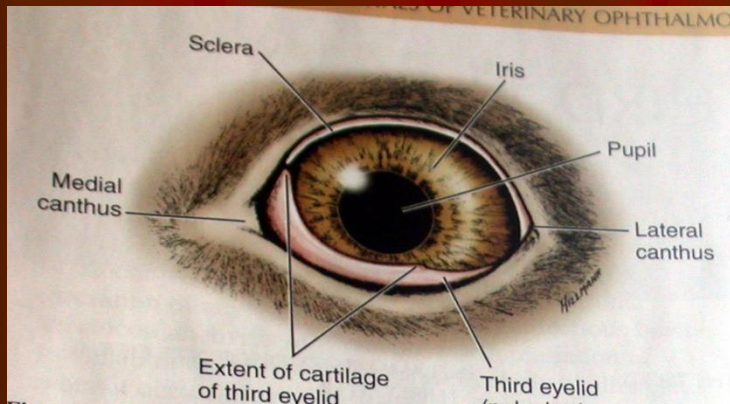
Dorsonazalden ventrotemporale doğru hareket



(photo courtesy Roy W. Bellhorn)

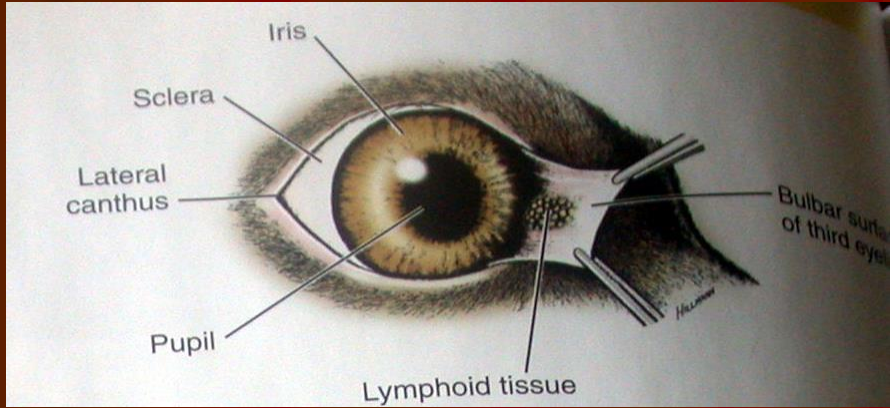
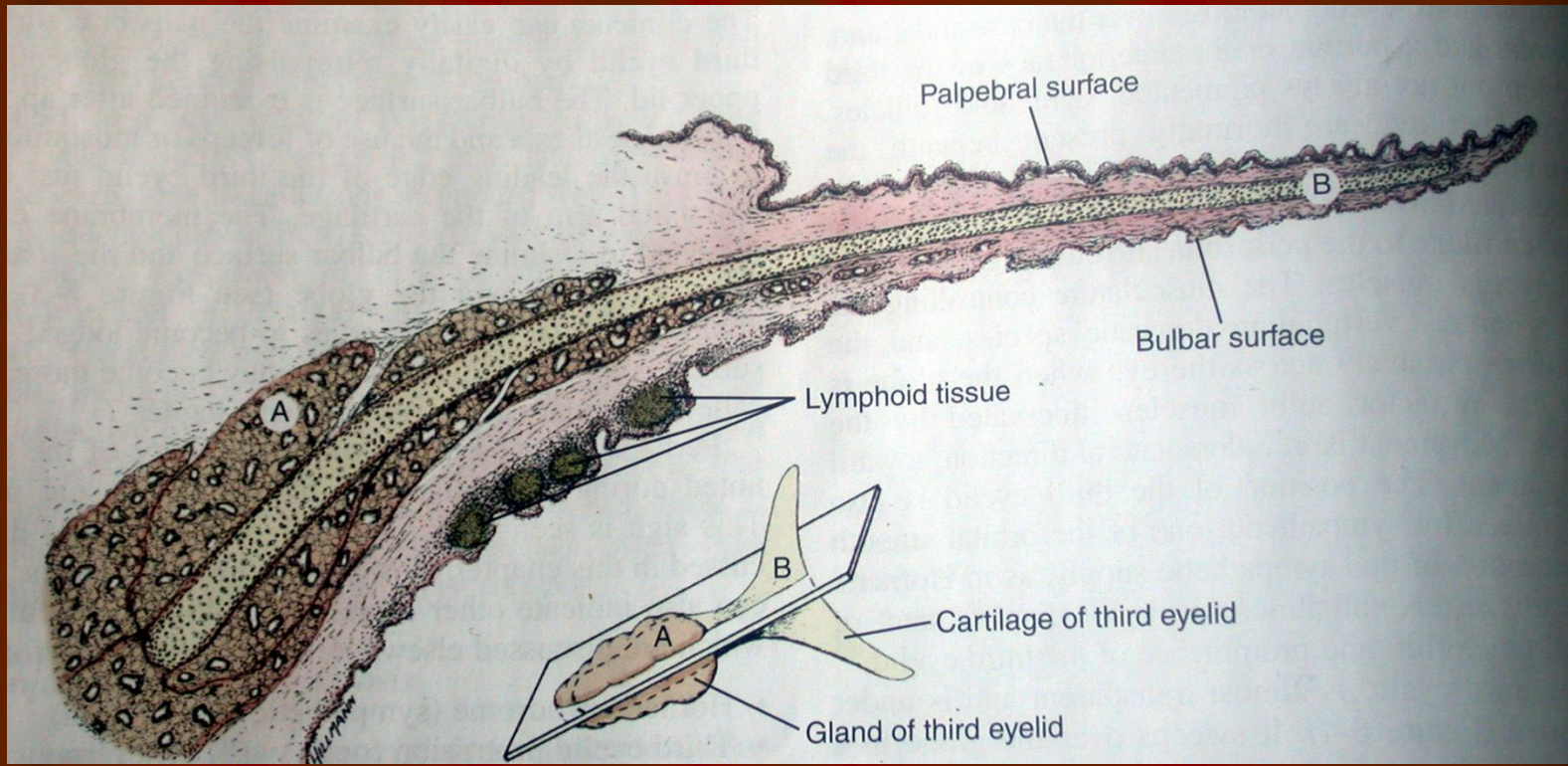
Süperiotemporal hareket





Mobil, protektif ve glandular yapıda olan MN kornea ve alt gözkapığı arasında yer alır.



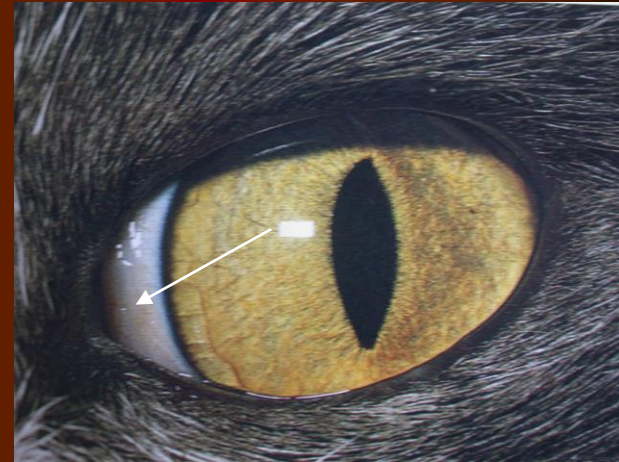
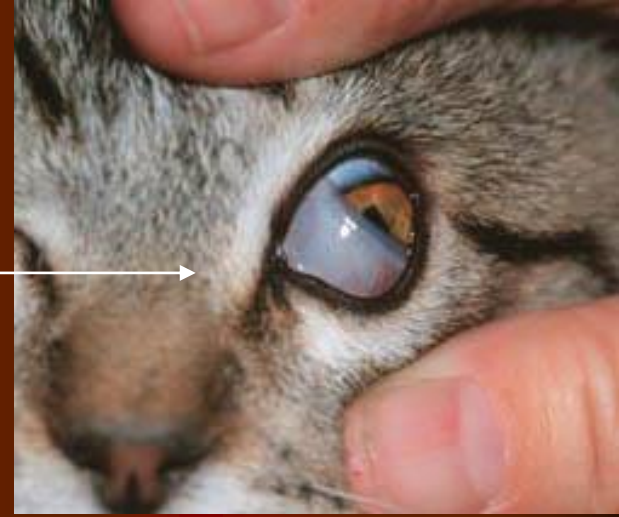


MN:

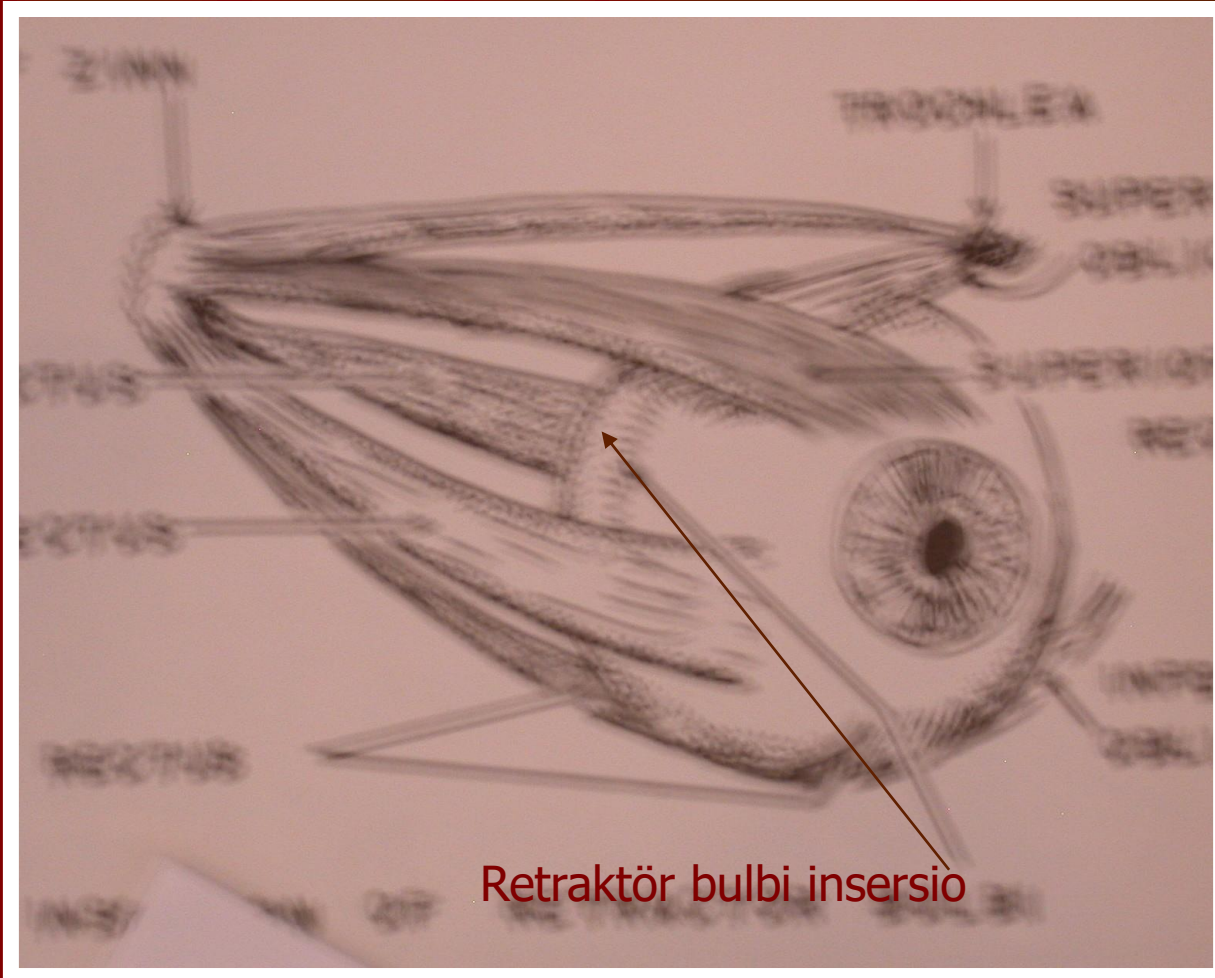
1. T şeklinde kıkırdak
2. Üçüncü göz kapağı bezi
3. Bulbar ve palpebral yüzü saran konjunktiva
4. Bulbar yüzeyde çok sayıda yüzlek lenf folikülü

# Üçüncü Göz Kapağının Düşmesi

- 3. göz kapağı  
M. Retraktör bulbi (N. Abducens : 6. kafa siniri tarafından innerve edilir) kontrakte olduğunda pasif olarak glob üzerinde hareket eder
- 3. göz kapağının glob üzerindeki normal pozisyonu ise orbital düz kaslardaki sempatik innervasyonla sağlanır







Retraktör bulbi insertio

(Horner's sendromu)

- Sempatik denervasyonda ise
- Myozis, Enoftalmus ve 3. göz kapağı protruzyonu gözlenir



# Haws sendromu

Bilateral MN düşmesi

Nedenler:

İshal

İdiopatik

Sempatik & parasempatik  
imbaansı

Sempatik tonosite azalması

Toro virus ?

Felin Disotonomi

Büyük hayvanlarda tetanoz

Tedavi: %1 fenilefrin





### 3. Göz Kapağı Bezinin İşlevi

- Gland seromukoid salgı yapar
- PTF'nin %50 sini oluşturur, İmmunglobulin üretir
- PTF nin kornea üzerine yayılmasını sağlar, korneayı kurumaktan korur
- Domuz ve bazı laboratuvar hayvanlarında orbita içinde 3. göz kapağı glandının daha derin bir bölümü bulunur (Harder's glandı)

# 3. Göz kapağı alınır mı?

Korneal ekspoziyonda artış

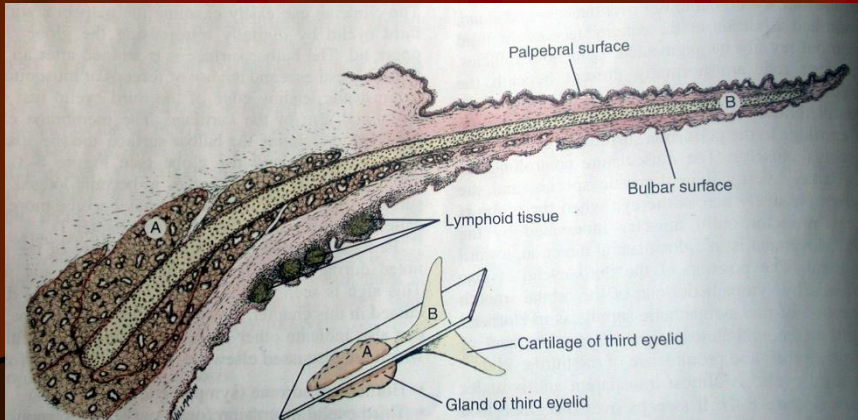
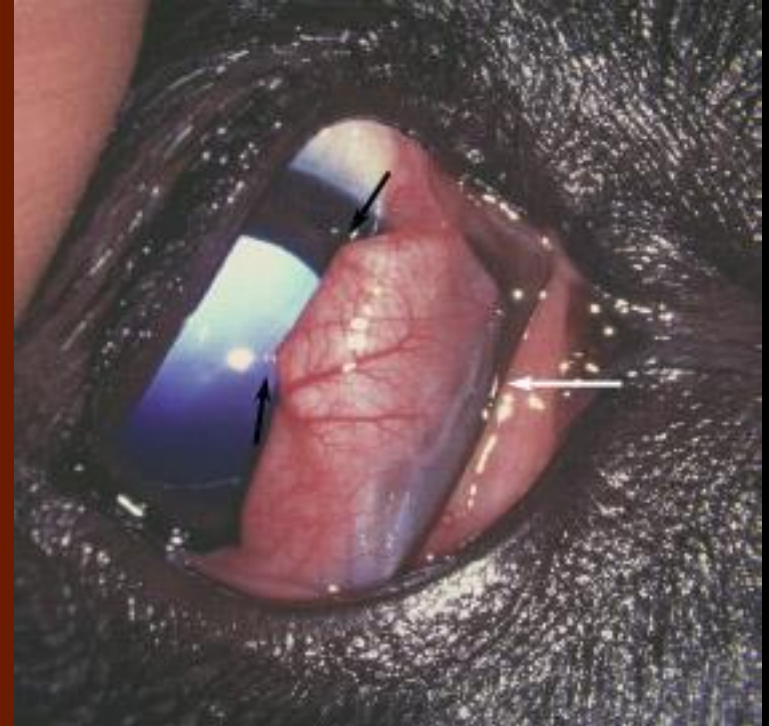Kronik konjunktivitis (genellikle purulent)

KCS

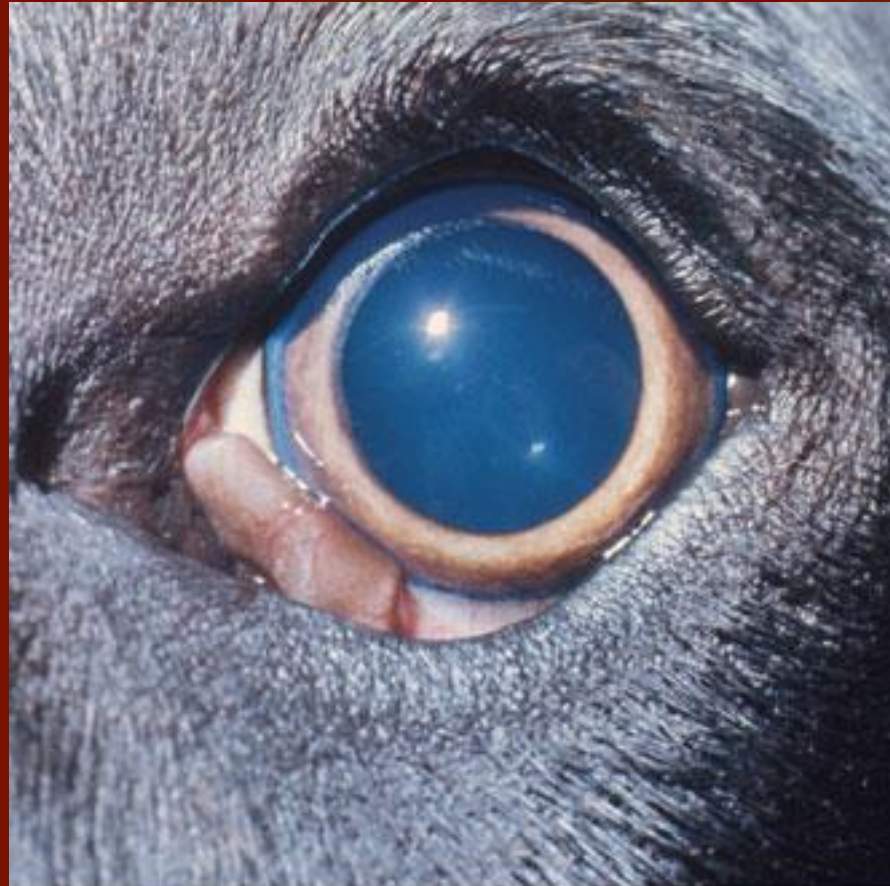# 3. Göz kapağı eversiyonu

(Saint Bernard, İris seter)

- T kıkırdağın iç yüzündeki büyüme oranı daha hızlıdır

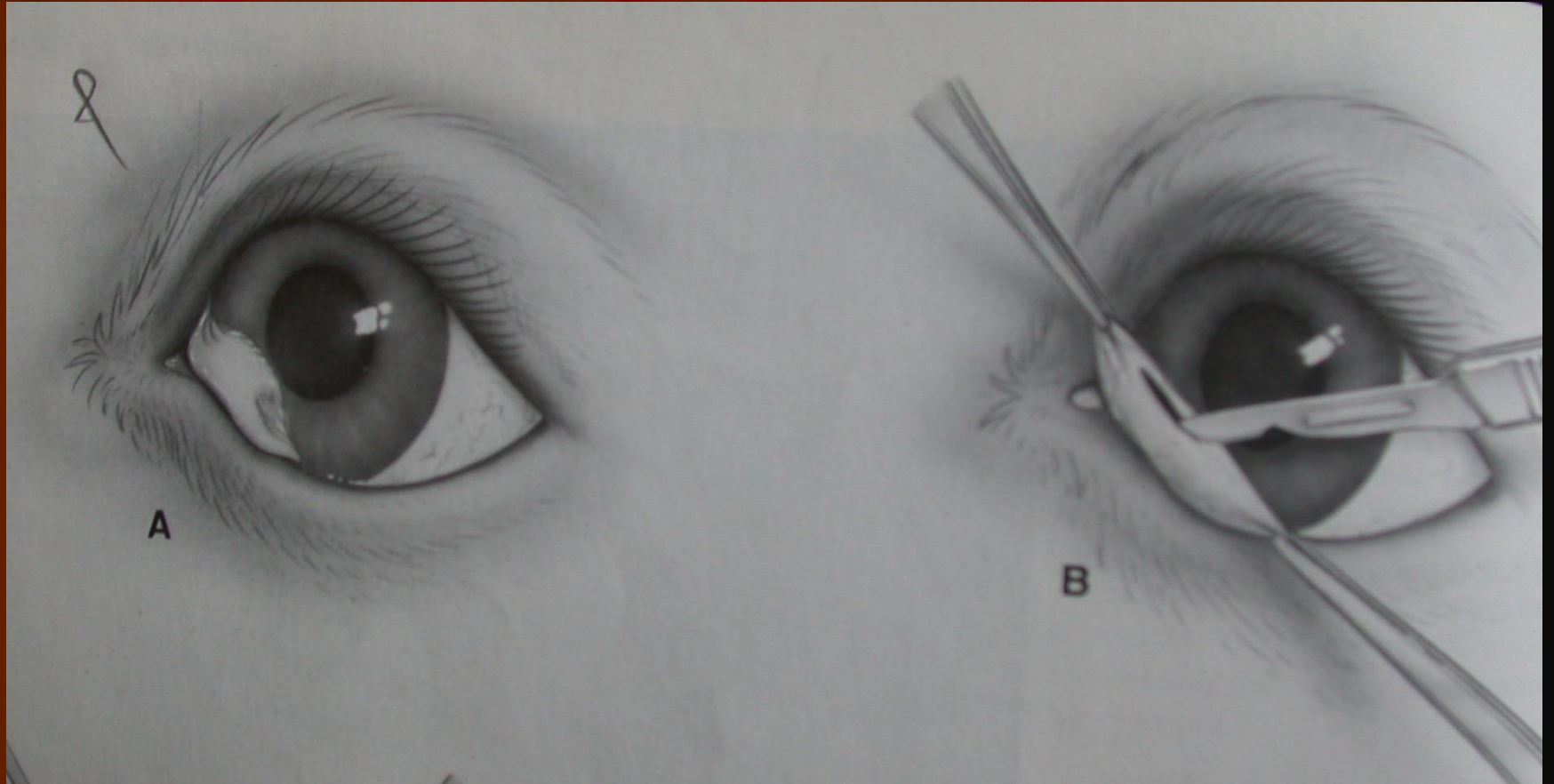


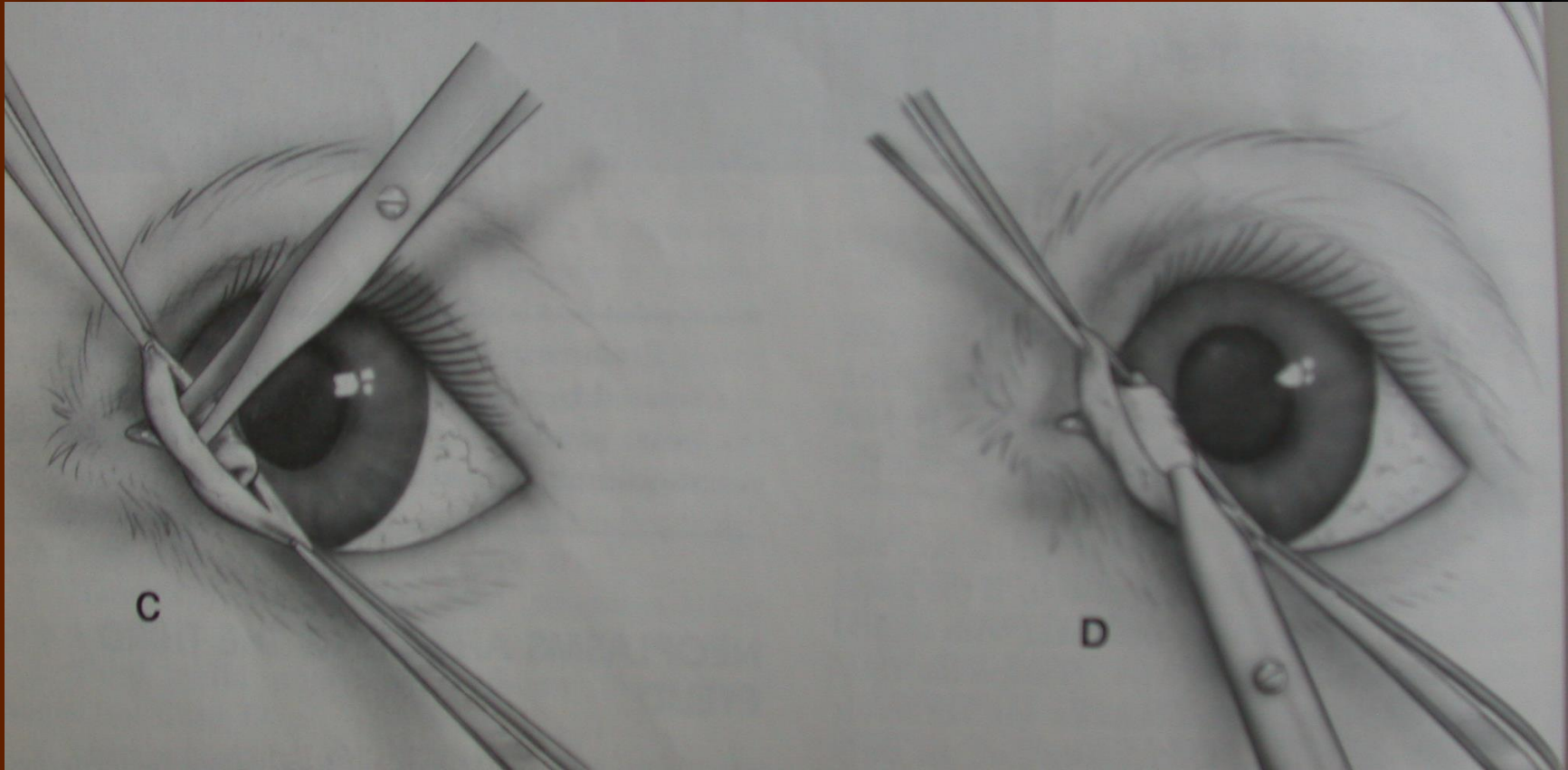




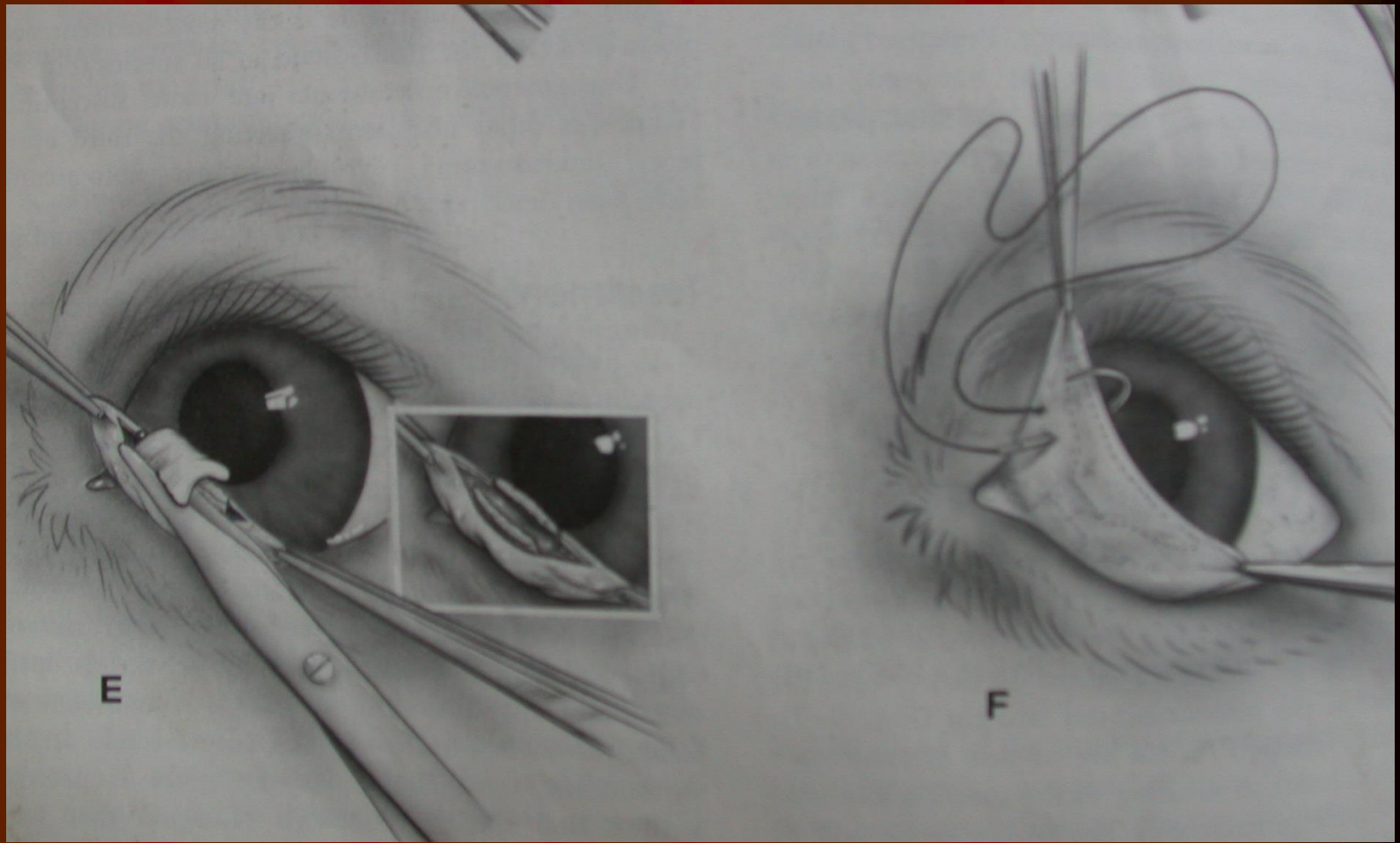
**Eversion of cartilage of third eyelid**

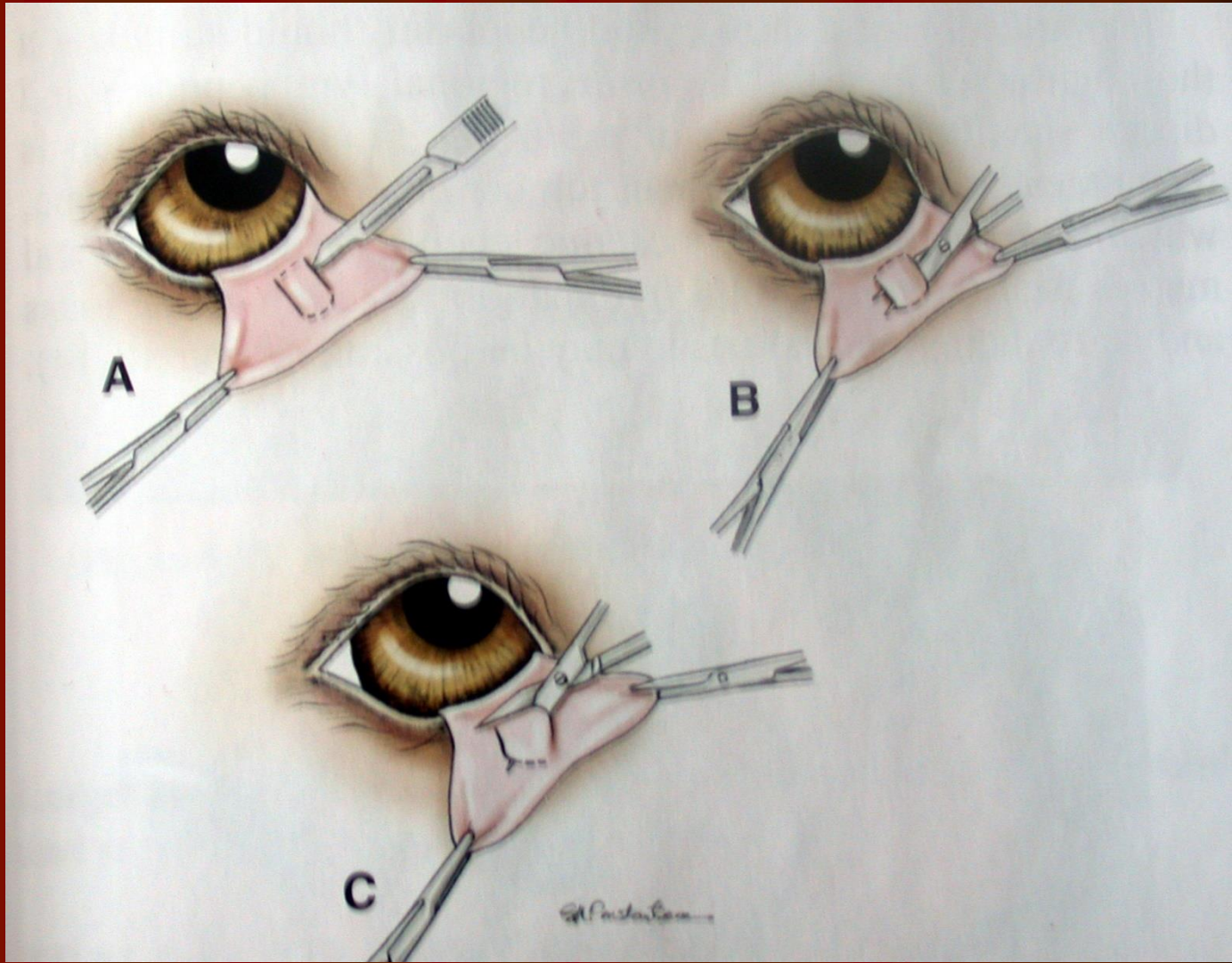
# Cerrahi





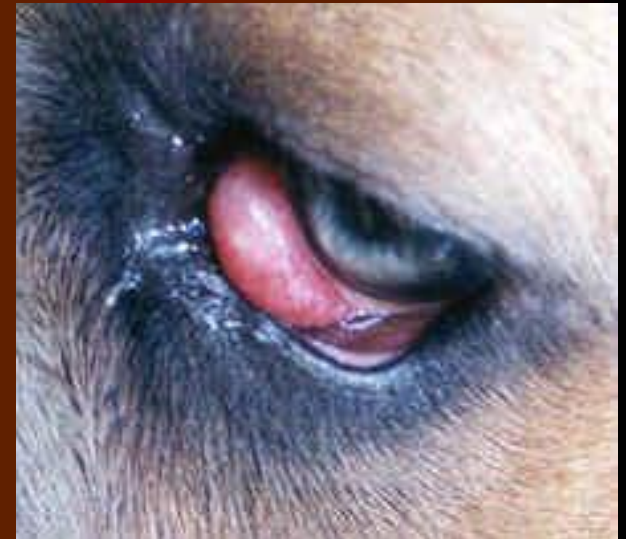
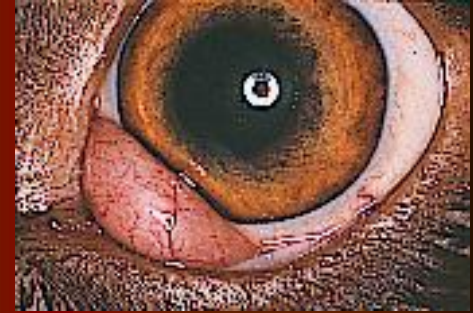
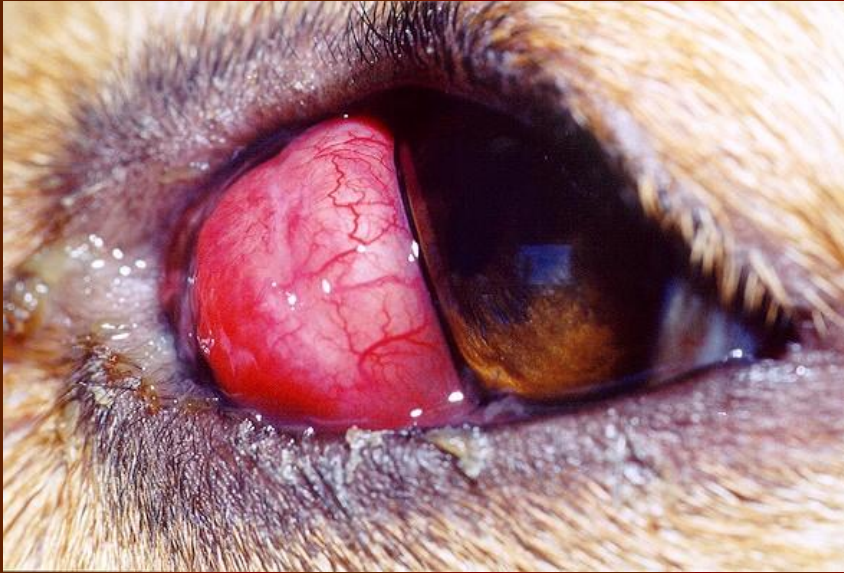




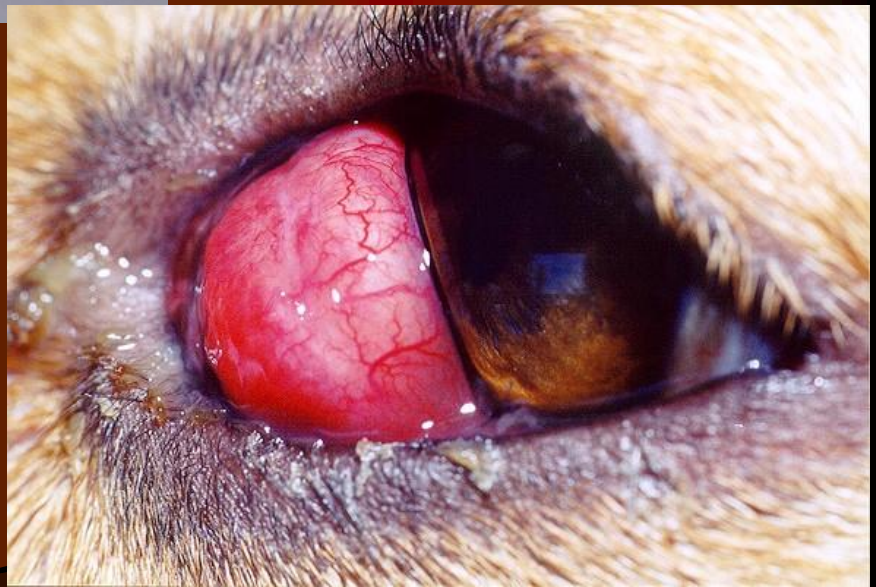
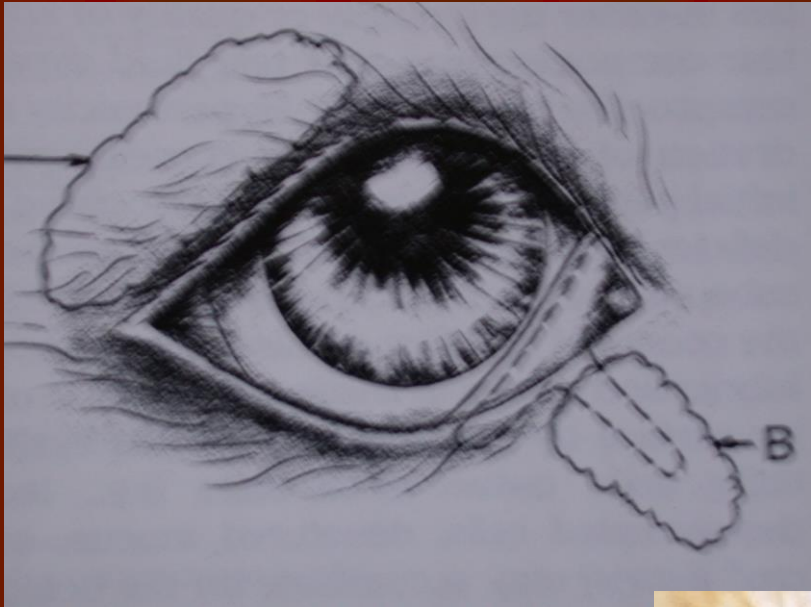### 3. Göz kapağı glandı protruzyonu (Cherry eye: kiraz göz)

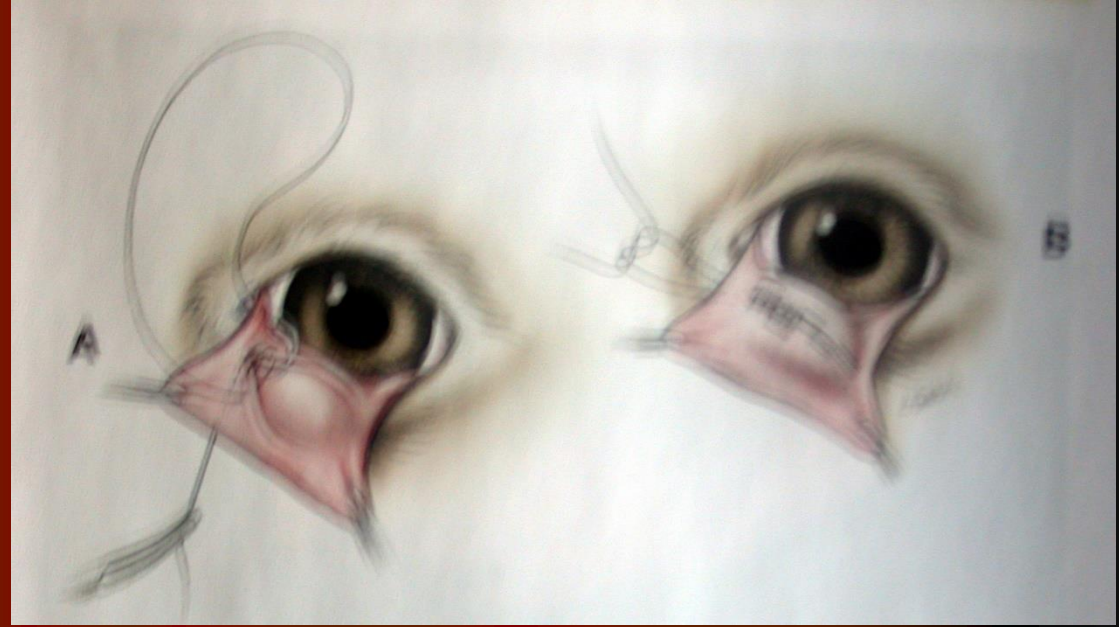



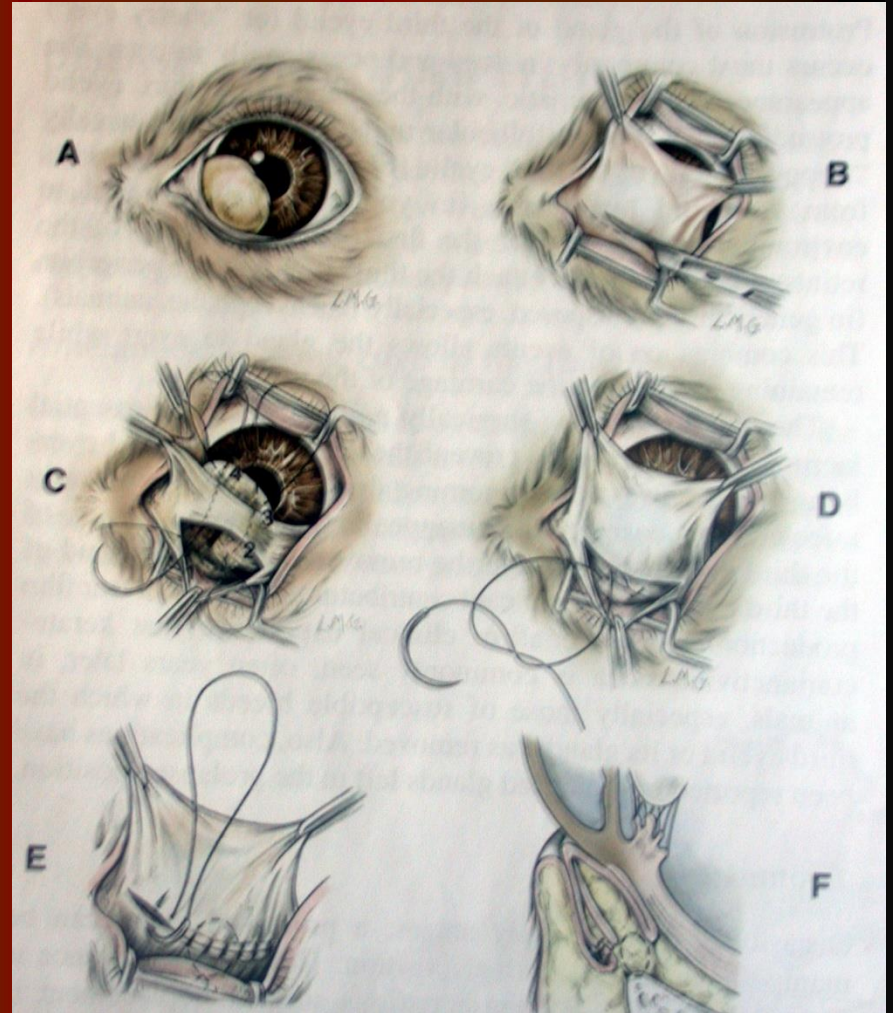


# Morgan cep tekniđi

- Paralel ensizyon
- Gland cep iđine sıkıřtırılır
- S¼rekli dikiřler ile dikilerek g¼m¼l¼r

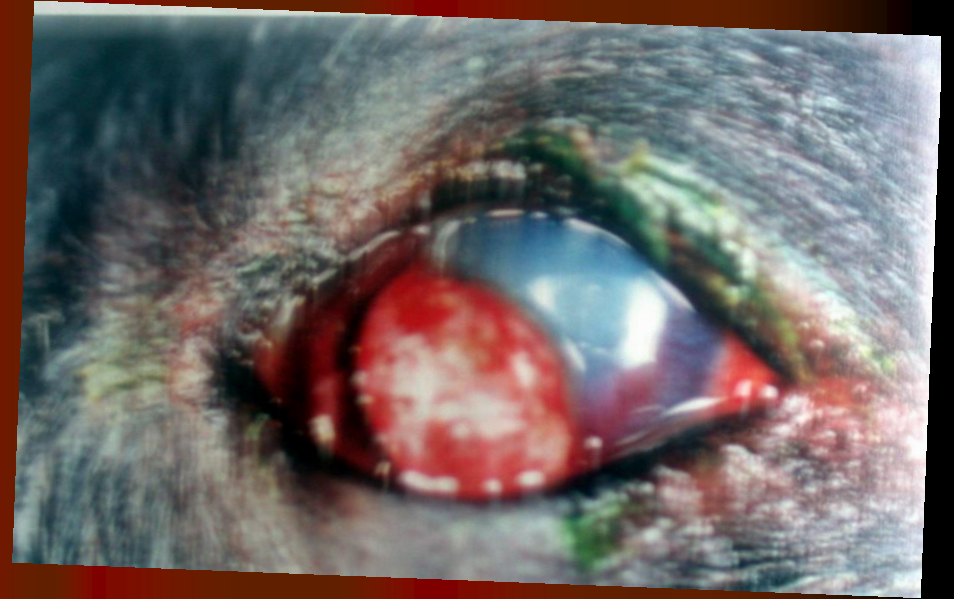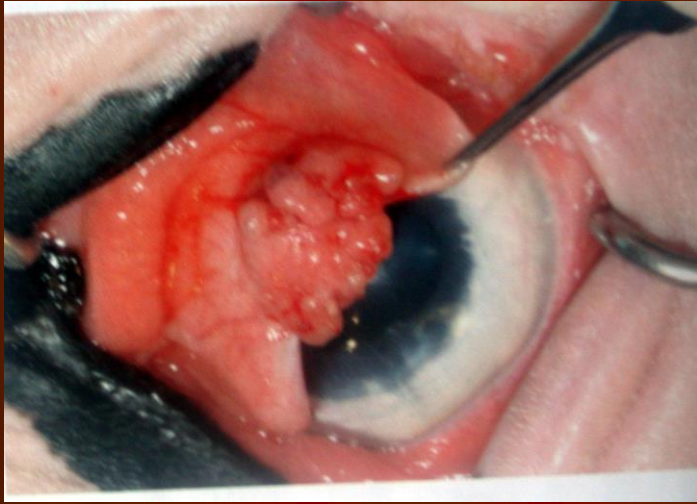


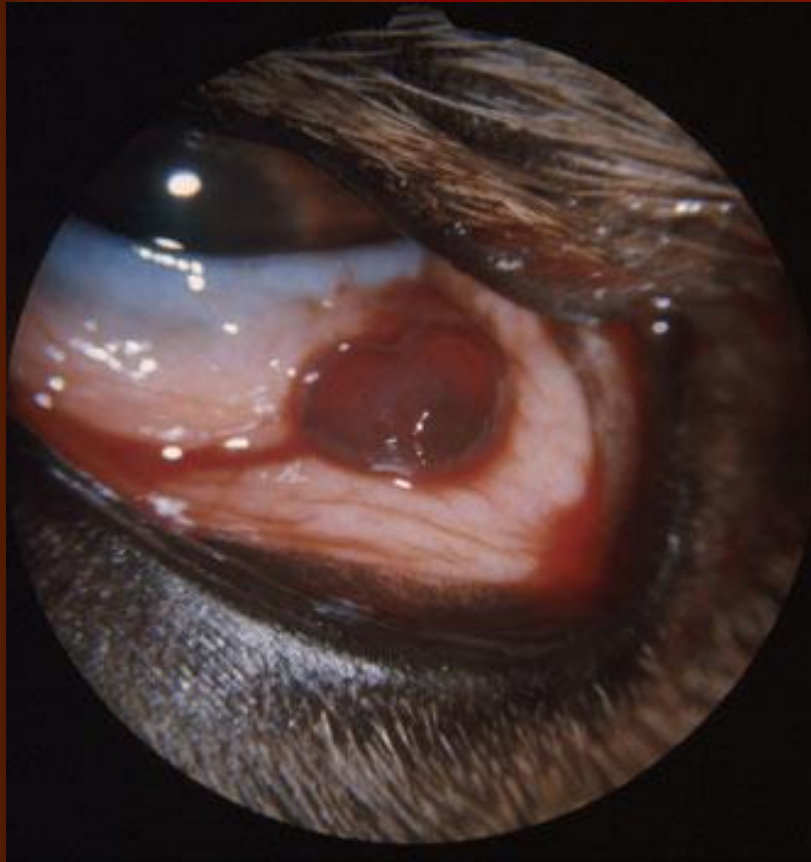
## Orbital kemere tutturulması



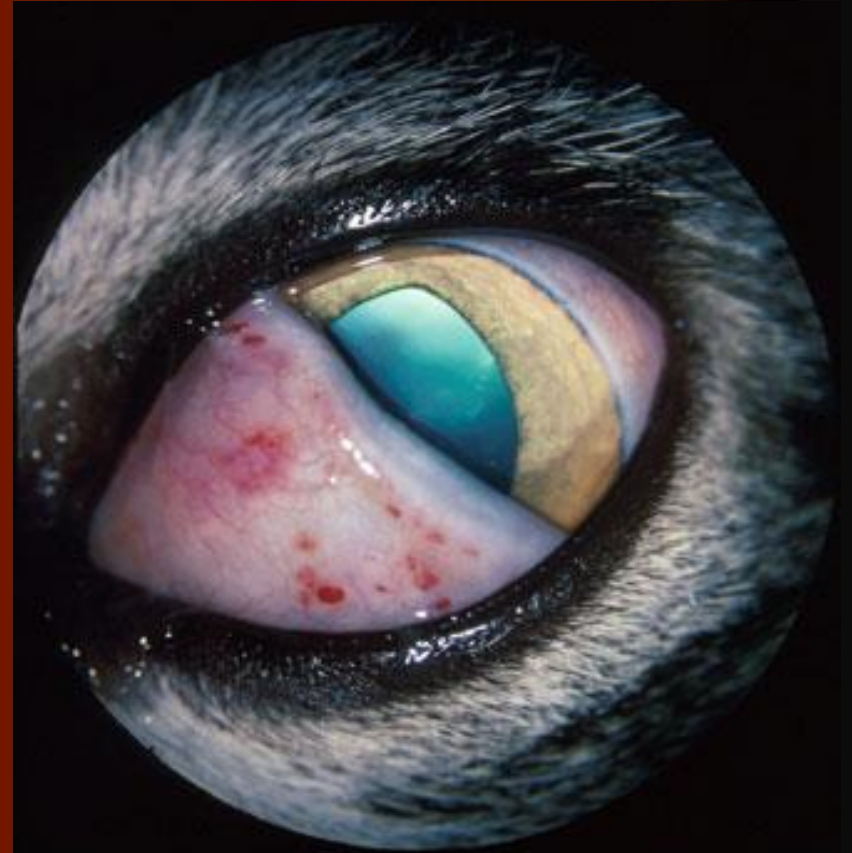


### 3. Göz kapağı marjini neoplazmaları

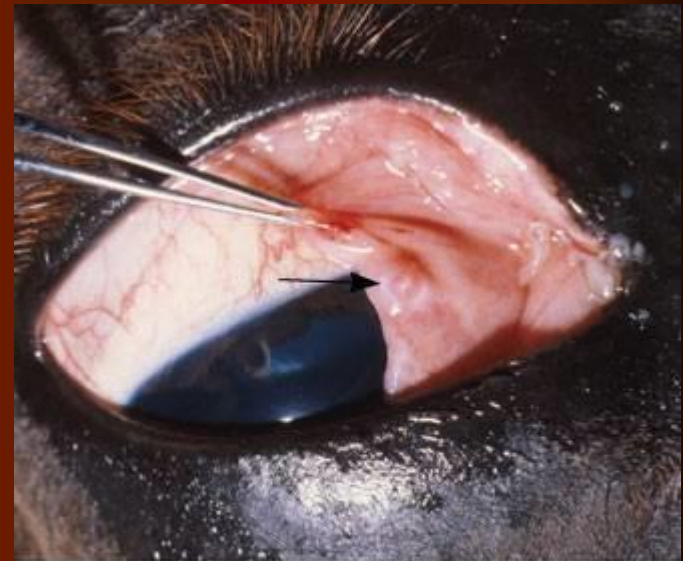
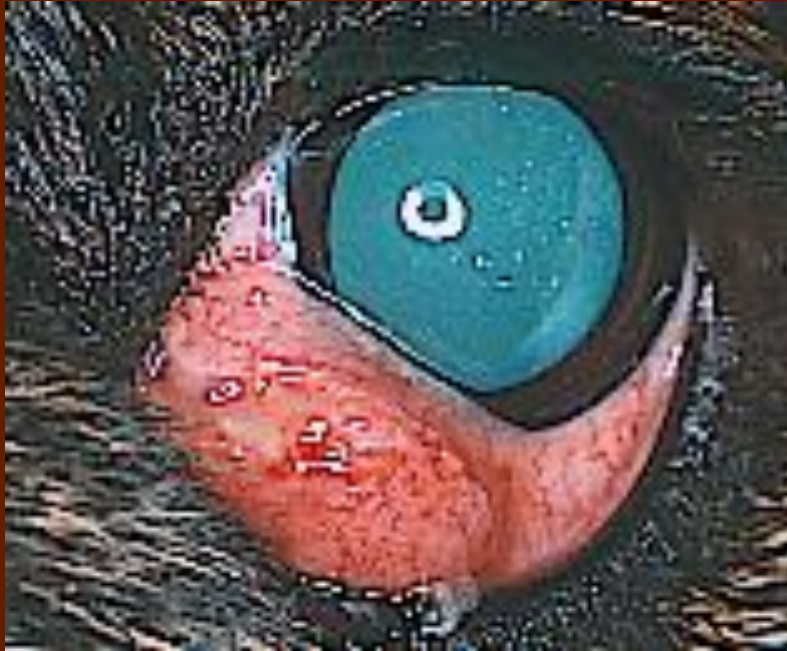



**Hemangioma, third eyelid**  
(photo courtesy Robert Peiffer)

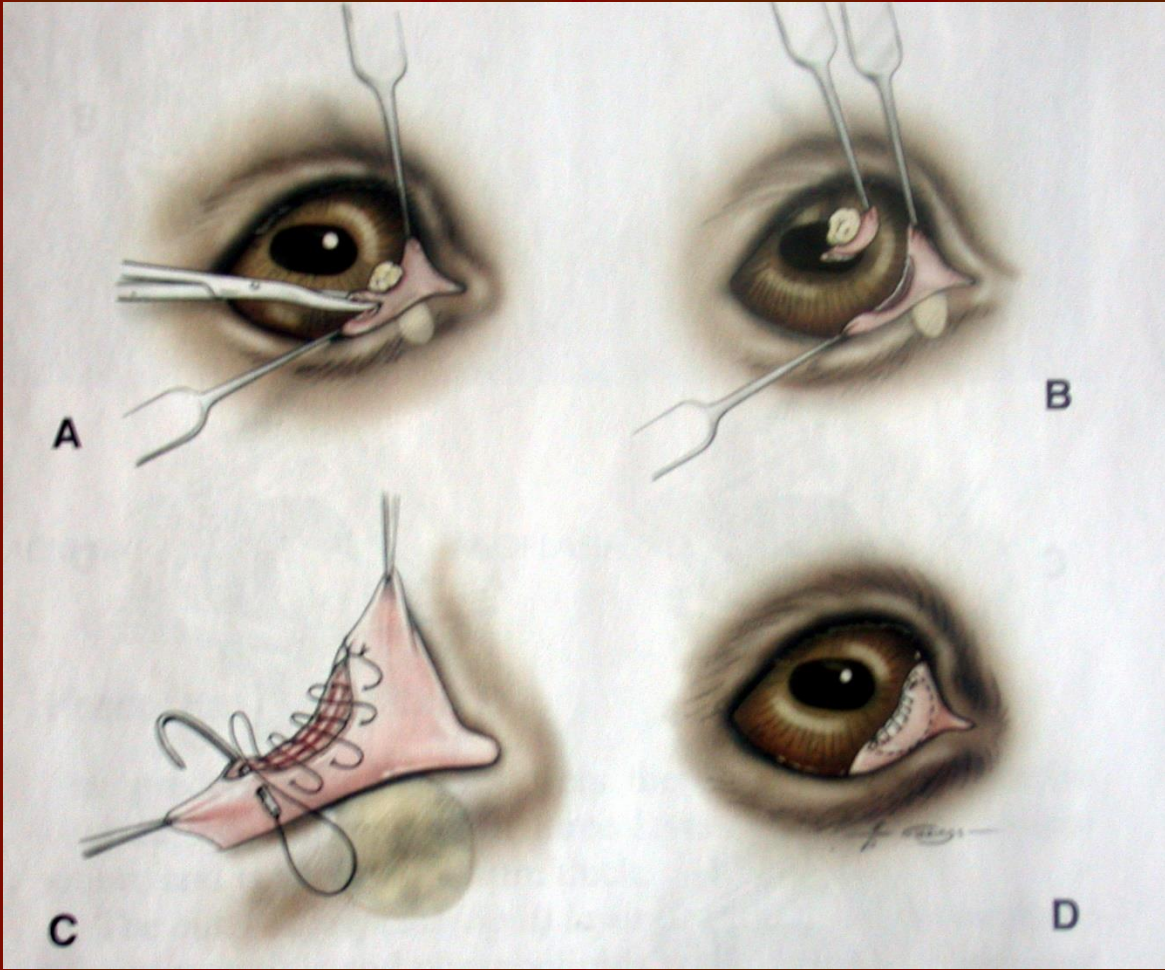

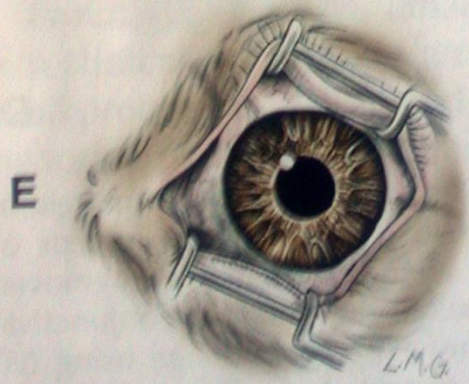
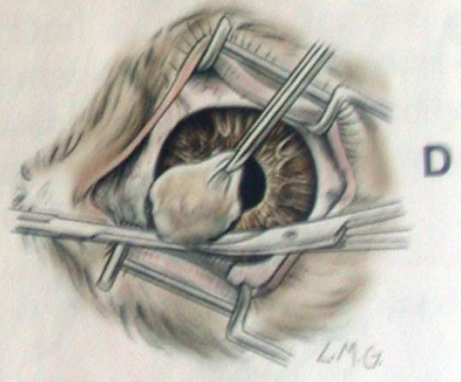

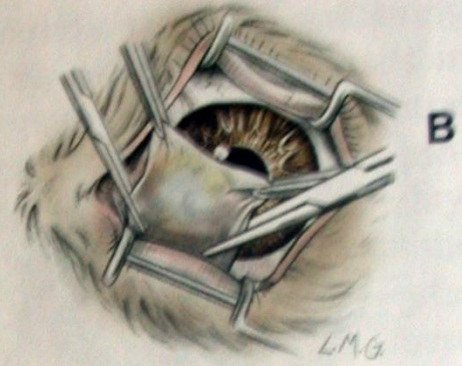
**Lymphosarcoma involving third eyelid, causing petechiae**



**Squamous cell carcinoma, horse; arrow points to mass involving third eyelid**

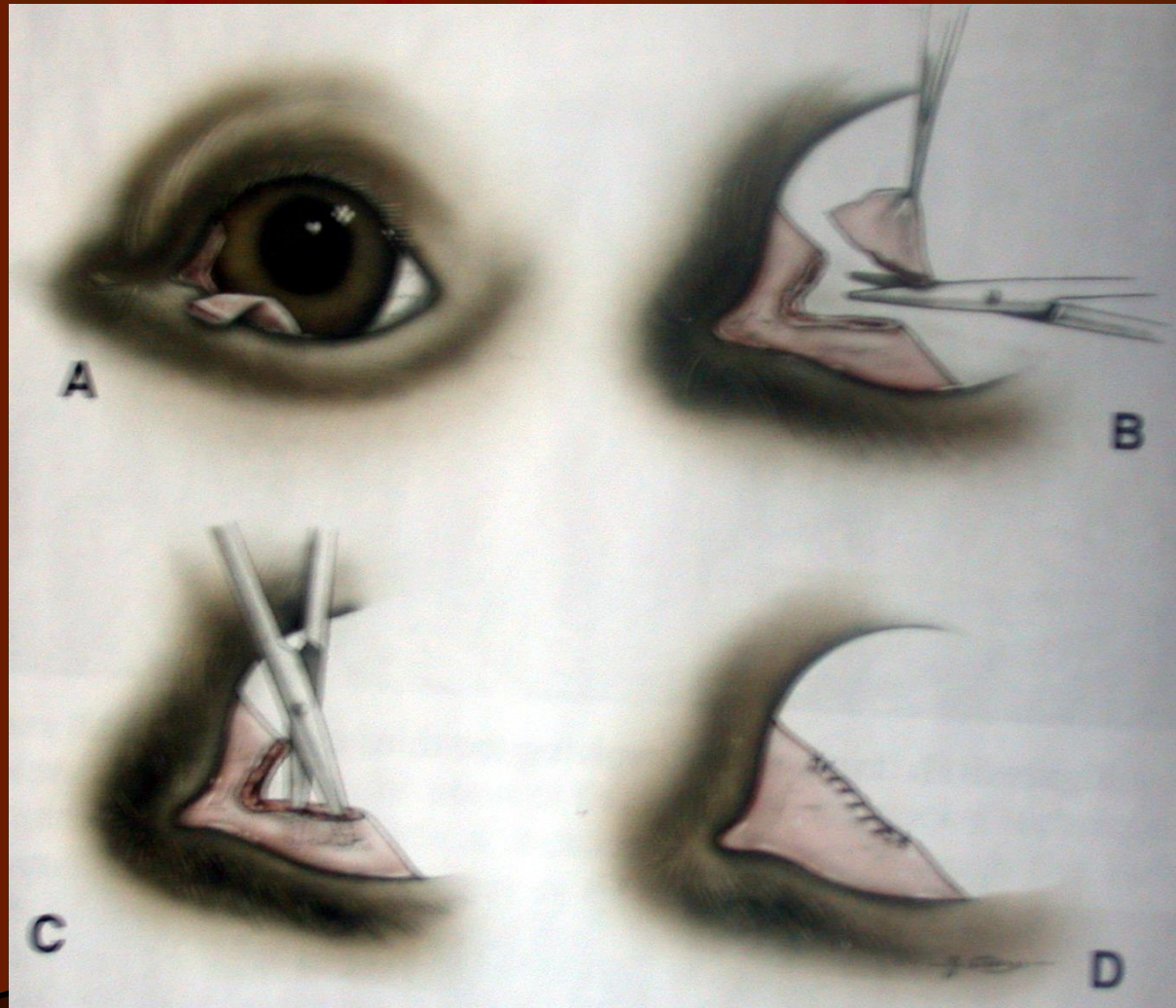




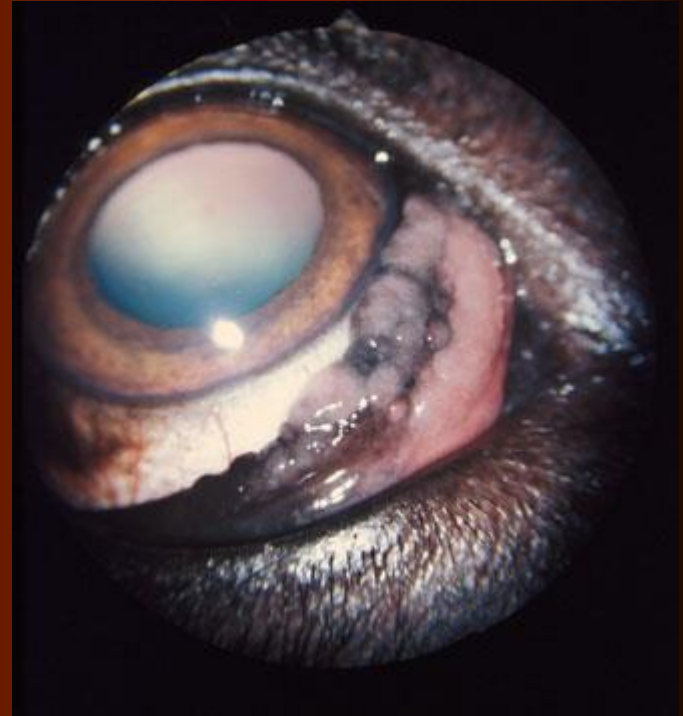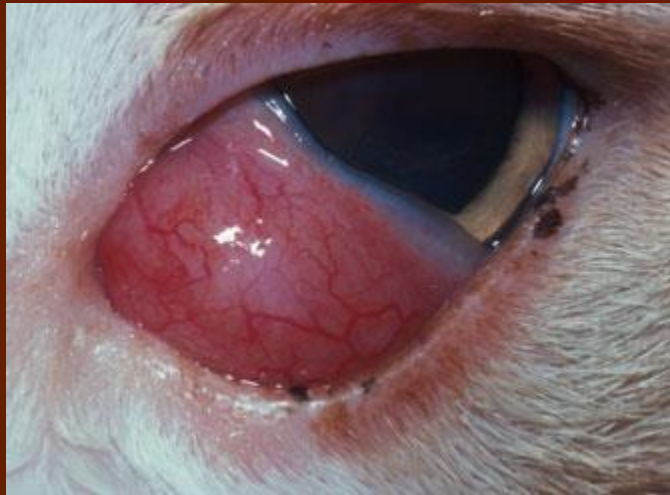



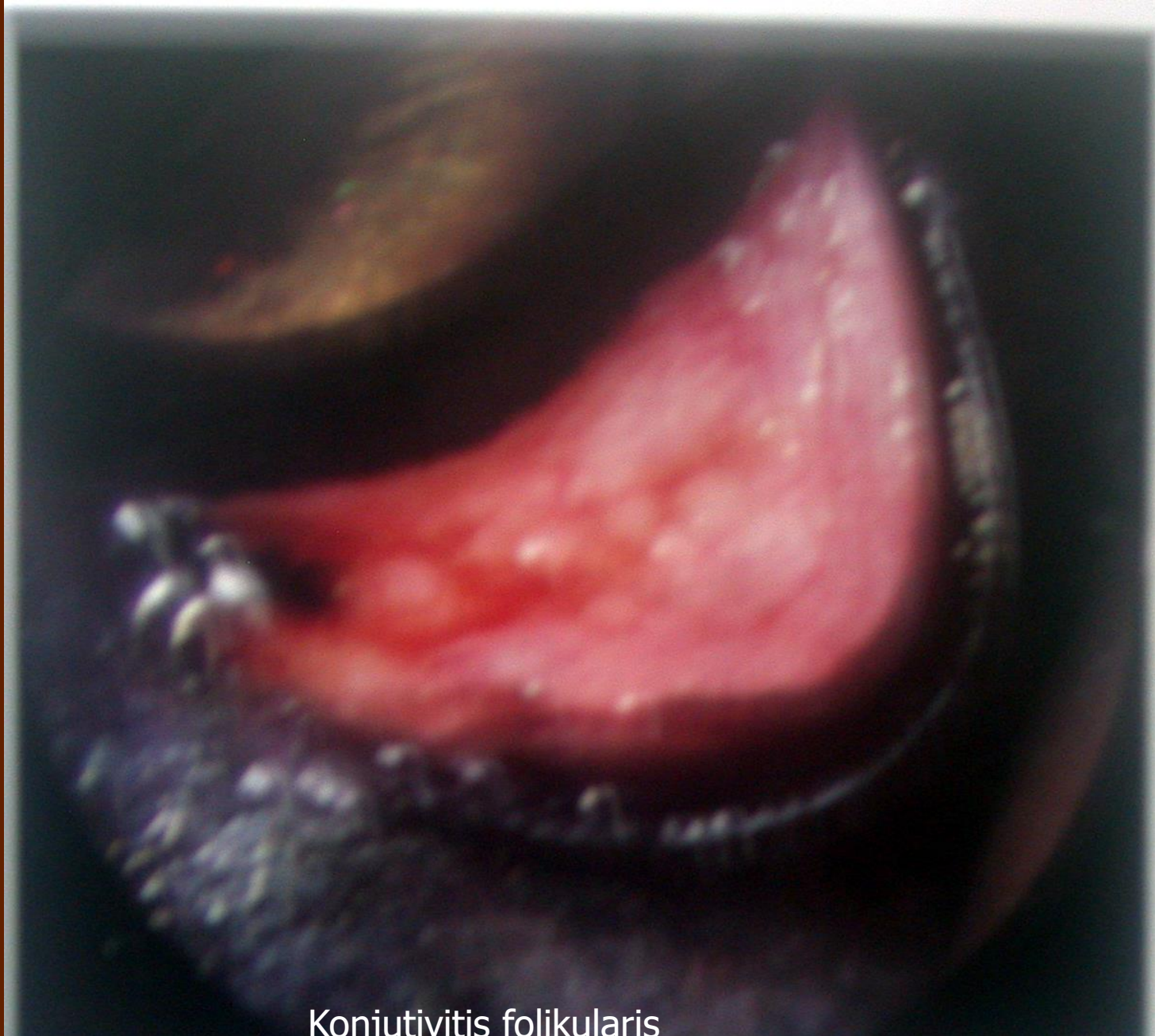
# Rekonstruksiyon









Konjunktivitis folikularis

